



HAL
open science

Acute cholangitis: Diagnosis and management

A. Sokal, A. Sauvanet, B. Fantin, V. de Lastours

► To cite this version:

A. Sokal, A. Sauvanet, B. Fantin, V. de Lastours. Acute cholangitis: Diagnosis and management. Journal of Visceral Surgery, 2019, 156, pp.515 - 525. <10.1016/j.jviscsurg.2019.05.007>. <hal-03489194>

HAL Id: hal-03489194

<https://hal.science/hal-03489194v1>

Submitted on 21 Jul 2022

HAL is a multi-disciplinary open access archive for the deposit and dissemination of scientific research documents, whether they are published or not. The documents may come from teaching and research institutions in France or abroad, or from public or private research centers.

L'archive ouverte pluridisciplinaire HAL, est destinée au dépôt et à la diffusion de documents scientifiques de niveau recherche, publiés ou non, émanant des établissements d'enseignement et de recherche français ou étrangers, des laboratoires publics ou privés.



Distributed under a Creative Commons CC BY-NC 4.0 - Attribution - Non-commercial use - International License

Angiocholites : diagnostic et prise en charge

Acute cholangitis : diagnosis and management

Authors: A. Sokal^a, A. Sauvanet^b, B. Fantin^{a,c}, V. de Lastours^{a,c}

a: Internal medicine unit, Hôpital Beaujon, Assistance-Publique des Hôpitaux de Paris

b: Hepatic and pancreatic surgery unit, digestive disease center, Hôpital Beaujon, Assistance-Publique des Hôpitaux de Paris

c: IAME, UMR 1137 Université Paris Diderot et INSERM, Paris 75018.

Corresponding author:

Victoire de Lastours,

+33 (1) 71 11 46 20

victoire.de-lastours@aphp.fr

Mise au point : Angiocholites : diagnostic et prise en charge

Angiocholites : diagnostic et prise en charge

Acute cholangitis : diagnosis and management

Mots clés : angiocholite, étiologie, épidémiologie, prise en charge.

Keywords : acute cholangitis, etiology, epidemiology, management.

Key points

- Acute cholangitis diagnosis is primarily clinical, and confirmed by biological and radiological data.
- While it has multiple etiologies, lithiasic and neoplastic obstacles are the two main causes.
- The most frequently found germs are *Escherichia coli* and *Klebsiella spp.*
- Treatment associates antimicrobial therapy targeting *Enterobacteriaceae* and adapted to the environment (particularly in cases involving biliary prosthesis or bilio-digestive anastomosis) associated with endoscopic draining of the biliary ducts

Résumé :

L'angiocholite est une infection de la bile et des voies biliaires, secondaire dans la majorité des cas à une obstruction des voies biliaires. Les étiologies en sont multiples, dominées par la maladie lithiasique et les néoplasies. Le diagnostic clinique repose sur la triade de Charcot (douleur, fièvre, ictère) mais sa sensibilité insuffisante a mené à son remplacement par un score plus complexe, ajoutant des données biologiques et radiologiques, validé par les Tokyo Guidelines depuis 2007. En cas de suspicion diagnostique, l'échographie abdominale permet une exploration rapide des voies biliaires mais ses performances diagnostiques sont médiocres, surtout en cas d'obstacle non lithiasique, contrairement à l'IRM pancréato-biliaire et l'écho-endoscopie dont les performances diagnostiques sont excellentes. Le scanner abdomino-pelvien reste néanmoins le plus disponible, avec des performances diagnostiques intermédiaires. La réalisation de prélèvements microbiologiques tels que les hémocultures (positives dans 40% des cas) et les cultures biliaires est indispensable. En cas d'angiocholite « communautaire », les 2 pathogènes les plus fréquents sont *Escherichia coli* et *Klebsiella spp.*, justifiant une antibiothérapie probabiliste par céphalosporine de 3^{ème} génération. L'intérêt d'une couverture systématique des entérocoques et des anaérobies est encore débattu, habituellement recommandée en cas d'angiocholite associée aux soins, en présence de critères de gravité pour l'entérocoque, et en présence d'une anastomose bilio-digestive pour les anaérobies. L'existence d'une prothèse biliaire est le seul facteur de risque identifié d'infection à bactérie multirésistante. A l'antibiothérapie doit s'ajouter un drainage des voies biliaires endoscopique ou radiologique. Malgré les progrès dans la prise en charge, la mortalité des angiocholites reste d'environ 5%.

Abstract :

Acute cholangitis is an infection of the bile and biliary tract which in most cases is the consequence of biliary tract obstruction. The two main causes are choledocholithiasis and neoplasia. Clinical diagnosis relies on Charcot's triad (pain, fever, jaundice) but the insufficient sensitivity of the latter led to the introduction in 2007 of a new score validated by the Tokyo Guidelines, which includes

Mise au point : Angiocholites : diagnostic et prise en charge

biological and radiological data. In case of clinical suspicion, abdominal ultrasound quickly explores the biliary tract, but its diagnostic capacities are poor, especially in case of non-gallstone obstruction, as opposed to magnetic resonance cholangiopancreatography and endoscopic ultrasound, of which the diagnostic capacities are excellent. CT scan is more widely available, with intermediate diagnostic capacities. Bacteriological sampling through blood cultures (positive in 40% of cases) and bile cultures is essential. In cases involving a wide variety of bacteria, the main pathogens having been found are *Escherichia coli* and *Klebsiella* spp., justifying first-line antimicrobial therapy by a third-generation cephalosporin. Systematic coverage of *Enterococcus* spp. and anaerobic infections remains debated, and is usually recommended only in case of health-care associated cholangitis, elevated *Enterococcus* severity levels, or anaerobic bilio-digestive anastomosis for anaerobes. Presence of a biliary stent is the only identified risk-factor associated with infections by multidrug-resistant pathogens. Along with antimicrobial therapy, endoscopic or radiological biliary drainage is a crucial management component. Despite improved management, mortality in cases of acute cholangitis remains approximately 5%.

Introduction :

Acute cholangitis or angiocholitis (from the Greek *angeion*: vessels and *kholé*: bile) is a potentially severe bile and biliary duct infection. Its first known description was given in 1877 by Jean Martin Charcot (1825-1893) in his “Lesson on diseases of the liver, biliary tract and kidneys” at the Paris faculty of medicine [1]. In the 18th lesson “Of symptomatic hepatic fever – Comparison with urosepsis fever”, he described an association of intermittent hepatic fever with icterus and biliary colic, which was to become the well-known eponymous triad: pain-fever-jaundice. In our times, this triad remains essential to clinical diagnosis, and is confirmed more often than not, by biological, microbiological and radiological data. In this review, we shall discuss the respective role of each of these, while bearing in mind that according to the Tokyo Guidelines, the gold standard for diagnosis of acute cholangitis consists in: observation of purulent bile; clinical remission following bile duct drainage; remission achieved by antimicrobial therapy alone, in patients in whom the only site of infection was the biliary tree [2,3].

In addition to diagnosis, treatment of acute cholangitis remains a major medical issue. Points of interest include management of patients with comorbidities, severity assessment, evolution of the implicated pathogens influencing the choice of probabilistic antimicrobial therapy (degree of coverage against multidrug-resistant bacteria [MRB], anaerobic infections, enterococci...), duration of antibiotic treatment and timing of bile duct drainage. The cruciality of bile duct treatment and management bears mentioning; while endoscopic procedures have yielded undeniable improvement, the respective roles of endoscope ultrasound and interventional radiology have yet to be clearly defined.

Since 2007, a group of experts from throughout the world has been working together in view of

proposing recommendations for diagnosis and treatment of acute cholangitis: the Tokyo Guidelines, which were updated in 2013 and most recently in 2018 [4].

This article proposes a review of recent developments incorporating the main points of interest stemming from the Tokyo Guidelines.

1- Pathophysiology and etiologies of acute cholangitis

Two central phenomena explain the pathophysiology of acute cholangitis. The first is obstruction of the biliary tract by an obstacle, leading to stoppage of enterohepatic circulation of bile and increased intraductal pressure, which is responsible for altered biliary secretion and brings about bilio-venous and bilio-lymphatic reflux [5,6]. The second consists in bacterial proliferation in bile, which is normally sterile, even though some colonization has been observed in persons without biliary tract infection. There are two possible sources of contamination: ascendant (duodenal flora) or hematogenous (portal venous blood) [7]. Heightened intraductal pressure subsequently leads to bilio-venous bacterial translocation. It bears mentioning that by definition, reflux cholangitis is the exception inasmuch as it is secondary not to biliary tract obstruction, but rather to food debris reflux, a source of transitory obstruction that is considerably more difficult to highlight (**Figure 1**).

The multiple etiologies of acute cholangitis are presented as exhaustively as possible in des **Table 1**, which supplements the table put forward by Mosler [8] and Carpenter [9] and schematized in **Figure 2** (according to [9],[10]). Given for information purposes only, the reported frequencies of occurrence should be interpreted cautiously insofar as they may vary considerably from one center to another according to patient recruitment and series duration. While the most recent and robust multicenter epidemiological data (more than 6000 acute cholangitis episodes) date from 2017, they originated in Japanese and Taiwanese centers [11]. And while lithiasis of the common bile duct represents the main etiology of acute cholangitis, other causes are tending to become more and more frequent; they include neoplasia (especially in patients over 50 years of age, possibly becoming the predominant etiology) [12], primary sclerosing cholangitis and ascending cholangitis following

Mise au point : Angiocholites : diagnostic et prise en charge

instrumentation of the biliary duct (0.5 to 2.4% of endoscopic retrograde cholangiopancreatography cases [ERCP]) [13]. Lastly, in patients with a biliary prosthesis, occlusion of the latter occurs in half of cases with a plastic prosthesis and in a quarter of cases in patients with self-expandable metal prostheses, putting them at high risk of cholangitis [14].

Asymptomatic gallstones (vesicular lithiasis) is frequent (around 10% of the population in Europe [15]), but cholangitis occurrence seems exceptional in asymptomatic patients and has relatively seldom been studied. As regards the few publications concerning patients with initially asymptomatic gallstones, not a single cholangitis episode was reported in three large-scale cohorts (at least 100 patients having been monitored for at least 10 years) [16–18]. In two other cohort studies, only one cholangitis episode was reported among 739 and 135 patients respectively [19,20], while in a third study four cases involving cholangitis were reported among 123 patients monitored for 20 years, but they went by different names (“angiocholitis” and “obstructive icterus”) [21]. On the basis of other, less recent data, the authors of the Tokyo Guidelines (TG) 2013 found an incidence of 0.3% to 1.6% of acute cholangitis in biliary lithiasis patients [2].

One particular case is reflux cholangitis, which complicates approximately 10% of bilio-digestive anastomoses whatever the indication: bile duct stones [22], postoperative stenosis repair [23] or cephalic duodenopancreatectomy [24]. Reflux is likely to consist in food debris and may possibly be objectified by imaging (one example: contrast radiography of the upper gastrointestinal transit in choledocoduodenal anastomosis) or scintigraphy (one example: biliary scintigraphy after cephalic duodenopancreatectomy). In this context, repeated cholangitis episodes should instigate search for a contributing factor such as anastomotic stenosis or an impediment to digestion beneath the anastomosis [23,24].

2- Acute cholangitis diagnosis

Clinical diagnosis of acute cholangitis is classically based in the Charcot triad (pain, fever, jaundice). However, its excellent specificity (96%) is counteracted by its poor sensitivity (26%) [6]. In fact,

Mise au point : Angiocholites : diagnostic et prise en charge

association of the three symptoms may be present in only 22% of cholangitis patients [25]. While the most frequent symptoms are fever and abdominal pain (up to 80% of patients), abdominal pain may be absent in half of elderly subjects [26], and jaundice is present in 60 to 70% of patients.

In 2007, a multidisciplinary meeting of international experts took place in Tokyo and published their initial recommendations (Tokyo Guidelines= TG), which were subsequently updated in 2013 and 2018. In TG 2007, a new diagnostic score introducing biological and radiological data was proposed and yielded improved but still insufficient sensitivity and specificity scores (83% and 80% respectively) [3]. The score was revised in 2013 and maintained in 2018 [27], it is presented in **Table 2**. In diagnosis of acute cholangitis, it presents sensitivity and specificity scores of 92% and 78% respectively. The revised score no longer includes abdominal pain, which is not sufficiently specific.

3- Severity criteria

In view of predicting the severity of an episode of acute cholangitis, in 2013 the TG experts drew up a scoring system, presented in **Table 3**, which was not modified in 2018. Three groups are classified according to severity; the illness is categorized as **grade 1**, non-severe, if none of the following serious symptoms are present : fever $>39^{\circ}\text{C}$, age >75 years, hyperleukocytosis $>12\text{G/L}$, bilirubinemia $>85\mu\text{mol/L}$ or hypoalbuminemia < 0.7 x the lower limit of the normal range. **Grade 3** is reached in the event of organ failure, while a patient is considered as **grade 2** or intermediate when at least two of the above-mentioned serious symptoms are present, but no organ failure has occurred. The three degrees of severity are associated with increasing mortality, from 1.2% for grade 1 to 2.6% for grade 2 and more than 5% for grade 3 [2,4,28]. It should nonetheless be noted that correlation between severity as measured by the score is less than perfect, particularly in patients suffering from cholangitis secondary to neoplasia, biliary prosthesis obstruction, or intrahepatic obstruction [28,29]; moreover, the score often tends to underestimate severity. Procalcitonin could constitute an

Mise au point : Angiocholites : diagnostic et prise en charge

interesting marker for severity (sensitivity at 97% and specificity at 73% for diagnosis of severe acute cholangitis) [30].

4- Imagery

Highlighting biliary tract dilatation or an obstacle in the biliary tract is a key diagnostic element. Several imagery modalities may be envisioned: abdominal ultrasound, abdominal CT, MRI and echo-endoscopy (EE), coupled or not with ERCP. Ultrasound is often the first-line diagnostic test, as it facilitates search for biliary tract dilatation, but while the results are relatively simple to visualize, they may be inadequate in the event of acute obstruction. Moreover, according to a Cochrane meta-analysis (to be interpreted with caution insofar as it is based on non-recent series, with pronouncedly variable results), ultrasound manifests low sensitivity (73%) in detection of common bile duct stone [31]. And as regards obstacles other than choledocholithiasis, its performances have been even less impressive. To sum up, abdominal ultrasound does not function as differential diagnosis, and other examinations must be proposed.

Abdominal and pelvic CT with and without injection presents several advantages; it is more sensitive and specific than ultrasound (a score proposed in 2012 presents sensitivity >83% and specificity approximating 83% in acute cholangitis diagnosis, whatever the cause) [32]; moreover, it facilitates search for complications (hepatic abscess, portal thrombosis...) and excludes alternative etiologies of abdominal pain. Bilio-pancreatic MRI represents the non-invasive modality with the best diagnostic yield when seeking out the origin of an obstacle, whatever the etiology, particularly with regard to malignant causes (sensitivity 96 %, specificity 100%) and bile duct stenoses [12]. Lastly, EE and ERCP, which can be carried out if necessary during the same anesthetic procedure, have evinced similarly excellent performances in detection of calculi; in addition, ERCP allows for therapeutic action [33]. That much said, a recent meta-analysis showed that MRI and EE performed as well as one another in detection of common bile duct stones [34]. While the literature often evokes the supposedly

Mise au point : Angiocholites : diagnostic et prise en charge

excellent diagnostic value of EE in cases of biliary neoplasia, there presently exists no study assessing with sufficient clarity its diagnostic performances.

In clinical practice :

-Hepatic ultrasound and abdominal MRI are non-invasive and non-irradiating, but restricted availability of the latter limits its utilization in emergencies, notwithstanding its excellent diagnostic performances.

-Non-invasive but irradiant, abdominal and pelvic CT is of interest due to its widespread availability, and diagnostic performances generally superior to ultrasound but inferior to MRI. .

-While EE and ERCP are second-line invasive examinations, their diagnostic performances are excellent; ERCP is irradiant but allows for therapeutic action.

4- Microbiology

The two key microbiological tests in case of acute cholangitis are hemoculture and bile culture. Hemocultures were positive in 40% of the episodes reported in a recent retrospective multicenter series and even more positive in the event of biliary stent obstruction [11,35]. In 20% of cases, hemocultures may be polymicrobial [36]. Bile cultures are even more cost-efficient (positive in 83% of cases according to the same multicenter study [11], but frequently more in other series) and objectify polymicrobial infection in at least 50% of cases [35,37,38]. A 2014 retrospective study showed total agreement of 31% between bile cultures and hemocultures, a finding raising the questions about the pathogenicity of the germs present in polymicrobial bile cultures, but over 70% of the tests were carried out more than 24h after installation of a biliary drain [37]. The main isolated germs are presented in **Table 4**, adapted from TG 2018 [39]: *Escherichia coli* and *Klebsiella* spp. are the two main germs responsible for acute cholangitis.

Mise au point : Angiocholites : diagnostic et prise en charge

As regards antibiotic resistance of the germs responsible for acute cholangitis, more particularly the occurrence of episodes implicating enterobacteria producing extended spectrum β -lactamases (ESBLs), data vary widely from one country to another; in Europe, a retrospective study on the positive bile test results from 83 patients in a German tertiary center identified 29% of multidrug-resistant (MDR) bacteria, including 54% of ESBL [38]. In Korea, *E. coli* ESBLs are the first microorganisms responsible for acute cholangitis, including community-acquired cholangitis, all in all representing 30.4% of cases [40]. Biliary stenting is the one MDR-independent risk factor identified in two retrospective studies, with relative risk of 3.6 to 4 times [38,41]. Presence of a biliary endoprosthesis is also a risk factor for cholangitis with enterococci (particularly *E. faecium*), *Pseudomonas aeruginosa* and *Stenotrophomonas maltophilia* [42]. Finally, even though colonization stents by fungal microorganisms is a frequent occurrence, fungal cholangitis remains exceptional [43].

5- Treatment of acute cholangitis

Treatment of acute cholangitis is a response to an emergency built around two fundamental procedures: antimicrobial therapy, and biliary tract drainage (**Figure 1**).

a- Antimicrobial therapy

The severity of acute cholangitis necessitates immediate antimicrobial therapy in emergency care, which is most often chosen probabilistically. Antibiotic treatment must cover the germs described above according to local ecology, without neglecting to take into consideration the relevant characteristics of the patient (renal and hepatic functions, allergies, known MRB colonization...) and of the antibiotic, as well as the severity of the specific case of acute cholangitis.

Generally speaking, as regards community-acquired forms without severity grade, the schema is based on 3rd-generation cephalosporin (cefotaxime or ceftriaxone), associated with an anaerobic

Mise au point : Angiocholites : diagnostic et prise en charge

agent in cases involving biliary-enteric anastomosis. In initially severe, nosocomial or care-associated forms (including prostheses), preferred anti-microbial treatments include broad-spectrum cephalosporin (cefepime) or an association piperacillin + tazobactam, both of them associated with vancomycin and an anti-anaerobic in cases involving biliary-enteric anastomosis [39,44,45]. These schemas require adaptation to local ecology and to patients' past history of infection and colonization (ESBL, vancomycin-resistant enterococcus (VRE), etc.). A synthesis of the different therapeutic schemas is proposed in **Table 5**. Given high rates of resistance, even in cases of community-acquired infections and, more broadly, the development of resistances, fluoroquinolones are not a recommended probabilistic antibiotic therapy. In any event, in order to reduce the risk of emergent multi-resistant organisms, antimicrobial therapy must be secondarily adapted to bacteriological test results.

In fact, the rationale for these associations revolves around a few fundamental issues. The first of these concerns the need to take anaerobes into account in probabilistic treatment, even though, due presumably to their low prevalence, the Infectious Diseases Society of America (IDSA) and the TG 2018 did so only in the case of biliary-enteric anastomosis [39,44]. The second issue involves the debated pathogenicity of enterococci, which is supposed to be taken into account in empirical treatment only in the event of severe infection, a nosocomial context or immunosuppression [44]. These recommendations should be compared to the results of a recent retrospective study on 573 episodes of acute bacterial cholangitis in two Japanese tertiary centers, where it was found that lack of coverage for enterococci and anaerobes was responsible for 30 and 8% respectively of the 133 cases in which anti-microbial therapy was inappropriate. However, more than 60% of acute cholangitis cases were care-associated or nosocomial, and a substantial proportion of them were serious episodes; 43% were grade III [36]. At an individual level, the risk-benefit ratio of the addition of metronidazole, a molecule with few side effects when utilized for a short time period, remains under discussion with regard to non-severe community-acquired forms. Lastly, effective coverage of

Mise au point : Angiocholites : diagnostic et prise en charge

Pseudomonas aeruginosa, of which the prevalence is highly variable, seems indispensable in patients fulfilling severity criteria.

Biliary diffusion of antibiotics could represent a selection criterion in anti-microbial therapy; and justify preference of ceftriaxone to cefotaxime, notably in non-severe forms due to its bilio-digestive excretion. However, studies conducted since 1976 on different antibiotics have shown that bile duct obstruction drastically reduced the biliary diffusion of antibiotics. Even biliary excretion molecules are well below minimal inhibitory concentrations (MIC) in bile in cases involving bile duct obstruction [46–48]. These considerations open debate on the usefulness of choosing an antibiotic with satisfactory biliary diffusion and underline the crucial importance of bile duct drainage.

In the final analysis, it is the duration of antimicrobial therapy that is most debatable. The 2018 Tokyo Guidelines suggested 4 to 7 days after identification of the source of infection, except with regard to enterococci and streptococci, for which the recommended duration, due to a risk of endocarditis, is 2 weeks [39]. However, the French Infectious Disease Society (SPILF) has proposed a reduction of anti-microbial therapy duration to 3 days, including in cases of bacteremia (with the notable exceptions of primary sclerosing cholangitis and liver transplant recipients) [49]. The above recommendations are based on two studies. The first, conducted by Kogure *et al.*, was a single-center prospective study testing cessation of anti-microbial therapy once body temperature has been lower than 37°C for 24h after bile duct drainage; as regards the 18 patients included, among whom 17 presented with cholangiolithiasis, the median duration of anti-microbial therapy was 3 days without relapse over the following 4 weeks [50]. The second was a single-center retrospective study of 80 patients comparing acute cholangitis relapse rates according to duration of anti-microbial therapy. The 41 patients having received anti-microbial therapy <3 days did not relapse more often after median 71-day follow-up compared to those having received 4-5 days or >5 days of treatment [51].

Mise au point : Angiocholites : diagnostic et prise en charge

To sum up, probabilistic anti-microbial therapy must be initiated immediately after hemoculture testing and consists in a beta-lactam antibiotic covering entero-bacteria, while anaerobic bacteria should probably be targeted only in cases involving biliary-enteric anastomosis, and enterococci only in contexts of nosocomial context, high severity, or immunodepression. Duration of 5 days following drainage appears sufficient.

b- Bile duct obstruction treatment

In cases of acute cholangitis, effective treatment of bile duct obstruction is of paramount importance. Post-surgical reflux cholangitis is an exception insofar as it generally does not necessitate drainage due to the fact that for all practical purposes, the bile has already been drained out [52]. In all other cases, drainage is an essential means of avoiding septic shock, death and complications such as hepatic abscesses; it also optimizes the action of antibiotics. Several modalities may be envisioned: surgical treatment (nowadays exceptional due to its high morbi-mortality compared to endoscopic treatment) [53], endoscopic drainage during ERCP or EE through installation of a metallic or plastic prosthesis or a naso-biliary drain or, finally, percutaneous transhepatic biliary drainage.

As regards the general principles of biliary (bile duct) drainage, the current reference method is transpapillary biliary drainage during ERCP, either by placing a stent in the bile ducts, or by means of naso-biliary drainage; according to a meta-analysis carried out in TG 2018, efficacy of the two modalities is similar in terms of endoscopic and clinical success, adverse effects, and risk of "redo" operation [9]. Association with ERCP endoscopic sphincterotomy aimed at reducing occurrence of post-ERCP acute pancreatitis should not be systematic insofar as its benefits remain debatable ; moreover, sphincterotomy is a complicated procedure with severe hemorrhaging in 4 to 8% of relevant cases [54,55].

Mise au point : Angiocholites : diagnostic et prise en charge

In the event of failure, percutaneous transhepatic or echo-endoscopic drainage (EE) is generally proposed. A recent meta-analysis (9 studies and 483 patients) showed better performances with EE (higher success rate and fewer complications), but these positive results should be readjusted due to probable bias in favor of EE [56].

In clinical practice:

-In non-severe or moderate cholangiolithiasis, biliary drainage is not systematically called for. In fact, stone removal is recommended subsequent to endoscopic sphincterotomy, or else following balloon dilatation (in the event of hemostatic disorders or small-scale lithiasis); when associated with extraction maneuvers, these procedure often suffices to effectively eliminate the obstacle. In the event of failure and persistent lithiasis in the common bile duct, biliary drainage becomes necessary. The naso-biliary drain is more frequently used in Asia than in Europe, where biliary endoprosthesis tends to be preferred on account of its relative simplicity.

-In cases of a large or multiple lithiasis, and particularly in the event of vesicular lithiasis, treatment is two-stepped. First, biliary drainage is carried out according to the modalities described above; second, lithiasis extraction is performed after dilatation with a larger balloon (with or without sphincterotomy) during a second ERCP. Cholecystectomy is subsequently carried out [9].

-Non-lithiasic cholangitis (especially when secondary to neoplasia) necessitates ERCP with insertion of an endo-biliary prosthesis or a naso-biliary drain; while they are similarly effective, the latter can cause patient discomfort. It should also be noted that in two retrospective studies involving 118 and 128 patients respectively, in cases of hilar (Klatskin) tumor, endoscopic drainage by naso-biliary drain was found to be superior to drainage by biliary prosthesis, insofar as it occasioned fewer complications and/or "redo" operations [57,58].

Mise au point : Angiocholites : diagnostic et prise en charge

-If ERCP drainage fails, two options may be: (1) percutaneous drainage, possibly completed secondarily by endoscopic stent placement using the “rendezvous” procedure, which permits removal of external drainage or (2) EE, but only in cases of non-lithiasic origin) [59].

Choosing the optimal moment for biliary drainage is another, incompletely elucidated question of interest, even if early drainage appears primordial [60]. A retrospective study on a large-scale sample (77323 patients) highlighted longer hospital stays and higher costs in the event of ERCP >48h [61]. Furthermore, two prospective studies involving 199 and 166 patients showed in multivariate analysis that mortality risk was 3.6 times higher when ERCP was carried out after 72 hours and that early biliary drainage performed within 24h was a predictive factor of survival at 30 days (OR 0.23, CI95 [0.05-0.95]; P = 0.04) [62,63].

According to TG 2018, endoscopic treatment delay should be stratified according to cholangitis severity (cf. **Table 3**): - for grade I, it is envisaged only in the event of failed anti-microbial treatment; for grade 2, it is recommended early; for grade 3, it is recommended as a matter of urgency, without any precise indication of time lapse (in general in the literature, emergency surgical drainage takes place during the first 12-24 hours, and early drainage during the first 48 hours). However, this stratification necessitates validation, especially insofar as an initial study did not find a correlation according to degree of severity (except for grade 2) between survival and time elapsed prior to drainage [28]. It also bears mentioning that in a retrospective study, it was suggested that some patients classified in grade I were actually in need of endoscopic drainage, a finding apparently in agreement with the data detailed above [64].

c- Treatment in particular cases

Mise au point : Angiocholites : diagnostic et prise en charge

In cases of liver abscess of biliary origin subsequently associated with bile duct obstruction, treatment consists in anti-microbial therapy and biliary duct drainage associated to a greater or lesser extent with abscess drainage. Anti-microbial therapy need be adapted to identified germs; when relevant documentation is incomplete, anti-microbial therapy similar to the treatment proposed above, and in **Table 5**, for acute cholangitis, may be recommended, taking the two following particularities into close account: (1) since anaerobia represents 35 to 45% of the germs under consideration, systematic coverage can be justified; (2) treatment duration is prolonged: 4 weeks when the abscess is small-scale or drained, and 6 weeks without drainage, if radio-clinic evolution is favorable. Biliary drainage is carried out as described above, and percutaneous drainage or puncture aspiration of the abscess must be performed when size exceeds 5 cm [65].

For patients with stenosis following digestive surgery, TG 2018 recommended ERCP assisted by balloon enteroscopy provided that experienced endoscopic surgeons are available; its success rate is high. If it fails or is impossible, percutaneous trans-hepatic approach should be proposed.

In patients suffering from primary sclerosing cholangitis, ERCP drainage is also indicated with balloon dilation of stenosis, and stenting need not necessarily be systematic. What matters in these cases is to eliminate the cholangio-carcinoma responsible for the stenosis; with this priority in mind, the diagnostic performances of cholangioscopy are superior to those of blind sampling [66].

As concerns prevention of recurrent reflux cholangitis, to our knowledge up until now no study has validated medical treatment.

A simplified algorithm of cholangitis treatment is proposed in **Figure 1**.

6- Complications and prognosis

Notwithstanding improved treatment and management, acute cholangitis remains a severe disease with mean mortality at 30 days ranging according to series and in correlation with initial severity, from 2.6% to 5% [11,28,29]. While some single-center studies have reported different rates,

recruitment bias is likely to have occurred, with the mortality rate partially depending on obstruction etiology. For example, Kiriya *et al.* reported a mortality rate of 7.2% in conjunction with underlying neoplasia. While different factors explaining poor prognoses have been identified, they vary from one study to the next, some examples being organ dysfunction, hypoalbuminemia, intrahepatic obstruction [29], a Charlson score > 3 (reflecting major comorbidities), bilirubin > 42.5 µmol/L, neoplastic obstruction or unsuitable initial anti-microbial therapy [36]. And finally, even though assay is difficult to carry out in routine testing, a study has suggested that a low level of interleukin 7 associated with a high level of procalcitonin (>0.5 ng/mL) may be a predictive factor for mortality [67].

Few complications of acute cholangitis are regularly reported. The main ones are: associated acute pancreatitis (especially in the case of lithiasic etiology; around 7.6% of cases in the series by Gomi *et al* [11], septic shock (at least 4% of cases) and hepatic abscesses (2% to 2,5%) [11,29]. Other complications occur less often: portal vein thrombosis [68], or infectious endocarditis (very rare: up to 0.26%) [11]. Just one case of bacterial meningitis has been reported [69].

Conclusions

Acute cholangitis remains a severe disease necessitating emergency multidisciplinary treatment associating anti-microbial therapy and biliary tract drainage. From a microbiological as well as an etiological standpoint, its epidemiology is subject to change and calls for regular and rigorous reassessment. Notwithstanding the existence of recommendations (Tokyo Guidelines), treatment and prognosis are closely connected with a patient's particularities (MRB colonization, biliary prosthesis, digestive surgical assemblies...), subjacent etiology, and a given center's availability of imagery and drainage techniques. A multidisciplinary management approach appears essential.

The authors have no ties of interest to declare.

References

- [1] Charcot J-M . Leçons sur les maladies du foie, des voies biliaires et des reins. Paris: bureaux du "Progrès médical"; 1877.
- [2] Kiriya S, Takada T, Strasberg SM et al. TG13 guidelines for diagnosis and severity grading of acute cholangitis (with videos). *J Hepato-Biliary-Pancreat Sci* 2013;20:24–34.
- [3] Kiriya S, Takada T, Strasberg SM et al. New diagnostic criteria and severity assessment of acute cholangitis in revised Tokyo Guidelines. *J Hepato-Biliary-Pancreat Sci* 2012;19:548–556.
- [4] Kiriya S, Kozaka K, Takada T et al. Tokyo Guidelines 2018: diagnostic criteria and severity grading of acute cholangitis (with videos). *J Hepato-Biliary-Pancreat Sci* 2018;25:17–30.
- [5] Scott-Conner CEH, Grogan JB. The Pathophysiology of Biliary Obstruction and Its Effect on Phagocytic and Immune Function. *J Surg Res* 1994;57:316–36.
- [6] Kimura Y, Takada T, Kawarada Y, et al. Definitions, pathophysiology, and epidemiology of acute cholangitis and cholecystitis: Tokyo Guidelines. *J Hepatobiliary Pancreat Surg* 2007;14:15–26.
- [7] Sung JY, Costerton JW, Shaffer EA. Defense system in the biliary tract against bacterial infection. *Dig Dis Sci* 1992;37:689–96.
- [8] Mosler P. Diagnosis and Management of Acute Cholangitis. *Curr Gastroenterol Rep* 2011;13:166–72.
- [9] Mukai S, Itoi T, Baron TH, et al. Indications and techniques of biliary drainage for acute cholangitis in updated Tokyo Guidelines 2018. *J Hepato-Biliary-Pancreat Sci* 2017.
- [10] Carpenter HA. Bacterial and Parasitic Cholangitis. *Mayo Clin Proc* 1998;73:473–8.
- [11] Gomi H, Takada T, Hwang T-L et al. Updated comprehensive epidemiology, microbiology, and outcomes among patients with acute cholangitis. *J Hepato-Biliary-Pancreat Sci* 2017;24:310–8.
- [12] Singh A, Mann HS, Thukral CL, Singh NR. Diagnostic Accuracy of MRCP as Compared to Ultrasound/CT in Patients with Obstructive Jaundice. *J Clin Diagn Res JCDR* 2014;8:103–7.
- [13] Ong T-Z, Khor J-L, Selamat D-S, Yeoh K-G, Ho K-Y. Complications of endoscopic retrograde cholangiography in the post-MRCP era: A tertiary center experience. *World J Gastroenterol WJG* 2005;11:5209–12.
- [14] Sawas T, Al Halabi S, Parsi MA, Vargo JJ. Self-expandable metal stents versus plastic stents for malignant biliary obstruction: a meta-analysis. *Gastrointest Endosc* 2015;82:256-267.e7.
- [15] Payen J-L, Muscari F, Vibert É, Ernst O, Pelletier G. Lithiase biliaire. *Presse Médicale* 2011;40:567–80.
- [16] Gracie WA, Ransohoff DF. The Natural History of Silent Gallstones. *N Engl J Med* 1982;307:798–800.
- [17] Attili AF, de Santis A, Capri R, Repice AM, Maselli S, Group G. The natural history of gallstones: The GREPCO experience. *Hepatology* 1995;21:656–60.
- [18] Shabanzadeh DM, Sørensen LT, Jørgensen T. A Prediction Rule for Risk Stratification of Incidentally Discovered Gallstones: Results From a Large Cohort Study. *Gastroenterology* 2016;150:156-167.e1.
- [19] Halldestam I, Enell E-L, Kullman E, Borch K. Development of symptoms and complications in individuals with asymptomatic gallstones. *Br J Surg* 2004;91:734–8. doi:10.1002/bjs.4547.
- [20] McSherry CK, Ferstenberg H, Calhoun WF, Lahman E, Virshup M. The natural history of diagnosed gallstone disease in symptomatic and asymptomatic patients. *Ann Surg* 1985;202:59–63.
- [21] Friedman GD, Raviola CA, Fireman B. Prognosis of gallstones with mild or no symptoms: 25 years of follow-up in a health maintenance organization. *J Clin Epidemiol* 1989;42:127–36.
- [22] Panis Y, Fagniez PL, Brisset D, Lacaine F, Levard H, Hay JM. Long term results of choledochoduodenostomy versus choledochojejunostomy for choledocholithiasis. The French Association for Surgical Research. *Surg Gynecol Obstet* 1993;177:33–7.
- [23] Barbier L, Souche R, Slim K, Ah-Soune P. Long-term consequences of bile duct injury after cholecystectomy. *J Visc Surg* 2014;151:269–79.

- [24] Ueda H, Ban D, Kudo A, Ochiai T, Tanaka S, Tanabe M. Refractory Long-Term Cholangitis After Pancreaticoduodenectomy: A Retrospective Study. *World J Surg* 2017;41:1882–9.
- [25] Csendes A, Diaz JC, Burdiles P, Maluenda F, Morales E. Risk factors and classification of acute suppurative cholangitis. *Br J Surg* 1992;79:655–8.
- [26] Agarwal N, Sharma BC, Sarin SK. Endoscopic management of acute cholangitis in elderly patients. *World J Gastroenterol* 2006;12:6551–5.
- [27] Yokoe M, Hata J, Takada T et al. Tokyo Guidelines 2018: diagnostic criteria and severity grading of acute cholecystitis (with videos). *J Hepato-Biliary-Pancreat Sci* 2018;25:41–54.
- [28] Kiriya S, Takada T, Hwang T-L et al. Clinical application and verification of the TG13 diagnostic and severity grading criteria for acute cholangitis: an international multicenter observational study. *J Hepato-Biliary-Pancreat Sci* 2017;24:329–37.
- [29] Sun G, Han L, Yang Y et al. Comparison of two editions of Tokyo guidelines for the management of acute cholangitis. *J Hepato-Biliary-Pancreat Sci* 2014;21:113–9.
- [30] Umefune G, Kogure H, Hamada T et al. Procalcitonin is a useful biomarker to predict severe acute cholangitis: a single-center prospective study. *J Gastroenterol* 2017;52:734–45.
- [31] Gurusamy KS, Giljaca V, Takwoingi Y et al. Ultrasound versus liver function tests for diagnosis of common bile duct stones. *Cochrane Database Syst Rev* 2015:CD011548.
- [32] Kim SW, Shin HC, Kim HC. Diagnostic performance of multidetector CT for acute cholangitis: evaluation of a CT scoring method. *Br J Radiol* 2012;85:770–7.
- [33] Park DH. Endoscopic ultrasound-guided biliary drainage of hilar biliary obstruction. *J Hepato-Biliary-Pancreat Sci* 2015;22:664–8.
- [34] Giljaca V, Gurusamy KS, Takwoingi Y et al. Endoscopic ultrasound versus magnetic resonance cholangiopancreatography for common bile duct stones. *Cochrane Database Syst Rev* 2015:CD011549.
- [35] Rerknimitr R, Fogel EL, Kalayci C, Esber E, Lehman GA, Sherman S. Microbiology of bile in patients with cholangitis or cholestasis with and without plastic biliary endoprosthesis. *Gastrointest Endosc* 2002;56:885–9.
- [36] Tagashira Y, Sakamoto N, Isogai T et al. Impact of inadequate initial antimicrobial therapy on mortality in patients with bacteraemic cholangitis: a retrospective cohort study. *Clin Microbiol Infect Off Publ Eur Soc Clin Microbiol Infect Dis* 2017;23:740–7.
- [37] Park JW, Lee JK, Lee KT, Lee KH, Sung YK, Kang C-I. How to interpret the bile culture results of patients with biliary tract infections. *Clin Res Hepatol Gastroenterol* 2014;38:300–9.
- [38] Reuken PA, Torres D, Baier M et al. Risk Factors for Multi-Drug Resistant Pathogens and Failure of Empiric First-Line Therapy in Acute Cholangitis. *PloS One* 2017;12:e0169900.
- [39] Gomi H, Solomkin JS, Schlossberg D et al. Tokyo Guidelines 2018: antimicrobial therapy for acute cholangitis and cholecystitis. *J Hepato-Biliary-Pancreat Sci* 2018;25:3–16.
- [40] Kwon JS, Han J, Kim TW et al. Changes in causative pathogens of acute cholangitis and their antimicrobial susceptibility over a period of 6 years. *Korean J Gastroenterol Taehan Sohwagi Hakhoe Chi* 2014;63:299–307.
- [41] Schneider J, De Waha P, Hapfelmeier A et al. Risk factors for increased antimicrobial resistance: a retrospective analysis of 309 acute cholangitis episodes. *J Antimicrob Chemother* 2014;69:519–25.
- [42] Weber A, Schneider J, Wagenpfeil S et al. Spectrum of pathogens in acute cholangitis in patients with and without biliary endoprosthesis. *J Infect* 2013;67:111–21.
- [43] Lübbert C, Wendt K, Feisthammel J et al. Epidemiology and Resistance Patterns of Bacterial and Fungal Colonization of Biliary Plastic Stents: A Prospective Cohort Study. *PLOS ONE* 2016;11:e0155479.
- [44] Solomkin JS, Mazuski JE, Bradley JS et al. Diagnosis and management of complicated intra-abdominal infection in adults and children: guidelines by the Surgical Infection Society and the Infectious Diseases Society of America. *Clin Infect Dis Off Publ Infect Dis Soc Am* 2010;50:133–64.

- [45] Société française d'anesthésie et. Antibiothérapie probabiliste des états septiques graves. *Ann Fr D'Anesthésie Réanimation* 2004;23:1020–6.
- [46] Dhalluin-Venier V, Bazin C, Massias L et al. Effects of biliary obstruction on the penetration of ciprofloxacin and cefotaxime. *Eur J Gastroenterol Hepatol* 2008;20:127.
- [47] Keighley MR, Drysdale RB, Quoraishi AH, Burdon DW, Alexander-Willians J. Antibiotics in biliary disease: the relative importance of antibiotic concentrations in the bile and serum. *Gut* 1976;17:495–500.
- [48] Leung JW, Ling TK, Chan RC et al. Antibiotics, biliary sepsis, and bile duct stones. *Gastrointest Endosc* 1994;40:716–21.
- [49] Wintenberger C, Guery B, Bonnet E, Castan B, Cohen R, Diamantis S, et al. Proposal for shorter antibiotic therapies. *Médecine Mal Infect* 2017;47:92–141.
- [50] Kogure H, Tsujino T, Yamamoto K et al. Fever-based antibiotic therapy for acute cholangitis following successful endoscopic biliary drainage. *J Gastroenterol* 2011;46:1411–7. doi:10.1007/s00535-011-0451-5.
- [51] van Lent AUG, Bartelsman JFWM, Tytgat GNJ, Speelman P, Prins JM. Duration of antibiotic therapy for cholangitis after successful endoscopic drainage of the biliary tract. *Gastrointest Endosc* 2002;55:518–22.
- [52] Miura F, Okamoto K, Takada T et al. Tokyo Guidelines 2018: initial management of acute biliary infection and flowchart for acute cholangitis. *J Hepato-Biliary-Pancreat Sci* 2018;25:31–40.
- [53] Lai ECS, Mok FPT, Tan ESY, et al. Endoscopic Biliary Drainage for Severe Acute Cholangitis. *N Engl J Med* 1992;326:1582–6.
- [54] Hui C-K, Lai K-C, Yuen M-F et al. Does the Addition of Endoscopic Sphincterotomy to Stent Insertion Improve Drainage of the Bile Duct in Acute Suppurative Cholangitis? *Gastrointest Endosc* 2003;58:500–4.
- [55] Sugiyama M, Atomi Y. The benefits of endoscopic nasobiliary drainage without sphincterotomy for acute cholangitis. *Am J Gastroenterol* 1998;93:2065–8.
- [56] Sharaiha RZ, Khan MA, Kamal F et al. Efficacy and safety of EUS-guided biliary drainage in comparison with percutaneous biliary drainage when ERCP fails: a systematic review and meta-analysis. *Gastrointest Endosc* 2017;85:904–14.
- [57] Kawakubo K, Kawakami H, Kuwatani M et al. Lower incidence of complications in endoscopic nasobiliary drainage for hilar cholangiocarcinoma. *World J Gastrointest Endosc* 2016;8:385–90.
- [58] Kawakami H, Kuwatani M, Onodera M et al. Endoscopic nasobiliary drainage is the most suitable preoperative biliary drainage method in the management of patients with hilar cholangiocarcinoma. *J Gastroenterol* 2011;46:242–8.
- [59] Calvo MM, Bujanda L, Heras I et al. The rendezvous technique for the treatment of choledocholithiasis. *Gastrointest Endosc* 2001;54:511–3.
- [60] Xu MM, Carr-Locke DL. Early ERCP for severe cholangitis? Of course! *Gastrointest Endosc* 2018;87:193–5.
- [61] Parikh MP, Wadhwa V, Thota PN, Lopez R, Sanaka MR. Outcomes Associated With Timing of ERCP in Acute Cholangitis Secondary to Choledocholithiasis. *J Clin Gastroenterol* 2018.
- [62] Hou LA, Laine L, Motamedi N, Sahakian A, Lane C, Buxbaum J. Optimal Timing of Endoscopic Retrograde Cholangiopancreatography in Acute Cholangitis. *J Clin Gastroenterol* 2017;51:534–8.
- [63] Tan M, Schaffalitzky de Muckadell OB, Laursen SB. Association between early ERCP and mortality in patients with acute cholangitis. *Gastrointest Endosc* 2018;87:185–92.
- [64] Nishino T, Hamano T, Mitsunaga Y et al. Clinical evaluation of the Tokyo Guidelines 2013 for severity assessment of acute cholangitis. *J Hepato-Biliary-Pancreat Sci* 2014;21:841–9.
- [65] Rossi G, Lafont E, Gasperini L et al. Abcès hépatiques. *Rev Médecine Interne* 2016;37:827–33.
- [66] Lindor KD, Kowdley KV, Harrison ME, American College of Gastroenterology. ACG Clinical Guideline: Primary Sclerosing Cholangitis. *Am J Gastroenterol* 2015;110:646–59; quiz 660.

Mise au point : Angiocholites : diagnostic et prise en charge

- [67] Suwa Y, Matsuyama R, Goto K et al. IL-7 and procalcitonin are useful biomarkers in the comprehensive evaluation of the severity of acute cholangitis. *J Hepato-Biliary-Pancreatic Sci* 2017;24:81–8.
- [68] Plessier A, Darwish-Murad S, Hernandez-Guerra M et al. Acute portal vein thrombosis unrelated to cirrhosis: A prospective multicenter follow-up study. *Hepatology* 2009;51:210–8.
- [69] Yamamoto K, Gotoda T, Kusano C et al. Severe Acute Cholangitis with Complications of Bacterial Meningitis Associated with Hearing Loss. *Intern Med Tokyo Jpn* 2015;54:1757–60.

Etiologies	Frequency	References
Biliary lithiasis	28 -70%	[6,11]
Malignant stenoses	10 -57%	[6,11,12]
-Pancreatic cancer		
-Cholangiocarcinoma		
- Gall bladder adenocarcinoma		
-Tumor of the bilio-pancreatic ampulla		
-Duodenal tumors		
-Hepatic metastases		
-Adenopathy		
-Others (other bile duct tumors, extrinsic compressions...)		
Benign stenoses:	4 - 28%	[6]
-Post-surgical (including cholecystectomy)		
-Acute or chronic pancreatitis		
-Primary sclerosing cholangitis		
-Other autoimmune disorders (including cholangitis associated with IgG4)		
-Complicated lithiasis (Mirizzi syndrome)		
-Congenital abnormalities (including Caroli disease)		
Parasitoses	0 - 24%	[10]
- <i>Ascaris lumbricoides</i>		
- <i>Clonorchis sinensis</i>		
- <i>Fasciola hepatica</i>		
- <i>Opisthorchis felineus</i>		
- <i>Opisthorchis viverrini</i>		
- <i>Echinococcus granulosus</i>		
- <i>Echinococcus multilocularis</i>		
- <i>Taenia Saginata</i>		
Others:		
-Duodenal diverticulum (Lemmel syndrome)		
-Haemobilia		
-Sump syndrome, reflux, surgical clip migration and other post-surgical causes		
-Obstruction or migration of biliary stent		
- Fungal balls (fungal masses)		
- Oriental cholangitis		
- Retroscopic post-cholangiopancreatography with endoscopic approach		
- Amyloses (digestive AL amyloidosis)		
- Vascular compression (cavernoma, aneurysms)		
-Medical (ceftriaxone, carbamazepine)		

Table 1 : Etiologies of acute cholangitis.

Criteria	Threshold
-----------------	------------------

Mise au point : Angiocholites : diagnostic et prise en charge

A-Systemic inflammation	
-A-1 Fever or chills	>38°C
-A-2 Biological inflammatory syndrome	Leukocytes <4 or >10G/L CRP≥10mg/L
B- Cholestasis	
-B-1 Icterus/Jaundice	Total bilirubin ≥ 34 µmol/L
-B-2 Abnormal liver function test	ASAT, ALAT, PAL and gamma-GT >1.5 x ULN
C- Imagery	
-C-1 Bile duct dilatation	
-C-2 Imagery providing proof of etiology	
Suspected diagnosis	One item in A + one item in B or C
Certain diagnosis	One item in A, B and C

Table 2: TG2013/2018 diagnostic criteria. CRP: C reactive protein, ASAT: aspartate aminotransferase, ALAT: alanine aminotransferase, ULN: Upper limit of normal

Mise au point : Angiocholites : diagnostic et prise en charge

Grade	Criteria	Threshold
Grade 3: Severe At least 1 criterium	Cardiovascular dysfunction	Dopamine > 5µg/kg/min or any dose of noradrenalin
	Neurological dysfunction	Consciousness disorders
	Respiratory dysfunction	PaO ₂ /FiO ₂ < 300
	Renal dysfunction	Creatininuria >176µmol/L or oliguria
	Liver dysfunction	INR >1,5
	Hematological dysfunction	Platelets < 100.000/mm ³
Grade 2: Moderate At least 2 criteria	Leucocytes	<4 G/L or >12G/L
	Fever	>39°C
	Age	>75 years
	Bilirubinemia	85 µmol/L
	Hypoalbuminemia	<0.7 x ULN
Grade 1: Mild No criteria 2 or 3		

Table 3: TG severity criteria 2013/2018. PaO₂: Partial pressure of oxygen; FiO₂: fraction of inspired oxygen; INR: International Normalized Ratio; ULN: Upper limit of normal.

Germ	Hemoculture (%)	Biliary cultures (%)
Gram negative bacilli		

Mise au point : Angiocholites : diagnostic et prise en charge

- <i>Escherichia coli</i>	35-62	31-44
- <i>Klebsiella</i> spp.	12-28	9-20
- <i>Pseudomonas</i> spp.	4-14	0.5-19
- <i>Enterobacter</i> spp.	2-7	5-9
- <i>Citrobacter</i> spp.	2-6	
- <i>Acinetobacter</i> spp.	3	
Gram-positive cocci		
- <i>Enterococcus</i> spp.	10-23	3-34
- <i>Streptococcus</i> spp.	6-9	2-10
- <i>Staphylococcus</i> spp.	2	0
Anaerobia	1	4-20
Others	17	

Table 4 : Micro-organisms responsible for acute cholangitis. Adapted from Tokyo Guidelines 2018

Mise au point : Angiocholites : diagnostic et prise en charge

Recommendations					
Community-acquired		Presence of bilio-digestive anastomosis		Care-associated or nosocomial (including post-ERCP)	
Without severity criterion		With gravity criterion			
SFAR (2004) [45]		<ul style="list-style-type: none"> -Amoxicillin /clavulanic acid + gentamicin or netilmicin -Ticarillin /clavulanic acid -Piperacillin + Metronidazole -Cefoxitin -Cefotaxime or Ceftriaxone + Metronidazole -With serious symptoms: association of gentamicin or netilmicin. 		<ul style="list-style-type: none"> - Piperacillin/tazobactam - Imipenem - Ceftazidime + Metronidazole -In association with amikacin 	
IDSA (2010, under revision) [44]				<ul style="list-style-type: none"> -Imipenem/Cilastatin -Meropenem -Doripenem -Piperacillin/Tazobactam -Ciprofloxacin -Levofloxacin -Cefepime -In association with metronidazole 	<ul style="list-style-type: none"> -Imipenem/Cilastatin -Meropenem -Doripenem -Piperacillin/Tazobactam -Ciprofloxacin -Levofloxacin -Cefepime -In association with metronidazole and vancomycin
TG 2018 [39]	Severity TG grade 1	Severity TG grade 2	Severity TG grade 3		
	<ul style="list-style-type: none"> -Cefazolin* or Cefotiam* or Cefuroxime* or Ceftriaxone or Cefotaxime (+ metronidazole if bilio-digestive anastomosis) -Cefmetazole*, -Cefoxitin* -Flomoxef* -Cefoperazone/sulbactam -Ertapenem - Ciprofloxacin or levofloxacin or pazufloxacin or moxifloxacin (+ Metronidazole if bilio-digestive anastomosis)§ 	<ul style="list-style-type: none"> -Ceftriaxone or Cefotaxime Or Cefepime Or Cefozopran Or Ceftazidime (+ Metronidazole if bilio-digestive anastomosis) -Cefoperazone/sulbactam -Ertapenem - Ciprofloxacin or levofloxacin or pazufloxacin or moxifloxacin (+ metronidazole if bilio-digestive anastomosis)§ 	<ul style="list-style-type: none"> -Piperacillin/tazobactam -Cefepime or Ceftazidime or Cefozopran (+metronidazole if bilio-digestive anastomosis) -Imipenem/cilastatin - Meropenem -Doripenem -Ertapenem -Aztreonam (+ metronidazole if bilio-digestive anastomosis) -In association with vancomycin 	<ul style="list-style-type: none"> -Piperacillin/tazobactam -Cefepime or Ceftazidime or Cefozopran (+ metronidazole if bilio-digestive anastomosis) -Imipenem/cilastatin - Meropenem -Doripenem -Ertapenem -Aztreonam (+ metronidazole if bilio-digestive anastomosis) -In association with vancomycin 	

Mise au point : Angiocholites : diagnostic et prise en charge

**According to local ecology (<20% resistance)*

§ Only for patients allergic to beta-lactam antibiotics or following antibiogram

IDSA: Infectious Diseases Society of America; SFAR: Société Française d'Anesthésie et de Réanimation; IDSA: TG2018: Tokyo Guidelines 2018,

See Table 3 for severity criteria

Table 5 : Probabilistic anti-microbial therapy for acute cholangitis, as proposed in different recommendations.

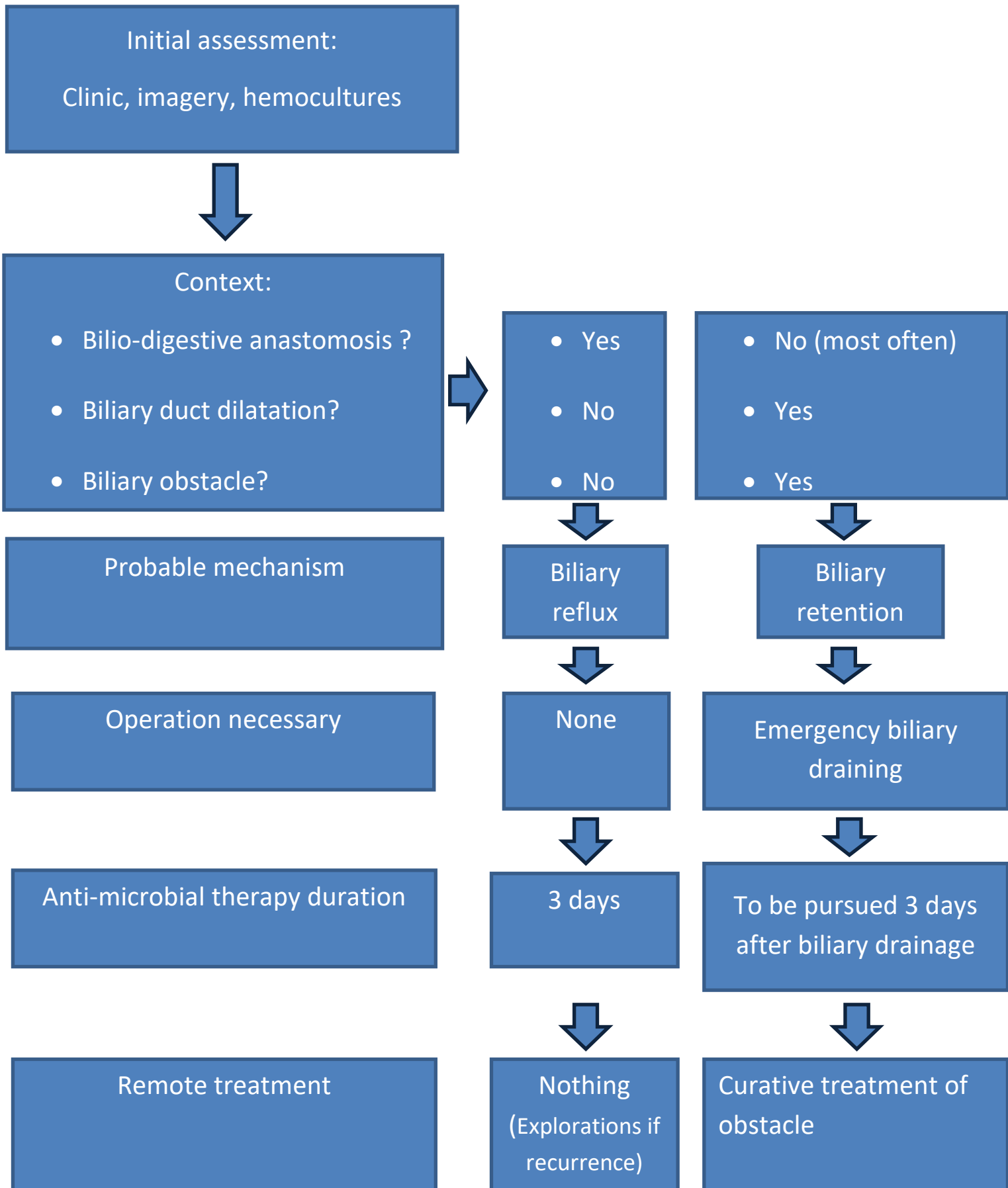
Mise au point : Angiocholite

Figure 1 : Proposition for treatment and management of acute cholangitis in accordance with the pathophysiological mechanism.

Figure 2 : Schema for the main causes of acute cholangitis

Original schema drawn from [9]. PSC: Primary sclerosing cholangitis

Figure 1 : Proposition for management and treatment of acute cholangitis in accordance with the pathophysiological mechanism



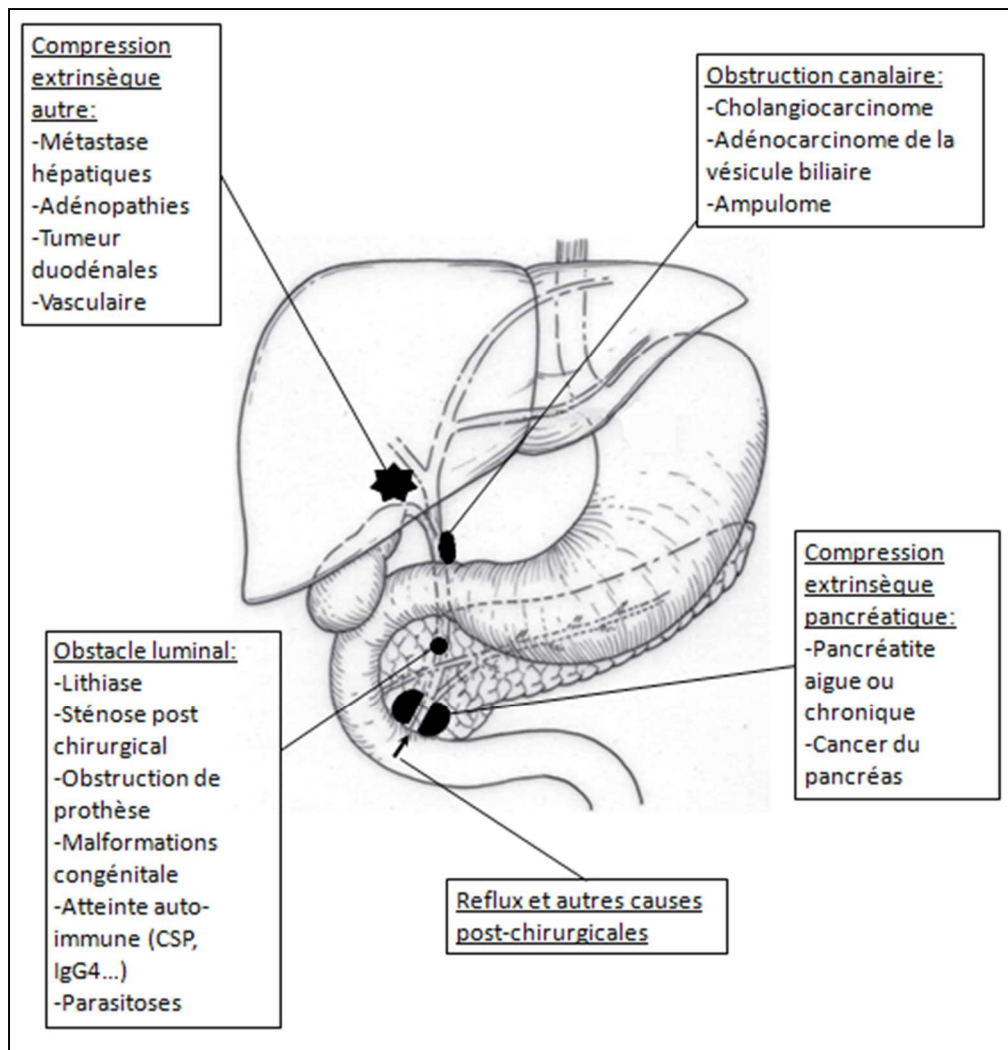


Figure 2 : Schema representing the main causes of acute cholangitis.

Original schema drawn from [10]. CSP: Primary sclerosing cholangitis

Other extrinsic compression: - Hepatic metastases - Adenopathy - Duodenal tumor - Vascular

Ductal obstruction: - Cholangiocarcinoma - Gall bladder adenocarcinoma - Periampullary cancer

Luminal obstruction: -Lithiasis - Post-surgical stenosis – Obstruction of prosthesis - Congenital malformations - autoimmune disorder (PSC, IgG4...) - Parasitosis

Extrinsic pancreatic compression: - Acute or chronic pancreatitis - Pancreatic cancer

Reflux and other post-surgical causes