



HAL
open science

Segmental aponeurectomy with Z-Plasty as a treatment option in Dupuytren's disease: A retrospective cohort study

Ludivine Gardeil, Valérie Matter Parrat, Anne Carole Portenard, Dorothee Coquerel, Albane Bonmarchand, Isabelle Auquit Auckbur

► To cite this version:

Ludivine Gardeil, Valérie Matter Parrat, Anne Carole Portenard, Dorothee Coquerel, Albane Bonmarchand, et al.. Segmental aponeurectomy with Z-Plasty as a treatment option in Dupuytren's disease: A retrospective cohort study. *Orthopaedics & Traumatology: Surgery & Research*, 2019, 105, pp.1627 - 1631. 10.1016/j.otsr.2019.08.016 . hal-03489179

HAL Id: hal-03489179

<https://hal.science/hal-03489179v1>

Submitted on 21 Jul 2022

HAL is a multi-disciplinary open access archive for the deposit and dissemination of scientific research documents, whether they are published or not. The documents may come from teaching and research institutions in France or abroad, or from public or private research centers.

L'archive ouverte pluridisciplinaire **HAL**, est destinée au dépôt et à la diffusion de documents scientifiques de niveau recherche, publiés ou non, émanant des établissements d'enseignement et de recherche français ou étrangers, des laboratoires publics ou privés.



Distributed under a Creative Commons Attribution - NonCommercial 4.0 International License

Original article

Segmental Aponeurectomy with Z-Plasty as a Treatment Option in Dupuytren's

Disease: A Retrospective Cohort Study

Ludivine **GARDEIL** (a), Valérie **MATTER PARRAT** (b), Anne Carole **PORTENARD** (a)

Dorothee **COQUEREL** (a), Albane **BONMARCHAND** (a), Isabelle **AUQUIT AUCKBUR**

(a)

(a) Service de Chirurgie plastique et de la main, CHU de Rouen, 1 Rue de Germont, 76031

Rouen Cedex, France

(b) Service de Chirurgie de la main, CHU de Strasbourg, 10 avenue Baumann, 67400 Illkirch

Graffenstaden, France

Corresponding author: Ludivine GARDEIL

ludivine.gardeil@gmail.com

ABSTRACT

Background: Aponeurectomy remains the reference standard treatment for digit tethering by palmar fascial cords in Dupuytren's disease but is associated with a substantial complication rate. An alternative technique decreases metacarpophalangeal joint (MCPJ) flexion contracture by combining palmar segmental aponeurectomy with Z-plasty skin closure. The primary objective of this study was to assess range of motion of the operated ray after the procedure. The secondary objectives were to assess the complication rate and to determine the recurrence rate after at least 1 year.

Hypothesis: Palmar segmental aponeurectomy with Z-plasty closure may provide the advantages of aponeurectomy while decreasing the surgical risk and recurrence rate.

Material and Methods: A retrospective study was conducted in 16 patients with predominant MCPJ flexion contracture due to a well-defined palmar fascial cord. Anaesthesia was loco-regional. The Z-plasty design involved a longitudinal incision along the palmar cord with an oblique incision at each end at a 60° angle to the longitudinal incision. The length of the aponeurectomy was about 1.5 cm, to allow full MCPJ extension.

Results: In all, the 16 patients – 13 males and 3 females – had 17 segmental palmar aponeurectomy procedures with Z-plasty closure. Mean operative time was 18 minutes. Before surgery, mean loss of extension was 47° at the MCP joint and 15° at the corresponding proximal interphalangeal joint (PIPJ). Immediately after surgery, a 97% improvement in MCPJ extension was noted, leaving a mean extension deficit of 1.25°. Mean follow-up was 18.9 months. No complications occurred. Two patients experienced a recurrence.

Discussion: Segmental palmar aponeurectomy as described by Moermans in 1991 improves extension similarly to extensive aponeurectomy but has a lower complication rate. Z-plasty provides good exposure of the pedicles and takes advantage of the greater pliability of the

skin on either side of the cord to lengthen the skin by 75%, thereby limiting the risk of the complications seen with needle aponeurotomy. Segmental palmar aponeurectomy with Z-plasty has a role in the management of Dupuytren's disease with flexion contracture predominantly involving the MCPJ.

Keywords: Dupuytren's disease, segmental aponeurectomy, Z-plasty, metacarpophalangeal joint contracture

Introduction

Dupuytren's disease is characterised by the benign proliferation of fibrous tissue in the palm of the hand. The cause is genetic and, consequently, no cure is available. Because Dupuytren's disease is common, its surgical treatment results in a major cost burden [1]. Extensive aponeurectomy is the most widely used treatment [2] and, when applied in a broad range of indications, improves joint extension ranging by 40% to 97% [3]. However, complications occur in 3.6% to 39.1% of cases, and the mean rate of major complications is 15.7% [4]. Moreover, recurrences are common. Thus, in a recent review the recurrence rate after 1 to 7 years ranged from 12% to 39% [5]. Another study found a 66% rate of recurrence within 10 years [6]. Further surgery is warranted only if the recurrence causes impairments but is associated with substantial risks [7], notably with a 10-fold increase in the rate of vascular injury [4].

Less invasive techniques associated with a lower risk of complications may therefore be helpful in patients whose predominant complaint is flexion contracture of a metacarpophalangeal joint (MCPJ) and who are relatively young or have early-stage or recurrent disease. Many surgical and non-surgical techniques have been suggested [8–10], including segmental palmar aponeurectomy with Z-plasty wound closure. Z-plasty takes advantage of the relative pliability of the skin on either side of the tethering cord and minimises the risk of the cutaneous complications seen with minimally invasive techniques after extension of the digit is restored.

The primary objective of this study was to assess range of motion of the operated ray after the procedure. The secondary objectives were to assess the complication rate and to determine the recurrence rate after at least 1 year. The working hypothesis was that palmar segmental aponeurectomy with Z-plasty closure may provide the advantages of aponeurectomy while decreasing the surgical risk and recurrence rate.

Patients and Methods

This single-centre retrospective study included 16 patients who underwent segmental palmar aponeurectomy with Z-plasty for Dupuytren disease at the Rouen university hospital (Rouen, France) between March 2015 and March 2017. Patients managed using other surgical techniques were not eligible for the study. All surgical procedures were performed by two senior surgeons at the plastic and hand surgery department of the Rouen university hospital. Patients were eligible for segmental palmar aponeurectomy with Z-plasty if they had flexion contracture predominantly involving the MCPJ of one or two adjacent rays, with a well-identified palmar fibrous cord.

All patients underwent segmental aponeurectomy with one or more Z-plasties, under locoregional anaesthesia. A tourniquet was placed at the root of the upper limb. An about 1.5-cm longitudinal incision was performed along the long axis of the cord. Starting at each end of this incision, a 60° oblique incision of identical length was performed. Several Z-plasties were used if the MCPJ flexion contracture was severe (Figure 1). These incisions allowed the creation of flaps and provided direct exposure of the cord. The neurovascular pedicles were visualised in the proximal-to-distal direction. Aponeurectomy was performed along about 1.5 cm, to allow full extension of the MCPJ. Upon extension of the digit, the skin flaps spontaneously lined up with the median tension line. Skin suturing was with separate stitches (Figure 2). A dynamic extension device with a Levame blade to keep the digit extended was fashioned after surgery and worn at night for several weeks. Each patient was assessed at least 1 year after surgery.

Loss of MCPJ and proximal interphalangeal joint (PIPJ) extension before surgery, 2 to 4 weeks after surgery, and at last follow-up was recorded, and the percentages of extension recovery were computed. We also recorded the operative time, complications, and

recurrences. Recurrence was defined as regrowth of fibroblastic tissue under the scar with a return of the MCPJ flexion contracture. Disease extension, in contrast, was defined as fibrosis of previously unaffected areas indicating spontaneous spread of the disease outside the surgical site.

The evaluation criteria were the absolute increase in extension range and the relative increase as a percentage of the initial extension deficit.

Results

We included 16 patients, 13 males and 3 females, who had a total of 17 palmar segmental aponeurectomy procedures with Z-plasty closure. The typical patient was a right-handed retiree who had surgery on the fourth ray of the left hand. Mean age at surgery was 68 years. Two patients had surgery for recurrences after needle aponeurotomy (patient #15) or extensive aponeurectomy (patient #17). The band was Y-shaped in 2 patients. Two rays of the same hand were treated during a single-stage procedure in 1 patient, and another patient had the procedure on both hands at an interval of 1 year. In all, surgery was performed on 20 rays. Most patients had Tubiana stage 1 or 2 disease (mean, 61.5°; range, 30°-120°) (Table 1) with a mean extension deficit of 47° (range, 30°-70°) at the MCPJ and 15° (range, 0°-60°) at the PIPJ.

At the early post-operative evaluation, full MCPJ extension was achieved in 95% of patients and mean extension loss was 1.25° (range, 0°-25°) at the MCPJ and 11.3° (range, 0°-60°) at the PIPJ (Table 2). The relative extension gain at this time point was 97% at the MCPJ and 23% at the PIPJ (Table 3). The PIPJ flexion contracture was improved in 50% of patients.

Follow-up was 1 to 3 years (mean, 18.9 months) in 14 patients; the remaining 2 patients were lost to follow-up after the early post-operative assessment. A recurrence developed at the MCPJ within the first year in 2 (11.1%) cases, including 1 with no adverse impact on joint

mobility (patient #5). Disease extension was common; thus flexion contracture of the PIPJ of the operated ray developed or progressed in 22.2% of cases.

No complications were recorded: there were no instances of nerve injury, digital necrosis, haematoma, infection, or complex regional pain syndrome.

Mean tourniquet time was 18 minutes.

Discussion

Palmar segmental aponeurectomy as described by Moermans [10] provides similar outcomes to those achieved by extensive aponeurectomy while having the low complication rates typical of minimally invasive techniques [5]. In a study of 56 patients managed using this technique combined with a C-shaped incision, full extension of the digit was achieved, the 1-year recurrence rate was 6%, and skin infection developed in only 2 patients [11]. Another study, of 40 hands, also managed with a C-shaped incision allowing excision of the nodule, produced a 37.1° increase in MCPJ extension with only 7 (17.5%) recurrences within 1 year, impaired wound healing in 1 case, a flexion deficit in 2 cases, and a nerve injury repaired intra-operatively in 1 case [12]. Among our patients, 95% recovered full extension. Added Z-plasty closure produced a 75% increase in longitudinal skin length by taking advantage of the relative pliability of the skin on either side of the cord [13,14]. This minimises the skin complications seen with percutaneous techniques and decreases wound care duration. No complications were recorded in our patients. Work by Mc Grouther [15] on the pathophysiology of Dupuytren's disease, as well as findings from two studies [16,17], suggest that the decreased tension on the scar achieved by the Z-plasty may decrease the risk of recurrence.

Other minimally invasive techniques are available for patients with flexion contracture predominantly involving a MCPJ, including needle aponeurotomy. Collagenase injections were introduced more recently but are generally reserved for patients at more advanced stages of the disease. These percutaneous techniques have produced very good outcomes with a low rate of major complications [3]. In a study of 1013 digits managed using needle aponeurotomy, mean MCPJ correction was 99% immediately after the procedure and the complication rates were low, with 34 (3.4%) cases of impaired wound healing, 6 (1.2%) cases of transient neurapraxia, and 1 (0.1%) case of nerve laceration [18]. In another study, of 311 digits, the increase in MCPJ extension was 79% and there was a single case of intra-operative nerve injury [19]. Phase II placebo-controlled trials of collagenase injection showed an 87.1% increase in MCPJ extension 30 days after the last injection [20]. The persistence of the abnormal tissue with these techniques explains the higher recurrence rates [18,19,21]. These minimally invasive methods carry a higher risk of skin complications (9% to 25%) during extension of the digit or at the injection site [5]. A meta-analysis showed that the number of complications after collagenase injection was at least 1 per patient [22] and did not correlate with disease severity [23]. These complications are minor but require a longer period of wound care, although the technique consists only in stab incisions. The injection of stromal vascular fraction after needle aponeurotomy may improve skin trophicity, thereby decreasing wound care duration [24].

Pre-operative adjustments are necessary to determine the placement of the Z-plasty incisions. The longitudinal length increase induced by the Z-plasty is equal to the decrease in the transverse direction. The need imposed by the strong contractures in Dupuytren's disease to lengthen the skin by several centimetres may come into conflict with the limited reserve along the transverse dimension of the palm. The 60° angle was chosen as the best compromise, with a 75% ratio in both directions [25]. Combining several Z-plasties is useful

to increase the lengthening when the MCPJ contracture is severe. The position of the Z-plasty is also important. Mc Gregor stated that the residual transverse scar should be positioned along the distal palmar crease [26]. However, the limited pliability of the palmar skin is an impediment to rotation of the flaps. In our experience, the skin integrated into the Z-plasty is more pliable and thicker when the incisions are positioned more distally, between the distal palmar crease and the crease at the base of the digits. The presence of a deep umbilication or adherent scar limits the ability to perform a Z-plasty, as it increases the risk of skin compromise. The application of these few rules is effective in avoiding the development of skin necrosis [27].

Malingue's plasty is a variant of the multiple Z-plasty that involves the exchange of two trapezoid flaps [28]. By recruiting the skin on the lateral side of the cord, this procedure increases the skin surface area by 46% without increasing the risk of cutaneous compromise. The recurrence rate of 10.3% was similar to the 11.1% rate in our population. Another skin closure technique that lengthens the skin is the Y-V plasty. No differences in recurrence rates have been demonstrated across skin plasty techniques [29].

We extended the indications of palmar segmental aponeurotomy to MCPJ contracture combined with a PIPJ deficit if the Tubiana score was 1 or 2. Improving the PIPJ flexion contracture was not our main objective but was nevertheless achieved in 50% of cases. We also performed palmar segmental aponeurotomy in 3 patients with a Tubiana score of 3 for reasons of patient preference, patient age, and recurrence 2 years after primary surgery, respectively. All 3 patients reported being satisfied and having experienced improvements for their daily activities.

The small sample size and limited follow-up duration in our study did not allow us to demonstrate a decrease in the recurrence rate with our surgical technique. A further study in a larger population and with a longer follow-up would allow an evaluation of this point.

Conclusion

We believe that palmar segmental aponeurectomy with Z-plasty closure is a valid therapeutic option for the treatment of Dupuytren disease. This technique is indicated when the flexion contracture predominantly involves the MCPJ. However, it may be suitable also when the cord limits the range of motion of the PIPJ in a patient who is not eligible for extensive aponeurectomy (due to patient preference, advanced age, or an early recurrence carrying a high risk of vascular injury).

Disclosure of interest

None of the authors has any conflicts of interest to declare.

Funding

None

Contributions of each author

LG performed the final evaluation and drafted the manuscript.

VMP and ACP contributed to draft the manuscript.

DC revised the manuscript for important intellectual content.

AB performed the procedures and revised the manuscript for important intellectual content.

IA conceived the technique, performed the procedures, and revised the manuscript for important intellectual content.

References

1. Maravic M, Lasbleiz S, Roulot E, Beaudreuil J. Hospitalization for Dupuytren's disease: a French national descriptive analysis, 2002 to 2009. *Orthop Traumatol Surg Res*. 2014 Oct;100(6):589–92.
2. Henry M. Dupuytren's disease: current state of the art. *Hand*. 2014 Mar;9(1):1–8.
3. Crean SM, Gerber RA, Le Graverand MPH, Boyd DM, Cappelleri JC. The efficacy and safety of fasciectomy and fasciotomy for Dupuytren's contracture in European patients: a structured review of published studies. *J Hand Surg Eur Vol*. 2011 Jun;36(5):396–407.
4. Denkler K. Surgical complications associated with fasciectomy for dupuytren's disease: a 20-year review of the English literature. *Eplasty*. 2010 Jan 27;10:e15.
5. Chen NC, Srinivasan RC, Shauver MJ, Chung KC. A systematic review of outcomes of fasciotomy, aponeurotomy, and collagenase treatments for Dupuytren's contracture. *Hand*. 2011 Sep;6(3):250–5.
6. Leclercq C, Tubiana R. La récurrence dans la Maladie de Dupuytren. *E-Mém Académie Natl Chir*. 2002;1(3):33–5.
7. Hueston J. Treatment of recurrent Dupuytren's disease. 1992. *Chir Main*. 2001 Jun;20(3):199–205.
8. Morhart M. Pearls and pitfalls of needle aponeurotomy in Dupuytren's disease. *Plast Reconstr Surg*. 2015 Mar;135(3):817–25.
9. Badalamente MA, Hurst LC. Enzyme injection as nonsurgical treatment of Dupuytren's disease. *J Hand Surg*. 2000 Jul;25(4):629–36.
10. Moermans JP. Segmental aponeurectomy in Dupuytren's disease. *J Hand Surg Br*. 1991 Aug;16(3):243–54.
11. Clibbon JJ, Logan AM. Palmar segmental aponeurectomy for Dupuytren's disease with metacarpophalangeal flexion contracture. *J Hand Surg Br*. 2001 Aug;26(4):360–1.

12. Andrew JG, Kay NR. Segmental aponeurectomy for Dupuytren's disease: a prospective study. *J Hand Surg Br.* 1991 Aug;16(3):255–7.
13. Rohrich RJ, Zbar RI. A simplified algorithm for the use of Z-plasty. *Plast Reconstr Surg.* 1999 Apr;103(5):1513–7; quiz 1518.
14. Hudson DA. Some thoughts on choosing a Z-plasty: the Z made simple. *Plast Reconstr Surg.* 2000 Sep;106(3):665–71.
15. McGrouther DA. The microanatomy of Dupuytren's contracture. *Hand.* 1982 Oct;14(3):215–36.
16. Ullah AS, Dias JJ, Bhowal B. Does a “firebreak” full-thickness skin graft prevent recurrence after surgery for Dupuytren's contracture?: a prospective, randomised trial. *J Bone Joint Surg Br.* 2009 Mar;91(3):374–8.
17. Citron N, Hearnden A. Skin tension in the aetiology of Dupuytren's disease; a prospective trial. *J Hand Surg Br.* 2003 Dec;28(6):528–30.
18. Pess GM, Pess RM, Pess RA. Results of needle aponeurotomy for Dupuytren contracture in over 1,000 fingers. *J Hand Surg.* 2012 Apr;37(4):651–6.
19. Foucher G, Medina J, Navarro R. Percutaneous needle aponeurotomy: complications and results. *J Hand Surg Br.* 2003 Oct;28(5):427–31.
20. Hurst LC, Badalamente MA, Hentz VR, Hotchkiss RN, Kaplan FTD, Meals RA, et al. Injectable collagenase clostridium histolyticum for Dupuytren's contracture. *N Engl J Med.* 2009 Sep 3;361(10):968–79.
21. Peimer CA, Blazar P, Coleman S, Kaplan FTD, Smith T, Lindau T. Dupuytren Contracture Recurrence Following Treatment With Collagenase Clostridium histolyticum (CORDLESS [Collagenase Option for Reduction of Dupuytren Long-Term Evaluation of Safety Study]): 5-Year Data. *J Hand Surg.* 2015 Aug;40(8):1597–605.

22. Brazzelli M, Cruickshank M, Tassie E, McNamee P, Robertson C, Elders A, et al. Collagenase clostridium histolyticum for the treatment of Dupuytren's contracture: systematic review and economic evaluation. *Health Technol Assess*. 2015 Oct;19(90):1–202.
23. Sanjuan-Cerveró R, Carrera-Hueso FJ, Vazquez-Ferreiro P. Adverse effects associated with collagenase clostridium histolyticum in Dupuytren disease: A prospective study. *Orthop Traumatol Surg Res*. 2018 Oct;104(6):901–5.
24. Nseir I, Delaunay F, Latrobe C, Bonmarchand A, Coquerel-Beghin D, Auquit-Auckbur I. Use of adipose tissue and stromal vascular fraction in hand surgery. *Orthop Traumatol Surg Res*. 2017;103(6):927–32.
25. McGregor IA. The theoretical basis of the Z-plasty. *Br J Plast Surg*. 1957 Jan;9(4):256–9.
26. McGregor IA. The Z-plasty in hand surgery. *J Bone Joint Surg Br*. 1967 Aug;49(3):448–57.
27. Gelberman RH, Panagis JS, Hergenroeder PT, Zakaib GS. Wound complications in the surgical management of Dupuytren's contracture: a comparison of operative incisions. *The Hand*. 1982 Oct;14(3):248–54.
28. Aparé T, Saint-Cast Y. [Malingue's procedure for digital retraction in Dupuytren's contracture--principle, modelling and clinical evaluation]. *Chir Main*. 2011 Feb;30(1):31–4.
29. Citron ND, Nunez V. Recurrence after surgery for Dupuytren's disease: a randomized trial of two skin incisions. *J Hand Surg Br*. 2005 Dec;30(6):563–6.

Table 1: Main features of the 16 study patients

Table 2: Extension deficits (°) at each time point

MCPJ: metacarpophalangeal joint; PIPJ: proximal interphalangeal joint; DIPJ: distal interphalangeal joint

Table 3: Short-term outcomes

MCPJ: metacarpophalangeal joint; PIPJ: proximal interphalangeal joint

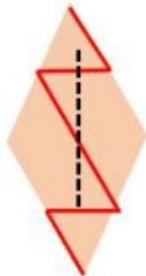
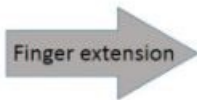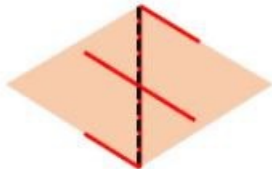
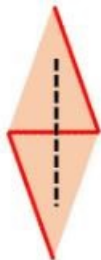
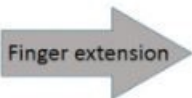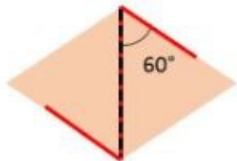
FIGURE LEGENDS

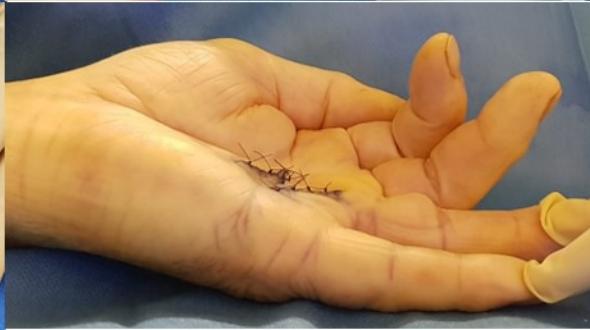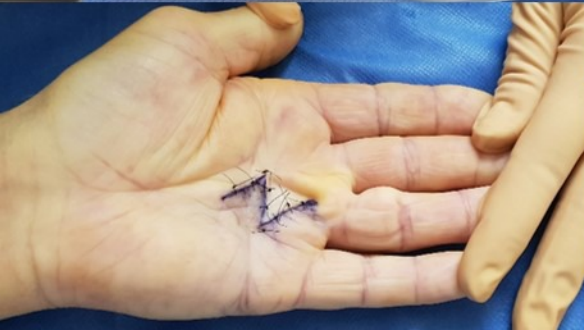
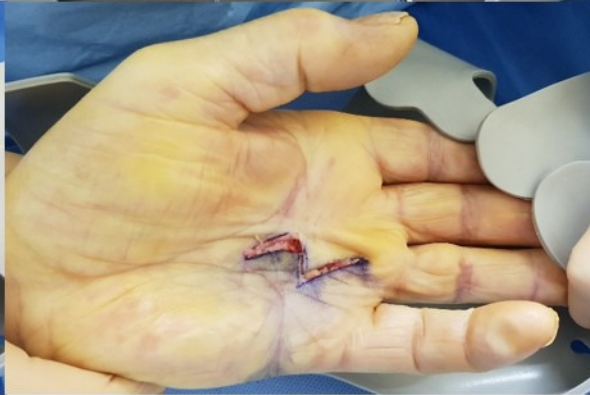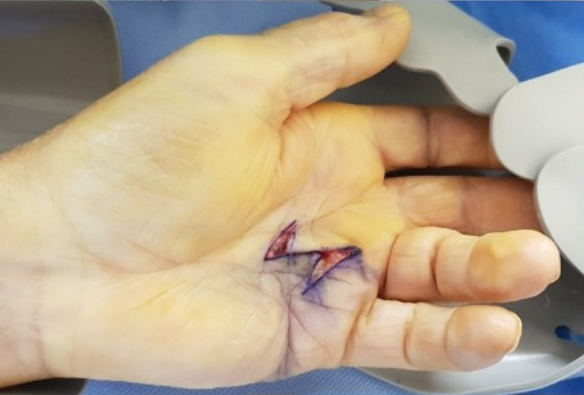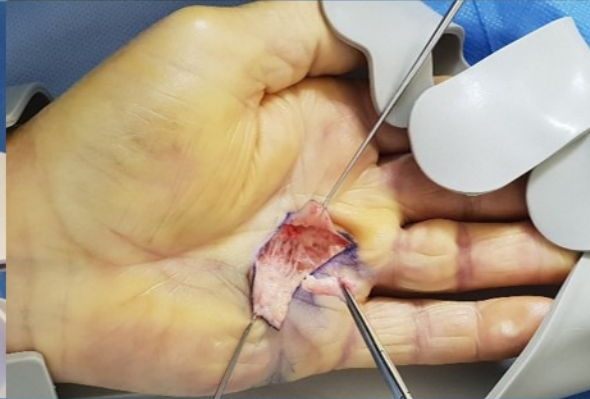
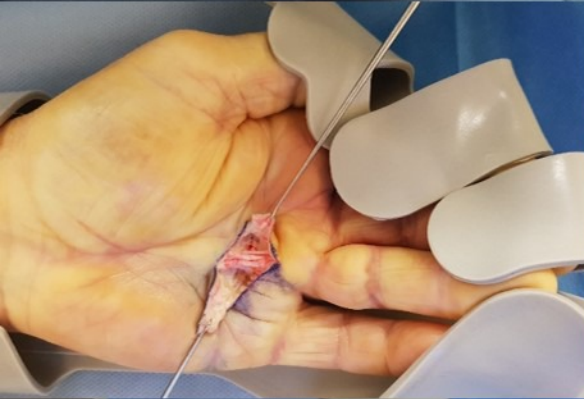
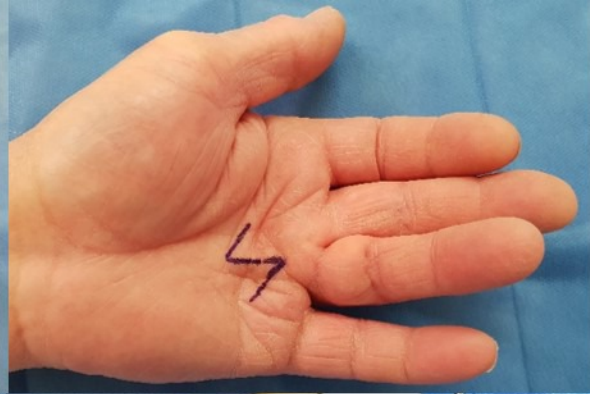
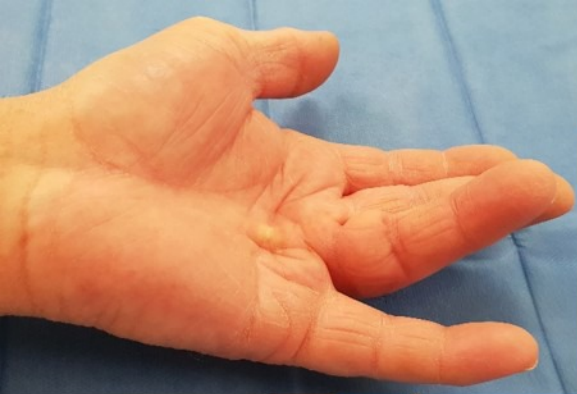Figure 1: Z-plasty design

- A. All incisions are the same length and both angles are 60° ; the result is 75% lengthening in the longitudinal direction
- B. Double Z-plasty: the longer incision resulted in increased longitudinal lengthening without increasing the transverse shortening

Figure 2: Operative technique

- a) Before surgery: cord tethering the fourth ray of the left hand
- b) Pre-operative marking of the Z-plasty
- c) During surgery: visualisation of the cord
- d) Complete excision of the cord allows full extension of the digit.
- e) Initial flap position
- f) Spontaneous positioning of the flaps upon extension of the digit
- g) Tension-free skin closure
- h) Full extension of the metacarpophalangeal joint





Case #	Age	Gender	Employment status	Dominant hand	Hand	Finger(s)	Tubiana stage
1	74	woman	retired	right	right	4	1 (40°)
2	60	man	technician	right	left	3 and 4	2 (65°) /1 (30°)
3	64	man	retired	right	left	4	2 (40°)
4	70	man	retired	right	left	4	1 (45°)
5	73	man	retired	right	left	5	1 (30°)
6	70	man	retired	right	left	4-5 Y	2 (50°)/(80°)
7	64	man	retired	right	left	4	2 (55°)
8	59	man	company manager	right	right	5	3 (120°)
9	73	man	retired	left	left	4	2 (90°)
10	63	man	ambulance driver	right	right	4	2 (60°)
11	47	man	machine operator	right	right	4	2 (50°)
12	65	man	retired	right	left	4	2 (60°)
13	81	woman	retired	right	left	5	2 (55°)
14	67	man	truck driver	right	left	5	2 (85°)
15	86	man	retired	right	right	4	3 (115°)
16	86	man	retired	right	left	4	1 (45°)
17	70	woman	retired	right	left	4-5 Y	1(30°) / 3 (110°)

Case #	Affected digit(s)	Pre-op, extension deficit (°)	Post-op, extension deficit (°)	Extension deficit at last follow-up (°)	Follow-up duration (months)
1	4th right	MCPJ : 40 PIPJ : 0	MCPJ : 25 PIPJ : 0	MCPJ : 25 PIPJ : 0	36
2	3rd and 4th left	MCPJ : 50/30 PIPJ : 15/0	MCPJ : 0/0 PIPJ : 15/0		lost to follow-up
3	4th left	MCPJ : 40 PIPJ : 0	MCPJ : 0 PIPJ : 0	MCPJ : 0 PIPJ : 0	24
4	4th left	MCPJ : 45 PIPJ : 0	MCPJ : 0 PIPJ : 0	MCPJ : 20 PIPJ : 10	12
5	5th left	MCPJ : 30 PIPJ : 0	MCPJ : 0 PIPJ : 0	MCPJ : 30 PIPJ : 0	24
6	4th and 5th left, Y	MCPJ : 50/65 PIPJ : 0/15	MCPJ : 0/0 PIPJ : 0/10	MCPJ : 0/0 PIPJ : 0/10	22
7	4th left	MCPJ : 30 PIPJ : 25	MCPJ : 0 PIPJ : 25	MCPJ : 0 PIPJ : 25	21
8	5th right	MCPJ : 70 PIPJ : 50	MCPJ : 0 PIPJ : 20	MCPJ : 0 PIPJ : 30	21
9	4th left	MCPJ : 65 PIPJ : 25	MCPJ : 0 PIPJ : 15	MCPJ : 0 PIPJ : 15	20
10	4th right	MCPJ : 30 PIPJ : 30	MCPJ : 0 PIPJ : 15		lost to follow-up
11	4th right	MCPJ : 50 PIPJ : 0	MCPJ : 0 PIPJ : 0	MCPJ : 0 PIPJ : 0	17
12	4th left	MCPJ : 30 PIPJ : 30	MCPJ : 0 PIPJ : 30	MCPJ : 0 PIPJ : 60	17
13	5th left	MCPJ : 55 PIPJ : 0	MCPJ : 0 PIPJ : 0	MCPJ : 0 PIPJ : 20	16
14	5th left	MCPJ : 60 PIPJ : 25	MCPJ : 0 PIPJ : 25	MCPJ : 0 PIPJ : 25	15
15	4th right	MCPJ : 70 PIPJ : 20 DIPJ : 25	MCPJ : 0 PIPJ : 10	MCPJ : 0 PIPJ : 10	15
16	4th left	MCPJ : 45 PIPJ : 0	MCPJ : 0 PIPJ : 0	MCPJ : 0 PIPJ : 0	12
17	4th and 5th left, Y	MCPJ : 30/50 PIPJ : 0/60	MCPJ : 0/0 PIPJ : 0/60	MCPJ : 0/0 PIPJ : 0/60	12

	MCPJ	PIPJ
Pre-op. extension deficit	47°	15°
Post-op. extension deficit	1.25°	11.3°
Percentage extension gain	97%	23%