



HAL
open science

Endovascular Aneurysm Sealing and Chimney Endovascular Aneurysm Sealing in the Treatment of Type Ia and Type III Endoleaks After Endovascular Aneurysm Repair

Fabien Lareyre, Claude Mialhe, Carine Dommerc, Juliette Raffort

► To cite this version:

Fabien Lareyre, Claude Mialhe, Carine Dommerc, Juliette Raffort. Endovascular Aneurysm Sealing and Chimney Endovascular Aneurysm Sealing in the Treatment of Type Ia and Type III Endoleaks After Endovascular Aneurysm Repair. *Annals of Vascular Surgery*, 2019, 61, pp.317 - 325. <10.1016/j.avsg.2019.05.029>. <hal-03488858>

HAL Id: hal-03488858

<https://hal.science/hal-03488858v1>

Submitted on 21 Jul 2022

HAL is a multi-disciplinary open access archive for the deposit and dissemination of scientific research documents, whether they are published or not. The documents may come from teaching and research institutions in France or abroad, or from public or private research centers.

L'archive ouverte pluridisciplinaire HAL, est destinée au dépôt et à la diffusion de documents scientifiques de niveau recherche, publiés ou non, émanant des établissements d'enseignement et de recherche français ou étrangers, des laboratoires publics ou privés.



Distributed under a Creative Commons CC BY-NC 4.0 - Attribution - Non-commercial use - International License

1 **Endovascular aneurysm sealing (EVAS) and chimney EVAS in the treatment of type Ia**
2 **and type III endoleaks after endovascular aneurysm repair (EVAR)**

3

4

5 Fabien Lareyre^(1,2), MD, PhD, Claude Mialhe⁽¹⁾, MD, Carine Dommerc⁽¹⁾, PhD, Juliette Raffort⁽²⁾, MD,
6 PhD

7 ⁽¹⁾ Cardiovascular Surgery Unit, Cardio Thoracic Centre of Monaco, Monaco

8 ⁽²⁾ Université Côte d'Azur, CHU, Inserm, C3M, Nice, France

9

10 **Corresponding author:** Fabien Lareyre, M.D

11 Cardio Thoracic Centre of Monaco

12 Avenue d'Ostende 11 bis 98000 Monaco

13 Fax number: +377 93 25 43 82

14 Telephone number: +377 92 16 82 14

15 Email address: fabien.lareyre@gmail.com

16 **E-mail addresses for all co-authors:**

17 fabien.lareyre@gmail.com,

18 cmialhe@ccm.mc

19 cdommerc@ccm.mc

20 juliette.raffort@hotmail.fr

21

22 **Acknowledgements:** none

23 **Conflicts of interest:** On behalf of all authors, the corresponding author states that there is no conflict
24 of interest.

25

26 **Abstract**

27 *Purpose:* The aim of this study was to report the treatment of type Ia and type III endoleaks
28 following EVAR or chimney-EVAR using EVAS and chimney-EVAS.

29 *Methods:* Ten consecutive patients who underwent EVAS procedure to treat endoleaks
30 following EVAR were retrospectively included between July 2015 and July 2017. Technical
31 success of EVAS was defined as a successful sealing of the Nellix endograft with visceral
32 vessel patency on intraoperative completion angiography.

33 *Results:* The median time between EVAR and EVAS procedure was 41.5 months (29 – 81.8).
34 Eight patients had an elective procedure, whereas 2 were treated in emergency. Chimney
35 endografts were placed during EVAS procedure in 4 patients whereas classic EVAS was
36 performed for the other 6 patients. The median procedural time was 222.5 minutes (138.8 –
37 418.8). The technical success was achieved for all patients. The median length of stay after
38 EVAS was 7 days (6.8 – 14). No death related to AAA or vascular complications were
39 reported for a median follow-up of 13.5 months (6.3 – 25.5). A re-intervention was required
40 for 2 patients who developed a persistent type II and type Ia endoleak which were
41 successfully treated using embolization procedure.

42 *Conclusion:* EVAS and chimney EVAS in the treatment of type Ia and type III endoleaks
43 following EVAR and chimney EVAR is technically feasible. Short-term follow-up suggests
44 that the procedure is a safe and efficient therapeutic alternative to manage disabled EVAR.

45

46

47 **Introduction**

48 Endovascular aneurysm repair (EVAR) has become a well-established alternative to open
49 repair (1). However, some patients may develop endoleaks, representing one of the most
50 frequent complications following EVAR (2-4). Even though endoleaks can resolve without
51 intervention, some can lead to sac aneurysm increase and cause aneurysm rupture (5). Type I
52 and type III endoleaks usually require a re-intervention using endovascular procedures or
53 open surgery to treat it. Several endovascular approaches have been described and their
54 technical success depends on the clinical and anatomical characteristics of the patient as well
55 as the experience of the centre and the training of the operators (6, 7). Nellix (Endologix,
56 Irvine, California) endovascular aneurysm sealing (EVAS) is a recent endovascular approach
57 which has demonstrated encouraging results in the treatment of abdominal aortic aneurysm
58 (AAA) (8-12). The Nellix system comprises two balloon-expandable endoframes each
59 surrounded by a polymer-filled endobag, allowing to fill the lumen of the AAA by the
60 polymer. Its use in the management of complications following prior endovascular aneurysm
61 repair (EVAR) has been so far scarcely investigated. A few studies described the treatment of
62 type I or type III endoleaks as well as ruptured AAA following EVAR using the EVAS
63 system (13-19). However, the cohorts used were small and the majority of patients who had
64 prior EVAR had a bifurcated endograft. Only a few studies reported patients who previously
65 had fenestrated endografts (13, 20) and none of them involved patients with prior chimney-

66 EVAR. In this context, the aim of this study was to investigate the feasibility of EVAS and
67 chimney-EVAS in the treatment of type Ia and type III endoleaks in patients who had prior
68 EVAR or chimney-EVAR.

69

70 **Material and methods**

71 *Patients*

72 Ten consecutive patients who underwent EVAS procedure following EVAR between July
73 2015 and October 2017 were retrospectively included (Table 1). This study was conducted in
74 conformity with the Declaration of Helsinki. The study protocol was approved by our
75 institutional local ethics committee and all enrolled patients gave informed written consent for
76 the procedure. The median age at the time of EVAS was 76 years (71.3 – 87.3) and the
77 proportion of men was 8 /10. Manuscript and electronic medical records from the computer
78 software program (Emed®, Bellerive sur Allier, France) were used to collect the clinical
79 characteristics of patients. EVAR was performed in our center. The indication of EVAR was
80 evaluated by a pluridisciplinary team composed of vascular surgeon and anesthetist based on
81 clinical and anatomical characteristics of patients, according to current guidelines (5, 21).
82 Imaging data were retrieved from the picture archiving and communication system (PACS).
83 Aortic aneurysm diameters were measured on the CT-scan imaging using automatic three-
84 dimensional sizing software (Endosize®, Therenva, Rennes, France). The sizing was
85 performed independently by a vascular surgeon and a technician of radiology. Several types
86 of endografts were available: Anaconda (Vascutek, Inchinnan, United Kingdom), AFX
87 (Endologix Inc, Irvine, California), Zenith (Cook Inc, Bloomington, Indiana), Endurant and
88 Talent (both Medtronic, Santa Rosa, California). Type I and type III endoleaks were defined
89 according to current guidelines (5). EVAS procedure was proposed to patients who developed

90 type Ia or type III endoleaks following EVAR and the indications were evaluated by a
91 vascular surgeon based on clinical, anatomic and imaging characteristics.

92

93 *Surgical procedure for EVAS*

94 EVAS was performed under general anaesthesia according to the technique previously
95 described (22). Access was achieved via bilateral percutaneous common femoral artery
96 punctures. Chimney-EVAS was performed in patients where a suprarenal seal was necessary
97 and more conventional treatments difficult or contra-indicated. For the chimney-EVAS, the
98 left axillary artery was exposed via open cut down. Renal and visceral arteries were
99 cannulated and long 7-F sheaths were placed. Covered balloon expandable stents (Bentley
100 InnoMed, Hechingen, Germany or Advanta V12 Atrium Maquet Getinge Group, Mijdrecht,
101 Netherlands) were placed into each of the target vessels. The Nellix stent-graft was introduced
102 via the common femoral artery and was positioned infrarenal into the iliac limbs.
103 Sequentially, the covered balloon expandable stents were inflated; then the Nellix stents.
104 Normal saline was used as a “pre-fill” to inflate the endobags. They were then inflated with an
105 aqueous polyethylene glycol-based polymer. All stent grafts were maintained inflated until
106 the polymer cured. Angiography was systematically performed at the end of the procedure to
107 assess the patency of the Nellix stent-grafts, chimney stents and identify the presence of
108 dissections and endoleaks. Arterial closure was performed using Prostar® XL Percutaneous
109 Vascular Surgical System or Proglide® System (Abbott Vascular).

110

111 *Study endpoints*

112 Technical success was defined as a successful sealing of the endoleak by the Nellix endograft
113 associated with Nellix and visceral stents patency on intraoperative completion angiography.
114 After EVAS, patients were regularly followed at 7 days, 1, 6 and 12 months. The outcomes
115 following EVAS were collected including the post-operative mortality, the occurrence of
116 endoleaks or the need of re-intervention. Re-intervention was defined as any secondary
117 procedure performed to maintain aneurysm exclusion or visceral perfusion.

118

119 *Statistical analysis*

120 Categorical data were expressed as ratio (number of patients reported to the total population)
121 and continuous variables were expressed as the median (interquartile range). Statistical
122 analyses were performed using GraphPad Prism® software (version 7.00, La Jolla California
123 USA).

124

125 **Results**

126 Ten patients with prior EVAR underwent an EVAS procedure to treat endoleaks (Table 1).
127 The maximum AAA diameter at the initial EVAR was 67.5 mm (50 – 71.3). During the initial
128 EVAR procedure, a chimney endograft was implanted for 3 patients; all of them had a 3-
129 vessel chimney endograft. The procedural characteristics of the EVAR procedure are detailed
130 in Table 2. Among the 7 patients who had a standard-EVAR procedure, 4 patients developed
131 a type Ia endoleak and 3 a type III endoleak (2 were due to a modular disconnection and 1 to
132 fabric tear in the body stent graft). Among the 3 patients who had a chimney-EVAR, 1
133 developed a type Ia endoleak and 2 a type III endoleak (1 was due to a modular disconnection
134 and 1 to fabric tear in the body stent graft).

135 The median time between EVAR and EVAS procedure was 41.5 months (29 – 81.8). At the
136 time of EVAS procedure, the maximum AAA diameter was 76 mm (64 – 92.3). Eight patients
137 had an elective procedure to treat a type I or a type III endoleak, regardless of aneurysm sac
138 growth. Two patient were treated in emergency. These 2 patients were admitted for an acute
139 back pain. For the first one, CT-scan revealed a type III endoleak without rupture which was
140 immediately treated using EVAS. The second one was treated for a type II endoleak
141 associated with a peri-aortic effusion. Additional chimney endografts were placed during
142 EVAS procedure in 4 patients; 2 had a 2-vessel chimney graft and 2 had a 3-vessel graft. The
143 median procedural time was 222.5 minutes (138.8 – 418.8). The median polymer fill volume
144 was 51.5 mL (32 – 57.5). The technical success was achieved for all patients. Representative
145 images of EVAS procedure to treat type III endoleak following chimney EVAR are shown in
146 Figure 1.

147 The median length of stay after EVAS was 7 days (6.8 – 14) and the median length of stay in
148 intensive care unit was 1 day (1 – 2).

149 The median follow-up period was 13.5 months (6.3 – 25.5). During the follow-up, 2 patients
150 died at respectively 19 days and 178 days following EVAS. The cause of death was an intra-
151 cerebral haemorrhage secondary to a trauma for the first patient and the aetiology was
152 unknown for the second one. No death related to AAA or vascular complications were
153 reported. A re-intervention was required for 2 patients. The first patient developed a type II
154 endoleak originating from the lumbar arteries diagnosed 5 months after EVAS (Figure 2A).
155 The second patient developed a type Ia endoleak. He was asymptomatic and the diagnosis was
156 suspected on the CT-scan performed at 5 months after EVAS. The presence of contrast agent
157 was observed in the aneurysmal sac without enlargement. An arteriography was then
158 performed and confirmed the diagnosis (Figure 2B). Both complications were successfully

159 treated using embolization procedure. No graft thrombosis, chimney graft occlusion or
160 endobag protrusion were reported.

161

162 **Discussion**

163 The development of type I and type III endoleaks after EVAR is often associated with
164 aneurysm sac enlargement and exposes to the risk of aneurysm rupture (5). They represent a
165 frequent complication affecting up to 12% of patients following EVAR and most often require
166 a re-intervention (4, 21). The treatment can be complex due to the presence of the endograft
167 and can be challenging especially in patients with difficult aneurysm morphology such as the
168 presence of an unfavourable neck or aneurysm extended to visceral vessels. Cannulating
169 visceral vessels can be challenging due to the presence of the previous graft. Endovascular
170 repair options for type I endoleaks include the placement of a proximal cuff, ballon molding
171 of the seal zone, embolization with coils or glue, or the use of endostaples (6, 23, 24). Other
172 alternatives include the use of chimney or fenestrated endografts (25, 26). Type III endoleaks
173 result from an incomplete seal between components or component separation and is also
174 associated with an increased risk of rupture. The treatment requires bridging the gap with an
175 appropriate graft using endovascular or open repair (5, 27). Endovascular procedures include
176 insertion of an aorto-uni-iliac endograft, insertion of an endograft limb extension or placement
177 of a covered stent (27). However, positioning and sizing the endograft can be difficult,
178 especially if the endoleak is located near the flow divider (15). In addition, the insertion of an
179 aorto-uni-iliac endograft can require a femoro-femoral bypass. There is currently no clear
180 consensus regarding the choice of the endovascular technique to treat type I and type III
181 endoleaks. The choice of the method depended on the patient's clinical and anatomic

182 characteristics, the experience of the centre as well as the training of the operators, taking in
183 consideration the advantages and limitations of each technique.

184 EVAS technique has emerged as a new endovascular approach and several studies have
185 demonstrated its safety and efficacy in the treatment of AAA (9, 28-31). The technique has
186 the advantage to conform to the anatomical and prosthetic structures and to achieve an
187 efficient seal thanks to the polymer endobags. The technique uses off-the-shelf products,
188 avoiding the requirement of custom-made material. In addition, the use of EVAS in
189 combination with chimney grafts offers the benefit to fill the spaces between the parallel
190 grafts by the endobags and thus limits the development of gutters (16, 32, 33). Due to its
191 advantages, EVAS technique represents an interesting alternative technique which could be
192 useful in the treatment of disabled endoprosthesis following EVAR even though it is currently
193 outside the instructions for use. Besides, the procedure requires a low polymer volume to fill
194 the endobag and self-expanding stent-graft are protected by the delivery system until the
195 deployment.

196 This study reported a single-centre experience on the treatment of type Ia and type III
197 endoleaks using EVAS and chimney-EVAS. Our results revealed an immediate technical
198 success in all patients on the per-operative angiography and no death related to AAA or
199 vascular complications, suggesting that this approach is safe. The median in-hospital length of
200 stay was relatively long as two patients stayed 33 days and 20 days respectively to treat non-
201 vascular medical complications. During the follow-up, two patients required a re-intervention
202 to treat a type Ia and a type II endoleak. Only a few studies reporting the management of
203 complications following EVAR using EVAS technique have been published so far (10, 13-20,
204 34). Among them, a study reported a serie of 15 consecutive patients with prior EVAR treated
205 with EVAS. EVAS was performed to treat 10 patients with type Ia endoleaks and 5 patients
206 with type III endoleaks (20). Similarly to our findings, the technical success was 100%, with

207 no further endoleak or additional re-intervention required. No death related to aneurysm, graft
208 thrombosis or chimney graft occlusion were observed. A case of endobag protrusion was
209 reported, with no clinical consequence. Note that an injury of the renal artery was reported for
210 one patient due to a guidewire injury which required a nephrectomy due to active bleeding.
211 Another study reported a serie of 4 patients with prior EVAR who were successfully treated
212 for a type Ia endoleak using chimney-EVAS (10). Other investigators reported the use of
213 EVAS to treat type I and type IIIb endoleaks in a serie of 10 consecutive patients (34). The
214 technical success was achieved in all patients and the short-term follow-up demonstrated a
215 resolution of the type Ia endoleaks and the proven type III endoleaks. However, for 3 patients
216 who initially had undetermined endoleaks, a re-intervention was required due to continued sac
217 expansion. At last, a few other case reports described the treatment of type I or type III
218 endoleaks as well as non-elective ruptured AAA following EVAR using the EVAS technique
219 (13-19). In all the studies, the technical success was achieved. In their study, Joseph et al.
220 reported the use of EVAS in 3 patients who had prior EVAR or fenestrated EVAR to treat
221 type Ia endoleaks (13). The technical success was 100%. The authors reported the occurrence
222 of dissections of the left subclavian artery in 2 patients which were successfully treated with
223 endovascular procedure and the occurrence of a common femoral artery pseudoaneurysm
224 which spontaneously thrombosed.

225 The use of Nellix in patients who had EVAR can be technically challenging and the success
226 of the procedure requires the training and the experience of the operators. In our centre,
227 EVAS has been used since 2013 and 68 devices have been implanted. The learning curve to
228 master the technique is an important concern before considering it as a potential alternative in
229 secondary procedures. Deploying the Nellix device in confined spaces can potentially expose
230 to a risk of endobag protrusion or rupture. The pressure monitoring and the pre-fill of the
231 endobags is a critical step to achieve a successful sealing and limit the risk of such

232 complications. In our study, we did not report any endobag rupture or protrusion. Other
233 investigators reported one case of endobag protrusion, without any clinical consequence (20).
234 The median of the polymer fill volume used in our study was 51.5 mL, which is concordant
235 with other studies (15, 19, 20). In our experience, we did not observe a difference on the
236 polymer filling volume depending on the original EVAR device. Optimal filling volumes
237 when using Nellix in patients who had EVAR remain to be determined and further studies
238 would be useful to address it.

239 Studies published so far were mainly case reports and patients treated with prior EVAR
240 mainly had bifurcated endografts. Only a few studies involved patients who had fenestrated
241 endografts (13, 20) and to the best of our knowledge, none of them described patients who
242 had prior chimney-EVAR. The interest of this study is to report a larger serie of patients
243 (n=10) who had EVAS or chimney-EVAS to treat type I and type III endoleaks in patients
244 who had prior EVAR or chimney-EVAR. The use of EVAS in the treatment of type III
245 endoleaks has been so far scarcely investigated (15, 20, 34). EVAS does not add fixation to
246 the repair. In cases of type IIIb endoleaks, relining of the stent graft is required. Relining of
247 the stent graft using bilateral Nellix is technically feasible, with no change in distraction
248 forces (35). Type IIIa endoleaks, related to modular disconnection, can be treated by
249 unilateral insertion of single covered stents (27). In this cohort, EVAS was proposed as an
250 alternative procedure in cases where it was estimated that a bilateral Nellix device could help
251 to strengthen the stability of the aneurysm because of its compliant endobags and ability to
252 conform to anatomical and prosthetic structures. In our cohort, 3 patients had prior chimney-
253 EVAR, which has never been previously described. The use of the Nellix system in patients
254 who had prior chimney-EVAR is challenging and particular attention should be taken to avoid
255 covering the existing chimney stents by the EVAS system. Re-cannulation of the vessels can
256 be required to re-introduce stents to avoid compression of the existing chimney stents by the

257 EVAS system. The procedure was successfully achieved in these patients and they did not
258 require a re-intervention, suggesting that the technique is safe and efficient.

259 This study presents some limitations. This was a single-centre retrospective study. Given the
260 scarcity of the literature and small number of patients involved, further multicentre clinical
261 studies should be performed to obtain larger cohorts. This would allow to better identify
262 anatomic characteristics and procedural characteristics of the prior EVAR that could be
263 predictive of the success of EVAS in the treatment of endoleaks. This would also help to
264 identify criteria that should be taken in consideration to choose the most appropriate
265 endovascular approach to treat type Ia and type III endoleaks following EVAR. At last,
266 follow-up on longer periods would be useful to address the long-term outcomes following
267 EVAS. At last, the use of EVAS as a secondary procedure is currently outside the instructions
268 for use and the recent suspension of the Nellix CE mark pay probably delay and limit clinical
269 protocols to investigate its interest in these indications.

270 EVAS and chimney EVAS in the treatment of type I and type III endoleaks following EVAR
271 and chimney EVAR is technically feasible. Short-term follow-up suggests that the procedure
272 is a safe and efficient therapeutic alternative to manage disabled EVAR. Further studies on
273 larger cohort and longer follow-up periods are required to evaluate its long-term efficiency
274 and identify potential predictive factors that may help to assess its indication in the treatment
275 of complications following EVAR.

276

277 **References:**

- 278 1. Donas KP, Torsello G, Bisdas T. New EVAR devices: pros and cons. J Cardiovasc
279 Surg (Torino). 2012;53(5):559-69.
- 280 2. Mehta M, Sternbach Y, Taggart JB, et al. Long-term outcomes of secondary

281 procedures after endovascular aneurysm repair. *J Vasc Surg.* 2010;52(6):1442-9.

282 3. Sampaio SM, Panneton JM, Mozes GI, et al. Proximal type I endoleak after
283 endovascular abdominal aortic aneurysm repair: predictive factors. *Ann Vasc Surg.*
284 2004;18(6):621-8.

285 4. Antoniou GA, Georgiadis GS, Antoniou SA, et al. Late Rupture of Abdominal Aortic
286 Aneurysm After Previous Endovascular Repair: A Systematic Review and Meta-analysis. *J*
287 *Endovasc Ther.* 2015;22(5):734-44.

288 5. Chaikof EL, Dalman RL, Eskandari MK, et al. The Society for Vascular Surgery
289 practice guidelines on the care of patients with an abdominal aortic aneurysm. *J Vasc Surg.*
290 2018;67(1):2-77 e2.

291 6. Bendermacher BL, Stokmans R, Cuypers PW, et al. EVAR reintervention
292 management strategies in contemporary practice. *J Cardiovasc Surg (Torino).*
293 2012;53(4):411-8.

294 7. Ghouri M, Krajcer Z. Endoluminal abdominal aortic aneurysm repair: the latest
295 advances in prevention of distal endograft migration and type 1 endoleak. *Tex Heart Inst J.*
296 2010;37(1):19-24.

297 8. Fisher RK, Torella F, England A, et al. Patient selection for endovascular sac sealing
298 of abdominal aortic aneurysm. *Semin Vasc Surg.* 2016;29(3):93-101.

299 9. Thompson MM, Heyligers JM, Hayes PD, et al. Endovascular Aneurysm Sealing:
300 Early and Midterm Results From the EVAS FORWARD Global Registry. *J Endovasc Ther.*
301 2016;23(5):685-92.

302 10. De Bruin JL, Brownrigg JR, Patterson BO, et al. The Endovascular Sealing Device in
303 Combination with Parallel Grafts for Treatment of Juxta/Suprarenal Abdominal Aortic
304 Aneurysms: Short-term Results of a Novel Alternative. *Eur J Vasc Endovasc Surg.*
305 2016;52(4):458-65.

- 306 11. Reijnen MM, de Bruin JL, Mathijssen EG, et al. Global Experience With the Nellix
307 Endosystem for Ruptured and Symptomatic Abdominal Aortic Aneurysms. *J Endovasc Ther.*
308 2016;23(1):21-8.
- 309 12. Gossetti B, Martinelli O, Ferri M, et al. Preliminary results of endovascular aneurysm
310 sealing from the multicenter Italian Research on Nellix Endoprosthesis (IRENE) study. *J Vasc*
311 *Surg.* 2018;67(5):1397-403.
- 312 13. Joseph SZ, Kwok CHR, Hockley JA, et al. A Technique of "Chimney Nellix" for the
313 Management of Type Ia Endoleak After EVAR. *J Vasc Interv Radiol.* 2018;29(5):623-7.
- 314 14. Bockler D, Reijnen MM, Krievins D, et al. Use of the Nellix EVAS system to treat
315 post-EVAR complications and to treat challenging infrarenal necks. *J Cardiovasc Surg*
316 (Torino). 2014;55(5):601-12.
- 317 15. van den Ham LH, Wiersema AM, Kievit JK, et al. Treatment of Type IIIb Endoleaks
318 After EVAR Using the Nellix EndoVascular Aneurysm Sealing System. *J Endovasc Ther.*
319 2016;23(1):29-32.
- 320 16. Torella F, Chan TY, Shaikh U, et al. ChEVAS: Combining Suprarenal EVAS with
321 Chimney Technique. *Cardiovasc Intervent Radiol.* 2015;38(5):1294-8.
- 322 17. Hughes CO, de Bruin JL, Karthikesalingam A, et al. Management of a type Ia
323 endoleak with the Nellix endovascular aneurysm sealing system. *J Endovasc Ther.*
324 2015;22(3):309-11.
- 325 18. Quintas A, Alves G. Three-vessel Chimney Technique Combined with Endovascular
326 Aortic Sealing Device for the Treatment of a Type Ia Endoleak. *Eur J Vasc Endovasc Surg.*
327 2017;53(3):379.
- 328 19. Martinelli O, Fresilli M, Irace L, et al. An Alternative Approach for Treating a Type Ia
329 Endoleak after Conventional EVAR Using the Nellix Endovascular Aneurysm Sealing. *Ann*
330 *Vasc Surg.* 2018;49:316 e5- e10.

- 331 20. Youssef M, Zerwes S, Jakob R, et al. Endovascular Aneurysm Sealing (EVAS) and
332 Chimney EVAS in the Treatment of Failed Endovascular Aneurysm Repairs. *J Endovasc*
333 *Ther.* 2017;24(1):115-20.
- 334 21. Moll FL, Powell JT, Fraedrich G, et al. Management of abdominal aortic aneurysms
335 clinical practice guidelines of the European society for vascular surgery. *Eur J Vasc Endovasc*
336 *Surg.* 2011;41 Suppl 1:S1-S58.
- 337 22. Brownrigg JR, de Bruin JL, Rossi L, et al. Endovascular aneurysm sealing for
338 infrarenal abdominal aortic aneurysms: 30-day outcomes of 105 patients in a single centre.
339 *Eur J Vasc Endovasc Surg.* 2015;50(2):157-64.
- 340 23. Bail DH, Walker T, Giehl J. Vascular endostapling systems for vascular endografts
341 (T)EVAR--systematic review--current state. *Vasc Endovascular Surg.* 2013;47(4):261-6.
- 342 24. Sheehan MK, Barbato J, Compton CN, et al. Effectiveness of coiling in the treatment
343 of endoleaks after endovascular repair. *J Vasc Surg.* 2004;40(3):430-4.
- 344 25. Donas KP, Telve D, Torsello G, et al. Use of parallel grafts to save failed prior
345 endovascular aortic aneurysm repair and type Ia endoleaks. *J Vasc Surg.* 2015;62(3):578-84.
- 346 26. Martin Z, Greenberg RK, Mastracci TM, et al. Late rescue of proximal endograft
347 failure using fenestrated and branched devices. *J Vasc Surg.* 2014;59(6):1479-87.
- 348 27. Maleux G, Poorteman L, Laenen A, et al. Incidence, etiology, and management of type
349 III endoleak after endovascular aortic repair. *J Vasc Surg.* 2017;66(4):1056-64.
- 350 28. Silingardi R, Coppi G, Ferrero E, et al. Midterm Outcomes of the Nellix Endovascular
351 Aneurysm Sealing System: A Dual-Center Experience. *J Endovasc Ther.* 2016;23(5):695-700.
- 352 29. Krievins DK, Holden A, Savlovskis J, et al. EVAR using the Nellix Sac-anchoring
353 endoprosthesis: treatment of favourable and adverse anatomy. *Eur J Vasc Endovasc Surg.*
354 2011;42(1):38-46.
- 355 30. Carpenter JP, Cuff R, Buckley C, et al. Results of the Nellix system investigational

- 356 device exemption pivotal trial for endovascular aneurysm sealing. *J Vasc Surg.*
357 2016;63(1):23-31 e1.
- 358 31. Bockler D, Holden A, Thompson M, et al. Multicenter Nellix EndoVascular
359 Aneurysm Sealing system experience in aneurysm sac sealing. *J Vasc Surg.* 2015;62(2):290-
360 8.
- 361 32. Malkawi AH, de Bruin JL, Loftus IM, et al. Treatment of a juxtarenal aneurysm with
362 the Nellix endovascular aneurysm sealing system and chimney stent. *J Endovasc Ther.*
363 2014;21(4):538-40.
- 364 33. Dijkstra ML, Lardenoye JW, van Oostayen JA, et al. Endovascular aneurysm sealing
365 for juxtarenal aneurysm using the Nellix device and chimney covered stents. *J Endovasc Ther.*
366 2014;21(4):541-7.
- 367 34. Paraskevas KI, Karouki M, Rehman A, et al. Endovascular Aneurysm Sealing (EVAS)
368 Alone or in Combination with Chimney Grafts (chEVAS) for Treating Complications of
369 Previous Endovascular Aneurysm Repair (EVAR) Procedures. *Cardiovasc Intervent Radiol.*
370 2018;41(7):1015-20.
- 371 35. Swaelens C, Poole RJ, Torella F, et al. Type IIIb Endoleak and Relining: A
372 Mathematical Model of Distraction Forces. *J Endovasc Ther.* 2016;23(2):297-301.

373

374

375 **Funding:** This study was not supported by any funding.

376

377 **Conflict of Interest:** The authors declare that they have no conflict of interest.

378 **Ethical approval :** All procedures performed in studies involving human participants were in
379 accordance with the ethical standards of the institutional and/or national research committee

380 and with the 1964 Helsinki declaration and its later amendments or comparable ethical
381 standards. For this type of study formal consent is not required.

382

383 **Informed consent:** For this type of study informed consent is not required.

384

385 **Consent for publication:** For this type of study consent for publication is not required.

386

387 **Figure legends:**

388 Figure 1: Representative images of EVAS procedure in the treatment of type III endoleak
389 following chimney EVAR.

390 (A) 3D-CT-scan 48 hours after chimney EVAR. (B) 3D-CT-scan before EVAS procedure
391 showing a tear in the body stent graft. (C) Peri-operative angiography after EVAS procedure
392 showing the 3 chimney stents. (D) CT-scan 48 hours after EVAS procedure showing the
393 successful exclusion of the aneurysm and the patency of the 3 chimney stents. (C1) 3D-CT-
394 scan reconstruction. (C2) Coronal section. (C3) Axial section.

395

396 Figure 2: Representative images of embolization procedure in the treatment of type II and
397 type Ia endoleak following EVAS in patients who had prior EVAR

398 (A) Peri-operative angiography showing a type II endoleak originating from the lumbar artery
399 and treated using embolization with coils. (B) Peri-operative angiography showing a type Ia
400 endoleak treated using embolization with coils.

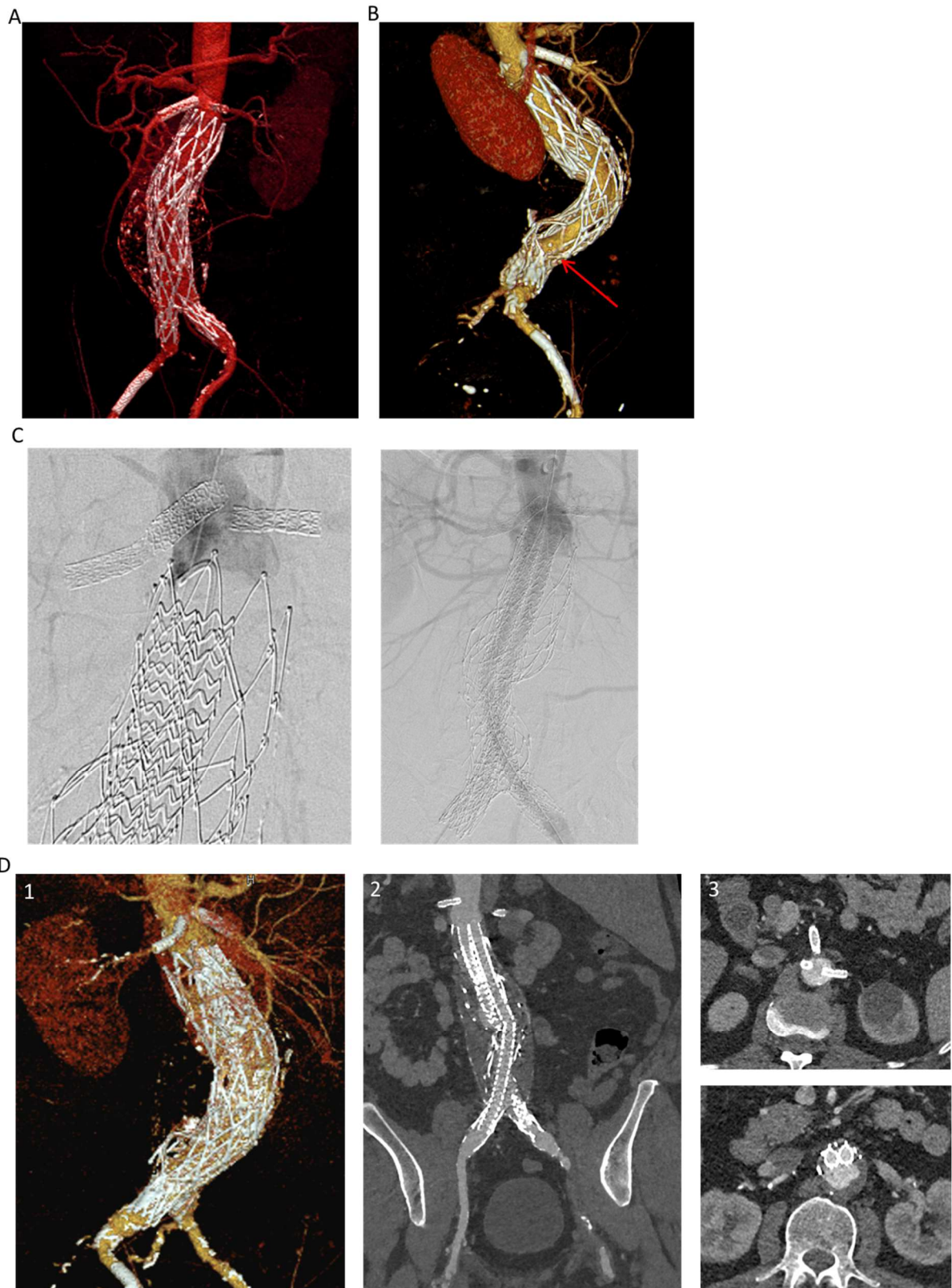


Figure 1: Representative images of EVAS procedure in the treatment of type III endoleak following chimney EVAR.

(A) 3D-CT-scan 48 hours after chimney EVAR. (B) 3D-CT-scan before EVAS procedure showing a tear in the body stent graft. (C) Peri-operative angiography after EVAS procedure showing the 3 chimney stents. (D) CT-scan 48 hours after EVAS procedure showing the successful exclusion of the aneurysm and the patency of the 3 chimney stents. (C1) 3D-CT-scan reconstruction. (C2) Coronal section. (C3) Axial section.

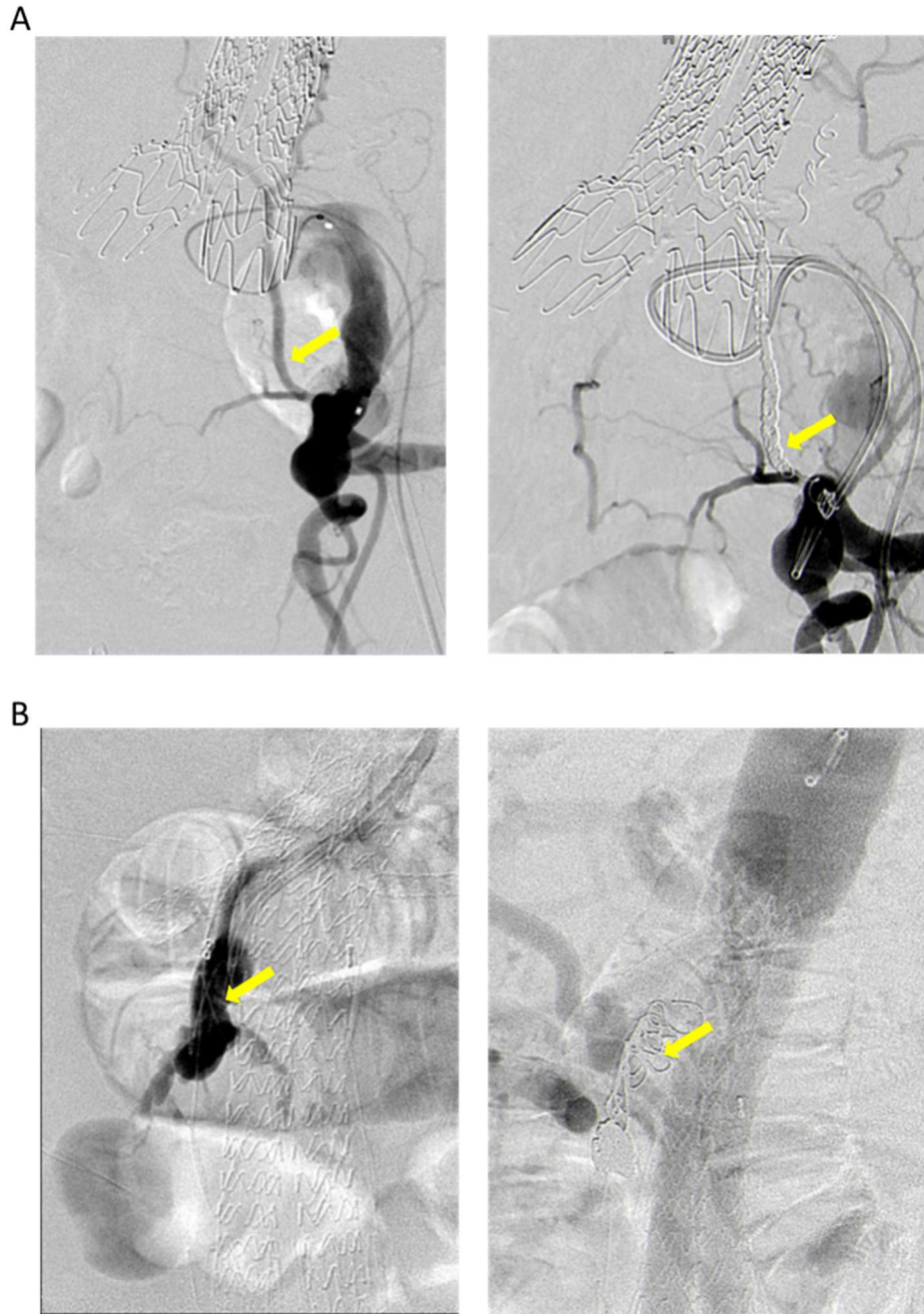


Figure 2: Representative images of embolization procedure in the treatment of type II and type Ia endoleak following EVAS in patients who had prior EVAR

(A) Peri-operative angiography showing a type II endoleak originating from the lumbar artery and treated using embolization with coils. (B) Peri-operative angiography showing a type Ia endoleak treated using embolization with coils.

Total patients (n= 10)		Data
General characteristics	Age	76 (66 – 83.3)
	Male Sex	8 /10
	Smoking	6 /10
	Arterial hypertension	4 /10
	Diabetes	0 /10
	Dyslipidemia	3 /10
	Prior percutaneous coronary intervention	6 /10
	Prior myocardial infarction	0 /10
	Severe chronic obstructive pulmonary disease	3 /10
	Obesity	1 /10
	American Society of Anesthesiologists (ASA) score	3 (3 -3)
	EVAR procedure	Maximum aneurysm diameter (mm)
Elective repair		8 /10
Type of endograft		
. Anaconda		2 /10
. AFX		4 /10
. Zenith		1 /10
. Endurant		1 /10
. Talent		2 /10
Chimney EVAR	3 /10	

	. 1-vessel	0 /10
	. 2-vessel	0 /10
	. 3-vessel	3 /10
	. 4-vessel	0 /10
	Complications after standard-EVAR	
	. Type Ia endoleaks	4 /7
	. Type III endoleaks	3 /7
	- IIIa: Modular Disconnection	2 /3
	- IIIb: Fabric tear in the body stent graft	1 /3
	Complications after chimney-EVAR	
	. Type Ia endoleaks	1 /3
	. Type III endoleaks	2 /3
	- IIIa: Modular Disconnection	1 /2
	- IIIb: Fabric tear in the body stent graft	1 /2
EVAS procedure	Time between EVAR and EVAS procedure (months)	41.5 (29 – 81.8)
	Maximum aneurysm diameter (mm)	76 (64 – 92.3)
	Elective repair	9 /10
	Chimney EVAS	4 /10
	. 1-vessel	0 /10
	. 2-vessel	2 /10
	. 3-vessel	2 /10
	. 4-vessel	0 /10

Procedural time (min)	222.5 (138.8 – 418.8)
Dose are product ($\mu\text{Gy m}^2$)	52011 (28196 – 82639)
Polymer fill volume (mL)	51.5 (32 – 57.5)
Technical success	10 /10

Table 1: Baseline characteristics of patients who had EVAS procedure following EVAR

Values are median (interquartile range) or ratio reported to the total population (10 patients).

Patients	Maximum AAA diameter (mm)	Type of endograft	Use of chimney graft	Type of endoleak after EVAR	Time between EVAR and EVAS procedure (months)
1	47	Anaconda	No	Ia	46
2	71	Talent	No	IIIb	102
3	68	Anaconda	No	IIIa	38
4	67	AFX	3-vessel chimney graft	Ia	29
5	72	Zenith	No	Ia	29
6	51	Talent	No	Ia	102
7	80	Endurant	No	Ia	75
8	60	AFX	No	IIIa	2
9	69	AFX	3-vessel chimney graft	IIIb	43
10	44	AFX	3-vessel chimney graft	IIIa	40

Table 2: Detail of procedural characteristics of EVAR procedure