



HAL
open science

Therapeutic plasma exchange in thrombotic thrombocytopenic purpura

Adrien Picod, François Provôt, Paul Coppo

► **To cite this version:**

Adrien Picod, François Provôt, Paul Coppo. Therapeutic plasma exchange in thrombotic thrombocytopenic purpura. *La Presse Médicale*, 2019, 48, pp.319 - 327. 10.1016/j.lpm.2019.08.024 . hal-03488830

HAL Id: hal-03488830

<https://hal.science/hal-03488830>

Submitted on 21 Jul 2022

HAL is a multi-disciplinary open access archive for the deposit and dissemination of scientific research documents, whether they are published or not. The documents may come from teaching and research institutions in France or abroad, or from public or private research centers.

L'archive ouverte pluridisciplinaire **HAL**, est destinée au dépôt et à la diffusion de documents scientifiques de niveau recherche, publiés ou non, émanant des établissements d'enseignement et de recherche français ou étrangers, des laboratoires publics ou privés.



Distributed under a Creative Commons Attribution - NonCommercial 4.0 International License

**PLASMA EXCHANGES AND OTHER APHERESIS TECHNIQUES IN SYSTEMIC
DISEASES**

Quarterly Medical Review

Therapeutic plasma exchange in thrombotic thrombocytopenic purpura

Échanges plasmatiques au cours du purpura thrombotique thrombocytopénique

Adrien Picod¹, François Provôt^{1,2}, Paul Coppo^{1,3,4,*}

1. Centre National de Référence des MicroAngiopathies Thrombotiques, 75000 Paris, France

2. Service de néphrologie, Hôpital Albert Calmette, 59000 Lille , France

3. Service d'hématologie, Hôpital Saint-Antoine, Assistance publique - Hôpitaux de Paris,
75012 Paris France

4. Sorbonne-Université, 75006 Paris, France

Corresponding Author:

Paul Coppo,

Centre National de Référence des Microangiopathies thrombotiques

Service d'hématologie

Hôpital Saint-Antoine

184 Rue du Faubourg Saint-Antoine

75012 Paris, France

E-mail: paul.coppo@aphp.fr

In this issue

Editorial

Therapeutic plasma exchange in thrombotic thrombocytopenic purpura

Adrien Picod et al, France

Plasma exchange in anti-glomerular basement membrane disease

Maria Prendecki et al, United Kingdom

Therapeutic Plasma Exchange in Guillain-Barre Syndrome and Chronic Inflammatory Demyelinating Polyradiculoneuropathy

Huy P. Pham et al, United states

Plasma Exchange in catastrophic antiphospholipid syndrome

Ignasi Rodríguez-Pintó et al, Spain

Indications of plasma exchanges in combination with intravenous immunoglobulins or therapeutic monoclonal antibodies. How to combine them?

Chiara Vendramin et al. United Kingdom

List of abbreviations:

TTP: Thrombotic thrombocytopenic purpura

ADAMTS13: a disintegrin and metalloprotease with thrombospondin type I repeats – 13rd member

TPE: Therapeutic plasma exchange

ULvWF: Ultralarge von Willebrand factor

iTTP: Immune-mediated TTP

cTTP: Congenital TTP

LDH : Lactate dehydrogenase

NAC: N-acetylcysteine

Abstract

Thrombotic thrombocytopenic purpura (TTP) is a life-threatening disease related to the formation of microvascular thrombosis and subsequent organ failure. The disease is accompanied with microangiopathic haemolytic anaemia, consumptive thrombocytopenia and lies on a severe deficiency in ADAMTS13, the von Willebrand factor-cleaving protease. In the acquired, immune-mediated form, this deficiency is due to the production of autoantibodies directed against the enzyme. Therapeutic plasma exchange has been used empirically for decades and still represents the cornerstone of TTP treatment. However, a better understanding of pathophysiological mechanisms underlying the disease has led these last years to the development of highly effective targeted therapies that might in the future restraint the use of therapeutic plasma exchange.

Introduction

Thrombotic thrombocytopenic purpura (TTP) is a specific form of thrombotic microangiopathy characterised by the association of a microangiopathic haemolytic anaemia, a consumptive thrombocytopenia, and organ failures of various severities, where typically the brain, the digestive tract and the heart are involved. TTP can be distinguished from other thrombotic microangiopathies by a severe deficiency (<10%) in the plasma enzyme ADAMTS13 (a disintegrin and metalloproteinase with thrombospondin type-1 repeats, 13rd member). This deficiency can be inherited, and related to ADAMTS13 biallelic mutations, or more commonly acquired (immune-mediated), in relation with the production of polyclonal autoantibodies directed against ADAMTS13. TTP is more frequent during adulthood, affecting 2 to 4 people per million per year, with a predominance for females (3 to 1 female to male ratio). The autoimmune form can be either isolated or associated with other clinical conditions such as pregnancy, connective tissue diseases, new HIV infection or the use of

antiplatelets agents (1). First used empirically for a disease whose pathophysiology was unknown, therapeutic plasma exchange (TPE) helped in the understanding of the disease and dramatically improved its prognosis. TPE is based on the extracorporeal separation and removal of plasma, and its replacement by a substitution fluid in order to either remove a toxic factor and/or replenish a deficient factor. This narrative review aims at presenting the main milestones in development, current standard and future of this centrepiece therapy in TTP.

History of TPE

TTP was first reported in 1924 as an acute febrile haemolytic anaemia with migratory neurologic symptoms in a 16-year-old girl. Although platelet count and schistocytes were unavailable, autopsy findings highly suggest the diagnosis, and it is likely that the haemorrhagic syndrome and anaemia described in the observation were the consequence of severe thrombocytopenia and microangiopathic hemolysis, respectively (2). The disease was rapidly fatal and the necropsy showed thrombosis of the microvasculature of several organs. Interestingly, Moschowitz added to this report that one of his colleagues, Max Lederer, had apparently observed four additional cases of this new nosologic entity, and that all these four patients had clinical improvement following blood transfusion. Much later, Rubinstein reported an “unusual” remission following whole blood exchange transfusions in an 11-year-old girl suffering from TTP. After each of two exchange transfusions, there was a clinical improvement associated with rise in platelet count and drop in reticulocytes percentage, both parameters still used nowadays to assess response to therapy (3). This observation was strengthened by the work of Bukowski who reported a small series of patients treated by exchange transfusion with up to 60 percent rate of remission for a disease that was at this time almost invariably fatal without treatment (4). Interestingly, a case report shed some light both

on disease pathophysiology and on the mechanism by which exchange transfusion were beneficial. In 1977, Byrnes et al reported the case of a 18-year old woman suffering from TTP who received consecutively over the course of her disease several regimens of exchange transfusions. Indeed, after removal of whole blood, she received either whole blood, washed red blood cells, or fresh plasma. Only procedure implicating the administration of fresh plasma seemed to have some effect on the disease, leading Byrnes to state that “the pathogenesis of TTP in this patient involved a deficient plasma factor”. Therapy was then completed using solely plasma infusion and the patient was discharged alive from the hospital (5). This observation was corroborated by several reports and TPE became the standard of care for TTP. Further work suggested that maximum efficiency was best reached with daily TPE of at least one estimated plasma volume (6) and a randomised controlled trial demonstrated the superiority of TPE over plasma infusion in the initial treatment of TTP (7). However, in this work, patients assigned to the TPE group received 3-times more plasma (45ml/kg/day) than patients assigned to the plasma infusion group, which likely influenced the results. Indeed, it cannot be totally excluded from this work that the superiority of TPE over plasma infusion in TTP mostly comes from the larger volumes of plasma provided by TPE rather than from the removal of pro-aggregant substances. It was then accepted that the deficient factor in TTP was responsible of a platelet aggregation propensity leading to the formation of microthrombi and organ failure (8). The knowledge of the disease progressed when an accumulation of ultralarge von Willebrand factor (ULvWF) multimers in patient plasma was demonstrated (9). Later it was reported that the deficient factor was an enzyme cleaving the von Willebrand factors multimers, namely ADAMTS13. In immune-mediated TTP (iTTP), severe ADAMTS13 deficiency results from autoantibodies directed against the enzyme, whereas in congenital TTP (cTTP) ADAMTS13 deficiency is caused by biallelic mutations of the encoding gene (10–14). The beneficial action of TPE for iTTP was then fully

explained by the infusion of the deficient factor, ADAMTS13 itself, and the putative removal of deleterious substances, namely autoantibodies against ADAMTS13 as well as proagregant ULvWF multimers. Accordingly, TPE is required for iTTP whereas plasma infusion is sufficient for the management of cTTP.

TPE Best of Practice

Nowadays TPE is recommended as the first line treatment of iTTP (Category I, Grade 1A) (15,16). TPE should be initiated as soon as possible because a longer delay is associated with early death (17). If TPE is not readily available, high-dose plasma infusion (25-30mL/kg/day) might be initiated but exposes to fluid overload (18,19). Treatment is most often started in the intensive care unit setting where all supportive measures can be undertaken, including intubation and mechanical ventilation for coma or respiratory failure, vasopressors initiation, renal replacement therapy, or even circulatory assistance for cardiogenic shock or refractory cardiac arrest (20).

Two modalities of plasma separation can be used for TPE, based either on respective density (centrifugation) or size (filtration) of blood components. Centrifugation plasmapheresis is the historical modality and consists in the centrifugation of whole blood in order to separate plasma from platelets, white blood cells, and erythrocytes. This technique requires one (discontinuous flow) or two (continuous flow) peripheral venous accesses depending on the device used and only allows low blood flow rates (50 to 80mL/min). Anticoagulation is most often performed by using citrate-dextrose solution which is almost completely eliminated along with plasma. The loss of volume is then compensated by administration of the substitution fluid. The filtration technique is newer and uses high permeability filters to separate plasma from other blood components. The substitution fluid is then added to the remaining cells before restitution to the patient. This technique requires high

blood flow rates (superior to 100mL/min), usually via a central venous access or a pre-existing arterio-venous fistula. To avoid filter clotting, anticoagulation can be achieved by different modalities including administration of heparin or regional anticoagulation using citrate and calcium infusion. Theoretically, the use of heparin exposes to an increased risk of bleeding and to the occurrence of heparin-induced thrombocytopenia, whereas the close, almost automated, monitoring allowed by the most recent devices of citrate regional anticoagulation, allows to avoid these pitfalls. However, in a series of critically ill patients undergoing TPE by filtration, the absence of anticoagulation has surprisingly not led to a rise in filter clotting's incidence which nevertheless remains a frequent event, involving more than a fifth of all procedures (21). There is no demonstrated benefit of one modality of TPE compared to the other and the choice should be based on team's experience and availability of the technique. Indeed, filtration is more frequently available for TPE in the intensive care unit context. The use of immunoabsorption in rescue therapy has been seldom reported for iTTP and is limited to case reports (22). TPE is performed on a daily basis until platelet count recovers (i.e. > 150 G/L for at least two days), lactate dehydrogenase (LDH) decreases, and clinical status improves. After complete response has been achieved (i.e., platelet count normalization (>150 G/L for at least two days) with clinical recovery), TPE used to be gradually tapered over 3 weeks to prevent exacerbations of the disease. Nevertheless, with the increasing use of B-cell depleting therapies and more recently anti-vWF agents (detailed below) this attitude has been abandoned by most teams and TPE are now being discontinued abruptly without any adverse event.

The volume of plasma exchange during each procedure ranges between 1.5X estimated patient plasma volume at the beginning of the therapy, and 1.0X subsequently. There is a strong rationale to use exogenous plasma as the sole replacement fluid. First of all, it seems logical to maximize the quantity of ADAMTS13 infused. Moreover, the use of other

replacement fluids such as 5% albumin or synthetic colloids is associated with coagulation disorders since depleted coagulation factors are not replenished. Together with severe thrombocytopenia, this situation might lead to life-threatening hemorrhages. Nevertheless, the use of 50% albumin 5% and 50% plasma as replacement fluid provided results that were comparable to those described with 100% plasma replacement (23).

Platelets transfusion, especially before central venous catheter insertion, should be avoided at all costs. Indeed, such attitude may expose to precipitated life-threatening thrombotic manifestations (24). In case of severe hemorrhage or urgent surgical intervention, platelets administration should be accompanied by plasma infusion and followed by TPE in as short a time as possible (25).

In addition to disease-driven complications, patients are exposed to complications directly resulting from TPE, and related to vascular access, and to the volume of the extracorporeal circuit and/or the replacement fluid (**Table 1**). It is noteworthy that the frequency of TPE-related complications decreases over time as a result of both experience of teams and the progressive decrease in the number of TPE sessions (26).

Various plasma preparations can be used as the replacement fluid. They are characterized by the technique used to ensure the absence of transmissible pathogens and donor's white blood cells, and may differ in their vWF content while ADAMTS13 activity remains constant (27) (**Table 2**). Overall, quarantine fresh frozen plasma, solvent-detergent or amotosalen-inactivated plasma seem as equally effective, on the basis of mostly retrospective studies with low levels of proof (28–34). A cryosupernatant plasma can be made after depletion of the cryoprecipitate formed after slow thawing of a frozen plasma secured by any method. The theoretical superiority of this cryoprecipitate-poor plasma lies into its low residual content in vWF which is removed with other “cryofactors” (XIII, VIII, I,

fibronectin). However, this superiority did not translate in any significant clinical benefit in randomized clinical trials (35–37).

Finally, TPE is associated with the removal of a variable fraction of any drug administered to the patient, depending on the plasma exchange technique, the exchanged volume, as well as the volume of distribution of the considered drug and the plasma protein to which it binds.

Adjunctive frontlines therapies

Nowadays, TPE are integrated in an overall management strategy of iTTP (**Figure 1**). The autoimmune nature of iTTP has led to the implementation of immunomodulation strategies. Notably, corticosteroids are empirically used despite a low level of evidence. In a recent study, corticosteroids were superior to cyclosporine with regard to the restoration of ADAMTS13 activity and the reduction of ADAMTS13 inhibitor titer (38). Intravenous or oral prednisone is often initiated at 1 to 1.5mg/kg/day but high doses of methylprednisolone (10mg/kg/day for 3 days followed by 2.5mg/kg/day) have been shown to be superior to this standard dosage in a multicentric randomized controlled trial, and could be used in the most severe patients (39).

The use of the anti-CD20 humanized monoclonal antibody rituximab has been reported initially in retrospective studies of patients refractory to, or with suboptimal response to initial therapy associating TPE and corticosteroids (40–43). In this setting, the addition of up to four doses of rituximab 375mg/m² weekly led to remission rates of 82% to 100%. These results were supported by two prospective studies (44,45). In one of these, rituximab regimen was slightly intensified and increased to 4 doses of 375mg/m² within two weeks to take into account the partial drug removal by TPE (45,46). Nevertheless, the kinetics of B-cell depletion proved to be similar to that observed in other autoimmune diseases that do not

require TPE and are treated with standard rituximab regimens. These encouraging results prompted the evaluation of rituximab as part of frontline treatment of newly diagnosed iTTP with once again impressive results. The addition of rituximab to TPE and corticosteroids led to a reduction in TPE duration, intensive care unit and whole hospital length of stay, as well as to a striking improvement in 1-year relapse free survival. However, relapses were observed later (43,45,47). Thus, several teams have now integrated frontline rituximab to the initial management of iTTP from these results. However, this attitude remains debated in line with two arguments: first B-cell depletion is only effective 10 days to 2 weeks after the first infusion, and the addition of rituximab thus does not prevent early death that typically occurs in the first 10 days. Second, a significant proportion of patients (about 50%) achieve remission with TPE and corticosteroid alone, without the need of any second line therapy. These arguments are counterbalanced by the need to ensure a durable suppression of anti-ADAMTS13 autoantibodies production to prevent relapses. In this way, the administration of preemptive rituximab infusions in patients in clinical remission but who experience a severe ADAMTS13 deficiency proved to remarkably prevent long term relapses (48,49).

Treatment of refractory iTTP

Patients with unresponsive iTTP, as defined by the absence of rise in platelet count to more than twice the initial count and persistence of LDH elevation after 4 days of initial treatment, need to be intensified. Rituximab should be added if not already administered. In case of new or persistent organ failure, TPE should be performed twice-daily. This strategy is based on an old observation that the highest cumulative volumes of plasma exchange were associated with the highest rate of response (6). Such strategy has been used and reported in two retrospective studies (50,51). Despite a very severe presentation, the implementation of such strategy to treat refractory iTTP led to survival rates of almost 95%. However, these

impressive results should be nuanced as most of these patients received concomitant salvage therapies, making definitive conclusions about the specific role of twice-daily TPE difficult. Nevertheless, due to their simplicity, our use is to propose twice-daily TPE as the first step of intensification. In the more severe patients unresponsive to twice-daily TPE, pulses of cyclophosphamide, vincristine, cyclosporine or even a splenectomy are proposed, despite severe thrombocytopenia (52).

The use of anti-plasma cell agents such as bortezomib could be useful to target long-lived plasma cells supposedly responsible of a persistent autoantibodies production despite effective B-cell depletion, although this strategy requires further evaluation (53). Other agents targeting plasma cells such as anti-CD38 monoclonal antibodies (daratumumab) could be of particular interest in this context.

The next future of iTTP treatment

A better understanding of the physiopathological mechanisms at work during iTTP has led to the development of molecules aimed at inhibiting the interaction between ULvWF multimers and platelets. During the last years, 3 new drugs of this therapeutic class have been evaluated: caplacizumab, ARC1779 (54,55) and GBR600 (56). Caplacizumab, formerly known as ALX-0081 (intravenous) or ALX-0681 (subcutaneous), is a humanized single variable domain bivalent antibody derived from camelidae (nanobody) which is the most advanced in development. So far it has been evaluated in a phase II study, the TITAN trial, and a phase III study, the HERCULES trial. In the TITAN trial, 75 patients were randomly assigned to received 10mg of caplacizumab or placebo daily from the start of therapy and for 30 days after the last TPE (57). The primary end-point was the time to complete response defined by platelet count recovery, which was significantly reduced in the caplacizumab arm versus placebo (39% reduction). Additionally, patients in the caplacizumab arm experienced a

greater proportion of complete remission at one month, with fewer exacerbations. However, after cessation of the study drug, patients in the caplacizumab group who still displayed a persistent undetectable ADAMTS13 deficiency at this time point showed a greater frequency of relapse. Indeed, while caplacizumab is able to rapidly suppress the formation of microthrombi, it has no activity on the autoimmune mechanism at work in the formation of antibodies against ADAMTS13. A post-hoc study of the TITAN trial showed that caplacizumab treatment resulted in a lower proportion of a composite endpoint associating major thromboembolic events or death (58). The HERCULES trial confirmed these results in a larger cohort. Caplacizumab compared to placebo allowed a significant reduction in the incidence of a primary composite endpoint including iTTP-related death, recurrence or major thromboembolic events (12.7% vs 49.3%, respectively). When compared to placebo, caplacizumab also allowed a significant reduction in TPE duration (mean, 5.8 days vs 9.4 days, respectively), as well as a decrease in the intensive care unit stay (3.4 days vs. 9.7 days, respectively) and in the whole hospital stay (9.9 days vs. 14.4 days, respectively) (59). Thus, by its suspensory mechanism of action on microthrombi formation, caplacizumab might fill the gap and succeed in reducing early death occurring before the sustained improvement of ADAMTS13 activity by rituximab. A phase IIIb study (post-HERCULES study) is currently ongoing in order to assess the long-term efficacy and tolerance of caplacizumab (NCT02878603); in the meantime, the drug was already approved by the European Medicines Agency for adult patients with iTTP as a frontline treatment in association with TPE/corticosteroids and rituximab. It is also under review by the Food and Drug Administration.

Because ADAMTS13 deficiency is directly involved in the occurrence of the disease, a treatment based on a specific ADAMTS13 supply is an attractive perspective. This strategy has been highlighted in mice knock-out for *adamts13* gene in which clinical and

hematological features of TTP can be reproduced after the administration of human recombinant vWF. Interestingly, the features of the disease could be reverted by the administration of recombinant human (rh)ADAMTS13 (60), opening the way to clinical trials in patients with cTTP. Moreover, the addition of rhADAMTS13 to iTTP patients plasma was able to restore ADAMTS13 activity with a linear correlation between the inhibitory titer and the requirement in rhADAMTS13 (61). A rhADAMTS13 has been developed and so far, and a phase I study assessed its tolerance and pharmacokinetics cTTP. In this trial, the administration of a single dose of rhADAMTS13 (5, 20 or 40U/kg) to 15 patients was well tolerated and showed efficacy as attested by the detection of ADAMTS13-mediated vWF cleavage products, a rise in platelet count, and a drop in LDH level. The half-life of rhADAMTS13 was comparable to this of the wild-type enzyme present in therapeutic plasma. Importantly, there was no evidence of immunogenicity, as no neutralizing antibodies were detected up to 28 days after rhADAMTS13 administration. A phase 3 study is now ongoing to assess rhADAMTS13 efficacy in cTTP (NCT03393975). As a perspective, such replacement strategy could significantly reduce the volume of plasma required to maintain patients in remission, or even replace plasmatherapy, allowing a decrease of plasma-related side effects: fluid overload, allergic reactions, transfusions-related acute lung injury and allo-immunisation. Lastly, the adaptation of rhADAMTS13 to patient weight, inhibitor titer and response to therapy would be part of a more personalized medicine. In the next future, the development of inhibitor-resistant recombinant ADAMTS13 proteins with enhanced vWF-cleaving activity should still refine this new approach (62).

N-acetylcysteine (NAC) is a small molecule commonly used to treat acetaminophen poisoning or as a mucolytic agent. Its ability to reduce disulfide bounds and thereby reducing the length of soluble ULvWF multimers raised interest for the treatment of TTP. Interestingly, it seems that NAC quite particularly disrupts the disulfide bound located in the A1 domain of

vWF, preventing its binding to the platelets receptor Gp1b (63). Despite a strong biologic rationale and an encouraging case report (64), definitive clinical evidence is still lacking, and its efficacy has been recently called into question in a mouse and baboon pre-clinical study (65). In this work, albeit effective as a prophylaxis, high-dose NAC was unable to reverse established TTP manifestations despite a reduction in ULvWF multimers length. NAC is currently evaluated as an adjunction to initial therapy with TPE in a randomized pilot trial (NCT01808521). However, due to partially overlapping mechanisms of action, NAC position in the future therapeutic strategy is questionable given the recent success of caplacizumab.

Conclusion

TPE have transformed iTTP management, allowing both the understanding of mechanisms at work in disease pathophysiology as well as a dramatic improvement in survival. They still nowadays represent an essential and urgent treatment of iTTP. Nonetheless, recent therapeutic advances gradually lead to a reduction in TPE treatment duration and the associated complications. As a promising perspective for the next future, a combination of rhADAMTS13 and caplacizumab with corticosteroids and B-cell depletion could even call into question the absolute requirement of TPE.

Disclosure of interest: AP and FP have no competing interest. PC is a member of the advisory board for Alexion, Octapharma, Shire and Ablynx part of Sanofi-Genzyme.

References

1. Joly BS, Coppo P, Veyradier A. Thrombotic thrombocytopenic purpura. *Blood*. 2017 May 25;129(21):2836–46.
2. Moschowitz E. An acute febrile pleiochromic anemia with hyaline thrombosis of the terminal arterioles and capillaries: an undescibed disease. *Arch Intern Med*. 1925 Jul 1;36(1):89.
3. Rubinstein MA, Kagan BM, Macgillviray MH, Merliss R, Sacks H. Unusual

- remission in a case of thrombotic thrombocytopenic purpura syndrome following fresh blood exchange transfusions. *Ann Intern Med.* 1959 Dec;51:1409–19.
4. Bukowski RM, Hewlett JS, Harris JW, Hoffman GC, Battle JD, Silverblatt E, et al. Exchange transfusions in the treatment of thrombotic thrombocytopenic purpura. *Semin Hematol.* 1976 Jul;13(3):219–32.
 5. Byrnes JJ, Khurana M. Treatment of Thrombotic Thrombocytopenic Purpura with Plasma. *N Engl J Med.* 1977 Dec 22;297(25):1386–9.
 6. Taft EG. Thrombotic thrombocytopenic purpura and dose of plasma exchange. *Blood.* 1979 Oct;54(4):842–9.
 7. Rock GA, Shumak KH, Buskard NA, Blanchette VS, Kelton JG, Nair RC, et al. Comparison of Plasma Exchange with Plasma Infusion in the Treatment of Thrombotic Thrombocytopenic Purpura. *N Engl J Med.* 1991 Aug 8;325(6):393–7.
 8. Lian EC, Harkness DR, Byrnes JJ, Wallach H, Nunez R. Presence of a platelet aggregating factor in the plasma of patients with thrombotic thrombocytopenic purpura (TTP) and its inhibition by normal plasma. *Blood.* 1979 Feb;53(2):333–8.
 9. Moake JL, Rudy CK, Troll JH, Weinstein MJ, Colannino NM, Azocar J, et al. Unusually Large Plasma Factor VIII: von Willebrand Factor Multimers in Chronic Relapsing Thrombotic Thrombocytopenic Purpura. *N Engl J Med.* 1982 Dec 2;307(23):1432–5.
 10. Tsai HM. Physiologic cleavage of von Willebrand factor by a plasma protease is dependent on its conformation and requires calcium ion. *Blood.* 1996 May 15;87(10):4235–44.
 11. Furlan M, Robles R, Lämmle B. Partial purification and characterization of a protease from human plasma cleaving von Willebrand factor to fragments produced by in vivo proteolysis. *Blood.* 1996 May 15;87(10):4223–34.
 12. Tsai H-M, Lian EC-Y. Antibodies to von Willebrand Factor–Cleaving Protease in Acute Thrombotic Thrombocytopenic Purpura. *N Engl J Med.* 1998 Nov 26;339(22):1585–94.
 13. Rieger M. ADAMTS13 autoantibodies in patients with thrombotic microangiopathies and other immunomediated diseases. *Blood.* 2005 Aug 15;106(4):1262–7.
 14. Levy GG, Nichols WC, Lian EC, Foroud T, McClintick JN, McGee BM, et al. Mutations in a member of the ADAMTS gene family cause thrombotic thrombocytopenic purpura. *Nature.* 2001 Oct;413(6855):488–94.
 15. Schwartz J, Padmanabhan A, Aqui N, Balogun RA, Connelly-Smith L, Delaney M, et al. Guidelines on the Use of Therapeutic Apheresis in Clinical Practice-Evidence-Based Approach from the Writing Committee of the American Society for Apheresis: The Seventh Special Issue: Therapeutic Apheresis-Guidelines 2016. *J Clin Apheresis.* 2016 Jun;31(3):149–338.
 16. Scully M, Cataland S, Coppo P, de la Rubia J, Friedman KD, Kremer Hovinga J, et al. Consensus on the standardization of terminology in thrombotic thrombocytopenic purpura and related thrombotic microangiopathies. *J Thromb Haemost.* 2017 Feb;15(2):312–22.
 17. Pereira A, Mazzara R, Monteagudo J, Sanz C, Puig L, Martínez A, et al. Thrombotic thrombocytopenic purpura/hemolytic uremic syndrome: a multivariate analysis of factors predicting the response to plasma exchange. *Ann Hematol.* 1995 Jun;70(6):319–23.
 18. Novitzky N, Jacobs P, Rosenstrauch W. The treatment of thrombotic thrombocytopenic purpura: plasma infusion or exchange? *Br J Haematol.* 1994 Jun;87(2):317–20.
 19. Coppo P, Bussel A, Charrier S, Adrie C, Galicier L, Boulanger E, et al. High-dose plasma infusion versus plasma exchange as early treatment of thrombotic thrombocytopenic purpura/hemolytic-uremic syndrome. *Medicine (Baltimore).* 2003 Jan;82(1):27–38.
 20. Zafrani L, Russell L, Azoulay E. Does this patient with thrombotic thrombocytopenic

- purpura have a cardiac involvement? *Intensive Care Med.* 2018 Jun;44(6):893–6.
21. Lemaire A, Parquet N, Galicier L, Boutboul D, Bertinchamp R, Malphettes M, et al. Plasma exchange in the intensive care unit: Technical aspects and complications. *J Clin Apheresis.* 2017 Dec;32(6):405–12.
 22. Knöbl P, Haas M, Laczika K, Varadi K, Turecek PL. Immunoabsorption for the treatment of a patient with severe thrombotic thrombocytopenic purpura resistant to plasma exchange: kinetics of an inhibitor of ADAMTS13: *Letters to the editors.* *J Thromb Haemost.* 2003 Jan;1(1):187–9.
 23. O'Brien KL, Price TH, Howell C, Delaney M. The use of 50% albumin/plasma replacement fluid in therapeutic plasma exchange for thrombotic thrombocytopenic purpura: Fifty Percent Albumin/Plasma Fluid for TPE in TTP. *J Clin Apheresis.* 2013 Dec;28(6):416–21.
 24. Riviere E, Saint-Léger M, James C, Delmas Y, Clouzeau B, Bui N, et al. Platelet transfusion and catheter insertion for plasma exchange in patients with thrombotic thrombocytopenic purpura and a low platelet count: PLT Transfusion for Catheter Insertion in TTP. *Transfusion (Paris).* 2015 Jul;55(7):1798–802.
 25. Coppo P, Lassoued K, Mariette X, Gossot D, Oksenhendler E, Adrie C, et al. Effectiveness of platelet transfusions after plasma exchange in adult thrombotic thrombocytopenic purpura: a report of two cases. *Am J Hematol.* 2001 Nov;68(3):198–201.
 26. Som S, Deford CC, Kaiser ML, Terrell DR, Kremer Hovinga JA, Lämmle B, et al. Decreasing frequency of plasma exchange complications in patients treated for thrombotic thrombocytopenic purpura-hemolytic uremic syndrome, 1996 to 2011 (CME): PLASMA EXCHANGE COMPLICATIONS IN TTP. *Transfusion (Paris).* 2012 Dec;52(12):2525–32.
 27. Hacquard M, Lecompte T, Belcour B, Geschier C, Jacquot C, Jacquot E, et al. Evaluation of the hemostatic potential including thrombin generation of three different therapeutic pathogen-reduced plasmas: Hemostatic potential of therapeutic plasma. *Vox Sang.* 2012 May;102(4):354–61.
 28. Toussaint-Hacquard M, Coppo P, Soudant M, Chevreux L, Mathieu-Nafissi S, Lecompte T, et al. Type of plasma preparation used for plasma exchange and clinical outcome of adult patients with acquired idiopathic thrombotic thrombocytopenic purpura: a French retrospective multicenter cohort study: THERAPEUTIC PLASMA AND TTP OUTCOME. *Transfusion (Paris).* 2015 Oct;55(10):2445–51.
 29. Guignier C, Benamara A, Oriol P, Coppo P, Mariat C, Garraud O. Amotosalen-inactivated plasma is as equally well tolerated as quarantine plasma in patients undergoing large volume therapeutic plasma exchange. *Transfus Clin Biol.* 2018 Feb;25(1):73–7.
 30. Mintz PD, Neff A, MacKenzie M, Goodnough LT, Hillyer C, Kessler C, et al. A randomized, controlled Phase III trial of therapeutic plasma exchange with fresh-frozen plasma (FFP) prepared with amotosalen and ultraviolet A light compared to untreated FFP in thrombotic thrombocytopenic purpura. *Transfusion (Paris).* 2006 Oct;46(10):1693–704.
 31. Herbrecht R, Ojeda-Urbe M, Kientz D, Fohrer C, Bohbot A, Hirschberger O, et al. Characterization of efficacy and safety of pathogen inactivated and quarantine plasma in routine use for treatment of acquired immune thrombotic thrombocytopenic purpura. *Vox Sang.* 2018 Jul;113(5):459–67.
 32. de la Rubia J, Arriaga F, Linares D, Larrea L, Carpio N, Marty ML, et al. Role of methylene blue-treated or fresh-frozen plasma in the response to plasma exchange in patients with thrombotic thrombocytopenic purpura. *Br J Haematol.* 2001 Sep;114(3):721–3.
 33. Alvarez-Larran A, Del Rio J, Ramirez C, Albo C, Pena F, Campos A, et al. Methylene blue-photoinactivated plasma vs. fresh-frozen plasma as replacement fluid for plasma exchange in thrombotic thrombocytopenic purpura. *Vox Sang.* 2004 May;86(4):246–51.
 34. del Río-Garma J, Alvarez-Larrán A, Martínez C, Muncunill J, Castellà D, de la Rubia

- J, et al. Methylene blue-photoinactivated plasma versus quarantine fresh frozen plasma in thrombotic thrombocytopenic purpura: a multicentric, prospective cohort study. *Br J Haematol.* 2008 Oct;143(1):39–45.
35. Rock G, Anderson D, Clark W, Leblond P, Palmer D, Sternbach M, et al. Does cryosupernatant plasma improve outcome in thrombotic thrombocytopenic purpura? No answer yet. *Br J Haematol.* 2005 Apr;129(1):79–86.
 36. Röthele E, Krumme B, Rump LC. Design of the prospective randomized study for the treatment of patients with thrombotic microangiopathy. PRODRROMI Study Group. *Ther Apher Off J Int Soc Apher Jpn Soc Apher.* 2000 Oct;4(5):327–31.
 37. Zeigler ZR, Shaddock RK, Gryn JF, Rintels PB, George JN, Besa EC, et al. Cryoprecipitate poor plasma does not improve early response in primary adult thrombotic thrombocytopenic purpura (TTP). *J Clin Apheresis.* 2001;16(1):19–22.
 38. Cataland SR, Kourlas PJ, Yang S, Geyer S, Witkoff L, Wu H, et al. Cyclosporine or steroids as an adjunct to plasma exchange in the treatment of immune-mediated thrombotic thrombocytopenic purpura. *Blood Adv.* 2017 Oct 24;1(23):2075–82.
 39. The Italian TTP Study Group, Balduini CL, Gugliotta L, Luppi M, Laurenti L, Klersy C, et al. High versus standard dose methylprednisolone in the acute phase of idiopathic thrombotic thrombocytopenic purpura: a randomized study. *Ann Hematol.* 2010 Jun;89(6):591–6.
 40. Jasti S, Coyle T, Gentile T, Rosales L, Poiesz B. Rituximab as an adjunct to plasma exchange in TTP: A report of 12 cases and review of literature. *J Clin Apheresis.* 2008;23(5):151–6.
 41. Ling HT, Field JJ, Blinder MA. Sustained response with rituximab in patients with thrombotic thrombocytopenic purpura: A report of 13 cases and review of the literature. *Am J Hematol.* 2009 Jul;84(7):418–21.
 42. Rubia J de la, Moscardó F, Gómez MJ, Guardia R, Rodríguez P, Sebrango A, et al. Efficacy and safety of rituximab in adult patients with idiopathic relapsing or refractory thrombotic thrombocytopenic purpura: Results of a Spanish multicenter study. *Transfus Apher Sci.* 2010 Dec;43(3):299–303.
 43. Page EE, Kremer Hovinga JA, Terrell DR, Vesely SK, George JN. Rituximab reduces risk for relapse in patients with thrombotic thrombocytopenic purpura. *Blood.* 2016 Jun 16;127(24):3092–4.
 44. Scully M, Cohen H, Cavenagh J, Benjamin S, Starke R, Killick S, et al. Remission in acute refractory and relapsing thrombotic thrombocytopenic purpura following rituximab is associated with a reduction in IgG antibodies to ADAMTS-13. *Br J Haematol.* 2007 Feb;136(3):451–61.
 45. Froissart A, Buffet M, Veyradier A, Poullin P, Provôt F, Malot S, et al. Efficacy and safety of first-line rituximab in severe, acquired thrombotic thrombocytopenic purpura with a suboptimal response to plasma exchange. Experience of the French Thrombotic Microangiopathies Reference Center. *Crit Care Med.* 2012 Jan;40(1):104–11.
 46. McDonald V, Manns K, Mackie IJ, Machin SJ, Scully MA. Rituximab pharmacokinetics during the management of acute idiopathic thrombotic thrombocytopenic purpura: PK of rituximab in TTP. *J Thromb Haemost.* 2010 Jun 7;8(6):1201–8.
 47. Scully M, McDonald V, Cavenagh J, Hunt BJ, Longair I, Cohen H, et al. A phase 2 study of the safety and efficacy of rituximab with plasma exchange in acute acquired thrombotic thrombocytopenic purpura. *Blood.* 2011 Aug 18;118(7):1746–53.
 48. Hie M, Gay J, Galicier L, Provot F, Presne C, Poullin P, et al. Preemptive rituximab infusions after remission efficiently prevent relapses in acquired thrombotic thrombocytopenic purpura. *Blood.* 2014 Jul 10;124(2):204–10.
 49. Jestin M, Benhamou Y, Schelpe A-S, Roose E, Provôt F, Galicier L, et al. Preemptive

- rituximab prevents long-term relapses in immune-mediated thrombotic thrombocytopenic purpura. *Blood*. 2018 Sep 10;blood-2018-04-840090.
50. Soucemarianadin M, Benhamou Y, Delmas Y, Pichereau C, Maury E, Pène F, et al. Twice-daily therapeutical plasma exchange-based salvage therapy in severe autoimmune thrombotic thrombocytopenic purpura: the French TMA Reference Center experience. *Eur J Haematol*. 2016 Aug;97(2):183–91.
 51. Nguyen L, Li X, Duvall D, Terrell DR, Vesely SK, George JN. Twice-daily plasma exchange for patients with refractory thrombotic thrombocytopenic purpura: the experience of the Oklahoma Registry, 1989 through 2006. *Transfusion (Paris)*. 2007 Nov 20;48(2):349–57.
 52. Sayani FA, Abrams CS. How I treat refractory thrombotic thrombocytopenic purpura. *Blood*. 2015 Jun 18;125(25):3860–7.
 53. Patriquin CJ, Thomas MR, Dutt T, McGuckin S, Blombery PA, Cranfield T, et al. Bortezomib in the treatment of refractory thrombotic thrombocytopenic purpura. *Br J Haematol*. 2016 Jun;173(5):779–85.
 54. Knöbl P, Jilma B, Gilbert JC, Hutabarat RM, Wagner PG, Jilma-Stohlawetz P. Anti-von Willebrand factor aptamer ARC1779 for refractory thrombotic thrombocytopenic purpura. *Transfusion (Paris)*. 2009 Oct;49(10):2181–5.
 55. Cataland SR, Peyvandi F, Mannucci PM, Lämmle B, Kremer Hovinga JA, Machin SJ, et al. Initial experience from a double-blind, placebo-controlled, clinical outcome study of ARC1779 in patients with thrombotic thrombocytopenic purpura. *Am J Hematol*. 2012 Apr;87(4):430–2.
 56. Feys HB, Roodt J, Vandeputte N, Pareyn I, Mottl H, Hou S, et al. Inhibition of von Willebrand factor-platelet glycoprotein Ib interaction prevents and reverses symptoms of acute acquired thrombotic thrombocytopenic purpura in baboons. *Blood*. 2012 Oct 25;120(17):3611–4.
 57. Peyvandi F, Scully M, Kremer Hovinga JA, Cataland S, Knöbl P, Wu H, et al. Caplacizumab for Acquired Thrombotic Thrombocytopenic Purpura. *N Engl J Med*. 2016 Feb 11;374(6):511–22.
 58. Peyvandi F, Scully M, Kremer Hovinga JA, Knöbl P, Cataland S, De Beuf K, et al. Caplacizumab reduces the frequency of major thromboembolic events, exacerbations and death in patients with acquired thrombotic thrombocytopenic purpura. *J Thromb Haemost*. 2017 Jul;15(7):1448–52.
 59. Scully M, Cataland SR, Peyvandi F, Coppo P, Knöbl P, Kremer Hovinga JA, et al. Caplacizumab Treatment for Acquired Thrombotic Thrombocytopenic Purpura. *N Engl J Med*. 2019 Jan 9;
 60. Schiviz A, Wuersch K, Piskernik C, Dietrich B, Hoellriegl W, Rottensteiner H, et al. A new mouse model mimicking thrombotic thrombocytopenic purpura: correction of symptoms by recombinant human ADAMTS13. *Blood*. 2012 Jun 21;119(25):6128–35.
 61. Plaimauer B, Kremer Hovinga JA, Juno C, Wolfsegger MJ, Skalicky S, Schmidt M, et al. Recombinant ADAMTS13 normalizes von Willebrand factor-cleaving activity in plasma of acquired TTP patients by overriding inhibitory antibodies: rADAMTS13 overrides inhibitors in TTP plasma. *J Thromb Haemost*. 2011 May;9(5):936–44.
 62. Jian C, Xiao J, Gong L, Skipwith CG, Jin S-Y, Kwaan HC, et al. Gain-of-function ADAMTS13 variants that are resistant to autoantibodies against ADAMTS13 in patients with acquired thrombotic thrombocytopenic purpura. *Blood*. 2012 Apr 19;119(16):3836–43.
 63. Chen J, Reheman A, Gushiken FC, Nolasco L, Fu X, Moake JL, et al. N-acetylcysteine reduces the size and activity of von Willebrand factor in human plasma and mice. *J Clin Invest*. 2011 Feb 1;121(2):593–603.
 64. Li GW, Rambally S, Kamboj J, Reilly S, Moake JL, Udden MM, et al. Treatment of refractory thrombotic thrombocytopenic purpura with N -acetylcysteine: a case report:

- Treatment of TTP with N-Acetylcysteine. *Transfusion (Paris)*. 2014 May;54(5):1221–4.
65. Tersteeg C, Roodt J, Van Rensburg WJ, Dekimpe C, Vandeputte N, Pareyn I, et al. N-acetylcysteine in preclinical mouse and baboon models of thrombotic thrombocytopenic purpura. *Blood*. 2017 Feb 23;129(8):1030–8.
66. Coppo P, Cuker A, George JN. Thrombotic thrombocytopenic purpura: Toward targeted therapy and precision medicine. *Res Pract Thromb Haemost*. 2019 Jan;3(1):26–37.
67. Coppo P, Schwarzing M, Buffet M, Wynckel A, Clabault K, Presne C, et al. Predictive Features of Severe Acquired ADAMTS13 Deficiency in Idiopathic Thrombotic Microangiopathies: The French TMA Reference Center Experience. Morty RE, editor. *PLoS ONE*. 2010 Apr 23;5(4):e10208.
68. Bendapudi PK, Hurwitz S, Fry A, Marques MB, Waldo SW, Li A, et al. Derivation and external validation of the PLASMIC score for rapid assessment of adults with thrombotic microangiopathies: a cohort study. *Lancet Haematol*. 2017 Apr;4(4):e157–64.

Figure 1. Current management of immune-mediated thrombotic thrombocytopenic purpura (adapted from (66))

Initial treatment with TPE and corticosteroids should be initiated as soon as the diagnosis is made or even suggested. Of utmost importance, to avoid a delay in the optimal management, TTP diagnosis should be suspected on the basis of clinical scores aimed at predicting a severe ADAMTS13 deficiency (67,68) ([‡]**Supplemental Table**). If the clinical probability of TTP is high the anti-vWF agent caplacizumab as well as frontline rituximab should also be associated with TPE and corticosteroids. Response to therapy should be assessed at least daily by repeated platelet count, LDH and clinical assessment. Patients experiencing refractoriness after 4 days or an exacerbation of the disease should be intensified. There is no consensual recommendation; our use is to propose twice-daily TPE. For the more severe patients, pulses of cyclophosphamide, vincristine, cyclosporine, splenectomy or bortezomib should be considered (*). TTP: thrombotic thrombocytopenic purpura. TPE: therapeutic plasma exchange.

Figure 1

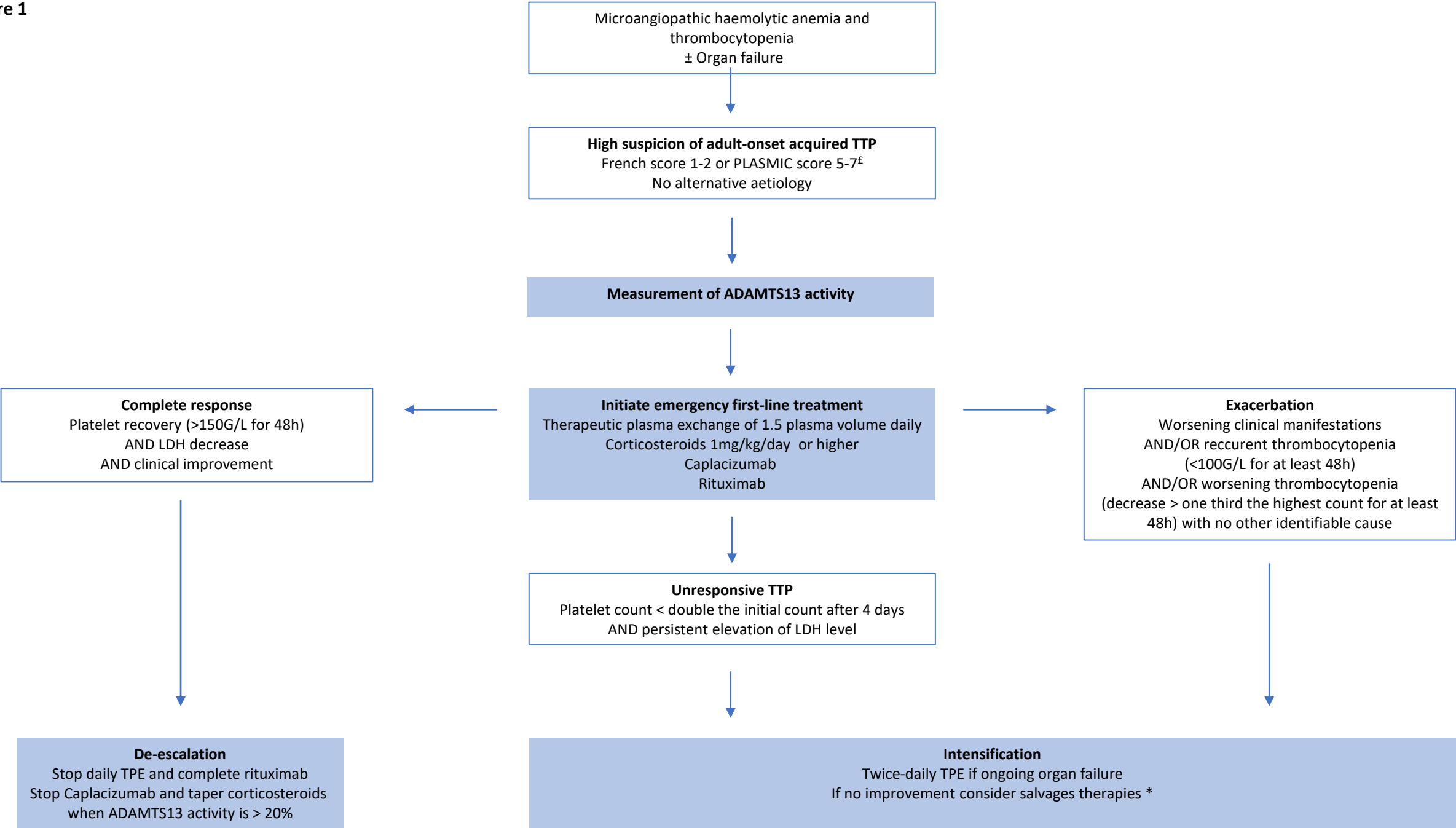


Table 1. Complications of TPE for iTTP (adapted from (26))

<p>Catheter-related complications</p> <p>Catheter related bleeding</p> <ul style="list-style-type: none">- Hemothorax- Retroperitoneal haemorrhage- Insertion site haemorrhage <p>Catheter related thrombosis</p> <p>Catheter related local or systemic infection</p> <p>Catheter dysfunction</p> <p>TPE procedure-related complications</p> <p>Hypotension</p> <p>Arrhythmia</p> <p>Hypocalcaemia</p> <p>Hypokalaemia</p> <p>Filter clotting (filtration)</p> <p>Reactions to plasma</p> <ul style="list-style-type: none">- Anaphylaxis- Serum sickness- Transfusion-related acute lung injury
--

Table 2. Classification of therapeutic plasmas according to securisation procedure

Plasma	Description	Evaluation in TTP
Quarantine fresh frozen plasma	Plasma stored in quarantine while waiting for donor retesting to ensure the absence of infectious pathogens after a window period.	Historical replacement fluid
Solvent detergent plasma	Pathogen and leukocytes inactivation by addition of solvent and detergent, followed by ultrafiltration. Reduced content in vWF due to ultrafiltration.	May be better tolerated than quarantine fresh frozen plasma (28).
Amotosalen-inactivated plasma	Pathogen and leukocytes inactivation by addition of amotosalen; exposition to UVA followed by removal of amotosalen by adsorption	No significative difference in efficacy or tolerance in comparison with quarantine fresh frozen plasma (29–31)
Methylene blue-inactivated plasma	Pathogen and leukocytes inactivation by addition of methylene blue and exposition to visible light.	Reported to be less effective than quarantine fresh frozen plasma in small retrospective and prospective studies (31–33). Methylene blue-inactivated plasma has been withdrawn from the list of authorized blood components in France as allergic reactions were more prevalent.(32–34)

vWF: von Willebrand Factor; UVA: ultraviolet A.