



HAL
open science

Intracranial calcifications under vitamin K antagonists or direct oral anticoagulants: Results from the French VIKING study in older adults

Gaëlle Annweiler, Mathieu Labriffe, Pierre Ménager, Guylaine Ferland, Antoine Brangier, Cédric Annweiler

► To cite this version:

Gaëlle Annweiler, Mathieu Labriffe, Pierre Ménager, Guylaine Ferland, Antoine Brangier, et al.. Intracranial calcifications under vitamin K antagonists or direct oral anticoagulants: Results from the French VIKING study in older adults. *Maturitas*, 2020, 132, pp.35 - 39. 10.1016/j.maturitas.2019.12.003 . hal-03488770

HAL Id: hal-03488770

<https://hal.science/hal-03488770>

Submitted on 21 Jul 2022

HAL is a multi-disciplinary open access archive for the deposit and dissemination of scientific research documents, whether they are published or not. The documents may come from teaching and research institutions in France or abroad, or from public or private research centers.

L'archive ouverte pluridisciplinaire **HAL**, est destinée au dépôt et à la diffusion de documents scientifiques de niveau recherche, publiés ou non, émanant des établissements d'enseignement et de recherche français ou étrangers, des laboratoires publics ou privés.



Distributed under a Creative Commons Attribution - NonCommercial 4.0 International License

Highlights

- The use of vitamin K antagonists was associated with greater burden of intracranial calcifications than direct oral anticoagulants.
 - The use of vitamin K antagonists correlated with greater burden of falcian calcifications compared with direct oral anticoagulants.
 - This finding may explain in part the executive dysfunction met with vitamin K antagonists.
-

Intracranial calcifications under vitamin K antagonists or direct oral anticoagulants:

Results from the French VIKING study in older adults

Gaëlle Annweiler, MD, BS ¹

Mathieu Labriffe, MD, MS ²

Pierre Ménager, MD, BS ³

Guylaine Ferland, PhD ⁴

Antoine Brangier, MD, BS ¹

Cédric Annweiler, MD, PhD ^{1,5}

On behalf of the SOCOS group

1: Department of Geriatric Medicine, Angers University Hospital; Angers University Memory Clinic; Research Center on Autonomy and Longevity; UPRES EA 4638, University of Angers, Angers, France; 2: Department of Radiology, Angers University Hospital, Angers, France; 3: Department of Geriatrics, Le Mans Hospital, Le Mans, France; 4: Montreal Heart

Institute Research Centre & Department of Nutrition, Université de Montréal, Montréal, Quebec, Canada; 5: Robarts Research Institute, Department of Medical Biophysics, Schulich School of Medicine and Dentistry, the University of Western Ontario, London, ON, Canada

Corresponding author: Cedric Annweiler, MD, PhD, Department of Geriatric Medicine, Angers University Hospital, 49933 Angers cedex 9, France; E-mail: Cedric.Annweiler@chu-angers.fr; Phone: ++33 2 41 35 47 25; Fax: ++33 2 41 35 48 94

Running title: Anticoagulant and intracranial calcifications

ABSTRACT

Objectives. The use of vitamin K antagonists (VKA) is associated with the onset of vascular and soft-tissue calcifications. Whether there are more intracranial calcifications under VKA remains unclear. The objective of this study was to determine whether the regular use of VKA in older adults was associated with an increased burden of intracranial calcifications compared with the use of direct oral anticoagulant (DOA).

Study design. Nineteen patients aged 70 years or more using VKA for more than 3 months and 19 controls (matched for age, gender and indication for anticoagulation) using DOA for more than 3 months were consecutively included in this study.

Main outcomes measures. The burden of intracranial calcifications was graded by an experienced neuroradiologist from 0 (no burden) to 3 (high burden) according to the quantity,

size, intensity and confluence of calcifications on computed tomography scan of the brain. Age, gender, frontal assessment battery (FAB) score, hypertension, dyslipidaemia, carotid artery stenosis, kidney failure and indication for anticoagulation were investigated as potential confounders.

Results. The 19 patients using VKA (median[IQR], 84years[7]; 10females) exhibited a greater burden of falxian calcifications than the 19 controls using DOA (respectively, 2[1] versus 1[2], $P=0.025$). Overall, we found that using VKA was directly associated with the global burden of intracranial calcifications ($\beta=1.54$, $P=0.049$). No correlation was found with calcifications in sites other than the falx cerebri.

Conclusions. The use of VKA was associated with a greater burden of intracranial calcifications compared with the use of DOA, specifically in the falx cerebri. This finding may explain part of the neurocognitive morbidity met with VKA.

Keywords

Anticoagulation; direct oral anticoagulant; brain; calcifications; older adults; vitamin K antagonist

•

1. INTRODUCTION

Vitamin K antagonists (VKAs) are commonly used for the prophylaxis and treatment of thromboembolic events, especially in older adults [1]. Unlike direct oral anticoagulants

(DOAs), which mechanisms do not interfere with the cycle of vitamin K, VKAs are inhibitors of the enzymatic conversion of inactive vitamin K epoxide to its reduced active form, thus resulting in a relative state of vitamin K deficiency [1]. Importantly, neurocognitive disorders have been reported among VKA users compared to those using no blood-thinning drugs [2-4]. The use of VKA was associated with impaired cognitive performance as a whole in previous studies [2,3], specifically with a decline of executive functions in longitudinal studies [4]. These associations were independent of the condition warranting the use of anticoagulation, notably the history of atrial fibrillation [2-4]. Thus the most likely explanation was based on the decreased bioavailability of the active form of vitamin K under VKA [5,6]. In fact, the use of VKA in animals has been associated with cognitive impairment and a dysregulation of the synthesis of sphingolipids, a constituent of the myelin sheath and neuronal membrane [6], and a reduction of the biological activation of the vitamin K-dependent proteins involved in neuronal physiology and survival [5]. Such changes may account for the onset of pathological morphological brain changes in VKA users [7,8].

Of note, the regular use of VKA has also been associated with the onset of vascular and extra-vascular calcifications, including in the coronary arteries or the tracheobronchial tree [9]. As intracranial calcifications could in turn lead to neurocognitive disorders [10], we hypothesized that the subcortical executive dysfunction that was observed in older VKA users may have resulted at least in part from a greater burden of intracranial calcifications depending on their quantity, size, confluence and location. The objective of this case-control study was to determine whether the regular use of VKA in older adults was associated with an increased burden of intracranial calcifications compared to the use of direct oral anticoagulant (DOA), as a comparator not interfering with the vitamin K cycle.

2. METHODS

2.1 Participants

We conducted the ‘VItamin K Inhibition and NeurocoGnition’ (VIKING) study, a case-control study with a 1:1 ratio. Cases were 19 consecutive patients aged 70 years and older using VKA in the Department of Geriatric Medicine of the University Hospital of Angers, France. Nineteen controls using a DOA matched on age (± 5 years), gender and indication for anticoagulation (i.e., atrial fibrillation versus venous thromboembolism or mechanical valve) were selected from other patients in the same Department between 1 January 2015 and 1 June 2017. Diads were screened using the computerized registry of Angers University Hospital, and finally included in the analysis after manual review of medical records by one author (PM). Diads were included in the analysis if i) both cases and controls used the anticoagulant for more than 3 months at the time of the inclusion, and ii) both cases and controls underwent a computed tomography of the brain at the time of the inclusion. Main exclusion criteria were severe kidney failure defined as creatinine clearance $<30\text{mL}/\text{min}$ according to Cockcroft-Gault formula, history of any acute medical illness in the preceding 3 months, poor vision, inability to understand or answer the study questionnaires, and refusal to participate in research.

2.2 Anticoagulants

The regular use of VKA (i.e., warfarin, acenocoumarol or fluindione) and DOA (i.e., apixaban, dabigatran, rivaroxaban) was noted from family physician prescriptions and sought by questioning the patients and relatives. The length of use above 3 months and the reason for treatment were checked and collected in a standardized manner from the family physician interview.

2.3 CT scan procedure

Images were acquired on CT scanner at the University Hospital of Angers, France, using a standardized CT protocol. CT is very sensitive for detection and localization of intracranial

calcifications [11]. The burden of intracranial calcifications was visually graded by an experienced neuroradiologist (ML) from 0 (no burden) to 1 (light burden), 2 (moderate burden) and ultimately 3 (high burden) according to a clinical reading combining the quantity, the size, the intensity and the confluence of calcifications across the brain, without knowledge of any clinical information including participants' age, gender, prior imaging findings or anticoagulants used. The following locations were distinguished: carotid siphons (i.e., intracranial internal carotids), internal carotids in their horizontal intra-petrous segment, intracranial fourth segment of the vertebral arteries, basilar artery, choroid plexus, pallidum (i.e., internal parts of lentiform nucleus), falx cerebri, calcifications in the immediate vicinity of veins or venous plexus, and others (i.e., rare or unusual locations of intracranial calcification). The sum of all site-specific calcification burdens was calculated to approximate a global burden of intracranial calcifications.

2.4 Covariables

Age, gender, frontal assessment battery (FAB) score, hypertension, dyslipidemia, carotid artery stenosis, kidney failure, and indications for anticoagulation were used as potential confounders in our analysis. The FAB score was used to assess the performance of the executive functions (total score range: 0-18, best), with good to excellent reliability and validity [12]. History of hypertension, dyslipidaemia and carotid artery stenosis was sought from the family physician correspondence and the patient's file, and by questioning the patient or relatives. The indication for anticoagulation (i.e., atrial fibrillation, venous thromboembolism or mechanical valve) was also sought by questioning the patients, the family physicians and the patients' files. Finally, serum concentration of creatinine was determined using automated standard laboratory methods at the University Hospital of Angers, France. Estimated glomerular filtration rate (eGFR) was calculated using the

Cockcroft-Gault formula ($[(140 - \text{age}_{\text{years}}) \times \text{weight}_{\text{kg}} / \text{creatinine}_{\mu\text{mol/L}}] \times 1.04$ for females, and $\times 1.25$ for males). Kidney failure was defined as $\text{eGFR} \leq 60$ mL/min.

2.5 Statistical analysis

Firstly, the participants' characteristics were summarized using medians [interquartile range, IQR] or frequencies and percentages, as appropriate. Univariate comparisons between 19 cases using VKA and 19 controls using DOA were performed using the Chi-square test Fisher exact test or the Mann-Whitney U test, as appropriate. Secondly, multiple linear regression models were used to examine the association between the use of VKA (independent variable) and the global burden of intracranial calcifications (dependent variable), while adjusting for studied potential confounders. Finally, a Pearson correlation matrix was used to determine which site-specific burdens of intracranial calcifications were specifically linked to the use of VKA in the studied sample. P-values less than 0.05 were considered significant. All statistics were performed using SPSS (version 19.0; SPSS, Inc., Chicago, IL).

2.6 Ethics

The study was conducted in accordance with the ethical standards set forth in the Helsinki Declaration (1983). Ethics approval was obtained from the Ethics Board of the University Hospital of Angers, France (2017). Informed consent was obtained at enrolment according to protocols approved by the local institutional review board.

3. RESULTS

Nineteen cases using VKA (median age [IQR], 84 years [7]; 10 females; median all-site calcification burden, 10 [7]) and 19 controls using DOA (84 years [7]; 10 females; median all-site calcification burden, 8 [2]) were recruited. The vast majority (94.7%) received anticoagulation due to a history of atrial fibrillation, with no difference between cases using VKA and matched controls using DOA. Univariate comparisons between cases and controls

showed no differences in the calcification burden across all studied locations, except in the falx cerebri (median, 2 [1] among VKA users versus 1 [2] among DOA users, $P=0.025$) (Table 1).

Table 2 shows multiple linear regressions between the regular use of anticoagulant and the global burden of intracranial calcifications. Using VKA was associated with a greater burden (fully adjusted $\beta=1.56$, $P=0.049$) compared to DOA used as a reference in the model ($\beta=1$).

The advance in age was also associated with a greater burden of intracranial calcifications.

Table 3 reports the correlations between the use of VKA and the burden of intracranial calcifications by site. Using VKA correlated positively with the burden of falxian calcifications ($r=0.41$ with $P=0.011$). Figure 1 shows CT scan transverse image from one representative participant using VKA, with calcifications in the frontal part of the falx cerebri marked by arrows. No correlation was found with the other locations (Table 3).

4. DISCUSSION

The main finding of this case-control study is that, irrespective of all measured potential confounders, the regular use of VKA was associated with a greater burden of intracranial calcifications compared to the use of DOA, specifically in the falx cerebri. In contrast, no correlations were found with the other locations. These findings may provide insight into the pathophysiology of neurocognitive disorders met among older adults using VKA.

Several lines of epidemiological evidence argue for an involvement of VKA in brain health. Some morphological changes of the brain are notably reported under VKA in prior literature. For instance, it is long known that newborns exposed *in utero* to warfarin or other coumarin derivatives exhibit abnormalities of the central nervous system [13]. Also in older adults, smaller whole-brain volume has been reported among those taking VKA regularly

compared to those taking no anticoagulant [7]. Specifically, the exposure to VKA correlated in another study with focal atrophies within the frontal lobes [8]. All these previous studies have yet addressed the brain changes only in terms of cerebral atrophy. Thus, the present study provides additional and novel evidence by exploring for the first time to our knowledge the possibility that the use of VKA may increase the risk of intracranial calcifications, with potential adverse consequences on neurocognition. Interestingly, the location of the calcifications found mainly in the frontal part of the falx cerebri is consistent with previous psychometric findings since the frontal-subcortical circuits, which support the executive functions, are nearby and could thus be altered by the mass effect of calcifications. Of note, our results are also consistent with previous studies reporting greater risks of vascular and extra-vascular calcifications among people with chronic vitamin K deficiency [9]. For instance, patients with chronic kidney disease suffer from extensive vascular calcifications resulting in excessive mortality [14]. The use of VKA has been associated with an increase in systemic calcification, including in the coronary and peripheral vasculature [9]. In one study, the Agatston score of coronary calcifications correlated positively with the duration of exposure to VKA [15]. In another study, the group treated with warfarin developed calcified vessels on mammograms at a rate 50% greater than age and diabetes status-matched controls [16]. For patients who were treated for more than 5 years with warfarin, the prevalence of vascular calcification increased to nearly 75% [16]. Finally, treatment with warfarin has also been linked to calcification in the tracheobronchial tree among patients lacking other traditional risk factors for calcification [17], stressing that both vascular and extra-vascular calcifications may occur in patients under VKA.

The mechanisms linking VKAs to calcification has been the matter of extensive research over the past decade. The main explanation relies on the matrix gamma-carboxyglutamate Gla protein (MGP), a highly insoluble protein synthesized by vascular

smooth muscle cells, which prevents calcification at the cellular level [18]. To become active, MGP undergoes a post-translational modification, i.e. carboxylation reaction, which requires vitamin K as a cofactor. Thus, in the setting of vitamin K deficiency, MGP cannot be converted to its active form [9]. As an illustration, homozygous MGP-deficient mice exhibited widespread calcification of the carotid arteries, aorta, celiac axis, renal arteries, and iliac arteries [19]. Similarly, rats treated with warfarin at high doses for long periods of time developed calcifications in multiple tissues [20]. Also, in otherwise healthy humans, poor vitamin K status as measured by MGP assays was linked to higher rates of vascular calcification [21]. In contrast, Schurgers et al. administered vitamin K in a rat model that prevented and even reversed vascular calcification [22]. Taken together, these studies suggest that chronic vitamin K deficiency due to VKA fails to activate MGP and may lead to systemic calcifications, including in the brain with plausible subsequent neurocognitive risk.

The strengths of the present study include i) the originality of the research question on drugs widely used in clinical routine, ii) the detailed description of the participants' characteristics allowing the use of multiple regression models to measure adjusted associations, and iii) the standardized collection of data from a single research center. Regardless, a number of limitations also existed. First, the observational case-control design of our study is less robust than a prospective longitudinal cohort study and prevents any causal inference because temporality cannot be demonstrated. Secondly, the limited size of the studied sample may have exposed to lack of statistical power with the risk of missing significant differences. Moreover participants were recruited from one single geriatric ward, which potentially limits generalization of our results to other settings, and it is also possible that the relatively poor state of health may have interfered with the association between VKA use and intracranial calcifications. However, this potential bias was limited by matching cases using VKA and controls using DOA. Fourthly, although we were able to control for important

characteristics that could modify the associations, residual potential confounders might still be present such as the serum phylloquinone concentration, the history of international normalized ratio (INR) or the use of drugs that interfere with calcifications. Despite these limitations, we were able to report among older adults an increased burden of intracranial calcifications under VKA. Further prospective observational cohorts and randomized clinical trials, preferentially on a variety of adult populations, are needed to clarify whether those using VKA are more likely to experience intracranial calcifications than those using DOA, and whether the regular use of DOAs could limit the onset of calcifications and prevent the neurocognitive disorders met under VKAs.

Contributors

Gaëlle Annweiler contributed to acquisition of data, analysis and interpretation of data, and drafting of the manuscript.

Mathieu Labriffe contributed to acquisition of data and critical revision of the manuscript for important intellectual content.

Pierre Ménager contributed to acquisition of data and critical revision of the manuscript for important intellectual content.

Guyline Ferland contributed to critical revision of the manuscript for important intellectual content.

Antoine Brangier contributed to study concept and design, acquisition of data, analysis and interpretation of data, and critical revision of the manuscript for important intellectual content.

Cédric Annweiler contributed to study concept and design, acquisition of data, analysis and interpretation of data, and drafting of the manuscript.

All authors saw and approved the final version.

Conflict of interest

The authors declare that they have no conflict of interest.

Funding

No sources of funding were used to assist in the preparation of this article.

Ethical approval

The study was conducted in accordance with the ethical standards set forth in the Helsinki Declaration (1983). Ethics approval was obtained from the Ethics Board of the University Hospital of Angers, France (2017). Informed consent was obtained at enrolment according to protocols approved by the local institutional review board.

Provenance and peer review

Peer review was directed by Professor Leon Flicker independently of Cedric Annweiler, an author and *Maturitas* editor, who was blinded to the process.

Research data (data sharing and collaboration)

There are no linked research data sets for this paper. Data will be made available on request.

REFERENCES

- [1] J. Ansell, J. Hirsh, E. Hylek, A. Jacobson, M. Crowther, G. Palareti G, American College of Chest Physicians: Pharmacology and management of the vitamin K antagonists: American College of Chest Physicians Evidence-Based Clinical Practice Guidelines, 8th Edition, Chest. 133 (2008) 160S-198S.

- [2] C. Annweiler, G. Ferland, P. Barberger-Gateau, A. Brangier, Y. Rolland, O. Beauchet, Vitamin K antagonists and cognitive impairment: Results from a cross-sectional pilot study among geriatric patients, *J. Gerontol. A. Biol. Sci. Med. Sci.* 70 (2015) 97-101.
- [3] G. Ferland, C. Féart, N. Presse, S. Lorrain, F. Bazin, C. Helmer, C. Berr, C. Annweiler, O. Rouaud, J.F. Dartigues, A. Fourrier-Reglat, P. Barberger-Gateau, Vitamin K antagonists and cognitive function in older adults: The Three-City cohort study, *J. Gerontol. A. Biol. Sci. Med. Sci.* 71 (2016) 1356-1362.
- [4] A. Brangier, G. Ferland, Y. Rolland, J. Gautier, C. Féart, C. Annweiler, Vitamin K Antagonists and Cognitive Decline in Older Adults: A 24-Month Follow-Up, *Nutrients.* 10 (2018) 6.
- [5] G. Ferland, Vitamin K and the nervous system: an overview of its actions, *Adv. Nutr.* 3 (2012) 204-212.
- [6] S. Tamadon-Nejad, B. Ouliass, G. Ferland. Vitamin K deficiency induced by warfarin is associated with cognitive and behavioral perturbations, and alterations in brain sphingolipids in rats, *Front. Aging. Neurosci.* 10 (2018) 213.
- [7] C. Annweiler, S. Denis, G. Duval, G. Ferland, R. Bartha, O. Beauchet, Use of vitamin K antagonists and brain volumetry in older adults: preliminary results from the gait study, *J. Am. Geriatr. Soc.* 63 (2015) 2199-2202.
- [8] A. Brangier, S. Celle, F. Roche, O. Beauchet, G. Ferland, C. Annweiler, Use of Vitamin K Antagonists and Brain Morphological Changes in Older Adults: An Exposed/Unexposed Voxel-Based Morphometric Study, *Dement. Geriatr. Cogn. Disord.* 45 (2018) 18-26.
- [9] T.J. Poterucha, S.Z. Goldhaber, Warfarin and Vascular Calcification, *Am. J. Med.* 129 (2016) 635.

- [10] J.L. Cummings, L.F. Gosenfeld, J.P. Houlihan, T. McCaffrey, Neuropsychiatric disturbances associated with idiopathic calcification of the basal ganglia, *Biol. Psychiatry*. 18 (1983) 591-601.
- [11] Y. Kiroğlu, C. Callı, N. Karabulut, C. Oncel C, Intracranial calcifications on CT, *Diagn. Interv. Radiol*. 16 (2010) 263-269.
- [12] B. Dubois, A. Slachevsky, I. Litvan, B. Pillon, The FAB: A frontal assessment battery at bedside, *Neurology*. 55 (2000) 1621-1626.
- [13] J.G. Hall, R.M. Pauli, K.M. Wilson, Maternal and fetal sequelae of anticoagulation during pregnancy, *Am. J. Med*. 68 (1980) 122-140.
- [14] L.J. Schurgers, D.V. Barreto, F.C. Barreto, S. Liabeuf, C. Renard, E.J. Magdeleyns, C. Vermeer, G. Choukroun, Z.A. Massy, The circulating inactive form of matrix gla protein is a surrogate marker for vascular calcification in chronic kidney disease: a preliminary report, *Clin. J. Am. Soc. Nephrol*. 5 (2010) 568-575.
- [15] B. Weijjs, Y. Blaauw, R.J. Rennenberg, L.J. Schurgers, C.C. Timmermans, L. Pison, R. Nieuwlaat, L. Hofstra, A.A. Kroon, J. Wildberger, H.J. Crijns, Patients using vitamin K antagonists show increased levels of coronary calcification: an observational study in low-risk atrial fibrillation patients, *Eur. Heart. J*. 32 (2011) 2555-2562.
- [16] E. Tantisattamo, K.H. Han, W.C. O'Neill, Increased vascular calcification in patients receiving warfarin, *Arterioscler. Thromb. Vasc. Biol*. 35 (2015) 237-242.
- [17] L. Eckersley, J. Stirling, C. Occleshaw, N. Wilson N, Two cases of warfarin-induced tracheobronchial calcification after Fontan surgery, *Pediatr. Cardiol*. 35 (2014) 954-958.

- [18] R.C. Johnson, J.A. Leopold, J. Loscalzo, Vascular calcification: pathobiological mechanisms and clinical implications, *Circ. Res.* 99 (2006) 1044-1059.
- [19] G. Luo, P. Ducy, M.D. McKee, G.J. Pinero, E. Loyer, R.R. Behringer, G. Karsenty, Spontaneous calcification of arteries and cartilage in mice lacking matrix GLA protein, *Nature*, 386 (1997) 78-81.
- [20] T. Kruger, S. Oelenberg, N. Kaesler, L.J. Schurgers, A.M. van de Sandt, P. Boor, G. Schlieper, V.M. Brandenburg, B.C. Fekete, V. Veulemans, M. Ketteler, C. Vermeer, W. Jahnen-Dechent, J. Floege, R. Westenfeld, Warfarin induces cardiovascular damage in mice, *Arterioscler. Thromb. Vasc. Biol.* 33 (2013) 2618-2624.
- [21] G.W. Dalmeijer, Y.T. van der Schouw, E.J. Magdeleyns, C. Vermeer, S.G. Elias, B.K. Velthuis, P.A. de Jong, J.W. Beulens, Circulating species of matrix gla protein and the risk of vascular calcification in healthy women, *Int. J. Cardiol.* 168 (2013) e168-e170.
- [22] L.J. Schurgers, H.M. Spronk, B.A. Soute, P.M. Schiffers, J.G. DeMey, C. Vermeer, Regression of warfarin-induced medial elastocalcinosis by high intake of vitamin K in rats, *Blood.* 109 (2007) 2823-2831.

Table 1. Summary of the participants' characteristics (n=38)

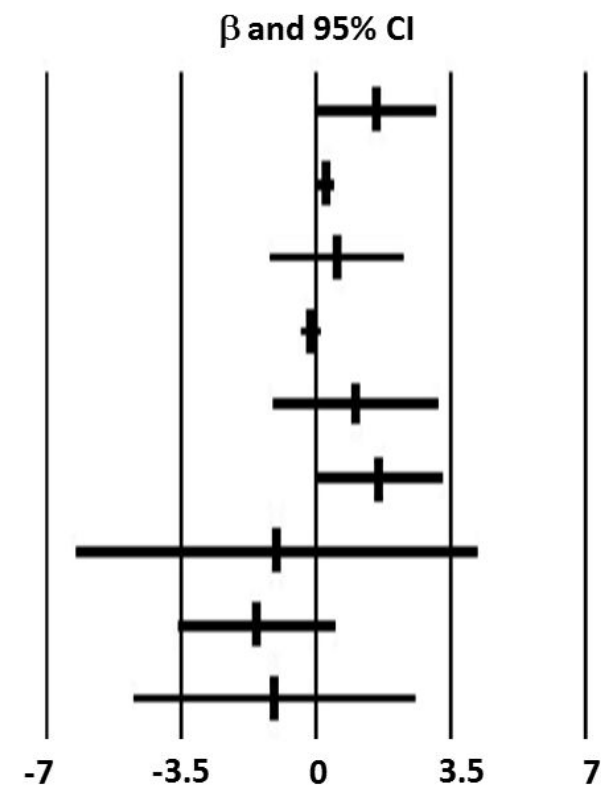
| | Total cohort (n=38) | Participants using | | P-Value* |
|---|------------------------|--------------------|----------------|--------------|
| | | VKA (n=19) | DOA (n=19) | |
| Demographical measures | | | | |
| Age, years | 84 [7] (73-91) | 84 [7] (73-91) | 84 [7] (73-89) | 0.795 |
| Female gender, n (%) | 20 (52.6) | 10 (52.6) | 10 (52.6) | 1.000 |
| Clinical measures | | | | |
| FAB score, /18 | 12 [4] (6-18) | 12 [5] (6-18) | 12 [4] (6-18) | 0.773 |
| Hypertension, n (%) | 31 (81.6) | 14 (73.7) | 17 (89.5) | 0.405 |
| Dyslipidaemia, n (%) | 19 (50.0) | 9 (47.4) | 10 (52.6) | 0.746 |
| Carotid artery stenosis, n (%) | 1 (2.6) | 1 (5.3) | 0 (0) | 1.000 |
| Kidney failure, n (%) | 11 (28.9) | 5 (26.3) | 6 (31.6) | 0.721 |
| Anticoagulation | | | | |
| Indication for anticoagulation, n (%) | | | | |
| Atrial fibrillation | 36 (94.7) | 18 (94.7) | 18 (94.7) | 1.000 |
| Venous thromboembolism or mechanical valve | 2 (5.3) | 1 (5.3) | 1 (5.3) | 1.000 |
| Anticoagulation > 3 months, n (%) | 38 (100.0) | 19 (100.0) | 19 (100.0) | 1.000 |
| Burden of intracranial calcifications | | | | |
| Carotid siphons [†] | 3 [1] (1-3) | 3 [1] (1-3) | 2 [1] (1-3) | 0.191 |
| Internal carotids in their horizontal intra-petrous segment | 0 [0] (0-1) | 0 [1] (0-1) | 0 [0] (0-1) | 0.418 |
| Intracranial V4 segment of the vertebral arteries | 1 [2] (0-3) | 1 [2] (0-3) | 1 [2] (0-3) | 0.977 |
| Basilar artery | 0 [0] (0-1) | 0 [0] (0-1) | 0 [0] (0-1) | 1.000 |
| Choroid plexus | 1 [0] (1-2) | 1 [0] (1-2) | 1 [0] (1-2) | 0.795 |
| Pallidum | 0 [1] (0-1) | 0 [0] (0-1) | 0 [1] (0-1) | 0.418 |
| Falx cerebri | 1.5 [1] (0-3) | 2 [1] (0-3) | 1 [2] (0-2) | 0.025 |
| Calcifications in the immediate vicinity of veins or | 1 [1] (0-3) | 1 [1] (0-3) | 1 [1] (0-2) | 0.563 |

| | | | | |
|---------------------|-------------|-------------|-------------|-------|
| venous plexus | | | | |
| Others [‡] | 0 [0] (0-1) | 0 [0] (0-1) | 0 [0] (0-1) | 0.795 |

Data presented as median [interquartile range] (range) where applicable; CI: confidence interval; DOA: direct oral anticoagulant; FAB: frontal assessment battery; V4: fourth ventricle; VKA: vitamin K antagonist; *: Comparisons of participants using VKA with those using DOA based on the Chi-square test or Fisher exact test or Mann-Whitney U test, as appropriate; †: intracranial internal carotids; ‡: rare or unusual locations of intracranial calcification. P-values significant (i.e. < 0.05) indicated in bold.

Table 2. Multiple logistic regressions examining the cross-sectional association between the use of vitamin K antagonists (VKA, independent variable) and the global burden of intracranial calcifications (dependent variable), adjusted for potential confounders

| Global burden of intracranial calcifications | | | |
|---|---------------------------|-----------------|----------------|
| | β | [95% CI] | P-Value |
| Use VKA (versus DOA) | 1.56 | [0.01;3.11] | 0.049 |
| Age | 0.25 | [0.05;0.46] | 0.017 |
| Female gender | 0.54 | [-1.22;2.29] | 0.536 |
| FAB score | -0.14 | [-0.41;0.13] | 0.287 |
| Hypertension | 1.02 | [-1.13;3.17] | 0.340 |
| Dyslipidaemia | 1.62 | [-0.05;3.29] | 0.057 |
| Carotid artery stenosis | -1.03 | [-6.24;4.18] | 0.689 |
| Kidney failure | -1.55 | [-3.59;0.49] | 0.130 |
| Indication, atrial fibrillation | -1.09 | [-4.76;2.59] | 0.550 |



β : coefficient of regression corresponding to a change in the global burden of intracranial calcifications; CI: confidence interval; DOA: direct oral anticoagulant; FAB: frontal assessment battery; β significant (i.e., P-value<0.05) indicated in bold.

Table 3. Correlation matrix of the use of vitamin K antagonist with the burden of intracranial calcifications by location (n=38)

| Characteristic | 1. | 2. | 3. | 4. | 5. | 6. | 7. | 8. | 9. |
|---|-----------|-----------|-----------|-----------|-----------|-----------|-----------|-----------|-----------|
| 1. Use of vitamin K antagonist | – | 0.19 | 0.20 | 0.00 | 0.00 | 0.08 | -0.17 | 0.41* | 0.16 |
| 2. Calcification burden in carotid siphons* | | – | 0.21 | 0.45** | 0.05 | 0.22 | -0.19 | 0.18 | 0.27 |
| 3. Calcification burden in internal carotids in their horizontal intra-petrous segment | | | – | 0.14 | 0.28 | 0.02 | 0.15 | 0.03 | -0.12 |
| 4. Calcification burden in intracranial V4 segment of the vertebral arteries | | | | – | 0.32 | -0.02 | -0.10 | -0.10 | 0.20 |
| 5. Calcification burden in basilar artery | | | | | – | -0.13 | -0.03 | -0.14 | -0.27 |
| 6. Calcification burden in choroid plexus | | | | | | – | -0.08 | 0.01 | 0.13 |
| 7. Calcification burden in pallidum | | | | | | | – | 0.06 | -0.22 |
| 8. Calcification burden in falx cerebri | | | | | | | | – | 0.49** |
| 9. Calcification burden in the immediate vicinity of veins or venous plexus | | | | | | | | | – |

*: P<0.05 (2-tailed); **: P<0.01 (2-tailed)

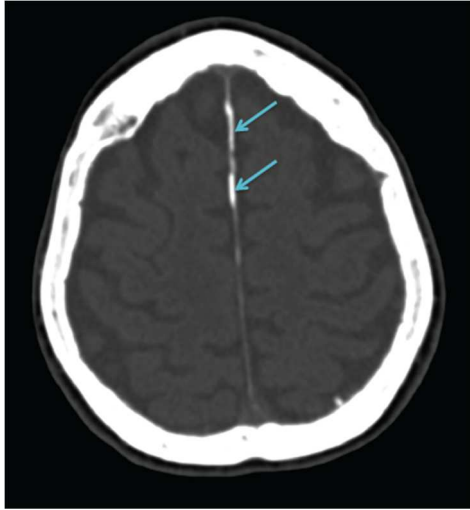


Figure 1. Representative example of a transverse CT-scan image from one participant using vitamin K antagonist, with the falcian calcifications marked by arrows.