HAL open science

Natural history of liver adenomatosis: A long-term observational study

Louise Barbier, Jean-Charles Nault, Fanny Dujardin, Béatrice Scotto, Marie Besson, Anne de Muret, Pascal Bourlier, Jessica Zucman-Rossi, Ephrem Salamé, Yannick Bacq

To cite this version:

Louise Barbier, Jean-Charles Nault, Fanny Dujardin, Béatrice Scotto, Marie Besson, et al.. Natural history of liver adenomatosis: A long-term observational study. Journal of Hepatology, 2019, 71, pp.1184 - 1192. 10.1016/j.jhep.2019.08.004 . hal-03488630

HAL Id: hal-03488630

https://hal.science/hal-03488630v1

Submitted on 21 Jul 2022

HAL is a multi-disciplinary open access archive for the deposit and dissemination of scientific research documents, whether they are published or not. The documents may come from teaching and research institutions in France or abroad, or from public or private research centers.

L'archive ouverte pluridisciplinaire **HAL**, est destinée au dépôt et à la diffusion de documents scientifiques de niveau recherche, publiés ou non, émanant des établissements d'enseignement et de recherche français ou étrangers, des laboratoires publics ou privés.

Distributed under a Creative Commons Attribution - NonCommercial 4.0 International License

Version of Record: https://www.sciencedirect.com/science/article/pii/S0168827819304702
Manuscript_5927d6004f358be299addf71132b78c8

Natural history of liver adenomatosis: a long-term observational study

Authors: Louise Barbier[1], Jean-Charles Nault[2,3], Fanny Dujardin[4], Béatrice Scotto[5], Marie Besson[5], Anne de Muret[4], Pascal Bourlier[1], Jessica Zucman-Rossi[3,6], Ephrem Salamé[1], Yannick Bacq[7]

Affiliations:

1: Digestive surgery and liver transplantation, Tours university hospital, University of Tours, FHU SUPORT, Tours, France.

2: Inserm UMR-1162, Génomique fonctionnelle des Tumeurs solides, Université Paris Descartes, Université Paris Diderot, Université Paris 13, Labex Immuno-Oncology, Paris, France.

3: Liver unit, Hôpital Jean Verdier, Hôpitaux Universitaires Paris-Seine-Saint-Denis, Assistance-Publique Hôpitaux de Paris, APHP, Bondy, France.

4: Pathology, Tours university hospital, University of Tours, Tours, France.

5: Radiology, Tours university hospital, University of Tours, Tours, France.

6: Hôpital Européen Georges Pompidou, HEGP, F-75015, Assistance Publique-Hôpitaux de Paris, APHP, Paris, France.

7: Department of Hepatology and Gastroenterology, University Hospital of Tours, Tours, France.

Corresponding author:

Louise Barbier

© 2019 published by Elsevier. This manuscript is made available under the CC BY NC user license
https://creativecommons.org/licenses/by-nc/4.0/

Digestive surgery and liver transplantation

Tours university hospital – hôpital Trousseau

Avenue de la République

37170 Chambray-lès-Tours

+33 (2)-47-47-81-23

+33 (2)-47-47-59-10

louisebarbier@hotmail.fr

Key-words: hepatocellular adenoma; hepatocellular carcinoma; hemorrhage; molecular biology; immunohistochemistry

Conflict of interest:

The authors declare that they have non conflict of interest.

Financial support:

This work supported by Association pour la recherche contre le cancer (2003), Société Nationale Française de Gastro-Entérologie (2005), Inca (2006), GENTHEP Inserm Network (2003 2008) and Institut National du Cancer (INCa) with the International Cancer Genome Consortium (ICGC LICA-FR project) and NoFLIC projects (PAIR HCC, INCa and ARC). The group is supported by the Ligue Nationale contre le Cancer (Equipe Labellisée), Labex OncoImmunology (investissement d'avenir), grant IREB, Coup d'Elan de la Fondation Bettencourt-Shueller, the SIRIC CARPEM and Fondation Mérieux.

Authors' contributions:

LB designed the study, analyzed data, wrote and submitted the manuscript

JCN, JZR analyzed samples for molecular biology and corrected the manuscript

FD, AdM analyzed samples and corrected the manuscript

BS, MB analyzed imaging and corrected the manuscript

PB, ES collected data and informed consents, and corrected the manuscript

YB designed the study, collected data and informed consents, and corrected the manuscript

Abbreviations:

LA: liver adenomatosis

HCA: hepatocellular adenoma

HHCA: HNF-1α mutated HCA

b^{ex3}HCA: ß -catenin mutated HCA in exon 3

$b^{ex7,8}$HCA: ß -catenin mutated HCA in exon 7 or 8

IHCA: inflammatory HCA

shHCA: sonic hedgehog HCA

b^{ex3}IHCA: ß -catenin mutated inflammatory HCA in exon 3

$b^{ex7,8}$IHCA: ß -catenin mutated inflammatory HCA in exon 7 or 8

UHCA: unclassified HCA

MODY 3: maturity onset diabetes on the young type 3

CTNNB1: cadherin-associated protein beta 1

FRK: fyn related kinase

gp130: glycoprotein 130

GLI1: glioma-associated oncogene 1

GS: glutamin synthase

IL-6: interleukin 6

JAK: janus kinase

LFABP: liver fatty acid binding protein

SAA: serum amyloid A

STAT: signal transducer and activator of transcription

MRI: magnetic resonance imaging

ABSTRACT

Background and aims: Liver adenomatosis (LA) is characterized by the presence of at least 10 hepatocellular adenomas (HCAs) but the natural history of this rare liver disorder remains unclear.

Methods: We analyzed in a monocentric cohort the natural history of 40 patients with LA, excluding glycogen storage. Pathological examination with immunostaining and molecular biology of surgical specimens or liver biopsies were performed.

Results: Forty patients (36 female) were included with a median follow-up of 10.6 [1.9-26.1] years. Six (15%) patients had familial LA all with germline HNF-1α mutation. Median age at diagnosis was 39 [9-55] years. Thirty-three (94%) women had a history of oral contraception, and 29 (81%) women had pregnancy before LA diagnosis. Overall, thirty-seven (93%) patients underwent surgery at diagnosis. Classification of HCAs showed 46% of patients with HNF-1α mutated HCA, 31% with inflammatory HCA, 3% with sonic hedgehog HCA, 8% with unclassified HCA. Only 15% of the patients demonstrated a “mixed LA” with different HCA subtypes. Hepatic complications were identified in 7 patients: one patient (3%) died from recurrent hepatocellular carcinoma after liver transplantation, and six (15%) had hemorrhages, among them five occurred at diagnosis with a fatal one during pregnancy, and two occurred in male patients with familial LA. Four patients (10%) had repeated liver resections. Finally, four (10%) patients developed extra hepatic malignancies during follow-up.

Conclusions: The diversity in HCA subtypes, the occurrence of bleeding and malignant transformation during long-term follow-up underline the heterogeneous nature of LA that justify close and specific management. In patients with germline HNF-1α mutation, familial LA occurred equally in male and female, with a high rate of bleeding in male patients.

Lay summary

Liver adenomatosis is a rare disease characterized by the presence of 10 or more hepatocellular adenomas that may rarely be of genetic origin. Patients with liver adenomatosis have multiple adenomas of different subtypes, with a risk of bleeding and malignant transformation that justify a specific management and follow-up.

Introduction

Hepatocellular adenomas (HCAs) are rare benign liver tumors that increased in frequency after the wide prescription of oral contraceptive pills in the 1960's. Currently its prevalence ranges between 1 and 4 for 100,000 individuals (1). Owing to its estrogen-dependence, the female to male ratio is 10:1 and HCAs predominantly affect young women around 30-40 years old (2,3). The two major risks of HCAs are symptomatic hemorrhage and malignant transformation with an occurrence estimated to 15% and 5% of the cases in surgical series, respectively (3,4). Identified risk factors for both complications are mostly the size of the lesion greater than 5cm and the male gender for malignant transformation (3,5).

A step forward in the understanding of HCAs pathogenesis has been made with the molecular classifications developed since 2001 and recently updated (2,6–9). This molecular classification identifies eight different subtypes of HCAs correlated with clinical and histopathological features: (1) HNF-1α inactivated HCA (HHCA) in 34% of the cases are usually massively steatotic; (2) ß-catenin activated HCAs with exon 3 (b^{ex3}HCA) associated with a higher risk of malignant transformation or (3) ß-catenin activated HCAs with exon 7 or 8 mutations ($b^{ex7,8}$HCA) with a low risk of malignant transformation in 7% and 4% of the tumors, respectively; (4) inflammatory HCA (IHCA), in 34% of the cases characterized by mutations in either IL6ST, STAT3, JAK1, GNAS, FRK, or IL6 somatic alterations and are associated with metabolic syndrome and alcohol intake; (5) sonic Hedgehog activated HCA (shHCA) with aberrant overexpression of GLI1 due to INHBE/GLI1 fusion in 4% of HCA associated

with a higher risk of bleeding; mixed inflammatory HCA also activated for ß-catenin with (6) exon 3 mutation (b^{ex3}IHCA) in 6% or with (7) exon7 or 8 of *CTNNB1* ($b^{ex7,8}$IHCA) in 4% of the cases; and finally (8) the tumors that remained unclassified (UHCA) in 7%.

For these patients, European Association for the Study of the Liver clinical guidelines (1) recommend to correct risk factors when possible, mainly by stopping oral contraception or androgen intake, and modifying lifestyle to lose weight. Taking into account their high risk of complication, liver resection is often proposed for HCAs in men, for large HCA (>5 cm) in women with a more aggressive strategy in all HCAs with ß-catenin activation. Trans arterial embolization represents an alternative treatment currently evaluated for HCAs (10).

Liver adenomatosis (LA) has first been described by Monges et al. (11) and Monaco et al. (12) in the early 1960's. Later in 1985, Flejou et al. (13) defined LA by the presence of 10 or more HCAs, both in men and women. Liver adenomatosis can develop on underlying liver pathology such as glycogen storage disease or vascular abnormalities like portal vein agenesis (14), but also on normal livers. A familial form associated with diabetes was described by Foster et al. (15) and in 2003, germline HNF-1α (also termed TCF1) inactivation, usually associated with maturity-onset diabetes of the young type 3 (MODY 3), were identified in patients with familial LA showing steatotic HCA with bi-allelic inactivating mutations of HNF1A in the tumors (16,17). The presence of multiple HCAs raises the question of its management,

especially when liver resection is not possible owing to the number and location of tumors, with some rare indications of liver transplantation that have been reported (14). The European Association for the Study of Liver guidelines (1) recommend that the management of patients with multiple HCAs should be based on the size of the largest tumor, based on the fact that clinical presentation and risk of bleeding or malignancy does not differ between patients with single or multiple HCAs. However, the natural history of LA is poorly described in the literature.

Here, we describe the 10 years follow-up of a cohort of 40 patients with LA developed on normal livers. We aim to reappraise the natural history and the risk of complication in this specific population of patients with HCAs.

Patients and Methods

The present study is a monocentric observational cohort study, it has been reported according to the strengthening the reporting of observational studies in epidemiology (STROBE) guidelines (18). Checklist of these items is available as supplementary table 1.

Setting

The study was conducted in one academic hospital, referent for liver tumors. All patients with LA who presented at our center between 1991 and 2015 were followed-up.

Ethics

The study was approved by our local ethics committee in human research (number 2015 010). All patients signed an informed consent to participate in the study and to have specific genetic studies on the biopsy and liver resection specimens, and on blood samples for patients with suspicion of familial LA.

Participants

All patients with (i) at least than 10 HCAs that can be measured on imaging, (ii) at least one HCA that was histologically proven (except for two patients with proven familial LA for whom HNF-1α inactivation was found in blood samples), (iii) normal underlying liver, except for liver steatosis, were included. Patients with (i) less than 10 HCAs, (ii) micro adenomas only, (iii) glycogen storage disease, history of steroids intake, (iv) no histological proof of HCA in sporadic forms of LA, were not included. Patients were included after a first radiological assessment. Histological proof was obtained by percutaneous liver biopsy or laparoscopic surgical biopsy in case of difficult percutaneous access, or by analysis of the resected specimen. For patients with suspicion of familial LA, the genetic study has been previously described (16,19,20). At the time of diagnosis, hormonal treatments and oral contraception were ceased in all patients except one. Diet and lifestyle intervention were provided for patients with body mass index greater than 25 kg/m^2 and/or liver steatosis. During their follow-up, patients with LA usually had clinical (including weight and body mass index), biological (liver function tests, leukocyte count, glycaemia and lipid tests) and imaging assessment every six or 12 months. Women with a desire for pregnancy were systematically re-assessed before stopping contraception.

Variables and data measurement

Radiological assessment

Radiological assessment was performed by two senior radiologists specialized in abdominal imaging (BS, MB). Abdominal ultra-sound and magnetic resonance imaging (MRI) were alternately performed. Only data from MRI were collected for analysis. Dedicated forms were filled at each MRI assessment: number of nodules, diameter of the biggest nodule, number of nodules greater than 3 and 5 cm, evolution in size/number since the last assessment, type of HCAs on MRI (inflammatory, steatotic, other), presence of hemorrhage, non-tumoral steatosis, and other associated benign liver lesions. All the patients underwent MR imaging on one of different 1.5-T units with a phased-array body coil. A section thickness, as thin as possible for each machine to explore the whole liver, was used in all sequences. In each patient, a fat-suppressed T2-weighted fast spin-echo sequence and fat-suppressed dynamic gadolinium-enhanced T1-weighted imaging in four phases (pre-contrast, arterial, portal, and delayed) after administration of an intravenous bolus of non–liver-specific gadolinium chelate were used. The optimal arterial phase was based on bolus tracking. The portal and delayed phases were acquired at 90 and 180 seconds, respectively after the injection.

In addition when available, T1-weighted in- and opposed-phase gradient-echo sequences or T1-weighted modified Dixon sequence and diffusion-weighted imaging (low B values below 100 sec/mm^2 and higher B values > 500 sec/mm^2) were used.

Diagnosis of HCA and subtype classification at imaging were performed using previously described MRI criteria (21). Diagnosis of HCA subtype with imaging was considered accurate if it was described (i) steatotic in imaging and considered a

HHCA in immunohistochemistry and molecular biology, (ii) inflammatory on imaging and considered a IHCA at immunochemistry and molecular biology, (iii) undetermined at imaging and UHCA at immunochemistry and molecular biology.

Surgery

For patients who underwent surgery, three senior surgeons (PB, ZB, ES) performed the liver resections, either by laparotomy or laparoscopically.

Pathological analysis

Two senior liver-specialized pathologists reviewed all the cases of HCAs (FD, AdM). Surgical specimens or liver biopsies (including tumoral and non-tumoral liver) were (i) fixed in formalin, embedded in paraffin and routinely processed for diagnosis purpose in our center, (ii) samples were frozen and stored at -80°C for further genetic analysis.

Paraffin sections were stained with hematoxylin-eosin, Masson's trichrome, Perls, and Gordon-Sweet colorations. A standardized form was used with (i) macroscopic examination: number and size of tumor, presence of a capsule, intra tumoral necrosis or hemorrhage, (ii) microscopic examination: intra tumoral steatosis, peliosis, inflammatory infiltrate, and fibrosis, (iii) analysis of the non-tumoral liver (macro vacuolar steatosis, fibrosis, steatosis micro foci with loss of liver fatty acid binding protein (LFABP) expression), and (iv) immunostaining. The immunochemistry profile of the HCA was performed with the following staining: glutamin synthase (GS), C reactive protein, serum amyloid A (SAA), LFABP, β-catenin, cytokeratin 7 and cytokeratin 19 in the beginning of our experience, actin-smooth muscle, and anti-

CD34 antibody (see Supplementary CTAT Table). Classification of HCAs in HNF-1α mutated, inflammatory, β-catenin mutated and unclassified HCAs based on immunostaining was performed according to previously published studies (7).

Complementary immunohistochemistry and molecular analysis of HCAs

Frozen sections available have been analyzed at INSERM U1162 for further molecular classification. All the specimens were analyzed by molecular biology in the present study have been already included in the study published in 2017 by Nault et al. (9). HCAs were classified according to the eight subgroups previously described using expression analysis and sequencing of *CTNNB1*, *HNF1A*, *IL6ST*, *FRK*, *STAT3*, *GNAS* and *JAK1* (9): HHCA, IHCA, b^{ex3}HCA, b^{ex3}IHCA, $b^{ex7,8}$HCA, $b^{ex7,8}$IHCA, shHCA, and UHCA (see Supplementary CTAT Table).

Classification of the patient was performed using molecular biology, or immunohistochemistry if molecular biology was not available (pathomolecular classification).

Bias

Some patients had different HCAs with different immunophenotypes: this inter-tumoral heterogeneity was considered as “mixed form”.

Statistical analysis

Statistical analysis was performed using Excel (Microsoft corporation) and Graph Pad Prism v7 software (la Jolla, Inc.). Qualitative data were described as absolute numbers and percentages. Qualitative data were described as median and ranges into square brackets. Survival curve was calculated using the Kaplan Meier method.

Missing data were reported for each variable if applicable. No patient was loss to follow-up.

Results

During the study period, 54 patients have been screened for LA. Forty patients who matched the inclusion criteria were finally included in the study (see flow chart as supplementary figure).

Clinical presentation at diagnosis

Thirty-six (90.0%) patients were female; all patients were Caucasian. Personal past medical history retrieved: MODY3 (n=1), mental deficiency in relation to neonatal anoxia (n=2), epilepsy (n=4), immune-mediated diseases (n=3: Crohn disease, acute articular rheumatism, spondyloarthritis), mosaic trisomy 8, associated with bone malformations, proteinuria, and deafness (n=1), gastric adenocarcinoma (n=1), and chronic hemolysis with dyserythropoiesis (n=1). Eleven (27.5%) patients had a familial history of diabetes mellitus, including three patients with MODY3.

Median body mass index was 23.2 [17.5-35.4] kg/m^2, with 6 (15.0%) patients with morbid obesity and body mass index > 30 kg/m^2. LA was diagnosed at a median age of 39.0 [9.2-54.8] years. Diagnostic circumstances were as follows: by chance (n=11, 27.5%), abdominal pain (n=14, 35.0%), liver function tests abnormalities (n=8, 20.0%), hemoperitoneum (n=4, 10.0%, including one pregnant patient who died at presentation, see below), and familial genetic screening (n=3, 7.5%). In one patient, a portal vein thrombosis with cavernoma was diagnosed at the same time. Liver

adenomatosis was sporadic in 34 (85.0%) patients whereas 6 patients had familial LA due to heterozygous germline HNF1A mutations. Regarding hormonal status, 33 (94.3%, information is missing for one patient) women were taking oral contraceptive pill for 15 [1-31] years (information available for 23 women). Twenty-nine (80.5%) already had a pregnancy before diagnosis of LA.

Initial biological presentation

Liver function tests were abnormal in 26 (66.7%, information missing for one patient) patients at presentation: six patients had an isolated cytolysis, and 20 patients had elevated gamma-glutamyl transferase with or without elevated cytolysis. Alkaline phosphatases were elevated in 22 patients (38.9%, data missing for two patients) with a median of 162 [122-652]. Liver function tests were always normal in patients with familial LA, whereas patients with moderate or severe steatosis in the non-tumoural liver (see below) all had abnormal liver function tests. No patient harbored an elevated alpha-foeto-protein at presentation.

Initial imaging

The first imaging performed at the diagnosis was abdominal ultra-sound in 31 patients (77.5%). MRI at diagnosis, before surgical resection, was available for 33 patients (one patient died at presentation, and for six patients initial imaging could not be retrieved). Size of the largest tumor was 59.5 [5.0-128.0] mm, with 27 (81.8%) patients whose largest tumor was above 5 cm. Steatosis on the non-tumor liver was found in 3 (9.1%) patients, and focal nodular hyperplasia in 7 (21.2%) patients. Intra-tumor hemorrhages at imaging were found in 5/31 (29.0%) patients. The type of the largest HCA based on imaging was reported for 31 patients. They were classified as

follow: steatotic compatible with HHCA: n=17 (54.8%), inflammatory: n=10 (32.3%), and undetermined: n=4 (12.9%). In two patients, imaging classification was not possible because of intra-tumoural hemorrhage.

Surgery

Totally, 37 (92.5%) patients underwent surgery. Three of them had previous arterial embolization for hemorrhage. Main indications for surgery were: size > 5cm (15 patients, 42.9%, including one man), previous HCA hemorrhage (4 patients including two men, 10.8%), suspicion of hepatocellular carcinoma (3 patients, 8.1%), the need for histological proof with lesions that were not easily accessible to percutaneous biopsy in (12 patients, 32.4%), resection before pregnancy (n=1), surgery for another indication (gastric adenocarcinoma) (n=1), and abdominal pain (n=1). Surgical procedures included (different procedures may be associated, total of 45 procedures): major hepatectomies (n=6, 13.3%), minor hepatectomies or atypical liver resections (n=26, 57.8%), biopsies (n=9, 20.0%), and hemostasis (n=3, 6.7%). One patient had a liver transplantation for hepatocellular carcinoma recurrence after initial liver resection.

Pathological analysis and classification by immunohistochemistry and molecular biology

Standardized pathological analysis was available for 38 patients. Among two patients with familial LA and diagnosis of the mutation in the peripheral blood, one did not have biopsy/resection, and one had histological proof of HCA but sections were not retrieved for standardized analysis. In total, 68 lesions were analyzed in 38 patients. Median number of tumors that were analyzed was 3[1-13], and the size of the largest

nodule was 55 [6-150] mm. Limits were sharp in 28/32 (87.5%) HCAs. No HCA presented with a capsule. Regarding HCAs, 9.4% had necrosis, 28.1% had hemorrhage, 56.1% had peliosis, and 7.3% had fibrosis. An intra-tumor inflammatory infiltrates was considered mild in 36.7%, moderate in 19.5%, and severe in 4.9% of HCAs. Regarding non-tumoural liver, fibrosis with septa was present in 4.9%, and peliosis in 9.8%. Steatosis was absent or mild in 85.4%, moderate in 7.3% (including two patients with IHCA and one patient with shHCA), and severe in 7.3% (including two patients with IHCA and one patient with UHCA) resections. Micro foci of steatosis were found in 39% of non-tumoral livers, including with LFABP loss of expression in 14 specimens, suggesting the presence of micro adenomas inactivated for HNF-1α.

Immunohistochemistry_was performed in all lesions except three: in one patient, the diagnosis was made at necropsy and the sample was not well preserved, and in another patient with two lesions, previous trans arterial embolization prevent from successfully performing immunostaining. Molecular biology could be performed in 51 tumors from 29 patients.

Totally, pathomolecular classification of the patients according to the subtype of HCA was available for 40 patients (pathological analysis n=38 patients, and peripheral blood analysis n=2 patients) and is detailed in table 1 and table 2.

Classification with MRI correlated to pathomolecular classification for 85.7% of patients (data available for 35 patients). HCAs that were not accurately identified by imaging were UHCAs in two cases, HHCAs in two cases, and a patient with both HHCAs and IHCAs.

Long-term follow-up

Thirty-nine patients were followed up for 10.6 [1.9-26.1] years (one patient died at presentation). During follow-up, clinical events were: malignant transformation (n=1 patient, see below), hemorrhage (n=1 patient, see below), onset of diabetes mellitus (n=2 patients), cancer that occurred after diagnosis of LA in four (10.3 %) patients, among one of them had familial LA: lymphoma, pulmonary adenocarcinoma, breast cancer, and renal cancer in two patients. Four women were pregnant after the diagnosis with five born children: 1 woman underwent surgical resection of the largest HCA before the pregnancy and there was a progression of the nodules in one woman after her pregnancy. At censor date, 37 patients were alive. The latest MRI available for comparison has been performed 69.8 [6.1-176.9] months after initial assessment in 30 patients. In 7 (23.3%) patients, lesions increased in size or number, in 9 (30.0%) patients lesions decreased in size or number, and in the remaining 14 (46.7%) the lesions were stable.

Description of patients with HCA complications (bleeding and malignant transformation)

Totally, six (15.0%) patients presented HCA hemorrhage. In five patients, bleeding revealed the disease: two patients were male with familial LA and HNF-1α inactivation with largest nodule being respectively 20mm and 40mm, one female patient had a 128mm mixed form HCA with HHCA and IHCA components, and one female patient had a 50mm-IHCA. The last patient (patient #12 in table 1) was pregnant with her second child and presented with hemorrhagic shock and uncontrollable intra abdominal bleeding that lead to her death. At necropsy, multiple modules and a 150 mm HCA was found. As sections have been kept in

formaldehyde, immunostaining and molecular biology could not be performed. The sixth patient was female and presented a hemorrhage after 7.7 years of follow-up: bleeding arose from an 87 mm HHCA. Notably, this patient did not stop oral contraception after diagnosis of LA.

One female patient (patient #29 in table 1) first underwent atypical liver resection for a non-complicated HCA > 5cm. Five years after the first liver resection, a complementary right hepatectomy was performed because of an increase in size of remaining HCAs. These HCAs were not inflammatory, not steatotic, and not beta-catenin activated at immunohistochemistry; a molecular profile was not performed. Four years after, an increase of HCA in the remnant liver was observed and liver transplantation was performed with malignant transformation found at histology in a 55mm IHCA (see figure 2). Figure 3 displays patients' survival without complication related to HCA (hemorrhage or HCC) at diagnosis or during follow-up with 87.5%, 87.5% and 74.9% of survival without HCA related complications at 1 years, 5 years and 10 years respectively.

Long-term follow-up of patients with familial liver adenomatosis

Six patients (15.0%, including 3 male) in the study had familial LA with heterozygous germline HNF-1α mutation from 2 families (R229X mutation for the first family and G55fsX57 mutation for the second one). Four of these six patients are displayed in the family tree (see figure 1); the fifth patient of this family with LA only had 9 HCAs and was not included in the study. Screening of members has been completed since previous publication (family A from Bacq et al. (16)). Two other patients with familial LA originate from another family (family B already described in Bacq et al. (16)).

All three female patients with familial LA were taking oral contraceptive pill at the time of diagnosis. Two male patients had initial bleeding at presentation. There was no other hepatic complication during follow-up. Five patients underwent liver resection. In four patients, hepatic nodules increased in size, in one patient the disease was stable and in one patient the lesions decreased in size. One patient developed a renal carcinoma and gastric and colonic polyps.

Discussion

To our knowledge, this study is the first specifically focusing on LA and its natural history. We better defined the population of LA patients: female gender (90%), a median age of 39 years at diagnosis, an association with HNF-1α germline mutation (15%), and with obesity (15%). Diagnosis frequently occurred in patients with large nodule > 5cm (80%) and with inaugural severe complication challenging the standard of care of these patients. HCA subtype was homogenous in 87% of the patients whereas in the remaining 13% different HCA subtypes coexisted in the same liver. Malignant transformation and intra peritoneal hemorrhage respectively occurred in 2.5% and 15.0% of the patients, mostly after 40 y of age. Complications were not more frequent than in isolated HCAs (3,4) but occurred in patients with HCAs of various types and sizes. Moreover, our cohort has the advantage to describe a long-follow up (up to 26 years) of these difficult to manage patients. We showed that, during follow-up, up to 23% of the patients harbored a new lesion or an increase in size of preexisting lesions at imaging. It led to a surgical resection in 4 (10%) patients due to modification in size or numbers.

Several features may be underlined in familial LA. All familial cases of LA involve a germline HNF-1α mutation. In this study, there was no female predominance (50%), and no male patient with LA had malignant transformation, unlike what has been previously shown in isolated HCAs (1,5,22). However, two out of three male patients with familial LA had intra-peritoneal hemorrhage arising from small HCAs. As suggested by the family tree (Figure 1), LA tends to appear in younger patients over the generations, although this might be explained by early screening. Among the

seven patients with germline HNF-1alpha mutation in this family, one patient had associated MODY3 diabetes together with LA, four had LA without MODY3 diabetes, and two had neither LA nor MODY 3 diabetes. Although HCAs may appear later, this result could suggest the possibility of an unraveled modifier gene of LA in carriers of HNF-1alpha mutation, as it has been shown in the expression of the MODY3 phenotype(23).

Immunohistochemistry correlated well with molecular biology, as previously shown (7). However, we suggest that molecular biology remains the gold standard, as immunohistochemistry cannot detect exon 7,8 beta-catenin mutations, and only 80% of exon 3 beta-catenin mutations (9). HCAs with sonic hedgehog activation could have a slight LFABP inactivation, but are not steatotic. Hence, they should not be classified as HHCAs in immunohistochemistry, although the LFABP inactivation may be misleading (9,24). Sporadic LA remains a very heterogeneous disease in terms of HCAs subtypes with 10 (29.4%) among 34 patients with sporadic LA that harbored different HCA subtypes in their liver. This heterogeneity was particularly remarkable in patient #10 (table 1), who had concomitant portal cavernoma, consistently with previous observations in vascular liver diseases (25). Beta-catenin mutated HCAs in exon 3 and HCAs with sonic hedhehog activation have been shown to be particularly at risk of malignant transformation and bleeding respectively (2,9). However, in our study, the very few numbers of shHCAs (only two cases) and malignant transformation (only one patient) were not sufficient to draw any conclusion on that specific point.

As in other HCAs, pregnancy remains a situation at risk with the need of a close follow-up. In our series, most patients had pregnancies *before* the diagnosis of LA, without hepatic complications, except for the patient with inaugural hemorrhagic shock during her second pregnancy. Regarding patients who became pregnant after diagnosis of LA, the biggest HCAs were resected before the pregnancy. More data are needed to propose the best management to pregnant women with HCAs. A study is on-going on this specific topic (26)and should bring answers in the future. In this study, most hemorrhages (five out of six) occurred at initial presentation. This very low proportion of hemorrhagic events after diagnosis (2.5%) may be explained by the cessation of oral contraception and the prophylactic resection of biggest lesions, especially before pregnancy.

Taken together, these results plead for a specific management and a close follow-up of patients with LA. It remains difficult to propose guidelines, owing to the heterogeneity of the disease. We may recommend at initial presentation to perform liver function tests, alpha-foeto-protein and glycaemia, together with suggestion of lifestyle interventions (physical activity and weight loss in case of obesity) and cessation of oral contraception. If all HCAs are steatotic, MODY 3 should be searched for together with germline HNF-1α mutation. If all HCAs are *not* steatotic, percutaneous biopsy of the largest or rapidly increasing nodule should be attempted if liver resection is not upfront proposed. In all patients with LA, a close follow-up is mandatory, with physical examination, biology including liver function tests, glycaemia and alpha-foeto-protein and MRI every year or according to the evolution of the disease. Ultrasound should eventually be reserved for patients with stable disease alternately with MRI, and performed by an experienced radiologist.

The rarity of LA and the small number of patients are a major limitation in this study. Although the definition of LA is not fully consensual, we chose the threshold of 10 HCAs, without taking into account micro-adenomas. It is however likely that patients with 8 or 9 HCAs would benefit from the same initial evaluation and surveillance. Also, the characterization of HCAs by immunohistochemistry and molecular biology is difficult due to the multiplicity of the tumors in a same patient, as shown in table 1. Some HCAs were not sent for molecular analysis, or could not be classified because of non-analyzable material.

Conclusion. In a clinical point-of-view, LA justifies a specific management, owing to its heterogeneity and the occurrence of complications dominated by hemorrhage. Germline HNF-1α mutation should be searched in patients with steatotic LA. In case of positivity, a familial screening of the mutation, LA and MODY 3 diabetes should be performed to identify asymptomatic LA in relatives. Interestingly, among our two families of LA, male patients did not show malignant transformation, but had a high risk of bleeding. These observations need to be validated in other familial LA described across the world. Overall, a close follow-up of patients with LA is needed to prevent complications and to plan pregnancies.

References

1. European Association for the Study of the Liver (EASL). EASL Clinical Practice Guidelines on the management of benign liver tumours. J Hepatol 2016;65:386–98.
2. Bioulac-Sage P, Laumonier H, Couchy G, Le Bail B, Sa Cunha A, Rullier A, et al. Hepatocellular adenoma management and phenotypic classification: the Bordeaux experience. Hepatology 2009;50:481–9.
3. Laurent A, Dokmak S, Nault JC, Pruvot FR, Fabre JM, Letoublon C, et al. European experience of 573 liver resections for hepatocellular adenoma: a cross-sectional study by the AFC-HCA-2013 study group. Hpb 2016;18:748–55.
4. Dokmak S, Paradis V, Vilgrain V, Sauvanet A, Farges O, Valla D, et al. A Single-Center Surgical Experience of 122 Patients With Single and Multiple Hepatocellular Adenomas. Gastroenterology 2009;137:1698–705.
5. Farges O, Ferreira N, Dokmak S, Belghiti J, Bedossa P, Paradis V. Changing trends in malignant transformation of hepatocellular adenoma. Gut 2011;60:85–9.
6. Nault JC, Bioulac-Sage P, Zucman-Rossi J. Hepatocellular benign tumors-from molecular classification to personalized clinical care. Gastroenterology 2013;144:888–902.
7. Bioulac-Sage P, Rebouissou S, Thomas C, Blanc J-F, Saric J, Sa Cunha A, et al. Hepatocellular adenoma subtype classification using molecular markers and immunohistochemistry. Hepatology 2007;46:740–8.

8. Rebouissou S, Bioulac-Sage P, Zucman-Rossi J. Molecular pathogenesis of focal nodular hyperplasia and hepatocellular adenoma. J Hepatol 2008;48:163–70.

9. Nault JC, Couchy G, Balabaud C, Morcrette G, Caruso S, Blanc JF, et al. Molecular Classification of Hepatocellular Adenoma Associates With Risk Factors, Bleeding, and Malignant Transformation. Gastroenterology 2017;152:880–94.

10. van Rosmalen B V., Coelen RJS, Bieze M, van Delden OM, Verheij J, Dejong CHC, et al. Systematic review of transarterial embolization for hepatocellular adenomas. Br J Surg 2017;104:823–35.

11. Monges H, Payan H, Legre M, Vignoli R. [Considerations on a case of benign multinodular adenoma of the liver]. Arch Mal Appar Dig Mal Nutr n.d.;52:725–37.

12. Monaco AP, Hallgrimsson J, McDermott W V. Multiple adenoma (hamartoma) of the liver treated by subtotal (90 percent) resection: morphological and functional studies of regeneration. Ann Surg 1964;159:513–9.

13. Flejou JF, Barge J, Menu Y, Degott C, Bismuth H, Potet F, et al. Liver adenomatosis. An entity distinct from liver adenoma? Gastroenterology 1985;89:1132–8.

14. Chiche L, David A, Adam RR, Oliverius MM, Klempnauer JJ, Vibert E, et al. Liver transplantation for adenomatosis: European experience. Liver Transplant 2016;22:516–26.

15. Foster JH, Donohue TA, Berman MM. Familial Liver-Cell Adenomas and Diabetes Mellitus. N Engl J Med 1978;299:239–41.

16. Bacq Y, Jacquemin E, Balabaud C, Jeannot E, Scotto B, Branchereau S, et al.

Familial liver adenomatosis associated with hepatocyte nuclear factor 1alpha inactivation. Gastroenterology 2003;125:1470–5.

17. Jeannot E, Poussin K, Chiche L, Bacq Y, Sturm N, Scoazec JY, et al. Association of CYP1B1 germ line mutations with hepatocyte nuclear factor 1alpha-mutated hepatocellular adenoma. Cancer Res 2007;67:2611–6.

18. von Elm E, Altman DG, Egger M, Pocock SJ, Gøtzsche PC, Vandenbroucke JP. The strengthening the reporting of observational studies in epidemiology (STROBE) statement: Guidelines for reporting observational studies. Int J Surg 2014;12:1495–9.

19. Bluteau O, Jeannot E, Bioulac-Sage P, Marqués JM, Blanc J-F, Bui H, et al. Bi-allelic inactivation of TCF1 in hepatic adenomas. Nat Genet 2002;32:312–5.

20. Jeannot E, Mellottee L, Bioulac-Sage P, Balabaud C, Scoazec JY, Van Nhieu JT, et al. Spectrum of HNF1A somatic mutations in hepatocellular adenoma differs from that in patients with MODY3 and suggests genotoxic damage. Diabetes 2010;59:1836–44.

21. Laumonier H, Bioulac-Sage P, Laurent C, Zucman-Rossi J, Balabaud C, Trillaud H. Hepatocellular adenomas: Magnetic resonance imaging features as a function of molecular pathological classification. Hepatology 2008;48:808–18.

22. Bioulac-Sage P, Sempoux C, Possenti L, Frulio N, Laumonier H, Laurent C, et al. Pathological Diagnosis of Hepatocellular Cellular Adenoma according to the Clinical Context. Int J Hepatol 2013;2013:253261.

23. Kim S-H, Ma X, Klupa T, Powers C, Pezzolesi M, Warram JH, et al. Genetic modifiers of the age at diagnosis of diabetes (MODY3) in carriers of hepatocyte nuclear factor-1alpha mutations map to chromosomes 5p15, 9q22, and 14q24. Diabetes 2003;52:2182–6.

24. Henriet E, Abou Hammoud A, Dupuy J-W, Dartigues B, Ezzoukry Z, Dugot-Senant N, et al. Argininosuccinate synthase 1 (ASS1): A marker of unclassified hepatocellular adenoma and high bleeding risk. Hepatology 2017;66:2016–28.

25. Sempoux C, Paradis V, Komuta M, Wee A, Calderaro J, Balabaud C, et al. Hepatocellular nodules expressing markers of hepatocellular adenomas in Budd-Chiari syndrome and other rare hepatic vascular disorders. J Hepatol 2015;63:1173–80.

26. van Aalten SM, Bröker MEE, Busschbach JJ V, de Koning HJ, de Man RA, Steegers EAP, et al. Pregnancy and liver adenoma management: PALM-study. BMC Gastroenterol 2012;12.

Acknowledgements

The authors would like to thank Franck Bumsel and Jean-Nicolas Pinho for their technical assistance.

The study is dedicated to Z. Benchellal.

Tables

Table 1. Classification of lesions according to immunostaining and molecular biology. Some patients had more than one HCA, and some HCAs were sampled several times. As stated in the methods, patients with inter-tumoral heterogeneity (according to molecular biology and/or immunohistochemistry) were classified as "mixed forms".

Footnote:

F: female, M: male

Molecular analysis was performed only in blood.

beta-cat: beta-catenin mutated HCA identified in immunohistochemistry, b^{ex3}HCA: beta-catenin mutated HCA in exon 3, $b^{ex7,8}$HCA: beta-catenin mutated HCA in exon 7 or 8, b^{ex3}IHCA: beta-catenin mutated inflammatory HCA in exon 3, $b^{ex7,8}$IHCA: beta-catenin mutated inflammatory HCA in exon 7 or 8; HHCA: HNF1alpha mutated HCA, IHCA: inflammatory HCA, shHCA: sonic hedgehog HCA, UHCA: unclassified HCA.

NA: not available

Table 2. Pathomolecular classification of the patients according to the subtype of HCA (n=39 patients).

Footnote: Patient #7 from table 1 could not be classified.

^{ex3}HCA: beta-catenin mutated HCA in exon 3, $b^{ex7,8}$HCA: beta-catenin mutated HCA in exon 7 or 8, b^{ex3}IHCA: beta-catenin mutated inflammatory HCA in exon 3, $b^{ex7,8}$IHCA: beta-catenin mutated inflammatory HCA in exon 7 or 8; HHCA: HNF1alpha mutated HCA, IHCA: inflammatory HCA, shHCA: sonic hedgehog HCA, UHCA: unclassified HCA.

Figures

Figure 1. Family tree of one family with R229X-germline mutation in HNF-1alpha. Square boxes represent men, and circle boxes represent women. The diagonal bar indicates that the individual is deceased. Diagonal hatched boxes represent patients with confirmed LA. Age at diagnosis of LA or testing is indicated in years (y). The presence of diabetes or is indicated below the box.

Part of this family tree has been published by Bacq et al. (16).

Footnote:

* This patient had proven mutation of HNF-1α but less than 10 HCAs at imaging; hence she was not included in the study (as stated in the flowchart in supplementary data).

HCA: Hepatocellular Adenoma, MODY3: maturity onset diabetes on the young type 3

HNF1 α-WT: patients with HNF-1alpha wild type; R229X : patients with germline R229X HNF-1alpha mutation.

Figure 2. Remnant left liver with LA at MRI (A), gross examination after surgery (B), and microscopic examination (C and D). The patient had had a previous right hepatectomy for LA. HCAs in her remnant liver increased in size and the patient received a liver transplant.

Figure 2A is an arterial phase of fat-suppressed dynamic gadolinium-enhanced T1 imaging showing multiple, large, and heterogeneous HCAs with variable enhancement intensity. Pathology showed a malignant transformation in a 55mm

IHCA: macroscopy (2B), and microscopy (2C and 2D). Figure 2C shows hematoxylin and eosin whole section with non-tumoural liver (*), IHCA (**), and hepatocellular carcinoma (***). Figure 2D is a C-reactive protein-positive cytoplasmic staining in IHCA (**) and hepatocellular carcinoma (***).

Figure 3. Hepatic complication-free survival since diagnosis of LA. Hemorrhage and malignant transformation were taken into account. Seven complications occurred, including five at presentation; median was not reached. Subjects at risk are displayed in the table.

Footnote: HCA: hepatocellular adenoma; IHCA: inflammatory HCA; LA: liver adenomatosis; MODY3: maturity onset diabetes on the young type 3; MRI: Magnetic Resonance Imaging

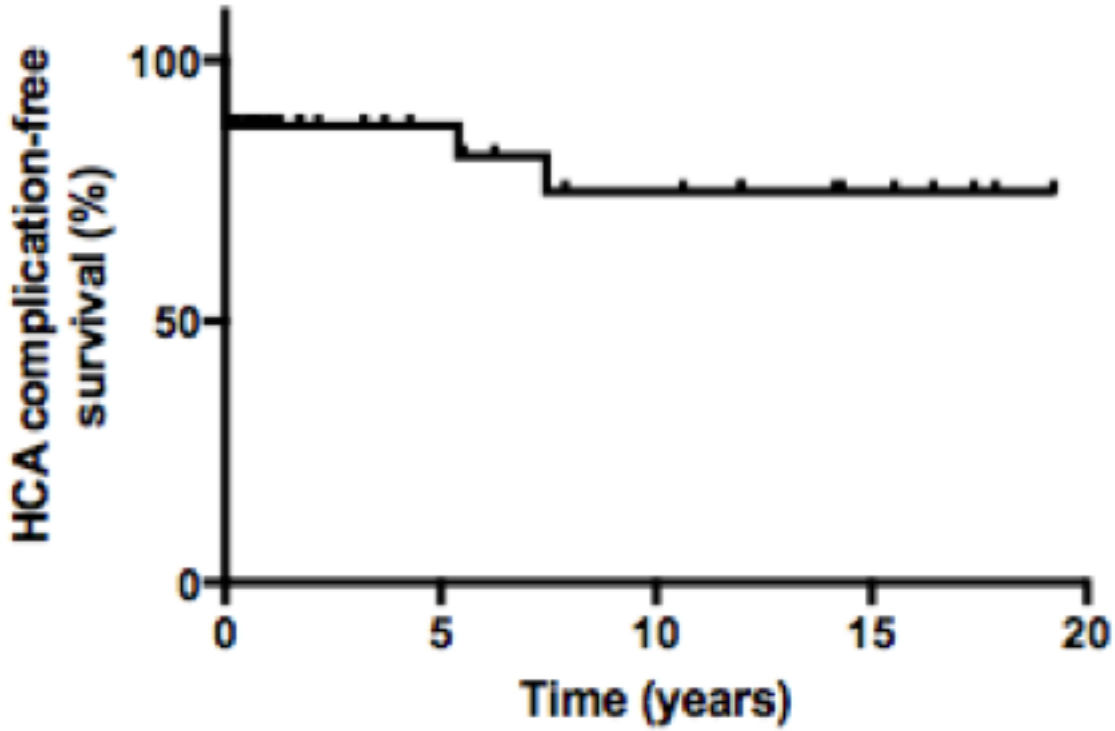

Years	0	5	10	15	20
Number of subjects at risk	40	16	11	6	1

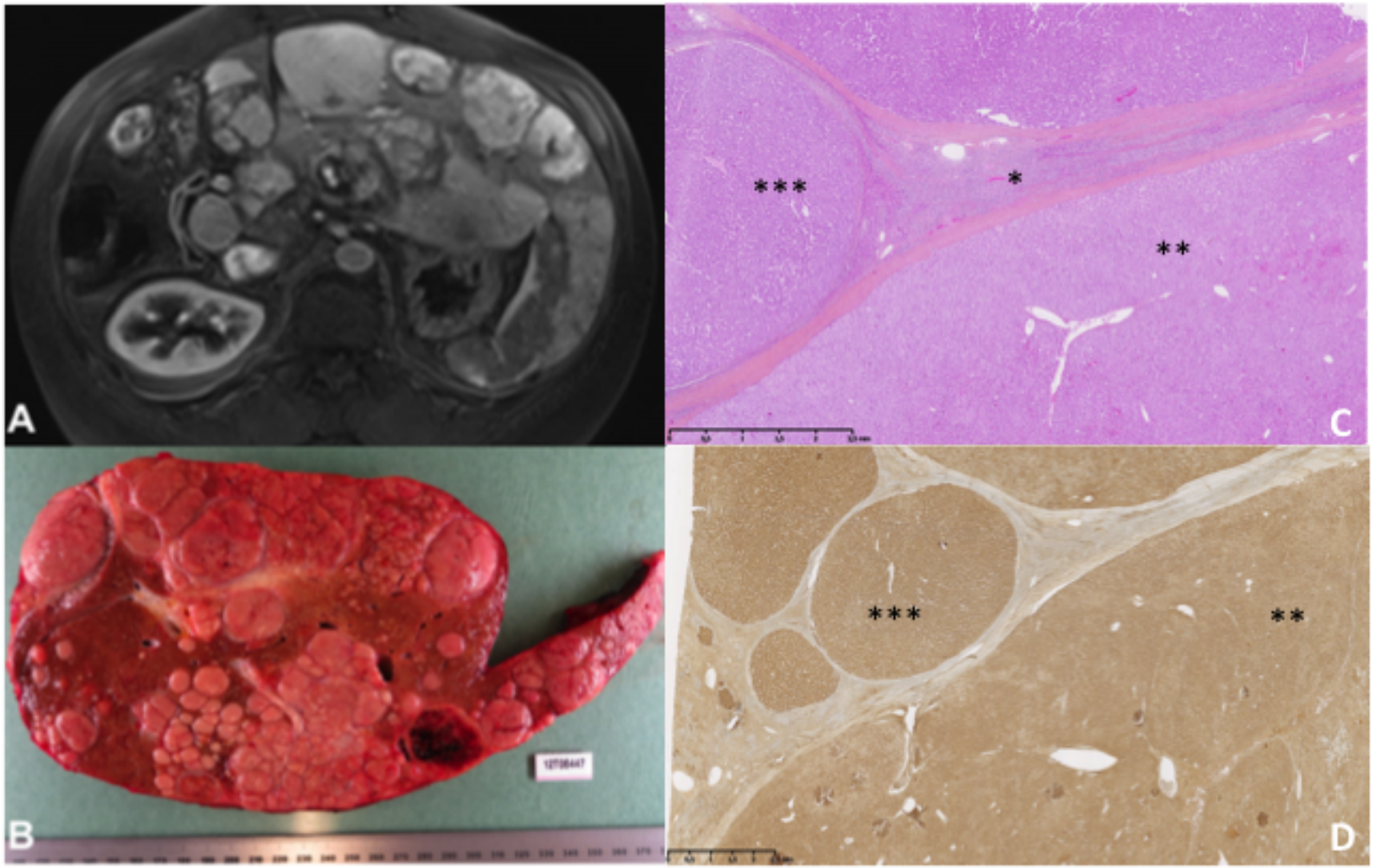
A
B
C
D
***
*
**
***
**

Table 1. Classification of lesions according to immunostaining and molecular biology.

Patient number and gender	Lesion number	Simplified molecular profile of HCA	Subgroup according to immunostaining of HCA	Germline HNF-1 α mutation	Subgroup of the patient*: pathomolecular classification	Complication Remark
1 (F)	1	HHCA	HHCA	No	HHCA	
2 (F)	2	IHCA	IHCA	-	IHCA	
3 (F)	3	*NA*	IHCA	-	$b^{ex7,8}$IHCA	
	4	$b^{ex7,8}$IHCA	IHCA	-		
4 (F)	5	*NA*	HHCA	No	HHCA	
5 (F)	6	*NA*	HHCA	Yes	HHCA	Hemorrhage
6 (M)	7	HHCA	HHCA	Yes	HHCA	Hemorrhage
7 (M)	8	*NA*	Not exploitable	-	Not classified	
8 (F)	9	*NA*	HHCA	Yes	HHCA	
9 (F)	10	*NA*	HHCA	No	HHCA	
10 (F)	11	b^{ex3}HCA	IHCA	-	Mixed form - b^{ex3}HCA - b^{ex3}IHCA - $b^{ex7,8}$HCA - UHCA	Portal vein thrombosis
	12	b^{ex3}HCA	IHCA			
	13	$b^{ex7,8}$HCA	IHCA			
	14	UHCA	IHCA			
	15	b^{ex3}IHCA	IHCA			
	16	UHCA	IHCA			
	17	UHCA	IHCA			
	18	UHCA	IHCA			
11 (F)	19	*NA*	UHCA	-	shHCA	
	20	shHCA	UHCA			
12 (F)	21	*NA*	UHCA	-	UHCA	Hemorrhage
13 (F)	22	IHCA	IHCA	-	IHCA	
14 (F)	23	IHCA	IHCA	-	IHCA	
15 (F)	24	UHCA	Not exploitable	-	UHCA	
	25	UHCA	Not exploitable			
16 (F)	26	HHCA	HHCA	No	HHCA	
17 (F)	27	b^{ex3}HCA	Beta-cat	-	Mixed form - HHCA - b^{ex3}HCA	
	28	*NA*	HHCA	No		
18 (F)	29	*NA*	HHCA	No	HHCA	
19 (F)	30	HHCA	HHCA	-	Mixed form - HHCA - IHCA	Hemorrhage
	31	IHCA	IHCA			
20 (F)	32	$b^{ex7,8}$IHCA	IHCA	-	Mixed form - $b^{ex7,8}$IHCA - IHCA	
	33	IHCA	IHCA			
21 (F)	34	HHCA	HHCA	No	HHCA	
	35	HHCA	HHCA			

	36	HHCA	HHCA			
22 (F)	37	*NA*	UHCA	-	UHCA	
23 (F)	38	$b^{ex7,8}$HCA	UHCA	-	Mixed form - shHCA - $b^{ex7,8}$HCA	
	39	shHCA	UHCA			
24 (F)	40	HHCA	HHCA	No	HHCA	
	41	HHCA	HHCA			
25 (F)	42	HHCA	HHCA	No	HHCA	
	43	HHCA	HHCA			
26 (F)	44	*NA*	HHCA	No	HHCA	
27 (F)	45	*NA*	IHCA	-	IHCA	
	46	*NA*	IHCA			
28 (F)	47	IHCA	IHCA	-	IHCA	Hemorrhage
	48	IHCA	IHCA			
	49	IHCA	IHCA			
	50	*NA*	IHCA			
29 (F)	51	IHCA	IHCA	-	IHCA	Malignant transformation
	52	*NA*	IHCA			
30 (F)	53	HHCA	HHCA	No	HHCA	
	54	HHCA	HHCA			
31 (F)	55	HHCA	HHCA	No	HHCA	
32 (F)	56	IHCA	IHCA	-	IHCA	
33 (F)	57	IHCA	IHCA	-	IHCA	
	58	*NA*	IHCA			
34 (M)	59	HHCA	HHCA	No	HHCA	Hemorrhage
35 (F)	60	HHCA	HHCA	Yes	HHCA	
36 (F)	61	IHCA	IHCA	-	IHCA	
	62	IHCA	IHCA			
37 (F)	63	IHCA	IHCA	-	IHCA	
	64	IHCA	IHCA			
	65	IHCA	IHCA			
	66	IHCA	IHCA			
	67	IHCA	IHCA			
38 (F)	68	IHCA	IHCA	-	IHCA	
39# (M)	-	-	-	Yes	HHCA	
40# (F)	-	-	-	Yes	HHCA	

Some patients had more than one HCA, and some HCAs were sampled several times. As stated in the methods, patients with inter-tumoral heterogeneity (according to molecular biology and/or immunohistochemistry) were classified as “mixed forms”.
F: female, M: male, # Molecular analysis was performed only in blood. beta-cat: beta-catenin mutated HCA identified in immunohistochemistry, bex3HCA: beta-catenin mutated HCA in exon 3, bex7,8HCA: beta-catenin mutated HCA in exon 7 or 8, bex3IHCA: beta-catenin mutated inflammatory HCA in exon 3, bex7,8IHCA: beta-catenin mutated inflammatory HCA in exon 7 or 8; HHCA: HNF1alpha mutated HCA, IHCA: inflammatory HCA, shHCA: sonic hedgehog HCA, UHCA: unclassified HCA. NA: not available

Table 2. Pathomolecular classification of the patients according to the subtype of HCA (n=39 patients).

HCA subtype	**Including**	**N**	**%**
HHCA		18	46.2
IHCA		11	30.7
shHCA		1	2.6
UHCA		3	7.7
Mixed forms		6	15.3
	IHCA+HHCA	1	2.6
	$b^{ex7,8}$HCA + shHCA	1	5.1
	HHCA + b^{ex3}HCA	1	2.6
	IHCA + $b^{ex7,8}$IHCA	2	2.6
	UHCA + b^{ex3}HCA + b^{ex3}IHCA + $b^{ex7,8}$HCA	1	2.6

40 patients with liver adenomatosis

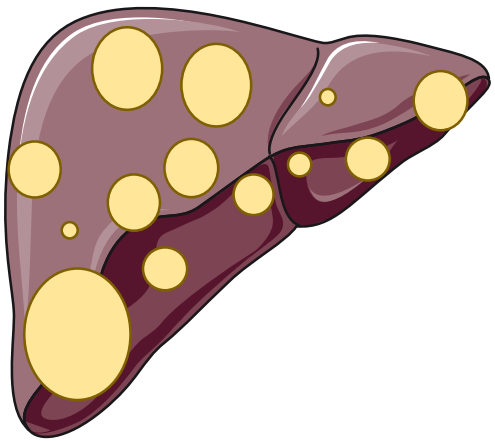

6 patients with familial adenomatosis due to *HNF1A* germline mutations

Median follow-up of 10 years

Malignant transformation
3%

Tumor bleeding
15%
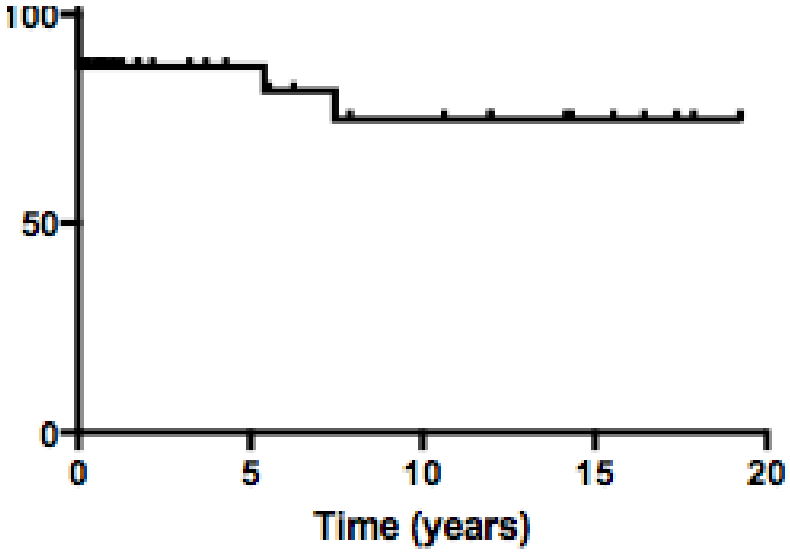
HCA-related complications free survival