



HAL
open science

Sagittal suture craniosynostosis or craniosynostoses? The heterogeneity of the most common premature fusion of the cranial sutures

F. Di Rocco, A. Gleizal, A. Szathmari, P.A. Beuriat, C. Paulus, C. Mottolese

► To cite this version:

F. Di Rocco, A. Gleizal, A. Szathmari, P.A. Beuriat, C. Paulus, et al.. Sagittal suture craniosynostosis or craniosynostoses? The heterogeneity of the most common premature fusion of the cranial sutures. *Neurochirurgie*, 2019, 65, pp.232 - 238. <10.1016/j.neuchi.2019.09.011>. <hal-03488492>

HAL Id: hal-03488492

<https://hal.science/hal-03488492v1>

Submitted on 21 Dec 2021

HAL is a multi-disciplinary open access archive for the deposit and dissemination of scientific research documents, whether they are published or not. The documents may come from teaching and research institutions in France or abroad, or from public or private research centers.

L'archive ouverte pluridisciplinaire **HAL**, est destinée au dépôt et à la diffusion de documents scientifiques de niveau recherche, publiés ou non, émanant des établissements d'enseignement et de recherche français ou étrangers, des laboratoires publics ou privés.



Distributed under a Creative Commons CC BY-NC 4.0 - Attribution - Non-commercial use - International License

Sagittal suture craniosynostosis or craniosynostoses? The heterogeneity of the most common premature fusion of the cranial sutures

F Di Rocco, A Gleizal, A Szathmari, PA Beuriat, C Paulus, C Mottolese

French Referral Center for Craniosynostosis, Lyon, Pediatric Neurosurgery, Hôpital Femme Mère Enfant, Université de Lyon, INSERM 1033, France

ABSTRACT

Background

Scaphocephaly is usually defined as the deformation of the skull resulting from the premature fusion of the sagittal suture. It is the most common type of craniosynostosis, and can be easily recognized on simple clinical examination. Its pathophysiology is easy to understand and to confirm on neuroradiological examination. In contrast, surgical indications are still somewhat controversial, the dispute mainly concerning therapeutic versus esthetic objectives. In recent years, however, several studies have challenged these basic and relatively simplistic interpretations of the pathophysiology of the condition.

Materials and methods

To assess the heterogeneity of scaphocephaly, we reviewed cases of scaphocephaly operated on at the Hôpital Femme Mère Enfant, Lyon University Hospital, France during a 10-year period (2008-2017) and performed a review of the literature on scaphocephaly and sagittal suture closure.

Results

During the 10-year period, 401 children were operated on for a scaphocephaly at the Hôpital Femme Mère Enfant, Lyon University Hospital. Mean age at surgery was 1.14 years, for a median 0.7 years (range, 4 months to 8.5 years). Several subtypes could be distinguished according to morphology, intracranial findings on imaging, patient age, and etiology associated to the sagittal synostosis. Two main surgical techniques were used to correct the malformation, depending on patient age, type of deformation and the surgeon's preference: cranial vault remodeling with occipital pole widening, with the patient in a prone position, and parietal enlargement with or without forehead remodeling, in dorsal decubitus.

Conclusions: The complexity and heterogeneous nature of sagittal synostoses depend on different pathogenic mechanisms leading to and interfering with the skull abnormalities: abnormalities of CSF dynamics, possibly associated with systemic alterations, accounting for the varied postoperative morphological and functional course, in terms of cognitive impairment and late complications (notably intra-cranial pressure elevation). However, the real impact of such heterogeneous clinical presentations on surgical indications and surgical results remains to be elucidated.

Keywords:

Sagittal suture, non-syndromic synostosis, single suture synostosis, craniostenosis, scaphocephaly

Introduction

Scaphocephaly, defined as the deformation of the skull following premature fusion of the sagittal suture, is the most common type of craniosynostosis encountered in clinical practice. It is easily recognized on simple clinical findings of elongated narrowed skull, frequent palpable ridge along the fused sagittal suture, radiologically confirmed by evidence of early closure of the sagittal suture. To re-open the early-fused suture to allow the skull to expand and accommodate the growing brain is the rationale of surgical indication in most cases, with opinions differing as to whether the real goal is cosmetic improvement or to protect the brain from the effects of impaired volumetric growth and altered cerebrospinal fluid (CSF) dynamics. Relatively unpredictable outcomes in terms of morphological correction, cognitive function, immediate or late synostotic recurrence, and late increases in intracranial pressure have been widely reported. These were mainly attributed to poor and/or unduly delayed surgical treatment or inadequate postoperative surveillance rather than to limited knowledge of pathophysiology, limitations in diagnosis, or failure to consider co-existing factors impacting surgical outcome. Consequently, correct management, timing and technical modalities remain the subject of enduring discussion, and no definitive guidelines for management have been established (29). Surprisingly, scant consideration has been paid to the possibility that sagittal craniosynostosis is not a single pathogenic entity: different anatomical and functional abnormalities may be overlooked in traditional diagnosis based merely on clinical semiology and radiological findings, but may make sagittal craniosynostosis a heterogeneous pathology that remains to be elucidated by pediatricians, geneticists, anatomists, neurologists, radiologists and pediatric neurosurgeons.

Patients and methods

To assess the heterogeneity of scaphocephaly, we performed a retrospective analysis of the cases operated on at the Hôpital Femme Mère Enfant, Lyon University Hospital (France) during a 10-year period from 2008 to 2017, and a review of the literature using the databases PubMed and Medline, with “scaphocephaly” and “sagittal suture closure” as keywords. The search was limited to reports published in English between January 2006 and January 2019, and focused on 4 main topics: epidemiology, morphology, genetics, outcome and neurodevelopmental disorders. The references included in the reports were also manually searched to find further references and reported studies not identified on our initial search strategy. Case reports were excluded.

Results

During the 10-year study period, 401 children were operated on for scaphocephaly in our center. Mean age at surgery was 1.14 years, for a median 0.7 years (range, 4 months to 8.5 years). All children underwent preoperative imaging by head CT or brain MRI.

Two main surgical techniques were used to correct the malformation, depending on the age of the patient, the type of deformation and surgeon's preference: cranial vault remodeling with parieto-occipital pole widening, with the patient in prone position, or parietal enlargement with or without forehead remodeling, with the patient in dorsal decubitus.

Several subtypes of scaphocephaly could be distinguished, according to morphology, intracranial imaging findings, patient age, and etiology associated to the sagittal synostosis. Postoperative results were also heterogeneous in terms of cognitive outcome and school performance.

Heterogeneity in morphology

As expected, different morphological subtypes were found, depending on the segment of the sagittal suture mainly involved in the pathological fusion process (Fig 1). While typical dolichocephaly was seen in infants with complete fusion of the sagittal suture, those with partial closure showed all the deformations described in literature, with specific terminology: *leptocephaly*, from premature fusion of the anterior third, resulting in equal narrowing of the head; *bathrocephaly*, from premature fusion of the anterior and middle thirds, with an occipital bulge; *clinocephaly*, from premature fusion of the middle third alone, with a retrocoronal depression; and *sphenocephaly*, which was the most common subtype, resulting from premature fusion of the middle and posterior middle thirds, with characteristic prominence of the bregma and forehead width exceeding the interparietal diameter. These various patterns have been previously described (51) and related to the origin and degree (partial or complete) of the suture fusion. The common frontal and/or occipital bossing associated with sagittal craniosynostosis is now considered as a compensatory phenomenon for restricted lateral growth, and may accentuate the clinical presentation of the deformity. Consequently, the heterogeneous subtypes are not merely related to the pathological suture but also to the pathophysiological processes compensating for the altered intracranial volume. These complex interrelations may obviously also impact surgical outcome, sometimes continuing to exert an effect in case of poor or delayed surgical correction. This also suggests that clinical evaluation based merely on cranial morphology is inadequate, as associated anomalies of the facial skeleton should also be taken into account (Figs 2 and 3).

Class II malocclusion is more common in scaphocephalic children than controls. Differences in nasofrontal angle are also found. However, the skull base is generally unaffected (19, 26, 28, 33).

Heterogeneity in intracranial findings

As expected, CT and MRI showed different morphological patterns in the subarachnoid spaces of infants with sagittal synostosis, ranging from apparently normal to a characteristic pooling of CSF at the frontal poles, often associated with enlargement of the interhemispheric fissure and dilation of the lateral ventricles (Fig.2), which was quite common, being detected up to two-thirds of cases.

Two main mechanisms have been proposed to explain these CSF disorders: passive accumulation of CSF secondary to compensatory morphological increases in forehead volume or, conversely, accumulation secondary to abnormal resorption. According to this second interpretation, the forehead deformation is induced by the focal accumulation of CSF. In favor of this hypothesis, CSF collections seem to occur more often when the bony ridge of the fused suture surrounds the sagittal sinus in a complete or partial groove (so-called Omega sign) than in case of a flat bony interparietal connection (46). Impaired CSF absorption was previously reported in infants with sagittal craniosynostosis, using the subarachnoid injection test (7, 11). Surgical decompression of the sagittal

sinus seems to improve the CSF dynamics, reducing pericerebral CSF collections on postoperative imaging.

Heterogeneity in age

Scaphocephaly can be found at any age. Antenatal diagnosis of scaphocephaly is also, but rarely, possible. During antenatal life, head measurements in scaphocephaly remain within normal limits in most fetuses, although abnormally short biparietal diameter and elongated fronto-occipital distance are observed in some instances. It is only at birth that the deformation and the bony ridge are clearly seen in the great majority of cases. Unlike other types of synostosis, some adults also show malformation, casting further doubt on the necessity for surgical correction if the esthetic blemish is accepted. However, in surgical series, older children tend to be symptomatic. In the present series, for instance, the older children presented a metabolic form of scaphocephaly, with signs and symptoms of chronic intracranial pressure (ICP) elevation.

Heterogeneity in etiology

Despite the large number of papers dealing with scaphocephaly, the actual etiopathogenesis of isolated scaphocephaly remains obscure. In recent years, an increasing number of genes affecting growth of the sagittal suture have been identified. Genes known to be involved in sagittal fusion include FGFR1-3, TWIST 1, RAB23, BMP, EFNB1 and PHEX, confirming the heterogeneity of the condition at a molecular level. (8, 40, 52). Obviously these recent findings could not be used in all of the cases in the present series, as genetic investigation has been performed routinely in children with scaphocephaly only in recent years.

Nevertheless, it emerged that the subgroup of patients with sagittal fusion due to underlying metabolic disease often presented an associated Chiari type 1 malformation.

The metabolic disease is sometimes already known at the diagnosis of craniosynostosis. This was the case, for instance, of one of our patients who was operated on at the age of 8.5 years. In other cases, the synostosis is recognized first, and its characteristics may lead to further diagnostic tests to rule out a metabolic disease. In coming years, systematic genetic screening for gene anomalies is likely to provide early diagnosis of the underlying condition, improving patient identification and management of the patient.

Discussion

Premature fusion of the sagittal suture can be due to a large spectrum of etiologies, although in most cases no clear cause is found. Similarly the consequences for the patient can be extremely heterogeneous. Several subtypes of scaphocephaly can be distinguished according to morphology, intracranial imaging findings, patient age, and the etiology associated with the sagittal synostosis. Postoperative results are also heterogeneous in terms of school performance and cognitive function.

Heterogeneity of consequences

Premature sagittal fusion is classically associated with two types of issues: esthetic blemish; and functional risk of ICP elevation, visual disturbance and neurocognitive sequelae.

- Deformation

There are several morphological subtypes (Fig.1), with different modalities of intracranial volume progression over time. In the first months of life, intracranial volume may remain within normal limits, but older scaphocephalic children have been reported to present increased volume (21, 35, 36). However, according to Seeberger et al., the intracranial volume is lower than in age-matched controls between 3 and 10 months of age, especially in boys (41). These figures show how the natural history of the condition is only partially known and might be more complex than usually thought. As well as these intracranial volumetric modifications, the skull deformity may also impact brain shape (1). The brain in scaphocephalic patients is not only longer than in controls but presents specific deformations, mostly in the occipital lobes, in the thalamus and in the shape of the lateral ventricles. The frontal region undergoes transverse widening. The hindbrain is also affected, with a posterior shift compared to controls.

- Raised intracranial pressure

The spectrum of ICP alterations in scaphocephalic children is extremely wide. ICP was recorded in 142 patients with scaphocephaly at a mean age of 1 year by Arnaud et al. (4), and ranged from 3 to 25 mm Hg. However, systematic ICP monitoring is seldom used nowadays. ICP elevation is usually diagnosed clinically, possibly with indirect radiological signs (Fig.3).

- Visual Function

Compared to other single suture synostoses, visual impairment is rare in scaphocephaly. Nevertheless, behavioral changes are common, affecting the ability to fix and follow, with distorted fixation shift in more than 70% of cases (39). In case of scaphocephaly with raised ICP, decreased visual activity and papilledema on fundoscopy can be observed. Prevalence of papilledema has been estimated at around 10% (17).

- Neurocognitive development

Full-scale IQ of patients with sagittal synostosis is usually within normal limits (44). Interestingly, some studies reported an increasing number of children with upper average or high full-scale IQ in isolated sagittal synostosis (5, 43).

However, other studies found that children with untreated scaphocephaly may have poorer performance than controls, while still within the normal range. In particular, infants may show motor

and/or mental development within the normal range but, when tested, the distribution of the scores is lower than expected (10).

According to some authors, children with scaphocephaly run a significantly higher risk of poor neurobehavioral outcome. In particular, the incidence of learning disabilities in children with scaphocephaly is relatively high (30, 45). Magge et al. reported that 50% of children with non-syndromic sagittal suture synostosis had reading and/or learning disabilities when tested between 6 and 16 years of age, despite falling within the normal range for intelligence (30).

Other authors found significantly poorer gross locomotor function than in normal controls (6) associated with discrepancies in IQ results, with verbal IQ significantly better than performance IQ (5). In another study, children operated on for sagittal synostosis showed a significantly higher perceptual reasoning IQ, but also significantly lower working-memory and processing-speed IQs than normal (24).

IQ correlated with ICP according to Arnaud et al., who found that mental outcome was poorer in children with high ICP (4) (16% vs 6% mental retardation; but $p=0.17$); although non-significant, the authors considered this to show an important trend. The association between ICP and IQ or DQ, however, has been questioned by other authors (18).

Several pathophysiological factors, alone or in combination, have been suggested to explain cognitive alterations associated with premature loss of the sagittal suture:

1. elevated ICP (38);
2. cerebral distortion secondary to abnormal skull shape (45);
3. primary brain malformation resulting in synostosis and neurodevelopmental difficulties (37, 45);
4. venous sinus compression and altered outflow (31, 46).

Heterogeneity in surgical procedures, with heterogeneous results

Two main goals for surgical treatment of sagittal synostosis are: 1) to prevent any functional cerebral damage (or to cure, in case of papilledema or raised ICP); and 2) to correct the esthetic blemish. These goals can be achieved by i) increasing skull volume in the affected regions, ii) reorienting the abnormal growth vectors, iii) restoring CSF dynamics, and iv) improving the esthetic aspect. Several surgical techniques have been described, but not all fulfill all these objectives.

Despite several decades of research, no single “gold standard” surgical procedure has shown superiority in the management of children with scaphocephaly (29).

Several types of procedure were proposed, named for the design of the osteotomies: Pi procedure, T Procedure, Y procedure, and also reverse Pi, reverse T, reverse Y and double Pi, double T, double H, anterior circle, double rectangle – going progressively to more and more extensive procedures such as whole cranial vault remodeling and expanding cranioplasty, aiming to achieve long-term correction of the deformity (14, 15, 22, 25, 32). However, in recent years, different centers have proposed different techniques to reduce the morbidity of surgical correction of scaphocephaly, by

using multiple small skin incisions (12), endoscopy (23) or different types of hardware (mainly springs or internal distractors) (2, 27, 48). Thus, the several surgical techniques nowadays available can be divided into two main categories: linear craniectomy with or without hardware (intraosseous springs or distractors, or postoperative helmet), and wide active reconstruction of the vault.

The advantages and limitations of the different techniques have been analyzed by the respective authors, mostly on surgical criteria (estimated blood loss, transfusion rates, duration of surgery and of hospital stay); long-term results were rarely reported, and limited to progression of the cranial index, which is in any case only a very partial indicator of skull morphology. Thus, despite a relatively large number of series, data to draw definitive conclusions on the efficacy of the various techniques are still lacking.

The actual impact of the surgical procedure on long-term functional outcome is still unknown, although these surgeries have been performed for several decades. Analyses in the literature are contradictory. Many of the existing studies on sagittal synostosis show major limitations, preventing any real conclusion being drawn. Studies often compared different types of population, different degrees of severity, different ages (at time of surgery or at the time of the outcome analysis), and different surgical techniques. All of these factors, and especially age at surgery, type of surgery, anesthesia technique and operative time, are liable to influence overall outcome (20).

Bearing these limitations in mind, however, most studies agree that children with sagittal synostosis may present long-term functional sequelae, mostly affecting language. Language impairment was reported by Virtanen et al. in 18 school-age children operated on by strip craniectomy before 30 weeks of age (49). Speech and/or language impairment was also found by Shipster et al., in 28 out of 76 children (43).

Conversely, preoperative gross locomotor function deficits tend to resolve after surgery, and the improvement continues with time (6).

Age at surgery plays a role. Several studies showed that functional results were better in children operated on in the first year or even first semester of life, compared to those operated on later (43). However, these results might be biased by the very reasons for late surgical correction: poor health status, or late referral. Not uncommonly, children are referred after a late diagnosis of sagittal suture closure following brain imaging performed for pre-existing functional problems.

Hashim and colleagues compared the long-term neuropsychological outcome in children operated on for sagittal synostosis, according to age at surgery and to type of procedure (extended strip craniectomy versus whole vault cranioplasty). Seventy patients, aged 5.75 to 24.42 years (mean, 10.04 years) underwent neuropsychological testing. The worst outcomes were in patients who had undergone surgery at ages older than 12 months. In the group of children operated before 6 months of age, extended strip craniectomy was associated with poorer performance than whole vault cranioplasty on full-scale IQ, verbal IQ, word reading and reading comprehension, suggesting that the type of procedure has a major impact on outcome (20).

As several studies reported that functional results differed according to type of surgery and age at surgery, it may be accepted that surgical correction of craniosynostosis has functional impact and not only esthetic impact.

Esthetically, results are also relatively heterogeneous according to degree of initial deformation, age at surgery and technique used. Usually, surgery is more likely to correct the transverse than the anteroposterior diameter (9). However, cranial index is generally improved.

Though cosmetic results are usually based on subjective scoring and should be considered with due caution, most series overall cosmetic results were excellent or good. Nevertheless, a minority of patients show poor results, and a second procedure may be needed.

Surgical technique plays a role in morphological outcome. Comparing extended strip craniectomy to subtotal calvarectomy, Panchal et al. found significantly greater improvement in cranial index 1 year after subtotal calvarectomy. However, long-term comparisons are needed for any conclusion to be drawn on the efficacy of the different techniques (34).

Heterogeneity in recurrence

Independently of surgical technique, one of the main reasons for poor long-term results is the inherent risk of recurrence. In a series of 79 children undergoing early extended strip craniectomy reported by van Veelen et al., 4 patients had to be reoperated on because of raised ICP (47). In Collmann et al.'s experience of 181 children operated on for scaphocephaly, 11 needed a second surgery for recurrence, and in 6 of these cases raised ICP was detected during follow-up. Notably, some of these patients were diagnosed with a syndromic form at the time of recurrence. This observation highlights, on the one hand the fact that an underlying syndrome may be missed when the child is very young, and on the other hand that there is also a risk of raised intracranial pressure and papilledema in surgically treated isolated sagittal synostosis (9).

Other studies confirmed this risk of secondary raised ICP, showing that secondary synostosis of previously patent sutures may occur. Postoperative loss of the coronal sutures is observed in 10% of children after craniectomy not involving the coronal sutures, with 1% of children without any overt underlying syndrome requiring surgical decompression overall (3). Loss of coronal sutures and lambdoid sutures is also extremely common after whole vault cranioplasty (40% and 75%, respectively in Seruya et al.'s report (42)). However, secondary loss of the coronal sutures can also be seen in non-operated scaphocephalic children (3).

Conclusion

Scaphocephaly is the commonest form of synostosis (13, 16), but etiology, natural history and optimal management remain unknown. Prolonged follow-up is essential after scaphocephaly correction for several reasons. Functionally, at school age the child might experience learning difficulties requiring specific management. Secondly, depending on surgical technique and age at surgery, skull re-ossification may be incomplete, leaving large bone defects requiring corrective surgery. Thirdly, raised intracranial pressure may occur despite early treatment. The risk of further rises in ICP during follow-up increases if other sutures, and especially the coronal sutures, close (3,

50). Further studies are needed to better define sagittal synostosis and its variants, the underlying pathophysiology and optimal treatment.

References

1. Aldridge K, Kane AA, Marsh JL, Yan P, Govier D, Richtsmeier JT. Relationship of brain and skull in pre- and postoperative sagittal synostosis. *J Anat.* 2005 Apr;206(4):373-85.
2. Arko L, Swanson JW, Fierst TM, Henn RE, Chang D, Storm PB, Bartlett SP, Taylor JA, Heuer GG Spring mediated sagittal craniosynostosis treatment *Neurosurg Focus* 2015 38(5)E7
3. Arnaud E, Capon-Degardin N, Michienzi J, Di Rocco F, Renier D. Scaphocephaly part II: Secondary coronal synostosis after scaphocephalic surgical correction. *J Craniofac Surg.* 2009 Sep;20 Suppl 2:1843-50.
4. Arnaud E, Renier D, Marchac D Prognosis for mental function in scaphocephaly. *J Neurosurg.* 1995 Sep;83(3):476-9.
5. Bellew M, Chumas P. Long-term developmental follow-up in children with nonsyndromic craniosynostosis. *J Neurosurg Pediatr.* 2015 Oct;16(4):445-51
6. Bellew M, Liddington M, Chumas P, Russell J. Preoperative and postoperative developmental attainment in patients with sagittal synostosis: 5-year follow-up. *J Neurosurg Pediatr.* 2011 Feb;7(2):121-6
7. Caldarelli M, Di Rocco C, Rossi GF Lumbar subarachnoid infusion test in pediatric neurosurgery, *Dev Med Child Neurol* 21: 71-82, 1979
8. Chauhan BK, Hoover JM, Scanga H, Medsinge A, Arnold GL, Nischal KK. Isolated sagittal synostosis in a boy with craniofrontonasal dysplasia and a novel EFNB1 mutation *Plast Reconstr Surg Glob Open* 2015 3(6) e427
9. Collmann H, Solomon BD, Schweitzer T, Kress W, Muenke M: Nonsyndromic craniosynostoses in *Craniosynostoses: molecular genetics, principles of diagnosis and treatment* Muenke M, Kress W, Collmann H Solomon BD Eds Monogr Hum Genet Basel Karger 2011 vol 19 165-176
10. Da Costa AC, Anderson VA, Savarirayan R, Wrennall JA, Chong DK, Holmes AD, Greensmith AL, Meara JG Neurodevelopmental functioning of infants with untreated single-suture craniosynostosis during early infancy. *Childs Nerv Syst.* 2012 Jun;28(6):869-77
11. Di Rocco C, M Caldarelli, A Mangiola, A Milani The lumbar infusion test in infants, *Child's Nerv System* 4:16-21, 1988
12. Di Rocco C. How to decrease the impact of surgical scar in the correction of sagittal synostosis. *Childs Nerv Syst.* 2003 Jan;19(1):42-5
13. Di Rocco F, Arnaud E, Renier D. Evolution in the frequency of nonsyndromic craniosynostosis. *J Neurosurg Pediatr.* 2009 Jul;4(1):21-5.
14. Di Rocco F, Ben Gbulie U, Meyer P, Arnaud E. Current techniques and protocols in the surgical management of scaphocephaly in young infants. *J Craniofac Surg.* 2014 Jan;25(1):39-41.
15. Di Rocco F, Knoll BI, Arnaud E, Blanot S, Meyer P, Cuttarree H, Sainte-Rose C, Marchac D. Scaphocephaly correction with retrocoronal and prelamdboid craniotomies (Renier's "H" technique). *Childs Nerv Syst.* 2012 Sep;28(9):1327-32.
16. Di Rocco F, Arnaud E, Meyer P, Sainte-Rose C, Renier D. Focus session on the changing "epidemiology" of craniosynostosis (comparing two quinquennia: 1985-1989 and 2003-2007) and its impact on the daily clinical practice: a review from Necker Enfants Malades. *Childs Nerv Syst.* 2009 Jul;25(7):807-11.

17. Florisson JM, van Veelen ML, Bannink N, van Adrichem LN, van der Meulen JJ, Bartels MC, Mathijssen IM. Papilledema in isolated single-suture craniosynostosis: prevalence and predictive factors. *J Craniofac Surg.* 2010 Jan;21(1):20-4
18. Gewalli F, Guimarães-Ferreira JP, Sahlin P, Emanuelsson I, Horneman G, Stephensen H, Lauritzen CG. Mental development after modified pi procedure: dynamic cranioplasty for sagittal synostosis. *Ann Plast Surg.* 2001 Apr;46(4):415-20.
19. Guimarães-Ferreira J, Gewalli F, David L, Darvann TA, Hermann NV, Kreiborg S, Friede H, Lauritzen CG. Sagittal synostosis: I. Preoperative morphology of the skull. *Scand J Plast Reconstr Surg Hand Surg.* 2006;40(4):193-9
20. Hashim PW, Patel A, Yang JF, Travieso R, Terner J, Losee JE, Pollack I, Jane J Sr, Jane J Jr, Kanev P, Mayes L, Duncan C, Bridgett DJ, Persing JA. The effects of whole-vault cranioplasty versus strip craniectomy on long-term neuropsychological outcomes in sagittal craniosynostosis. *Plast Reconstr Surg.* 2014 Sep;134(3):491-501.
21. Heller JB, Heller MM, Knoll B. Intracranial volume and cephalic index outcome. *Plast Reconstr Surg.* 2008 Jan;121(1):187-95.
22. Jane JA, Francel PC The evolution of treatment for sagittal synostosis : a personal record in *Craniofacial anomalies : Growth and development from a surgical perspective* JT Goodrich and CD Hall Eds Thieme New York 1995
23. Jimenez DF, Barone CM, Rogers JN Endoscopic wide vertex craniectomy in *Controversies in Pediatric Neurosurgery* GI Jallo, KF Kothbauer, G Pradilla Eds Thieme NY, 2010
24. Kljajić M, Maltese G, Tarnow P, Sand P, Kölby L. The Cognitive Profile of Children with Nonsyndromic Craniosynostosis. *Plast Reconstr Surg.* 2019 May;143(5):1037e-1052e
25. Kiehna EN, Jane JA Early strip craniectomy in *Controversies in Pediatric Neurosurgery* GI Jallo, KF Kothbauer, G Pradilla Eds Thieme NY, 2010
26. Kolar JC, Salter EM, Weinberg SM. Preoperative craniofacial dysmorphology in isolated sagittal synostosis: a comprehensive anthropometric evaluation. *J Craniofac Surg.* 2010 Sep;21(5):1404-10
27. Lauritzen CG, Davis C, Ivarsson A, Sanger C, Hewitt TD. The evolving role of springs in craniofacial surgery: the first 100 clinical cases. *Plast Reconstr Surg.* 2008 Feb;121(2):545-54.
28. Lehuis A, Bortoluzzi P, Huynh N, Bach N Occlusal relations in patients with scaphocephaly *J Craniofac Surg* 2015 26(6) 1893-9
29. Lee BS, Hwang LS, Doumit GD, Wooley J, Papay FA, Luciano MG, Recinos VM Management options of non-syndromic sagittal craniosynostosis *J Clin Neuroscience* 2017, May 39, 28-34
30. Magge, SN, Westerveld M, Pruzinsky T Persing JA. Long-term neuropsychological effects of sagittal craniosynostosis on child development *J Craniofac Surg.* 2002 Jan;13(1):99-104.
31. Massimi, L, Caldarelli M, Tamburrini, G, Paternoster G, Di Rocco C Isolated sagittal synostosis : definition, classification and surgical indications *Child's Nerv Syst* 2012 Sep;28(9):1311-7
32. Mori K, Sakamoto T, Nakai K The surgical management of scaphocephaly in *Craniofacial anomalies : Growth and development from a surgical perspective* JT Goodrich and CD Hall Eds Thieme New York 1995
33. Nicolini F, Arnaud A, Usami K, Vecchione A, Brunelle F, Di Rocco F Impact of extra-axial cerebrospinal fluid collection in frontal morphology after surgical treatment of scaphocephaly *Surg Neurol Int.* 2018 Oct 30;9:215.

34. Panchal J, Marsh JL, Park TS, Kaufman B, Pilgram T, Huang SH. Sagittal craniosynostosis outcome assessment for two methods and timings of intervention. *Plast Reconstr Surg.* 1999 May;103(6):1574-84.
35. Posnick JC, Armstrong D, Bite U. Metopic and sagittal synostosis: intracranial volume measurements prior to and after cranio-orbital reshaping in childhood. *Plast Reconstr Surg.* 1995 Aug;96(2):299-309; discussion 310-5.
36. Posnick JC, Lin KY, Chen P, Armstrong D. Sagittal synostosis: quantitative assessment of presenting deformity and surgical results based on CT scans. *Plast Reconstr Surg.* 1993 Nov;92(6):1015-24
37. Raybaud C, Di Rocco C Brain malformation in syndromic craniosynostoses, a primary disorder of white matter: a review. *Childs Nerv Syst.* 2007 Dec;23(12):1379-88
38. Renier D, Sainte-Rose C, Marchac D, Hirsch JF Intracranial pressure in craniostenosis. *J Neurosurg.* 1982 Sep;57(3):370-7.
39. Ricci D, Vasco G, Baranello G, Salerni A, Amante R, Tamburrini G, Dickmann A, Di Rocco C, Velardi F, Mercuri E. Visual function in infants with non-syndromic craniosynostosis. *Dev Med Child Neurol.* 2007 Aug;49(8):574-6.
40. Rothenbuhler A, Fadel N, Debza Y, Bacchetta J, Diallo MT, Adamsbaum C, Linglart A, Di Rocco F. High incidence of cranial synostosis and Chiari I malformation in children with X-linked hypophosphatemic rickets (XLHR). *J Bone Miner Res.* 2018 Oct 23
41. Seeberger R, Hoffmann J, Freudlsperger C, Berger M, Bodem J, Horn D, Engel M. Intracranial volume in isolated sagittal synostosis measured by 3D photocephalometry *J Craniomaxillofac Surg* 2016 44(5) 626-631
42. Seruya M, Tan SY, Wray AC, Penington AJ, Greensmith AL, Holmes AD, Chong DK Total cranial vault remodeling for isolated sagittal synostosis: part I. Postoperative cranial suture patency. *Plast Reconstr Surg.* 2013 Oct;132(4):602e-610e.
43. Shipster C, Hearst D, Somerville A, Stackhouse J, Hayward R, Wade A. Speech, language, and cognitive development in children with isolated sagittal synostosis. *Dev Med Child Neurol.* 2003 Jan;45(1):34-43.
44. Speltz ML, Collett BR, Wallace ER, Starr JR, Craddock MM, Buono L, Cunningham M, Kapp-Simon K Intellectual and academic functioning of school-age children with single-suture craniosynostosis. *Pediatrics* 2015 Mar;135(3):e615-23
45. Speltz ML, Kapp-Simon KA, Cunningham M, Marsh J, Dawson G. Single-suture craniosynostosis: a review of neurobehavioral research and theory. *J Pediatr Psychol.* 2004 Dec;29(8):651-68
46. Usami K, Nicolini F, Arnaud E, Di Rocco F. Cerebrospinal fluid collections in sagittal suture synostosis. *Childs Nerv Syst.* 2016 Mar;32(3):519-25
47. Van Veelen ML, Eelkman Rooda OH, de Jong T, Dammers R, van Adrichem LN, Mathijssen IM. Results of early surgery for sagittal suture synostosis: long-term follow-up and the occurrence of raised intracranial pressure. *Childs Nerv Syst.* 2013 Jun;29(6):997-1005
48. Van Veelen ML, Mathijssen IM Spring-assisted correction of sagittal suture synostosis *Child's Nerv Syst* 2012 28(9) 1347-51
49. Virtanen R, Korhonen T, Fagerholm J, Viljanto J. Neurocognitive sequelae of scaphocephaly *Pediatrics* 1999 103(4):791-5

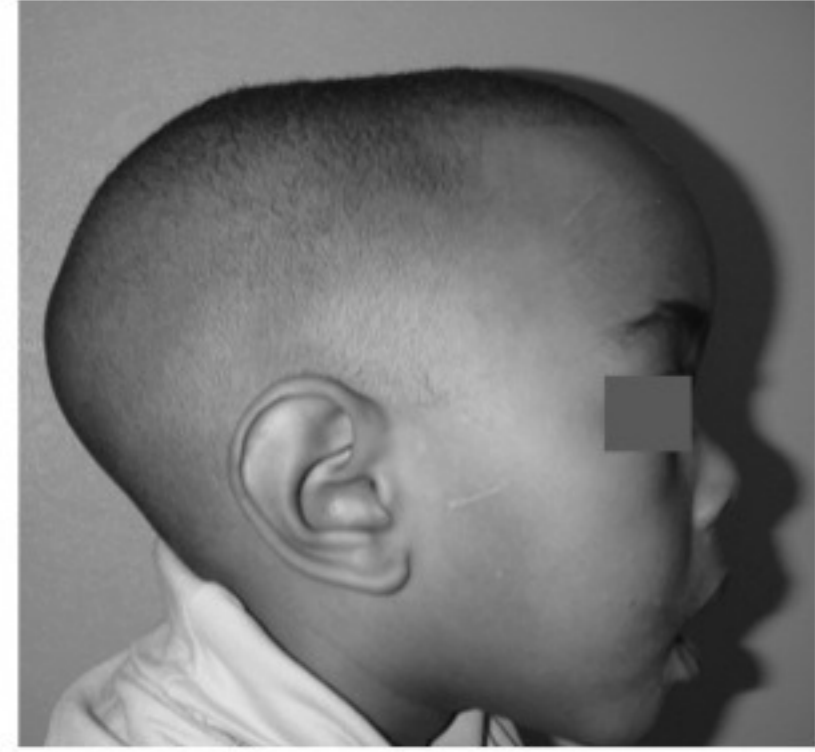
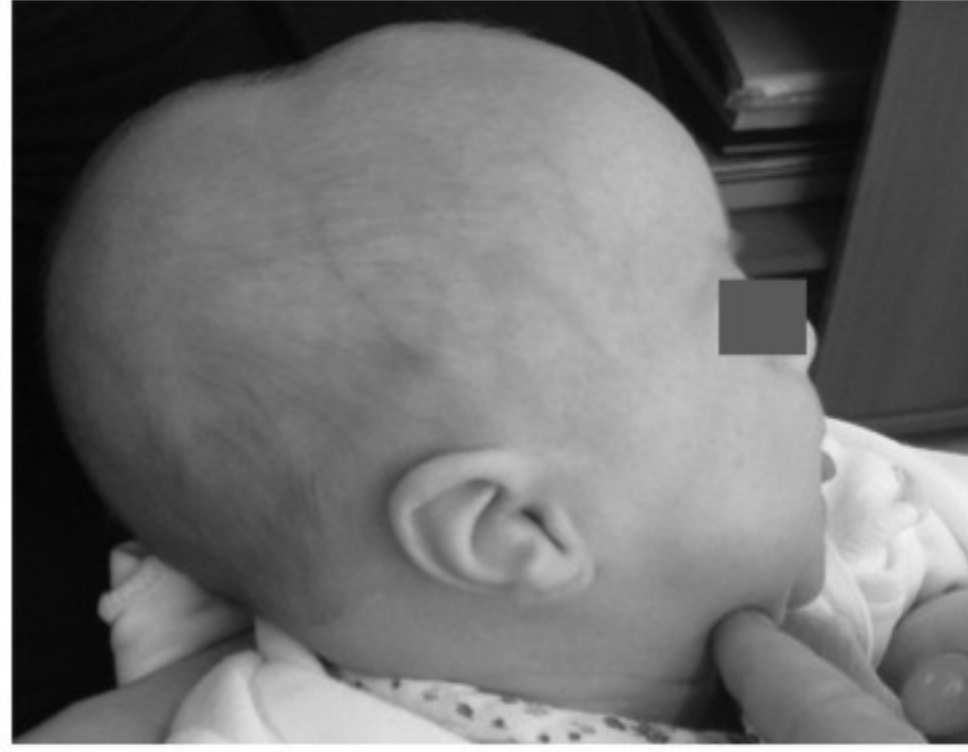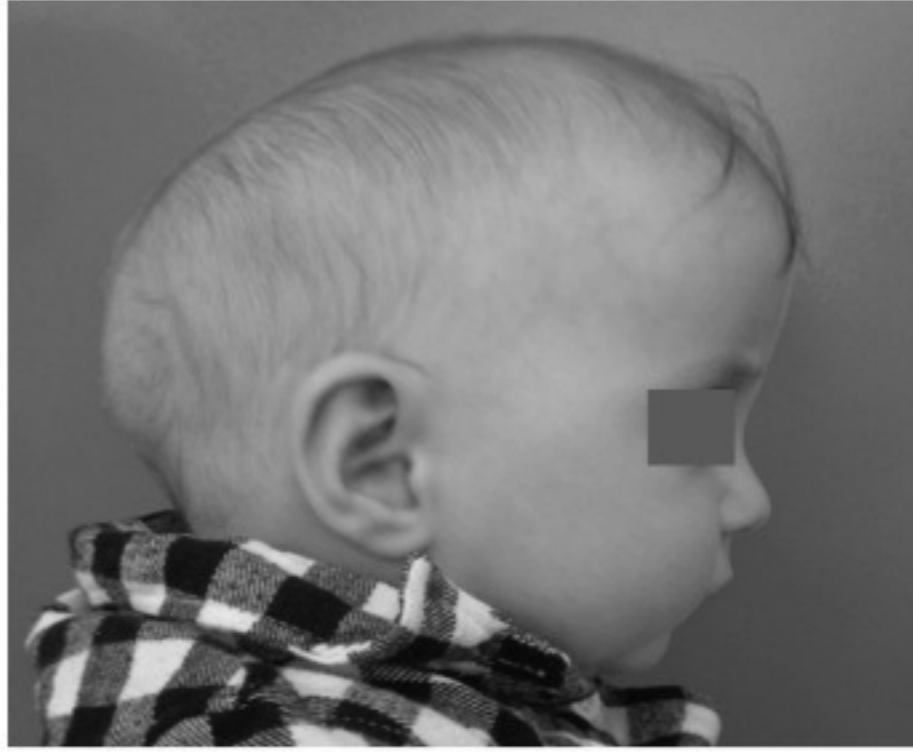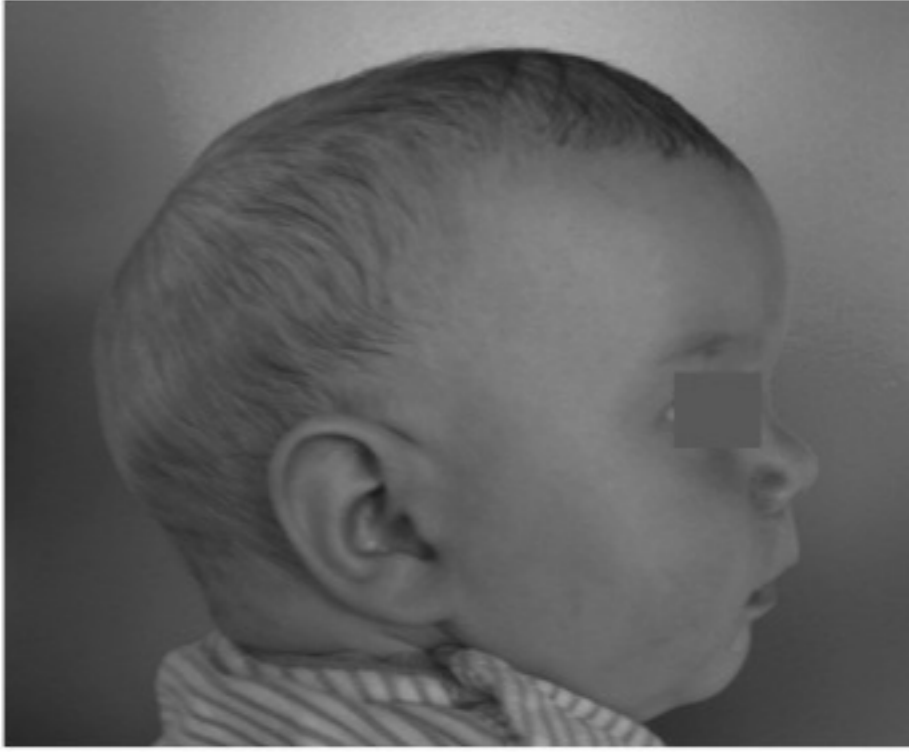50. Yarbrough CK, Smyth MD, Holekamp TF, Ranalli NJ, Huang AH, Patel KB, Kane AA, Woo AS. Delayed synostoses of uninvolved sutures after surgical treatment of nonsyndromic craniosynostosis. *J Craniofac Surg*. 2014 Jan;25(1):119-23
51. Heuzé Y, Boyadjiev SA, Marsh JL, Kane AA, Cherkez E, Boggan JE, Richtsmeier JT. New insights into the relationship between suture closure and craniofacial dysmorphology in sagittal nonsyndromic craniosynostosis. *J Anat*. 2010 Aug;217(2):85-96
52. Ye X, Guilmatre A, Reva B, Peter I, Heuzé Y, Richtsmeier JT, Fox DJ, Goedken RJ, Jabs EW, Romitti PA. Mutation screening of candidate genes in patients with non syndromic sagittal synostosis *Plast Reconstr Surg* 2016 137 (3) 952-61

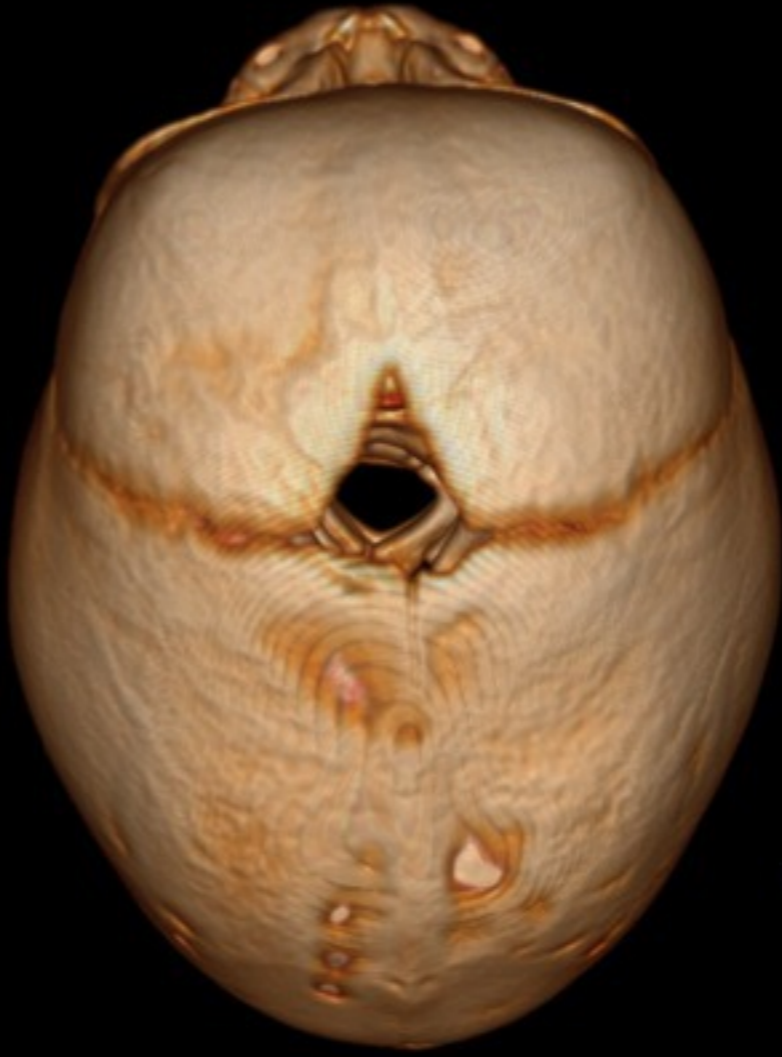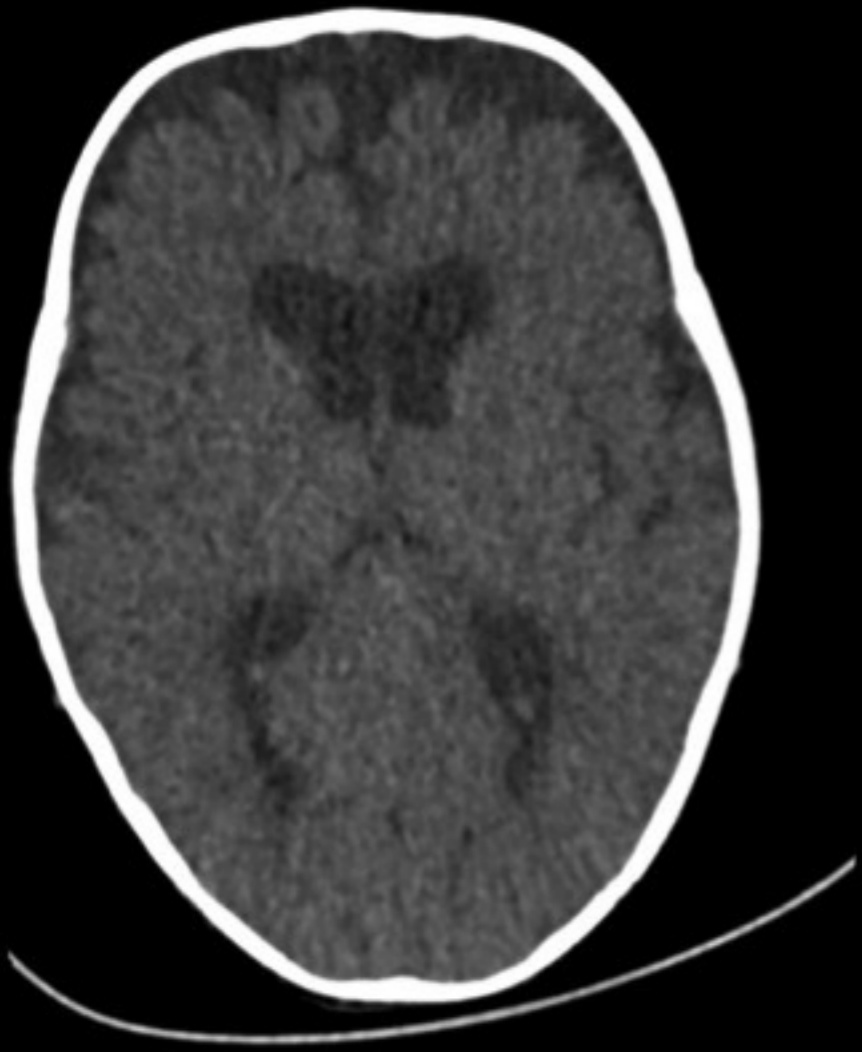
LEGENDS FOR FIGURES

Fig. 1. Morphological appearance of children with isolated loss of the sagittal suture. Note heterogeneity of shapes.

Fig.2 Axial CT scans and 3D reconstructions in a 6-month-old (top) and 9-month-old boy (bottom) with scaphocephaly. Note heterogeneity in the morphology of the skull and CSF spaces.

Fig 3. 3D CT of the skull and brain MRI of a 7-year-old girl with clinical signs and symptoms of raised ICP and papilledema on fundoscopy. Note the digitiform impressions and the descent of cerebellar tonsils on sagittal MRI.





10



