



HAL
open science

The growth of the posterior cranial fossa in FGFR2-induced faciocraniosynostosis: A review

G. Coll, F. Abed Rabbo, V. Jecko, L. Sakka, F. Di Rocco, M. Delion

► To cite this version:

G. Coll, F. Abed Rabbo, V. Jecko, L. Sakka, F. Di Rocco, et al.. The growth of the posterior cranial fossa in FGFR2-induced faciocraniosynostosis: A review. *Neurochirurgie*, 2019, 65, pp.221 - 227. 10.1016/j.neuchi.2019.09.005 . hal-03488488

HAL Id: hal-03488488

<https://hal.science/hal-03488488>

Submitted on 21 Dec 2021

HAL is a multi-disciplinary open access archive for the deposit and dissemination of scientific research documents, whether they are published or not. The documents may come from teaching and research institutions in France or abroad, or from public or private research centers.

L'archive ouverte pluridisciplinaire **HAL**, est destinée au dépôt et à la diffusion de documents scientifiques de niveau recherche, publiés ou non, émanant des établissements d'enseignement et de recherche français ou étrangers, des laboratoires publics ou privés.



Distributed under a Creative Commons Attribution - NonCommercial 4.0 International License

The growth of the posterior cranial fossa in FGFR2-induced faciocraniosynostosis: a review

La croissance de la fosse postérieure dans les faciocraniosténoses FGFR-2 induites : une revue

Guillaume Coll^{1,2}, Francis Abed Rabbo¹, Vincent Jecko³, Laurent Sakka^{1,4}, Federico Di Rocco^{5,6}, Matthieu Delion⁷

¹. *Service de Neurochirurgie, CHU Clermont-Ferrand, Clermont-Ferrand, F-63000, France*

². *Université Clermont Auvergne, CNRS, SIGMA Clermont, Institut Pascal, Clermont-Ferrand, F-63000, France.*

³. *Service de Neurochirurgie, CHU Bordeaux, Bordeaux, France*

⁴. *Laboratoire d'Anatomie et d'Organogenèse, Laboratoire de Biophysique Sensorielle, NeuroDol, Faculté de Médecine, Université Clermont Auvergne, F-63000 Clermont-Ferrand, France*

⁵. *Service de Neurochirurgie Pédiatrique, Hôpital Femme Mère Enfant, Lyon, France*

⁶. *Université Claude Bernard, INSERM 1033, Lyon, France*

⁷. *Service de Neurochirurgie, CHU Anger, Anger, France*

Correspondence : Dr Guillaume Coll
Service de Neurochirurgie,
Hôpital Gabriel-Montpied, C.H.U., B.P. 69,
58 Rue Montalembert
63003 Clermont-Ferrand, France.
Tel: +33.4.73.75.21.04
Fax: +33.4.73.75.21.90
e-mail: gcoll@chu-clermontferrand.fr

Disclosure of funding: The authors have no personal financial or institutional interest in any of the drugs, materials, or devices described in this article.

ABSTRACT

Background: The growth of the posterior fossa in syndromic craniostenosis was studied in many papers. However, few studies described the pathophysiological growth mechanisms in non-operated infants with fibroblast growth factor receptor (FGFR) type 2 mutation (Crouzon, Apert or Pfeiffer syndrome), although these are essential to understanding cranial vault expansion and hydrocephalus treatment in these syndromes.

Objective: A review of the medical literature was performed, to understand the physiological and pathological growth mechanisms of the posterior fossa in normal infants and infants with craniostenosis related to FGFR2 mutation.

Discussion: Of the various techniques for measuring posterior fossa volume, direct slice-by-slice contouring is the most precise and sensitive. Posterior fossa growth follows a bi-phasic pattern due to opening of the petro-occipital, occipito-mastoidal and sphenoccipital sutures. Some studies reported smaller posterior fossae in syndromic craniostenosis, whereas direct contouring studies reported no difference between normal and craniostenotic patients. In Crouzon syndrome, synchondrosis fusion occurs earlier than in normal subjects, and follows a precise pattern. This premature fusion in Crouzon syndrome leads to a stenotic foramen magnum and facial retrusion.

Keywords: Complex craniosynostosis, Posterior fossa, Growth, Skull-base synchondrosis, FGFR-2

INTRODUCTION

The posterior fossa derives from two different embryonic tissues: the para-axial mesodermis forming the chondrocranium, and the neural crest forming the neurocranium [1]. The chondrocranium comprises the sphenoidal body, the petrosal part of the temporal bone, and the basi-occipital, exo-occipital and inferior part of the supra-occipital bone [2,3]. The neurocranium includes only the superior part of the supra-occipital bone [2,3].

The membranous sutures of the cranial dome (calvaria) are formed by mesenchymal cells that later differentiate into osteoblasts. Differentiation is controlled by the Runx2 gene [1,4–12]. Runx2 activation depends on Dlx-2, Dlx-5 and β -catenin pathways and inhibition on Msx-2 and Twist pathways [1,4–9]. Transforming growth factor- β , bone morphogenetic proteins and fibroblast growth factors are other factors produced by the dura and that induce osteoblastic cellular differentiation [13,14]. Biomechanical factors may also be involved in calvaria growth. Experimental studies have proved that pressure applied on the inner surface of the cranium by cerebral expansion induces osteoblastic differentiation in the periosteum of the cranial sutures [15,16].

The skull base includes the cartilaginous synchondrosis. Chondroblast cellular differentiation is regulated by transcription factors such as SOX9, SOX5 and SOX 6 and by growth factors such as bone morphogenetic protein, fibroblast growth factor, and insulin-like growth factor [17,18]. Calcification of the cartilaginous matrix is induced by matrix metalloproteinase-13, angiogenic growth factor, vascular endothelial growth

factor and Runx2, since SOX9 is not expressed during this step [17–19]. The calcified cartilage is then replaced by endochondral bone [19].

The relation between cranial dome growth, skull-base growth and facial growth is complex. The growth of these three parts is synergic, and any minor change in the growth of one part will have consequences on the growth of the others. Premature ossification of the cranial sutures in infants strongly affects the growth of the basal craniofacial skeleton [20], especially in case of FGFR2-related faciocraniosynostosis (in particular, Crouzon, Apert or Pfeiffer syndrome) [21,22]. These changes in the posterior fossa can lead to active cerebrospinal fluid circulation disorders requiring treatment [21], cerebellar tonsil ectopia requiring occipital fenestration [21], or turribrachycephaly requiring posterior cranial vault expansion [21]. Ossification of the cranial sutures (membranous and cartilaginous) can be analyzed on CT. In 1995, Madeline and Elster [23] proposed a 5-grade classification of this ossification based on CT images (Table1): Grade I, absence of ossification [23]; Grade II, incipient ossification, with “suspicious areas for bony bridging” [23]; Grade III, intensification of ossification and “fusion or bridging across a portion of the synchondrosis” [23]; Grade IV, fused suture with a small “remnant sclerotic margin” [23]; and Grade V, completely fused suture [23]. CT studies of the ossification process of the cranial sutures shed light on posterior fossa growth in normal infants and in patients with faciocraniosynostosis: a correlation was reported between volumetric growth of the posterior cranial fossa and ossification of the sutures graded according to Madeline and Elster. We will not distinguish hereinafter between membranous and cartilaginous sutures, for reasons of convenience.

METHOD

Two literature searches were conducted on PubMed: one with keywords “posterior cranial fossa”, “growth”; and one with “fibroblast growth factor type 2 receptor”, “posterior cranial fossa”, “growth”. Respectively, 317 and 4 articles were retrieved; only 16 of the 317 articles dealt with the growth of the posterior cranial fossa in healthy children. The complete reference lists of all 20 articles were exhaustively analyzed.

POSTERIOR FOSSA GROWTH

Practical considerations

Estimations of posterior fossa growth and volume are an important aspect of the analysis of the pediatric literature on developmental diseases. Two methods exist: direct and indirect segmental methods. Direct segmentation is more precise than indirect methods, in which the margin of error can exceed 5%. Despite this generally admitted fact, most studies estimated posterior fossa volume and growth by indirect segmentation, such as Cavalieri’s method [24–29], and few used direct segmentation [21,30].

Growth in normal subjects

A study by Coll et al. in 2016 measured the volumetric growth of the posterior fossa in 235 infants (132 boys and 103 girls) [31]. The posterior fossa was manually contoured on millimetric CT slices by a single neurosurgeon (figure1) [31]. Volumetric growth

correlated with fusion grade in the 12 sutures of the posterior fossa: anterior interoccipital synchondrosis (AIOS), posterior interoccipital synchondrosis (PIOS), petro-occipital synchondrosis (POS), occipitomastoidal synchondrosis (OMS), sphenoccipital synchondrosis (SOS), Kerckring supra-occipital synchondrosis, and the lambdoid sutures (LS) (figure 2) [31]. Posterior fossa growth comprises two phases: [31] a rapid growth phase from birth to 3.58 years, and then a slow growth phase until 16 years (figure 3). The rapid growth phase is explained by the absence of ossification (Madeline and Elster grade I) of OMS, POS and SOS, the mean age of grade I in OMS, POS and SOS being 1.95, 3.58 and 5.09 years, respectively. The first sutures to fuse are PIOS and AIOS, at around 1.72 and 4.23 years, respectively. The slow growth phase is due to POS and SOS being in grade II until 10.37 and 10.14 years, respectively.

Posterior fossa growth differs between sexes: the rapid growth phase is shorter and faster in girls (birth to 2.67 years) than boys (birth to 4.5 years) (figure 3) [31]. The final (adult) volume of the posterior fossa is greater in boys (figure 4) [31]. This difference in volume is not caused by growth rate but by a smaller posterior fossa volume at birth in girls (64.92 cm^3 vs. 104.73 cm^3 ; $p=0.002$) (figure 4) [31].

Growth in faciocraniostenosis

In 1976, Hoffman [32] was the first to postulate that the posterior fossa is smaller in syndromic craniostenosis than in normal subjects. This was later confirmed experimentally by Marin Padilla, estimations of posterior fossa volume by Sgouros [6] and Wang [46], and isotopic cisternographic studies [33]. Selection bias must be borne in mind in these studies. It is frequent that infants with syndromic craniostenosis

undergo neurosurgical procedures in their first years to treat cerebrospinal fluid (CSF) circulation abnormalities, tonsillar prolapse or posterior expansion. These procedures alter the natural growth of the posterior fossa, and it is difficult to find a study that includes only non-operated patients. Some studies included craniostenotic patients with unidentified syndromes in order to increase sample size [34] or because genetic testing was not available [35]. One study [21] compared posterior fossa volume in FGFR2-induced faciocraniostenosis (14 Crouzon, 6 Pfeiffer and 11 Apert syndromes) versus normal subjects. Volumes were calculated on millimetric CT slices by contouring the space between the tent of the cerebellum, occipital bone, clivus and temporal bone [14]. The anterolateral boundary was the ridge of the petrous part of the temporal bone and the anterior boundary its connection with the posterior petroclinoid ligament [14]. No significant difference was found between patients and normal subjects [14]. The main bias in this study was age at inclusion: birth to 2 years [14]. However, the study by Sgouros [6], which included only patients of the same age-group and had broader inclusion criteria, including non-syndromic craniostenosis, found differences between craniostenotic and normal subjects [6].

The smaller posterior fossa volume in syndromic craniostenosis correlated with early fusion of the lambdoid suture [35]. This fusion is earlier in Crouzon patients (median, 21 months) than in Apert patients (median, 60 months) [35]. Moreover, the study by Sgouros [6] correlated the smaller posterior fossa volume in syndromic craniostenosis to a pathological skull dome (calvaria), particularly for the coronal and spheno-occipital sutures.

Particularities of skull-base synchondrosis ossification in Crouzon syndrome.

Coll et al. studied 11 skull-base sutures, using the Madeline-Elster classification [23], in 30 infants (17 boys and 13 girls) with genetically confirmed Crouzon syndrome [22]. CT scans were taken before any neurosurgical procedure [22]. This was the only study with precise selection criteria, ensuring the homogeneity of the study population [22]. Other skull-base ossification studies in Crouzon syndrome also included patients after neurosurgery [36–38], or did not perform genetic tests to confirm diagnosis [36,39]. In comparison to normal subjects, skull-base sutures fuse prematurely in Crouzon syndrome ($p=0.002$) [22] (figure 5). The pattern of synchondrosis ossification in Crouzon patients differs from that in normal subjects (figure 6). PIOS and LS fuse at approximately 10 months of age. This is followed by AIOS and OMS fusion during the second year. Finally, SOS and POS fuse at the end of the first trimester of the third year (figure 7) [22]. This early skull-base synchondrosis ossification has multiple repercussions on the growth of the posterior fossa. The fusion of the interoccipital synchondroses, and especially PIOS, decreases the area of the foramen magnum [22,31,38,40,41]. Premature fusion of POS [22] and SOS [22,36,37,42] may be the key to explaining facial retrusion in Crouzon Syndrome: these sutures fuse during the third year in Crouzon patients, in contrast to the 13th year in normal subjects [22].

No difference in posterior fossa volume was observed between normal infants and Crouzon patients up to 2 years of age [21], in contrast to other studies with less selective inclusion criteria [34,43–46]. It is important to bear in mind a potential selection bias related to age: in Crouzon patients, skull-base synchondrosis ossification is at grade IV

or V, after 2 years of age [22]; in contrast, these synchondroses still have growth potential after 2 years in normal subjects [22].

CONCLUSION

Posterior fossa growth in FGFR2-related syndromic craniostenosis (Crouzon, Apert, or Pfeiffer syndrome) is difficult to analyze, because it requires non-operated patients with genetically confirmed diagnosis. Few studies in the literature meet these conditions [21,22,41], but reported modifications in the posterior fossa in Crouzon patients, and particularly a decrease in foramen magnum area and facial retrusion. These modifications are caused by premature ossification of the posterior interoccipital synchondrosis (PIOS) and of the petro-occipital and sphenoccipital synchondrosis complex.

FIGURE LEGENDS

Figure 1. Three-dimensional reconstruction, axial, sagittal, and coronal computed tomography millimeter slices showing posterior fossa volume calculation in a 5-day-old girl (iPlan stereotaxy 3.0.2; Brainlab, Munich, Germany). Color version available online only. Adapted from reference [31](#).

Figure 2. A: 3D reconstruction of the skull base in a 5-day-old girl (control group), inferior view showing (1) the anterior interoccipital synchondroses, (2) posterior interoccipital synchondroses, (3) occipitomastoidal synchondroses, (4) lambdoid sutures, (5) petro-occipital synchondroses, and (6) spheno-occipital synchondrosis. B: 3D reconstruction of the skull base in a 5-day-old girl (control group), posteroinferior view showing (1) the anterior interoccipital synchondroses, (2) posterior interoccipital synchondroses, (3) occipitomastoidal synchondroses, and (4) lambdoid sutures. C: 3D reconstruction of the skull base in a 5-day-old girl (control group), endocranial view showing (1) the anterior interoccipital synchondroses, (2) posterior interoccipital synchondroses, (3) occipitomastoidal synchondroses (not shown), (4) lambdoid sutures, (5) petro-occipital synchondroses, and (6) spheno-occipital synchondrosis. D: 3D reconstruction of the skull base in a 5-day-old girl (control group), endocranial view showing (1) the anterior interoccipital synchondroses, (2) posterior interoccipital synchondroses, (3) occipitomastoidal synchondroses, (4) lambdoid sutures, (5) petro-occipital synchondroses, and (6) spheno-occipital synchondrosis. Adapted from reference [31](#).

Figure 3. Posterior cranial fossa volume (PCFV) distribution by sex and age with lower curves extrapolating the change of PCFV. Error bars for the PCFV; circles represent the mean; bars represent the 95% confidence interval (CI); boys are compared with girls. Adapted from reference [31](#)

Figure 4. Error bars for the posterior cranial fossa volume by age class of 1 year; circles represent the mean; bars represent the 95% confidence interval (CI). Comparison between boys and girls. Adapted from reference [31](#).

Figure 5. Error bars for Madeline-Elster grade by synchondrosis. Comparison of Crouzon children and controls. Central symbols represent mean ages according to grade, bars represent the 95% confidence interval. (A) Anterior intraoccipital synchondrosis. (B) Lambdoid suture. (C) Occipitomastoid synchondrosis. (D) Posterior intraoccipital synchondrosis. (E) Petro-occipital synchondrosis. (F) Spheno-occipital synchondrosis. CI: confidence interval. Adapted from reference [22](#).

Figure 6. Schematic view of ossification of skull base synchondroses. The healthy pattern of ossification is compared with children with Crouzon syndrome. Mean ages of closures are color coded. Adapted from reference [22](#).

Figure 7. Error bars for Madeline-Elster grade by synchondrosis, according to grade. Central symbols represent mean ages of grade. Skull-base synchondroses in children with Crouzon syndrome are compared and bars represent the 95% confidence interval (CI). Adapted from reference [22](#).

References

- [1] Lenton KA, Nacamuli RP, Wan DC, Helms JA, Longaker MT. Cranial suture biology. *Curr Top Dev Biol* 2005;66:287–328. doi:10.1016/S0070-2153(05)66009-7.
- [2] Sadler TW. *Langman's Medical Embryology*. 10th edition. Baltimore, Maryland: Lippincott Williams and Wilkins; n.d.
- [3] Bernard S, Loukas M, Rizk E, Oskouian RJ, Delashaw J, Shane Tubbs R. The human occipital bone: review and update on its embryology and molecular development. *Childs Nerv Syst* 2015. doi:10.1007/s00381-015-2870-8.
- [4] Holleville N, Quilhac A, Bontoux M, Monsoro-Burq AH. BMP signals regulate *Dlx5* during early avian skull development. *Dev Biol* 2003;257:177–89.
- [5] Opperman LA. Cranial sutures as intramembranous bone growth sites. *Dev Dyn Off Publ Am Assoc Anat* 2000;219:472–85.
- [6] Rice DPC, Rice R, Thesleff I. Molecular mechanisms in calvarial bone and suture development, and their relation to craniosynostosis. *Eur J Orthod* 2003;25:139–48.
- [7] Ryoo H-M, Lee M-H, Kim Y-J. Critical molecular switches involved in BMP-2-induced osteogenic differentiation of mesenchymal cells. *Gene* 2006;366:51–7. doi:10.1016/j.gene.2005.10.011.
- [8] Nakashima K, Zhou X, Kunkel G, Zhang Z, Deng JM, Behringer RR, et al. The novel zinc finger-containing transcription factor osterix is required for osteoblast differentiation and bone formation. *Cell* 2002;108:17–29.
- [9] Holleville N, Matéos S, Bontoux M, Bollerot K, Monsoro-Burq A-H. *Dlx5* drives *Runx2* expression and osteogenic differentiation in developing cranial suture mesenchyme. *Dev Biol* 2007;304:860–74. doi:10.1016/j.ydbio.2007.01.003.
- [10] Komori T, Yagi H, Nomura S, Yamaguchi A, Sasaki K, Deguchi K, et al. Targeted disruption of *Cbfa1* results in a complete lack of bone formation owing to maturational arrest of osteoblasts. *Cell* 1997;89:755–64.
- [11] Otto F, Thornell AP, Crompton T, Denzel A, Gilmour KC, Rosewell IR, et al. *Cbfa1*, a candidate gene for cleidocranial dysplasia syndrome, is essential for osteoblast differentiation and bone development. *Cell* 1997;89:765–71.
- [12] Stock M, Schäfer H, Fliegauf M, Otto F. Identification of novel genes of the bone-specific transcription factor *Runx2*. *J Bone Miner Res* 2004;19:959–72. doi:10.1359/jbmr.2004.19.6.959.

- [13] Li S, Quarto N, Longaker MT. Dura mater-derived FGF-2 mediates mitogenic signaling in calvarial osteoblasts. *Am J Physiol Cell Physiol* 2007;293:C1834-1842. doi:10.1152/ajpcell.00135.2007.
- [14] Ogle RC, Tholpady SS, McGlynn KA, Ogle RA. Regulation of cranial suture morphogenesis. *Cells Tissues Organs* 2004;176:54–66. doi:10.1159/000075027.
- [15] Liu SS-Y, Kyung H-M, Buschang PH. Continuous forces are more effective than intermittent forces in expanding sutures. *Eur J Orthod* 2010;32:371–80. doi:10.1093/ejo/cjp103.
- [16] Lieberman DE. How and why humans grow thin skulls: experimental evidence for systemic cortical robusticity. *Am J Phys Anthropol* 1996;101:217–36. doi:10.1002/(SICI)1096-8644(199610)101:2<217::AID-AJPA7>3.0.CO;2-Z.
- [17] Liu C-F, Lefebvre V. The transcription factors SOX9 and SOX5/SOX6 cooperate genome-wide through super-enhancers to drive chondrogenesis. *Nucleic Acids Res* 2015;43:8183–203. doi:10.1093/nar/gkv688.
- [18] Orfanidou T, Iliopoulos D, Malizos KN, Tsezou A. Involvement of SOX-9 and FGF-23 in RUNX-2 regulation in osteoarthritic chondrocytes. *J Cell Mol Med* 2009;13:3186–94. doi:10.1111/j.1582-4934.2009.00678.x.
- [19] Quintana L, zur Nieden NI, Semino CE. Morphogenetic and Regulatory Mechanisms During Developmental Chondrogenesis: New Paradigms for Cartilage Tissue Engineering. *Tissue Eng Part B Rev* 2009;15:29–41. doi:10.1089/ten.teb.2008.0329.
- [20] Goodrich JT. Skull base growth in craniosynostosis. *Childs Nerv Syst* 2005;21:871–9. doi:10.1007/s00381-004-1113-1.
- [21] Coll G, Arnaud E, Collet C, Brunelle F, Sainte-Rose C, Di Rocco F. Skull Base Morphology in Fibroblast Growth Factor Receptor Type 2-Related Faciocraniosynostosis: A Descriptive Analysis. *Neurosurgery* 2015;76:571–83. doi:10.1227/NEU.0000000000000676.
- [22] Coll G, Sakka L, Botella C, Pham-Dang N, Collet C, Zerah M, et al. Pattern of Closure of Skull Base Synchronoses in Crouzon Syndrome. *World Neurosurg* 2018;109:e460–7. doi:10.1016/j.wneu.2017.09.208.
- [23] Madeline LA, Elster AD. Suture closure in the human chondrocranium: CT assessment. *Radiology* 1995;196:747–56. doi:10.1148/radiology.196.3.7644639.
- [24] Tubbs RS, Wellons JC, Smyth MD, Bartolucci AA, Blount JP, Oakes WJ, et al. Children with growth hormone deficiency and Chiari I malformation: a morphometric analysis of the posterior cranial fossa. *Pediatr Neurosurg* 2003;38:324–8. doi:70416.

- [25] Tubbs RS, Wellons JC, Blount JP, Grabb PA, Oakes WJ. Inclination of the odontoid process in the pediatric Chiari I malformation. *J Neurosurg* 2003;98:43–9.
- [26] Tubbs RS, Hill M, Loukas M, Shoja MM, Oakes WJ. Volumetric analysis of the posterior cranial fossa in a family with four generations of the Chiari malformation Type I. *J Neurosurg Pediatr* 2008;1:21–4. doi:10.3171/PED-08/01/021.
- [27] Tubbs RS, Webb D, Abdullatif H, Conklin M, Doyle S, Oakes WJ. Posterior cranial fossa volume in patients with rickets: insights into the increased occurrence of Chiari I malformation in metabolic bone disease. *Neurosurgery* 2004;55:380–3; discussion 383–384.
- [28] Clatterbuck RE, Sipos EP. The efficient calculation of neurosurgically relevant volumes from computed tomographic scans using Cavalieri's Direct Estimator. *Neurosurgery* 1997;40:339–42; discussion 343.
- [29] Vurdem ÜE, Acer N, Ertekin T, Savranlar A, Inci MF. Analysis of the volumes of the posterior cranial fossa, cerebellum, and herniated tonsils using the stereological methods in patients with Chiari type I malformation. *ScientificWorldJournal* 2012;2012:616934. doi:10.1100/2012/616934.
- [30] Sgouros S, Kountouri M, Natarajan K. Posterior fossa volume in children with Chiari malformation Type I. *J Neurosurg* 2006;105:101–6. doi:10.3171/ped.2006.105.2.101.
- [31] Coll G, Lemaire J-J, Di Rocco F, Barthélémy I, Garcier J-M, De Schlichting E, et al. Human Foramen Magnum Area and Posterior Cranial Fossa Volume Growth in Relation to Cranial Base Synchronosis Closure in the Course of Child Development. *Neurosurgery* 2016;79:722–35. doi:10.1227/NEU.0000000000001309.
- [32] Hoffman HJ, Tucker WS. Cephalocranial disproportion. A complication of the treatment of hydrocephalus in children. *Childs Brain* 1976;2:167–76.
- [33] Scarfò GB, Tomaccini D, Gambacorta D, Capaccioli L. Contribution to the study of craniostenosis: disturbance of the cerebrospinal fluid flow in oxycephaly. *Helv Paediatr Acta* 1979;34:235–43.
- [34] Sgouros S, Natarajan K, Hockley AD, Goldin JH, Wake M. Skull base growth in craniosynostosis. *Pediatr Neurosurg* 1999;31:281–93.
- [35] Cinalli G, Renier D, Sebag G, Sainte-Rose C, Arnaud E, Pierre-Kahn A. Chronic tonsillar herniation in Crouzon's and Apert's syndromes: the role of premature synostosis of the lambdoid suture. *J Neurosurg* 1995;83:575–82. doi:10.3171/jns.1995.83.4.0575.
- [36] Goldstein JA, Paliga JT, Wink JD, Bartlett SP, Nah H-D, Taylor JA. Earlier evidence of sphenoid-occipital synchondrosis fusion correlates with severity of midface

hypoplasia in patients with syndromic craniosynostosis. *Plast Reconstr Surg* 2014;134:504–10. doi:10.1097/PRS.0000000000000419.

[37] Tahiri Y, Paliga JT, Vossough A, Bartlett SP, Taylor JA. The spheno-occipital synchondrosis fuses prematurely in patients with Crouzon syndrome and midface hypoplasia compared with age- and gender-matched controls. *J Oral Maxillofac Surg* 2014;72:1173–9. doi:10.1016/j.joms.2013.11.015.

[38] Rijken BFM, Lequin MH, Van Veelen M-LC, de Rooi J, Mathijssen IMJ. The formation of the foramen magnum and its role in developing ventriculomegaly and Chiari I malformation in children with craniosynostosis syndromes. *J Cranio-Maxillo-Fac Surg* 2015;43:1042–8. doi:10.1016/j.jcms.2015.04.025.

[39] Kreiborg S, Marsh JL, Cohen MM Jr, Liversage M, Pedersen H, Skovby F, et al. Comparative three-dimensional analysis of CT-scans of the calvaria and cranial base in Apert and Crouzon syndromes. *J Cranio-Maxillo-Fac Surg* 1993;21:181–8.

[40] Rijken BFM, Lequin MH, de Rooi JJ, van Veelen M-LC, Mathijssen IMJ. Foramen magnum size and involvement of its intraoccipital synchondroses in Crouzon syndrome. *Plast Reconstr Surg* 2013;132:993e–1000e. doi:10.1097/PRS.0b013e3182a8077e.

[41] Coll G, Arnaud E, Selek L, Brunelle F, Sainte-Rose C, Collet C, et al. The growth of the foramen magnum in Crouzon syndrome. *Childs Nerv Syst* 2012;28:1525–35. doi:10.1007/s00381-012-1805-x.

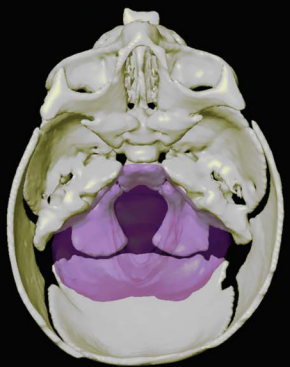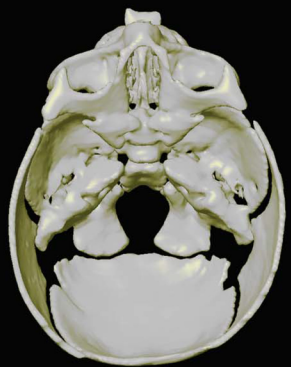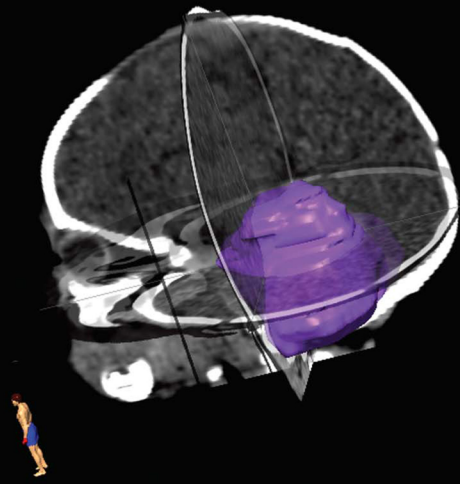
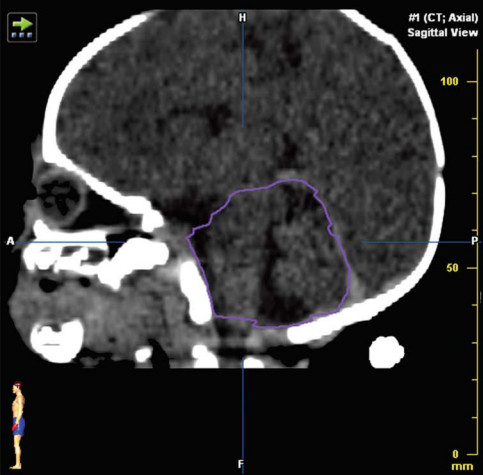
[42] McGrath J, Gerety PA, Derderian CA, Steinbacher DM, Vossough A, Bartlett SP, et al. Differential closure of the spheno-occipital synchondrosis in syndromic craniosynostosis. *Plast Reconstr Surg* 2012;130:681e–9e. doi:10.1097/PRS.0b013e318267d4c0.

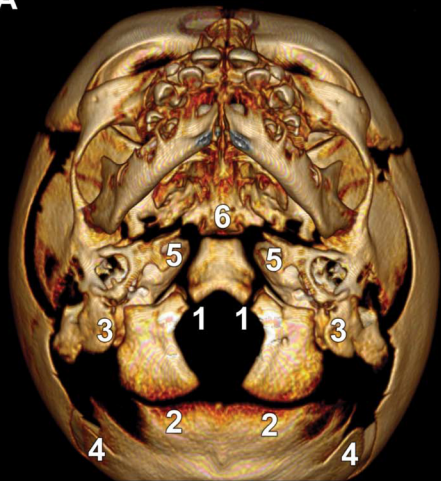
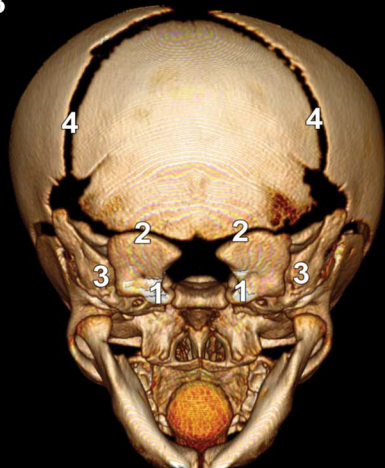
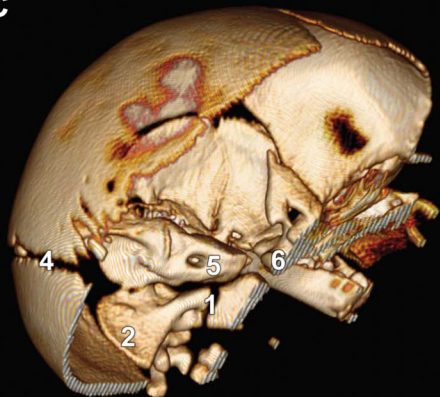
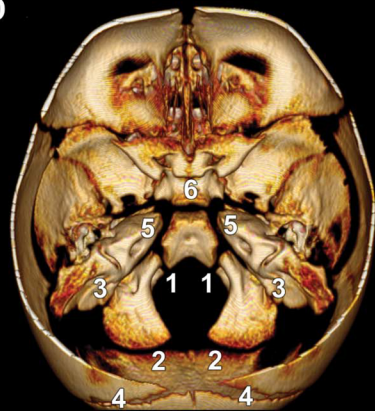[43] Collmann H, Sörensen N, Krauss J, Mühling J. Hydrocephalus in craniosynostosis. *Childs Nerv Syst* 1988;4:279–85.

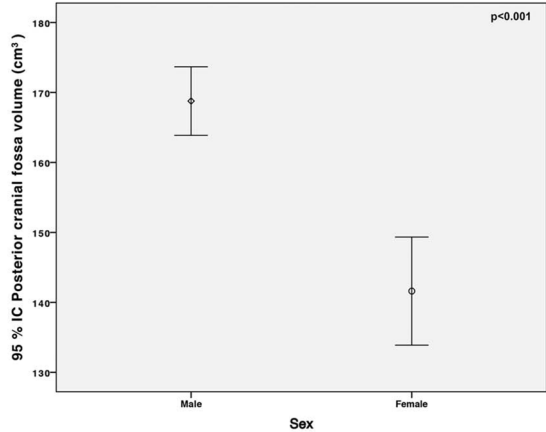
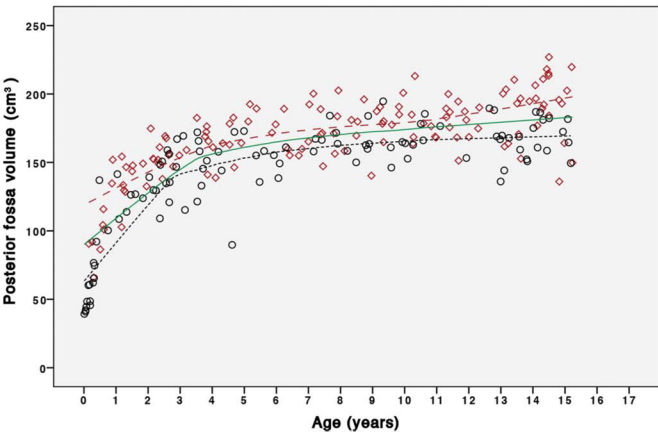
[44] Marin-Padilla M, Marin-Padilla TM. Morphogenesis of experimentally induced Arnold--Chiari malformation. *J Neurol Sci* 1981;50:29–55.

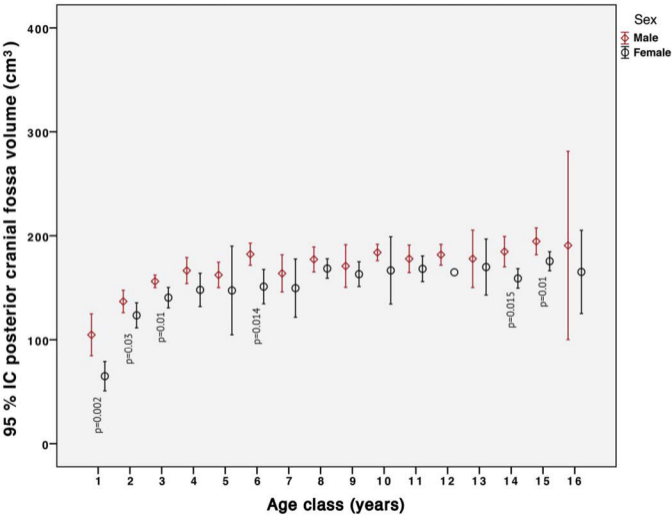
[45] Richtsmeier JT. Comparative study of normal, Crouzon, and Apert craniofacial morphology using finite element scaling analysis. *Am J Phys Anthropol* 1987;74:473–93. doi:10.1002/ajpa.1330740407.

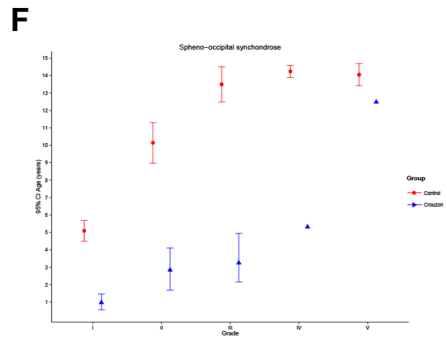
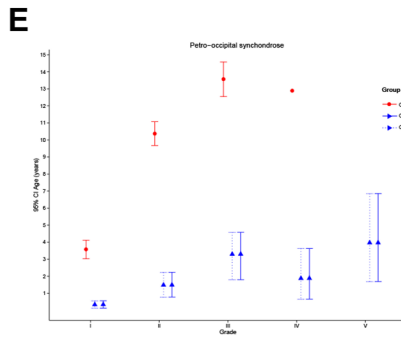
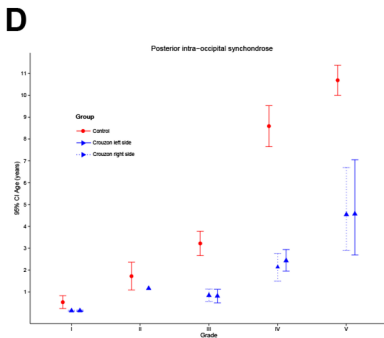
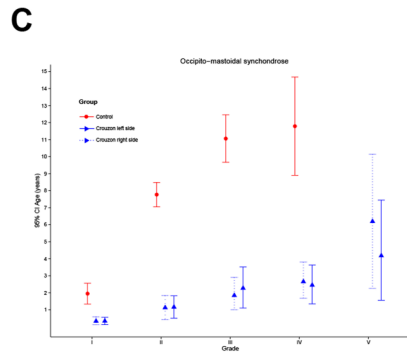
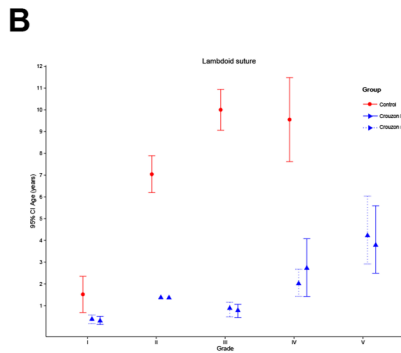
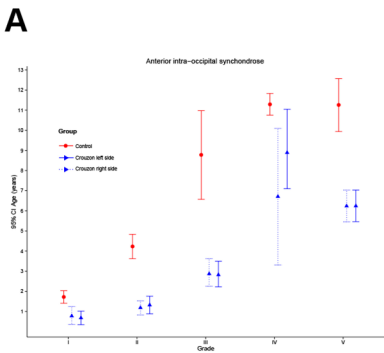
[46] Thompson DN, Harkness W, Jones BM, Hayward RD. Aetiology of herniation of the hindbrain in craniosynostosis. An investigation incorporating intracranial pressure monitoring and magnetic resonance imaging. *Pediatr Neurosurg* 1997;26:288–95.



A**B****C****D**

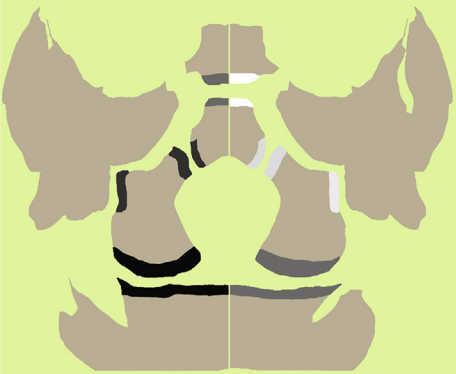





CROUZON

HEALTHY



13
11
8
6
5
4
3
2
1

Age (years)

Crouzon

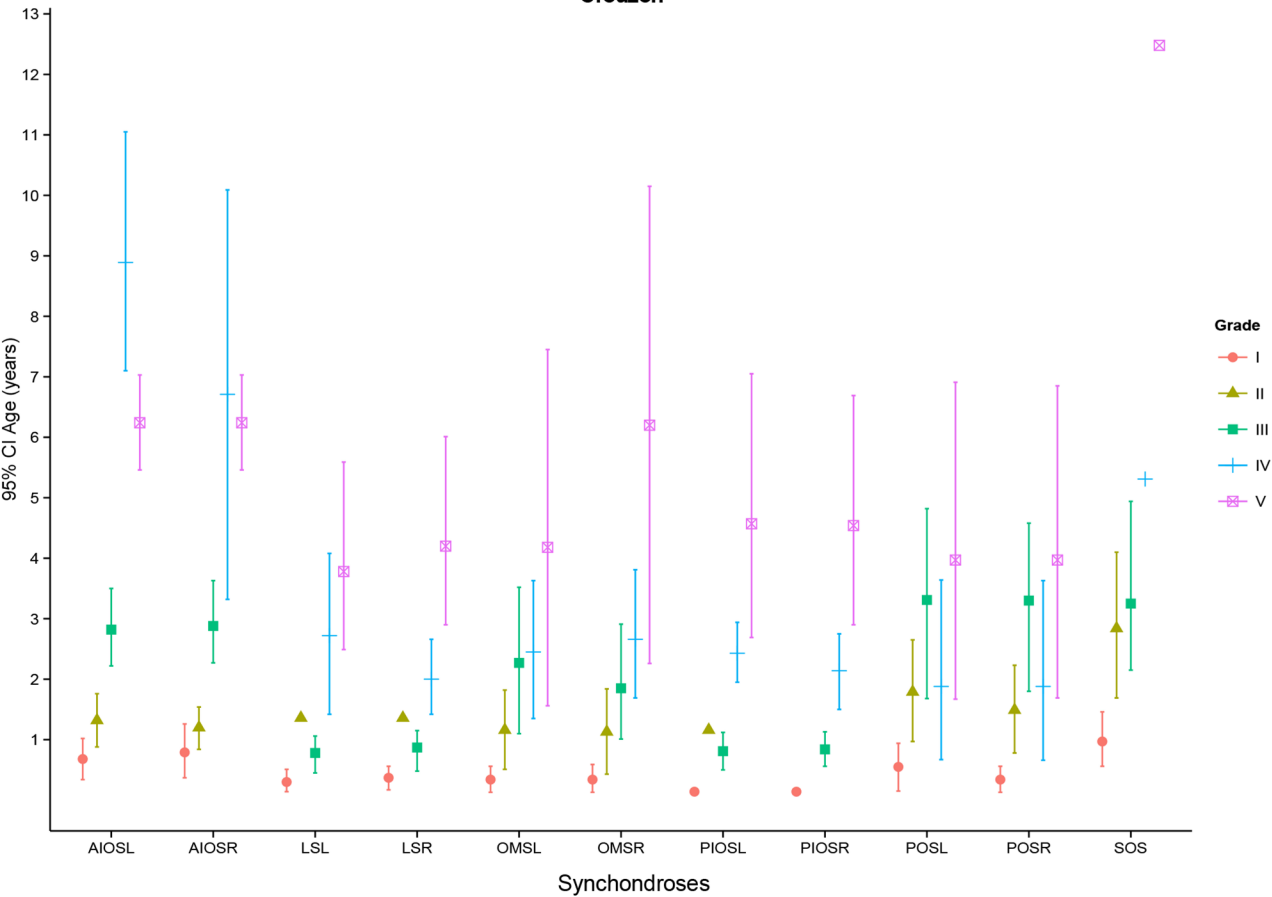


Table 1. Madeline and Elster synchondrosis closure grades, adapted from [23]

Grade	Character
I	Margins of the synchondrosis (suture) are clearly separated on all sections.
II	Clear separation of the synchondrosis (suture) is seen along most sections, but some areas are indistinct or suspicious for bony bridging.
III	Area of fusion or bridging across a portion of the synchondrosis (suture) is seen.
IV	Complete fusion of the synchondrosis (suture) with remnant sclerotic margin is seen.
V	Complete closure is seen with no apparent vestige remaining.