



Acute Retinal Necrosis: Virological Features Using Quantitative Polymerase Chain Reaction, Therapeutic Management, and Clinical Outcomes

Meriem Hafidi, Hélène Janin-Manificat, Philippe Denis, Bruce Charleux, Muriel Rabilloud, Andre Boibieux, Carole Burillon, Laurent Kodjikian, Emilie Frobert

► To cite this version:

Meriem Hafidi, Hélène Janin-Manificat, Philippe Denis, Bruce Charleux, Muriel Rabilloud, et al.. Acute Retinal Necrosis: Virological Features Using Quantitative Polymerase Chain Reaction, Therapeutic Management, and Clinical Outcomes. American Journal of Ophthalmology, 2019, 208, pp.376 - 386. 10.1016/j.ajo.2019.08.007 . hal-03488365

HAL Id: hal-03488365

<https://hal.science/hal-03488365>

Submitted on 21 Dec 2021

HAL is a multi-disciplinary open access archive for the deposit and dissemination of scientific research documents, whether they are published or not. The documents may come from teaching and research institutions in France or abroad, or from public or private research centers.

L'archive ouverte pluridisciplinaire **HAL**, est destinée au dépôt et à la diffusion de documents scientifiques de niveau recherche, publiés ou non, émanant des établissements d'enseignement et de recherche français ou étrangers, des laboratoires publics ou privés.



Distributed under a Creative Commons Attribution - NonCommercial 4.0 International License

Acute retinal necrosis: virological features using quantitative PCR, therapeutic management, and clinical outcomes

Meriem Hafidi,¹ Hélène Janin-Manificat,^{1,2} Philippe Denis,^{3,4} Bruce Charleux,¹ Muriel Rabilloud,^{3,5,6} Andre Boibieux,⁷ Carole Burillon,^{1,3} Laurent Kodjikian,^{3,4} Emilie Frobert,^{3,8,9}

¹ Department of Ophthalmology, Edouard Herriot Hospital, Hospices Civils de Lyon, Lyon, France

² La Coline Ophthalmological Center, Clinique l'Infirmierie Protestante, Caluire et Cuire, France

³ University of Lyon, Lyon, France

⁴ Department of Ophthalmology, Croix Rousse Hospital, Hospices Civils de Lyon, Lyon, France

⁵ Department of Biostatistics and Bioinformatics, Hospices Civils de Lyon, Lyon, France

⁶ Laboratory of Biometry and Evolutive Biology, CNRS, UMR 5558, Equipe Biostatistique-Santé, Villeurbanne, France

⁷ Department of Infectious Diseases, Croix Rousse Hospital, Hospices Civils de Lyon, Lyon, France

⁸ Laboratory of Virology, Institut des Agents Infectieux (IAI) de Lyon, Hospices Civils de Lyon, Lyon, France

⁹ Centre International de Recherche en Infectiologie (CIRI), Inserm U1111, Centre National de la Recherche Scientifique (CNRS) UMR5308, Ecole Nationale Supérieure de Lyon (ENS), Equipe Virpath, Lyon, France

Corresponding author:

Dr. Meriem Hafidi
Department of Ophthalmology, Pavillon C
Edouard Herriot Hospital
5, Place d'Arsonval
Lyon 69003, France
Tel: +33 (0)4 72 11 62 17
Fax: +33 (0)4 72 11 62 38
E-mail: meriem.hafidi1@gmail.com

Supplemental Material available at AJO.com.

Short title: Management and outcomes of acute retinal necrosis.

Introduction

Acute retinal necrosis (ARN) syndrome is a rare viral retinitis caused by the varicella zoster virus (VZV), herpes simplex virus (HSV) type 1 or 2, and, more rarely, by cytomegalovirus (CMV).¹ It was first described in 1971 by Urayama et al. as a unilateral panuveitis with retinal vasculitis and necrotizing retinitis, and occurring in both immunocompetent and immunocompromised hosts.^{2,3} The prognosis is often poor, with severe visual loss and retinal detachment, despite intensive antiviral therapy.^{4,5}

Polymerase chain reaction (PCR) is a rapid and sensitive method for the detection of viral DNA that is useful for the diagnosis of ARN.^{6–9} With recent advances in molecular biology, real-time quantitative PCR (qPCR) enables quantitative measurements of the viral load.¹⁰ A correlation between the clinical course and viral load kinetics has been reported in other herpes virus-related infections such as encephalitis and chickenpox.^{11,12} In cases of ARN syndrome, qPCR revealed that a high VZV DNA copy number is associated with more extensive retinitis, worse visual acuity (VA), and the development of retinal detachment (RD).^{13,14} Furthermore, a few case series have described the kinetics of viral DNA during systemic treatment and suggested that qPCR may be a useful method to monitor viral activity and the patient's response to antiviral therapeutics.^{15–17}

There are significant variations in treatment practices, especially concerning the use of intravitreal injections (IVTs).¹⁸ Many studies have reported the efficacy of IVTs of foscarnet or ganciclovir,^{19–22} but there are no guidelines for therapeutic indications, duration, or dose. The purpose of the present report was to assess the role of qPCR in the therapeutic management of ARN syndrome, and to evaluate the outcomes of patients treated with intensive intravitreal therapy.

Methods

This study was a retrospective observational case series of 24 patients with ARN in the Departments of Ophthalmology of the Croix-Rousse and Edouard Herriot Teaching Hospitals (Lyon, France) who were treated and followed-up between May 2010 and December 2016. Cases were identified from the virology department database that contained the qPCR results of herpes viruses from samples of the aqueous humor (AH). All patients met the criteria for ARN defined by the American Uveitis Society.²³ Written informed consent was obtained from all participants. The ethics committee of the Hospices Civils de Lyon (Lyon, France) approved this study, and the study was performed according to the tenets of the Declaration of Helsinki.

Patients and clinical assessment

Each patient's medical record was retrospectively reviewed to obtain the following demographic data: age at presentation, gender, laterality, history of a herpetic infection, duration of symptoms prior to presentation, previous medical history (specifically, the presence of a disease altering cellular or humoral immunity, or use of immunosuppressive therapy in order to assess the immune status of the patient). In addition, the causal virus and results of any antiviral resistance investigation were also collected.

The following ophthalmologic characteristics were collected: initial and final best corrected visual acuity (BCVA); initial number of retinal quadrants involved, defined after

dilated fundusoscopic examination; and occurrence of complications. Visual acuity was assessed using Snellen charts and converted to the logarithm of the minimum angle of resolution (logMAR). For visual acuities < 20/400, the following logMAR conversions were used: counting fingers = 1.6, hand movement = 2, light perception = 2.5.^{21,24} Details of the systemic antiviral medication and intravitreal injections were collected.

DNA viral load

Viral DNA was extracted using an automatic nucleic acid platform (NucliSENS EasyMAG, BioMérieux, Lyon, France) from samples of the AH obtained after anterior chamber paracentesis (ACP; 200 µL in 50 µL of elution buffer), as recommended by the manufacturer. Real-time qPCR was performed using HSV1, HSV2, VZV, and CMV R-gene™ Quantification kits (Argène, BioMérieux). Results were expressed as copies of DNA per mL of AH (the threshold of quantification was 500 copies per mL and that of detection was 100 copies per mL).

Antiviral resistance

HSV *UL23* and *UL30* genes, which, respectively, encode thymidine kinase and DNA polymerase, were sequenced using Sanger technology as reported previously.²⁵ Nucleotide sequences were compared with those of the sensitive reference strains KOS (HSV1) and HG52 (HSV2; GenBank accession numbers JQ673480 and Z86099, respectively) using SeqmanII software (DNASTar Inc, Wisconsin, USA).

VZV resistance was investigated by sequencing *ORF28* and *ORF36* that encode DNA polymerase and thymidine kinase, respectively. Sequences were compared to the wild-type OKA strain (GenBank accession number AB097933).²⁶

Statistical analysis

Quantitative characteristics were described using the median and range. Qualitative characteristics were described using the absolute and relative frequencies in each category.

The main outcome was the difference between the final and initial VA, expressed in logMAR. The comparison of the final and initial VA was performed using the Wilcoxon test, a non-parametric test for paired data.

A linear mixed model with a random intercept and a random slope was created to estimate the mean slope corresponding to the mean decrease in the logarithm (log) of the viral load per day, and the gaps of the individual slopes to the mean slope. The fixed regression coefficients of the linear mixed model were used to estimate the mean time to achieve a 50% reduction in viral load and to decrease to the detection threshold of the viral load (< 100 copies/mL).

The Kaplan-Meier method was used to estimate the probability of the occurrence of RD.

Statistical significance was defined as a two-tailed *P* value of <0.05. The analyses were performed using IBM SPSS Statistics for Windows, Version 21.0 (IBM Corp., Armonk, NY, USA) and R version 3.2.5 (R Core Team 2017. R: A language and environment for statistical computing. R Foundation for Statistical Computing, Vienna, Austria).

Results

The initial patient characteristics are reported in Table 1.

Demographic data

Samples from 25 eyes of 24 patients were collected (13 females, 11 males); the mean duration of follow-up was 17 months (range: 2-74 months). The infectious agent was VZV in 15 patients (62.5%), HSV1 in 4 patients (16.7%), HSV2 in 3 patients (12.5%), and CMV in 2 patients (8.3%). The median age at presentation was 58 years (range: 20-86 years). Patients with HSV2 were significantly younger (median age: 32 years; range: 20-34 years) than those with another virus (median age: 60 years; range: 40-86 years; $P = 0.001$). Eight patients (33.3%) were immunocompromised and 12 patients (50.0%) had a history of previous herpes infection.

Clinical features at presentation

The median duration of symptoms (first clinical signs to initiation of treatment) was 7 days (range: 1-45 days). The median initial VA was 0.8 logMAR (Snellen equivalent, ~20/125). Eleven eyes (44%) had an initial VA $\leq 20/200$; 11 eyes (44%) had an initial VA of 20/200-20/40; and 3 eyes (12%) had an initial VA $> 20/40$. Retinitis occurred in one quadrant in 3 eyes (12%), two quadrants in 6 eyes (24%), three quadrants in 2 eyes (8%), and four quadrants in 10 eyes (40%). The fundus was inaccessible due to hyalitis in 4 eyes (16%). One patient had initial bilateral involvement and RD in 1 eye. One patient had a central retinal artery occlusion (CRAO) at presentation.

Visual acuity outcomes

The VA was significantly improved ($P = 0.04$) (mean: -0.29 logMAR; median: -0.2 logMAR; range: -1.09 to -1 logMAR). The distributions of the initial and final VA of each patient are presented in Figure 1. The distributions of VAs according to the causative virus are presented in Supplemental Material 2 at AJO.com. Among patients with VZV, the median gain in VA was -0.2 logMAR (range: -1.9 to 0.6 logMAR). Patients with HSV1 ARN had a median gain of -0.2 logMAR (range: -1.2 to 1 logMAR). All patients with HSV2 showed improved VA, the median gain was -0.8 logMAR (range: -0.9 to -0.1 logMAR). One case of CMV ARN had a final VA of 20/20; the other had a final VA of 20/100 (mean gain, 0.05 logMAR). Overall, the final VA was $\leq 20/200$ for 5 eyes (20%), 20/200-20/40 (inclusive) for 12 eyes (48%), and $> 20/40$ for 8 eyes (32%). Among the 16 patients who were followed for at least 1 year, the final VA was $\leq 20/200$ for 4 eyes (25%), 20/200-20/40 (inclusive) for 8 eyes (50%), and $> 20/40$ for 4 eyes (25%).

There was no significant difference in final VA between patients treated with corticosteroids (median VA 0.45 log) and the others (0.5 log; $P = 0.59$).

Retinal detachment outcomes

In total, 4 eyes (16%) developed RD, which occurred between presentation and 5 months after the diagnosis of ARN. The probability of the occurrence of RD was estimated to be 18.5% at year 1 (95% CI [1.8%; 35.2%]).

Therapeutic management

The details of the therapeutic management and clinical evolution of each patient are summarized in Table 2.

Initial antiviral treatment

The initial antiviral treatment was administered intravenously to 23 patients and orally (valacyclovir, 1000 mg, 3 times daily) to 1 patient (#1). To manage VZV and HSV ARN, intravenous acyclovir was used as first-line therapy for 17 patients (77%), administered at a dose of 10 mg/kg every 8 hours; it was replaced by a combination of intravenous foscarnet and ganciclovir for 2 very severe cases (#8, #11) including the case of CRAO (#8). Ganciclovir was used intravenously for one immunocompromised patient (#4). Foscarnet was used intravenously for 3 patients (13.6%; #7, #10, #16) initially and was secondarily used with acyclovir in 1 patient. Patients with CMV ARN were treated with intravenous ganciclovir. Intravenous treatment was continued until complete resolution of retinitis; the median duration was 24 days (range: 15-48 days).

Intravitreal treatment

Twenty-two eyes (88%) received at least one IVT of an antiviral agent (ganciclovir and/or foscarnet) in combination with systemic therapy. Seventeen patients received the same treatment regimen: initial intensive treatment with biweekly injections for the duration of intravenous treatment, followed by weekly injections according to the clinical course and change in viral load. The median number of IVTs was 9 (range: 0-28). Ganciclovir (2000 µg/0.05 mL) was administered to 14 eyes; foscarnet (2.4 mg/0.1 mL) was administered to all patients with CMV infection and to 4 patients with VZV infection (2 were immunocompromised). Two patients (#8, #12) received a combination of foscarnet and ganciclovir. For one patient (#17), the drug was switched, from ganciclovir to foscarnet, after 7 IVTs due to the slow clinical improvement and a delay in reduction of the viral load. Ten patients were treated with injections until the viral load was undetectable.

Oral antiviral therapy

All patients received oral antiviral therapy with valacyclovir (20 patients) or valganciclovir (4 patients) as a part of the intravenous therapy. This was continued for all patients until the most recent follow-up.

Corticotherapy

Corticosteroid therapy (1 mg/kg/day) was introduced to 10 patients (46%); this started between 3 and 60 days after initiation of antiviral treatment (median: 16.5 days) and allowed clinical improvement for all patients. Four patients (#4, #5, #14, #15) were already receiving low-dose corticosteroids (less than 20 mg/day) before the occurrence of ARN, and the dosage was not changed.

Viral DNA

Viral kinetics

A quantification of the viral load was obtained at least once for all patients, and a change over time was evaluated in the 19 patients who had ≥ 2 samples. Details of observed and predicted reductions of viral load over time are reported in Figure 2. Patient 5 had bilateral involvement with RD; the viral load in the detached eye could not be quantified. The median number of the samples was 8 (range: 1-24 samples); the only complication related to ACP was the occurrence of an iatrogenic cataract.

The initial mean viral load was 811591 copies/mL (5.91 log) for VZV, 1794023 copies/mL (6.25 log) for CMV, and 1794023 copies/mL (6.12 log) for HSV1. The initial viral load was lower in the HSV2 group (66240 copies/mL; 4.82 log) than in the VZV group ($P = 0.09$). Among the total population, the viral load at time 0 was estimated to be 5.87 log, which corresponds to a mean viral load at time 0 of 738268 (95% CI [325696; 1673463]). In order to obtain a homogeneous population for assessment of the initial evolution of viral load, we analyzed the viral loads of 17 patients who received the same combined systemic (intravenous acyclovir) and intravitreal treatment. We observed an initial plateau in 8 patients. A plateau was defined as a change in viral load of less than 10% in patients for whom we had a minimum of 2 samples during the first week. We could not judge the presence or absence of a plateau in the 5 patients who had had only one measurement in the first week. The median duration of the plateau in these patients was 15.5 days (range: 7-28 days). The remaining 4 patients experienced a reduction in the viral load on initiation of treatment.

The mean decrease in viral load was estimated to be -0.076 log per day (95% CI [-0.93; -0.59]; $P < 0.001$); the mean time required to achieve a 50% reduction in viral load was estimated to be 3.95 days for all viruses and 4.20 days for the VZV group. The mean decreases in viral loads according to the type of virus are presented in Supplemental Material 1 at AJO.com.

The mean time required for viral load to be below the detection threshold was estimated to be 50.9 days. In the 10 patients who had an undetectable final viral load, this was achieved after a mean 56.1 days (range: 27-119 days).

Role of immune competence

Mean baseline viral load was 2401728 copies/mL (6.38 log; range, 143000-13000000 copies/mL) in the immunocompromised group and 822144 copies/mL (5.9 log; range, 2400-6100000 copies/mL) in the non-immunocompromised group. This difference was not statistically significant ($P = 0.35$).

There was no significant difference in the rate of decrease in viral load between immunocompromised patients (mean decrease in viral load: -0.067 log per day) and the others (0.074 log; $P = 0.37$).

Role of corticotherapy

No significant difference was observed in the decrease in viral load between patients treated with corticosteroids and those who were not (mean decrease in viral load: -0.071 log per day vs. -0.073 log per day; $P = 0.89$).

Resistance to antivirals

Antiviral resistance was investigated in 3 HSV1 patients (patients #16, #17, and #19), and 3 VZV patients (patients #13, #14, and #15). Among the HSV1 patients, patient #17 tested positive for mutation of the thymidine kinase gene. In this patient, duration of the plateau phase was significantly longer (28 days) compared to other patients in the series, who also had a plateau (11.6 days; $P = 0.04$). The plateau phase corresponded to treatment with intravenous acyclovir and IVTs of ganciclovir; the decrease ensued after replacement of ganciclovir with foscarnet.

With DNA polymerase sequencing, we did not find a resistance mutation in any of the 3 patients. In the VZV patients, the DNA sequences were unfortunately incomplete, and all regions could not be analyzed. No mutation related to resistance was found in the sequences tested.

Discussion

To the best of our knowledge, the present study is the largest series to describe the evolution of the viral load of ARN using qPCR during treatment. The antiviral treatment regimen used was largely homogeneous, and included initial intravenous therapy combined with bi-weekly IVTs, followed by oral therapy with weekly IVTs. This treatment protocol yielded good outcomes in terms of VA and the RD rate.

Half of the included patients had a history of herpes infection, making it an important and often reported diagnostic guidance element.²⁷ It is assumed that ARN occurs when immune dysfunction allows the herpes virus to reactivate.²⁹ It is of note that a third of patients included herein were immunosuppressed, which is higher than that reported in the literature.³ This is an important clinical consideration for the choice of antivirals since resistance to acyclovir is common in such patients.³⁰

The retrospective nature and the variable duration of follow-up are the primary sources of bias of the present study. The limited follow-up period of some patients may have resulted in an underestimation of the rate of RD, however, it is reported that 96% of the cases of RD occur early, within 5 months of onset of the first symptoms.⁷ Furthermore, when tracking bias was taken into account by using Kaplan-Meier analysis, the probability of RD herein remained the lowest rate reported in the literature (Table 3).

In the present study, a clinically significant improvement in VA and only a fifth of patients had a final VA $\leq 20/200$, compared to 46% in the literature.⁴⁴ The markedly better visual outcomes herein could be explained by the use of IVT, but also the intensive and extended antiviral treatment administered to each patient. For instance, it has been demonstrated that IVTs are beneficial for VA and decrease the risk of RD.^{20,21,42} It can be assumed that in cases of occlusive vasculitis, retinal penetration of systemic antiviral treatment may be decreased, and IVTs may intensify the treatment by increasing the intraocular concentrations and accelerating healing. Furthermore, the median number of IVTs was high compared to other series, wherein only 1 to 7 injections were administered.^{21,22,36,51,52} As for the duration of use, it is interesting to note that on the study reported by Meghpara *et al.*, IVTs were used for a mean duration of 59 days and good outcomes were found.²⁰

We observed a change in the viral load in 3 phases: a first plateau period that was not always present, a logarithmic decrease phase, and a negativation phase. The first study that described this profile of viral load during treatment of VZV ARN was performed by Bernheim *et al.*¹⁵ In their study, the initial plateau and the delay of the time to negativity were longer, probably related to the differences in treatment used. Additional studies are needed to support the role of IVT in the decrease of the viral load. We continued ACP and IVTs until negativation of the viral load in 10 cases. As ACP is a minimally invasive procedure with infrequent side effects,⁵³ the repetition of this technique to achieve negativity seems acceptable to ensure healing. Some authors recommend performing a puncture when injecting 0.1 mL of a substance to avoid a short-term increase in intraocular pressure. Thus, the frequency of the punctures could be adapted to that of the IVT. Since a significant complication occurred herein, it seems

reasonable to reduce the number of punctures to improve safety.³⁷ It is, however, not possible to establish a direct relationship between the viral load and the clinical course since other factors, such as immune status or corticosteroid therapy, come into consideration. However, it is logical to presume that the final VA is improved in cases of rapid healing and when the viral load decreases rapidly.

Acyclovir is the first-line treatment for HSV and VZV ARN, due to its efficacy and good tolerability,³⁸ and herein it was used as such in most cases. The median duration of intravenous therapy was much longer than the duration more commonly used in clinical practice (7 to 10 days). The duration of intravenous treatment was decided by the treating ophthalmologists, based on their preferences with respect to the resolution of retinitis.

No study has previously described the change in viral load in the context of resistance to acyclovir; a prolonged plateau, as observed in the present study, could be a reason to change the treatment and test for resistance. Resistance to acyclovir is more common in immunosuppressed patients,³⁹ which may favor the administration of foscarnet as a first-line therapy. In addition, synergy is observed between foscarnet and ganciclovir *in vitro*, which may justify their use as dual therapy in severe cases. We used a combination of ganciclovir and foscarnet (intravitreal or intravenous) for a highly immunocompromised patient, and for extremely severe ARN. In the case with CRAO, intraretinal penetration of intravenous antivirals was probably minimal, IVTs of ganciclovir and foscarnet were also used to achieve the highest intraocular concentration.

Oral treatment was traditionally initiated as an adjunct to intravenous treatment to reduce the risk of bilateralization.⁴⁰ In the present study, it was continued for all patients until the most recent follow-up visit. Recent studies have also demonstrated its effectiveness when administered from the initial phase of management,^{41,42} as we observed in one patient herein. Intravenous antiviral therapy was the reference at the time of patient management; however, it could be replaced by oral treatment, as both strategies are associated with similar outcomes.²⁴ There is no recommendation for the duration of preventive treatment, but it seems justified to continue long-term treatment due to the risk of recurrence and bilateralization, which may occur years after the first episode.⁴³ Systemic corticosteroids are often co-administered with antiviral therapy to reduce local inflammation.⁴⁴ They very likely play an important role in the decrease of the viral load but this has not been demonstrated herein, probably due to heterogeneous introduction date and duration of use. The time of introduction is often discussed in the literature because of the risk of aggravation if the infection is insufficiently controlled by the antiviral treatment, but no study has formally investigated this aspect.

In conclusion, numerous and prolonged IVTs, used as adjunctive therapy, could improve the prognosis of treated patients by decreasing the risk of retinal detachment and improving visual acuity. Real-time qPCR enables monitoring of the response to treatment and can provide evidence for resistance to antiviral treatment by enabling the detection of cases with a prolonged initial plateau of viral load.

Acknowledgments/Disclosure: The authors would like to thank Philip Robinson (DRCI, Hospices Civils de Lyon, Lyon, France) for help in manuscript preparation.

a. Funding/Support: None.

b. Financial Disclosures: No financial disclosures.

c. Other Acknowledgments: None.

References

1. Ganatra JB, Chandler D, Santos C, Kuppermann B, Margolis TP. Viral causes of the acute retinal necrosis syndrome. *Am J Ophthalmol* 2000;129(2):166-172.
2. Urayama A, Yamada N, Sasaki T. Unilateral acute uveitis with retinal periarteritis and detachment. *Rinsho Ganka* 1971;25:607-619.
3. Rochat C, Herbort CP. [Acute retinal necrosis syndrome. Lausanne cases, review of the literature and new physiopathogenetic hypothesis]. *Klin Monbl Augenheilkd* 1994;204(5):440-449.
4. Roy R, Pal BP, Mathur G, Rao C, Das D, Biswas J. Acute retinal necrosis: clinical features, management and outcomes – a 10 year consecutive case series. *Ocul Immunol Inflamm* 2014;22(3):170-174.
5. Sims JL, Yeoh J, Stawell RJ. Acute retinal necrosis: a case series with clinical features and treatment outcomes. *Clin Exp Ophthalmol* 2009;37(5):473-477.
6. Knox CM, Chandler D, Short GA, Margolis TP. Polymerase chain reaction-based assays of vitreous samples for the diagnosis of viral retinitis. Use in diagnostic dilemmas. *Ophthalmology* 1998;105(1):37-44;discussion 44-45.
7. Lau CH, Missotten T, Salzmann J, Lightman SL. Acute retinal necrosis: features, management, and outcomes. *Ophthalmology* 2007;114(4):756-762.e1.
8. Sugita S, Shimizu N, Watanabe K, et al. Use of multiplex PCR and real-time PCR to detect human herpes virus genome in ocular fluids of patients with uveitis. *Br J Ophthalmol* 2008;92(7):928-932.
9. Gargiulo F, De Francesco MA, Nascimbeni G, et al. Polymerase chain reaction as a rapid diagnostic tool for therapy of acute retinal necrosis syndrome. *J Medical Virol* 2003;69(3):397-400.
10. Dworkin LL, Gibler TM, Van Gelder RN. Real-time quantitative polymerase chain reaction diagnosis of infectious posterior uveitis. *Arch Ophthalmol* 2002;120(11):1534-1539.
11. Kimura H, Kido S, Ozaki T, et al. Comparison of quantitations of viral load in varicella and zoster. *J Clin Microbiol* 2000;38(6):2447-2449.
12. Ando Y, Kimura H, Miwata H, Kudo T, Shibata M, Morishima T. Quantitative analysis of herpes simplex virus DNA in cerebrospinal fluid of children with herpes simplex encephalitis. *J Med Virol* 1993;41(2):170-173.
13. Abe T, Sato M, Tamai M. Correlation of varicella-zoster virus copies and final visual acuities of acute retinal necrosis syndrome. *Graefes Arch Clin Exp Ophthalmol* 1998;236(10):747-752.
14. Calvo CM, Khan MA, Mehta S, Garg SJ, Dunn JP. Correlation of clinical outcomes with quantitative polymerase chain reaction DNA copy number in patients with acute retinal necrosis. *Ocul Immunol Inflamm* 2017;25(2):246-252.
15. Bernheim D, Germe R, Labetoulle M, Romanet JP, Morand P, Chiquet C. Time profile of viral DNA in aqueous humor samples of patients treated for varicella-zoster virus acute retinal necrosis by use of quantitative real-time PCR. *J Clin Microbiol* 2013;51(7):2160-2166.
16. Asano S, Yoshikawa T, Kimura H, et al. Monitoring herpesvirus DNA in three cases of acute retinal necrosis by real-time PCR. *J Clin Virol* 2004;29(3):206-209.
17. Cottet L, Kaiser L, Hirsch HH, Baglivo E. HSV2 acute retinal necrosis: diagnosis and monitoring with quantitative polymerase chain reaction. *Int Ophthalmol* 2009;29(3):199-201.

18. Winterhalter S, Stuebiger N, Maier A-K, et al. Acute retinal necrosis: diagnostic and treatment strategies in Germany. *Ocul Immunol Inflamm* 2016;24(5):537-543.
19. Luu KK, Scott IU, Chaudhry NA, Verm A, Davis JL. Intravitreal antiviral injections as adjunctive therapy in the management of immunocompetent patients with necrotizing herpetic retinopathy. *Am J Ophthalmol* 2000;129(6):811-813.
20. Meghpara B, Sulkowski G, Kesen MR, Tessler HH, Goldstein DA. Long-term follow-up of acute retinal necrosis. *Retina* 2010;30(5):795-800.
21. Yeh S, Suhler EB, Smith JR, et al. Combination systemic and intravitreal antiviral therapy in the management of acute retinal necrosis syndrome. *Ophthalmic Surg Lasers Imaging Retina* 2014;45(5):399-407.
22. Wong R, Pavesio CE, Laidlaw DAH, Williamson TH, Graham EM, Stanford MR. Acute retinal necrosis: the effects of intravitreal foscarnet and virus type on outcome. *Ophthalmology* 2010;117(3):556-560.
23. Holland GN. Standard diagnostic criteria for the acute retinal necrosis syndrome. Executive Committee of the American Uveitis Society. *Am J Ophthalmol* 1994;117(5):663-667.
24. Tibbetts MD, Shah CP, Young LH, Duker JS, Maguire JI, Morley MG. Treatment of acute retinal necrosis. *Ophthalmology* 2010;117(4):818-824.
25. Frobert E, Cortay J-C, Ooka T, et al. Genotypic detection of acyclovir-resistant HSV-1: characterization of 67 ACV-sensitive and 14 ACV-resistant viruses. *Antiviral Res* 2008;79(1):28-36.
26. Andrei G, Topalis D, Fiten P, et al. In vitro-selected drug-resistant varicella-zoster virus mutants in the thymidine kinase and DNA polymerase genes yield novel phenotype-genotype associations and highlight differences between antiherpesvirus drugs. *J Virol* 2012;86(5):2641-2652.
27. Okafor K, Lu J, Thinda S, et al. Acute retinal necrosis presenting in developmentally-delayed patients with neonatal encephalitis: a case series and literature review. *Ocul Immunol Inflamm* 2017;25(4):563-568.
28. Tran THC, Stanescu D, Caspers-Velu L, et al. Clinical characteristics of acute HSV-2 retinal necrosis. *Am J Ophthalmol* 2004;137(5):872-879.
29. Rochat C, Polla BS, Herbort CP. Immunological profiles in patients with acute retinal necrosis. *Graefes Arch Clin Exp Ophthalmol* 1996;234(9):547-552.
30. Gilbert C, Bestman-Smith J, Boivin G. Resistance of herpesviruses to antiviral drugs: clinical impacts and molecular mechanisms. *Drug Resist Updat* 2002;5(2):88-114.
31. Fisher JP, Lewis ML, Blumenkranz M, et al. The acute retinal necrosis syndrome. Part 1: Clinical manifestations. *Ophthalmology* 1982;89(12):1309-1316.
32. Clarkson JG, Blumenkranz MS, Culbertson WW, Flynn Jr HW, Lewis ML. Retinal detachment following the acute retinal necrosis syndrome. *Ophthalmology* 1984;91(12):1665-1668.
33. Matsuo T, Morimoto K, Matsuo N. Factors associated with poor visual outcome in acute retinal necrosis. *Br J Ophthalmol* 1991;75(8):450-454.
34. Crapotta JA, Freeman WR, Feldman RM, et al. Visual outcome in acute retinal necrosis. *Retina* 1993;13(3):208-213.
35. Tran THC, Bodaghi B, Rozenberg F, Cassoux N, Fardeau C, LeHoang P. [Viral cause and management of necrotizing herpetic retinopathies]. *J Fr Ophthalmol* 2004;27(3):223-236.
36. Tran THC, Cassoux N, Bodaghi B, Lehoang P. Successful treatment with

combination of systemic antiviral drugs and intravitreal ganciclovir injections in the management of severe necrotizing herpetic retinitis. *Ocul Immunol Inflamm* 2003;11(2):141-144.

37. Kotliar K, Maier M, Bauer S, Feucht N, Lohmann C, Lanzl I. Effect of intravitreal injections and volume changes on intraocular pressure: clinical results and biomechanical model. *Acta Ophthalmologica Scandinavica*. 2007;85(7):777-781.

38. Morel C, Metge F, Roman S, et al. [Acute retinal necrosis: clinical presentation, treatment, and prognosis in a series of 22 patients]. *J Fr Ophtalmol* 2004;27(1):7-13.

39. Frobert E, Burrell S, Ducastelle-Lepretre S, et al. Resistance of herpes simplex viruses to acyclovir: an update from a ten-year survey in France. *Antiviral Res*. 2014;111:36-41.

40. Aizman A, Johnson MW, Elner SG. Treatment of acute retinal necrosis syndrome with oral antiviral medications. *Ophthalmology* 2007;114(2):307-312.

41. Muthiah MN, Michaelides M, Child CS, Mitchell SM. Acute retinal necrosis: a national population-based study to assess the incidence, methods of diagnosis, treatment strategies and outcomes in the UK. *Br J Ophthalmol* 2007;91(11):1452-1455.

42. Ishida T, Sugamoto Y, Sugita S, Mochizuki M. Prophylactic vitrectomy for acute retinal necrosis. *Jpn J Ophthalmol* 2009;53(5):486-489.

43. Hillenkamp J, Nölle B, Bruns C, Rautenberg P, Fickenscher H, Roeder J. Acute retinal necrosis: clinical features, early vitrectomy, and outcomes. *Ophthalmology* 2009;116(10):1971-1975.e2.

44. Wong R, Pavesio CE, Laidlaw DAH, Williamson TH, Graham EM, Stanford MR. Acute retinal necrosis: the effects of intravitreal foscarnet and virus type on outcome. *Ophthalmology* 2010;117(3):556-560.

45. Taylor SR, Hamilton R, Hooper CY, et al. Valacyclovir in the treatment of acute retinal necrosis. *BMC Ophthalmology* 2012;12(1):48.

46. Cochrane TF, Silvestri G, McDowell C, Foot B, McAvoy CE. Acute retinal necrosis in the United Kingdom: results of a prospective surveillance study. *Eye* 2012;26(3):370-378.

47. Luo YH, Duan XC, Chen BH, Tang LS, Guo XJ. Efficacy and necessity of prophylactic vitrectomy for acute retinal necrosis syndrome. *Int J Ophthalmol* 2012;5(4):482-487.

48. Jeon S, Kakizaki H, Lee WK, Jee D. Effect of prolonged oral acyclovir treatment in acute retinal necrosis. *Ocul Immunol Inflamm* 2012;20(4):288-292.

49. Iwahashi-Shima C, Azumi A, Ohguro N, et al. Acute retinal necrosis: factors associated with anatomic and visual outcomes. *Jpn J Ophthalmol* 2013;57(1):98-103.

50. Flaxel CJ, Yeh S, Lauer AK. Combination systemic and intravitreal antiviral therapy in the management of acute retinal necrosis syndrome (an American Ophthalmological Society thesis). *Trans Am Ophthalmol Soc* 2013;111:133-144.

51. Huang JM, Callanan P, Callanan D, Wang RC. Rate of retinal detachment after early prophylactic vitrectomy for acute retinal necrosis. *Ocul Immunol Inflamm* 2016;26(2):204-207.

52. Butler NJ, Moradi A, Salek SS, et al. Acute retinal necrosis: presenting characteristics and clinical outcomes in a cohort of polymerase chain reaction-positive patients. *Am J Ophthalmol* 2017;179:179-189.

53. Kishore K, Jain S, Zarbin MA. Intravitreal ganciclovir and dexamethasone as adjunctive therapy in the management of acute retinal necrosis caused by varicella

zoster virus. *Ophthalmic Surg Lasers Imaging* 2011;42 Online:e87-90.

54. Patel P, Ahmed E, Subramanian ML. Intravitreal foscarnet therapy for acyclovir-resistant acute retinal necrosis after herpes simplex encephalitis. *Ophthalmic Surg Lasers Imaging* 2010;9:1-3.

55. Van der Lelij A, Rothova A. Diagnostic anterior chamber paracentesis in uveitis: a safe procedure? *Br J Ophthalmol* 1997;81(11):976-979.

56. Blumenkranz MS, Culbertson WW, Clarkson JG, Dix R. Treatment of the acute retinal necrosis syndrome with intravenous acyclovir. *Ophthalmology* 1986;93(3):296-300.

57. Emerson GG, Smith JR, Wilson DJ, Rosenbaum JT, Flaxel CJ. Primary treatment of acute retinal necrosis with oral antiviral therapy. *Ophthalmology* 2006;113(12):2259-2261.

58. Aslanides IM, De Souza S, Wong DTW, et al. Oral valacyclovir in the treatment of acute retinal necrosis syndrome. *Retina* 2002;22(3):352-354.

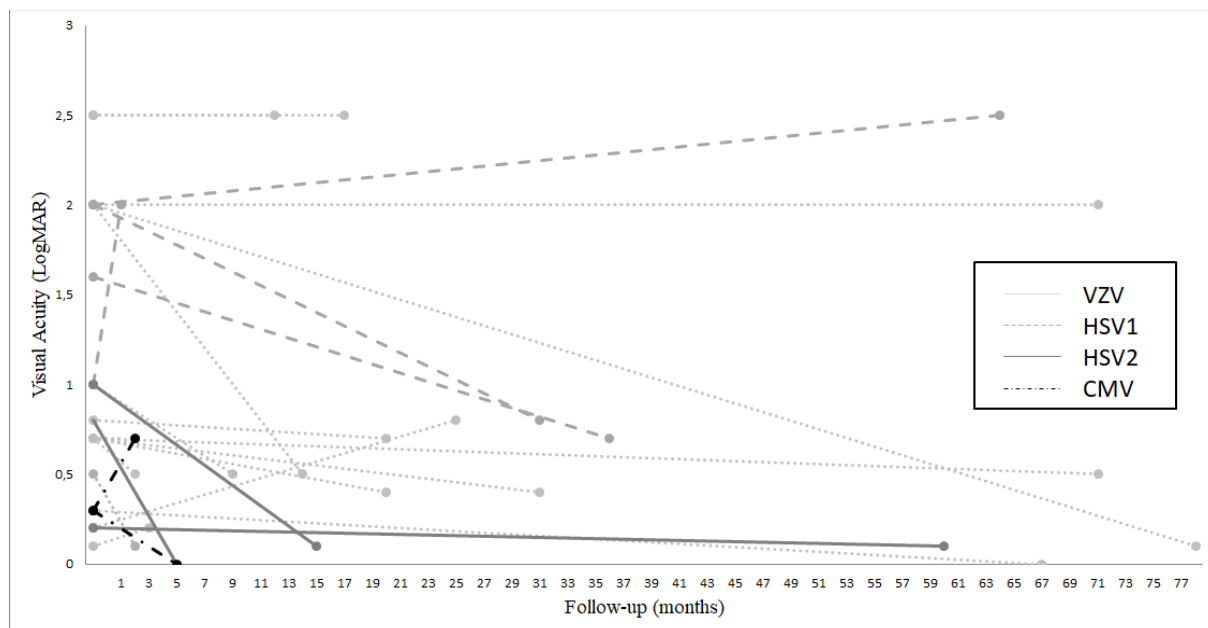
59. La Cava M, Abbouda A, Restivo L, Zito R. Delayed onset of bilateral acute retinal necrosis syndrome: a 46-year interval. *Semin Ophthalmol* 2015;30(2):146-149.

60. Shantha JG, Weissman HM, Debiec MR, Albin TA, Yeh S. Advances in the management of acute retinal necrosis. *Int Ophthalmol Clin* 2015;55(3):1-13.

Captions

FIGURE 1. Distributions of initial and final visual acuity. CMV, cytomegalovirus, HSV, herpes simplex virus, VZV, varicella zoster virus.

FIGURE 2. Observed and predicted reductions of viral load over time.



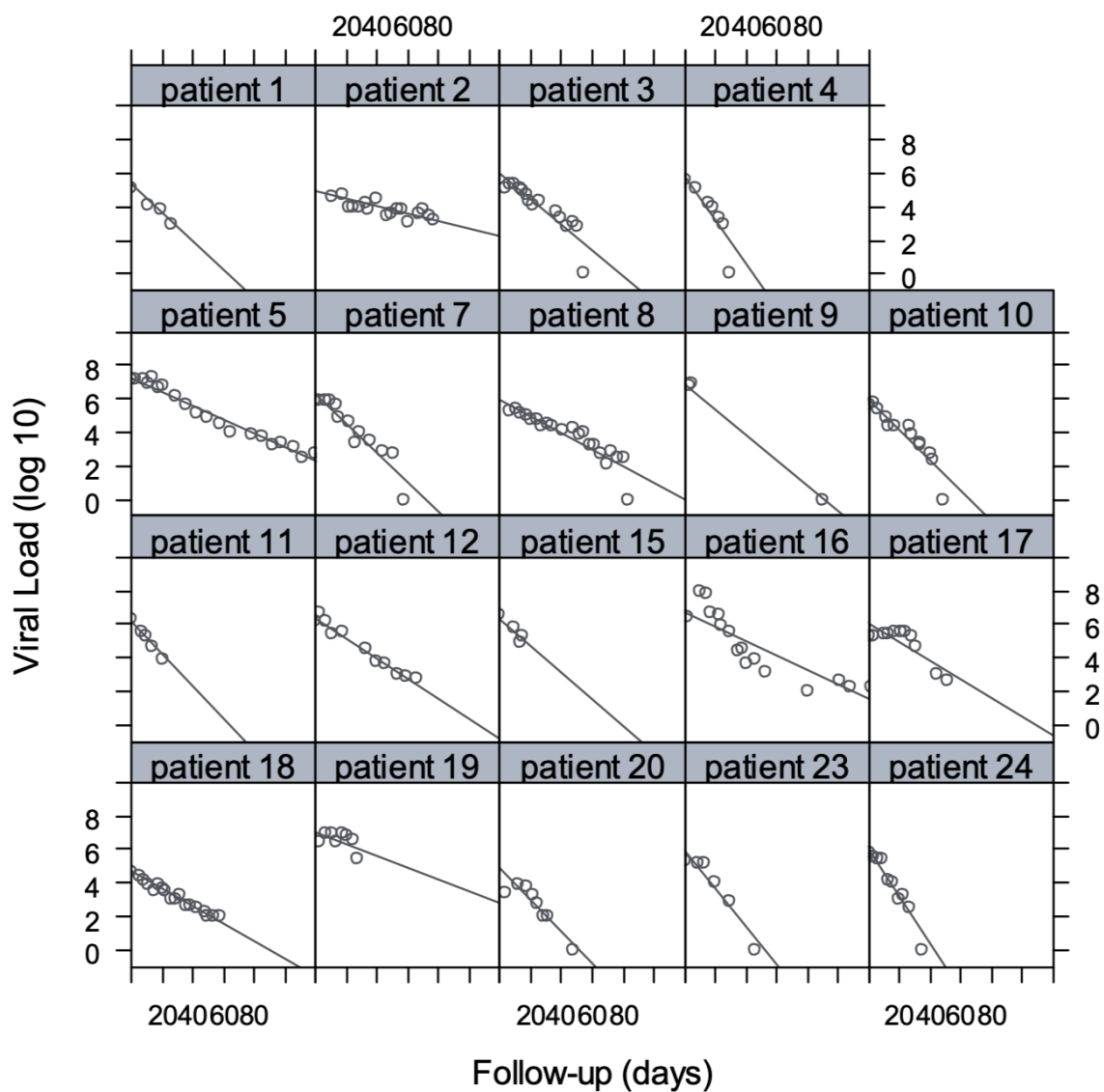


Table 1. Patient characteristics

Patient	Age	Gender	Virus	Prior herpetic infection	Immune dysfunction (ID)	Type of immunosuppression	Laterality	Symptom duration (days)	Presenting VA	Quadrants of retinitis	Duration of follow-up (months)	Other clinical findings at diagnosis
1	65	F	VZV	No	YES	Lung cancer, chemotherapy	OD	15	20/200	2	10	Initial RD
2	80	M	VZV	No	NO		OS	10	20/100	2	21	
3	42	F	VZV	No	NO		OD	3	20/32	1	26	
4	60	M	VZV	Thorax shingles (2 month prior)	YES	IgA nephropathy, corticosteroids	OS	7	20/40	2	68	
5 (OD) 5 (OS)	76	M	VZV	No	YES	Rheumatoid arthritis, corticosteroids	OU	7	20/100 HM	1 4	74	Initial RD
6	48	M	VZV	Zoster ophthalmicus (9 days prior)	NO		OS	1	20/100	NA	32	
7	51	F	VZV	No	NO		OS	15	HM	NA	79	
8	62	F	VZV	No	NO		OD	1	LP	4	18	
9	86	F	VZV	Zoster ophthalmicus (15 days prior)	NO		OD	7	LP	NA	13	Initial CRAO
10	81	M	VZV	Intercostal shingles (1 month prior)	NO		OD	10	20/125	2	21	
11	59	M	VZV	No	NO		OD	15	HM	4	15	
12	82	M	VZV	No	YES	Multiple myeloma, chemotherapy, corticosteroids	OS	21	20/100	4	2	
13	65	F	VZV	Shingles (15 days prior)	NO		OD	7	20/63	4	3	Initial CRAO
14	42	M	VZV	Intercostal shingles (30 years prior)	NO		OD	2	20/25	4	4	
15	75	F	VZV	No	YES	Kidney transplant, immunosuppressive therapy, corticosteroids	OS	28	20/100	3	3	
16	40	M	HSV1	Herpetic encephalitis (10 years prior)	NO		OS	4	CF	4	37	
17	47	F	HSV1	Herpetic encephalitis (30 years prior)	NO		OD	4	HM	4	32	Initial CRAO
18	37	F	HSV1	Herpetic encephalitis (neonatal)	NO		OS	15	HM	NA	65	
19	51	F	HSV1	Herpetic encephalitis (3 months prior)	YES	Lung cancer, chemotherapy	OS	15	20/200	3	2	
20	34	F	HSV2	Herpetic keratitis	NO		OS	3	20/32	4	61	
21	20	F	HSV2	HSV2 neonatal								Initial CRAO
22	32	M	HSV2	meningoencephalitis, intercostal shingles (10 years prior)	NO		OS	30	20/200	2	16	
23	78	M	CMV	No	YES	Cavum lymphoma, chemotherapy	OS	45	20/40	4	5	
24	57	F	CMV	No	YES	acute lymphoblastic leukemia, chemotherapy	OS	7	20/40	2	3	

HSV: herpes simplex virus; VZV: varicella zoster virus; CMV: cytomegalovirus; VA: visual acuity; HM: hand motion; CF: counting fingers; LP: light perception; NA: not accessible; RD: retinal detachment; CRAO: central retinal artery occlusion; Age is expressed in years.

Table 2. Treatment details and clinical outcomes

Patient	qPCR (number)	Initial viral load (copies/mL)	IV treatment	Duration of IV antiviral therapy (days)	Intravitreal treatment	Number of injections	Prophylactic laser	High-dose corticosteroid	Anticoagulant (AC) or antiplatelet (AP) therapy	Oral medication (maintenance)	Complications	Final VA
1	4	143000	No	0	Foscarnet	4	No	No	No	Valacyclovir	RD (5 th month)	20/63
2	17	43000	Acyclovir	30	Ganciclovir	14	PPR (Neovascular glaucoma)	No	No	Valacyclovir	Neovascular glaucoma	20/50
3	16	131000	Acyclovir	48	Ganciclovir	23	No	Yes	AC (LMWH) 2 months, then AP (aspirin 75mg/day)	Valacyclovir	Macular edema	20/125
4	10	380000	Ganciclovir	21	Foscarnet	13	No	No*	No	Valganciclovir		20/20
5 (OD)	23	13000000			Ganciclovir	26	No	No*				20/63
5 (OS)	0		Acyclovir	21	Ganciclovir	3	No	No*	No	Valacyclovir	RD (at presentation)	HM
6	1	22000	Acyclovir	28	Ganciclovir	2	No	Yes	AP* (aspirin 75mg/day)	Valacyclovir	Macular edema, macular epiretinal membrane	20/50
7	13	760000	Foscarnet	35	Ganciclovir	14	Yes	No	AP (aspirin 75mg/day)	Valacyclovir	Macular edema	20/25
8	24	180873	Acyclovir then foscarnet + ganciclovir	31 (10+21)	Ganciclovir + foscarnet	25	PPR (CRAO)	No	No	Valacyclovir	CRAO (at presentation)	LP
9	4	6100000	Acyclovir	21	Ganciclovir	2	No	No	AP * (aspirin 75mg/day)	Valacyclovir		LP
10	13	400000	Foscarnet	28	Ganciclovir	14	Yes	Yes	AP (aspirin 75mg/day)	Valacyclovir	Macular edema, macular epiretinal membrane	20/100
11	5	2000000	Acyclovir then ganciclovir + foscarnet	43 (2+41)	Ganciclovir	4	No	Yes	AP * (aspirin 250mg/day)	Valganciclovir	Macular epiretinal membrane	20/63
12	11	1310000	Acyclovir	21	Ganciclovir + foscarnet	13	No	No*	No	Valacyclovir		20/100
13	1	478327	Acyclovir	15	Foscarnet	1	No	Yes	AC (15 days)	Valacyclovir		20/25
14	1	10300	Acyclovir	15	0	0	No	Yes	AP (aspirin 75mg/day)	Valacyclovir		20/32
15	4	3302232	Acyclovir	21	Foscarnet	5	No	No*	AP * (aspirin 75mg/day)	Valacyclovir		20/63
16	17	2700000	Foscarnet then acyclovir	30 (15+15)	Ganciclovir	28	No	No	AP (aspirin 75mg/day)	Valacyclovir	RD (2 nd day)	20/100
17	11	185000	Acyclovir	28	Ganciclovir	13	No	Yes	AP (aspirin	Valacyclovir		20/125

					then foscarnet (G7/F6)				75mg/day)			
18	18	50000	Acyclovir	26	Ganciclovir	18	No	No	No	Valacyclovir	Optic atrophy	LP
19	8	305000	Acyclovir then foscarnet + acyclovir	48 (24+24)	Ganciclovir	9	No	Yes	AC * (LMWH)	Valacyclovir		HM
20	8	2400	Acyclovir	24	Ganciclovir	8	No	No	No	Valacyclovir	RD (4 th month)	20/25
21	1	88400	Acyclovir	15	0	0	No	Yes	AP (aspirin 75mg/day)	Valacyclovir	Macular edema	20/25
22	1	3010	Acyclovir	15	0	0	No	Yes	No	Valacyclovir		20/20
23	6	213592	Ganciclovir	21	Foscarnet	6	No	No	No	Valganciclovir		20/20
24	10	560000	Ganciclovir	21	Foscarnet	9	No	No	No	Valganciclovir		20/100

qPCR: real-time PCR; IV: intravenous; IVT: intravitreal injection; VA: visual acuity; HM: hand motion; LP: light perception; RD: retinal detachment; PPR (panretinal photocoagulation); G: ganciclovir; F: foscarnet; CRAO: central retinal artery occlusion; *: usual treatment; OD: ocular dexter; OS: ocular sinister; LMWH: Low molecular weight heparin

Table 3. Retinal detachment rates reported in the literature

Publication date	Author(s)	Number of eyes	RD rate
1982	Fisher et al. ³¹	41	50%
1989	Clarkson et al. ³²	32	50%
1991	Matsuo et al. ³³	26	50%
1993	Crapotta et al. ³⁴	13	23%
1998	Abe et al. ¹³	12	50%
2004	Tran et al. ³⁵	46	17.7%
2004	Chau Tran et al. ³⁶	12	41.7%
2004	Morel et al. ³⁷	22	50%
2007	Lau et al. ⁷	22	35.3%
2007	Aizman et al. ³⁸	10	37.5%
2007	Muthiah et al. ³⁹	12	75%
2009	Ishida et al. ⁴⁰	18	33%
2009	Sims et al. ⁵	23	39%
2009	Hillenkamp et al. ⁴¹	30	73%
2010	Meghpara et al. ²⁰	25	20%
2010	Wong et al. ⁴²	81	47.0%
2010	Tibbets et al. ²⁴	58	50%
2012	Taylor et al. ⁴³	10	30%
2012	Cochrane et al. ⁴⁴	52	30.8%
2012	Luo et al. ⁴⁵	37	48.0%
2012	Jeon et al. ⁴⁶	63	49.9%
2013	Iwahashi-Shima et al. ⁴⁷	104	33%
2013	Flaxel et al. ⁴⁸	29	45%
2013	Bernheim et al. ¹⁵	6	67%

2014	Roy et al. ⁴	63	66.1%
2015	Winterhalter et al. ¹⁸	35	67%
2016	Huang et al. ⁴⁹	29	45%
2016	Calvo et al. ¹⁴	14	57%
2017	Butler et al. ⁵⁰	41	59%
