



HAL
open science

Ten-year outcomes of cementless anatomical femoral implants after 3D computed tomography planning. Follow-up note

Olivier Tostain, Emmanuel Debuyzer, Kevin Benad, Sophie Putman, Adeline Pierache, Julien Girard, Gilles Pasquier

► To cite this version:

Olivier Tostain, Emmanuel Debuyzer, Kevin Benad, Sophie Putman, Adeline Pierache, et al.. Ten-year outcomes of cementless anatomical femoral implants after 3D computed tomography planning. Follow-up note. *Orthopaedics & Traumatology: Surgery & Research*, 2019, 105, pp.937 - 942. 10.1016/j.otsr.2019.04.019 . hal-03488068

HAL Id: hal-03488068

<https://hal.science/hal-03488068v1>

Submitted on 20 Jul 2022

HAL is a multi-disciplinary open access archive for the deposit and dissemination of scientific research documents, whether they are published or not. The documents may come from teaching and research institutions in France or abroad, or from public or private research centers.

L'archive ouverte pluridisciplinaire **HAL**, est destinée au dépôt et à la diffusion de documents scientifiques de niveau recherche, publiés ou non, émanant des établissements d'enseignement et de recherche français ou étrangers, des laboratoires publics ou privés.



Distributed under a Creative Commons Attribution - NonCommercial 4.0 International License

Ten-Year Outcomes of Cementless Anatomical Femoral Implants after 3D Computed Tomography Planning. Follow-up note.

Olivier **Tostain**^{a,b,*}, Emmanuel **Debuyzer**^{a,b}, Kevin **Benad**^{a,b}, Sophie **Putman**^{a,b}, Adeline **Pierache**^c, Julien **Girard**^{a,b}, Gilles **Pasquier**^{a,b}

^a Service d'orthopédie, département universitaire de chirurgie orthopédique et de traumatologie, hôpital Salengro, CHRU de Lille, place de Verdun, 59037 Lille, France; Faculté de médecine, université Lille-Nord-de-France, 59000 Lille, France

^b Faculté de médecine, université Lille-Nord-de-France, 59000 Lille, France

^c Unité de Méthodologie - Biostatistique et Data Management –Maison Régionale de la Recherche Clinique - CHRU de Lille, Lille, France

***Corresponding author:** Olivier Tostain, Département universitaire de chirurgie orthopédique, service d'orthopédie C et D, hôpital Roger-Salengro, université Lille-2, CHRU de Lille, 59037 Lille Cedex, FRANCE

E-mail: oliviertostain@orange.fr

ABSTRACT

Background: Pre-operative 3D planning based on computed tomography (CT) imaging is used to optimise the restitution of normal hip anatomy during primary total hip arthroplasty (THA). Although CT planning has been proven effective and reproducible, its influence on long-term THA outcomes is unknown. In this 10-year follow-up study of patients managed with the same technique of CT-planned primary anatomical THA, the objectives were to assess femoral implant survival, long-term functional outcomes, 10-year outcomes of titanium modular femoral necks, and associations with the dislocation rate.

Hypothesis: Pre-operative CT planning of primary THA ensures achievement of the NICE criterion of a lower than 5% femoral revision rate within 10 years.

Material and Methods: The study included 61 patients (61 hips) managed between 2004 and 2007 by CT-planned primary THA via the posterior approach, with an uncemented anatomical femoral component (SPS[®], Symbios); when deemed necessary by the surgeon to restore normal anatomy, a titanium modular femoral neck was used (35/61 patients). After 10 years, 17 patients had died and 3 were lost to follow-up, leaving 41 patients with a mean age of 76 years (range, 60-91 years) for re-evaluation. Clinical outcomes were assessed by determining the Harris Hip Score (HHS) and the Postel-Merle d'Aubigné (PMA) score, which were compared to baseline values. Radiographs were evaluated using the AGORA Roentgenographic Assessment system (ARA).

Results: The 10-year femoral component survival rate was 96% (95%CI, 88;99%). Revision was required in 4 patients, to treat delayed peri-prosthetic fractures (n=2) or to correct initial cup malposition (n=2). No changes occurred from 2010 to last follow-up in the mean HHS (90 [95%CI, 84;95] and 91 [95%CI, 77;96], respectively) or mean PMA score (16 [95%CI, 14;17] and 15.5 [95%CI, 14;16.5], respectively). The mean ARA score was 5.2 (range, 3-6) at

last follow-up. No complications related to the use of modular femoral necks were recorded. Dislocation occurred in 2 patients, but in neither was the pre-operative plan followed during surgery.

Discussion: The SPS[®] stem produced good 10-year clinical and radiographic outcomes. No patients experienced complications related to use of a titanium modular femoral neck. The restoration of anatomical hip geometry made possible by pre-operative CT planning provided sustained clinical improvements with a low complication rate.

Level of evidence : IV, retrospective observational cohort study

Key words: Total hip arthroplasty. Anatomical femoral implant. HIP. Pre-operative 3D planning. Computed tomography.

1. Introduction

Pre-operative 3D planning based on computed tomography (CT) imaging is used to optimize the restoration of normal hip anatomy during total hip arthroplasty (THA). Although CT planning has been proven effective and reproducible [1], its influence on long-term THA outcomes is unknown. Modular femoral necks in combination with 3D CT planning were introduced recently to improve the match with native hip geometry in each individual patient [2,3]. However, their use remains limited and highly controversial [4–6]. In 2010, we reported on the changes in femoral offset induced by THA as measured using a CT evaluation protocol [7].

To the best of our knowledge, only few studies have assessed functional outcomes after CT-planned THA [8]. Moreover, their follow-up durations were less than 10 years, and none evaluated functional score changes over time. Therefore, to extend our 2010 findings [7], we conducted a second study, in 2017, in the same patient population managed with primary anatomical THA. The objectives were to assess femoral implant survival, long-term functional outcomes, 10-year outcomes of titanium modular femoral necks, notably those with a large offset or long varus configuration, and associations with the dislocation rate. The working hypothesis was that pre-operative 3D CT planning ensured achievement of the NICE criterion of a lower than 5% femoral revision rate within 10 years [9].

2. Material and Methods

2.1. Patients

The initial retrospective cohort was composed of 61 patients managed with unilateral primary THA between September 2004 and March 2007. **Figure 1** is the patient flow chart. At

re-evaluation in 2017, 17 patients had died and 3 were lost to follow-up. **Tables 1 and 2** report the main patient characteristics and list the inclusion and exclusion criteria.

2.2 Methods

In all 61 patients, the same surgeon (GP) performed unilateral primary THA via the postero-lateral approach, with capsular suturing. Pre-operative 3D CT planning was performed using HipPLAN software (Symbios, Yverdon-les-Bains, France). Based on the results, the size of the femoral component and most appropriate type of femoral neck were determined. The femoral component was the anatomical SPS[®] (Symbios, Yverdon, Switzerland) made of a titanium alloy with hydroxyapatite coating of the metaphyseal surface. This component was available as a monoblock version and as a modular version with a titanium Morse taper. The modular version was chosen when deemed necessary by the surgeon to restore native hip anatomy [7], i.e., in 35 patients, including 24 who received a long varus neck and 11 a short varus neck. The goal was to restore normal, or to correct abnormal, native offset and lengths, as appropriate. **Table 3** reports data on hip reconstruction accuracy.

We did not evaluate the outcomes of the acetabular component, as the bearing couple was metal-polyethylene in some patients and ceramic-polyethylene in others. A single-mobility hydroxyapatite-coated cup was used. Femoral head diameter was 28 mm.

2.3 Assessment methods

The patients were re-evaluated in 2017 by an assessor who had not been involved in performing the THA procedures. Femoral component survival was assessed using femoral revision as the criterion for failure. The Harris Hip Score (HHS) [10], Postel-Merle-D'Aubigné (MPA) score [11], and Oxford Hip Score (OHS) [12] were determined and the

values compared to those obtained in 2010. The radiographs included an antero-posterior pelvic view and antero-posterior and lateral views of the hip in each patient. Two observers used the AGORA Roentgenographic Assessment system (ARA) [13] to assess the radiographs.

2.4. Statistical analysis

Qualitative variables were described as n (%), normally distributed quantitative variables as mean \pm SD, and non-normally distributed quantitative variables as median [interquartile range]. Distribution normality was assessed graphically and by applying the Shapiro-Wilk test.

The cumulative incidence of femoral revision was estimated using the method devised by Kalbfleisch and Prentice and a competing-risks model in which death with no revision was the competing risk. Changes in clinical and radiographic variables over time were evaluated using the Wilcoxon test for paired samples. The statistical analyses were done using SAS version 9.4 software (SAS Institute, Cary, NC, USA). All tests were two-sided, and *p* values smaller than 0.05 were taken to indicate significant differences.

3. Results

The 10-year femoral component survival rate was 96% (95% confidence interval [95%CI], 88%;99%) (Figure 2). No significant changes occurred between 2010 and 2017 in the median HHS (90 [95%CI, 84;95] and 91 [95%CI, 77;96], respectively; *p*=0.49) or median PMA score (15.5 [95%CI, 14;16.5] and 16 [95%CI, 14;17], respectively; *p*=0.078). At last follow-up, the median OHS was 17.2/60 (95%CI, 15;19); the highest value was 12.

None of the re-evaluated patients reported thigh pain. The data in Table 4 illustrate the stability of the hip scores between 2010 and 2017.

Full sets of radiographs taken at last follow-up were available for 40 of the 41 patients. The mean ARA score at last follow-up was 5.2 (range, 3-6) and was not significantly different from the mean value in 2010 (Table 3). A stable area of bridging sclerosis at the tip of the femoral component with no surrounding radiolucent line was visible in 4 patients. Spot welding was seen in zones 2 and 6 in 11 (27.5%) patients. No patient had evidence of stress shielding or cortical thinning over the femoral component (Figure 3).

A modular femoral neck was used in 35 of the 41 patients, including 24 who received the long varus and 11 the short varus variant. No failures of either type of modular femoral neck were recorded during follow-up.

Femoral component revision was required in 3 patients. Among them, 2 experienced peri-prosthetic fractures due to falls 18 months and 10 years post-operatively. Both patients were managed by bipolar revision. The remaining patient required bipolar revision 6 years post-operatively due to recurrent dislocation.

Dislocation occurred in 2 (3%; 95%CI, 1.3%-7.3%) patients. One was the above-mentioned patient who required bipolar revision due to anterior dislocation 6 months post-operatively. The other patient had the cup replaced by a dual-mobility cup 4 years post-operatively due to posterior dislocation, with the femoral component left in place. In the patient with anterior dislocation, cup anteversion was 45° instead of the planned 23°, and femoral anteversion was 30° instead of the planned 20°. The posterior cam effect and recurrent dislocation had resulted in polyethylene wear. In the patient with posterior dislocation, the planned targets had not been met either (cup anteversion was 17° instead of the planned 25°). This patient reported a feeling of hip instability as early as 1 year post-operatively.

In 2 patients, prosthetic joint infection developed, before 2010, 3 and 48 months post-operatively. The causative organism was *Proteus mirabilis* in the first case and a streptococcus in the second case. Both patients recovered fully after simple irrigation and appropriate antibiotic therapy.

4. Discussion

The anatomical SPS[®] femoral component implanted after 3D CT planning produces good long-term outcomes and meets the NICE criterion of a less than 0.5% femoral revision rate per year. Importantly, the 96% 10-year femoral component survival rate was computed with death as a competing risk, to factor in the high 10-year mortality rate in our population. The findings from our 2010 study [7] demonstrated benefits from using a modular femoral neck combined with pre-operative 3D CT planning to restore large offsets. We therefore felt it was important to obtain data on implant survival and long-term outcomes after THA using a modular femoral neck. The follow-up data reported here indicate that the good early functional outcomes found in the earlier study are sustained over time. Similar results were obtained by Sariali et al. [8] and Mouttet et al. [14] using the same implant and 3D planning method but different surgical approaches (Table 5, [15,16,17]). The outcomes in our population are comparable to those in other case-series studies of primary uncemented THA (Table 5).

Our 2010 study [7] focussed on restoration of normal hip geometry. Here, the 10-year radiographic outcomes indicate good implant fixation in the long term. Ramaniraka et al. [18] suggested that the extra-medullary design of an uncemented femoral component (anteversion and retroversion, neck varus and valgus) may significantly influence fixation quality of the intra-medullary part of the stem.

Sariali et al. [19] highlighted the importance of proximal femoral anatomy, notably anterior metaphyseal flare, when using short stem designs. The SPS[®] stem used in our patients features 15° of proximal helitorsion and 42° of lateral flare, which, combined with the greater antero-posterior bulk compared to straight stems, increases stability by providing good intra-medullary contact, thereby ensuring strong long-term fixation.

None of the re-evaluated patients reported thigh pain. The radiographic outcomes were good, as shown by the high ARA scores. No radiographic evidence of stress shielding or distal fixation was observed [20]. We believe that the anatomical metaphyseal fixation of the SPS[®] stem ensures physiological load transfer to the cancellous bone, thereby optimising bone remodelling [21] and minimising stress shielding [22] and the attendant thigh pain [20]. In a study by Flecher et al. of patients younger than 50 years of age [23] in which the stem was custom-made based on CT modelling, no instances of thigh pain were recorded. These data support the possibility that tailoring the stem to the intra-medullary femoral geometry may minimise thigh pain [8]. Furthermore, work by Flecher et al. [23-24] showed good outcomes with custom-made stems designed with HipPLAN software, which was also used in our study.

The dislocation rate in our population was consistent with earlier reports of dislocation in 2% to 5% of cases [25–27]. In both patients with dislocation in our study, implant version differed from the intended value determined by pre-operative planning. In most of our patients, a modular titanium neck was used. In the initial cohort [7], a long varus femoral neck was often combined with a short or medium-length stem to adapt to this common anatomical characteristic. No complications related to modular long varus femoral necks were recorded in our patients.

Modular femoral neck implants have been blamed for metal wear particle production, implant fractures, corrosion, allergic reactions, and fluid-filled pseudo-tumours [6,28,29]. A

2017 meta-analysis by Colas et al. [4] showed shorter survival with modular necks compared to monoblock necks. No fractures or signs of osteolysis possibly related to corrosion were noted in our patients. However, our patients did not undergo blood metal assays or ultrasonography. Nonetheless, of the 35 patients with modular necks, 32 were completely free of pain. Corrosion is usually responsible for pain or osteolysis. Thus, the existence of corrosion in our patients with a follow-up of at least 10 years is unlikely. The absence of femoral neck fractures in our patients may be ascribable to the avoidance of extreme constructs (long varus neck and long femoral head augment), which were deemed excessively hazardous, and to the unavailability of 16-mm varus necks at the beginning of the study period.

The limitations of our study include the high mortality rate ascribable to the compromised health status of many patients at the time of surgery. Thus, 25 patients had an American Society of Anesthesiologists score ≥ 3 , and among them 9 died before the 2017 re-evaluation. Finally, differences in the bearing couple of the acetabular component precluded an assessment of the acetabular cup.

5. Conclusion

The SPS[®] stem met the NICE criterion, provided good 10-year functional outcomes, and remained stable over time. In 2010, Pasquier et al. [7] reported the use of 3D CT planning combined with implantation of a modular neck to restore native offset, including long varus necks in some patients. At present, the use of modular necks remains extremely limited. Nevertheless, none of our patients experienced any of the complications classically ascribed to modular necks. One possibility is that 3D CT planning optimised the use of modular necks.

We are not aware of any studies comparing long-term outcomes after 2D versus 3D planning. Such a comparison in a large population would be of interest.

Disclosure of interest

None of the authors has any conflicts of interest to declare in relation with this study.

Financial ties unrelated to this study are as follows: GP is an education and research consultant for Zimmer-Biomet, SP is an education and research consultant for Corin-Tornier, and JG is a consultant for Microport and Smith&Nephew. None of the other authors has any financial ties unrelated to this study.

Funding

None

Contributions of each author

O. Tostain and K. Benad re-evaluated the patients in 2017 and reviewed the radiographs.

G. Pasquier performed the total hip arthroplasties.

A. Pierache performed the statistical analysis.

S. Putman, E. Debuyzer, and J. Girard contributed to draft and revise the manuscript.

References

1. Sariali E, Mauprivez R, Khiami F, Pascal-Mousselard H, Catonné Y. Accuracy of the preoperative planning for cementless total hip arthroplasty. A randomised comparison between three-dimensional computerised planning and conventional templating. *Orthop Traumatol Surg Res* 2012;98:151-58.
2. Miki H, Sugano N. Modular neck for prevention of prosthetic impingement in cases with excessively anteverted femur. *Clin Biomech Bristol Avon* 2011;26:944-49.
3. Matsushita A, Nakashima Y, Fujii M, Sato T, Iwamoto Y. Modular necks improve the range of hip motion in cases with excessively anteverted or retroverted femurs in THA. *Clin Orthop Relat Res* 2010;468:3342-7.
4. Colas S, Allalou A, Poichotte A, Piriou P, Dray-Spira R, Zureik M. Exchangeable femoral neck (dual-modular) tha prostheses have poorer survivorship than other designs: A nationwide cohort of 324,108 patients. *Clin Orthop Relat Res* 2017;475:2046-59.
5. Collier JP, Mayor MB, Williams IR, Surprenant VA, Surprenant HP, Currier BH. The tradeoffs associated with modular hip prostheses. *Clin Orthop Relat Res* 1995;311:91-101.
6. Ghanem E, Ward DM, Robbins CE, Nandi S, Bono JV, Talmo CT. Corrosion and adverse local tissue reaction in one type of modular neck stem. *J Arthroplasty* 2015;30:178-93.
7. Pasquier G, Ducharne G, Ali ES, Giraud F, Mouttet A, Durante E. Total hip arthroplasty offset measurement: is CT scan the most accurate option? *Orthop Traumatol Surg Res* 2010;96:367-75.
8. Sariali E, Mouttet A, Mordasini P, Catonné Y. High 10-year survival rate with an anatomic cementless stem (SPS). *Clin Orthop Relat Res* 2012;470:1941-9.

9. Roberts VI, Esler CN, Harper WM. What impact have NICE guidelines had on the trends of hip arthroplasty since their publication? The results from the Trent Regional Arthroplasty Study between 1990 and 2005. *J Bone Joint Surg Br* 2007;89:864-7.
9. Mak PH, Campbell RC, Irwin MG, American Society of Anesthesiologists. The ASA Physical Status Classification: inter-observer consistency. *American Society of Anesthesiologists. Anaesth Intensive Care* 2002;30:633-40.
10. Harris WH. Traumatic arthritis of the hip after dislocation and acetabular fractures: treatment by mold arthroplasty. An end-result study using a new method of result evaluation. *J Bone Joint Surg Am* 1969;51:737-55.
11. Merle D'Aubigné R. Numerical classification of the function of the hip. 1970. *Rev Chir Orthop* 1990;76:371-4
12. Delaunay C, Epinette J-A, Dawson J, Murray D, Jolles B-M. Cross-cultural adaptations of the Oxford-12 HIP score to the French speaking population. *Orthop Traumatol Surg Res* 2009;95:89-99.
13. Epinette JA. Radiographic assessment of cementless hip prostheses: The "ARA" scoring system. *Eur J Orthop Surg Traumatol* 1999;9:91-4.
14. Mouttet A, Philippot R, Farizon F, Vallotton P-H, Ibnou-Zekri N. [Five-year follow-up of a hydroxyapatite coated stem]. *Rev Chir Orthop* 2008;94:746-52.
15. Delaunay CP, Putman S, Puliéro B, Bégin M, Migaud H, Bonnomet F. Cementless total hip arthroplasty with metasul bearings provides good results in active young patients: A concise followup. *Clin Orthop Relat Res* 2016;474:2126-33.
16. Epinette J-A, Asencio G, Essig J, Llagonne B, Nourissat C. Clinical results, radiological findings and survival of a proximally hydroxyapatite-coated hip ABG II stem at a minimum of ten years' follow-up: results of a consecutive multicentre study of 1148 hips in 1053 patients. *Bone Joint J* 2013;95:1610-6.

17. Bidar R, Kouyoumdjian P, Munini E, Asencio G. Long-term results of the ABG-1 hydroxyapatite coated total hip arthroplasty: analysis of 111 cases with a minimum follow-up of 10 years. *Orthop Traumatol Surg Res* 2009;95:579-87
18. Ramaniraka NA, Rakotomanana LR, Rubin PJ, Leyvraz P. Noncemented total hip arthroplasty: influence of extramedullary parameters on initial implant stability and on bone-implant interface stresses. *Rev Chir Orthop* 2000;86:590-7.
19. Sariali E, Knaffo Y. Three-dimensional analysis of the proximal anterior femoral flare and torsion. Anatomic bases for metaphyseally fixed short stems design. *Int Orthop* 2017 41:2017-23.
20. Naumann T, Buchner F, Eckardt V. Pain in the thigh following Zweymüller's total endoprosthesis: computerized tomography studies of the morphological behavior of the metadiaphyseal femur. *Z Orthop Ihre Grenzgeb.* 1987;125:664-8.
21. Chen HH, Morrey BF, An KN, Luo ZP. Bone remodeling characteristics of a short-stemmed total hip replacement. *J Arthroplasty* 2009;24:945-50.
22. Kerner J, Huiskes R, van Lenthe GH, Weinans H, van Rietbergen B, Engh CA, Amis AA. Correlation between pre-operative periprosthetic bone density and post-operative bone loss in THA can be explained by strain-adaptive remodelling. *J Biomech* 1999;32(7):695-703.
23. Flecher X, Parratte S, Aubaniac JM, Argenson JN. Three-dimensional custom-designed cementless femoral stem for osteoarthritis secondary to congenital dislocation of the hip. *J Bone Joint Surg Br.* 2007 ;89:1586-91.
24. Flecher X, Ollivier M, Maman P, Pesenti S, Parratte S, Argenson JN. Long-term results of custom cementless-stem total hip arthroplasty performed in hip fusion. *Int Orthop* 2018;42:1259-1264
25. Morrey BF. Difficult complications after hip joint replacement. Dislocation. *Clin Orthop Relat Res* 1997;344:179-87.

26. Hutten D. Luxations et subluxations des prothèses totales de hanche. Conférences Enseign SOFCOT N°55, Elsevier. 1996, pp 19-46.
27. Malchau H, Herberts P, Eisler T, Garellick G, Söderman P. The Swedish Total Hip Replacement Register. J Bone Joint Surg Am 2002;84:2-20.
28. Canham CD, Muradov PI, Simpson JB, Incavo SJ. Corrosion and adverse local tissue reaction after total hip arthroplasty with a modular titanium alloy femoral neck. Arthroplasty Today 2017;3:211-4.
29. Wright G, Sporer S, Urban R, Jacobs J. Fracture of a modular femoral neck after total hip arthroplasty: a case report. J Bone Joint Surg Am 2010;92:1518-21.

FIGURE LEGENDS

Figure 1: Patient flow chart, starting with the 61 patients in the initial cohort study

Figure 2: Plot of femoral component survival, with death as a competing risk

Figure 3: Hip radiograph taken 10 years after primary total hip arthroplasty -- Modular SPS[®]
stem

Table 1: Main features of the study population – inclusion and exclusion criteria

Variable	Value
N of patients in the initial cohort	61
Males/Females	16 / 45
Age at THA, years, mean (range)	74 (44-83)
Body mass index, kg/m ² , mean	30.5
Body mass index >30, n	32
ASA score [9], median [IQR]	2 [1- 4]
N of re-evaluated patients	41
N of patients who died during FU	17
N of patients lost to FU	3
Age at re-evaluation, years, mean (range)	76.1 (60-91)
Inclusion criteria	Primary hip OA, no requirement for concomitant osteotomy (pelvis or femur), pre-operative CT planning stabilising feasibility (no extreme sizes, no extreme modular neck constructs)
Exclusion criteria	THA for developmental dysplasia, history of hip infection, history of hip injury, pre-operative CT planning showing doubtful results or suggesting hazards (construct requiring an extreme neck, extreme size), osteopenia

THA, total hip arthroplasty; ASA, American Society of Anesthesiologists; FU, follow-up; OA, osteoarthritis

Table 2: Reasons for primary total hip arthroplasty

Reason	N	%
Primary hip OA	55	90
OA complicating moderate dysplasia	4	7
Avascular necrosis	1	1.5
Residual fracture deformity	1	1.5

OA, osteoarthritis

Table 3: Changes from before to after surgery in femoral offset, femoral anteversion and lengths

Population	Pre-operative femoral offset, mm, mean±SD (range)	N of patients	Post-operative femoral offset, mm, mean±SD (range)	Difference, mm, mean±SD
Overall	42.90 ± 5.43 (31-55)	61	44.68 ± 6.29 (2857)	1.88 ± 4.71
Long varus neck	45.54 ± 5.27 (32-55)	24	48.58 ± 3.86 (41-57)	3.04 ± 3.92
Short varus neck	42.27 ± 4.27 (34-49)	11	42.73 ± 4.84 (3549)	0.45 ± 4.08
Straight neck	40.63 ± 5.04 (31-51)	26	41.89 ± 6.65 (2856)	1.26 ± 5.54
	Pre-operative femoral anteversion, °, mean±SD		Post-operative femoral anteversion, °, mean±SD	Difference, °, mean±SD
Overall	24.29° ± 9.39	61	25.94 ± 10.35	2.07±4.39
	Pre-operative length, mm, mean±SD (range)		Post-operative length, mm, mean±SD (range)	Difference, mm, mean±SD
Overall (population with available data)	751 ± 48 (650-869)	58	753 ± 48 (655-870)	1.66 ± 5.63

Table 4: Harris Hip Score (total and individual items), Postel-Merle d’Aubigné score, and AGORA Roentgenographic Assessment score before surgery then 5 and 10 years later

Parameters	Before surgery,	After 5 years,	After 10 years,	<i>p</i> value	
	median [IQR] (n = 61)	median [IQR] (n = 54)	median [IQR] (n = 41)	<i>p</i> value 2010 vs. 2017	pre- operative vs. 2017
Total HHS [10]	43 [35-50]	90 [84-95]	91 [77-96]	0.497	<0.0001
HHS, pain	10 [10-20]	40 [40-44]	40 [40-44]	0.476	<0.0001
HHS, walking	18 [12-18]	29.5 [24-33]	30 [23-33]	0.093	<0.0001
HHS, activity	7 [7-9]	12 [11-14]	11 [9-13]	0.082	<0.0001
HHS, mobility	4 [3-5]	9 [8-10]	6 [6-6]	0.031	<0.0001
PMS score [11]	8.5 [7-10]	16 [14-17]	15.5 [14-16.5]	0.078	<0.0001
Score ARA [13]		5.3 [4-6]	5.2 [4-6]	0.442	

IQR, interquartile range; HHS, Harris Hip Score; PMS, Postel-Merle d’Aubigné; ARA, AGORA Roentgenographic Assessment

Table 5: Long-term outcomes of uncemented femoral stems in previous studies and our study

Authors	Femoral implant	Mean FU, years	Population	Survival (% at last FU)	Mean HHS
Our study	SPS Symbios	10	61	96	91
Mouttet et al. [14]	SPS Symbios	5	176	98.8	93.1
Sariali et al. [8]	SPS Symbios	10	171	97	90
Migaud et al. [15]	Alloclassic-SL	15	83	96	-
Epinette et al. [16]	ABG II	10	1053	99.7	94.7
Bidar et al. [17]	ABG I	13	111	94.3	87.3

FU, follow-up; HHS, Harris Hip Score

Figure 1 : Study flowchart about the 61 patients of initial publication.

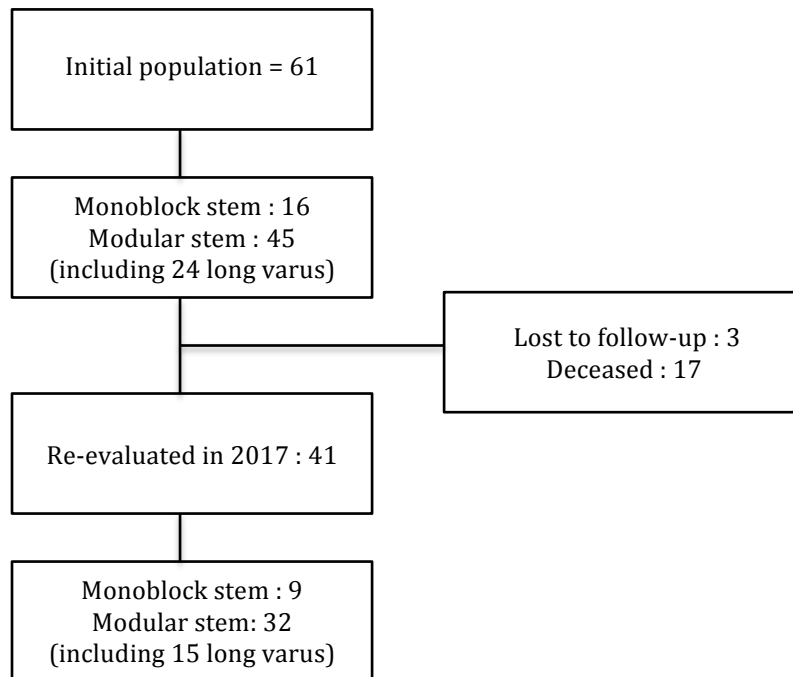


Figure 2 : Survival curve of the stem, decease considered as competitor event.

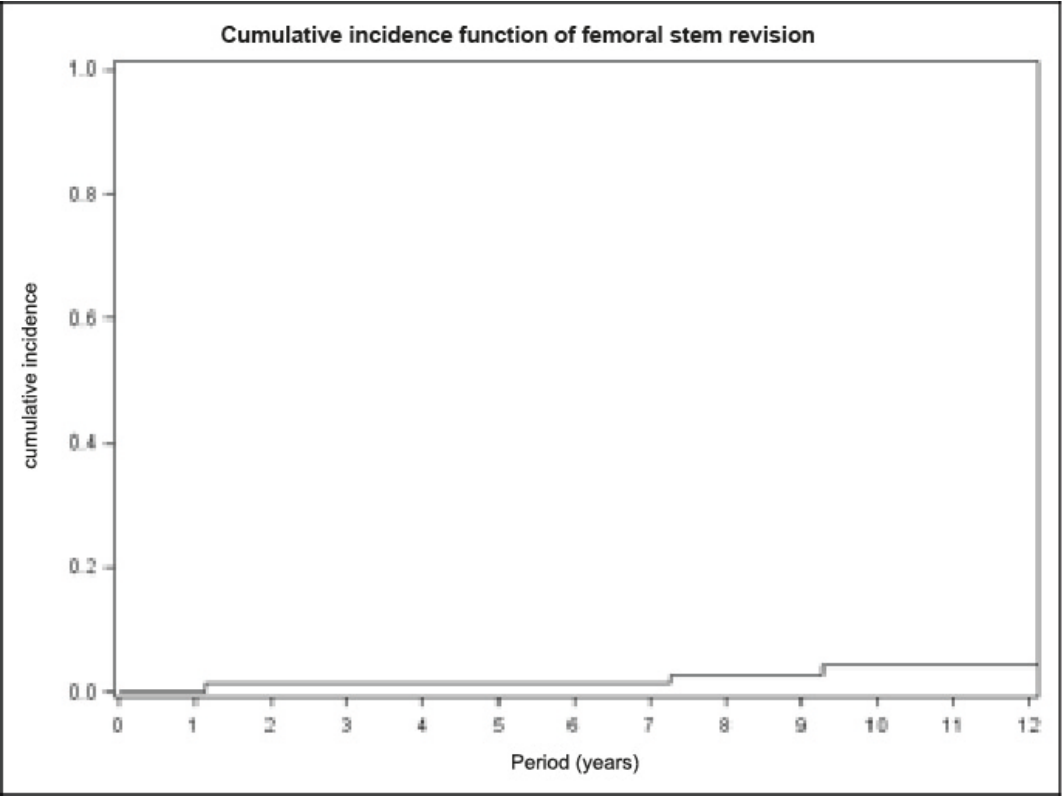


Figure 3 : Radiographic results at ten years. SPS modular stem.

