



HAL
open science

Orthopaedic surgery for patients with central nervous system lesions: Concepts and techniques

F. Genêt, P. Denormandie, M.A. Keenan

► To cite this version:

F. Genêt, P. Denormandie, M.A. Keenan. Orthopaedic surgery for patients with central nervous system lesions: Concepts and techniques. *Annals of Physical and Rehabilitation Medicine*, 2019, 62, pp.225 - 233. <10.1016/j.rehab.2018.09.004>. <hal-03488067>

HAL Id: hal-03488067

<https://hal.science/hal-03488067v1>

Submitted on 20 Dec 2021

HAL is a multi-disciplinary open access archive for the deposit and dissemination of scientific research documents, whether they are published or not. The documents may come from teaching and research institutions in France or abroad, or from public or private research centers.

L'archive ouverte pluridisciplinaire HAL, est destinée au dépôt et à la diffusion de documents scientifiques de niveau recherche, publiés ou non, émanant des établissements d'enseignement et de recherche français ou étrangers, des laboratoires publics ou privés.



Distributed under a Creative Commons CC BY-NC 4.0 - Attribution - Non-commercial use - International License

Orthopaedic surgery for patients with central nervous system lesions: concepts and techniques

Genêt F^{1,2}, MD, PhD, Denormandie P^{2,3}, MD, Keenan MA, MD⁴

¹ Service de Médecine Physique et de Réadaptation, Hôpital Raymond Poincaré, Assistance Publique – Hôpitaux de Paris, CIC-IT 1429, Garches, France

² Service de Université Versailles Saint Quentin en Yvelines, "End:icap" U1179 INSERM, UFR des Sciences de la Santé – Simone Veil, 2 avenue de la source de bièvres, 78170 Montigny le Bretonneux, France.

³ Chirurgie orthopédique et traumatologique, Hôpital Raymond Poincaré, Assistance Publique – Hôpitaux de Paris, CIC-IT 1429, Garches, France

⁴ Penn Neuro-Orthopaedics Service, University of Pennsylvania, Philadelphia, PA, USA

Corresponding Author: **Pr François Genêt**
Service de Médecine Physique et de Réadaptation
CHU R.Poincaré
104 Bd R.Poincaré
9230 Garches, France
Tel 01.47.10.70.70
Fax 01.47.10.70.73
email: francois.genet@aphp.fr

Abstract

Since ancient times, the aim of orthopedic surgery has been to correct limb and joint deformities, including those resulting from central nervous system lesions. Recent developments in the treatment of spasticity have led to changes in concepts and management strategies. The increase in life expectancy has increased the functional needs of patients. Orthopedic surgery, along with treatments for spasticity, improves the functional capacity of patients with neuro-orthopaedic disorders, improving their autonomy. In this paper, we describe key moments in the history of orthopedic surgery regarding the treatment of patients with central nervous system lesions, from poliomyelitis to stroke-related hemiplegia, from the limbs to the spine, and from contractures to heterotopic ossification. A synthesis of the current surgical techniques is then provided, and the importance of multidisciplinary evaluation and management is highlighted, along with indications for medical, rehabilitation and surgical

treatments and their combinations. We explain why it is essential to consider patients' expectations and to set achievable goals, particularly before surgery, which is by nature irreversible. More recently, specialized surgical teams have begun to favor the use of soft-tissue techniques over bony and joint procedures, except for spinal disorders. We highlight that orthopedic surgery is no longer the end-point of treatment. For example, lengthening a contracted muscle improves the balance around a joint, improving mobility and stability but may be only part of the problem. Further medical treatment and rehabilitation, or additional surgery, are often necessary to continue to improve the function of the limb. Despite the recognized effectiveness of orthopedic surgery for neuro-orthopedic disorders, few studies have formally evaluated them. Hence, there is a need for research to provide evidence to support orthopedic surgery for treating neuro-orthopedic disorders.

Keywords: orthopaedic surgery, spasticity, neurotomy, neurectomy, hyponeurotization, tendon lengthening, tendon transfer, arthrodesis, heterotopic ossification

Introduction

Orthopaedic surgery to correct limb and joint deformities is not new; one of the first papers dates back to the 18th century, and there are traces of surgical procedures performed in ancient times [1–3]. For patients with central nervous system (CNS) lesions, secondary orthopaedic problems often develop as a result of muscle hypertonicity and paresis. The principles of surgical treatment are to improve muscle balance by lengthening and/or reducing the activity of the muscles that are agonists to the deformity, allowing antagonist muscle activity to be expressed. If the treatment is to be successful, care must be taken to maintain joint mobility and stability (Table). As such, combined techniques involving bony procedures and tendon transfers

or lengthening may be carried out [4]. Techniques to correct deformities have evolved somewhat on a trial and error basis. Some disasters brought about an understanding that certain deformities were actually useful to the patient. This **situation** led to the concept of producing only the changes necessary to improve the patient's function, without totally correcting the deformity [5].

The aim of this paper is to explain the role of orthopedic surgery in the global management of neuro-orthopedic disorders in patients with CNS lesions. We particularly wish to convey that surgery should be considered one of many tools in the armamentaria of rehabilitation and should not be reserved only for deformities that did not respond to non-surgical management.

The history of neuro-orthopaedics

Poliomyelitis. This disease causes lesions in the ventral horn of the spinal cord, leading to muscle weakness, **which in** children, leads to limb deformities during growth. The surgical speciality of neuro-orthopedics had its modern beginnings during the polio epidemics of the 1940s **and 1950s** [5,6]. The complex inter-relationships of numerous deformities and muscle weakness presented a challenge. The need for the collective contributions of multiple health providers became apparent. Surgeons, physiatrists, pneumonologists, physiotherapists, occupational therapists and orthotists had to work in teams for the optimal benefit for the patient.

Surgery to rebalance muscle forces, stabilize a spine or flail joint, or correct limb deformities became common. Physicians gained an understanding of how correcting static deformities **affected** dynamic function. They developed the principles of redirecting muscle forces. Because poliomyelitis is a lower motor neuron (LMN) problem, measurement of active and passive joint range of motion (ROM) and muscle strength were straightforward. Early on, it became clear

that prevention of deformities was paramount to diminish the need for surgical correction and the potential and unnecessary loss of precious muscle strength. Spinal fusions were performed for stabilization [7]. It was important that the patient could sit upright to facilitate respiratory function. A challenge was to avoid prolonged immobilization of the spine in a cast while awaiting fusion. With no internal fixation devices yet developed, the halo vest cast was devised to provide external support and allow for patient mobilization [8]. Other procedures commonly performed to control the knee during the stance phase of gait to compensate the quadriceps paralysis included fusion of the talocrural and subtalar joints to position the foot in equinus [9] and generate an extension force at the knee [10]; soft-tissue interventions such as hamstring muscles transfer [11] or reconstruction of the posterior tissues [12], although success was limited by recurrence; fusion of the knee in a more functional position to improve stability, although this tended to restrict participation [13]; and supracondylar femoral osteotomy to reduce recurvatum by allowing forces to pass in front of the flexion/extension axis of the knee [14]. The other aim of interventions was to control troublesome deformities: knee varus osteotomies and osteotomies and fusion for foot deformities [9,15]. These techniques could be complemented by tendon transfers to rebalance or enhance muscle function [9]: weakness of the triceps surae could be improved by transfer of the extrinsic muscles to the heel (flexor digitorum longus, flexor hallucis longus, fibularis longus); correction of hyper-extension of the hallux improved foot alignment during dorsiflexion, which was further improved with transfer of the extensor hallucis longus tendon to the base of the first metatarsal; and excessive eversion of the foot caused by paralysis of the tibialis anterior muscle could be improved with transfer of the fibulares muscles to the medial side of the foot. Varus deformity resulting from weakness of the foot inverters could be improved by transfer of the extensor hallucis longus or tibialis anterior muscle to the lateral side of the foot.

Cerebral palsy (CP). In the 1940s, Drs. Baker, Banks, and Green, as well as others, noted that too much attention was paid to nonsurgical treatment in children with CP [16–18]. They began to develop surgical procedures to correct deformities in patients with spasticity [19]. From the knowledge and success obtained in polio patients, the clinical evaluations and surgical techniques were then applied to other neurologic disorders such as CP. As with polio, the decisions regarding surgical treatments were based on clinical evaluation. The treatments focused on the lower extremities to enable a patient to walk or to improve the quality of ambulation [16]. Surgeons soon learned that the techniques initially used for polio were less successful because of lack of appreciation of the differences between upper and LMN disorders. Muscle spasticity, muscle activation, the presence or degree of motor control, sensory function, and cognitive abilities presented clinicians with new and more complex challenges. The deformities were a result of multiple muscle forces, which were more difficult to discern. Equinus was treated by surgical lengthening of the Achilles' tendon [5]. Equinovarus with the inversion of the foot was attributed to abnormal activity of the tibialis posterior muscle. For this deformity, the tibialis posterior muscle was transferred or lengthened [20,21]. More severe or rigid varus and valgus deformities of the foot were corrected by bony stabilization [15]. Patients with CP benefited from the development of 3D gait analysis for planning appropriate surgical techniques. Indeed, 3D gait analysis changed the management of all central neurological injuries.

The treatment and follow-up of children with CP provided an understanding of bone and muscle growth and development in the presence of spasticity and paresis. Several orthopedic surgical techniques were proposed, with good results notably for gait. These children reached adulthood with orthopaedic issues that required specific reasoning and management approaches different from those applied to patients who acquired lesions during adulthood. Adults with CP tend to develop arthritis in specific joints because of joint deformities. This in turn exacerbates the joint

deformity to angles that cause pain and loss of function (i.e., increasing knee recurvatum with age).

Stroke and traumatic brain injury (TBI). In the 1970s and 1980s, survival rate and life expectancy after stroke became longer; thus, residual limb deformities and resulting disabilities became apparent. More attention was paid to functional losses. Advances in anesthesia and medical management resulted in more confidence in performing surgery in stroke survivors. Similarly, the 1980s saw the development of more formalized, systematic and invasive trauma care programs. TBIs were common in multiple trauma cases. Initially, little attention was paid to orthopedic injuries as physicians concentrated on injuries to major organs. As survival rates improved with intensive multidisciplinary care, crippling limb deformities became common. Fracture non-unions and malunions, undiagnosed peripheral nerve injuries, the development of contractures and heterotopic ossification caused severe impairments and impediments to rehabilitation. Surgery to correct the orthopedic problems resulting from delayed treatment of the spastic limb deformities often led to a poorer outcome. Even when fracture care was possible soon after injury, spasticity or flaccid paralysis in an uncooperative patient made care extremely challenging.

When a patient had stabilized after stroke or TBI, spastic limb deformities were noted to impair function. The surgical procedures for CP were used to treat the deformities after stroke and TBI [5]. These procedures had variable results. It was then understood that the muscle groups involved in the deformities and the biomechanical presentations were not the same for lesions acquired during adulthood as for lesions acquired at birth or during childhood. In the 1970s and 1980s, instrumented gait analysis and multi-channel dynamic electromyography were developed [22,23]. Application of these technologies greatly enhanced decision making. The timing of muscle activation during walking and other activities provided a more sophisticated

understanding of the nature and cause of deformities as well as compensatory adjustments. Later assessment tools such as motion analysis led to an even greater understanding of function [5].

Tetraplegia. In parallel with all these advances, upper-limb surgery for patients with tetraplegia gained recognition in the early 1970s thanks to the work of Moberg [24], Zancolli [25] and Lamb [26]. Their work formed the basis for the Giens International Classification, which is still used today [27]. The goals of surgery were to produce active elbow extension to improve grasping abilities, wheelchair propulsion and, to a lesser extent, the capacity to transfer [28]. Two techniques were proposed: transfer of the posterior deltoidus on the triceps brachii and transfer of the biceps brachii on the triceps brachii [29]. The second objective was to restore grasping by strengthening the key grip (thumb and index) and the global digito-palmar grip by tendon transfers that had an active or passive (tenodesis effect) effect [29]. These techniques are still used today and measuring patient satisfaction is very important (30). Activity and participation should be particularly evaluated because they may improve markedly, even with small improvements in muscle strength and grip capacity [30].

Following the success of neurotization in patients with peripheral nerve lesions, Benassy, followed by Kiwerski and then Krasuski, demonstrated the feasibility and the effectiveness of transfer of the musculocutaneous nerve to the median nerve for patients with tetraplegia [31–34]. Since these investigations, many more studies, especially in animals, have demonstrated the feasibility and effectiveness of transferring peripheral nerves emerging from above the level of the spinal cord injury to nerves emerging below [35–37].

Heterotopic ossification (HO). HO is the presence of bone in soft tissue where bone does not normally develop; it causes pain and loss of ROM. Guy Patin, a French physician and

philosopher, was the first to describe this phenomenon, in 1692. He described it in children with fibrodysplasia ossificans progressiva [38]. Several descriptions of the disorder were then reported, by Coppnig in 1740, Freke in 1741 and Riedel in 1833. It was not until 1918, when Augusta Klumpke-Déjerine and André Cellier provided a histological, clinical and anatomical description of these ectopic bone formations in soldiers with war-related spinal cord injuries [39,40]. Later, neurogenic HO (NHO) was described in stroke [41], TBI [42], poliomyelitis [43], and tetanus [44]. Attempts have been made to develop prophylactic treatments for NHO. Studies carried out in patients with spinal cord injury provide strong support for the use of non-steroidal anti-inflammatory drugs; however, their use is limited by side effects [45]. Currently, the only treatment for NHO is surgical excision, and there are no guidelines for management of the condition [46]. Surgical excision increases ROM and, importantly, also improves both active and passive function and reduces pain and bedsores. The pathophysiological mechanisms behind the development of NHO are still poorly understood, and medical and clinical treatments are based on the experience of surgical-rehabilitation teams, with no real measure of their effectiveness.

Types of interventions currently performed

Tendon lengthening is the surgical lengthening of a tendon of a contracted muscle. The aim can be to restore function, prevent secondary complications, or modify the function of a muscle. Lengthening a tendon can also reduce focal spasticity by modifying the threshold of the neuromuscular spindle [47]. This procedure is often associated with a partial neurotomy. Medical techniques to lengthen muscles (casting, rehabilitation etc.) are almost exclusively used in children [48] to avoid or postpone surgery because with continued skeletal growth, the muscle tension characteristics will change. Medical techniques are also used in adults but mostly to combine or complete surgical techniques. Different surgical procedures can be carried

out depending on the expected ROM and antagonist activity (e.g., voluntary and mainly involuntary activity masked by the contracture and deformity): simple tenotomy (surgical or percutaneous); intramuscular tendon lengthening, or lengthening of the tendon proper (simple, “Z” performed percutaneously or with sutures); and proximal disinsertion using the Flexor Origin Slide (Page-Scaglietti procedure) [49,50] (Fig. 1). Tendon lengthening can be performed on an upper limb (i.e., tendon fractional lengthening to improve shoulder function in patients with spastic hemiparesis (pectoralis major, latissimus dorsi, teres major) [51] or to treat a closed spastic and contractured hand (flexor carpi radialis, palmaris longus, flexor carpi ulnaris; interossei and abductor digiti minimi; adductor pollicis, interossei palmaris, flexor pollicis brevis; extensor carpi ulnaris) [49,50]. Lower-limb percutaneous tenotomies, developed in the early 19th century are being used again because they are considered safe alternatives to more invasive surgical techniques [52–54]. Very rarely and when there are significant anesthetic or vascular risks, a progressive correction by external fixator can be performed [55,56].

The purpose of **tendon transfers** is to rebalance the forces across a joint or enhance the strength of another muscle. The original biomechanical function of the muscle may or may not be modified. If it is changed, extensive rehabilitation is required to learn new motor control. This is particularly appropriate for peripheral neurological lesions because of no alteration of the central motor command and thus the new control can easily be integrated by the patient. If the muscle is spastic (CNS lesion), the effect of this will automatically transfer to the function allowed by the new insertion. Tendon transfers may be partial or complete (Fig. 2A1). A minimum muscle strength is necessary (MRC score of 4) because one point will be lost after treatment. Clinical assessment of strength is accurate in LMN patients. In most cases, muscle strength cannot be realistically assessed in CNS patients. Spasticity and the impaired volitional muscle activation will obscure the estimation of strength. The inability of a muscle to relax is not the same as strength. It should be assumed that all spastic muscles are weak. Effective

treatments show that the diminution of spasticity will uncover underlying weakness. Transfers can be performed on **an** upper limb (i.e., flexor carpi ulnaris on the back of the hand as “active tenodesis” to help the extension of the wrist) or lower limb (i.e., partial transfer of the tibialis anterior on the fibularis brevis or the lateral surface of the cuboideum to compensate for deformity in "pronation-adduction" of the foot when the synkinetic contraction of the tibialis anterior is triggered during the swing phase of gait [Fig. 2A1 and A2] or the rectus femoris to gracilis muscle transfer with fractional lengthening of the vasti muscles for adults with stiff knee gait [57]). In some cases, a passive transfer (tenodesis) is indicated. This **transfer** is more common in the upper limb (i.e., shortening of the carpus extensors, mainly extensor carpi radialis brevis, to compensate for a wrist "falling" in flexion). Preoperative assessment of the postoperative supposed action of the antagonists or the effect of gravity is essential to avoid recurrence of the deformity.

Associated bone and joint procedures may still be **performed**, but the need for these procedures has decreased with improved early care [5,49,50]. Soft-tissue surgery (tendon and muscle) has become more successful, especially **if performed** early when deformities are mild [5,50]. Soft-tissue surgery is more easily performed and preserves more function and mobility. Bone surgery may require prolonged immobilization and prevent weight bearing. Although uncommon, delayed bone healing or infection can occur. Bony procedures are more frequently **performed** in the lower limb. The most common bony procedure is the triple arthrodesis: fusion of the talocalcaneonavicular, subtalar and calcaneocuboid joints (Fig. 2D1 and D2). A triple arthrodesis is **used** to correct a severely pronated foot. Foot pronation can occur as a result of long-term walking with an uncorrected triceps surae contracture. Loss of function of the tibialis posterior also leads to a pronated foot. Other than resection of **HO**, bony procedures in the upper extremity are far less common. Pronation deformities can be corrected by lengthening the distal tendon of the pronator teres and disinsertion of the pronator quadratus. A forearm supination

deformity can be corrected by re-routing the biceps brachii tendon around the proximal radius. For very severe flexion contractures of the wrist and fingers, resection of the proximal row of the carpal bones (very rarely associated with shortening of the distal radius and/or lengthening of the flexor tendons) and arthrodesis of the wrist may be required [58,59]. Lengthening of the wrist and extrinsic finger flexors may also be performed [17,49,50]. The wrist is immobilized until full bony fusion is obtained. Patients with vascular disorders such as arteriopathy (e.g., after ischemic stroke) and smokers are at increased risk of delayed bone healing and sepsis.

Neurosurgical treatments for spasticity mainly involve neurotomy and DREZotomy. Neurotomy is a partial section of the branches or fascicles of the motor nerve, including motor alpha and gamma fibers, but mostly the proprioceptive Ia, Ib and II fibers, which are the main targets of this technique. Neurotomy has a permanent effect on spasticity, but the induced muscle weakness is reversible because of collateral sprouting [60]. Transient motor nerve block with local anesthetic is nearly always useful to determine the presence of contracture before surgery but also to evaluate the muscle strength, analyze the function of antagonist muscles, and predict the result of a neurotomy. If the causes of the deformity are mixed (spasticity and contracture), neurotomy (to reduce spasticity) can be associated with tendon lengthening or transfer (to reduce contracture) to obtain a full correction. Neurotomy can be proposed as first-line treatment, when the maximum total dose of botulinum toxin has been reached, or if the patient wishes to stop regular injections. DREZotomy involves sectioning the dorsal roots as they enter the spinal cord. It is also not reversible. This procedure is useful for regional spasticity. Although some surgeons still promote the technique, use of intrathecal baclofen may be more appropriate (simpler surgical procedure, short-course of rehabilitation and reversible)[61].

Heterotopic ossification (HO)

Current management of HO involves excision as soon as the patient's function is reduced by stiffness or pain becomes a problem, as long comorbidities are controlled and there is a suitable cleavage plane to remove the bony outgrowth [62–65]. The main limitation of early management is diagnosing the HO [66,67]. The current gold standard for diagnosis is CT (with contrast) with 3D reconstruction and standard X-rays [67] (Fig. 2B1, B2 and B3). Because of the lack of motion, positioning of the limb is limited, so standard radiographs in multiple projections are needed (Fig. 2B1). Radiographs provide important information regarding the relation between HO and neurovascular structures and helps determine the surgical approach [68,69]. Surgical resection of HO is technically challenging. At times, alternate surgical approaches must be used to find the best access to the cleavage plane [68]. Intra-operatively, HO and native bone have the same appearance. Decisions as to which bone should be removed is largely based on the morphology. Intra-operative radiographs can be used to confirm whether the bone in question is HO. Large vessels and nerves may be adherent to or contained within the HO (Fig. 2C1 and C2).

Because we now know that there is no benefit in waiting for the maturation phase of the HO before surgery, serum alkaline phosphatase assay and scintigraphy are no longer recommended [64,65]. The risk of recurrence is not related to the time since the CNS lesion [67], the multisite nature of the HO or extension around a joint [70], or the severity of functional and cognitive deficits [71]. To allow for inflammatory processes to settle and to reduce the risk of recurrence, 1 week of rest and non-steroidal anti-inflammatory drugs, if possible, are recommended after the HO removal. Rehabilitation can then begin gradually with no particular limitations. Another useful alternative is the infiltration of cortisone in the zone where the HO contacts another bony structure (including other part of the HO), causing pain.

Decision-making for orthopaedic surgery

Clinical assessment. Neuro-orthopaedic surgery can only be as successful as the pre-operative assessment is accurate. Deformities that are useful for function and those that are detrimental must be differentiated. Also, whether muscle hypo-extensibility is due to hypertonicity or fixed contracture must be determined. Thorough examination of the antagonist muscles is vital because masked hyper-activity released after surgery can render the surgery unsuccessful. Motor nerve blocks [72–74] or botulinum toxin injection may be useful to fully assess joint motion and the status of adjacent and antagonist muscles. Assessment should be multidisciplinary, including at least surgeons and physiatrists, and often physiotherapists and anaesthetists [49,50]. The examination should include the patient's (and/or caregiver's) needs and expectations. It should also determine the current use of the limb, often underestimated by the patient. For example, an elbow-flexion contracture may be useful to hold a bag against the side, freeing the other hand, and contractures of the extrinsic finger flexors may allow the patient to hold a bicycle handlebar. These functions will no longer be possible after the deformities are corrected. The patient must be aware of this.

The objective examination must include a functional examination to determine how the deformity affects movement [75]. A sound knowledge of functional anatomy is necessary to determine the muscles involved in a deformity. For example, functional analysis of knee extension in weight bearing provides an indication of the function of the quadriceps muscle and also the triceps surae, especially the soleus, and the gluteus maximus (with other secondary knee extensors). In fact, both these muscles extend the knee when the foot is on the ground: the triceps surae extends the tibia on the femur, whereas the gluteus maximus extends the femur on the pelvis.

Determining goals. Once the causes of the deformity have been established, realistic, appropriate goals must then be set and prioritized with the patient and caregivers [50]. Goals can range from **correcting** an adductus of the fifth finger of the hand to facilitate dressing, to complex global surgery of the lower limb to make walking possible. The goal could also be to reduce pain and improve hygiene and appearance. Goal Attainment Scaling is a useful tool to assess the outcome of surgical procedures [50]. The expectations of patients who have been disabled since childhood differ from those of patients who sustained a neurological injury in adulthood. For the former, they have often already undergone many interventions and their expectations are less ambitious than those **with** a CNS injury in adulthood. Patients who have adulthood CNS injuries often wish to become "as before". The goals of surgery and medical treatments are often below their ambitions and thus **we must** spend time educating them **in terms** of realistic expectations [76]. The patient should also be made aware of the time the different procedures and subsequent rehabilitation will take [5].

Failures. The success of neuro-orthopaedic procedures depends on the quality of the preoperative examination. The two main complications are overcorrection, with release of previously masked dystonia of the antagonist muscles, and the recurrence of the deformity by **transferring** a muscle that was too weak or **after** failure of sutures. Associated impairments may also be missed (proximal muscle weakness, cerebellar syndrome, etc.). All the risks of invasive procedures in fragile patients also exist: germs (bacteriuria etc.), vascular impairments and bone loss increase the risk of complications such as sepsis and delayed bone healing.

Botulinum toxin injection as a complement to orthopedic surgery

Botulinum toxin **injection** reduces spasticity but cannot change muscle properties such as viscosity and elasticity that cause hypoextensibility and contracture [77,78]. In this case, orthopedic surgery is the treatment of choice to improve function. However, if botulinum toxin **injection** is unsuccessful, the reason must be determined **before** surgery. The physiatrist should ensure **that** the correct muscle was injected [79], with an appropriate dose [80]. Botulinum toxin can be useful as a clinical test to simulate to a certain extent the effects of reducing muscle activity on the function of the relevant limb segment to ensure **that** the desired effect is achieved [81]. It can help to differentiate between spasticity and true contracture.

Botulinum toxin **injection** can also be used along with surgery. Pre-operative injections can reduce the temporary increase in spasticity caused by pain. They can also reduce the tension on a tendon transfer or lengthening, protecting the repair during the early phase of healing. One advantage of surgery is that if botulinum toxin injection is no longer required in the segment, the dose can be redistributed to other muscles, **thus** increasing its effectiveness on other segments.

Patients with multiple deformities

Patients with multiple deformities often require multiple interventions. If the goal is to improve passive function, all the interventions can usually be carried out simultaneously. However, if the aim is to improve function, interventions should be prioritized. The static and dynamic components of the limitation of the **ROM** of the joint should be considered: if a contracture is involved, this should be corrected first [82]. In our experience, lengthening a shortened tendon can reduce the tonic reflex response to **a** stretch of the muscle, reducing spasticity [47].

If several procedures are required, careful planning is necessary to preserve maximal autonomy in between the interventions and provide appropriate rehabilitation. For example, the late removal of a complex NHO of the elbow with an ankylosis of the joint that requires subsequent arthroplasty (and frequently instability) must often be performed after correction of equinovarus of the foot, so that the patient can use crutches during recovery. An elbow-flexor-pronator contracture should be treated before a wrist flexion contracture to avoid the recurrence of the wrist deformity. A hip-flexor contracture should be treated at the same time as that of a knee-flexor contracture in patients on bedrest to avoid recurrence. Indeed, hip flexor and knee flexor deformities occur simultaneously. Correcting only one of these deformities will allow or require that the other joint remain flexed. Both deformities require correction at the same time whether by medical or surgical techniques. Equally, bilateral equinus deformities should be corrected simultaneously. However, if the deformities are bilateral, and a simultaneous correction of both extremities is envisaged, it is important to consider how the patient will cope during the post-operative period and organise appropriate care.

Postoperative care and rehabilitation

Post-operative care after upper and lower extremity surgery is procedure- and immobilization-dependent (Figure 1). For example, for the upper limb, with tendon lengthening at the shoulder or elbow, active and passive motion can be started immediately. For the elbow, a removable splint may be helpful for pain control for a short period of time. With a biceps brachii suspension procedure performed to correct inferior glenohumeral subluxation, an arm sling is used for 6 weeks. Physiotherapy may begin with gentle passive mobilizations at 1 week post-surgery. For the wrist and hand, splint or cast immobilization is used for fusions until bony union has occurred. Tendon transfers, such as a wrist flexor to a wrist extensor, are protected in a wrist splint for 6 weeks. Intramuscular lengthenings of finger flexor tendons are protected

with a wrist splint for 2 weeks **to** prevent inadvertent over-lengthening, which could occur with wrist hyperextension. Active flexion can be started immediately after surgery. No passive finger extension should be performed to avoid over-lengthening with subsequent weakness of the grasp.

For the lower limb, stiff knee gait may be treated by transfer of the rectus femoris to the gracilis tendon, with a removable knee splint used for pain control. Correction of knee flexion contractures often requires the application of serial casts to obtain full knee extension. If full extension is obtained at the time of surgery, then a removable splint is used to control pain. Active and passive motion of the knee can be started as tolerated.

After bony procedures (arthrodesis or osteotomy), a cast **is** required for 2 months, with total unloading for 1.5 months for the lower limb. If only soft tissue procedures have been carried out, the cast will be required for 35 days, and complete loading will be possible. Botulinum toxin injection 1 month before surgery may be helpful to improve tolerance of casts.

Monitoring of the patient is necessary to ensure **that** postsurgical complications do not occur. For patients who are unable to cooperate or **who** are returning to a facility with limited care and supervision, it is safer to provide more immobilization for a longer period of time.

Appropriate physiotherapy is a major key for success. **The** aim of the medical-surgical treatment of deformities is to alter the alignment and function of limb segments, **so** specialised rehabilitation is an essential component. A relationship of trust must be developed to ensure genuine collaborations for the benefit of patients. Rehabilitation is often necessary before surgery or just after to teach safety and autonomy while the patient is in the cast. One of the goals of physiotherapy is to integrate the new state of the limb into the patient's motor program, **which** requires early, repetitive, intense and multimodal rehabilitation [83] [84].

Level of evidence

The number of manuscripts published on the effectiveness of these techniques **has greatly increased** since the 1950s. As explained above, each decade offers studies on functional treatments of neurological etiologies whose management is progressing or causing public health problems **owing** to the number of survivors affected. Only retrospective and descriptive studies are available regarding the surgical techniques described above. Samples are heterogeneous and often small. Moreover, combined techniques are frequently used, and whether the technique itself has been effective **is unclear. Therefore, the** level of evidence is low. In addition, follow-up is often limited to 6 months. **Some** series of patients **were** evaluated **after** several years, but this mainly concerns **CP**. The idea of these studies was to test the effectiveness of surgical techniques (for spine and limbs) performed in childhood in adulthood. Expertise is essentially clinical and empirical, and the techniques are defended by the surgical teams who created them or **who** regularly **performed** them. However, in clinical practice, physicians and physiotherapists are convinced of the effectiveness of these procedures. Moreover, from an ethical point of view, **performing** prospective, controlled studies **is complicated**. However, studies comparing techniques could be carried out. The use of databases **for** case-control studies, as has been done for **HO**, may be a solution for **evaluating** surgical procedures, especially since the development of tools such as artificial intelligence (i.e., database creation from text file reading).

Conclusion

The aim of neuro-orthopedic surgery in patients with CNS lesions is to correct joint deformities, improve function (active or passive), and increase quality of life. As such, it should not be considered a last resort but as part of the overall management strategy. We believe orthopaedic

surgery should be performed as soon as possible to allow early and intensive rehabilitation to optimise recovery. To ensure success, understanding the patient's and caregiver's expectations is essential. Joint goals based on the patient's needs and what is realistic need to be determined before surgery. Thorough assessment should be performed by a specialist multidisciplinary team to determine the causes of the deformity and plan appropriate surgery. Patients who have undergone successful treatment return with new, more ambitious goals enabled by the improvement in functional capability after the previous intervention.

Conflict of interest. None declared.

Funding Sources: This research did not receive any specific grant from funding agencies in the public, commercial, or not-for-profit sectors.

Figure captions

Figure 1. Characteristics of tendon-muscle lengthening techniques.

Figure 2. Examples of surgical techniques and imagery for neuro-orthopedic deformities. A) tibialis anterior tendon transfer (A1: medialisation; A2: hemi lateral transfer); B) images of heterotopic bilateral hip ossification (B1: X-ray; B2: CT scan; B3: 3D reconstruction CT scan); C) Left anterior femoral neurovascular bundle embedded in the heterotopic ossification (C1: CT scan; C2: 3D CT scan); **D)** Triple arthrodesis of the ankle (D1: diagram of fused joints; D2: lateral X-ray after surgery).

References

- [1] Bouvier M. Mémoire sur la section du tendon d'Achille dans le traitement des pieds-bots. Mém. Académie R. Médecine, vol. VII, 1838.



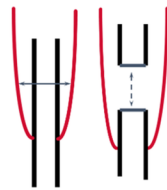
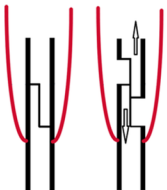
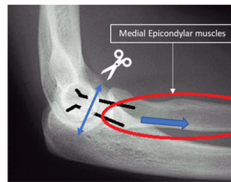
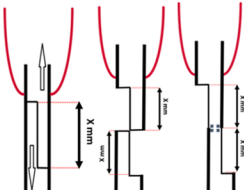
- [2] Hernigou P, Huys M, Pariat J, Jammal S. History of clubfoot treatment, part I: From manipulation in antiquity to splint and plaster in Renaissance before tenotomy. *Int Orthop* 2017;41:1693–704. doi:10.1007/s00264-017-3487-1.
- [3] Hernigou P, Gravina N, Potage D, Dubory A. History of club-foot treatment; part II: tenotomy in the nineteenth century. *Int Orthop* 2017;41:2205–12. doi:10.1007/s00264-017-3578-z.
- [4] van der Krans A, Louwerens JWK, Anderson P. Adult acquired flexible flatfoot, treated by calcaneocuboid distraction arthrodesis, posterior tibial tendon augmentation, and percutaneous Achilles tendon lengthening: a prospective outcome study of 20 patients. *Acta Orthop* 2006;77:156–63. doi:10.1080/17453670610045858.
- [5] Houlden H, Charlton P, Singh D. Neurology and orthopaedics. *J Neurol Neurosurg Psychiatry* 2007;224–32.
- [6] Green WT. Orthopedic management of poliomyelitis. *Pediatr Clin North Am* 1953;35–41.
- [7] Desai SK, Brayton A, Chua VB, Luerssen TG, Jea A. The lasting legacy of Paul Randall Harrington to pediatric spine surgery: historical vignette. *J Neurosurg Spine* 2013;18:170–7. doi:10.3171/2012.11.SPINE12979.
- [8] Godfried DH, Amory DW, Lubicky JP. The halo-Milwaukee brace. Case series of a revived technique. *Spine* 1999;24:2273–7.
- [9] Lindholm R. Subtalar arthrodesis in poliomyelitis. A clinical study on triple arthrodesis with and without simultaneous tendon transfer in 211 adult feet, including some cases of Lambrinudi's arthrodesis for drop-foot. *Ann Chir Gynaecol Fenn Suppl* 1960;49:1–117.
- [10] Genêt F, Schnitzler A, Mathieu S, Autret K, Théfenne L, Dizien O, et al. Orthotic devices and gait in polio patients. *Ann Phys Rehabil Med* 2010;53:51–9. doi:10.1016/j.rehab.2009.11.005.
- [11] Caldwell GD. Transplantation of the biceps femoris to the patella by the medial route in poliomyelitic quadriceps paralysis. *J Bone Joint Surg Am* 1955;37-A:347–53.
- [12] Perry J, O'Brien JP, Hodgson AR. Triple tenodesis of the knee. A soft-tissue operation for the correction of paralytic genu recurvatum. *J Bone Joint Surg Am* 1976;58:978–85.
- [13] Men HX, Bian CH, Yang CD, Zhang ZL, Wu CC, Pang BY. Surgical treatment of the flail knee after poliomyelitis. *J Bone Joint Surg Br* 1991;73:195–9.
- [14] Conner AN. The treatment of flexion contractures of the knee in poliomyelitis. *J Bone Joint Surg Br* 1970;52:138–44.
- [15] Williams PF, Menelaus MB. Triple arthrodesis by inlay grafting--a method suitable for the undeformed or valgus foot. *J Bone Joint Surg Br* 1977;59:333–6.
- [16] Banks HH, Green WT. The correction of equinus deformity in cerebral palsy. *J Bone Joint Surg Am* 1958;40-A:1359–79.
- [17] Green WT, Banks HH. Flexor carpi ulnaris transplant and its use in cerebral palsy. *J Bone Joint Surg Am* 1962;44-A:1343–430.
- [18] Baker LD. A rational approach to the surgical needs of the cerebral palsy patient. *J Bone Joint Surg Am* 1956;38-A:313–23.
- [19] Green WT. Tendon transplantation in rehabilitation. - PubMed - NCBI n.d. <https://www.ncbi.nlm.nih.gov/pubmed/13415882> (accessed February 15, 2018).
- [20] Bisla RS, Louis HJ, Albano P. Transfer of tibialis posterior tendon in cerebral palsy. *J Bone Joint Surg Am* 1976;58:497–500.
- [21] Green NE, Griffin PP, Shiavi R. Split posterior tibial-tendon transfer in spastic cerebral palsy. *J Bone Joint Surg Am* 1983;65:748–54.
- [22] Perry J, Hoffer MM, Giovan P, Antonelli D, Greenberg R. Gait analysis of the triceps surae in cerebral palsy. A preoperative and postoperative clinical and electromyographic study. *J Bone Joint Surg Am* 1974;56:511–20.

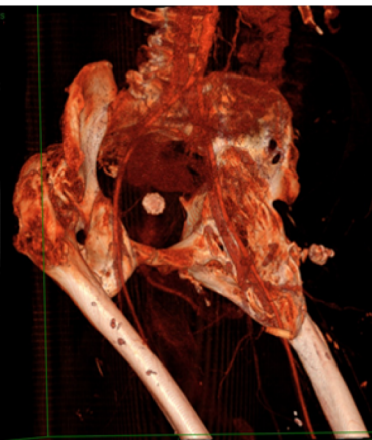
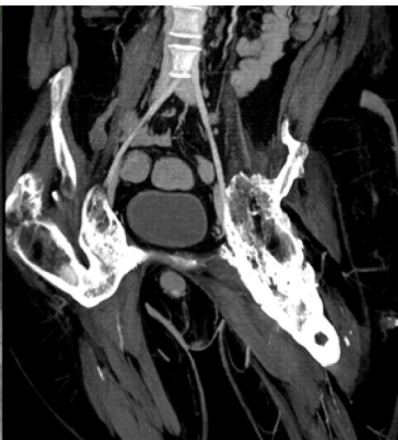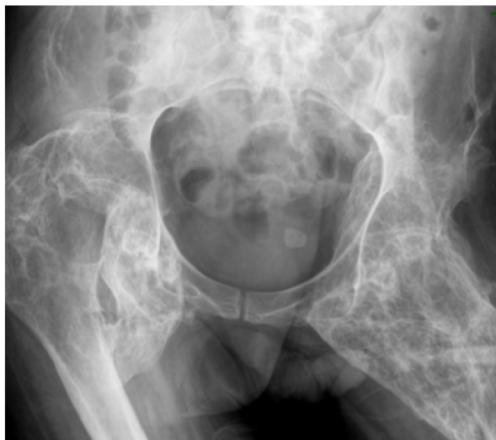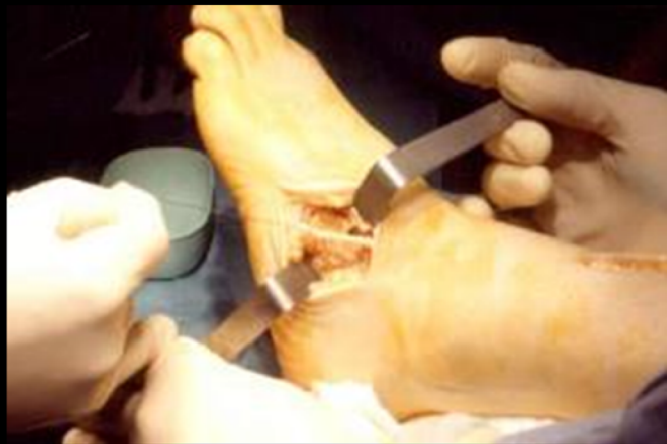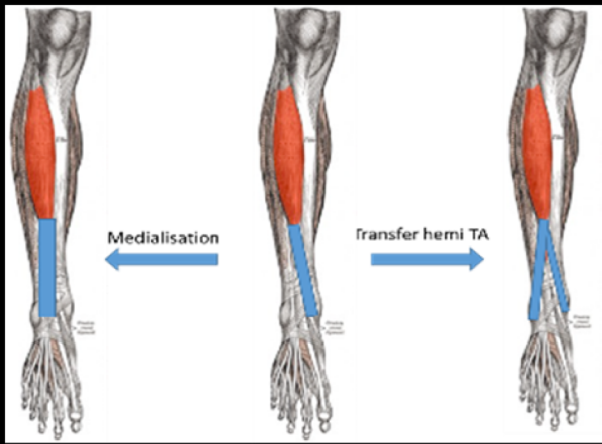
- [23] Takebe K, Basmajian JV. Gait analysis in stroke patients to assess treatments of foot-drop. *Arch Phys Med Rehabil* 1976;57:305–10.
- [24] Moberg E. Surgical treatment for absent single-hand grip and elbow extension in quadriplegia. Principles and preliminary experience. *J Bone Joint Surg Am* 1975;57:196–206.
- [25] Zancolli E. Surgery for the quadriplegic hand with active, strong wrist extension preserved. A study of 97 cases. *Clin Orthop* 1975:101–13.
- [26] Lamb DW, Chan KM. Surgical reconstruction of the upper limb in traumatic tetraplegia. A review of 41 patients. *J Bone Joint Surg Br* 1983;65:291–8.
- [27] McDowell C, Moberg E., House JH. The Second International Conference on Surgical Rehabilitation of the Upper Limb in Tetraplegia (Quadriplegia). *The Journal of Hand Surgery* 1986;11A:604–8.
- [28] Allieu Y. General indications for functional surgery of the hand in tetraplegic patients. *Hand Clin* 2002;18:413–21.
- [29] Revol M, Cormerais A, Laffont I, Pedelucq J-P, Dizien O, Servant J-M. Tendon transfers as applied to tetraplegia. *Hand Clin* 2002;18:423–39.
- [30] Bunketorp-Käll L, Reinholdt C, Fridén J, Wangdell J. Essential gains and health after upper-limb tetraplegia surgery identified by the International classification of functioning, disability and health (ICF). *Spinal Cord* 2017;55:857–63. doi:10.1038/sc.2017.36.
- [31] Benassy J. A case of transposition of the musculo-cutaneous nerve upon the median nerve. *Paraplegia* 1965;3:199–202. doi:10.1038/sc.1965.29.
- [32] Benassy J. Transposition of the musculo-cutaneous nerve upon the median nerve. Case report. *Med Serv J Can* 1966;22:695–7.
- [33] Kiwerski J. Recovery of simple hand function in tetraplegia patients following transfer of the musculo-cutaneous nerve into the median nerve. *Paraplegia* 1982;20:242–7. doi:10.1038/sc.1982.44.
- [34] Krasuski M, Kiwerski J. An analysis of the results of transferring the musculocutaneous nerve onto the median nerve in tetraplegics. *Arch Orthop Trauma Surg* 1991;111:32–3.
- [35] Oppenheim JS, Spitzer DE, Winfree CJ. Spinal cord bypass surgery using peripheral nerve transfers: review of translational studies and a case report on its use following complete spinal cord injury in a human. Experimental article. *Neurosurg Focus* 2009;26:E6. doi:10.3171/FOC.2009.26.2.E6.
- [36] Vialle R, Lepeintre J-F, Court C, Loureiro M-C, Lacroix C, Tadié M. Anatomical feasibility of using the ninth, 10th, and 11th intercostal nerves for the treatment of neurological deficits after damage to the spinal cord. *J Neurosurg Spine* 2006;4:225–32. doi:10.3171/spi.2006.4.3.225.
- [37] von Wild KRH, Brunelli GA. Restoration of locomotion in paraplegics with aid of autologous bypass grafts for direct neurotisation of muscles by upper motor neurons--the future: surgery of the spinal cord? *Acta Neurochir Suppl* 2003;87:107–12.
- [38] Buyse G, Silberstein J, Goemans N, Casaer P. Fibrodysplasia ossificans progressiva: still turning into wood after 300 years? *Eur J Pediatr* 1995;154:694–9.
- [39] Dejerine A, Ceillier A. Para-osteo-arthropathies des Paraplegiques par lesion medullaire: Etude clinique et radiographique. *Ann Med* 1918;5:497–535.
- [40] Dejerine M, Ceillier A, Dejerine Y. Para-ostéo-arthropathies des paraplégiques par lésion médullaire. Etude anatomique et histologique. *Rev Neurol* 1919:399–407.
- [41] Genêt F, Minooee K, Jourdan C, Ruet A, Denormandie P, Schnitzler A. Troublesome heterotopic ossification and stroke: Features and risk factors. A case control study. *Brain Inj* 2015:1–6. doi:10.3109/02699052.2015.1005133.

- [42] Cipriano CA, Pill SG, Keenan MA. Heterotopic ossification following traumatic brain injury and spinal cord injury. *J Am Acad Orthop Surg* 2009;17:689–97.
- [43] Costello F, Brown A. Myositis ossificans complicating anterior poliomyelitis. *J Bone Joint Surg Br* 1951;33:594–7.
- [44] Gunn D, Young W. Myositis ossificans as a complication of tetanus. *J Bone Joint Surg Br* 1959;41-B:535–40.
- [45] Banovac K, Williams JM, Patrick LD, Haniff YM. Prevention of heterotopic ossification after spinal cord injury with indomethacin. *Spinal Cord* 2001;39:370–4.
- [46] Genêt F, Kulina I, Vaquette C, Torossian F, Millard S, Pettit AR, et al. Neurological heterotopic ossification following spinal cord injury is triggered by macrophage-mediated inflammation in muscle. *J Pathol* 2015;236:229–40. doi:10.1002/path.4519.
- [47] Vlachou M, Pierce R, Davis RM, Sussman M. Does tendon lengthening surgery affect muscle tone in children with cerebral palsy? *Acta Orthop Belg* 2009;75:808–14.
- [48] Dursun N, Gokbel T, Akarsu M, Dursun E. Randomized Controlled Trial on Effectiveness of Intermittent Serial Casting on Spastic Equinus Foot in Children with Cerebral Palsy After Botulinum Toxin-A Treatment. *Am J Phys Med Rehabil* 2017;96:221–5. doi:10.1097/PHM.0000000000000627.
- [49] Thevenin-Lemoine C, Denormandie P, Schnitzler A, Lautridou C, Allieu Y, Genêt F. Flexor origin slide for contracture of spastic finger flexor muscles: a retrospective study. *J Bone Joint Surg Am* 2013;95:446–53. doi:10.2106/JBJS.K.00190.
- [50] Gatin L, Schnitzler A, Calé F, Genêt G, Denormandie P, Genêt F. Soft Tissue Surgery for Adults With Nonfunctional, Spastic Hands Following Central Nervous System Lesions: A Retrospective Study. *J Hand Surg* 2017;42:1035.e1-1035.e7. doi:10.1016/j.jhsa.2017.08.003.
- [51] Namdari S, Alish H, Baldwin K, Mehta S, Keenan MA. Outcomes of tendon fractional lengthenings to improve shoulder function in patients with spastic hemiparesis. *J Shoulder Elbow Surg* 2012;21:691–8. doi:10.1016/j.jse.2011.03.026.
- [52] Schnitzler A, Diebold A, Parratte B, Tliba L, Genêt F, Denormandie P. An alternative treatment for contractures of the elderly institutionalized persons: Microinvasive percutaneous needle tenotomy of the finger flexors. *Ann Phys Rehabil Med* 2016. doi:10.1016/j.rehab.2015.11.005.
- [53] Chesnel C, Genêt F, Almangour W, Denormandie P, Parratte B, Schnitzler A. Effectiveness and Complications of Percutaneous Needle Tenotomy with a Large Needle for Muscle Contractures: A Cadaver Study. *PloS One* 2015;10:e0143495. doi:10.1371/journal.pone.0143495.
- [54] Schnitzler A, Genêt F, Diebold A, Mailhan L, Jourdan C, Denormandie P. Lengthening of knee flexor muscles by percutaneous needle tenotomy: Description of the technique and preliminary results. *PloS One* 2017;12:e0182062. doi:10.1371/journal.pone.0182062.
- [55] Cuttica DJ, Decarbo WT, Philbin TM. Correction of rigid equinovarus deformity using a multiplanar external fixator. *Foot Ankle Int* 2011;32:S533-539. doi:10.3113/FAI.2011.0533.
- [56] Genêt F, Laffont I, Denormandie P, Schnitzler A, Lapeyre E, Dizien O. [Constituted adult equine from the ankle: surgical treatment by Ilizarov external fixator]. *Ann Readaptation Med Phys Rev Sci Soc Francaise Reeducation Fonct Readaptation Med Phys* 2005;48:101–5. doi:10.1016/j.anrmp.2004.09.005.
- [57] Namdari S, Pill SG, Makani A, Keenan MA. Rectus femoris to gracilis muscle transfer with fractional lengthening of the vastus muscles: a treatment for adults with stiff knee gait. *Phys Ther* 2010;90:261–8. doi:10.2522/ptj.20090151.

- [58] Donadio J, Upex P, Bachy M, Fitoussi F. Wrist arthrodesis in adolescents with cerebral palsy. *J Hand Surg Eur Vol* 2016;41:758–62. doi:10.1177/1753193415625611.
- [59] Rayan GM, Young BT. Arthrodesis of the spastic wrist. *J Hand Surg* 1999;24:944–52. doi:10.1053/jhsu.1999.0944.
- [60] Deltombe T, Gustin T. Selective tibial neurotomy in the treatment of spastic equinovarus foot in hemiplegic patients: a 2-year longitudinal follow-up of 30 cases. *Arch Phys Med Rehabil* 2010;91:1025–30. doi:10.1016/j.apmr.2010.04.010.
- [61] Lazorthes Y, Sol J-C, Sallerin B, Verdié J-C. The surgical management of spasticity. *Eur J Neurol* 2002;9 Suppl 1:35–41; discussion 53–61.
- [62] Genet F, Jourdan C, Schnitzler A, Lautridou C, Guillemot D, Judet T, et al. Troublesome heterotopic ossification after central nervous system damage: a survey of 570 surgeries. *PLoS One* 2011;6:e16632. doi:10.1371/journal.pone.0016632.
- [63] Genet F, Chehensse C, Jourdan C, Lautridou C, Denormandie P, Schnitzler A. Impact of the Operative Delay and the Degree of Neurologic Sequelae on Recurrence of Excised Heterotopic Ossification in Patients With Traumatic Brain Injury. *J Head Trauma Rehabil* 2012. doi:10.1097/HTR.0b013e31822b54ba.
- [64] Genêt F, Ruet A, Almangour W, Gatin L, Denormandie P, Schnitzler A. Beliefs relating to recurrence of heterotopic ossification following excision in patients with spinal cord injury: a review. *Spinal Cord* 2015;53:340–4. doi:10.1038/sc.2015.20.
- [65] Almangour W, Schnitzler A, Salga M, Debaud C, Denormandie P, Genêt F. Recurrence of heterotopic ossification after removal in patients with traumatic brain injury: A systematic review. *Ann Phys Rehabil Med* 2016;59:263–9. doi:10.1016/j.rehab.2016.03.009.
- [66] Salga M, Jourdan C, Durand M-C, Hangard C, Denormandie P, Carlier R-Y, et al. Sciatic nerve compression by neurogenic heterotopic ossification: use of CT to determine surgical indications. *Skeletal Radiol* 2015;44:233–40. doi:10.1007/s00256-014-2003-6.
- [67] Carlier RY, Safa DML, Parva P, Mompoin D, Judet T, Denormandie P, et al. Ankylosing neurogenic myositis ossificans of the hip. An enhanced volumetric CT study. *J Bone Joint Surg Br* 2005;87:301–5.
- [68] Pansard E, Schnitzler A, Lautridou C, Judet T, Denormandie P, Genêt F. Heterotopic ossification of the shoulder after central nervous system lesion: indications for surgery and results. *J Shoulder Elb Surg Am Shoulder Elb Surg Al* 2013;22:767–74. doi:10.1016/j.jse.2012.08.017.
- [69] Denormandie P, de l'Escalopier N, Gatin L, Grelier A, Genêt F. Resection of neurogenic heterotopic ossification (NHO) of the hip. *Orthop Traumatol Surg Res OTSR* 2017. doi:10.1016/j.otsr.2017.04.015.
- [70] Genêt F, Jourdan C, Lautridou C, Chehensse C, Minooee K, Denormandie P, et al. The impact of preoperative hip heterotopic ossification extent on recurrence in patients with head and spinal cord injury: a case control study. *PloS One* 2011;6:e23129. doi:10.1371/journal.pone.0023129.
- [71] Genêt F, Chehensse C, Jourdan C, Lautridou C, Denormandie P, Schnitzler A. Impact of the operative delay and the degree of neurologic sequelae on recurrence of excised heterotopic ossification in patients with traumatic brain injury. *J Head Trauma Rehabil* 2012;27:443–8. doi:10.1097/HTR.0b013e31822b54ba.
- [72] Elovic EP, Esquenazi A, Alter KE, Lin JL, Alfaro A, Kaelin DL. Chemodenervation and nerve blocks in the diagnosis and management of spasticity and muscle overactivity. *PM R* 2009;1:842–51. doi:10.1016/j.pmrj.2009.08.001.

- [73] Deltombe T, Wautier D, De Cloedt P, Fostier M, Gustin T. Assessment and treatment of spastic equinovarus foot after stroke: Guidance from the Mont-Godinne interdisciplinary group. *J Rehabil Med* 2017;49:461–8. doi:10.2340/16501977-2226.
- [74] Buffenoir K, Decq P, Lefaucheur J. Interest of peripheral anesthetic blocks as a diagnosis and prognosis tool in patients with spastic equinus foot: a clinical and electrophysiological study of the effects of block of nerve branches to the triceps surae muscle. *Clin Neurophysiol* 2005;116:1596–600.
- [75] Genet F, Schnitzler A, Droz-Bartholet F, Salga M, Tatu L, Debaud C, et al. Successive motor nerve blocks to identify the muscles causing a spasticity pattern: example of the arm flexion pattern. *J Anat* 2017;230:106–16.
- [76] Hosalkar H, Babatunde O, Goebel J, Rendon N, Bashyal R, Keenan MA. Outcomes of musculoskeletal surgeries in adult patients with cerebral palsy. *Current Orthopaedic Practice* 2010;21:71–6.
- [77] Gracies J-M. Pathophysiology of spastic paresis. II: Emergence of muscle overactivity. *Muscle Nerve* 2005;31:552–71. doi:10.1002/mus.20285.
- [78] Lieber RL, Roberts TJ, Blemker SS, Lee SSM, Herzog W. Skeletal muscle mechanics, energetics and plasticity. *J Neuroengineering Rehabil* 2017;14:108. doi:10.1186/s12984-017-0318-y.
- [79] Schnitzler A, Roche N, Denormandie P, Lautridou C, Parratte B, Genet F. Manual needle placement: accuracy of botulinum toxin A injections. *Muscle Nerve* 2012;46:531–4. doi:10.1002/mus.23410.
- [80] Kwakkel G, Meskers CGM. Botulinum toxin A for upper limb spasticity. *Lancet Neurol* 2015;14:969–71. doi:10.1016/S1474-4422(15)00222-7.
- [81] Rutz E, Hofmann E, Brunner R. Preoperative botulinum toxin test injections before muscle lengthening in cerebral palsy. *J Orthop Sci Off J Jpn Orthop Assoc* 2010;15:647–53. doi:10.1007/s00776-010-1509-6.
- [82] Pomerance JF, Keenan MA. Correction of severe spastic flexion contractures in the nonfunctional hand. *J Hand Surg* 1996;21:828–33. doi:10.1016/S0363-5023(96)80199-7.
- [83] Carr JH, Shepherd RB. Enhancing physical activity and brain reorganization after stroke. *Neurol Res Int* 2011;2011:515938. doi:10.1155/2011/515938.
- [84] Morris DM, Crago JE, DeLuca SC, Pidikiti RD, Taub E. Constraint-induced movement therapy for motor recovery after stroke. *NeuroRehabilitation* 1997;9:29–43. doi:10.3233/NRE-1997-9104.

Technique	Simple tenotomy	Simple Intramuscular tenotomy	Z Intramuscular tenotomy	Proximal muscle release (Forearm - Page-Scaglietti procedure)	Z tenotomy
Schematic representation 					
Location	Tendon	Myotendinous Union	Myotendinous Union	Proximal insertion of the muscle	Tendon
Procedure	Surgically or percutaneously	Surgically or percutaneously	Surgically or percutaneously	Surgically	Surgically (needs suture)
Expected lengthening		15-20 mm (10-15°)	20-50 mm (20-50°)	10 to 60 mm (10 to 60°)	No limit: X mm tendon lengthening = X° gain in range of motion gain
Immobilization	Cast 10 days (Skin and pain management)	Cast 35 days with weight bearing	Cast 35 days with weight bearing	Cast 21 days (Early muscular contractions under cast)	Cast 35 days with weight bearing



A1		A2	
B1	B2	B3	
C1	C2	D1	D2

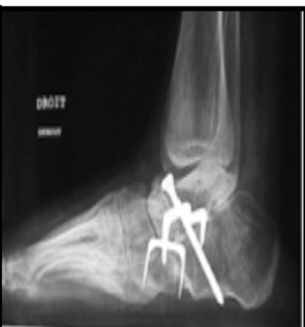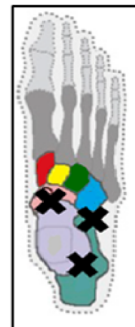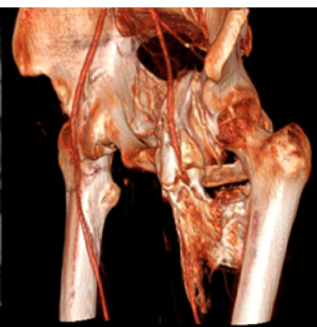
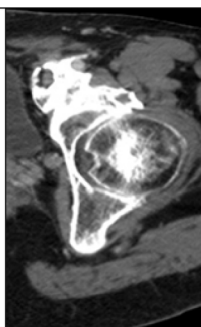


Table. Aims and methods of focal medical and surgical treatments for neuro-orthopedic deformities.

Medical treatments and rehabilitation	Surgical treatments
Aim: Rebalance agonist/antagonist effects by reducing agonist activity	
<p>Spasticity</p> <ul style="list-style-type: none"> • Action on the nerve (phenolization) • Action on the muscle (motor plate: botulinum toxin injection) • Intrathecal baclofen <p>Contracture</p> <ul style="list-style-type: none"> • Action on muscle and tendon (physiotherapy, percutaneous tenotomy) 	<p>Spasticity</p> <ul style="list-style-type: none"> • Action on the nerve (partial neurotomy) • Action on the dorsal root (DREZtomy) <p>Contracture</p> <ul style="list-style-type: none"> • Action on muscle & tendon (lengthening etc.)
Aim: Rebalance agonist/antagonist effects by increasing antagonist activity	
<p>Physiotherapy, self-guided rehabilitation, functional electrical stimulation, etc.</p>	<p>Muscle transfers, tenodesis</p>
Ensure mobility and joint stability	
<p>Physiotherapy, self-guided rehabilitation, functional electrical stimulation, etc.</p>	<p>Arthrolisis, heterotopic ossification removal, arthroplasty, arthrodesis, osteotomy</p>