



HAL
open science

Autopsy findings of ectodermal dysplasia and sex development disorder in a fetus with 19q12q13 microdeletion

Nicolas Mottet, Christelle Cabrol, Jean-Patrick Metz, Claire Toubin, Francine Arbez-Gindre, Mylène Valduga, Ken Mcelreavey, Didier Riethmuller, Lionel van Maldergem, Juliette Piard

► To cite this version:

Nicolas Mottet, Christelle Cabrol, Jean-Patrick Metz, Claire Toubin, Francine Arbez-Gindre, et al.. Autopsy findings of ectodermal dysplasia and sex development disorder in a fetus with 19q12q13 microdeletion. *European Journal of Medical Genetics*, 2019, 62 (9), pp.103539. 10.1016/j.ejmg.2018.09.006 . hal-03488020

HAL Id: hal-03488020

<https://hal.science/hal-03488020v1>

Submitted on 20 Jul 2022

HAL is a multi-disciplinary open access archive for the deposit and dissemination of scientific research documents, whether they are published or not. The documents may come from teaching and research institutions in France or abroad, or from public or private research centers.

L'archive ouverte pluridisciplinaire **HAL**, est destinée au dépôt et à la diffusion de documents scientifiques de niveau recherche, publiés ou non, émanant des établissements d'enseignement et de recherche français ou étrangers, des laboratoires publics ou privés.



Distributed under a Creative Commons Attribution - NonCommercial 4.0 International License

Autopsy findings of ectodermal dysplasia and sex development disorder in a fetus with 19q12q13 microdeletion

Nicolas Mottet^a, Christelle Cabrol^b, Jean-Patrick Metz^a, Claire Toubin^a, Francine Arbez-Gindre^c, Mylène Valduga^d, Kenneth McElreavey^e, Didier Riethmuller^a, Lionel Van Maldergem^b, Juliette Piard^b

^a Pole Mère-femme, service de gynécologie Obstétrique, ^b Centre de Génétique Humaine ^c Service d'Anatomie Pathologie, Centre Hospitalier Universitaire, Université de Franche-Comté, Besançon, France

^d Laboratoire de génétique, Université de Nancy, France

^e Département de Biologie du Développement et cellules Souches, CNRS UMR 3738, Institut Pasteur, Paris, France

Corresponding author :

MOTTET Nicolas
Service de gynécologie-obstétrique, Pôle Mère-Femme
CHU Jean Minjoz, Université de Franche-Comté
3 Boulevard Fleming
25030 Besançon
Phone : +33 381 21 88 95
Email: ncmottet@gmail.com

Abstract

A 5,6 Mb *de novo* 19q12-q13.12 interstitial deletion was diagnosed prenatally by array-comparative genomic hybridization in a 26 weeks male fetus presenting with intra-uterine growth retardation, left clubfoot, atypical genitalia and dysmorphic features. Autopsic examination following termination of pregnancy identified a severe disorder of sex development (DSD) including hypospadias, micropenis, bifid scrotum and right cryptorchidism associated with signs of ectodermal dysplasia : scalp hypopigmentation, thick and frizzy hair, absence of eyelashes, poorly developed nails and a thin skin with prominent superficial veins. Other findings were abnormal lung lobation and facial dysmorphism.

This new case of DSD with a 19q12q13 deletion expands the phenotypic spectrum associated with this chromosomal rearrangement and suggests that *WTIP* is a strong candidate gene involved in male sex differentiation.

Keywords: 19q12q13 deletion; ectodermal dysplasia; disorder of sex development; lung lobation

Highlights

- *WTIP* is a strong candidate gene involved in male sex differentiation
- Abnormal lung lobation might represent a novel feature of the 19q12q13 deletion
- The current observation shows for the first time autopsy findings illustrating hair anomalies and ectodermal involvement in the 19q12q13 deletion syndrome

Introduction

Chromosomal microarray is recommended in case of severe fetal growth restriction (FGR) diagnosed by prenatal ultrasound screening especially when associated abnormalities are present. The microarray provides additional valuable clinical information where a malformed fetus presents with an apparently normal karyotype. A 10% incremental yield has been reported in published series in fetuses with FGR and structural anomalies (Borrell et al., 2016).

The 19q12q13.11 deletion is a multiple congenital malformation/mental retardation (MCA/MR) syndrome where common clinical features are pre- or postnatal growth retardation, developmental delay, learning disability, microcephaly, hypospadias in affected males and distinctive features involving cutaneous tissues especially signs of ectodermal dysplasia (ED) and occipital cutis aplasia (Lin et al., 2012; Meyer et al., 2017).

We report here autopsy findings in a case of 19q12q13 deletion syndrome diagnosed prenatally by high-resolution chromosomal microarray. We expand the phenotypic spectrum associated with this chromosomal rearrangement and suggest that *WTIP* (OMIM 614790) may be involved in male sex differentiation.

Clinical report

A 27-year-old Caucasian woman (para 0, gravida 1) was referred to our department at 26 weeks of gestation (WG) for fetal growth restriction at – 2SD and left clubfoot. Her history was unremarkable. In particular, there was no exposure to any teratogenic agent. A repetition of ultrasound scans confirmed these findings and also indicated anomalies of the male external genitalia including a bifid scrotum and a small penis with an abnormal curvature. Three-dimensional ultrasounds of the fetal face showed hypertelorism and pronounced inferior palpebral fold with wrinkled eyelids (Fig.1).

Based on these findings, an array-CGH was performed at 27 WG, which revealed an interstitial 5,6 Mb deletion of chromosome 19q12-q13.12. (Fig.2). Array-CGH was performed with an Agilent Human Genome CGH Microarray Kit 180 k (Agilent Technologies Inc., Santa Clara, CA). The data were analyzed by Agilent Cytogenomics software with the statistical algorithm ADM-2, using 3-probe minimum aberration call. The molecular karyotype of the patient, accordingly with the ISCN2016, was arr[GRCh37]19q12q13.12(31597035-37220382)x1 dn. Quantitative PCR analysis confirmed the microdeletion with two different primers pairs (A : sens GGACAAACCAGGCAAGAAAA and reverse ACCTGTTTCTTCCCATCACG; C: sens GAGGCTGCAGACAGAGAAGG and reverse CCTCATGCCATAACCAGACT). Fluorescent in situ hybridization on parental metaphase with probes BAC RP11-298M15 in 19q13.11 and RP11-38C1 in 19q13.12 (control probe RP11-184M17 in 19p13.12) shows that the deletion was *de novo*. No other CNVs with a potential clinical impact were detected by array-CGH analysis. Based on these results and the polymalformation syndrome observed, the couple asked for termination of pregnancy at 31 WG.

Autopsy findings confirmed mild fetal growth restriction with a birthweight of 1370g (-2 SD). Morphological examination showed telecanthus, pronounced infra-orbital folds, a

broad nose, downslanting palpebral fissures and thin vermilion of the upper lip. Hair was atypically shaped and coloured with a light pigmentation and a woolly and frizzy appearance. Other cutaneous features were the absence of eyelashes, poorly developed nails and a thin skin with apparent superficial veins (Fig.1). Examination of the genitalia revealed a micropenis (12 mm), hypospadias, bifid scrotum and right cryptorchidism (Fig.1). Anteposed anus was observed. Additional findings were pupillary asymmetry with unilateral microcoria, left clubfoot, 11 rib pairs, hypoplastic kidneys with normal parenchyma and lung lobation defect with 2 right lobes and a unique left lobe. Microscopic examination of gonads, eyes and kidneys showed a normal structure.

Discussion

The 19q12q13 deletion syndrome is characterized by multiple congenital malformation and dermatological features including signs of ectodermal dysplasia (ED) and scalp aplasia. Twenty nine cases (including this report) have been reported in the literature so far and are detailed in table 1 and supplemental table 1. Twelve patients are female, sixteen are male and one patient has a complete sex-reversal with female genitalia and a 46,XY karyotype (Lin et al., 2012). Common clinical features include prenatal (19/20) and postnatal growth retardation (17/18), developmental delay or intellectual disability (25/27), facial dysmorphism (26/27), microcephaly (17/20), signs of ED, cutis aplasia (12/20) and disorder of sex development (DSD) in 46,XY males including hypospadias (10/11), bifid scrotum (6/9) and cryptorchidism (9/11). Signs of ED includes sparse hair or eyelashes or eyebrows (13/20), thin and dry skin (9/18), tooth anomalies (7/18) and dysplastic nails (9/19) (Lin et al., 2012; Meyer et al., 2017; Malan et al., 2009; Urquhart et al., 2015; Melo et al., 2015; Venegas-Vega

et al., 2014; Schuurs-Hoeijmakers et al., 2009; Gana et al., 2012; Forzano et al., 2012; Kulharya et al., 1998) (Table 1 and supplemental table 1).

The current observation fits previous descriptions and provides for the first time autopsy findings illustrating hair anomalies and ectodermal involvement. Indeed, light hair with a thick and frizzy appearance associated with absence of eyelashes, poorly developed nails and thin skin were particularly remarkable in our patient (Fig. 1).

The fetus also presented with lung lobulation anomalies that might represent a novel feature of the 19q12q13 deletion syndrome although we cannot exclude the possibility that the co-occurrence is coincidental.

The size of previously reported deletions ranges from 186 Kb to 11 Mb (Fig.2). A 324 kb minimal overlapping critical region has been proposed including zinc-finger genes belonging to the KRAB-ZNF family and known to be involved in embryonic development, cell differentiation, cell proliferation and cell cycle regulation (Gana et al., 2012; Urrutia, 2003). However, genes outside the minimal critical region such as *KMT2B* (OMIM *606834), *WTIP* (OMIM *614790) and *UBA2* (OMIM *613295) have also been proposed to contribute to the phenotype (Gana et al., 2012; Melo et al., 2015). *KMT2B* has recently been involved in a complex progressive early-onset dystonia (Meyer et al., 2017). The hypothesis of Melo et al. that deletions of *UBA2* might be responsible for cutis aplasia (Melo et al., 2015) is reinforced by the identification of a missense mutation in *UBA2* in a patient with cutis aplasia, Duane anomaly and bilateral hip dysplasia (Marble et al., 2017). Therefore, *UBA2* mutations may be a new autosomal dominant cause of congenital scalp defects. Mutations in *CHST8* have been described in the autosomal recessive genodermatosis peeling skin syndrome characterized by lifelong, continuous shedding of the upper epidermis (Cabral et al., 2012). The dermatological features of this condition are very different from those observed in patients with 19q12q13 deletion syndrome. However, the role of haploinsufficiency of

CHST8 in the cutaneous phenotype is questionable. *WTIP* (Wilms tumor interacting protein) appears as a strong candidate for DSD (Melo et al., 2015) since its product physically interacts with the WT1 (Wilms tumor 1) protein, which is involved in mammalian urogenital development. Zebrafish studies have demonstrated a role for *WTIP* in genitourinary and renal development, with *WTIP* knockdown embryos demonstrating cloacal malformation (Bubenshchikova et al., 2012). All but one male patient reported in the literature has hypospadias. Patient 4 of Chowdhury et al has normal genitalia and the deletion observed in this boy does not involve *WTIP* (Chowdhury et al., 2014). In our case, the fetus displays not only a hypospadias but a severe DSD associating hypospadias, curved micropenis, unilateral cryptorchidism and a bifid scrotum. This observation suggests that *WTIP* haploinsufficiency may result in a range of DSD starting from the first stage of gonadal differentiation (XX males) to the later stage (XY males with hypospadias) (Gana et al., 2012). We analyzed whole exome sequencing datasets of 120 patients with 46,XY gonadal dysgenesis or XY male with ambiguous genitalia (data not shown) and no further deleterious variant in *WTIP* was identified suggesting that it is a very rare cause of DSD. No mutations in any of the other genes in the 19q12q13 region were found.

In conclusion, the current report illustrates the high prevalence of dermatological anomalies in the 19q12q13 deletion syndrome even in the prenatal period and suggests that *WTIP* is a strong candidate for the development of DSD in the male. It also adds abnormal lung lobulation as a possible component of the phenotypic spectrum.

Figure 1 : Fetal autoptic features. Note prominent nose, thin lips, downslanting palpebral fissures, telecanthus, pronounced infra-orbital folds, absence of eyelashes and a wrinkled appearance of the eyelids (a,b). The hair as a light pigmentation with a wooly and frizzy appearance (c). Anomalies of the external genitalia included micropenis, hypospadias and bifid scrotum (d).

Figure 2 : Schematic representation showing deletions in the 19q12q13 chromosome region identified in our patient plus the patients reported in literature. The size in Mb and the coordinates of each deletion are included. The minimal overlapping region (reported by Gana et al.) is highlighted in blue. RefSeq genes are annotated below.

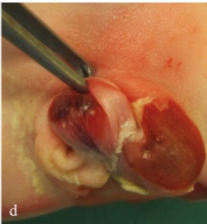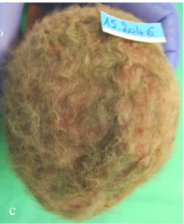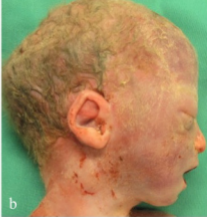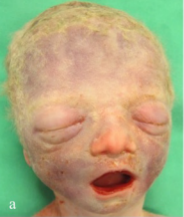Table 1 : Summary of clinical features of patients with a 19q12q13 deletion. Enlever le tiret devant "Heart"

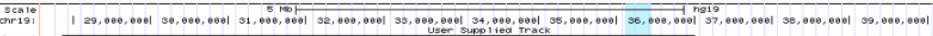
Supplemental Table 1 : Detailed clinical findings of our case and patients previously reported in the literature with a 19q12q13 deletion.

References

- Borrell, A., Grande, M., Meler, E., Sabrià, J., Mazarico, E., Muñoz, A., Rodriguez-Revena, L., Badenas, C., Figueras, F., 2016. Genomic Microarray in Fetuses with Early Growth Restriction: A Multicenter Study. *Fetal Diagn. Ther.*
- Bubenshchikova, E., Ichimura, K., Fukuyo, Y., Powell, R., Hsu, C., Morrical, S.O., Sedor, J.R., Sakai, T., Obara, T., 2012. Wtip and Vangl2 are required for mitotic spindle orientation and cloaca morphogenesis. *Biol. Open* 1, 588–596.
- Cabral RM, Kurban M, Wajid M, Shimomura Y, Petukhova L, Christiano AM. Whole-exome sequencing in a single proband reveals a mutation in the CHST8 gene in autosomal recessive peeling skin syndrome. *Genomics*. 2012 Apr;99(4):202-8
- Chowdhury, S., Bandholz, A.M., Parkash, S., Dyack, S., Rideout, A.L., Leppig, K.A., Thiese, H., Wheeler, P.G., Tsang, M., Ballif, B.C., Shaffer, L.G., Torchia, B.S., Ellison, J.W., Rosenfeld, J.A., 2014. Phenotypic and molecular characterization of 19q12q13.1 deletions: a report of five patients. *Am. J. Med. Genet. A*. 164A, 62–69.
- Forzano, F., Napoli, F., Uliana, V., Malacarne, M., Viaggi, C., Bloise, R., Coviello, D., Di Maria, E., Olivieri, I., Di Iorgi, N., Faravelli, F., 2012. 19q13 microdeletion syndrome: Further refining the critical region. *Eur. J. Med. Genet.* 55, 429–432.
- Gana, S., Veggiotti, P., Sciacca, G., Fedeli, C., Bersano, A., Micieli, G., Maghnie, M., Ciccone, R., Rossi, E., Plunkett, K., Bi, W., Sutton, V.R., Zuffardi, O., 2012. 19q13.11 cryptic deletion: description of two new cases and indication for a role of WTIP haploinsufficiency in hypospadias. *Eur. J. Hum. Genet. EJHG* 20, 852–856.
- Kulharya, A.S., Michaelis, R.C., Norris, K.S., Taylor, H.A., Garcia-Heras, J., 1998. Constitutional del(19)(q12q13.1) in a three-year-old girl with severe phenotypic abnormalities affecting multiple organ systems. *Am. J. Med. Genet.* 77, 391–394.
- Lin, S.-Y., Lee, C.-N., Chen, T.-C., Tu, M.-P., Lin, C.-Y., Chang, T.-Y., Su, Y.-N., 2012. A fetus with 19q13.11 microdeletion presenting with intrauterine growth restriction and multiple cystic kidney. *Case Rep. Perinat. Med.* 1, 69–74.
- Malan, V., Raoul, O., Firth, H.V., Royer, G., Turleau, C., Bernheim, A., Willatt, L., Munnich, A., Vekemans, M., Lyonnet, S., Cormier-Daire, V., Colleaux, L., 2009. 19q13.11 deletion syndrome: a novel clinically recognisable genetic condition identified by array comparative genomic hybridisation. *J. Med. Genet.* 46, 635–640.
- Marble, M., Guilen Sacoto, M.J., Chikarmane R., Gargiulo D., Juusola, J., 2017. Missense variant in UBA2 associated with aplasia cutis congenita, duane Anomaly, hip dysplasia, and other anomalies: A possible new disorder involving the SUMOylation pathway. *Am. J. Med. Gen. Part A*. 173A:758-761
- Melo, J.B., Estevinho, A., Saraiva, J., Ramos, L., Carreira, I.M., 2015. Cutis Aplasia as a clinical hallmark for the syndrome associated with 19q13.11 deletion: the possible role for UBA2 gene. *Mol. Cytogenet.* 8, 21.
- Meyer, E., Carss, K.J., Rankin, J., Nichols, J.M.E., Grozeva, D., Joseph, A.P., Mencacci, N.E., Papandreou, A., Ng, J., Barral, S., Ngoh, A., Ben-Pazi, H., Willemsen, M.A., Arkadir, D., Barnicoat, A., Bergman, H., Bhate, S., Boys, A., Darin, N., Foulds, N., Gutowski, N., Hills, A., Houlden, H., Hurst, J.A., Israel, Z., Kaminska, M., Limousin, P., Lumsden, D., McKee, S., Misra, S., Mohammed, S.S., Nakou, V., Nicolai, J., Nilsson, M., Pall, H., Peall, K.J., Peters, G.B., Prabhakar, P., Reuter, M.S., Rump, P., Segel, R., Sinnema, M., Smith, M., Turnpenny, P., White, S.M., Wiczorek, D., Wiethoff, S., Wilson, B.T., Winter, G., Wragg, C., Pope, S., Heales, S.J.H., Morrogh, D., UK10K Consortium, Deciphering Developmental Disorders Study, NIH BioResource Rare Diseases Consortium, Pittman, A., Carr, L.J., Perez-Dueñas, B., Lin, J.-P., Reis, A., Gahl,

- W.A., Toro, C., Bhatia, K.P., Wood, N.W., Kamsteeg, E.-J., Chong, W.K., Gissen, P., Topf, M., Dale, R.C., Chubb, J.R., Raymond, F.L., Kurian, M.A., 2017. Mutations in the histone methyltransferase gene *KMT2B* cause complex early-onset dystonia. *Nat. Genet.* 49, 223–237.
- Schuurs-Hoeijmakers, J.H.M., Vermeer, S., van Bon, B.W.M., Pfundt, R., Marcelis, C., de Brouwer, A.P.M., de Leeuw, N., de Vries, B.B.A., 2009. Refining the critical region of the novel 19q13.11 microdeletion syndrome to 750 Kb. *J. Med. Genet.* 46, 421–423.
- Urquhart, J.E., Williams, S.G., Bhaskar, S.S., Bowers, N., Clayton-Smith, J., Newman, W.G., 2015. Deletion of 19q13 reveals clinical overlap with Dubowitz syndrome. *J. Hum. Genet.* 60, 781–785.
- Urrutia, R., 2003. KRAB-containing zinc-finger repressor proteins. *Genome Biol.* 4, 231.
- Venegas-Vega, C., Nieto-Martínez, K., Martínez-Herrera, A., Gómez-Laguna, L., Berumen, J., Cervantes, A., Kofman, S., Fernández-Ramírez, F., 2014. 19q13.11 microdeletion concomitant with *ins(2;19)(p25.3;q13.1q13.4)dn* in a boy: potential role of *UBA2* in the associated phenotype. *Mol. Cytogenet.* 7, 61.





PresentReport

- Choudhury1
- Choudhury5
- Choudhury3
- Choudhury4
- Ma lan1
- L in
- PresentReport
- Meyer5
- Meyer5
- Ma lan3
- Ma lan2
- Urohart
- Me 10
- Choudhury2
- Venegas-Vega
- Meyer3
- Meyer3
- huurs-Hoeijmakers
- Gana1
- Forzano
- Meyer6
- Gana2
- Meyer2
- Meyer7
- Meyer8
- Meyer1
- Meyer10
- Meyer9
- Meyer4

UCSC Genes (RefSeq, GenBank, CCDS, Rfam, tRNAs & Comparative Genomics)

UCRFS1 | CCNE1 | **AV746584** | ZNF567 | WDR88 | ZNF567 | LSI14A | ZNF38 | HNF4 | OVOL2 | ZNF798 | ZNF548 | DFF1 | VSTG2B | ZNF536 | TSH23 | DPY19L3 | LRP3 | KIAA0355 | SCH1B | ETV2 | ZFP143 | ZNF420 | WDR67 | GGH | FOF4 | ZNF342 | USF2 | HCS1 | ZNF461 | ZNF529 | ZNF607 | NPF4K1 | FLEKHF1 | RNRK027 | CEBPG | PDCD2L | FYXD3 | LIN37 | ZNF556 | HKR1 | SPINT2 | C19orf12 | ROS98P | FEED | **UBA8** | LG14 | HSPB6 | ZNF260 | ZNF527 | YIF1B | C19orf12 | **CHST6** | **MTIP** | FYXD1 | NPHS1 | ZNF529 | ZNF569 | KCNKG | UR11 | TOR12 | KCTD15 | SC02882 | LSR | RPLP1 | ZNF382 | ZNF570 | CATSPERG | SLC7A5 | ZNF342 | USF2 | HCS1 | ZNF461 | ZNF529 | ZNF607 | NPF4K1 | CEF69 | ZNF181 | NHP | LRFN3 | ZNF567 | ZNF571 | SPRED3 | C19orf48 | ZNF599 | MAG | SYNE4 | ZNF658 | ZFP30 | FAM98C | RHPN2 | ZNF792 | SBS1 | TBCB | ZNF529 | ZNF607 | NPF4K1 | GPATCH1 | GRANK1P | HUS1 | AK747375 | ZNF573 | EIF3I | SLC7A10 | NPH-AS1 | **KNT2B** | ZNF568 | ZNF568 | C19orf33 | FYXD7 | NRPB10 | ZNF568 | C19orf33 | FYXD5 | TYROBP | AK747376 | RASGRP4 | FAM187B | SDHAF1 | ZNF558 | FFR1 | THAF8 | ZNF558 | FFR3 | WDR62 | LOC10631078 | FFR3 | POLR21 | FFR2 | CAPN5 | KRTDAP | ZNF555 | CAPDN5 | LOC720752 | A747325 | TMEN147 | ATP4A | RDM42 | COX6B1 | UPK1A-AS1 | ZBTB32 | TOPFR1 | U2AF1L4 | U2AF1L4 | PSENF1 | C19orf55 | RRHGAP33 | PROHG2 | KIRREL2 | ALKBH6 | BC871899 | COX7A1 | ZNF146 | AV746630 | LOC644189

	Reported case	Published cases (n= 28)
<i>Prenatal features</i>		
- IUGR < 5 th p	+	19/20
- Genital anomalies	+	1/20
- Facial anomalies	+	-
<i>Postnatal features or autopsy findings</i>		
Growth retardation	+	17/18
Developmental delay	NA	25/27
Ectodermal dysplasia		
- cutis aplasia	-	12/20
- sparse eyelashes	-	13/20
- thin skin	+	9/18
- abnormal hair	+	7/20
- abnormal teeth	+	7/18
- dysplastic nails	+	9/19
Genital abnormalities		
- hypospadias	+	10/11
- cryptorchidism	+	9/11
- bifid scrotum	+	6/9
Heart defects	-	6/19
Limbs abnormalities		
- syndactyly	-	7/18
- clubfeet	+	2/19
- ectrodactyly	-	1/19