



HAL
open science

Portal vein thrombosis and liver cirrhosis: Long-term anticoagulation is effective and safe

Michel Bergère, Domitille Erard-Poinsot, Olivier Boillot, Pierre-Jean Valette,
Olivier Guillaud, Christine Chambon-Augoyard, Jérôme Dumortier

► **To cite this version:**

Michel Bergère, Domitille Erard-Poinsot, Olivier Boillot, Pierre-Jean Valette, Olivier Guillaud, et al.. Portal vein thrombosis and liver cirrhosis: Long-term anticoagulation is effective and safe. *Clinics and Research in Hepatology and Gastroenterology*, 2019, 43, pp.395 - 402. <10.1016/j.clinre.2018.11.011>. <hal-03487995>

HAL Id: hal-03487995

<https://hal.science/hal-03487995v1>

Submitted on 20 Dec 2021

HAL is a multi-disciplinary open access archive for the deposit and dissemination of scientific research documents, whether they are published or not. The documents may come from teaching and research institutions in France or abroad, or from public or private research centers.

L'archive ouverte pluridisciplinaire **HAL**, est destinée au dépôt et à la diffusion de documents scientifiques de niveau recherche, publiés ou non, émanant des établissements d'enseignement et de recherche français ou étrangers, des laboratoires publics ou privés.



Distributed under a Creative Commons CC BY-NC 4.0 - Attribution - Non-commercial use - International License

**Portal vein thrombosis and liver cirrhosis:
long term anticoagulation is effective and safe**

Michel BERGERE (1), Domitille ERARD-POINSOT (1,2), Olivier BOILLOT (1,2),
Pierre-Jean VALETTE (1,2), Olivier GUILLAUD (1), Christine CHAMBON-AUGOYARD (1),
Jérôme DUMORTIER (1,2).

(1) Fédération des Spécialités Digestives, Hôpital Edouard Herriot, Hospices Civils de Lyon

(2) Université Claude Bernard Lyon 1,

Abbreviations:

PVT = Portal vein thrombosis

VKA = Vitamin K – antagonist

LMWH = Low molecular weight heparin

LT = Liver transplantation

TIPS = Transjugular intrahepatic portosystemic shunt

MELD = Model for end-stage liver disease

Address for correspondence:

Jérôme Dumortier, MD, PhD,

Hôpital Edouard Herriot, Pavillons D et L,

69437 Lyon Cedex 03, France

fax number: +33 (0)4 72 11 01 47

phone number : +33 (0)4 72 11 01 11

E-mail: jerome.dumortier@chu-lyon.fr

Keywords: liver cirrhosis; portal vein thrombosis; anticoagulation; bleeding; outcome; recurrence.

Word count of manuscript: 2370 including main text

Word count of abstract: 238

Number of figures: 1

Number of tables: 5

Authorship statement:

JD is the Guarantor of the article.

JD brought the concept; MB and DEP collected the data; MB and JD wrote the paper; OG made the statistical analysis; DEP, OB, CCA, PJV, OG and JD were involved in patient care and inclusion.

All co-authors approved the final version of the paper.

Conflict of interest and financial disclosure: None to declare

Abstract

Background and aims: Portal vein thrombosis (PVT) is a common complication of liver cirrhosis. Anticoagulation therapy is efficient, but is associated with potentially severe side-effects, especially bleeding episodes. It is therefore still unclear which patients will benefit from anticoagulation, and for what duration. The aim of the present study was to retrospectively analyse our single centre experience on long-term anticoagulation in patients presenting a PVT, complicating cirrhosis.

Methods: Data of 40 cirrhotic patients with PVT treated by anticoagulation therapy from June 2003 to May 2018 were collected. Regular imaging was performed to monitor the outcome of PVT. The hemorrhagic complications and the recurrence of the PVT after anticoagulation withdrawal were also analyzed.

Results: The median follow-up under anticoagulation therapy was 33.7 months. Complete (57.5%) or partial (25.0%) recanalization of PVT was observed. Fifteen bleeding episodes (37.5%) occurred in our population, related to portal hypertension in 7 (46.7%). Eleven (73.3%) patients required hospitalization and eight (53.3%) required blood transfusion. No patient died from bleeding complication. Anticoagulation was stopped in 10 patients (25.0%), because of regression of PVT in 5 patients or a haemorrhagic episode in 5 patients. Among those 10 patients, 7 had a recurrence or extension of the initial PVT.

Conclusions: Our results confirm that anticoagulation allows a recanalization of PVT complicating cirrhosis in the majority of the cases, is associated with non-severe bleeding complications, and can be maintained for a long duration in order to avoid recurrence.

INTRODUCTION

Non-neoplastic portal vein thrombosis (PVT) is a complication of liver cirrhosis, whatever the initial cause of liver disease, with a prevalence reaching 0.6% to 26% of patients, and an incidence (more rarely evaluated) reaching 7.4% to 16% per year (1-3). This prevalence increases with the severity of the disease and this is illustrated by the highest rates in patients listed for liver transplantation (LT). PVT can involve the intra- or extra-hepatic segments of the portal vein and extend to the superior mesenteric vein and/or the splenic vein. In addition, PVT can induce a partial vein obstruction or a complete blockade of portal blood flow. PVT can be asymptomatic but can also lead to a large spectrum of signs and symptoms, such as intestinal infarction or the complications of portal hypertension, such as ascites or variceal bleeding.

The role of anticoagulation (using vitamin K antagonist (VKA) or low molecular weight heparin (LMWH)) for the treatment of PVT in patients with cirrhosis remains controversial. In summary, anticoagulation is efficient, but is associated with potentially severe side-effects, especially bleeding episodes (4); it is therefore still unclear which patients will benefit from anticoagulation, and for what duration. A recent meta-analysis disclosed that a significantly higher proportion of patients treated with anticoagulants underwent PVT recanalization than patients who did not receive anticoagulants (71% vs. 42%, respectively, and complete recanalization 53% vs. 33%) (5). In the Baveno VI consensus conference, it has been stated that “In non-candidates to LT, no recommendation regarding anticoagulation treatment can be made at present. Anticoagulation could be considered in selected cases” (6). Indeed, in patients who are waiting for a LT and who present a PVT, the aim of anticoagulation is to obtain a complete recanalization, permit the transplantation and reduce both post-transplant morbidity and mortality (7).

The aim of the present study was to retrospectively analyse our single centre experience on long-term anticoagulation in patients presenting a non-neoplastic PVT complicating cirrhosis.

PATIENTS AND METHODS

Study population

All patients who received anticoagulation therapy for the treatment of a non-neoplastic thrombosis of the splenoportomesenteric axis complicating liver cirrhosis, started between June 2003 to May 2018 in our center (hôpital Edouard Herriot, Hospices civils de Lyon) were included in the present retrospective study. The decision to start anticoagulation treatment was not protocolized but at each physician's discretion. Anticoagulation was started after appropriate primary or secondary prophylaxis of variceal bleeding. Cirrhosis was diagnosed on the basis of clinical, laboratory, and imaging studies or liver biopsy. Patients presenting a cavernomatous transformation of the portal vein were not included in the present study. All patients received VKA or LMWH, at therapeutic doses.

The following end-points were evaluated: (1) rate of partial or complete recanalization, (2) safety of anticoagulation therapy, and (3) rate of recurrent thrombosis after recanalization. All data analysed in the present study were retrospectively collected from medical records.

Portal vein thrombosis and follow-up

Thrombosis of the splenoportomesenteric axis was defined as the absence of flow in part or all the lumen of the portal vein trunk, portal vein branches, splenic vein, or superior mesenteric vein associated with the presence of solid material within the vein, as documented by imaging studies (Doppler ultrasonography, CT-scan, magnetic resonance imaging (MRI)), in the absence of local hepatocellular carcinoma (HCC). The date on which the imaging technique showed thrombosis indicating the need to start anticoagulation therapy was defined as time zero. Patients were followed until death, liver transplantation (LT) or end of the study (May 31st 2018).

Clinical, laboratory, and radiologic data were collected just before the beginning of anticoagulation treatment and, whenever possible, every 6 months thereafter. Collected data consisted in gender, age at PVT diagnosis, time under anticoagulation, Child and MELD scores, morphological characteristics of PVT, bleeding episodes, secondary occurrence of hepatocellular carcinoma, LT or death. Recanalization of splenoportomesenteric axis was evaluated by Doppler ultrasound, CT scan, or MRI.

Evolution of thrombosis was classified as previously reported by Delgado *et al.* (4). Recanalization was considered complete when the portal vein trunk, at least 1 of the 2 main intrahepatic portal vein branches, the SV, and the SMV were all patent. Recanalization was considered partial when, although not fulfilling the previous criteria, patency was achieved in the portal vein trunk and in at least one of its main branches, in the SV (if previously thrombosed), in the SMV (if previously thrombosed), or when there was at least 50% reduction in the size of the thrombus in cases of complete thrombosis. Otherwise, nonresponse to anticoagulation was considered. The percentage of time in which patient's INR was in therapeutic range (TTR) measured the quality of anticoagulation treatment.

Statistical analysis

Quantitative variables were described using mean, range, standard deviation (SD) and median. Qualitative values were tabulated and percentages were calculated. Qualitative variables were compared using the χ^2 test or Fischer's exact test when appropriate. Quantitative variables were compared using the Student t-test or non-parametric tests (Mann-Whitney or Kruskal-Wallis tests) when appropriate. Statistical analysis was performed with SPSS version 23.0 (IBM, New York, USA); p values lower than 0.05 were considered to be statistically significant.

RESULTS

Base-line characteristics

From June 2003 to May 2018, anticoagulation therapy has been used in our center in 40 patients with splenoportomesenteric axis thrombosis due to cirrhosis. The main characteristics of the study population at the time of diagnosis are presented in Table 1.

The diagnosis of thrombosis was made by Doppler-ultrasonography for 14 patients, CT-scan for 18 patients and MRI for 6 patients. In the majority of the patients, the diagnosis was made from radiological screening for HCC, and thrombosis involved the portal trunk and was partial.

The mean initial Child-Pugh score was 6.8 ± 1.8 and the MELD score was 11.6 ± 2.7 .

Anticoagulation therapy

Upper digestive endoscopy was performed before beginning anticoagulation therapy, in 38 patients, and oesophageal varices band ligation was done in 14 cases (including 10 patients who already had recent band ligation before PVT diagnosis).

All patients initially received LMWH before conversion to VKA. The target of international normalized ratio (INR) for patients on VKA was between 2 and 2.5. Finally, VKA was used for 32 patients and LMWH for the remaining 8. Some patients remained on LMWH because of associated cancer or high bleeding-risk or suspicion of patient suboptimal compliance.

Patients were on anticoagulation therapy for a median time of 33.7 months (2.0-124.0). Mean TTR was $70.1\pm 17.5\%$.

Bleeding episodes under anticoagulation therapy

Fifteen bleeding episodes among 15 patients (37.5%) occurred during follow-up under anticoagulation therapy (Table 2). In 7 cases (46.7%), bleeding was related to portal hypertension (portal hypertension gastritis, oesophageal variceal, rectal variceal or colitis related to portal hypertension). Eleven (73.3%) patients required hospitalization for a median length stay of 7 days (1-28). A minority of the bleeding episodes required endoscopic treatment (13.3%) or surgical treatment (6.7%); 8 patients (53.4%) required blood transfusion. No patient died from bleeding complication.

The most important complication was a subdural hematoma which needed no neurosurgical management, and occurred in the patient who had the longest duration of anticoagulation (124 months).

None of the biological characteristics was significantly associated with the occurrence of bleeding except the haemoglobin level at the diagnosis of PVT (Table 3). Patients who presented bleeding complications had more frequently history of bleeding before PVT, 26.7% vs. 16.0 %, but the difference did not reach statistical difference.

Evolution of thrombosis

PVT's evolution under anticoagulation

We observed a complete regression of thrombosis in 23 patients (57.5%), a partial recanalization for 10 patients (25.0%), no evolution for 5 patients (12.5%) and a thrombosis extension for 2 patients (5.0%), after a delay of 2 to 18 months. The only significant predictive factor of outcome was a lower platelet count in patients who presented PVT recanalization (Table 4).

PVT's evolution after anticoagulation withdrawal

Anticoagulation was stopped in 10 patients (25.0%). Discontinuation was secondary to either a regression or a decrease of the PVT in 5 patients or a hemorrhagic episode in 5 patients. Among those 10 patients, 7 had a recurrence of the initial PVT or an extension of the thrombosis. Among these 7 patients, anticoagulation was resumed for 4 of them and there was a decrease without complete regression of PVT, 1 patient underwent TIPS insertion and 2 patients did not receive anticoagulation again because of chronic or recurrent bleeding.

Liver transplantation and survival

From our initial population of 40 patients, 8 patients underwent a LT after a median delay of 43.4 months (4-94), and 11 patients died during the follow-up after a median delay of 20 months (2-54). The causes of death were liver failure (n=6), sepsis (n=3), hypoxic cardiac arrest (n=1), breast cancer (n=1) and mesenteric ischemia (n=1).

Global outcome of all patients included in the study is summarized in Figure 1.

DISCUSSION

The aim of the present study was to analyze our experience on long-term anticoagulation in patients presenting a non-neoplastic PVT complicating cirrhosis. It has been suggested that the presence of a PVT is a marker of severity of cirrhosis, but without showing any direct involvement in the evolution of liver disease (8). Nevertheless, a meta-analysis demonstrated an increased mortality rate and an increased risk of ascitic decompensation in patients with PVT (9). Similarly, a randomized controlled trial that the use of enoxaparin could prevent the occurrence of PVT and reduce the rate of liver decompensation (10). Despite that liver failure related to cirrhosis induces a significant decrease in synthesis of pro-coagulant factors, mainly prothrombin, it has been clearly demonstrated during the last decade that cirrhosis is associated with a state of hypercoagulability, related to a decrease in the level of protein C and an increase in factor VIII (11). This added to the “mechanical” resisting effect of liver cirrhosis on venous portal flow. Finally, animal model studies reported that the evolution of hepatic fibrosis could be directly related to the prothrombotic state induced by chronic liver disease and that anticoagulation could slow down the fibrosing evolution process (12).

The use of anticoagulation therapy, and duration, for the treatment of PVT, remain controversial because of the lack of prospective and comparative data, as well as the increased risk of bleeding in patients with portal hypertension. In addition, spontaneous repermeabilization is possible in a significant proportion of cases. Ghabril *et al.* reported from a very large cohort of almost 50,000 patients that PVT is a risk factor for early postoperative mortality and graft loss after LT (13). Therefore, anticoagulant therapy is well established and recommended for patients waiting for LT with primary goal of facilitating intraoperative venous reconstruction and decrease post-operative complications (1, 6). Nevertheless, limiting active treatment of PVT in LT candidates has the major drawback that in many patients it is not possible to rule out that LT will never been discussed during follow-up of each individual.

In our cohort, anticoagulation was associated with a complete resolution the initial PVT in 57.5% of the patients and a partial resolution in 25.0%, *i.e.* a favorable outcome in 82.5% of the patients. These

results compares well with the existing data found in the literature (Table 5). The meta-analysis of Qi *et al.* found an average recanalization rate of 67.0% (95%CI, 54.7%-77.6%) (14). Since spontaneous recanalization could occur in one third of patients with PVT, Qi *et al.* reported an odds ratio in favor of the anticoagulation (*vs.* not) of 4.16 (95%CI, 1.88-9.20). Similarly, the recent meta-analysis of Loffredo *et al.* including 217 patients in 6 studies found an odds ratio of 3.4 (95%CI, 1.5-7.4); complete recanalization rates were 53% *vs.* 33% with and without anticoagulation, respectively (5). The vast majority of available data, including ours, concerns VKA and LMWH. Recent studies suggest that the use of new oral anticoagulant such as rivaroxaban could be as effective and safe as our actual treatment (15, 16). This is an interesting development because of the absence of required regular biological monitoring. In addition, a randomized multicenter trial is ongoing with the aim to evaluate the impact of rivaroxaban on cirrhosis progression and the incidence of portal thrombosis (Clinical trial NCT02643212 CIRROXABAN). Regarding possible predictors of response to anticoagulation therapy, the major factor is probably the early initiation of anticoagulant therapy (14 days) after the diagnosis of thrombosis (4). The delay before starting anticoagulation is dependent on the existence (and the treatment) of large esophageal and/or gastric varices. Inversely to Delgado (4), we found a platelet count significantly higher in patients who did not recanalize PVT.

The only alternative to anticoagulation is the insertion of a transjugular intra-hepatic portosystemic shunt (TIPS), which can restore a normal portal flow and therefore reduce the risk of thrombus formation. Indeed, TIPS has been proposed for the management of PVT, especially in patients waiting LT, with a complete resolution of the PVT at 1 month post-TIPS of 76% without associated anticoagulation (17). In addition, innovations in interventional radiology even allow complete recanalization of PVT without anticoagulation with TIPS using a trans-splenic approach (18).

Of course, the major drawback of anticoagulation is the risk of bleeding complications in a high risk population. In the absence of recommendations we choose a “low” target of INR (2-2.5). We report herein 15 episodes of bleeding (global rate of 37.5%), but only 5 of them led to discontinuation of anticoagulation therapy. The most serious complication occurred in our patient with the longest

duration of anticoagulant therapy (124 months). Interestingly, the results of the 2 meta-analyses strongly support that anticoagulation does not increase bleeding risk in patients who are on their own at risk. The meta-analysis of Qi *et al.* reported a very low excess risk for bleeding of 1.4% (95% CI = 0.3% - 3.4%) and Loffredo *et al.* found a lower bleeding rate in the group treated compared to the untreated group (5, 14). Interestingly, no death has ever been reported with the use of anticoagulants. This is concordant with the available data on anticoagulation in the cirrhotic patients, outside the field of PVT, such as atrial fibrillation or deep vein thrombosis, disclosing that anticoagulation does not significantly increase the risk of upper gastrointestinal bleeding (19, 20).

In conclusion, our study confirms that anticoagulation allows a recanalization of PVT complicating cirrhosis in the majority of the cases, is associated with non-severe bleeding complication, and can be maintained for a long duration in order to avoid recurrence.

References

1. Francoz C, Belghiti J, Vilgrain V, Sommacale D, Paradis V, Condat B, et al. Splanchnic vein thrombosis in candidates for liver transplantation: usefulness of screening and anticoagulation. *Gut* 2005;54:691-7.
2. Zocco MA, Di Stasio E, De Cristofaro R, Novi M, Ainora ME, Ponziani F, et al. Thrombotic risk factors in patients with liver cirrhosis: correlation with MELD scoring system and portal vein thrombosis development. *J Hepatol* 2009;51:682-9.
3. Tsochatzis EA, Senzolo M, Germani G, Gatt A, Burroughs AK. Systematic review: portal vein thrombosis in cirrhosis. *Aliment Pharmacol Ther* 2010;31:366-74.
4. Delgado MG, Seijo S, Yepes I, Achezar L, Catalina MV, Garcia-Criado A, et al. Efficacy and safety of anticoagulation on patients with cirrhosis and portal vein thrombosis. *Clin Gastroenterol Hepatol* 2012;10:776-83.
5. Loffredo L, Pastori D, Farcomeni A, Violi F. Effects of Anticoagulants in Patients With Cirrhosis and Portal Vein Thrombosis: A Systematic Review and Meta-analysis. *Gastroenterology* 2017;153:480-7 e1.
6. de Franchis R. Expanding consensus in portal hypertension: Report of the Baveno VI Consensus Workshop: Stratifying risk and individualizing care for portal hypertension. *J Hepatol* 2015;63:743-52.
7. Rodriguez-Castro KI, Porte RJ, Nadal E, Germani G, Burra P, Senzolo M. Management of nonneoplastic portal vein thrombosis in the setting of liver transplantation: a systematic review. *Transplantation* 2012;94:1145-53.
8. Nery F, Chevret S, Condat B, de Raucourt E, Boudaoud L, Rautou PE, et al. Causes and consequences of portal vein thrombosis in 1,243 patients with cirrhosis: results of a longitudinal study. *Hepatology* 2015;61:660-7.
9. Stine JG, Shah PM, Cornella SL, Rudnick SR, Ghabril MS, Stukenborg GJ, et al. Portal vein thrombosis, mortality and hepatic decompensation in patients with cirrhosis: A meta-analysis. *World J Hepatol* 2015;7:2774-80.
10. Villa E, Camma C, Marietta M, Luongo M, Critelli R, Colopi S, et al. Enoxaparin prevents portal vein thrombosis and liver decompensation in patients with advanced cirrhosis. *Gastroenterology* 2012;143:1253-60 e1-4.
11. Tripodi A, Anstee QM, Sogaard KK, Primignani M, Valla DC. Hypercoagulability in cirrhosis: causes and consequences. *J Thromb Haemost* 2011;9:1713-23.

12. Anstee QM, Goldin RD, Wright M, Martinelli A, Cox R, Thursz MR. Coagulation status modulates murine hepatic fibrogenesis: implications for the development of novel therapies. *J Thromb Haemost* 2008;6:1336-43.
13. Ghabril M, Agarwal S, Lacerda M, Chalasani N, Kwo P, Tector AJ. Portal Vein Thrombosis Is a Risk Factor for Poor Early Outcomes After Liver Transplantation: Analysis of Risk Factors and Outcomes for Portal Vein Thrombosis in Waitlisted Patients. *Transplantation* 2016;100:126-33.
14. Qi X, De Stefano V, Li H, Dai J, Guo X, Fan D. Anticoagulation for the treatment of portal vein thrombosis in liver cirrhosis: a systematic review and meta-analysis of observational studies. *Eur J Intern Med* 2015;26:23-9.
15. De Gottardi A, Trebicka J, Klinger C, Plessier A, Seijo S, Terziroli B, et al. Antithrombotic treatment with direct-acting oral anticoagulants in patients with splanchnic vein thrombosis and cirrhosis. *Liver Int* 2017;37:694-9.
16. Hanafy AS, Abd-Elsalam S, Dawoud MM. Randomized controlled trial of rivaroxaban versus warfarin in the management of acute non-neoplastic portal vein thrombosis. *Vascul Pharmacol* 2018.
17. Salem R, Vouche M, Baker T, Herrero JI, Caicedo JC, Fryer J, et al. Pretransplant Portal Vein Recanalization-Transjugular Intrahepatic Portosystemic Shunt in Patients With Complete Obliterative Portal Vein Thrombosis. *Transplantation* 2015;99:2347-55.
18. Kallini JR, Gabr A, Kulik L, Ganger D, Lewandowski R, Thornburg B, et al. Noncirrhotic complete obliterative portal vein thrombosis: Novel management using trans-splenic transjugular intrahepatic portosystemic shunt with portal vein recanalization. *Hepatology* 2016;63:1387-90.
19. Cerini F, Gonzalez JM, Torres F, Puente A, Casas M, Vinaixa C, et al. Impact of anticoagulation on upper-gastrointestinal bleeding in cirrhosis. A retrospective multicenter study. *Hepatology* 2015;62:575-83.
20. Intagliata NM, Henry ZH, Shah N, Lisman T, Caldwell SH, Northup PG. Prophylactic anticoagulation for venous thromboembolism in hospitalized cirrhosis patients is not associated with high rates of gastrointestinal bleeding. *Liver Int* 2014;34:26-32.
21. Senzolo M, T MS, Rossetto V, Burra P, Cillo U, Boccagni P, et al. Prospective evaluation of anticoagulation and transjugular intrahepatic portosystemic shunt for the management of portal vein thrombosis in cirrhosis. *Liver Int* 2012;32:919-27.
22. Chen H, Liu L, Qi X, He C, Wu F, Fan D, et al. Efficacy and safety of anticoagulation in more advanced portal vein thrombosis in patients with liver cirrhosis. *Eur J Gastroenterol Hepatol* 2016;28:82-9.
23. Fujiyama S, Saitoh S, Kawamura Y, Sezaki H, Hosaka T, Akuta N, et al. Portal vein thrombosis in liver cirrhosis: incidence, management, and outcome. *BMC Gastroenterol* 2017;17:112.

24. Artaza T, Lopes M, Romero M, Gomez AZ, de la Cruz G, Sanchez JJ, et al. Efficacy and safety of anticoagulation in non-malignant portal vein thrombosis in patients with liver cirrhosis. *Gastroenterol Hepatol* 2018.
25. La Mura V, Braham S, Tosetti G, Branchi F, Bitto N, Moia M, et al. Harmful and Beneficial Effects of Anticoagulants in Patients With Cirrhosis and Portal Vein Thrombosis. *Clin Gastroenterol Hepatol* 2018;16:1146-52 e4.

Legends for figure

Figure 1: Flow-chart of the patients included in the study

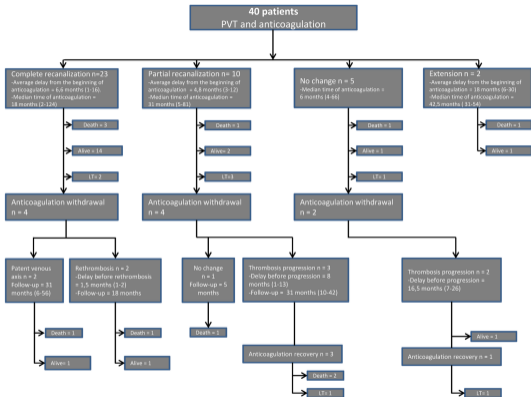


Table 1: Characteristics of the study population (n=40)

Age	57.4 +/- 10.7
Sexe	
Male	31
Female	9
Etiology of cirrhosis	
Alcohol	21
NASH	6
Viral	4
Others	9
CHILD-PUGH score	6.8 +/- 1.9
CHILD-PUGH parameters	19/15/6
Albumine (g/L)	33 +/- 6
Prothrombin rate (%)	64.7 +/- 14
Bilirubine (µmol/L)	35.1 +/- 31.1
Ascite	
1 point	25
2 points	12
3 points	4
Hepatic encephalopathy	
1 point	38
2 points	3
3 points	0
Creatinine umol/L	72.8 +/- 11.0
History of HCC	7
Diagnosis with Doppler/TDM/MRI	15/18/10
Diagnosis during follow-up / decompensation / post-endovascular intervention/ abdominal pain	31/4/4/1
Extension of thrombosis	
Portal trunk	25 (62.5%)
Complete	3
Partial	22
Right branch	19 (47.5%)
Complete	5
Partial	13
Left branch	10 (25.0%)
Complete	0
Partial	10 (25.0%)
Superior mesenteric vein	15 (37.5%)
Complete	1
Partial	14
Splénomésenteric confluence	3 (7.5%)
Splenic vein partial	1 (2.5%)
Complete	0
Partial	1

Table 2: Description of bleeding complications of anticoagulation (n=15)

	Type of anticoagulant	Hospitalization required	Modification about anticoagulation and treatment	INR at complication	Platelets count (giga/L)	Blood cell transfusion	Time from beginning of anticoagulation (months)
<i>Gastrointestinal bleeding and related to portal hypertension</i>							
<i>Rectal variceal bleeding</i>	VKA	Yes	Antagonisation and Switch VKA for LMWH during the complication	>10	86	No	8
<i>Esophagal bleeding after band ligation</i>	LMWH	Yes	Stop LMVH	2.78	60	Yes	5
<i>Portal hypertension gastritis</i>	VKA	Yes	Switch VKA for LMWH during the complication	2.28	57	Yes	9
<i>Portal hypertension gastritis</i>	LMWH	Yes	Switch VKA for LMWH during the complication	1.28	115	Yes	15
<i>Portal hypertension gastritis</i>	VKA	Yes	Stop VKA	2.73	41	Yes	42
<i>Portal hypertension gastritis</i>	VKA	No	Iron supplementation	2	60	No	8
<i>Portal hypertension colitis</i>	VKA	Yes	Switch VKA for LMWH during the complication	2.89	92	Yes	9
<i>Iron deficiency anemia without endoscopic abnormalities</i>							
<i>Anemia</i>	LMWH	No	Iron supplementation	1.6	131	No	5
<i>Anemia</i>	VKA	Yes	Iron supplementation	>10	110	Yes	3
<i>Extra-digestive bleeding</i>							
<i>Epistaxis</i>	VKA	Yes	Stop anticoagulation during complication	5	85	Yes	25
<i>Hematuria</i>	VKA	No	-	MD	MD	No	39
<i>Metrorrhagia</i>	LMWH	No	-	1.2	44	No	2
<i>Subdural hematoma</i>	VKA	Yes	Stop Anticoagulation	3.0	84	No	124
<i>Bleeding after paracentesis</i>	VKA	Yes	Antagonisation - Stop anticoagulation during complication	3.3	106	Yes	18
<i>Hematoma after skin-surgery</i>	LMWH	Yes	Stop anticoagulation during complication	1.1	127	Yes	3

Table 3: Factors associated with bleeding complications of anticoagulation

	No bleeding complication (n=25)	Bleeding complication (n=15)	p
MELD score	11.6 +/- 2.9	11.8 +/- 2.2	0.68
CHILD PUGH score	6.7 +/- 1.8	6.7 +/- 1.6	0.93
Platelet count (giga/L)	94.2 +/- 71.3	94 +/- 50	0.99
Hemoglobin (g/L)	122.0 +/- 20.2	97 +/- 42	0.033
Leucocyte (giga/L)	4.3 +/- 1.9	4.7 +/- 2.2	0.64
Duration of anticoagulation (months)	29.7 +/- 27.6	41.2 +/- 37.4	0.28
Use of VKA / LMWH	20 / 5	12 / 3	1.00
Prior bleeding before anticoagulation (yes /no)	4 / 21	4 / 11	0.44

Table 4: Factors associated with PVT evolution

	Repermbilization (n=33)	No repermbilization (n=7)	p
Age	57.8	54.2	0.55
Sexe Men / Women	24/9	6/1	0.66
CHILD-PUGH score	6.7	6.1	0.33
Ascite at diagnostic (yes/no)	14/19	1/6	0.22
Hepatic Encephalopathy at diagnostic (yes/no)	4/29	1/6	1.00
Presence of HCC at diagnosis (yes / no)	5/28	2/5	0.58
Platelet count (giga/L)	79	163	0.001
1 Vessel affected	14	4	0.68
2 Vessels affected	13	2	0.69
More than 3 vessels affected	6	1	1.00
One trunk completely thrombosed	3	0	1.00
Diagnostic circumstance :			0.92
-follow-up	25	6	
-decompensation	4	0	
-post radiological intervention	4	0	
-pain	0	1	
Endoscopic portal hypertension (VO 2-3 and gastric PH / VO1)	25/7	5/2	0.65
Radiologic shunt (yes/no)	29/4	6/1	1.00
VKA/LMWH	27/6	5/2	0.61
Median follow up (months)	35.4	24.7	0.43
Start of anticoagulation from PVT (<1 month / >1 month)	27/6	5/2	0.61

Table 5: Summary of the major previous studies

Author, year	Number of patients	Median or mean follow-up (months)	Evolution of PVT under anticoagulation (n - %) complete or partial recanalization / no effect or extension	Bleeding under anticoagulation (n - %)
Francoz, 2005 (1)	19	7.9 (md)	8 - 42.1% /11 - 57.9%	NA
Delgado, 2012 (4)	55	6.8 (1-56)	33 - 60.0% /22 - 40.0%	11 - 20.0 % (6 related to portal hypertension)
Senzolo, 2012 (21)	33	21.6 (md)	21 - 63.6% /12 - 36.4%	3 - 9.1%
Chen, 2016 (22)	30	7.6 (0.2-52.0)	15 - 50.0% /15 - 50.0%	NA
Fujiyama, 2017 (23)	90	NA	74 - 82.0%/16 - 18.0%	NA
Artaza, 2018 (24)	32	NA	23 - 71.9%/9 - 28.1%	3 - 9.4%
La Mura, 2018 (25)	63	23.3±16.2	44 - 69.8%/ 19 - 30.2%	13 - 20.6% (5 related to portal hypertension)
Bergère, 2018	40	33.7 (2-124)	33 - 82.5% / 7 - 17.5%	15 - 37.5% (7 related to portal hypertension)

NA: not available, md: median.