HAL open science

Wild crocodiles hunted to make mummies in Roman Egypt: Evidence from synchrotron imaging

Stéphanie M. Porcier, Camille Berruyer, Stéphane Pasquali, Salima Ikram, Didier Berthet, Paul Tafforeau

To cite this version:

Stéphanie M. Porcier, Camille Berruyer, Stéphane Pasquali, Salima Ikram, Didier Berthet, et al.. Wild crocodiles hunted to make mummies in Roman Egypt: Evidence from synchrotron imaging. Journal of Archaeological Science, 2019, 110, pp.105009 -. 10.1016/j.jas.2019.105009 . hal-03487884

HAL Id: hal-03487884

https://hal.science/hal-03487884v1

Submitted on 20 Jul 2022

HAL is a multi-disciplinary open access archive for the deposit and dissemination of scientific research documents, whether they are published or not. The documents may come from teaching and research institutions in France or abroad, or from public or private research centers.

L'archive ouverte pluridisciplinaire **HAL**, est destinée au dépôt et à la diffusion de documents scientifiques de niveau recherche, publiés ou non, émanant des établissements d'enseignement et de recherche français ou étrangers, des laboratoires publics ou privés.

Distributed under a Creative Commons Attribution - NonCommercial 4.0 International License

Version of Record: https://www.sciencedirect.com/science/article/pii/S0305440319300950
Manuscript_ec7d1269825a8809e6f22b1832fb8d5e

Wild Crocodiles Hunted to Make Mummies in Roman Egypt: Evidence from Synchrotron Imaging

Stéphanie M. Porcier [a,b,*], Camille Berruyer [c, d], Stéphane Pasquali [a], Salima Ikram [e, f], Didier Berthet [g] & Paul Tafforeau [c]

[a] Université Paul-Valéry Montpellier 3, CNRS, UMR 5140_ASM "Archéologie des Sociétés Méditerranéennes", LabEx ARCHIMEDE, France.

[b] Laboratoire CNRS "Histoire et Sources des Mondes Antiques" (HiSoMA_UMR 5189), Maison de l'Orient et de la Méditerranée, Lyon, France.

[c] European Synchrotron Radiation Facility (ESRF), Grenoble, France.

[d] Laboratoire CNRS "ArchéOrient" (UMR 5133), Maison de l'Orient et de la Méditerranée, Lyon, France.

[e] Department of Sociology, Egyptology, and Anthropology, American University in Cairo (AUC), Cairo, Egypt.

[f] Department of Near Eastern Studies, Yale University, New Haven, CT, USA.

[g] Musée des Confluences, Lyon, France.

Declarations of interest: none

Abstract

An ancient Egyptian crocodile mummy (MHNL 90001591, Musée des Confluences, Lyon, France) dating to the Roman period and discovered at Kom-Ombo (Upper Egypt) was analysed through synchrotron multiscale microtomography. Using this advanced technology, the virtual autopsy of the animal was carried out without affecting the bones, flesh, balms and linen bandages. The technique allows for the precise analysis of the specimen's bones and tissue, enabling us to establish the cause of death and the last meal(s) of the animal. From these data, we can conclude that this crocodile was hunted while living in the wild. This is the first evidence for this mode of obtaining animals to produce mummies. With this case study, it is apparent that the praxis related to the mummification of animals in ancient Egypt are more diverse than the current Egyptological reconstruction of that phenomenon.

Keywords : Ancient Egypt, Crocodile, Animal mummy, Hunting, Roman Period, Environment, Synchrotron tomography

© 2019 published by Elsevier. This manuscript is made available under the CC BY NC user license
https://creativecommons.org/licenses/by-nc/4.0/

Highlights:

- Hunting as a source of animals to produce mummies
- Highlight to the cause of death and the last meal(s) of a crocodile
- Virtual autopsy of a crocodile mummy through 3D Synchrotron Imaging
- Diversity of the praxis related to the mummification of animals in ancient Egypt

* Corresponding author. E-mail address: stephanie.porcier@gmail.com (S.M. Porcier)
Université Paul-Valéry Montpellier 3, CNRS, UMR 5140_ASM "Archéologie des Sociétés Méditerranéennes", LabEx ARCHIMEDE. Rue du Professeur Henri Serre, F-34199 Montpellier, France.

Why, into the entrails, the entrails of the crocodile… So to speak, for exploration, for investigation of the facts on the spot. I would, of course, be a novelty, but that is progressive and would at the same time show zeal for enlightenment. (Dostoevsky, 1865) If epigraphs are accepted

1. Introduction

From the 1st Millennium BC until the 4th Century AD (Roman period), the ancient Egyptians mummified millions of animals, most of the mummies having been classified as 'votive offerings' to gods and goddesses by Egyptologists (Ikram, 2017; Richardin et al., 2017). Such large numbers of this type of mummy raises the question of how the animals required for their manufacture were obtained. Egyptologists have proposed several means for supplying such large number of dead bodies. (1) Textual and archaeological evidences indicate that already dead (and sometimes decaying) animals, domestic or wild, were gathered for embalming (Spiegelberg, 1928; Preisigke and Spiegelberg, 1914; Ray, 2011), what tends to prove in particular the large proportion of fragmentary individuals in many mummy packages, as well as the presence of necrophagous insects (Boessneck and von den Driesch, 1987). (2) Another source of supplying would have been the gathering of the bodies of pets as mentioned by Herodotus, the Greek historian (Hérodotus, II.66-67; Boessneck and von den Driesch, 1987). (3) Breeding or keeping animals is the most efficient way, as well as the best documented, for procuring large numbers of animals for mummification (Nicholson, 1994;

Davies and Smith, 2005; Ikram, 2017). For example, mummified ibises at all stages of development, from egg to juvenile to adult, as well as dog or cat mummies of neonates to old animals, have been found (Ikram, 2017; Ikram et al., 2013). Moreover, textual references to « birth chapels » of ibises (Ray, 1976), have raised the question of artificial incubation of eggs for breeding purposes (Martin, 1981; Meeks, 1997). In the case of crocodiles, it has been shown that incubation of eggs and breeding of juveniles and adults were practised to obtain animals to mummify for the god Sobek (Molcho, 2014). The most telling example is the temple of Medinet Madi (Fayum) where two structures have been identified as egg-incubation areas, and crocodile nurseries (Bresciani and Giammarusti, 2006). To this category must be added the animals trapped in their natural environment, fed into structures provided for this purpose, and then sometimes allowed to breed in captivity; as birds of prey for example (Meeks, 2012; Ikram et al., 2015). (4) At last, only a very few Egyptologists have suggested hunting as a mode of procuring animals for mummification, as there was insufficient evidence to support this hypothesis (Preisigke and Spiegelberg, 1914; Nicholson, 1994), except in the case of fish that are caught in their natural habitat (Van Neer, 2004).

In the course of work of the MAHES (Momies Animales et Humaines EgyptienneS) international research program, we analysed a crocodile mummy through synchrotron multiscale microtomography. The resulting data shows that the animal was killed while living in the wild and then was rapidly mummified. This allows us to propose hunting as a mode of obtaining crocodile for mummification. This praxis, which had never been documented by Egyptology, is the first concrete evidence of hunting being used to source animals for mummification.

2. Material and methods

2.1 The crocodile mummy MHNL 90001591

The crocodile mummy (inventory number MHNL 90001591 (Fig. 1)) under study - which has been dated to the Roman period (1935 ± 30 BP; 1-130 cal. AD) using ^{14}C accelerator mass spectrometry (Richardin et al., 2017) - is from the Musée des Confluences in Lyon (France), which houses the largest collection of animal mummies in the world outside Egypt with more than 2500 mummified specimens (cats, dogs, foxes, gazelles, rams, shrews, baboons, ibis, crocodiles, fish, etc.). It brought back from Upper Egypt in the early 20th century, more precisely from Kom Ombo ancient city of a great temple of Sobek. The exact

find-spot is undocumented in the museum register but the mummy was presumably discovered in the el-Shatb necropolis during the excavations carried out by Dr Louis Lortet in February 1909 for the Museum d'histoire naturelle of Lyon (Lortet and Gaillard, 1909; Rabolt, 2013).

Fig. 1. The crocodile mummy MHNL 90001591. *(color: in print and online)*

2.2 Comparison medical CT scan and synchrotron microtomography

In the field of Egyptology, a variety of imaging techniques have been used to study mummies. These include radiography (Falke, 1997; Morgan and McGovern□Hoffman, 2008; McKnight, 2010; Atherton-Woolham and Mcknight, 2014), CT scan (Jackowski et al., 2008; Morgan et al., 2011; Cornelius et al., 2012; Wade et al., 2012; Atherton-Woolham and Mcknight, 2014; McKnight et al., 2015a; Anderson and Antoine, 2019), sometimes MRI, and more less frequently Micro-Computed Tomography (Du Plessis et al., 2015; Ikram et al., 2015). These imaging techniques have revolutionized the study of mummies. Nevertheless, the resolution of these images is often insufficient for archaeological studies where seeing details is crucial. Propagation phase-contrast synchrotron microtomography (PPC-SRµCT) uses a specific technology: the synchrotron light. Thanks to the properties of this particular beam (e.g. coherence, flux, divergence and source size) it is possible to use propagation phase contrast and to create virtual images with a much smaller voxel (3D pixels) size that considerably increases the resolution (Fig. 2). The phase contrast effect also dramatically improves the sensitivity to small details compared with classical absorption contrast (Tafforeau et al., 2006). Despite the fact that this synchrotron-based approach is increasingly used for palaeontological samples, its application on archaeological samples remains very limited, especially regarding investigations of mummies. It has to be noticed that propagation

phase contrast is, to a limited extend, accessible with specific laboratory X-ray sources based systems, as demonstrated on the recent study of a human mummified hand, but these applications remain currently at the proof of concept level due to the extremely long acquisition time it implies (Romell et al., 2018), and the limitations of size of the object studied.

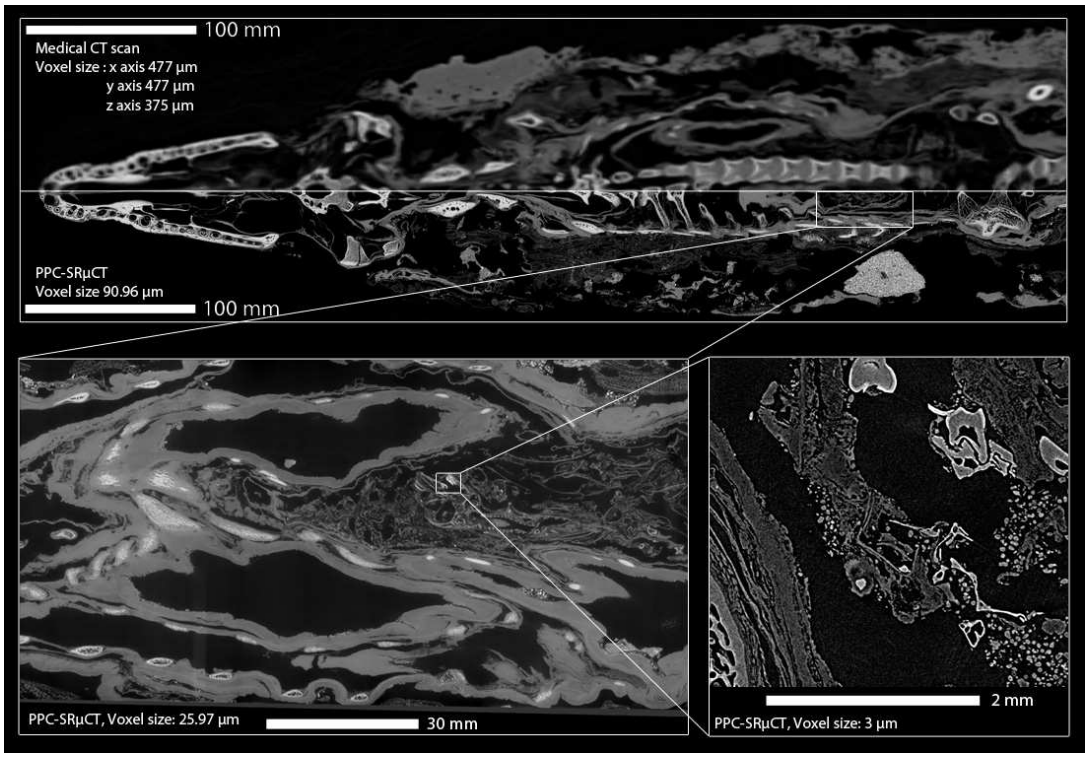

Fig. 2. Comparison between PPC-SRµCT (voxel size 90 µm) and medical CT scan (voxel size: x axis: 477 µm, y axis: 477 µm, z axis: 375 µm; directed by Samuel Mérigeaud, Tridilogy). It illustrates the multi-resolution synchrotron X-ray imaging used in this study: from 90,96 µm for imaging the complete mummy, 25,97 µm for the stomach content, to 3 µm for the teeth of the rodent inside the stomach of the crocodile. The images were taken through different angles for 90,96 µm, 25,97 µm and 3 µm in order to see relevant structures for the different scans.

2.3 Synchrotron imaging protocol

To investigate this specimen, we used the non-destructive hierarchical imaging approach based on the propagation phase-contrast synchrotron microtomography (PPC-SRµCT) with voxel sizes ranging from 90.96 down to 3 µm. The different scans of the mummy MHNL 90001591 were performed at the beamline BM05 of the ESRF. Four different configurations were used to image respectively the complete specimen (voxel size: 90,96 µm; setup presented on Fig. 3 and Video 1), the stomach content (voxel size: 25,97 µm), the humerus structure, (voxel size: 12,99 µm), and the teeth of the rodent in the stomach (voxel size: 3

µm). The reconstruction was performed using the single distance phase retrieval algorithm (Paganin et al., 2002) and filtered back projection as implemented in the PyHST2 software (Mirone et al., 2014). All the 3D renderings and segmentations were performed using the software VGStudioMax 3.0 (Volume Graphics, Heidelberg, Germany). All the acquisition parameters are summarized in the Supplementary Material (Table SM1).

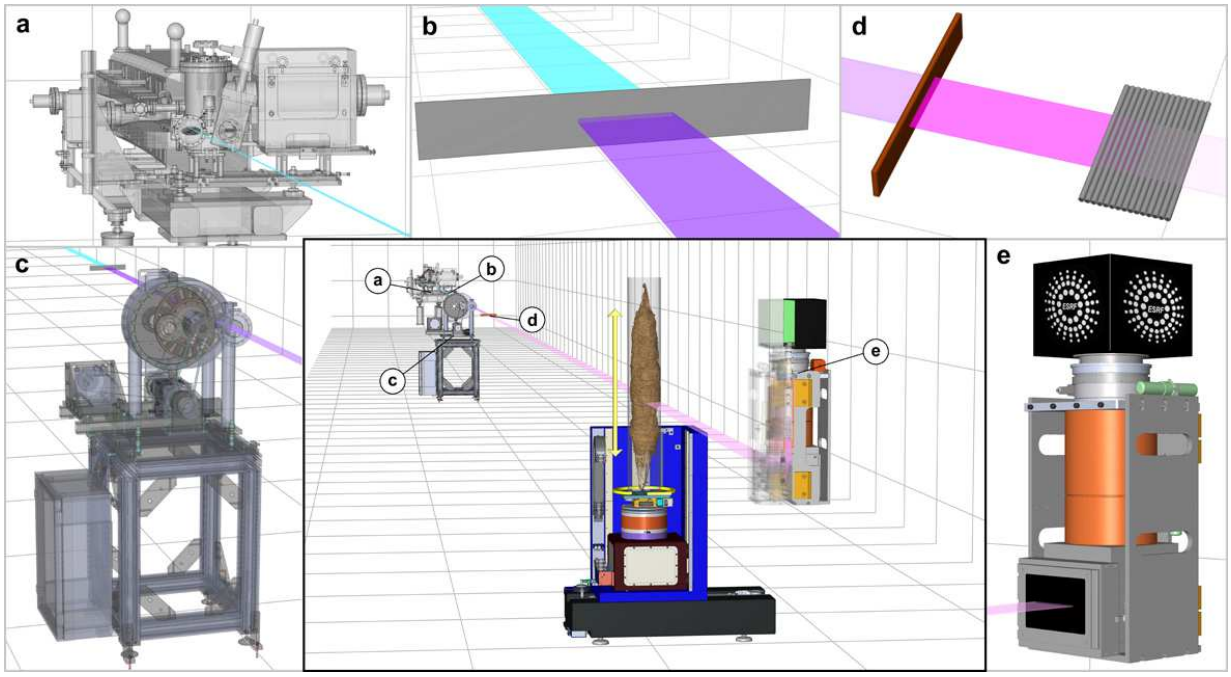

Fig. 3. Schematic diagram of the experimental setup on the BM05 beamline. Perspective rendering is used as the total distance between the X-ray source and the detector is 55m. In addition to the sample stage with the crocodile mummy installed vertically, different elements are depicted with more details. (a) bending magnet in the storage ring, *i.e.* the X-ray source of BM05. (b) 0.4mm thick molybdenum filter to cut out the low energies from the white beam. (c) chopper used to reduce beam power without changing its spectrum. (d) 3mm thick copper filter followed by 15 aluminum bars of 5mm diameter to reach high energies and compensate natural beam vertical profile. (e) Indirect detector based on a large crystal scintillator that produces visible light from X-ray, projected onto a CCD camera through optics. *(color: in print and online)*

3. Results

Mummy MHNL 90001591 is wrapped in several layers of linen impregnated with resins, except for the head and the tip of the tail (Fig. 4a, b, Video 2). The 3D segmentation of the 90,96 µm voxel size data made it possible to separate the mummy from its linen layers (Fig. 4c, Video 2), and then to virtually remove its skin and osteoderms in order to isolate its skeleton and its internal organs (Fig. 4d, e, f, Video 2). The virtual autopsy revealed a juvenile male (Appendices A, Video 3), measuring 112 cm in length (the end of the tail is missing). A

skeletochronological study carried out using virtual histology on the 12,99 µm voxel size data, on the humerus diaphysis, indicates an age at death between 3 and 4 years (Appendices B). The body is very well preserved, without any trace of decomposition, and was not eviscerated during the course of mummification (Fig. 4e).

Fig. 4. Photo and 3D rendering of the crocodile mummy (Inv. MHNL 90001591). Photograph in dorsal view (**a**); 3D rendering showing the same view with the wrapping (**b**), the skin of the crocodile (without the wrapping) in dorsal view (**c**), the muscles and the skeleton in dorsal view (**d**), some internal organs and skeleton in ventral view (**e**) and the skeleton in dorsal view (**f**). *(color: in print and online)*

The crocodile's cranium is fractured in different areas, as visible on medical CT scan and PPC-SRµCT, indicating that the animal received a violent blow (Fig. 5, Video 4). The fracture is located on the top of the skull and affects the frontal, the left squamosal, the left part of the parietal, the left prefrontal, the right quadratum and the right palatine process of palatine and the left postorbital (Shaker and el-Bably, 2015).

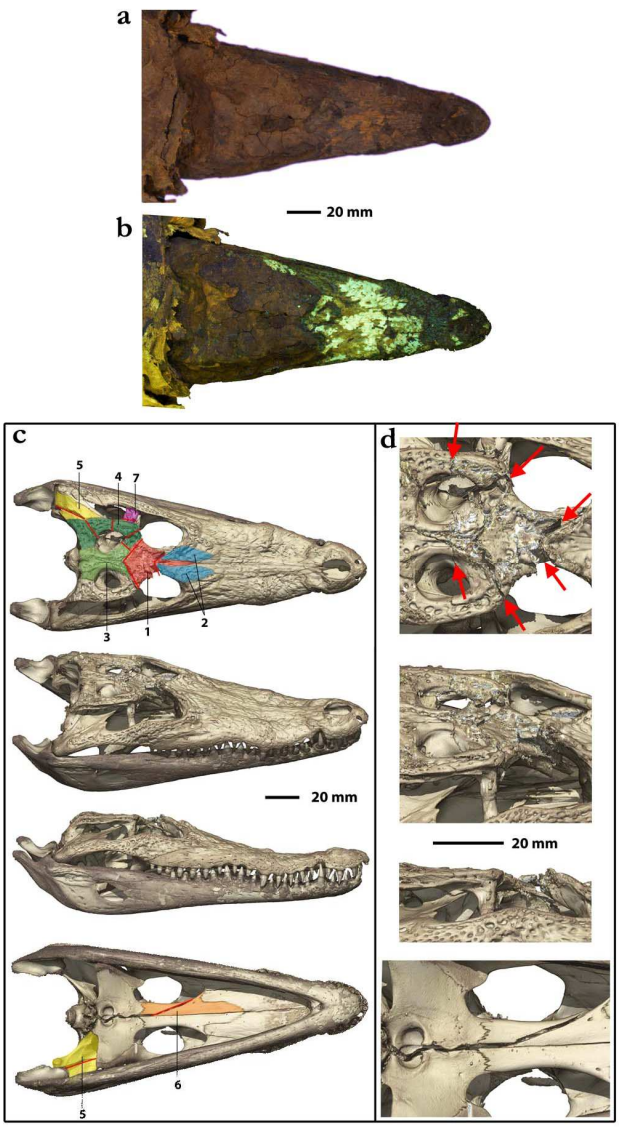

Fig. 5. Photo of the head and 3D rendering showing the lethal skull fracture. From top to bottom: Visible light photography (**a**), Ultra Violet fluorescence photography shows the balm and cranium reconstruction area (**b**), 3d rendering viewed from four different angles and the associated zooms focusing on the fracture itself (**c-d**). The different bones affected by the fracture (red lines and red arrows) are coloured on the dorsal and the ventral views 1. Frontal 2. Prefrontal 3. Parietal 4. Squamosal 5. Quadratum 6. Palatine process of palatine 7. Postorbital. *(color: in print and online)*

Imaging obtained by PPC-SRµCT has enabled the virtual examination of the crocodile's internal organs, which remain inside the body. The stomach, imaged with a voxel size of 25.97 µm, contains different elements in various proportions (Fig. 6, Video 5). As our aim was only to define the diversity level of the stomach contents, only superficial determination of the various organisms present was performed in most of the cases. First of all, the preliminary survey indicates that stomach content is well preserved and is dominated

by soft shell eggs (Fig. 6e) and fragments of insects. Eggs are present in all the stomach with a slightly higher density on the posterior part. We counted 28 different specimens that measure 13.4 mm by 10 mm in average (Fig SM2, table SM3). All the eggs are quite similar in their general aspect, and homogeneous in term of size and eggshell thickness and structure. Considering that they all present a similar level of digestion, one can assume that they were swallowed in a much limited time period. The most probable explanation is that these eggs originate from a single nest belonging to small lizards or snakes, which were eaten by the crocodile. The second most frequent component in the stomach is insects. They include a sub-complete large hemipteran (51.6 mm long) that shows evidence of bite marks. We tentatively identified as a giant water bug *L. cordofanus* (= anc. *L. niloticum*) (Perez Goodwyn, 2006) (Fig. 6a, Fig SM4), the only species of this genus know in Egypt. Other remains of insects, represented by fragments only, (Fig. 6b) belong to coleopterans. We distinguished two groups based on the shape, size, and pattern of these elytra. Several elytra present bite marks too (Fig SM5). All the insects, except the *L. cordofanus*, present only the cuticle, the soft parts having been already digested. In addition to reptiles' eggs and insects, several other remains have been identified in the stomach: three fish vertebrae, only the vertebral bodies are partially preserved due to digestion (Fig. 6c, Fig SM6), fragments of feathers (Fig. 6d), some unidentified plants (Fig. 6f) and a nearly complete rodent (Fig. 6g). The rodent is relatively well preserved, except the head and the lumbar region that are smashed. The flesh and the fur are conserved, though the bones of the forefeet (carpals, metacarpals, phalanges), the distal part of the hind feet (i.e. phalanges) and the last caudal vertebrae are missing, probably destroyed by digestive process. The rodent was identified as a member of the Muridae family based on the 3 µm voxel size data of its teeth. The dental wear, indicates an old individual, and makes it impossible to directly identify it to species level. However considering that there is only one species of *Mus* known in Egypt (Hoath, 2009), we can be tentatively attributed to the species *Mus musculus* (Osborn and Helmy, 1980) whose size and dental morphology are compatible with our observations.

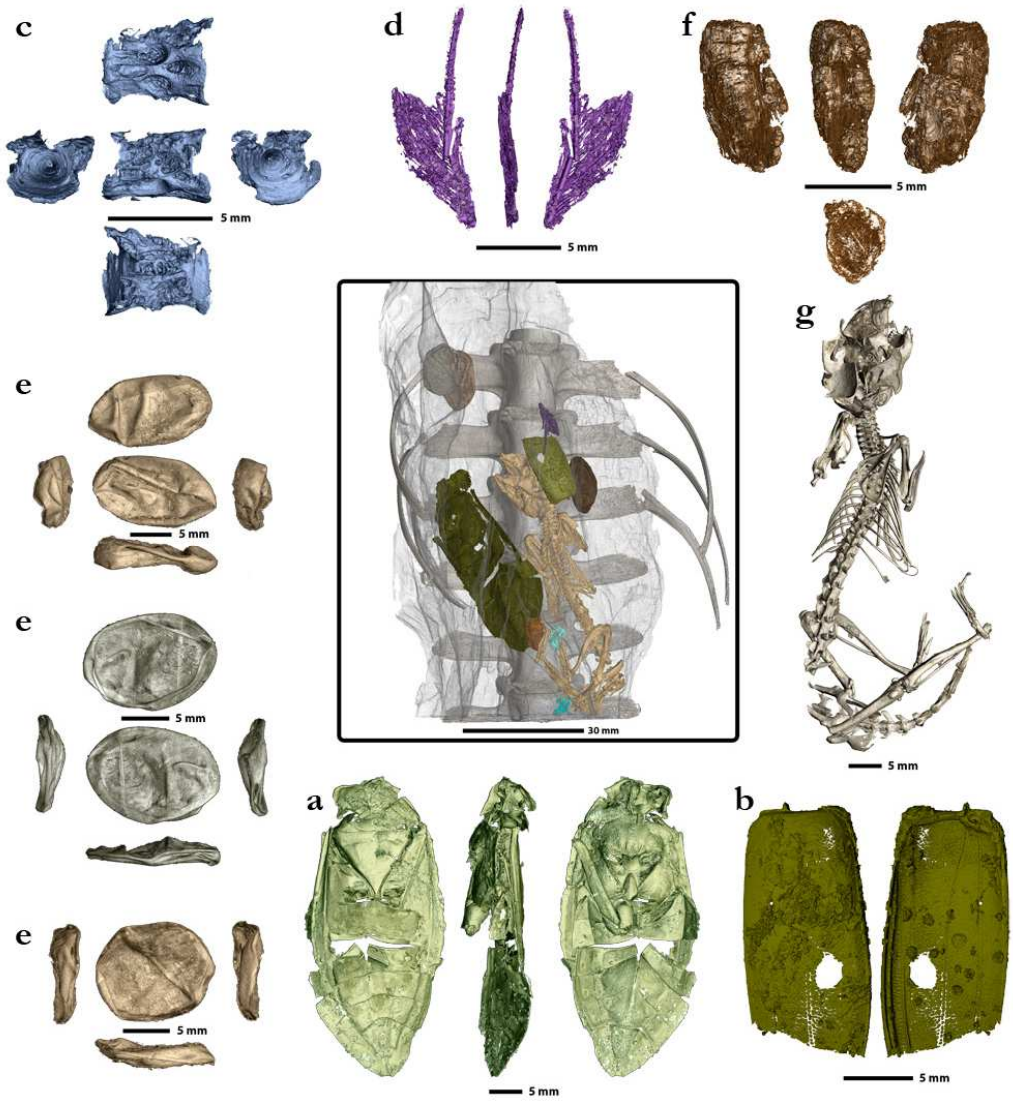

Fig. 6. 3D rendering showing a part of the contents of the crocodile stomach. Stomach (black box) of the crocodile and a representation of the diversity of the stomach content. A nearly complete large *Lethocerus cordofanus* (**a**), a coleopteran elytra (**b**), a fish vertebrae (**c**), a feather (**d**), some soft shell eggs (**e**), a plant (**f**) and a complete rodent from genus *Mus* (**g**). *(color: in print and online)*

4. Discussion

4.1 The cause of the death

The most probable cause of death is a serious skull fracture on the top of skull that caused a direct trauma to the brain. The size of the fracture as well as its direction and shape suggest that it was made by a single blow presumably with a 2cm thick wooden club, aimed at the posterior right side of the crocodile, probably when it was resting on the ground. During

the course of mummification, the depression in the cranium was filled with resinous material, probably to restore the original appearance of the skull so that the animal seemed intact. A similar fracture was noticed on a mummified crocodile kept at Manchester Museum (MM9, 1772; provenance unknown) (McKnight et al., 2015b) and on at least two crocodile heads also from Kom Ombo (Musée des Confluences MHNL 90001839 to 90001841, unpublished, Fig. 7). The latter are not complete, only the back of the skulls are preserved. Dr. Louis Lortet and Dr. Claude Gaillard examined the skulls more than a century ago and concluded that the animals had an undergone amputation of the muzzle caused by a violent blow of an axe that had severed the maxilla and the mandible (Lortet and Gaillard, 1909). According to them, this amputation was intended to prevent the crocodiles from biting anyone before they were killed. Following analysis of radiographic images and CT-scan images carried out as part of the MAHES project, it is not possible to confirm the hypothesis that these animals were mutilated while living. The depression in the cranium of MNHL 90001839 and 90001841 (Fig. 7a), were filled with resinous material during the course of mummification as crocodile MNHL 90001591 (Fig. 4b-c).

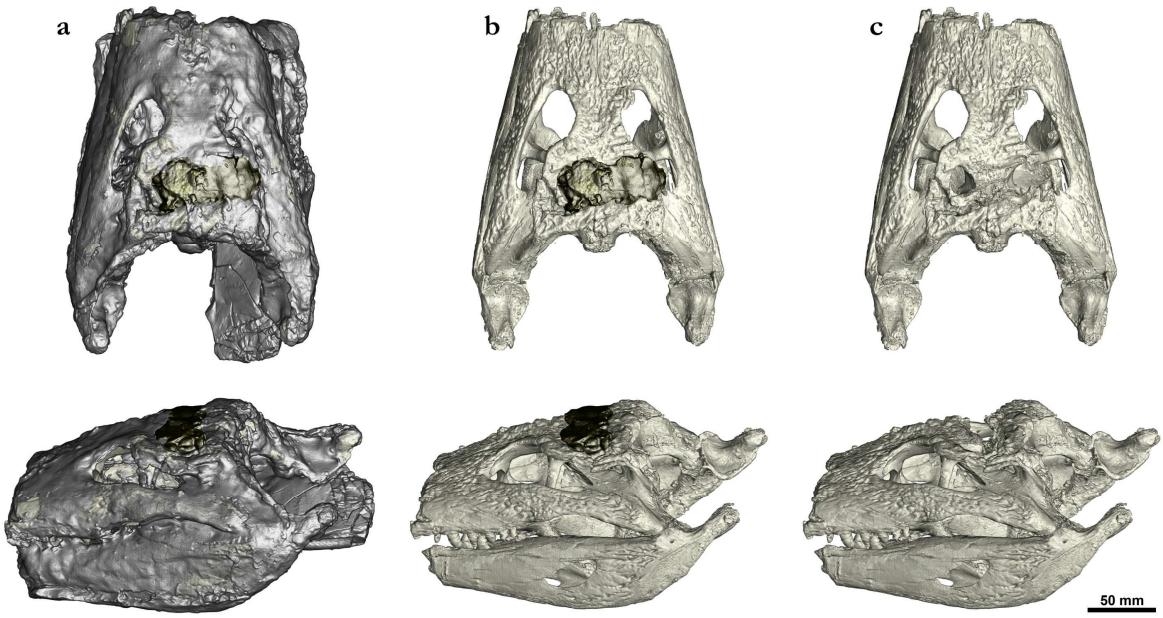

Fig. 7. 3D rendering of a fragment of crocodile skull from Kom Ombo (MHNL 90001841). 3D rendering showing the crocodile's head covered with balm in dorsal and lateral views (**a**), the skull and mandibles with cranium reconstruction area (**b**), the skull and mandibles, without cranium reconstruction area, illustrating cranial fracture at the level of the braincase (**c**) (initial CT from scan Samuel Merigeaud, Tridilogy). *(color: in print and online)*

4.2 The stomach content

The examination of the stomach content clearly shows that it had a diverse diet, corresponding to that of wild crocodiles of a similar age. In the wild, the diet of young crocodiles consists primarily of insects and arachnids (Wallace and Leslie, 2008). Sub-adult crocodiles have a more diverse diet, feeding on small mammals, birds, reptiles, amphibians, crustaceans, fish, and gastropods. They feed on insects and arachnids too, but in a lower proportion than younger animals (Wallace and Leslie, 2008; Tucker et al., 1996; Diefenbach, 1975). When fish are eaten, only the vertebrae remain relatively undigested (Wallace and Leslie, 2008). Unlike other reptiles, complete digestion by crocodiles is relatively quick, and in general takes 72 hours (Pooley and Gans, 1976), although it can be slower, taking up to 8 days if the ambient temperature is around 20°C (Diefenbach, 1975).

Recently, the stomach content of another mummified crocodile (British Museum EA 38562) also coming from Kom Ombo and dated, using ^{14}C accelerator mass spectrometry, to the Saite Period (2518 ± 27 BP; 653-542 cal. BC), was CT-scanned (Anderson and Antoine, 2019). The adult animal measured 3.84 m. It was fed with choice cuts of meat: the right foreleg of a cow/ox (scapula, proximal and distal ends of the humerus) and several long bone shaft fragments have been identified. This supports the hypothesis that the animal was kept in captivity and fed a special diet. These observations can be compared with the writings of the Greco-Roman authors who reported that the Egyptians kept crocodiles in captivity within consecrated enclosures, and that their attendants fed them with sumptuous foods, which consisted of prime meat and poultry (Herodotus II, 69; Diodorus Siculus, I, 84; Strabo XVII, 1, 38; see also Aelianus, X, 21).

In our case, the diverse foodstuffs found in the stomach as well as the bite marks observed on many organisms are clearly the result of a natural diet in the wild, rather than one provided by doting humans. The state of preservation of the bones of the rodent, as well as the general state of the large water bug, demonstrates that they were consumed only a few hours before the crocodile's death. Indeed, studies demonstrate that mice are completely decalcified 24 hours after ingestion (Fisher, 1981). This indicates that the crocodile was not captured alive and kept until it was killed.

4.3 The mummification process

As there is no evidence for insects or fly larvae linked to cadaver decay, it is obvious

that the mummification process was started very rapidly after the death. In this case, mummification consisted of no evisceration - which is common among the animal mummies - , desiccation of the body using natron salts, filling of the hole in the head, anointing the body with resins and oils, and finally wrapping it in linen bandages (Bondetti et al., 2019).

5. Conclusion

All facts ultimately point towards the hypothesis that crocodile MHNL 90001591 was intentionally killed while it was living in its natural environment for the purpose of making mummy. As such, hunting appears as the most likely context, although neither ancient textual sources nor archaeological remains give other evidence that animals were hunted to obtain specimens for mummification. However, this can be compared *mutatis mutandis* to the case of fishing and fowling migratory birds to obtain animals for mummification (van Neer, 2004; Nicholson, 1994). It cannot be ascertained absolutely whether crocodile MHNL 90001591 was strictly a wild animal, or if it lived in relative captivity in its natural environment, in an area bordering the Nile or on the banks of a canal where human action was limited (Molcho, 2014).

With this single example from Roman Egypt, it is impossible to establish if the mummification of a hunted crocodile is an exceptional case resulting from a contingent event, or if hunting might be considered as a common mode of obtaining animals for mummification at a time when the production of 'votive mummies' seems to have increased, and thus the particular modes of production are possibly a consequence (mainly young crocodiles and simply manufactured mummies) (Craston, 2017). Additionally, we cannot exclude the hypothesis that the mummification of a hunted crocodile was a prescription for a particular (but still unidentified) ritual practice, possibly for a specific divine form of Sobek (Quaegebeur, 1984). If analyses of other crocodile mummies show similar results, one would have to reconsider - on both diachrony and synchrony - the current scholarly ideas about the process for sourcing animals for mummification, the process for manufacturing animal mummies, and the related ritual praxis.

Our results demonstrate once again the relevance of such an interdisciplinary study in the field of Archaeology, that ensues from a fruitful dialogue between the traditional 'two cultures' (i.e. Science and Humanities) with a common interpretative framework of the material facts brought here by state-of-the-art imaging technologies (Kristiansen, 2017;

Anheim et al., 2015; Bertrand et al., 2013). In this context, Egyptology translates the science-based evidence at anthropological and historical levels.

Conflicts of interest and funding

The authors declare that they have no conflict of interest. This research was carried out within the framework of the MAHES Project (Momies Animales et Humaines EgyptienneS) supported by the Agence Nationale de la Recherche from the « Investissement d'Avenir » program ANR-11-LABX-0032-01 LabEx ARCHIMEDE, and by the ESRF.

Acknowledgements

The authors want to thank the European Synchrotron Radiation Facility for granting us beamtime at BM05 and ID19. We also acknowledge the Musée des Confluences (Lyon, France); the Agence National de la Recherche; the Labex Archimede (Montpellier, France) especially David Lefèvre and Frédéric Servajean for their ongoing support. We also thank Cédric Audibert, Corentin Bochaton, Ivan Ineich, Laurent Viriot, Vincent Lazzari, Nuria Rovira and Claire Newton for their help in identifying stomach contents. We acknowledge Halima Ali-Toybou for her help in the first synchrotronscanning session of the specimen. Finally, we are grateful to Roger Lichtenberg and Samuel Merigeaud for their contribution to the MAHES project, especially in the radiography and CT-scan of this specimen.

Appendices and Supplementary Material

Appendices and Supplementary Material related to this article can be found at XXX (to be completed by the Editor)

Additional information

All the tomographic data used for the study, as well as several other details scans not presented in the present paper, are available on the open access tomographic database of the ESRF: http://paleo.esrf.eu

References

Anderson, J., Antoine, D., 2019. Scanning Sobek: mummy of the crocodile god. In: Porcier, S., Ikram, S., Pasquali, S. (Eds.), Creatures of Earth, Water, and Sky. Proceedings of the Firth International Symposium of Animals in Ancient Egypt, ISAAE 1, 01-04 June 2016, Lyon, France. Sidestone Press, Leiden (in press).

Anheim, É., Thoury, M., Bertrand, L. 2015. Micro-imagerie de matériaux anciens complexes (I). Rev. synth. 136 (3-4), 329-354. https://doi.org/10.1007/s11873-014-0249-8

Atherton-Woolham, S.D., Mcknight, L., 2014. Post-mortem restorations in ancient Egyptian animal mummies using imaging. Papers on Anthropology, XXIII (1), 9–17. https://doi.org/10.12697/poa.2014.23.1.01

Bertrand, L., Thoury, M., Anheim, E., 2013. Ancient materials specificities for their synchrotron examination and insights into their epistemological implications. Journal of Cultural Heritage 14, 277–289. http://dx.doi.org/10.1016/j.culher.2012.09.003

Boessneck, J., von den Driesch, A., 1987. Tierknochenfunde. In: Boessneck, J. (Ed.), Tuna el-Gebel I. Die Tiergalerien. Hildesheimer Ägyptologische Beiträge 24. Gerstenberg-Verlag, Hildesheim, pp. 98–104.

Bondetti, M., Porcier, St., Ménager, M. Vieillescazes, C., 2019. Une analyse chimique de la composition de baumes de momies animales égyptiennes conservées au musée des Confluences (Lyon, France). In: Porcier, S., Ikram, S., Pasquali, S. (Eds.), Creatures of Earth, Water, and Sky. Proceedings of the Firth International Symposium of Animals in Ancient Egypt, ISAAE 1, 01-04 June 2016, Lyon, France. Sidestone Press, Leiden (in press).

Bresciani, E., Giammarusti, A., 2006. La scoperta del tempio "C" ovvero tempio doppio di Sobek Religione. La nursery per i coccodrilli Sobek nel Tempio C (1999). Gli ultimi coccodrilli di Medinet Madi. In: Bresciani, E., Giammarusti, A., Pintaudi, R., Silvano, F. (Eds.), Medinet Madi. Venti anni di esplorazione archeologica (1984-2005). Università di Pisa, Pisa, pp. 215–219.

Cornelius, I., Swanepoel, L.C., Du Plessis, A., Slabbert, R., 2012. Looking inside votive creatures: computed tomography (CT) scanning of ancient Egyptian mummified animals in Iziko Museums of South Africa: a preliminary report. Akroterion 57, 129–148. http://dx.doi.org/10.7445/57-0-135

Craston, J.I., 2017. Mummified crocodiles: from deity to commodity? In: O'Sullivan, R., Marini, C., Binnberg, J. (Eds.), Archaeological approaches to breaking boundaries:

interaction, integration and division. Proceedings of the Graduate Archaeology at Oxford conferences 2015-2016. BAR International Series 2869. BAR Publishing, Oxford, pp. 83–96.

Davies, S., Smith, H.S., 2005. The Sacred Animal Necropolis at North Saqqara. The Falcon Complex and Catacomb: The Archaeological Report. London: Egypt Exploration Society.

Diefenbach, C.O., 1975. Gastric function in *Caiman crocodilus* (Crocodylia: Reptilia). I-Rate of gastric digestion and gastric motility as a function of temperature. Comp. Biochem. Physiol. 51 (2), 259–265. https://doi.org/10.1016/0300-9629(75)90369-2

Dostoevsky, F.M., 1865. The Crocodile. An Extraordinary Incident. Epoch Magazine. Translated from Russian by C. Garnett. Adelaide: The University of Adelaide Library eBooks. If epigraphs are accepted

Du Plessis, A., Slabbert, R., Swanepoel, L.C., Els, J., Booysen, G.J., Ikram, S., Cornelius, I., 2015. Three-dimensional model of an ancient Egyptian falcon mummy skeleton. Rapid Prototyp. J. 21 (4), 368–372. http://dx.doi.org/10.1108/RPJ-09-2013-0089

Falke, T.H.M., 1997. Radiology of Ancient Egyptian Mummified Animals. In: van Dijk, J. (Ed.), Essays on Ancient Egypt in Honour of Herman te Velde, Egyptological Memoirs 1. STYX Publications, Groningen, pp. 55–59.

Fisher, D.C., 1981. Crocodilian scatology, microvertebrate concentrations, and enamel-less teeth. Paleobiology 7 (2), 262–275. https://doi.org/10.1017/S0094837300004048

Hoath, R., 2009. A Field Guide to the Mammals of Egypt. American Univ. in Cairo Press, Cairo.

Ikram, S., 2017. Animals in ancient Egyptian religion: belief, identity, power, and economy. In: Albarella, U., Rizzetto, M., Russ, H., Vickers, K., Viner-Daniels, S. (Eds.), The Oxford Handbook of Zooarchaeology. Oxford University Press, Oxford, pp. 452–465. http://dx.doi.org/10.1093/oxfordhb/9780199686476.001.0001

Ikram, S., Nicholson, P., Bertini, B., Hurley, D., 2013. Killing Man's best friend?. Archaeological Review from Cambridge 28 (2): 48–66.

Ikram, S., Slabbert, R., Cornelius, I., Du Plessis, A., Swanepoel, L.C., Weber, H., 2015. Fatal force-feeding or Gluttonous Gagging? The death of Kestrel SACHM 2575. J. Archaeol. Sci. 63, 72–77. http://dx.doi.org/10.1016/j.jas.2015.08.015

Jackowski, C., Bolliger, S., Thali, M.J., 2008. Common and unexpected findings in mummies from ancient Egypt and South America as revealed by CT. RadioGraphics 28 (5), 1477–1492. https://doi.org/10.1148/rg.285075112

Kristiansen, K., 2017. The Nature of Archaeological Knowledge and Its Ontological Turns, Norwegian Archaeological Review, 50 (2), 120–123. https://doi.org/10.1080/00293652.2017.1372802

Lortet, L., Gaillard, Cl., 1909. La Faune Momifiée de l'Ancienne Égypte. Archives du Museum d'Histoire naturelle de Lyon 10. Henri Georg, Lyon, pp. 295–299.

McKnight, L.M., 2010. Imaging applied to animal mummification in ancient Egypt. BAR International Series 2175. Archaeopress, Oxford.

McKnight, L.M., Adams, J.E., Chamberlain, A., Atherton-Woolham, St., Bibb, R., 2015a. Application of clinical imaging and 3D printing to the identification of anomalies in an ancient Egyptian animal mummy. J. Archaeol. Sci. Rep. 3, 328–332. http://dx.doi.org/10.1016/j.jasrep.2015.06.028

McKnight, L.M., Atherton-Woolham, S., Adams, J., 2015b. Imaging of Ancient Egyptian Animal Mummies. RadioGraphics 35 (7), 2108–2120. https://doi.org/10.1148/rg.2015140309

Martin, G., 1981. The Sacred Animal Necropolis at North Saqqâra. Excavation Memoir 50. Egypt Exploration Society, London.

Meeks, D., 1997. Les couveuses artificielles en Égypte. In: Meeks, D., Garcia, D. (Eds), Techniques et économies antiques et médiévales. Le temps de l'innovation. Colloque International (CNRS) Aix-en-Provence (mai 1996). Travaux du Centre Camille Jullian 21. Errance, Paris, pp. 132–134.

Meeks, D., 2012. La hiérarchie des êtres vivants selon la conception égyptienne. In: Gasse, A., Servajean, Fr., Thiers, Chr. (Eds), *Et in Ægypto et ad Ægyptum* III, Recueil d'études dédiées à Jean-Claude Grenier, CENiM 5. Université Paul-Valéry, Montpellier, pp. 517-543.

Mirone, A., Gouillart, E., Brun, E., Tafforeau, P., Kieffer, J., 2014. PyHST2: an hybrid distributed code for high speed tomographic reconstruction with iterative reconstruction and a priori knowledge capabilities. Nuclear Instruments and Methods in Physics Research Section B: Beam Interactions with Materials and Atoms 324, 41–48. https://doi.org/10.1016/j.nimb.2013.09.030

Molcho, M., 2014. Crocodile breeding in the crocodile cults of the Graeco-Roman Fayum. Journal of Egyptian Archaeology 100, 181–193. https://doi.org/10.1177/030751331410000110

Morgan, L.W., McGovern-Hoffman, S., 2008. Noninvasive radiographic analysis of an Egyptian falcon mummy from the late period 664–332 BC. J. Avian Biol. 39, 584–587. https://doi.org/10.1111/j.0908-8857.2008.04269.x

Morgan, L.W., McGovern-Huffman, S., French-Kreigh, P., 2011. Comparison of two falconid mummies from the late period of ancient Egypt using noninvasive techniques. J. Raptor Res 45 (4), 357–361. https://doi.org/10.3356/JRR-11-21.1

Nicholson, P.T., 1994. Preliminary Report on Work at the Sacred Animal Necropolis, North Saqqara, 1992. Journal of Egyptian Archaeology 80, 1–10. https://doi.org/10.1177/030751339408000102

Osborn, D.J., Helmy, I., 1980. The Contemporary Land Mammals of Egypt (including Sinai). Fieldiana Zoology new ser. 5. Field Museum of Natural History, Chicago.

Paganin, D., Mayo, S.C., Gureyev, T.E., Miller, P.R., Wilkins, S.W., 2002. Simultaneous phase and amplitude extraction from a single defocused image of a homogeneous object. Journal of Microscopy 206 (1), 33–40. https://doi.org/10.1046/j.1365-2818.2002.01010.x

Perez Goodwyn, P.J., 2006. Taxonomic revision of the subfamily Lethocerinae Lauck & Menke (Heteroptera: Belostomatidae). Stuttgarter Beitr. Naturk. Ser. *A* 695, 1–71.

Pooley, A.C., Gans, C., 1976. The Nile Crocodile. Scientific American 234 (4), 114–125.

Preisigke, F., Spiegelberg, W., 1914. Die Prinz-Joachim-Ostraka, Schriften der Wissenscheftlichen Gesellschaft in Strassburg 19, 1-64 (especially 30□31). https://oi-idb-static.uchicago.edu/multimedia/1343/PJO.pdf

Quaegebeur, J., 1984. La désignation ‘porteurs des dieux’ et le culte des dieux-crocodiles dans les textes des époques tardives. In: Mélanges Adolphe Gutbub. Université de Montpellier, Montpellier, pp. 161–173.Rabolt, M.-C., 2013. Louis Lortet (1836-1909), un médecin naturaliste en Orient. Thèse de Doctorat réalisée sous la direction de Ph. Jaussaud et de R. Perrot. Université Claude Bernard, Lyon I. https://tel.archives-ouvertes.fr/tel-01170276

Ray, J.D., 1976. The Archives of Hor. Texts from Excavations 2. Egypt Exploration Society, London.

Ray, J.D., 2011. Texts from the Baboon and Falcon Galleries, Demotic, Hieroglyphic and Greek Inscriptions from the Sacred Animal Necropolis, North Saqqara. Texts from Excavations 15. Egypt Exploration Society, London.

Richardin, P., Porcier, St., Ikram, S., Louarn, G., Berthet, D., 2017. Cats, crocodiles, cattle, and more: initial steps toward establishing a chronology of ancient Egyptian animals mummies. Radiocarbon 59 (2), 595–607. https://doi.org/10.1017/RDC.2016.102

Romell, J., Vågberg, W., Romell, M., Häggman, S., Ikram, S., Hertz, H.M., 2018. Soft-Tissue Imaging in a Human Mummy: Propagation-based Phase-Contrast CT. Radiology 289 (3), 670–676. https://doi.org/10.1148/radiol.2018180945

Shaker, N.A., el-Bably, S.H., 2015. Morphological and Radiological Studies on the Skull of the Nile Crocodile (*Crocodylus niloticus*). International Journal of Anatomy and Research 3 (3), 1331–1340. https://doi.org/10.16965/ijar.2015.206

Spiegelberg, W., 1928. Neue Urkunden zum ägyptischen Tierkultus. Bayerische Akademie der Wissenschaften. Sitzungsberichte. Philos. philol. und histor. Klasse. Abh. 3, 1-18.

Tafforeau, P., Boistel, R., Boller, E., et al., 2006. Applications of X-ray synchrotron microtomography for non-destructive 3D studies of paleontological specimens. Appl. Phys. A 83, 195–202. https://doi.org/10.1007/s00339-006-3507-2

Tucker, A.D., Limpus, C.J., McCallum, H.I., McDonald, K.R., 1996. Ontogenetic dietary partitioning by *Crocodyus johnstoni* during the dry season. Copeia 1996 (4), 978–988. https://doi.org/10.2307/1447661

van Neer, W., 2004. Evolution of prehistoric fishing in the Nile Valley. Journal of African Archaeology 2, 251–269. https://doi.org/10.3213/1612-1651-10030

Wade, A.D., Ikram, S., Conlogue, G., Beckett, R., Nelson, A.J., Colten, R., Lawson, B., Tampieri, D., 2012. Foodstuff placement in ibis mummies and the role of viscera in embalming. J. Archaeol. Sci. 39 (5), 1642–1647. http://dx.doi.org/10.1016/j.jas.2012.01.003

Wallace, K.M., Leslie, A.J., 2008. Diet of the Nile Crocodile (*Crocodylus niloticus*) in the Okavango Delta, Botswana. Journal of Herpetology 42 (2), 361–368. https://doi.org/10.1670/07-1071.1