



**HAL**  
open science

# Transcranial direct current stimulation in patients with obsessive compulsive disorder: A randomized controlled trial

Rémy Bation, Marine Mondino, Florent Le Camus, Mohamed Saoud, Jerome Brunelin

## ► To cite this version:

Rémy Bation, Marine Mondino, Florent Le Camus, Mohamed Saoud, Jerome Brunelin. Transcranial direct current stimulation in patients with obsessive compulsive disorder: A randomized controlled trial. *European Psychiatry*, 2019, 62, pp.38 - 44. 10.1016/j.eurpsy.2019.08.011 . hal-03487848

**HAL Id: hal-03487848**

**<https://hal.science/hal-03487848>**

Submitted on 20 Jul 2022

**HAL** is a multi-disciplinary open access archive for the deposit and dissemination of scientific research documents, whether they are published or not. The documents may come from teaching and research institutions in France or abroad, or from public or private research centers.

L'archive ouverte pluridisciplinaire **HAL**, est destinée au dépôt et à la diffusion de documents scientifiques de niveau recherche, publiés ou non, émanant des établissements d'enseignement et de recherche français ou étrangers, des laboratoires publics ou privés.



Distributed under a Creative Commons Attribution - NonCommercial 4.0 International License

tDCS in OCD

## Title

**Transcranial direct current stimulation in patients with obsessive compulsive disorder:  
A randomized controlled trial**

Authors

Rémy BATION<sup>1,2,3</sup>; Marine MONDINO<sup>1,2</sup>; Florent LE CAMUS<sup>1,2</sup>; Mohamed SAOUD<sup>1,2,3</sup>;  
Jerome BRUNELIN<sup>1,2</sup>

Affiliations

- 1) INSERM U1028; CNRS UMR5292; PSYR2 Team; Lyon Neuroscience Research Center; Université Claude Bernard Lyon 1, Lyon, France
- 2) Centre Hospitalier Le Vinatier, Bron, France
- 3) Psychiatric Unit, Wertheimer Neurologic Hospital, CHU Lyon, F69500, Bron, France

Correspondence

Rémy BATION

Wertheimer Neurologic Hospital, CHU Lyon, F69500, Bron, France

[remy.bation@chu-lyon.fr](mailto:remy.bation@chu-lyon.fr)

Word counts

In the abstract: 229

In the text: 3257

Number of figures: 3/ Number of tables: 2/ Number of supplementary materials: 0

## **Abstract**

**Background:** Obsessive-compulsive disorder (OCD) is a severe mental disorder with poor response to the available treatments. Neuroimaging studies have identified dysfunctions within the orbito-fronto-striato-pallido-thalamic network in patients with OCD. Here, we assessed the efficacy and safety of transcranial direct current stimulation (tDCS) applied with the cathode over the orbitofrontal cortex (OFC) and the anode over the right cerebellum to decrease OCD symptoms in patients with treatment-resistant OCD.

**Methods:** In a randomized sham-controlled double-blind study, 21 patients with OCD were assigned to receive ten 20-min sessions (two sessions per day) of either active (2 mA) or sham tDCS. The clinical symptoms were measured using the Yale-Brown Obsessive and Compulsive Scale (YBOCS). Acute effects on the symptoms were measured from baseline to immediately after the 10 tDCS sessions. Long-lasting effects were measured 1 and 3 months after the 10th tDCS session.

**Results:** Compared with the sham tDCS, active tDCS significantly decreased OCD symptoms immediately after the 10th tDCS session ( $F_{(1,19)}=5.26$ ,  $p = 0.03$ ). However, no significant differences were observed between the active and sham groups in terms of changes in YBOCS score or the number of responders one and 3 months after tDCS.

**Conclusion:** Despite significant acute effects, tDCS with the cathode placed over the left OFC and the anode placed over the right cerebellum was not significantly effective in inducing a long-lasting reduction of symptoms in patients with treatment-resistant OCD.

## **Main Text**

### BACKGROUND

Obsessive-compulsive disorder (OCD) is a highly prevalent and devastating psychiatric condition. Despite advances in patient management, approximately 30-60% of patients do not improve or show a partial response to current medications whether given in combination with cognitive and behavioral therapies (CBTs) or are unable to tolerate medication side effects.

(1)

Growing evidence suggests that the neurobiological substrates of OCD involve abnormal activity and connectivity within the orbito-fronto-striato-pallido-thalamic network with increased activity in the orbitofrontal cortex (OFC), the cingulate gyrus and the caudate (2, 3). This hyperactivity is correlated with the severity of OCD and is diminished by effective pharmacological, psychotherapeutic and neurosurgical treatments (4). Structural abnormalities have also been highlighted in this circuit in the form of decreased gray matter volume in the OFC and the cingulate, in contrast to the increased volume of the thalamus and the putamen (5). More recently, the role of the cerebellum in OCD pathophysiology has been highlighted by studies showing increased cerebellar volume (6-11) and increased connectivity (12,13), including connections with the basal ganglia (14), in patients with OCD compared to those of healthy controls. Hypoactivity in the cerebellum has also been described in patients with OCD (15-18) and seems to be corrected by neurosurgical treatment (19), cognitive and behavioral therapy (15, 20) or selective serotonin reuptake inhibitors (SSRIs) (20, 21). Altogether, these studies suggest that the cerebellum might have a significant yet poorly appreciated role in neuropsychiatric diseases including OCD.

When used repeatedly, noninvasive brain stimulation techniques such as repetitive transcranial magnetic stimulation (rTMS) and direct current stimulation (tDCS) were

described as powerful tools to modulate activity and connectivity within large widespread brain networks. The physiological effects of those techniques can outlast the stimulation period. In cases of treatment-resistant symptoms, these techniques have been proposed as therapeutic options when applied over abnormal brain regions in patients with several psychiatric conditions (22, 23). Hence, rTMS has been used in several clinical studies in patients with OCD (24). Targeting the supplementary motor area (SMA), the OFC or the medial prefrontal cortex with “inhibitory” low-frequency rTMS holds promise for alleviating obsessive and compulsive symptoms (23, 25). However, other studies failed to highlight the usefulness of rTMS in patients with OCD, leaving room to explore other approaches (24). tDCS is a noninvasive technique in which a weak current is generated between an anode and a cathode placed over the scalp of the subject. Neurophysiological and animal studies described that an increase in cortical excitability and spontaneous neural activity occurred under the anode, whereas a decrease in cortical excitability and spontaneous neural activity occurred under the cathode (26). tDCS enables the simultaneous stimulation of different areas and modulation of different brain areas involved in cortico-subcortical loops (27). tDCS has been shown to have clinical effectiveness in the treatment of various psychiatric disorders (22). It has been suggested that tDCS might be useful in decreasing the symptoms of patients with treatment-resistant OCD (28, 29), but the optimal target locations and stimulation parameters remain under debate.

We hypothesized that targeting the left hyperactive OFC (3) with cathodal tDCS (assumed to decrease cortical excitability (26)) coupled with anodal tDCS (assumed to increase cortical excitability (26)) over the right hypoactive cerebellum (15) may reduce obsessive and compulsive symptoms by modulating neuronal activity within the orbito-fronto-striato-pallido-thalamic loop. We have previously reported the efficacy of this electrode montage in

## tDCS in OCD

an open-label study that included 8 patients with treatment-resistant OCD (30). Here, we developed a randomized sham-controlled study to assess the clinical efficacy and safety of OFC cathodal-tDCS coupled with cerebellum anodal-tDCS in patients with treatment-resistant OCD. We investigated the acute effects of tDCS by assessing the symptoms immediately after the tDCS regimen and the long-lasting effects by measuring symptoms one and three months after tDCS.

## 1 MATERIALS AND METHODS

Patients were randomly assigned in a 1:1 ratio to either the active or sham tDCS group. We used a block randomization with a block size of four. The study was approved by the local ethics committee (Comité de Protection des Personnes of Sud-Est 6, Lyon, France). All subjects gave their written informed consent after receiving a full description of the study. This study was preliminarily registered on the clinicaltrials.gov database (clinicaltrials.gov identifier NCT 02407288).

### 1.1 Subjects

To be eligible, patients had to be 18-70 years old, have a primary diagnosis of OCD according to the DSM IV criteria, have clinically significant OCD symptoms (defined as a total Yale-Brown Obsessive and Compulsive Scale (YBOCS) (31) score  $> 16$ ) and have received an adequate trial of SSRI (at least 12 weeks, of which 6 weeks had to be at the maximum tolerated dose). Patients were not included if they presented severe depressive symptoms defined by a Montgomery and Asberg Depression Rating Scale (MADRS) (32) score  $> 30$ , had a history of psychotic disorders, drug abuse, or significant head injury, were acutely suicidal, or had implanted devices or metal in the brain. Pregnant women were not eligible to participate. Patients with prior exposure to tDCS were also excluded to reduce the risk of unblinding. Subjects were required to receive stable doses of a serotonin reuptake inhibitor

(SRI) for at least 6 weeks before entering the study. The medication dosage was kept consistent throughout the trial.

A total of 35 patients were assessed for eligibility. Thirteen patients declined to participate, and one patient was excluded because of an additional diagnosis of a psychotic disorder. A total of 21 patients completed the study. The final analyzed sample consisted of 21 right-handed patients with treatment-resistant OCD, of which, 10 patients received active tDCS, and 11 received sham treatment. Please see the CONSORT flow chart diagram shown in Figure 1.

\*\* Figure 1 about here\*\*

## 1.2 tDCS parameters

Stimulation sessions were delivered using a neuroConn DC stimulator (Ilmeneau, GmbH) with two 7×5 cm (35 cm<sup>2</sup>) sponge electrodes soaked in a saline solution (0.9% NaCl). The patients received 2 sessions of tDCS per day for 5 consecutive days (from Monday to Friday). The two daily sessions were separated by at least 3 hours. Each session of active tDCS consisted of delivering a direct current with an intensity set at 2 mA for 20 min. The electrodes were placed according to the international 10-20 electrode placement system. The cathode was placed on FP1 to target the left OFC, and the anode was placed 3 cm below theinion and 1 cm right of the midline to target the right cerebellum. To maintain blinding of the experimenters and participants regarding the tDCS condition, we used the commercial built-in sham procedure of the device (double-blind ‘study mode’). The care provider entered a preprogrammed code that delivered either active or sham tDCS but was unaware of which

## tDCS in OCD

condition the code applied. The list of codes was established by a researcher not involved in the tDCS delivery, data collection or analyses. In the sham, the same stimulation parameters as in the real condition were displayed, but after 40 s of real stimulation (2 mA), only brief current pulses of 110  $\mu$ A over 15 ms occurred every 550 ms through the remainder of the 20-min period. Participants, care providers, investigators, and outcome assessors were blinded to the treatment assignment. Safety was assessed after each tDCS session with a structured interview (33), and serious adverse events were systematically recorded by the investigator.

### 1.3 Clinical outcomes

All clinical outcomes were measured at baseline (before the first tDCS session), immediately after the 10 tDCS sessions (M0), and one month (M1) and three months after tDCS (M3).

Obsessive and compulsive symptoms were assessed using the Y-BOCS, the clinical global impression scale (CGI) (34) and a self-reporting OCD visual analogue scale (OCD-VAS). To complete the OCD-VAS, patients were required to rate their current obsessive and compulsive symptoms on a 10-point scale (0 = Worst Ever to 10 = Best Ever). The clinical response was defined as a decrease  $\geq 35\%$  on the Y-BOCS or a score of 2 or less on the CGI-I (much or very much improved). Depressive symptoms and anxiety were assessed using the MADRS (32) and State-Trait Anxiety Inventory (STAI-YA) (35), respectively. Level of functioning was assessed by the Global Assessment of Functioning (GAF) scale (36).

### 1.4 Statistical analysis

Statistical analyses were performed using SPSS (version 22). Fisher's exact tests and two-tailed Student's t-tests were applied to compare the demographics and clinical measures at baseline between the active and sham groups for categorical and continuous variables, respectively.



The primary analysis investigated acute changes in the YBOCS score. Acute changes in clinical scores between baseline and after the 10 tDCS sessions (at M0) were compared using repeated-measures analysis of variance (ANOVA) with treatment as the intergroup factor and time as the intrasubject factor. For significant changes, post hoc comparisons were performed using Fisher's least significant difference tests.

Secondary clinical analyses investigated maintenance effects on the YBOCS score, response rate and effects on other symptoms. Changes in the YBOCS scores over the 12-week follow-up period were compared using repeated-measures analysis of variance (ANOVA), including terms for group, time, and time by group interaction. Response rates at each time point (defined as an Y-BOCS score reduction of at least 35% between inclusion and month 1 post-tDCS) were compared using Fisher's exact test. The effects on other symptoms (MADRS, CGI, STAI, VAS) were analyzed in the same manner.

All tests were conducted with two-sided significance levels ( $\alpha= 0.05$ ).

## 2 RESULTS

### 2.1 Demographics and baseline clinical characteristics

Twenty-one patients were recruited and completed the trial. As shown in Table 1, the active and sham groups did not differ significantly in demographics or baseline clinical ratings.

INSERT TABLE 1 ABOUT HERE

### 2.2 Clinical outcomes

Clinical measures are presented in Table 2. The evolution of the total YBOCS score

## tDCS in OCD

throughout the study period is represented in Figure 2.

### Acute effect

The repeated-measures ANOVA revealed a significant interaction between time and group ( $F_{(1,19)}=5.26$ ,  $p = 0.033$ ). After the 10<sup>th</sup> session of tDCS, the YBOCS score increased by a mean of + 2.3% (standard deviation 5.9) in the sham group and decreased by -4.7% (7.9) in the active group. The post hoc comparisons showed a significant reduction in YBOCS scores in the active group after the 10<sup>th</sup> session compared to those at baseline ( $p = 0.031$ ). However, no differences were observed in the sham group between baseline and after the 10<sup>th</sup> session, and no differences were observed between groups after the 10<sup>th</sup> session.

### Maintenance effect

The repeated-measures ANOVA for the 12-week period revealed a significant time effect ( $F_{(3,57)} = 4.93$ ,  $p = 0.01$ ) but no significant group effect ( $F_{(3,57)} = 0.64$ ,  $p = 0.43$ ) or interaction between time and group effect ( $F_{(3,57)} = 0.66$ ,  $p = 0.53$ ).

No patients were classified as responders in either group at M0. The response rate at month 1 was not different between the 2 groups (10% in the active group vs 0% in the sham group;  $p= 0.47$ ). The response rate at month 3 was not different between the 2 groups (20% in the active group vs 10% in the sham group,  $p = 0.58$ ). Two patients in the active group were classified as responders at the end of the trial. These two patients had the lowest level of resistance (2 and 3 according to the stage of resistance defined by Pallanti and Quercioli (1): 2 and 3 SSRIs and a cognitive and behavioral therapy method) in the active group (mean level of resistance: 6.2) and were both young women with contamination OCD.

### Effect on other symptoms

The repeated-measures ANOVA on the Global Assessment Functioning scores revealed a significant group by time interaction ( $p=0.028$ ) (Table 2), but the post hoc tests showed no significant differences between the groups at any time.

The linear regression model testing if changes in the total Y-BOCS scores between baseline and month 3 post-tDCS were associated with resistance level, total YBOCS score at baseline, depression score at baseline, anxiety score at baseline, sex, and thematic content revealed that only the level of resistance was associated with an improvement in YBOCS score at the end of the trial ( $F_{(1,9)} = 7.695$ ,  $R^2 = 0.490$   $p=0.024$ ) in the active group.

Regarding the safety of tDCS in patients with OCD, the stimulation sessions were well tolerated by the patients, and no serious adverse events were observed.

INSERT FIGURE 2 ABOUT HERE

INSERT TABLE 2 ABOUT HERE

### 3 DISCUSSION

The present study is the first parallel randomized sham-controlled study to explore the clinical efficacy and safety of fronto-cerebellar tDCS in patients with SSRI-resistant OCD. The results indicated that active tDCS targeting the left OFC and the right cerebellum induced a significant acute reduction of OCD symptoms immediately after the tDCS regimen compared to sham stimulation. However, active tDCS was not superior to sham stimulation in alleviating OCD symptoms over a 12-week period. Among the different clinical measures evaluated (total YBOCS scores, subscores, questionnaire results, clinician global inventory score), no significant differences between the active and sham groups were revealed.

The lack of significant long-lasting effects of active tDCS observed in this study could be partially explained by the high level of resistance of the included subjects. The majority of subjects included in this study had severe (YBOCS score at inclusion of 29 and 29.5 for the active and sham groups, respectively), chronic (an illness duration of more than 20 years) and resistant symptoms (mean resistance level above 5, which corresponds to at least 3 selective serotonin reuptake inhibitors, including clomipramine and a cognitive and behavioral therapy method). The patients were on a stable medication dosage for at least six weeks before inclusion into the study and during the three-month follow-up. Assessments were performed in accordance with the European Medicines Agency guidelines with the OCD auto- and hetero-evaluations (OCD-VAS and YBOCS), a functional assessment (CGI) and a three-month follow-up (37). The population was carefully selected to be clinically stable without major comorbidities, including depression (MADRS < 30). A linear regression confirmed that the level of resistance was related to improvements in obsessive and compulsive symptoms at the end of the trial. In line with this hypothesis, the two responders had the lowest resistance level within the active group. Thus, these negative results cannot be easily generalized to SSRI-resistant OCD patients because our population showed a high level of resistance (above 5 according to the Pallanti and Quercioli criteria (1)).

Second, the lack of significant long-lasting effects observed in the current study can also be partially explained by the tDCS parameters. Indeed, the optimal tDCS parameters in terms of both dosage and electrode placement are not yet well-established for the treatment of OCD (38) and could have been suboptimal in our study. We chose to use a treatment pattern that has induced beneficial outcomes in patients with schizophrenia (39): two 20-min daily sessions delivered in one week; however, recent data showed that patients with other psychiatric diseases (e.g., depression and schizophrenia) favored longer treatment (>4 weeks

in depression), higher intensity (3 mA versus 2 mA) and longer sessions (30 min versus 20 min). One can hypothesize that a higher tDCS dosage than the dosage in this study could be suitable to achieve remission in patients with OCD (22). The tDCS dose, along with head anatomy, determines the resulting current flow (intensity and pattern) in the brain and in turn affects the resulting neurophysiological and behavioral changes (40). An electric field distribution simulation made using SimNIBS 2.0.1 (41) of the electrode montage used in the current study showed a high electric density in the right cerebellum, but the electric field in the prefrontal cortex was more pronounced in the inferior frontal gyrus than in the orbitofrontal gyrus (Figure 3). The insufficient electric field density in the OFC area might explain the lack of long-lasting clinical effects observed in the current study.

INSERT FIGURE 3 ABOUT HERE

Our montage is the first cerebellar tDCS montage used in OCD patients. The cerebellar involvement in OCD pathophysiology has gained increasing attention in recent years with large-scale studies and meta-analyses showing bilateral enlargement and functional and structural hyperconnectivity in the cerebellum (42, 43). However, specifying the nature of cerebellar dysfunction remains a daunting task. According to the embodied cognition theory, cognition and emotion are grounded in the sensorimotor system and share similar modes of processing. These connections might be extremely relevant in the cerebellar setting where sensorimotor, cognition and emotion share the same type of processing (Universal Cerebellar transform theory (44)). Therefore, the cerebellum and its connection with the basal ganglia and cortical area may implement habitual, nonflexible patterns of movement (rituals), cognitions and emotions (obsessions) (45). The cerebellum and its connection with basal ganglia loops are involved in setting habits (45) and could, in this way, contribute to the

## tDCS in OCD

imbalance between goal-directed actions and habits in OCD (46). Volume alteration has not been reported in children with OCD (9), suggesting that cerebellum enlargement could be an adaptive process of OCD tendencies to over-rely on habitual rigid automatic stimulus-driven behaviors and cognitions.

In summary, tDCS with the cathode placed over the left OFC combined with the anode placed over the right cerebellum is a safe approach in patients with OCD, but despite a statistically significant acute effect, we failed to confirm the promising results observed in a previous open-label trial (30). Many positive results obtained in open label study fail to be replicated in RCT. Different phenomenon may increase the risk of false positive in open label study: publication bias, regression towards the average, a higher level of expectancy for response compare to the level of expectancy in RCT. One limitation of the current study is the sample size. Indeed, although comparable with other studies in the field, it could be considered as relatively small, especially in the context of heterogeneity in OCD. Owing to the highly prevalent resistance of OCD patients in this study, further controlled studies should be considered before any conclusions are made regarding the usefulness of tDCS in patients with OCD. Future studies should pay particular attention to factors that can improve the clinical efficacy of tDCS. First, inducing activity during stimulation of the targeted neuronal networks is of prime importance to achieving neurobiological and clinical effects because tDCS mostly works by enhancing neuroplasticity (47) and learning (48). Combining noninvasive brain stimulation with symptom provocation (49, 50) or cognitive behavioral therapy techniques could potentially improve outcomes (51). Second, the amount of electrical stimulation that reaches the targeted area is a critical factor in inducing clinical effects. Computational models to estimate cortical electric fields (52) and high-definition tDCS (53) are tools that may help

us design more focused tDCS montages. Third, the tDCS dosage could be insufficient in our study. Using a higher number of sessions over a longer period of time may be needed to obtain clinically significant responses. Lastly, optimal electrode positioning in OCD remains a daunting issue. Neuroimaging studies, can only infer correlation and not causation. Non-invasive brain stimulation clinical studies have yielded mixed findings, as distinct brain areas have been stimulated, (e.g., the left or right dorsolateral prefrontal cortex, the OFC, the supplementary motor areas) with no distinct most effective intervention (24). Two categories of tDCS montages have been used: montages with electric field focused in different prefrontal cortical regions and montages with more diffused electric field in larger and distributed cortical areas across different brain regions. However, for both categories of montages improvement of symptoms has been reported (54). The incomplete understanding of the neurocircuits involved in OCD and its different subtypes (55) associated with the variability of individual effects of tDCS may explain modest and heterogenous clinical results in resistant OCD.

### **Conflicts of interest**

None to disclose

### **Funding**

The study was supported by the “Conseil Scientifique de la Recherche” from CH le Vinatier.

### **Acknowledgments**

The authors thank Caroline Damasceno, Frederic Haesebaert, and Philippe Vignaud for their help with the project.

## References

1. Pallanti S, Quercioli L. Treatment-refractory obsessive-compulsive disorder: methodological issues, operational definitions and therapeutic lines. *Prog Neuropsychopharmacol Biol Psychiatry*. 2006 May;30(3):400–12.
2. Whiteside SP, Port JD, Abramowitz JS. A meta-analysis of functional neuroimaging in obsessive-compulsive disorder. *Psychiatry Res*. 2004 Nov 15;132(1):69–79.
3. Fettes P, Schulze L, Downar J. Cortico-Striatal-Thalamic Loop Circuits of the Orbitofrontal Cortex: Promising Therapeutic Targets in Psychiatric Illness. *Front Syst Neurosci*. 2017;11:25.
4. van der Straten AL, Denys D, van Wingen GA. Impact of treatment on resting cerebral blood flow and metabolism in obsessive compulsive disorder: a meta-analysis. *Sci Rep*. 2017 Dec 12;7(1):17464.
5. Piras F, Piras F, Chiapponi C, Girardi P, Caltagirone C, Spalletta G. Widespread structural brain changes in OCD: a systematic review of voxel-based morphometry studies. *Cortex J Devoted Study Nerv Syst Behav*. 2015 Jan;62:89–108.
6. Pujol J, Soriano-Mas C, Alonso P, Cardoner N, Menchón JM, Deus J, et al. Mapping structural brain alterations in obsessive-compulsive disorder. *Arch Gen Psychiatry*. 2004 Jul;61(7):720–30.
7. Tobe RH, Bansal R, Xu D, Hao X, Liu J, Sanchez J, et al. Cerebellar morphology in Tourette syndrome and obsessive-compulsive disorder. *Ann Neurol*. 2010 Apr;67(4):479–87.
8. Real E, Labad J, Alonso P, Segalàs C, Jiménez-Murcia S, Bueno B, et al. Stressful life events at onset of obsessive-compulsive disorder are associated with a distinct clinical pattern. *Depress Anxiety*. 2011 May;28(5):367–76.
9. Hu X, Du M, Chen L, Li L, Zhou M, Zhang L, et al. Meta-analytic investigations of common and distinct grey matter alterations in youths and adults with obsessive-compulsive disorder. *Neurosci Biobehav Rev*. 2017 Jul;78:91–103.
10. de Wit SJ, Alonso P, Schweren L, Mataix-Cols D, Lochner C, Menchón JM, et al. Multicenter voxel-based morphometry mega-analysis of structural brain scans in obsessive-compulsive disorder. *Am J Psychiatry*. 2014 Mar;171(3):340–9.
11. Eng GK, Sim K, Chen S-HA. Meta-analytic investigations of structural grey matter, executive domain-related functional activations, and white matter diffusivity in obsessive compulsive disorder: an integrative review. *Neurosci Biobehav Rev*. 2015 May;52:233–57.
12. Anticevic A, Hu S, Zhang S, Savic A, Billingslea E, Wasylink S, et al. Global resting-state functional magnetic resonance imaging analysis identifies frontal cortex, striatal, and cerebellar dysconnectivity in obsessive-compulsive disorder. *Biol Psychiatry*. 2014 Apr 15;75(8):595–605.
13. Tian L, Meng C, Jiang Y, Tang Q, Wang S, Xie X, et al. Abnormal functional connectivity of brain network hubs associated with symptom severity in treatment-naive patients with obsessive-compulsive disorder: A resting-state functional MRI study. *Prog Neuropsychopharmacol Biol Psychiatry*. 2016 Apr 3;66:104–11.
14. Vaghi MM, Vértes PE, Kitzbichler MG, Apergis-Schoute AM, van der Flier FE, Fineberg NA, et al. Specific Frontostriatal Circuits for Impaired Cognitive Flexibility and Goal-Directed Planning in Obsessive-Compulsive Disorder: Evidence From Resting-State Functional Connectivity. *Biol Psychiatry*. 2017 15;81(8):708–17.
15. Nabeyama M, Nakagawa A, Yoshiura T, Nakao T, Nakatani E, Togao O, et al. Functional MRI study of brain activation alterations in patients with obsessive-compulsive disorder after symptom improvement. *Psychiatry Res*. 2008 Aug 30;163(3):236–47.
16. Wen S-L, Cheng M-H, Cheng M-F, Yue J-H, Wang H. Pharmacotherapy response and regional cerebral blood flow characteristics in patients with obsessive-compulsive disorder. *Behav Brain Funct BBF*. 2013;9:31.



17. Milad MR, Furtak SC, Greenberg JL, Keshaviah A, Im JJ, Falkenstein MJ, et al. Deficits in conditioned fear extinction in obsessive-compulsive disorder and neurobiological changes in the fear circuit. *JAMA Psychiatry*. 2013 Jun;70(6):608–618; quiz 554.
18. Moon C-M, Jeong G-W. Associations of neurofunctional, morphometric and metabolic abnormalities with clinical symptom severity and recognition deficit in obsessive-compulsive disorder. *J Affect Disord*. 2018;227:603–12.
19. Zuo C, Ma Y, Sun B, Peng S, Zhang H, Eidelberg D, et al. Metabolic imaging of bilateral anterior capsulotomy in refractory obsessive compulsive disorder: an FDG PET study. *J Cereb Blood Flow Metab Off J Int Soc Cereb Blood Flow Metab*. 2013 Jun;33(6):880–7.
20. Sanematsu H, Nakao T, Yoshiura T, Nabeyama M, Togao O, Tomita M, et al. Predictors of treatment response to fluvoxamine in obsessive-compulsive disorder: an fMRI study. *J Psychiatr Res*. 2010 Mar;44(4):193–200.
21. Nakao T, Nakagawa A, Yoshiura T, Nakatani E, Nabeyama M, Yoshizato C, et al. Brain activation of patients with obsessive-compulsive disorder during neuropsychological and symptom provocation tasks before and after symptom improvement: a functional magnetic resonance imaging study. *Biol Psychiatry*. 2005 Apr 15;57(8):901–10.
22. Lefaucheur J-P, Antal A, Ayache SS, Benninger DH, Brunelin J, Cogiamanian F, et al. Evidence-based guidelines on the therapeutic use of transcranial direct current stimulation (tDCS). *Clin Neurophysiol Off J Int Fed Clin Neurophysiol*. 2017 Jan;128(1):56–92.
23. Lefaucheur J-P, André-Obadia N, Antal A, Ayache SS, Baeken C, Benninger DH, et al. Evidence-based guidelines on the therapeutic use of repetitive transcranial magnetic stimulation (rTMS). *Clin Neurophysiol Off J Int Fed Clin Neurophysiol*. 2014 Nov;125(11):2150–206.
24. Lusicic A, Schruers KR, Pallanti S, Castle DJ. Transcranial magnetic stimulation in the treatment of obsessive-compulsive disorder: current perspectives. *Neuropsychiatr Dis Treat*. 2018;14:1721–36.
25. Trevizol AP, Shiozawa P, Cook IA, Sato IA, Kaku CB, Guimarães FB, et al. Transcranial Magnetic Stimulation for Obsessive-Compulsive Disorder: An Updated Systematic Review and Meta-analysis. *J ECT*. 2016 Dec;32(4):262–6.
26. Stagg CJ, Antal A, Nitsche MA. Physiology of Transcranial Direct Current Stimulation. *J ECT*. 2018;34(3):144–52.
27. Fonteneau C, Redoute J, Haesebaert F, Le Bars D, Costes N, Suaud-Chagny M-F, et al. Frontal Transcranial Direct Current Stimulation Induces Dopamine Release in the Ventral Striatum in Human. *Cereb Cortex N Y N 1991*. 2018 Jul 1;28(7):2636–46.
28. Brunelin J, Mondino M, Bation R, Palm U, Saoud M, Poulet E. Transcranial Direct Current Stimulation for Obsessive-Compulsive Disorder: A Systematic Review. *Brain Sci*. 2018 Feb 24;8(2).
29. D’Urso G, Mantovani A, Patti S, Toscano E, de Bartolomeis A. Transcranial Direct Current Stimulation in Obsessive-Compulsive Disorder, Posttraumatic Stress Disorder, and Anxiety Disorders. *J ECT*. 2018;34(3):172–81.
30. Bation R, Poulet E, Haesebaert F, Saoud M, Brunelin J. Transcranial direct current stimulation in treatment-resistant obsessive-compulsive disorder: An open-label pilot study. *Prog Neuropsychopharmacol Biol Psychiatry*. 2016 Feb 4;65:153–7.
31. Goodman WK, Price LH, Rasmussen SA, Mazure C, Delgado P, Heninger GR, et al. The Yale-Brown Obsessive Compulsive Scale. II. Validity. *Arch Gen Psychiatry*. 1989 Nov;46(11):1012–6.
32. Montgomery SA, Asberg M. A new depression scale designed to be sensitive to change. *Br J Psychiatry J Ment Sci*. 1979 Apr;134:382–9.
33. Brunoni AR, Amadera J, Berbel B, Volz MS, Rizzerio BG, Fregni F. A systematic

review on reporting and assessment of adverse effects associated with transcranial direct current stimulation. *Int J Neuropsychopharmacol Off Sci J Coll Int Neuropsychopharmacol CINP*. 2011 Sep;14(8):1133–45.

34. Guy William. *Clinical Global Impressions*. In: *ECDEU Assessment Manual for Psychopharmacology*. Rockville, MD: US Department of Health, Education, and Welfare Public Health Service Alcohol, Drug Abuse, and Mental Health Administration; 1976. p. 218–22.

35. Spielberger CD. *Manual for the State-trait anxiety inventory*. Consulting Psychologists Press; 1983.

36. Pedersen G, Urnes Ø, Hummelen B, Wilberg T, Kvarstein EH. Revised manual for the Global Assessment of Functioning scale. *Eur Psychiatry J Assoc Eur Psychiatr*. 2018;51:16–9.

37. European Medicines Agency. *Clinical investigation of medicinal products for the treatment of obsessive compulsive disorder*. 2005.

38. Senço NM, Huang Y, D’Urso G, Parra LC, Bikson M, Mantovani A, et al. Transcranial direct current stimulation in obsessive-compulsive disorder: emerging clinical evidence and considerations for optimal montage of electrodes. *Expert Rev Med Devices*. 2015 Jul;12(4):381–91.

39. Brunelin J, Mondino M, Gassab L, Haesebaert F, Gaha L, Suaud-Chagny M-F, et al. Examining transcranial direct-current stimulation (tDCS) as a treatment for hallucinations in schizophrenia. *Am J Psychiatry*. 2012 Jul 1;169(7):719–24.

40. Truong DQ, Bikson M. Physics of Transcranial Direct Current Stimulation Devices and Their History. *J ECT*. 2018;34(3):137–43.

41. Thielscher A, Antunes A, Saturnino GB. Field modeling for transcranial magnetic stimulation: A useful tool to understand the physiological effects of TMS? In: *2015 37th Annual International Conference of the IEEE Engineering in Medicine and Biology Society (EMBC)*. 2015. p. 222–5.

42. Lázaro L, Calvo A, Ortiz AG, Ortiz AE, Morer A, Moreno E, et al. Microstructural brain abnormalities and symptom dimensions in child and adolescent patients with obsessive-compulsive disorder: a diffusion tensor imaging study. *Depress Anxiety*. 2014 Dec;31(12):1007–17.

43. Hartmann T, Vandborg S, Rosenberg R, Sørensen L, Videbech P. Increased fractional anisotropy in cerebellum in obsessive-compulsive disorder. *Acta Neuropsychiatr*. 2016 Jun;28(3):141–8.

44. Guell X, Gabrieli JDE, Schmahmann JD. Embodied cognition and the cerebellum: Perspectives from the Dysmetria of Thought and the Universal Cerebellar Transform theories. *Cortex J Devoted Study Nerv Syst Behav*. 2018 Mar;100:140–8.

45. Watson P, van Wingen G, de Wit S. Conflicted between Goal-Directed and Habitual Control, an fMRI Investigation. *eNeuro*. 2018 Aug;5(4).

46. Gillan CM. Habits and goals in OCD. In: *Obsessive-compulsive disorder: Phenomenology, pathophysiology, and treatment*. New York, NY, US: Oxford University Press; 2017. p. 161–70.

47. Huang Y-Z, Lu M-K, Antal A, Classen J, Nitsche M, Ziemann U, et al. Plasticity induced by non-invasive transcranial brain stimulation: A position paper. *Clin Neurophysiol Off J Int Fed Clin Neurophysiol*. 2017;128(11):2318–29.

48. Simonsmeier BA, Grabner RH, Hein J, Krenz U, Schneider M. Electrical brain stimulation (tES) improves learning more than performance: A meta-analysis. *Neurosci Biobehav Rev*. 2018 Jan;84:171–81.

49. Carmi L, Alyagon U, Barnea-Ygaël N, Zohar J, Dar R, Zangen A. Clinical and electrophysiological outcomes of deep TMS over the medial prefrontal and anterior cingulate

cortices in OCD patients. *Brain Stimulat.* 2018 Feb;11(1):158–65.

50. FDA. Press Announcements - FDA permits marketing of transcranial magnetic stimulation for treatment of obsessive compulsive disorder [Internet]. 2018 [cited 2018 Oct 18]. Available from:

<https://www.fda.gov/newsevents/newsroom/pressannouncements/ucm617244.htm>

51. Sathappan AV, Luber BM, Lisanby SH. The dynamic Duo: Combining noninvasive brain stimulation with cognitive interventions. *Prog Neuropsychopharmacol Biol Psychiatry.* 2018 Oct 9;

52. Edwards D, Cortes M, Datta A, Minhas P, Wassermann EM, Bikson M. Physiological and modeling evidence for focal transcranial electrical brain stimulation in humans: a basis for high-definition tDCS. *NeuroImage.* 2013 Jul 1;74:266–75.

53. Turski CA, Kessler-Jones A, Chow C, Hermann B, Hsu D, Jones J, et al. Extended Multiple-Field High-Definition transcranial direct current stimulation (HD-tDCS) is well tolerated and safe in healthy adults. *Restor Neurol Neurosci.* 2017;35(6):631–42.

54. Felipe da Silva R de M, Batistuzzo MC, Shavitt RG, Miguel EC, Stern E, Mezger E, et al. Transcranial direct current stimulation in obsessive-compulsive disorder: an update in electric field modeling and investigations for optimal electrode montage. *Expert Rev Neurother.* 2019 Jun 27;

55. van den Heuvel OA, Remijnse PL, Mataix-Cols D, Vrenken H, Groenewegen HJ, Uylings HBM, et al. The major symptom dimensions of obsessive-compulsive disorder are mediated by partially distinct neural systems. *Brain J Neurol.* 2009 Apr;132(Pt 4):853–68.

Figure captions

Figure 1. CONSORT flow chart diagram of the study.

Figure. 2. Evolution of the Y-BOCS scores in patients with OCD after receiving either active (in black) or sham (in gray) tDCS. The results are given as the mean +/- SEM.

Figure 3. Estimation results of the electric field distribution of the tDCS montage with two 7 x 5 cm electrodes. The anode was placed over the right cerebellum (1 cm to the right and 3 cm below the inion), and the cathode was placed over the left supraorbital region (Fp1). The electric field strength was scaled from 0 (minimum: blue) to 1 mV/mm (maximum: red). Electric field simulation was performed with SimNIBS 2.0.1 using the standard head model provided by the software and a current intensity of 2 mA.

Table 1: Demographic and clinical baseline characteristics of the patients with OCD included in the study. No differences were observed between patients in the active and sham groups. The results are given as the mean (SD: standard deviation)

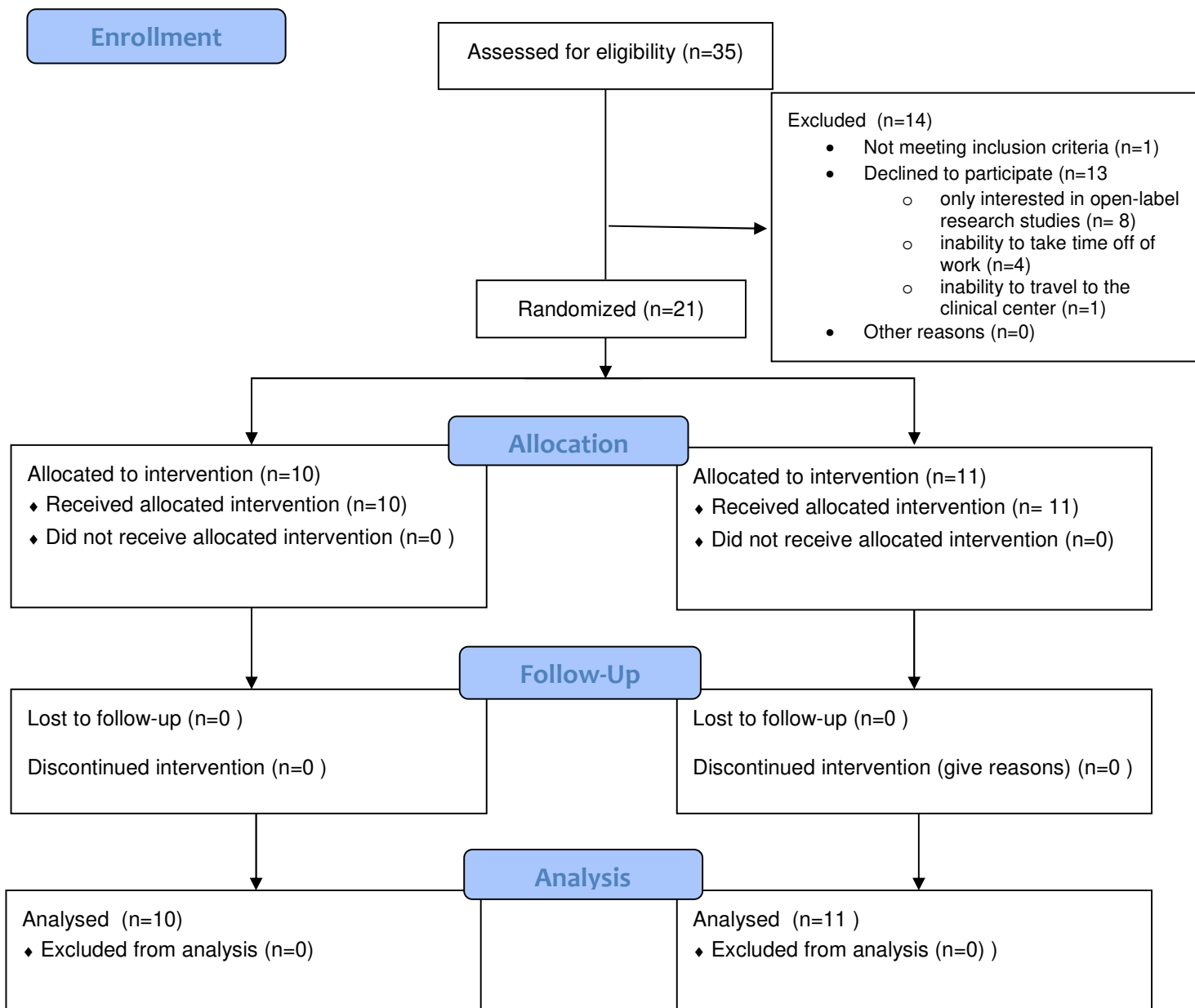
	Active tDCS		Sham tDCS		p
	Mean	SD	Mean	SD	
N	10		11		
Right-handed (n)	10		11		1
Female (n)	8		4		0.08
Age (years)	44.8	19.9	41.2	11.9	0.75
Educational level (years)	12.4	3.5	12.1	2.5	0.97
Age of onset (years)	23.0	14.5	22.7	13.7	0.86
Duration of illness (years)	22.9	16.9	19.4	10.4	0.75
Resistance level	6.2	2.5	5.2	2.1	0.31
Severity (Y-BOCS)	29.0	9.7	29.5	6.6	0.80
Severity (VAS)	6.9	1.5	6.5	2.1	0.94
Insight (BABS)	6.1	3.5	5.5	3.2	0.65
Depressive symptoms (MADRS)	13.3	7.7	18.4	5.3	0.10
Anxiety (STAI-YA)	47.6	23.2	52.3	8.5	0.59
Patients on potentiation (%)	30		36.4		1
Main symptom dimension: contamination (%)	70		54.5		0.39
Main symptom dimension: checking (%)	20		45.5		0.66

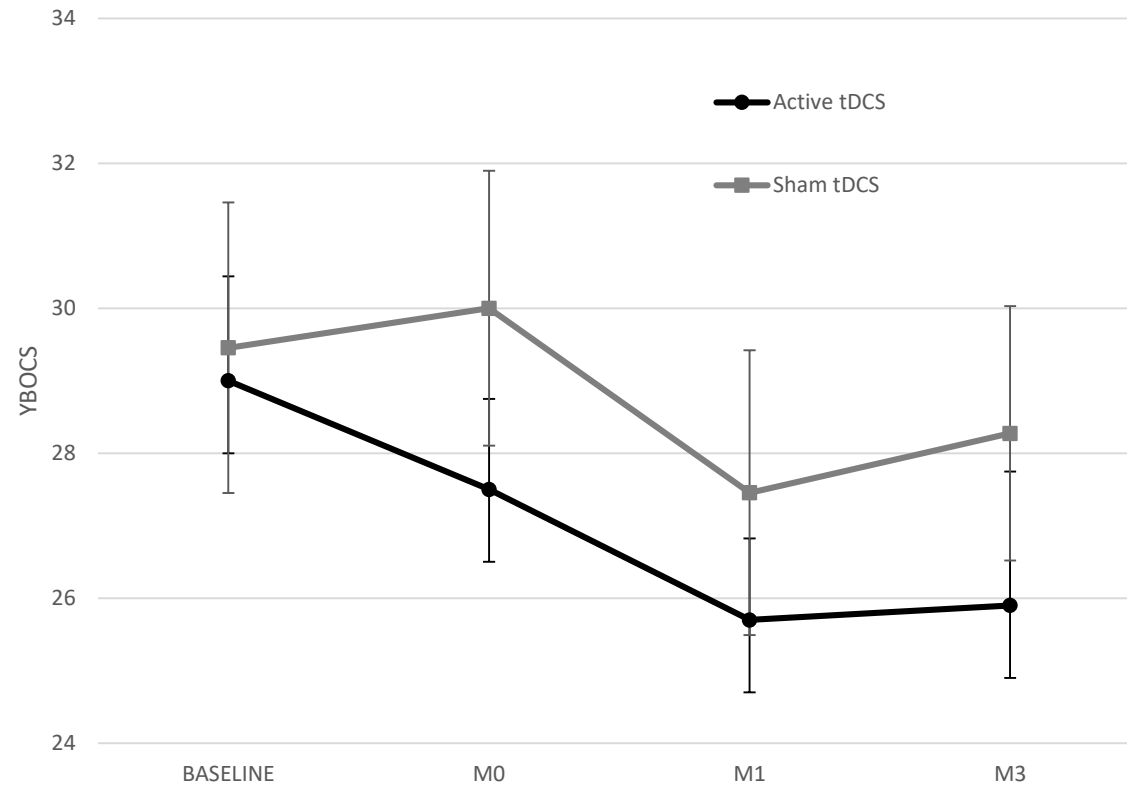
## tDCS in OCD

Table. 2: Changes in clinical outcomes after patients received 10 sessions of tDCS (ANOVA with repeated measures) \*:  $p \leq 0.05$

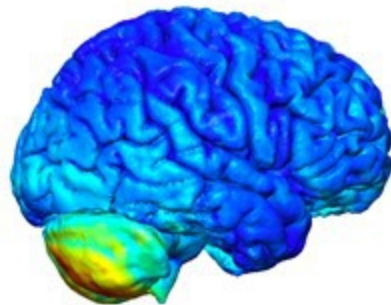
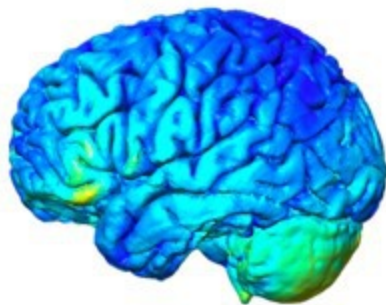
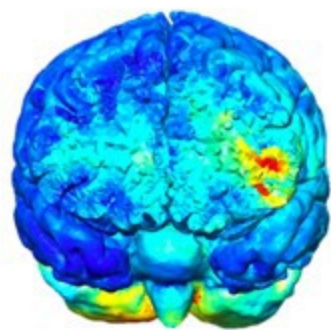
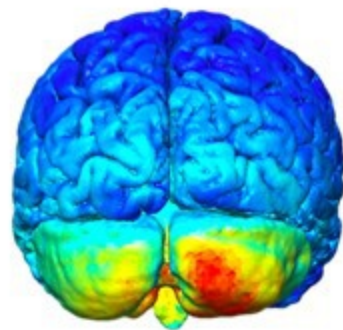
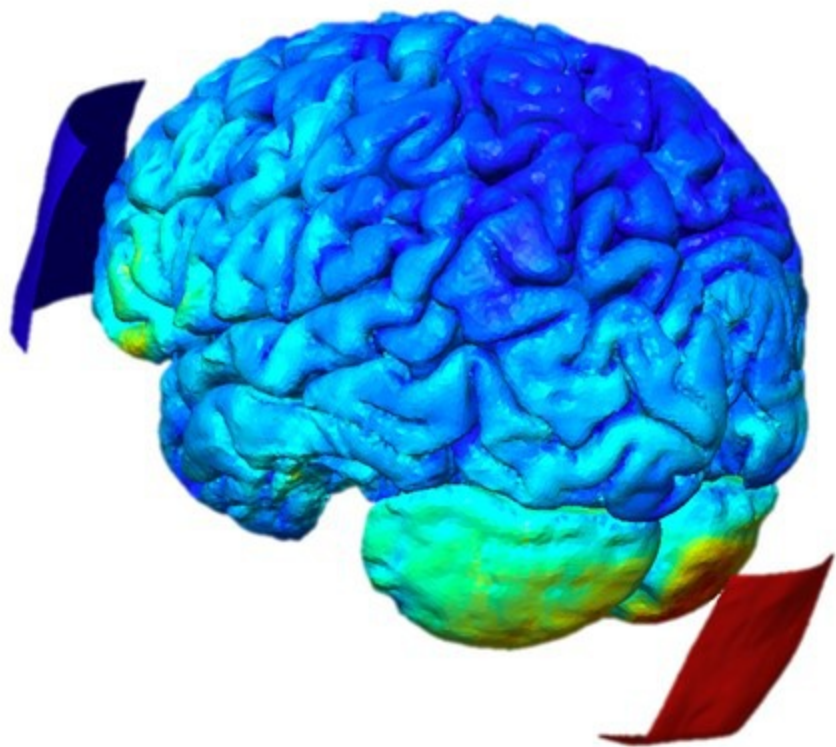
	Active tDCS (N=10)									Sham tDCS (N=11)									ANOVA (time*group)	ANOVA (time)
	BASELINE	M0			M1			M3			Baseline	M0			M1			M3		
YBOCS total	29.00 ± 4.55	27.50 ± 3.95	25.70 ± 3.56	25.90 ± 5.84	29.45 ± 6.65	30.00 ± 6.29	27.45 ± 6.52	28.27 ± 5.82										$F_{(3,57)}=0.663$ ; $p=0.53$	$F_{(3,57)}=4.927$ ; $p=0.01^*$	
responders (%)		0.00	10.00	20.00		0.00	0.00	9.09												
YBOCS obsession	15.00 ± 2.75	14.00 ± 2.98	13.60 ± 2.32	13.30 ± 3.23	15.36 ± 3.59	15.45 ± 3.27	14.55 ± 3.67	14.64 ± 2.46										$F_{(3,57)}=0.697$ ; $p=0.59$	$F_{(3,57)}=3.288$ ; $p=0.03^*$	
YBOCS compulsion	14.10 ± 2.08	13.30 ± 1.42	12.10 ± 1.85	12.50 ± 2.84	14.09 ± 3.94	14.55 ± 3.67	13.09 ± 3.67	13.64 ± 3.75										$F_{(3,57)}=0.64$ ; $p=0.53$	$F_{(3,57)}=3.889$ ; $p=0.03^*$	
VAS	6.92 ± 1.50	6.29 ± 1.38	6.68 ± 2.04	6.40 ± 2.27	6.56 ± 2.03	6.59 ± 1.17	5.98 ± 1.76	6.29 ± 2.00										$F_{(3,54)}=0.779$ ; $p=0.51$	$F_{(3,54)}=0.486$ ; $p=0.69$	
CGI-S	6.10 ± 0.99	6.00 ± 1.05	6.00 ± 1.05	5.20 ± 1.40	6.00 ± 0.89	5.45 ± 1.44	5.91 ± 0.83	5.82 ± 0.87										$F_{(3,57)}=0.112$ ; $p=0.71$	$F_{(3,57)}=2.308$ ; $p=0.11$	
MADRS	13.30 ± 6.95	11.00 ± 7.53	11.30 ± 6.72	13.50 ± 7.28	18.36 ± 5.30	19.00 ± 6.62	15.73 ± 6.92	15.73 ± 6.81										$F_{(3,57)}=1.059$ ; $p=0.37$	$F_{(3,57)}=0.693$ ; $p=0.56$	
STAI-YA	47.63 ± 18.07	45.90 ± 9.96	51.22 ± 14.29	49.30 ± 14.67	52.27 ± 8.47	46.00 ± 13.74	53.18 ± 11.32	53.45 ± 9.49										$F_{(3,45)}=0.127$ ; $p=0.94$	$F_{(3,45)}=1.459$ ; $p=0.24$	
GAF	42.30 ± 13.33	43.20 ± 13.70	44.40 ± 13.53	47.20 ± 14.61	41.71 ± 14.10	40.27 ± 12.05	46.00 ± 12.32	40.64 ± 12.26										$F_{(3,57)}=3.248$ ; $p=0.028^*$	$F_{(3,57)}=2.862$ ; $p=0.045^*$	

M0: after 10 sessions of tDCS; M1: one month after tDCS, and M3: 3 months after tDCS









normE

0

0.5

1

