



HAL
open science

Brain abscess in immunocompetent adult patients

M. Cantiera, P. Tattevin, R. Sonnevile

► **To cite this version:**

M. Cantiera, P. Tattevin, R. Sonnevile. Brain abscess in immunocompetent adult patients. *Revue Neurologique*, 2019, 175, pp.469 - 474. 10.1016/j.neurol.2019.07.002 . hal-03487807

HAL Id: hal-03487807

<https://hal.science/hal-03487807v1>

Submitted on 20 Dec 2021

HAL is a multi-disciplinary open access archive for the deposit and dissemination of scientific research documents, whether they are published or not. The documents may come from teaching and research institutions in France or abroad, or from public or private research centers.

L'archive ouverte pluridisciplinaire **HAL**, est destinée au dépôt et à la diffusion de documents scientifiques de niveau recherche, publiés ou non, émanant des établissements d'enseignement et de recherche français ou étrangers, des laboratoires publics ou privés.



Distributed under a Creative Commons Attribution - NonCommercial 4.0 International License

Brain abscess in immunocompetent adult patients

M. Cantier¹, P. Tattevin², R. Sonneville¹

¹Department of intensive care medicine and infectious diseases, AP-HP, Bichat Hospital, and UMR1148, LVTS, Sorbonne Paris Cité, INSERM/Paris Diderot University, Paris, France

²Infectious diseases and intensive care unit, Pontchaillou University Hospital, Rennes, France

* *Corresponding Author*: R. Sonneville, romain.sonneville@aphp.fr; Department of intensive care medicine and infectious diseases, AP-HP, Bichat Hospital, and UMR1148, LVTS, Sorbonne Paris Cité, INSERM/Paris Diderot University, Paris, France

ABSTRACT

Brain abscess is a focal infection of the brain due to contiguous spread of pathogens following otitis, sinusitis, neurosurgery or traumatic brain injury or through hematogenous dissemination. Classical symptoms consisting of headache, fever, and focal signs may be absent on admission and brain MRI with contrast plays a major role in diagnosis. Initial management consists of stereotactic aspiration for microbiological documentation empirical treatment covering common pathogens, including oral streptococci, staphylococci, anaerobes, and *Enterobacteriaceae*. Deescalation of antimicrobials based on microbiology is safe only when samples have been processed optimally, or when primary diagnosis is endocarditis. A 6-week combination of third-generation cephalosporin and metronidazole will cure most cases of community-acquired brain abscess in immunocompetent adults. Significant advent in brain imaging, minimally invasive surgery, molecular biology, and antibacterial agents, has dramatically improved the prognosis. Main indicators of outcome include altered mental status at presentation and intraventricular rupture.

Keywords: brain abscess, bacterial, immunocompetent, stereotactic surgery, brain magnetic resonance imaging.

Introduction

Brain abscess is a focal infection of the brain due to contiguous spread of pathogens following otitis, sinusitis, neurosurgery or traumatic brain injury, or through hematogenous dissemination. Classical symptoms may be absent and diagnostic and therapeutic management is challenging [1-3]. Significant progress in imaging, neurosurgery, microbiology, and use of antimicrobial agents led to an improved prognosis over the last decades [4]. In the present paper, we provide an overview of the key points for management of brain abscess in immunocompetent patients.

Pathogenesis

Brain abscess begins as a localized area of infectious cerebritis, and develops into a collection of pus surrounded by a well-vascularized capsule [5]. A landmark experimental model of streptococcal brain abscesses estimated that well encapsulated lesions were formed after 14 days [6], with five concentric histological zones : a necrotic center; surrounded by peripheral inflammatory cells, macrophages, and fibroblasts; the dense collagenous capsule; a layer of neovascularization with cerebritis; and external astrogliosis and cerebral edema.

In immunocompetent patients, bacteria are responsible for >95% of brain abscess. The brain is particularly susceptible to bacterial infections once the blood-brain barrier has been crossed [7] and polymicrobial infections by anaerobes and other bacteria may be involved in the pathogenesis [8]. Bacteria enter the brain either through contiguous spread in 40-50% of cases, or through hematogenous dissemination in 30-40% of cases (e.g. in case of infective endocarditis). The clinician has to identify the pathogenesis, as this has consequences regarding the main bacteria to be suspected, the investigations to be performed, the therapeutic strategy, and secondary prevention (Table 1).

Epidemiology

There is limited data available on the epidemiology of brain abscess. The incidence in the general population has been estimated at 0.3 to 0.9 per 100,000 inhabitants per year in developed countries such as the USA, Finland and Denmark [10-12], with a male-to-female sex ratio of 2:1 to 3:1, and a median age of 30 to 40 years. The incidence may decrease when the general health of the population improves, according to studies performed in the USA during years 1935-1981 [12], and in South Africa during years 1983-2002 [13].

A meta-analysis of 9,699 cases of brain abscess reported between 1935 and 2012, found no significant differences in the distribution of bacterial pathogens over the last 60 years [2]. Main predisposing conditions were contiguous infections, including otitis or mastoiditis (33%), sinusitis (10%), and meningitis (6%). Hematogenous spread was considered to be involved in one-third of cases, mostly with endocarditis (13%), pulmonary infection (8%) or dental infection (5%). Others were attributed to recent neurosurgery (9%), or cranial trauma (14%), while the source could not be identified in 19% of cases.

The risk of brain abscess is estimated at 5-9% in patients with hereditary hemorrhagic telangiectasia (1000 times higher than in the general population) [14], <5% in patients with infective endocarditis [15], and 0.2% after cranial surgery [16]. Brain abscess was encountered in only 0.5% (14/950) of patients with bacterial meningitis in the 2006-2011 nationwide prospective cohort from the Netherlands [17].

Diagnosis

The mean duration of symptoms reported before diagnosis of brain abscess is 8.3 days [2]. Headache is observed in 49-97% of patients, fever in 32-79%, focal neurologic deficit in 20-66%, seizures in 13-35%, and mental status changes in 28-91% [1, 2, 4, 5, 13, 18-21]. In a patient with brain abscess, the abrupt onset of meningeal signs, associated with worsening of headache and neurological status, should lead to urgent brain imaging, to rule out rupture into the ventricular space with ventriculitis, associated with high risk of obstructive hydrocephalus, and lethality of 50-85% [11, 22].

Brain imaging is the cornerstone for the diagnosis of brain abscess (Figures 1 and 2). CT with contrast-enhancement typically shows a peripheral ring-enhanced lesion including a hypodense center, surrounded by a variable hypodense area (edema). Lesions detected with CT are mostly single lesions located in frontal (31%) or temporal (28%) lobes [2]. Magnetic resonance imaging (MRI) should be preferred, as it allows identification of additional lesions, earlier detection of lesions at risk of complications, and lower toxicity of gadolinium. Multimodal MRI improved the differential diagnosis between brain abscesses and tumors [23, 24]: the capsule of pyogenic abscess appears hyperintense in T1-weighted sequence and hypointense in T2-weighted sequence, with regular enhancement after gadolinium injection. The necrotic center of pyogenic abscess is hypointense in T1-weighted sequence, hyperintense in T2-weighted sequence, typically hyperintense in diffusion weighted imaging

(DWI) with restricted apparent diffusion coefficient (ADC). MR spectroscopy reveals peaks corresponding to lipids, lactate and amino-acids [23].

Blood cultures should be collected before initiation of antimicrobials, as it was found to be positive in 28% of patients [2]. HIV testing should be proposed to all patients with brain abscess, as cerebral toxoplasmosis represents the first opportunistic brain infection in patients with HIV infection.

Neurosurgery

Mini-invasive stereotactic aspiration has transformed neurosurgical approach and improved prognosis over last decades. Neuronavigation assistance with CT or MRI allows targeting any brain abscess ≥ 1 cm [25]. Stereotactic aspiration is indicated for all patients with undocumented brain abscess ≥ 1 cm, while total resection through craniotomy is rarely considered first (e.g. in case of large multi-lobulated abscess and severe cranial hypertension). Drainage is also proposed irrespective of previous microbiological documentation for large abscess ≥ 2.5 cm [26], and should be discussed in lesions at high risk of intraventricular rupture, or in case of difficult-to-treat bacteria or fungal infections. External ventricular drainage and monitoring of intracranial pressure is indicated in all cases of rupture into the ventricular system, and in selected cases of large brain or cerebellar abscess with hydrocephalus.

Optimal sampling of abscess tissues and fluids are of critical importance to accurate bacterial identification. The risk of sub-optimal sampling is related to the fragility of some pathogens and the polymicrobial context. In our institution, we build a surgical protocol to limit the risk of pre-analytical adverse events and non-contributive sampling (Table 2).

Microbiology

In the previously mentioned meta-analysis, at least one pathogen was documented in 4,543 (68%) patients with bacterial tissue analyses, of whom 23% were polymicrobial [2]. Main pathogens identified were: Streptococci (34%, mostly oral streptococci including the *milleri* group), Staphylococci (18%, of whom 84% were *S. aureus*), gram-negative bacilli (15%, mostly *Enterobacteriaceae*). However, these data are probably not representative of the distribution of pathogens involved in brain abscess, because many samples may have been obtained after the start of antimicrobials, and issues in sample processing and culture

techniques could impact detection of strict anaerobes such as *Prevotella* sp., *Bacteroides* sp., and *Fusobacterium* sp. [27-29].

The advent of molecular biology permits to detect and amplify bacterial genetic material from abscess samples. The systematic use of multiple 16S ribosomal DNA sequencing increased the proportion of documentation from 66% to 83%, as compared to conventional cultures [30, 31]. However, the clinical significance of numerous bacteria present within a single sample, not found by conventional cultures, remains to be proven.

Antibacterial treatment

In the absence of any randomized trial, there is a global consensus for antimicrobials management. First, treatment should be initiated as soon as possible, immediately after stereotactic aspiration and blood cultures sampling. Second, empirical treatment should cover oral streptococci, methicillin-susceptible staphylococci, strict anaerobes, and *Enterobacteriaceae*. Third, for community-acquired abscess in adults, a combination of i.v. cefotaxime 8-12 g/day or ceftriaxone, 4g/day, and i.v. metronidazole (1.5 g/day), is recommended in most settings. One of the major controversies concerns de-escalation once microbiological results are available. Given the large proportion of polymicrobial brain abscess (at least >30%), and the relatively high risk of missing a co-pathogen, many experts would advocate, except in case of endocarditis, to keep an adequate coverage for anaerobes throughout 6 weeks, even when stereotactic aspiration found no anaerobes. Any additional suspicion that samples were sub-optimal (e.g. limited volume, samples obtained while antibacterial treatment was already initiated, long delay between sampling and analysis), should prompt clinician to continue empirical treatment for the whole six-week duration.

Basic principles of antimicrobial drug administration include the use of drugs with significant diffusion through the blood-brain barrier [32], the use of agents that remain active in an acid environment (e.g. metronidazole, not affected by low pH, will be the preferential drug for anaerobes). Another controversy relies in the preferential use of parenteral drugs. We routinely switch to oral drugs early, provided that the bacteria targeted are susceptible to an effective oral drug, well absorbed, and that adherence is not an issue.

Symptomatic measures

Simple measures may be of importance in patients with intracranial hypertension and/or altered mental status. Early ICU admission should be considered in patients with

comorbidities, severe neurological presentation (i.e., GCS \leq 13 and/or seizures), and/or cerebral edema with significant mass effect. A short course of adjunctive steroids may be proposed in case of warning signs of brain herniation. Primary seizure prophylaxis is not recommended.

Conclusion

In conclusion, the prognosis of brain abscess has dramatically improved due to advent in brain imaging, mini-invasive neurosurgery, and better use of antimicrobials. When diagnosis is made ‘in time’, and basic rules of management are applied, the rate of cure will be >90%. However, the emergence of antibacterial resistance may reverse these trends in some settings.

Contribution

All authors have contributed in the article preparation (drafting and revising) and have approved the final article.

Declarations of interest

The authors declare no conflict of interest

REFERENCES

- [1] Brouwer MC, Tunkel AR, McKhann GM, 2nd, van de Beek D. Brain abscess. *N Engl J Med* 2014;371(5):447-56.
- [2] Brouwer MC, Coutinho JM, van de Beek D. Clinical characteristics and outcome of brain abscess: systematic review and meta-analysis. *Neurology* 2014;82(9):806-13.
- [3] Saez-Llorens X, Nieto-Guevara J. Brain abscess. *Handb Clin Neurol* 2013;112:1127-34.
- [4] Tattevin P, Bruneel F, Clair B, Lellouche F, de Broucker T, Chevret S, et al. Bacterial brain abscesses: a retrospective study of 94 patients admitted to an intensive care unit (1980 to 1999). *Am J Med* 2003;115(2):143-6.
- [5] Mathisen GE, Johnson JP. Brain abscess. *Clin Infect Dis* 1997;25(4):763-79; quiz 80-1.
- [6] Britt RH, Enzmann DR, Yeager AS. Neuropathological and computerized tomographic findings in experimental brain abscess. *J Neurosurg* 1981;55(4):590-603.
- [7] Mendes M, Moore P, Wheeler CB, Winn HR, Rodeheaver G. Susceptibility of brain and skin to bacterial challenge. *J Neurosurg* 1980;52(6):772-5.
- [8] Onderdonk AB, Kasper DL, Mansheim BJ, Louie TJ, Gorbach SL, Bartlett JG. Experimental animal models for anaerobic infections. *Rev Infect Dis* 1979;1(2):291-301.
- [9] Brouwer MC, van de Beek D. Epidemiology, diagnosis, and treatment of brain abscesses. *Curr Opin Infect Dis* 2017;30(1):129-34.
- [10] Laulajainen-Hongisto A, Lempinen L, Farkkila E, Saat R, Markkola A, Leskinen K, et al. Intracranial abscesses over the last four decades; changes in aetiology, diagnostics, treatment and outcome. *Infect Dis (Lond)* 2016;48(4):310-6.
- [11] Helweg-Larsen J, Astradsson A, Richhall H, Erdal J, Laursen A, Brennum J. Pyogenic brain abscess, a 15 year survey. *BMC Infect Dis* 2012;12:332.
- [12] Nicolosi A, Hauser WA, Musicco M, Kurland LT. Incidence and prognosis of brain abscess in a defined population: Olmsted County, Minnesota, 1935-1981. *Neuroepidemiology* 1991;10(3):122-31.
- [13] Nathoo N, Nadvi SS, Narotam PK, van Dellen JR. Brain abscess: management and outcome analysis of a computed tomography era experience with 973 patients. *World Neurosurg* 2011;75(5-6):716-26; discussion 612-7.
- [14] Dupuis-Girod S, Giraud S, Decullier E, Lesca G, Cottin V, Faure F, et al. Hemorrhagic hereditary telangiectasia (Rendu-Osler disease) and infectious diseases: an underestimated association. *Clin Infect Dis* 2007;44(6):841-5.
- [15] Sonnevile R, Mirabel M, Hajage D, Tubach F, Vignon P, Perez P, et al. Neurologic complications and outcomes of infective endocarditis in critically ill patients: the ENDOcardite en REAnimation prospective multicenter study. *Crit Care Med* 2011;39(6):1474-81.
- [16] McClelland S, 3rd, Hall WA. Postoperative central nervous system infection: incidence and associated factors in 2111 neurosurgical procedures. *Clin Infect Dis* 2007;45(1):55-9.
- [17] Jim KK, Brouwer MC, van der Ende A, van de Beek D. Cerebral abscesses in patients with bacterial meningitis. *J Infect* 2012;64(2):236-8.
- [18] Lu CH, Chang WN, Lui CC. Strategies for the management of bacterial brain abscess. *J Clin Neurosci* 2006;13(10):979-85.
- [19] Seydoux C, Francioli P. Bacterial brain abscesses: factors influencing mortality and sequelae. *Clin Infect Dis* 1992;15(3):394-401.
- [20] Yang SY. Brain abscess: a review of 400 cases. *J Neurosurg* 1981;55(5):794-9.
- [21] Chun CH, Johnson JD, Hofstetter M, Raff MJ. Brain abscess. A study of 45 consecutive cases. *Medicine (Baltimore)* 1986;65(6):415-31.
- [22] Takeshita M, Kawamata T, Izawa M, Hori T. Prodromal signs and clinical factors influencing outcome in patients with intraventricular rupture of purulent brain abscess. *Neurosurgery* 2001;48(2):310-6; discussion 6-7.
- [23] Muccio CF, Caranci F, D'Arco F, Cerase A, De Lipsis L, Esposito G, et al. Magnetic resonance features of pyogenic brain abscesses and differential diagnosis using morphological and functional imaging studies: a pictorial essay. *J Neuroradiol* 2014;41(3):153-67.

- [24] Reddy JS, Mishra AM, Behari S, Husain M, Gupta V, Rastogi M, et al. The role of diffusion-weighted imaging in the differential diagnosis of intracranial cystic mass lesions: a report of 147 lesions. *Surg Neurol* 2006;66(3):246-50; discussion 50-1.
- [25] Barlas O, Sencer A, Erkan K, Eraksoy H, Sencer S, Bayindir C. Stereotactic surgery in the management of brain abscess. *Surg Neurol* 1999;52(4):404-10; discussion 11.
- [26] Mamelak AN, Mampalam TJ, Obana WG, Rosenblum ML. Improved management of multiple brain abscesses: a combined surgical and medical approach. *Neurosurgery* 1995;36(1):76-85; discussion -6.
- [27] de Louvois J. Bacteriological examination of pus from abscesses of the central nervous system. *J Clin Pathol* 1980;33(1):66-71.
- [28] de Louvois J, Gortavai P, Hurley R. Bacteriology of abscesses of the central nervous system: a multicentre prospective study. *Br Med J* 1977;2(6093):981-4.
- [29] Gortvai P, De Louvois J, Hurley R. The bacteriology and chemotherapy of acute pyogenic brain abscess. *Br J Neurosurg* 1987;1(2):189-203.
- [30] Al Masalma M, Armougom F, Scheld WM, Dufour H, Roche PH, Drancourt M, et al. The expansion of the microbiological spectrum of brain abscesses with use of multiple 16S ribosomal DNA sequencing. *Clin Infect Dis* 2009;48(9):1169-78.
- [31] Al Masalma M, Lonjon M, Richet H, Dufour H, Roche PH, Drancourt M, et al. Metagenomic analysis of brain abscesses identifies specific bacterial associations. *Clin Infect Dis* 2012;54(2):202-10.
- [32] Nau R, Sorgel F, Eiffert H. Penetration of drugs through the blood-cerebrospinal fluid/blood-brain barrier for treatment of central nervous system infections. *Clin Microbiol Rev* 2010;23(4):858-83.

Table 1. Pathogenesis of brain abscess and its consequences for patients management. HACEK, *Haemophilus* spp., *Aggregatibacter* spp., *Cardiobacterium* spp., *Eikenella corrodens*, and *Kingella* spp.; ENT, ear, nose and throat

Predisposing condition	Bacteria	Comments
Hematogenous (30-40% of brain abscess in immunocompetent patients)		
Infective endocarditis	<i>Staphylococcus aureus</i> , oral streptococci, HACEK bacteria	Even with no previously known underlying condition, echocardiography must be performed in all patients with bilateral or cryptogenic brain abscess
Pulmonary circulation shunts (congenital heart disease, arterio-venous fistulas)	Polymicrobial, including streptococci, anaerobes (<i>Actinomyces</i> sp., <i>Prevotella</i> sp., <i>Bacteroides</i> sp., <i>Fusobacterium</i> sp.)	Careful skin examination to detect skin lesions related to hereditary hemorrhagic telangiectasia (Rendu-Osler-Weber syndrome)
Dental infection	Polymicrobial, mainly <i>Streptococcus milleri</i> group (<i>S. anginosus</i> , <i>S. constellatus</i> , <i>S. intermedius</i>), anaerobes (<i>Actinomyces</i> sp., <i>Prevotella</i> sp., <i>Bacteroides</i> sp., <i>Fusobacterium</i> sp.)	Preferentially affect frontal lobes Orthopantomogram and dentist consultation to be performed May require dental extraction Secondary prevention is key (reinforced dental hygiene)
Contiguous spread from local infection (40-50% of brain abscess in immunocompetent)		
Otitis, mastoiditis, sinusitis	Polymicrobial, mainly streptococci, Enterobacteriaceae, <i>Streptococcus pneumoniae</i> , anaerobes (<i>Prevotella</i> sp., <i>Bacteroides</i> sp.), <i>S. aureus</i> (sinusitis)	Preferentially affect temporal lobes (otitis, mastoiditis, sphenoid sinusitis), or frontal lobes (other sinusitis) Systematic ENT examination for patients with unilateral brain abscess Selected cases may require surgery for source control
Cranial traumatism	Polymicrobial, mainly <i>S. aureus</i> , <i>Streptococcus pyogenes</i> , anaerobes (<i>Clostridium</i> sp., <i>Actinomyces</i> sp.)	Risk factors: open wound contaminated with environmental flora (telluric bacteria), sub-optimal or delayed wound care
Neurosurgery	Polymicrobial, mainly <i>S. aureus</i> , coagulase-negative staphylococci, Enterobacteriaceae	Risk factors: foreign devices, including ventricular derivation, bone graft, etc.
Cryptogenic brain abscess (10-20% of brain abscess in immunocompetent)		

Table 2. Guidelines for the processing of surgical samples (stereotactic aspiration or craniotomy)

Laboratory	Samples	Targets, comments
Bacteriology	10 mL to be directly inoculated on blood culture bottles (aerobic/anaerobic)	Streptococci, staphylococci, anaerobes (blood culture bottles increases the yield, especially if previous use of antibacterials)
	Two separate dry tubes At least 5 mL in each tube	<ul style="list-style-type: none"> - Gram staining - Cultures on routine media - Molecular biology to be performed if cultures sterile after 48 h - Tests for mycobacteria if risk factors for tuberculosis
Histology	One dry tube for fluid sample If tissue, to be sent in sterile water	Differential diagnosis (cancer)
Mycology, parasitology	Dry tube	<p>Only if immunocompromised (HIV, immunosuppressive agents, organ transplant, malignant hemopathy)</p> <p>Specific tests for <i>Toxoplasma</i>, invasive mycosis (<i>Aspergillus</i> spp.)</p>
<p>Basic rules</p> <p>To be sent within one hour to the microbiology laboratory, for immediate processing, 24/24</p> <p>Two sets of blood cultures should be obtained, before and just after surgery, optimally prior to antibiotic administration.</p> <p>Patients characteristics and clinical suspicion to be reported in the laboratory form</p>		

Figure 1. Brain abscess in a patient with pulmonary circulation shunts and dental infection. Multimodal imaging studies revealing brain abscess in a 66-years old women with Rendu-Osler disease and previous pulmonary arterio-venous fistulas, associated with a dental infection. **A:** CT showing a right thalamic brain abscess, with hypodense center, peripheral annular contrast-enhancement, perilesional edema and mass effect on the third ventricle; **B and C:** on T1-weighted MRI the necrotic center appears hypointense, the capsule appears hyperintense with regular enhancement after gadolinium injection; **D and E:** the necrotic center appears hyperintense in diffusion weighted imaging (DWI) with low values of apparent diffusion coefficient (ADC); **F:** the necrotic center and perilesional edema appear hyperintense on fluid attenuation inversion recovery (FLAIR)-T2 sequence; **G:** favourable evolution at 6 months on MRI showing no enhancement after gadolinium injection; **H:** periapical periodontitis due to a dental infection ; **I:** pulmonary arterio-venous fistulas embolized.

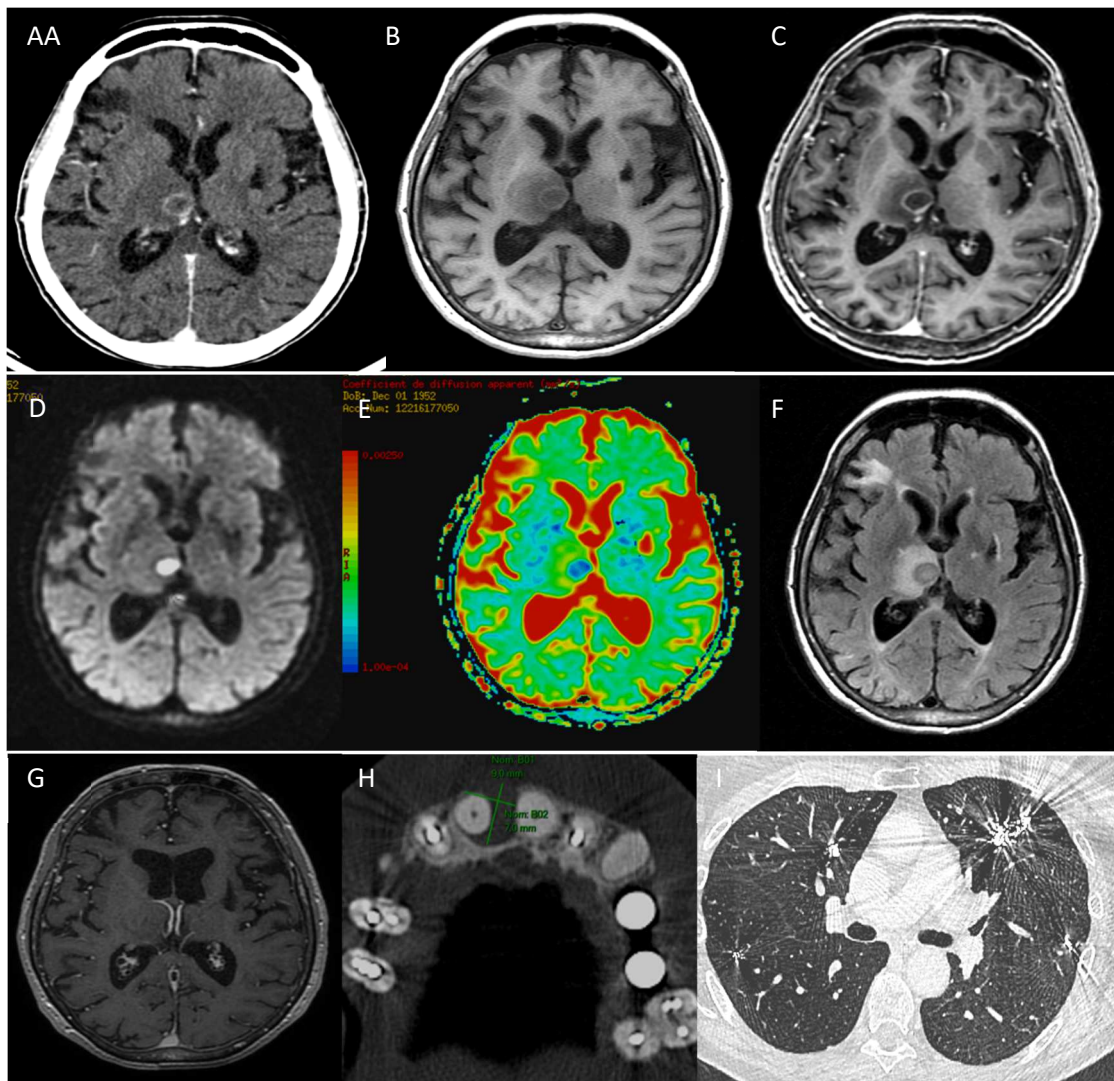


Figure 2. Follow-up MRI showing a new brain abscess in the same patient 6 years later. **A and B:** T1- and perfusion-weighted MRI showing two small agglutinated nodular lesions enhanced after gadolinium injection, with vasogenic perilesional edema; **C:** MR spectroscopy reveals peaks corresponding to lactate and amino-acids.

