



**HAL**  
open science

## **Reconstruction of exenteration socket with Integra® dermal substitute and skin graft**

F. Ameloot, H. Mezzine, G. Khairallah, G. Hayek, M. Zaidi, L. Lhuillier, M. Talbi,  
M. Sot, J.M. Perone

### ► **To cite this version:**

F. Ameloot, H. Mezzine, G. Khairallah, G. Hayek, M. Zaidi, et al.. Reconstruction of exenteration socket with Integra® dermal substitute and skin graft. *Journal Français d’Ophtalmologie*, 2019, 42, pp.746 - 752. <10.1016/j.jfo.2019.03.023>. <hal-03487715>

**HAL Id: hal-03487715**

**<https://hal.science/hal-03487715v1>**

Submitted on 20 Jul 2022

**HAL** is a multi-disciplinary open access archive for the deposit and dissemination of scientific research documents, whether they are published or not. The documents may come from teaching and research institutions in France or abroad, or from public or private research centers.

L’archive ouverte pluridisciplinaire **HAL**, est destinée au dépôt et à la diffusion de documents scientifiques de niveau recherche, publiés ou non, émanant des établissements d’enseignement et de recherche français ou étrangers, des laboratoires publics ou privés.



Distributed under a Creative Commons CC BY-NC 4.0 - Attribution - Non-commercial use - International License

## **Reconstruction of exenteration socket with Integra® dermal substitute and skin graft**

## **Reconstruction de cavité d'exentération avec substitut dermique Integra® et greffe de peau**

*Cet article est issu d'une communication orale présentée lors du 120e congrès de la Société Française d'Ophtalmologie en mai 2014*

### **Auteurs :**

*François Ameloot<sup>1</sup>, Hicham Mezzine<sup>2</sup>, Grégoire Khairallah<sup>2</sup>, George Hayek<sup>1</sup>, Mohamed Zaidi<sup>1</sup>, Louis Lhuillier<sup>1</sup>, Marouane Talbi<sup>2</sup>, Maxime Sot<sup>1</sup>, Jean Marc Perone<sup>1, \*</sup>*

- 1- Département d'ophtalmologie, Mercy Hospital, Regional Hospital Center of Metz-Thionville, 57085 Metz CEDEX 3, France
- 2- Service de chirurgie maxillo-faciale, Mercy Hospital, Regional Hospital Center of Metz-Thionville, 57085 Metz CEDEX 3, France

### **Auteur correspondant\* :**

*Jean Marc Perone, [Jm.perone@chr-metz-thionville.fr](mailto:Jm.perone@chr-metz-thionville.fr), Tél. : +33 387553428*  
Département d'ophtalmologie, Mercy Hospital, Regional Hospital Center of Metz-Thionville, 1 allée du château, CS 45001, 57085 Metz CEDEX 03, France

### **Titre court :**

**Integra® dermal substitute after exenteration**  
**Substitut dermique Integra® après exentération**

## **Abstract :**

The authors report their experience with the use of Integra® dermal substitute, in combination with a thin skin graft, following an orbital exenteration. The clinical case described relates to a 42-year-old gentleman with an ulcerative retractile lesion of the right lower eyelid. Histopathological examination diagnosed a moderately differentiated epidermoid carcinoma infiltrating the orbit. Total exenteration was necessary as well as secondary radiation therapy and chemotherapy. Rehabilitation of the exenterated socket was performed by inserting an Integra® patch, followed by an additional thin skin graft one month later.

The authors review the various available techniques for exenterations, their indications and the various possible secondary rehabilitations. Despite being less utilized, the dermal substitute technique, which is relatively new, seems to offer quicker and easier rehabilitation compared to traditional techniques.

A comparative study would be necessary to define superiority among the different techniques of exenteration, with respect to the speed of rehabilitation and resistance to radiation therapy.

**Key words :** exenteration, orbital tumors, dermal substitute, Integra®, epithesis.

## **Résumé :**

Les auteurs rapportent leur expérience à propos de l'utilisation de substitut dermique Integra® associé à une greffe de peau fine dans les suites d'une exentération pour tumeur orbitaire. Le cas clinique décrit concerne un patient de 42ans présentant une lésion ulcérate et rétractile de la paupière inférieure droite s'apparentant après examen anatomopathologique au diagnostic de carcinome epidermoïde moyennement différencié infiltrant l'orbite. Une exentération totale a été nécessaire associée dans les suites à une radiothérapie et une chimiothérapie. La réhabilitation de la cavité d'exentération est effectuée par la mise en place d'un patch d'Integra® suivi un mois plus tard d'une greffe de peau fine additionnelle.

Les auteurs font le point sur les techniques d'exentérations, leurs indications et sur les différentes réhabilitations secondaires possibles, dont celle faisant appel au substitut dermique qui reste encore relativement peu pratiquée à l'heure actuelle, malgré des suites potentielles relativement simples et autorisant une réhabilitation par épithèse accélérée.

Une étude comparative serait nécessaire pour définir une supériorité de l'une ou l'autre des techniques d'exentération, à la fois par rapport à la rapidité de réhabilitation et à la résistance vis-à-vis de la radiothérapie.

**Mots-clés :** exentération, tumeurs orbitaires, substitut dermique, Integra®, épithèses.

## **INTRODUCTION :**

Orbital exenteration is a surgical procedure used for the treatment of certain ocular, orbital, and palpebral malignancies that invaded the orbit and cannot be treated conservatively.

It is an extremely mutilating procedure, removing all the orbital elements, and leaving nude the orbital bony walls [1-2]. Exenterations can be partial (with eyelid preservation) or total (by extending the procedure to the adjacent tissues or periorbital cavities) when the lesion is extensive [2-3]. The main etiologies requiring exenteration are the palpebral malignancies invading the orbit by contiguity : epithelial tumors (basal cell epithelioma and squamous cell carcinoma), sebaceous carcinoma, conjunctival melanoma and squamous cell carcinoma [4-5].

Total orbital exenteration is the most commonly used technique and involves the bulk removal of eyelids and orbital contents covered by its periosteum. After having incised the skin until the bony rim and circularly around the entire orbital circumference, the periosteum is opened, and the periosteal sac is detached to the apex where the neurovascular pedicle is then carefully coagulated and sectioned [2-5]. The orbital walls are thus left nude and various methods are available for the cavity repair : spontaneous epithelialization, graft or flap.

Techniques such as locoregional flap (temporal muscle, frontal cutaneous) or free flap (rectus muscle of the abdomen, thigh) have long been the preferred solutions because they allow a correct filling of the orbital hollowness and even of a greater cavity volume if an enlarged exenteration was performed. Locoregional flap are robust and tolerate radiotherapy [6]. In case of total exenteration without adjuvant treatment, spontaneous epithelialization was the alternative choice versus thin skin grafts [3].

Recently, the appearance of epithesis techniques (made up of silicon), which is magnetically fixed to pillars that are osteo-integrated onto the orbital rim, significantly improved the rehabilitations of the exenteration cavities [7]. This requires, however, to opt either for a reconstruction solution leaving the orbital cavity open, or for a reoperation on the previously disposed flap, to ensure their correct placement and stability [6].

Orbital exenteration leaves a significant aesthetic and psychological scar and the rehabilitation of the exenteration cavity is therefore a major issue in the management of these patients. Its goal is to restore at best the aesthetic unity of the face with the possibility of adaptation of an epithesis, while allowing a satisfactory oncological surveillance but also the use of adjuvant treatments if necessary.

We describe here the case of a patient who benefited from a new alternative to the reconstruction of the orbital cavity after exenteration.

## **CASE DESCRIPTION :**

We report the case of a 42-year-old patient, referred to our department for a neglected retractile lesion of the outer half of the lower right eyelid, causing an irritative discomfort that became unbearable. After anamnesis, the patient described a history of chalazion having badly evolved with a stable scar for several months. He had already consulted several specialists for this lesion for the last 3 years, but being very anxious, he had always refused care. The clinical examination was delicate, but there was an ulcerative and retractile lesion, with madarosis on the outer half of the lower right eyelid, retraction of the conjunctival sac and a scar entropion of the lower eyelid (Fig. 1).

Because of the patient's anxiety, a biopsy under general anesthesia was made. While under general anesthesia, an external cantholysis was performed, this helped us to visualize the inferior and lateral conjunctival sac that was infiltrated by lesional tissue. Tissue induration was also noted extending to and below the outer orbital rim, reaching the orbit under the external canthal tendon. A large resection of the outer half of the lower eyelid, the outer canthus, the lateral third of the upper eyelid and the infiltrated conjunctiva was performed. The extemporaneous examination found a carcinomatous infiltration by an epidermoid carcinoma moderately differentiated with invasion of all the edges including the deep ones. Given the importance of the lesion and its local invasion, no additional resection was performed, and the decision was made to wait for the final histopathological results. The diagnosis of a moderately differentiated epidermoid carcinoma infiltrating the orbit was confirmed and the case of the patient was presented during a multidisciplinary consultation meeting. Total exenteration was decided with the possibility of performing adjuvant radiotherapy and chemotherapy according to the final pathological findings.

Total exenteration was performed under general anesthesia. After a skin incision to the bony rim, the orbital contents were removed from the periosteal sac with exposure of the bony walls of the orbital cavity (Fig. 2). Extemporaneous examination confirmed healthy margins greater than 5 mm. In addition, resection of the temporal and infero-temporal orbital bone ridges was performed (Fig. 3).

The rehabilitation of the exenteration cavity is carried out by setting up an Integra patch. Developed in 1981 by Yanna and Burke [8] to provide immediate wound coverage after excision, Integra® allows the regeneration of a functional dermis with a histologically normal architecture after extracellular matrix degradation. The patch consists of a bilayer substitute composed of an extracellular matrix covered with a Silastic® film. The synthetic surface layer is a 0.10 mm thick polysiloxane polymer film for water and gas exchange. The 2 mm thick dermal layer is a combination of bovine collagen Type I fibers and chondroitin-6-sulfate glycosaminoglycan, cross-linked by glutaraldehyde [9]. The dermal layer colonized by the cells of the patient is definitive and should be ideally grafted between D14 and D21 after removal of the superficial layer. Definitive healing takes place about one month after the Integra application (Fig. 4).

After hydrating the Integra leaflet for 2 minutes in physiological saline solution, it is placed in the exenteration cavity and sutured directly to the skin margins (Figure 5). The patch is finally plated on the orbital walls by a Jelonet leaflet topped by a compressive pledget (Figure 6). The duration of the intervention was 140 minutes.

An antibiotic prophylaxis with Amoxicillin + clavulanic acid was introduced for 10 days and the patient was able to leave 2 days after the surgery. Cavity monitoring and dressing repair were then performed every 3 days. Healing was satisfactory with the appearance of a budding tissue under the silicone film, 10 days only after the exenteration.

The definitive anatomopathological findings revealed a moderately differentiated epidermoid carcinoma infiltrating the orbit with healthy margins of 0.5 cm along the inferotemporal periosteum. Perineural sheathing and carcinomatous endovascular emboli were also present. Therefore, an adjuvant treatment by radio and chemotherapy was decided during a new multidisciplinary consultation meeting.

Four weeks after the first procedure, the patient underwent another general anesthesia procedure for port-a-cath placement.

Therefore, the decision to perform skin grafting in the exenteration cavity at the same time was taken. After ablation of the silicone film, we found a well vascularized budding of neo-dermal tissue.

A thin skin graft (0.2 mm), taken from the inside of the right thigh and expanded 1.7 times, was then placed in the cavity and sutured onto the skin margins but also attached directly to the neodermal tissue in the bottom of the cavity. The graft was then covered with Jelonet and a pledget to best conform with the orbital walls. The grafting was complete and rapid. Total re-epithelialization of the cavity was obtained 7 weeks after the exenteration.

Radiotherapy treatment was started the following week, with a dose of 30 grays divided into 15 fractions over the course of 20 days, concomitantly with 3 cures of CISPLATYL (A cure once every 15 days). A low cumulative dose of 30 grays was possible because the adjuvant treatment also included chemotherapy, otherwise this dose would have been too low for isolated radiotherapy. The tolerance of the graft with respect to radiotherapy was excellent, no disunion, no necrosis and no desquamation was noted (Figure 7).

Six months after the exenteration, a stable cavity was obtained, without post radiotherapy integument complications. The cavity was easy to monitor, free of recurrences, and well opened, allowing us to easily start the process of cosmetic rehabilitation by an epithesis. Epiplating titanium plates (Medicon, Tuttlingen, Germany) were directly fitted with their magnets on the superior and infero-lateral orbital rims (Fig. 8).

The healing of the skin above the plates and around the magnets was correct. 4 weeks after the establishment of the anchors, molding of the cavity for the creation of the silicone epithesis adapted to the osteo-integrated implants was performed (fig. 9).

In summary, the use of INTEGRA® for reconstruction, allowed us to obtain a rehabilitated cavity, ready to be equipped with an epithesis and easy to monitor. The reconstruction took only 7 months after the orbital exenteration with adjuvant radio and chemotherapy.

## **DISCUSSION :**

In case of orbital invasion, the management of oculo-orbito-palpebral malignancies sometimes requires exenteration. In the literature, after exenteration, the most commonly used reconstruction techniques are spontaneous epithelialization (32 to 80 % of cases), muscle flaps (25 to 77 % of cases) and skin grafts (from 23 to 63 % of cases) [6, 10-14]. The recent appearance of epithesis supported by osteo-integrated implants has significantly improved the cosmetic rehabilitation of exenteration cavities, and their use makes it possible to adapt stable epitheses in 20 to 95 % of the cases [6, 10, 15], with a satisfactory result for the patients [7, 16].

The choice of the reconstruction technique should be guided by the size of the deficit to be filled, the use of a possible adjuvant radiotherapy (requiring a rapid making of a cavity that can tolerate it) and finally the patient's will for wearing of an epithesis (requiring the creation of a so-called open cavity) [6, 12].

After exenteration, the spontaneous epithelialization of the cavity by granulation is a frequently used reconstruction solution. It makes it possible to obtain cavities that are easier to adapt with epithesis, and also easy to monitor, without the associated difficulties and complications with the removal and the use of a flap or graft. However, it requires frequent care and regular monitoring. The healing average duration can vary between 3 to 10 months, depending on the studies, and is highly dependent on a possible necessary adjuvant radiotherapy [12-14, 17].

Adaptation of osteo-integrated implants comes later than with the other means of reconstruction and is usually postponed around 11 to 19 months after exenteration in case of granulation [10, 13]. There is also a higher rate of fistula-like complications than with grafts or flaps [17-18] ranging from 28 % in the series of Rahman et al. [13] to 68 % in the series of Mohr et al. [12]. These fistulas arise because of the secretions create a chronic flow with an inflammatory cavity. All of which is uncomfortable for the patients and therefore hindering the prosthetic adaptation.

Fine or dermal skin grafts accelerate the recovery of the bony walls of the cavity. Healing is usually achieved in 6 to 8 weeks. Although they allow the rapid creation of an ideal open cavity for future prosthetic adaptation, they have a significant failure rate given the difficulty of fixing them directly onto the bone. Moreover, the tissues created being thin, they hardly tolerate radiotherapy and healing problems can also occur during the placement of bone implants [11, 13-14]. For Hanasono et al. [6] their indications are limited to partial or total exenterations, not requiring radiotherapy and where rapid prosthetic rehabilitation is desired.

The immediate reconstruction of the cavities by loco-regional flaps (temporal or frontal) or free flaps can cover large skin deficits and has the advantage of reconstructing the cavity in a single operation. It can be helpful especially for patients with precarious general conditions, but this lengthens the duration of the surgery by several hours as well as the duration of hospitalization. [6]. Their large volume and rapid healing allow an optimum filling of the cavity thus limiting the risk of fistula. Their robustness gives them good tolerance to

adjuvant radiotherapy [19]. Their cosmetic results are however less satisfactory than the adaptation of an epithesis, and in the case of desired secondary rehabilitation, as they create so-called full cavities, the flaps will hinder the adaptation of epithesis and revision procedures may be necessary [6, 20].

In addition, there is a risk of comorbidities and significant aesthetic damage related to the site of sampling. Finally, the flap will make it more difficult to monitor the cavity for early detection of potential recurrences that may occur in up to 24 % of the cases [14]. Developed in the 80s by the team of Yanna and Burke [8], the Integra® has been available in France for about twenty years and used for the management of burn victims where it has shown its effectiveness [9, 21]. Currently, because of its ease of use, its ability to bud directly onto the bone, and its satisfactory aesthetic and functional results, it is increasingly used in plastic and reconstructive surgery. It makes it possible to obtain a rapid quality skin coverage (4 to 6 weeks).

Also, quality skin coverage can be obtained in large losses of substance, including the scalp or the face, all of which without using flaps, reduce the operating time, hospitalization time, and comorbidities related to the flap sampling sites [22-25].

Finally, tissues reconstructed with the help of Integra® have a good tolerance with respect to radiotherapy [26]. In our case, the placement of the dermal substitute, combined with a secondary skin graft, has shown to be effective in reconstructing a complex loss of substance with exposed orbital bone. It allowed a quality healing of the exenterated cavity in just 6 weeks and all while having well tolerated an adjuvant radiotherapy that could have been deleterious to a transplant. A few similar cases of use of Integra® dermal substitute, secondary to exenterations, have been described in the literature in recent years : a series of 7 cases described by Rafailov et al. in 2017 [27], a series of 5 cases described by Ozgonul et al. [25] as well as a unique case described by Patel et al. in 2018 [28].

For all the described cases, the procedure and the hospitalization duration were shorter than with graft or flap reconstruction techniques [6]. Postoperative care was simpler, shorter and not very demanding compared to that required with spontaneous epithelialization. However, a second intervention was required in the month following exenteration, to perform thin skin grafting. Some one-step procedures were described and showed satisfactory results as well [23, 29].

In our patient cosmetic rehabilitation was started only 6 months after the exenteration in order to be able to monitor the reaction of the reconstructed cavity in the aftermath of the radiotherapy, but also to detect a possible retraction of the reconstructed cutaneous tissue by dermal substitutes, whose surface area can decrease by 30 % [23-24].

Healing on the bone implants was satisfactory and the well open cavity allowed easy adaptation of the epithesis with stability and comfort.

As in the previous publications, we didn't note any complications such as early fistula, dermatitis or necrosis after radiotherapy of the cavity. In addition, the use of the Integra® made it possible to avoid any complications or facial unaesthetic scarring related to the site of flap removal. Finally, in the absence of flap, the monitoring of a possible recurrence in the cavity was easy and since healing was rapid it was not confused with budding tissue.

## **CONCLUSION :**

The use of Integra® Dermal Substitute combined with a thin skin graft appears to be a simple and satisfactory alternative for the reconstruction of orbital exenterated cavities. It allows rapid healing with a good local tolerance to radiotherapy. It is fast, simple and harmless for the rest of the face. Finally, this combination allows early cosmetic rehabilitation, while ensuring optimal local cancer monitoring. A comparative study would confirm the interest of this treatment in post-exenteration reconstructions.

## **Conflict of interest :**

The authors declare having no conflict of interest related to this article.

## **BIBLIOGRAPHY :**

- [1] Pollack RS. Orbital and periorbital tumors. Indications for exenteration. Calif Med 1959;91:207-11.
- [2] Mouriaux F, Barraco P, Patenôtre P, Pellerin P. [Orbital exenteration]. J Fr Ophtalmol 2001;24(8):865-74.
- [3] Kiratli H, Koç İ. Orbital exenteration: Institutional review of evolving trends in indications and rehabilitation techniques. Orbit Amst Neth 2018;37(3):179-86.
- [4] Soysal HG. Orbital exenteration: a 10-year experience of a general oncology hospital. Orbit Amst Neth 2010;29(3):135-9.
- [5] George J-L. [Orbital tumors: the ophthalmologist's point of view (biopsies - approaches - exenteration)]. Neurochirurgie 2010;56(2-3):236-40.
- [6] Hanasono MM, Lee JC, Yang JS, Skoracki RJ, Reece GP, Esmaeli B. An algorithmic approach to reconstructive surgery and prosthetic rehabilitation after orbital exenteration. Plast Reconstr Surg 2009;123(1):98-105.
- [7] Melicher Larson JS, Nerad JA. The use of osseointegration and rare earth magnetic coupling for oculofacial prosthesis retention in the exenterated orbit. Curr Opin Ophthalmol 2009;20(5):412-6.
- [8] Burke JF, Yannas IV, Quinby WC, Bondoc CC, Jung WK. Successful use of a physiologically acceptable artificial skin in the treatment of extensive burn injury. Ann Surg 1981;194(4):413-28.
- [9] Lamy J, Yassine A-H, Gourari A, Forme N, Zakine G. [The role of skin substitutes in the surgical treatment of extensive burns covering more than 60 % of total body surface

area. A review of patients over a 10-year period at the Tours University Hospital]. *Ann Chir Plast Esthet* 2015;60(2):131-9.

- [10] Langlois B, Jacomet P-V, Putterman M, Morax S, Galatoire O. [Evaluation of reconstructive techniques after orbital exenteration in 56 cases]. *J Fr Ophtalmol* 2012;35(9):667-77.
- [11] Nassab RS, Thomas SS, Murray D. Orbital exenteration for advanced periorbital skin cancers: 20 years experience. *J Plast Reconstr Aesthetic Surg JPRAS* 2007;60(10):1103-9.
- [12] Mohr C, Esser J. Orbital exenteration: surgical and reconstructive strategies. *Graefes Arch Clin Exp Ophthalmol Albrecht Von Graefes Arch Klin Exp Ophthalmol* 1997;235(5):288-95.
- [13] Rahman I, Cook AE, Leatherbarrow B. Orbital exenteration: a 13 year Manchester experience. *Br J Ophthalmol* 2005;89(10):1335-40.
- [14] Nemet AY, Martin P, Bengler R, Kourt G, Sharma V, Ghabrial R, et al. Orbital exenteration: a 15-year study of 38 cases. *Ophthal Plast Reconstr Surg* 2007;23(6):468-72.
- [15] Greig AVH, Jones S, Haylock C, Joshi N, McLellan G, Clarke P, et al. Reconstruction of the exenterated orbit with osseointegrated implants. *J Plast Reconstr Aesthetic Surg JPRAS* 2010;63(10):1656-65.
- [16] Moran WJ, Toljanic JA, Panje WR. Implant-retained prosthetic rehabilitation of orbital defects. *Arch Otolaryngol Head Neck Surg* 1996;122(1):46-50.
- [17] Putterman AM. Orbital exenteration with spontaneous granulation. *Arch Ophthalmol Chic Ill* 1960 1986;104(1):139-40.
- [18] Bartley GB, Garrity JA, Waller RR, Henderson JW, Ilstrup DM. Orbital exenteration at the Mayo Clinic. 1967-1986. *Ophthalmology* 1989;96(4):468-73.
- [19] Benazzou S, Arkha Y, Boulaadas M, Essakalli L, Kzadri M. [Orbital exenteration]. *Rev Stomatol Chir Maxillofac* 2011;112(2):69-74.
- [20] Tyers AG. Orbital exenteration for invasive skin tumours. *Eye Lond Engl* 2006;20(10):1165-70.
- [21] Dantzer E, Queruel P, Salinier L, Palmier B, Quinot JF. [Integra, a new surgical alternative for the treatment of massive burns. Clinical evaluation of acute and reconstructive surgery: 39 cases]. *Ann Chir Plast Esthet* 2001;46(3):173-89.
- [22] Khan MAA, Ali SN, Farid M, Pancholi M, Rayatt S, Yap LH. Use of dermal regeneration template (Integra) for reconstruction of full-thickness complex oncologic scalp defects. *J Craniofac Surg* 2010;21(3):905-9.

- [23] Koenen W, Felcht M, Vockenroth K, Sassmann G, Goerdts S, Faulhaber J. One-stage reconstruction of deep facial defects with a single layer dermal regeneration template. *J Eur Acad Dermatol Venereol JEADV* 2011;25(7):788-93.
- [24] Felcht M, Koenen W, Sassmann G, Goerdts S, Faulhaber J. Two-stage reconstruction of head and neck defects after tumor resection with a dermal regeneration template. *J Cutan Med Surg* 2011;15(5):259-65.
- [25] Ozgonul C, Diniz Grisolia AB, Demirci H. The Use of Integra® Dermal Regeneration Template for the Orbital Exenteration Socket: A Novel Technique. *Ophthal Plast Reconstr Surg* 2018;34(1):64-7.
- [26] Tufaro AP, Buck DW, Fischer AC. The use of artificial dermis in the reconstruction of oncologic surgical defects. *Plast Reconstr Surg* 2007;120(3):638-46.
- [27] Rafailov L, Turbin RE, Langer PD. Use of bilayer matrix wound dressing in the exenterated socket. *Orbit* 2017;36(6):397-400.
- [28] Patel SY, Tamboli DA, Mancini R. *Int Ophthalmol*. Two-stage rapid exenteration reconstruction to allow early radiation therapy for an aggressive orbital cancer 2018;38(2):833-836.
- [29] Demiri E, Papaconstantinou A, Dionyssiou D, Dionyssopoulos A, Kaidoglou K, Efstratiou I. Reconstruction of skin avulsion injuries of the upper extremity with integra® dermal regeneration template and skin grafts in a single-stage procedure. *Arch Orthop Trauma Surg* 2013;133(11):1521-6.

## **Legends of the figures**

**Figure 1 :** initial aspect of the lesion during management, with an ulcerative and retractile lesion of the outer half of the lower right eyelid.

**Figure 2 :** extirpation of the periosteal sac with the orbital content.

**Figure 3 :** orbital cavity exposed with resection of temporal orbital rim.

**Figure 4 :** from left to right and from bottom to top : Integra® patch ; initial skin deficit ; 6 days after placement of the patch, we note the formation of the neo-dermis under the Silicone sheet ; Removal of the silicone film ; placement of an expanded thin skin graft on the new dermis ; J30 complete healing with reformation of the cutaneous tissue.

**Figure 5 :** Integra® patch set up in the orbital cavity.

**Figure 6 :** Jelonet® tamponade to patch the orbital wall patch.

**Figure 7 :** Cavity 15 weeks after the exenteration and 1 month after the end of the adjuvant radiotherapy.

**Figure 8 :** Cavity equipped with osteo-integrated implant 7 months after the exenteration.

**Figure 9 :** final epithesis.

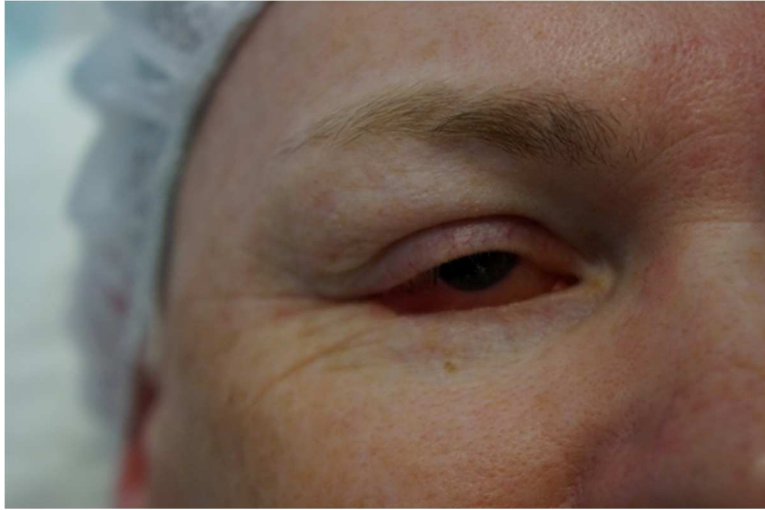

Figure 1: initial aspect of the lesion during management, with an ulcerative and retractile lesion of the outer half of the lower right eyelid.

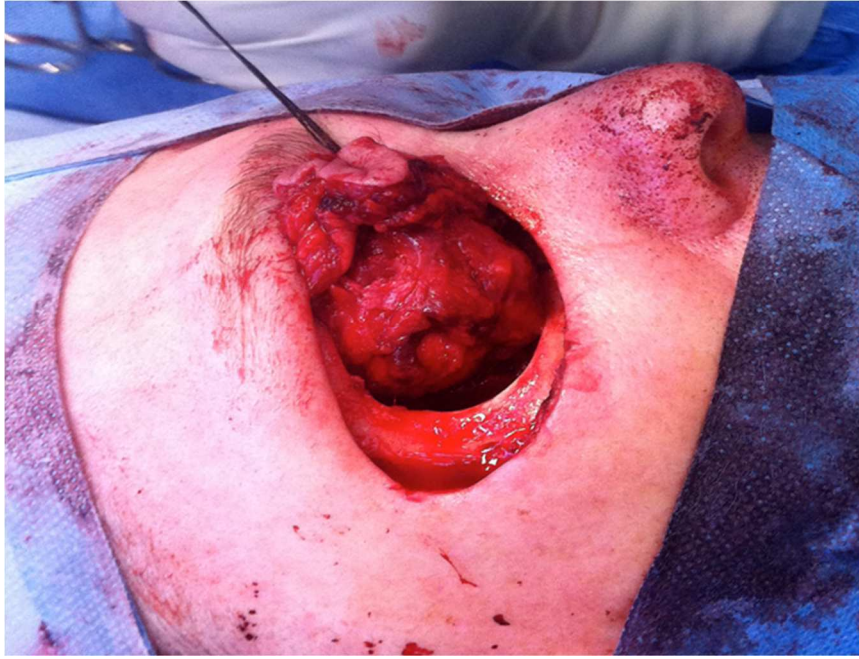


Figure 2: extirpation of the periosteal sac with the orbital content

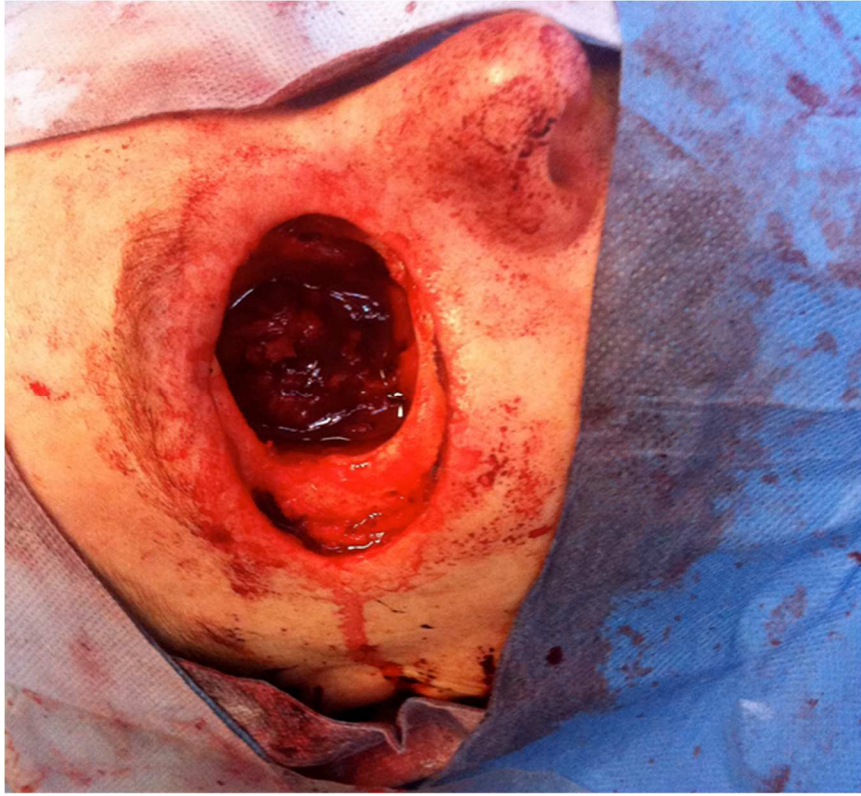


Figure 3 : orbital cavity exposed with resection of temporal orbital rim




Figure 4: from left to right and from bottom to top: Integra® patch; initial skin deficit; 6 days after placement of the patch, we note the formation of the neo-dermis under the silicone sheet; Removal of the silicone film; placement of an expanded thin skin graft on the new dermis; J30 complete healing with reformation of the cutaneous tissue

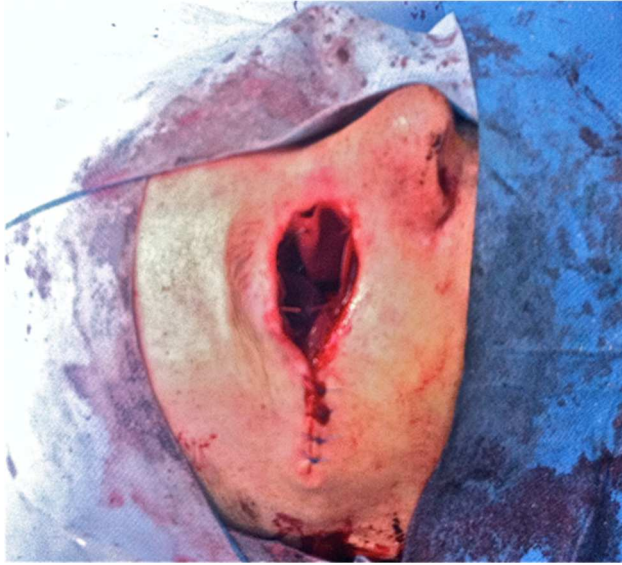


Figure 5: Integra® patch set up in the orbital cavity

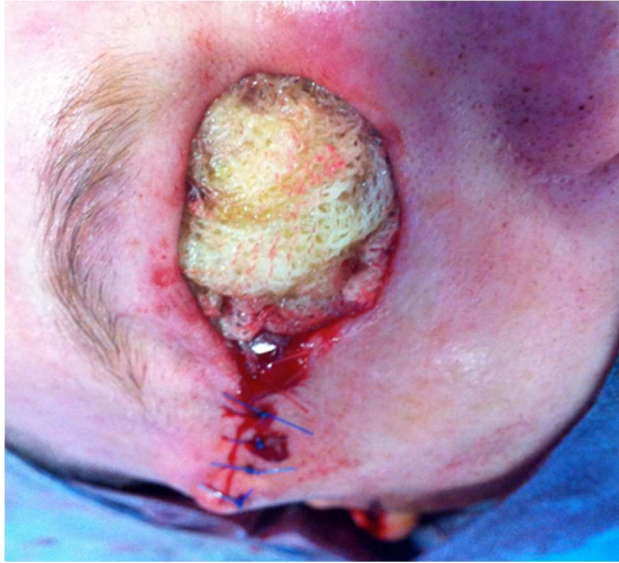


Figure 6: Jelonet® tamponade to patch the orbital wall patch.

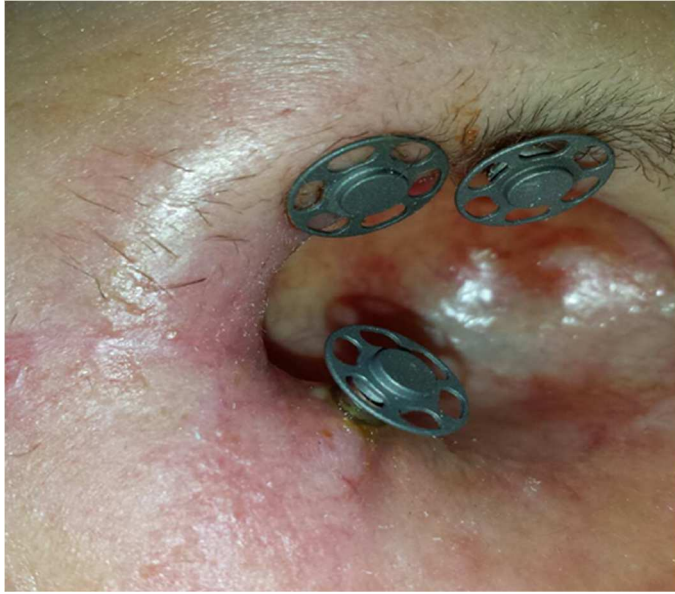

Figure 8: Cavity equipped with osteo-integrated implant 7 months after the exenteration.

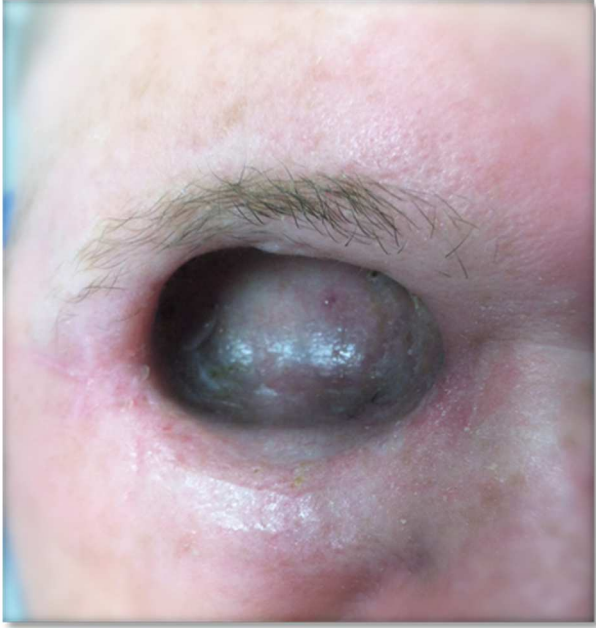


Figure 7: Cavity 15 weeks after the exenteration and 1 month after the end of the adjuvant radiotherapy.

