



HAL
open science

Fingertip amputations treated with occlusive dressings

J. Boudard, F. Loisel, S. El Rifaï, D. Feuvrier, L. Obert, I. Pluvy

► To cite this version:

J. Boudard, F. Loisel, S. El Rifaï, D. Feuvrier, L. Obert, et al.. Fingertip amputations treated with occlusive dressings. *Hand Surgery and Rehabilitation*, 2019, 38, pp.257 - 261. <10.1016/j.hansur.2019.06.002>. <hal-03487695>

HAL Id: hal-03487695

<https://hal.science/hal-03487695v1>

Submitted on 20 Jul 2022

HAL is a multi-disciplinary open access archive for the deposit and dissemination of scientific research documents, whether they are published or not. The documents may come from teaching and research institutions in France or abroad, or from public or private research centers.

L'archive ouverte pluridisciplinaire **HAL**, est destinée au dépôt et à la diffusion de documents scientifiques de niveau recherche, publiés ou non, émanant des établissements d'enseignement et de recherche français ou étrangers, des laboratoires publics ou privés.



Distributed under a Creative Commons CC BY-NC 4.0 - Attribution - Non-commercial use - International License

Fingertip amputations treated with occlusive dressings

Amputation digitale distale traitée par pansement occlusif

J. Boudard, S. El Rifaï, D. Feuvrier, L. Obert, F. Loisel

Service d'Orthopédie, de Traumatologie, de Chirurgie Plastique, Reconstructrice et
Assistance Main, CHRU Besançon - CHI Vesoul & CIC IT, 808, boulevard Fleming, 25033
Besançon, France, and

EA Nano médecine, Université de Franche Comté, 1, rue Claude Goudimel, 25000
Besançon, France

Corresponding author:

Julien Boudard

Service d'Orthopédie, de Traumatologie, de Chirurgie Plastique, Reconstructrice et
Assistance Main, CHRU Besançon - CHI Vesoul & CIC IT, 808, boulevard Fleming, 25033
Besançon, France

julienboudard@hotmail.fr

Other e-mail addresses:

seb470@hotmail.com

feuvrier.damien@gmail.com

laurentobert@yahoo.fr

francois_loisel@yahoo.fr

Conflict of interest:

Laurent Obert has established relationships with the following organizations: FX solutions, Zimmer, Medartis, Evolutis, Wright, Elsevier. None of the other authors have conflicts of

interest related to this work.

Fingertip amputations treated with occlusive dressings

Amputation digitale distale traitée par pansement occlusif

Abstract

The aim of this study was to analyze a series of patients who suffered a distal finger amputation and who were treated with occlusive dressings. A retrospective study was done of 19 patients from a single hospital. At the review, an independent examiner evaluated the time required for wound healing, the number of occlusive dressings used, fingertip trophic skin changes, epicritic sensitivity using the Weber two-point discrimination (2PD) test, sensitivity based on the monofilament test, complications, the presence of dysesthesia or cold intolerance, and the QuickDASH score.

The mean follow-up was 12.6 months (6–25). A mean of 3.2 occlusive dressings (3–5) were used per patient, and the mean healing time was 4.3 weeks (4–5). The skin texture, fingertips and nail bed were good or excellent in 18 cases. The 2PD test was good or normal in 16 cases. Eighteen patients were satisfied or very satisfied with the outcome. The mean QuickDASH score was 5.53 (0–20.45).

In the literature, the recovery of tactile sensation is good after use of occlusive dressings (2PD of 2.5 to 4.0 mm). The mean sensitivity reported in various studies is better than that observed after use of a skin flap. While the sample size in our study was small, the functional outcome and appearance were good. Thus we prefer using occlusive dressings in Zone 1 and 2 fingertip amputations, and flaps in zones 3 and 4 to ensure better fingertip viability and sensation.

Résumé

L'objectif de cette évaluation était d'analyser une série de patients ayant présenté une amputation digitale distale traitée par pansement occlusif.

Une évaluation monocentrique rétrospective était réalisée pour une série de 19

patients. Au plus grand recul, un évaluateur indépendant analysait le délai de cicatrisation, le nombre de pansements occlusifs nécessaires, la trophicité pulpaire, la sensibilité tactile épicrotique par le test des deux points, la sensibilité au test du monofilament, l'existence de complications, la présence de dysesthésies et d'intolérance au froid, le score QuickDASH.

Dix-neuf patients ont pu être revus au recul de 12,6 mois (6-25). Le nombre de pansements occlusifs par patient était de 3,2 (3-5) avec un délai de cicatrisation de 4,3 semaines (4-5). La trophicité pulpaire était excellente ou bonne dans 18 cas. La sensibilité au test de Weber était normale ou bonne dans 16 cas. Dix-huit patients se disaient satisfaits ou très satisfaits. Le score QuickDASH atteignait 5,53 (0-20,45).

Dans la littérature, la récupération de la sensibilité tactile est bonne après pansement occlusif (Weber = 2,5 à 4 mm). La sensibilité moyenne des différentes séries est meilleure que celle observée après lambeaux. L'effectif de notre série est faible, mais nous observons de bons résultats fonctionnels et esthétiques. Notre traitement de choix est représenté par les pansements occlusifs en zones 1 et 2, alors que nous utilisons les lambeaux dans les zones 3 et 4 afin d'apporter une meilleure trophicité pulpaire.

Keywords: Fingertip amputation; Second intention healing; Occlusive dressing

Mots-clefs : Amputation digitale distale ; Cicatrisation dirigée ; Pansement occlusif

1. Introduction

The treatment strategy for fingertip amputations depends on the amputation level along the injured finger and the patient's condition, but also on the surgeon's preferences [1,2]. Treatment is a means to provide the missing skin with coverage flaps or to allow spontaneous regeneration of the fingertip through nonsurgical treatment (occlusive dressing, impregnated gauze dressings). This treatment also aims to restore fingertip function: fine sensation, skin stability allowing the fingertips to grasp objects, satisfactory appearance [1]. Over the years, these goals have been achieved using coverage flaps. However, flaps are associated with complications such as necrosis, infection, finger stiffness, reduced sensation, wound healing sequelae, and fingertip instability.

An occlusive dressing prevents scar formation and allows regeneration of the fingertip in zone 1 and 2, or even zone 3 amputations in the Merle and Dautel topography [3]. Several studies have reported good clinical outcomes [1,2,4-8].

The aim of our study was to report on a new series of patients with a distal fingertip amputation who were treated with occlusive dressings and were evaluated continuously over a 4-year period. They were then reviewed by an independent surgeon at the end of the healing phase. We hypothesized that four dressings would be sufficient to regenerate the fingertip.

2. Patients and methods

This was a retrospective study of cases at a single hospital. Patients who suffered a distal fingertip amputation between 2011 and 2015 and were treated with occlusive dressings were evaluated. Included were patients who suffered a fingertip amputation distal to the distal interphalangeal joint, regardless of which finger was injured, the amputation mechanism or the amputation zone (classification of Merle and Dautel [3]).

2.1. Occlusive dressing application technique

For zone 1, 2, 3 amputations, the dressing was applied in the emergency room after

lavage with sterile water, under local anesthesia if necessary. Two semipermeable dressings (Tegaderm®, 3M™, Maplewood, Minnesota, United States) (Fig. 1) were used to wrap the entire amputation zone and were secured with adhesive down to the proximal interphalangeal joint. No antibiotics or antiseptic agents were used at any time, from the initial treatment until the wound healed [1,9]. The dressing was changed each week during an office visit. In all, three to six dressings were used per patient. The patient was not given any specific instructions on using the amputated and bandaged finger. One week after the dressing was applied, the skin was macerated and whitish in color (Fig. 2). After two or three dressings, the wound gave off an unpleasant, even nauseating, odor. Charcoal or adhesive bandages at the base of the finger were used to reduce this problem [9].

2.2. Methods

At the final review, an investigator who was not involved in the initial treatment decision evaluated the time to healing, the number of occlusive dressings used, complications and trophic changes in the reconstructed fingertip. The latter was evaluated relative to the fingertip of the same finger in the contralateral hand as described by Lasserre et al. [1]: “excellent” when both fingertips were identical, “poor” when a defect was present in the reconstructed fingertip that was more than one-quarter compared with the contralateral finger, and “good” between these two extremes. The reappearance of fingerprints was recorded. Epicritic sensation (Weber two-point discrimination test – 2PD) was performed and interpreted as described by Moberg [10]. The monofilament test was performed with five sizes and interpreted as follows: a response to the 2.83 monofilament was considered normal; a response to the 3.61 monofilament showed a reduction in fine sensitivity, a response to the 4.31 monofilament showed a reduction in protective sensation, and a response to the 4.56 or 5.07 monofilaments showed a loss of protective sensation (Touch-Test™ Sensory Evaluator Instructions). The presence of dysesthesia or cold intolerance and their duration was recorded. The QuickDASH and time to return to work were documented. Lastly, nail-related complications were evaluated, and the patients were asked at the review

visit to rate their satisfaction with the outcome as “very satisfied,” “satisfied” or “disappointed.”

2.3. Statistics

Comparisons of normally distributed data were performed with Student’s *t* test. The threshold for statistical significance (*p* value) was set at 0.05. An evaluation of whether certain events were related to each other was done using the Chi-square test or Fisher’s exact test. The correlation between two quantitative variables was determined with the Pearson correlation test.

3. Results

Nineteen patients treated with an occlusive dressing for a distal finger amputation between 2011 and 2015 were included. Their mean age was 47.3 years (22–73). The vast majority of the population was male (89.5%). The amputation mechanism consisted of clean transection, crushing, or mutilation. The amputations occurred mainly in zones 1 and 2 (78.9% of cases) (Table 1). The mean follow-up at the review was 12.6 years (6–25).

A mean of 3.2 (3–5) occlusive dressings were used per patient and the mean healing time was 4.3 ± 1 weeks (4–5). The fingertip condition was deemed excellent in 6 cases, good in 12 cases and poor in 1 case. The fingerprints were restored in all patients.

Based on the Weber 2PD and Moberg scale, sensitivity was normal in 15 cases, good in 1 case and discriminatory in the other 3 cases. None of the patients had normal sensation on the monofilament test. Reduction in fine sensitivity was found in 10 cases, reduction in protective sensitivity in 7 cases and loss of protective sensitivity in 2 cases. Thirteen patients continued to have dysesthesia at the review, one patient had altered sensation for 1 month after healing and five patients had no troubles. Four patients had persistent cold intolerance, including two patients who had a zone 3 amputation.

As for complications, nail dystrophy was found in four patients (three hook-nail deformities and one ridged nail), all of whom had a zone 3 amputation. No local or systemic

infections occurred that required treatment or surgery.

At the final review, 13 patients were very satisfied with the final outcome while five were satisfied and one was disappointed. The mean QuickDASH score was 5.53 (0–20.45). The time to return to work in the 13 employed patients was 4.8 ± 4 weeks (1–13). None of the variables were significant predictors of the outcome, given the small size of the subgroups.

4. Discussion

4.1. Reality and quality of fingertip regeneration

Our hypothesis that four dressings are needed to regenerate the fingertip was confirmed, although the outcomes were not as good in zone 3 amputations. While occlusive dressings are an effective solution with a long history of use, their use varies greatly between hospitals either due to lack of knowledge or due to fear. We found 17 publications on this topic, 14 of which were case series, including 2 comparative studies, evaluating 382 patients. The published articles can be divided into pre-2010 and post-2010 for analysis purpose.

Before 2010, and especially in the large studies of more than 200 cases by Mennen and Wiese [4], the authors described the outcomes after 1 or 2 months of treatment. The Weber 2DP test was 4 mm, the complication rate was very low and there were no infections. The articles published before 2010 all stressed the nauseating odor.

In 1974, Illingworth [7] reported excellent esthetic and functional outcomes in 300 cases of fingertip amputation in children treated non-surgically, even for amputations at the base of the distal phalanx (zone 4).

A few years later, Fox et al. [8] claimed that occlusive dressings were superior to local flaps for zone 1 amputations. The dressing was done using aluminum foil. Louis et al. [11] reported very good tactile discrimination in 29 patients treated with occlusive dressings in zone 1. Two-thirds of patients were away from work for only 1 day. In 1981, De Boer and Collinson [12] compared dressings with Fucidine® (31 zone 1 amputations) to occlusive dressings with Flammazine® (26 zone 1 and 3 injuries with exposed bone). They reported

excellent fingertip reconstruction, even in the cases of exposed bone (occlusive dressing). The healing time was the same between groups, but the patients in the occlusive dressing group returned to work faster, as the waterproofness of this dressing allowed early resumption of duties in all working conditions.

Quell et al. [6] reported good sensitivity and good viability after 42 distal amputations including those with bone loss. Mennen and Wiese [4] recommended this non-surgical treatment for any distal amputation given the published results (better results for tactile sensation). The appearance of the fingertip was nearly normal.

Starting in 2010, various comparative studies on frostbite were published and ultrasonography was incorporated to evaluate the regenerated fingertip. In 2010, Lasserre et al. [1] were the first to describe the biological composition of the exudate in the dressing. They found several types of saprophytic and pathogenic bacteria. These potentially aggressive pathogenic species never caused an infection in patients. The types of pathogenic bacteria varied from one week to the next and differed from the normal skin flora. The second finding was the large amount of angiogenesis-promoting growth factors such as PDGF, VEGF and GF, which were not detectable in the occlusive dressings of the control subjects.

Hoigné et al. [5] were the first to use ultrasonography to measure the percentage of the fingertip regenerated. Nearly 90% of the fingertip was restored after occlusive dressings were used for zone 2 and 3 amputations.

4.2. Fingertip sensitivity

In these various studies, the recovery in tactile spatial acuity was good, with mean 2PD ranging from 2.5 to 4 mm. However, there are no data on how these vary by amputation zone. The mean sensitivity reported in the literature is better with occlusive dressings than when flap coverage is used [13]. There are no reports of the monofilament test being used. We have no explanation for why this test found worse sensitivity than the Weber 2PD in our study. The healing time in our study was 4.1 weeks, which is consistent with other published

studies, whether using flap coverage or an occlusive dressing (Table 2) [13]. However, it is difficult to compare studies given the wide range of situations and extent of fingertip injuries involved. Patients who suffer a zone 3 amputation have the worse outcomes in terms of sensitivity and vitality of the fingertip. This suggests occlusive dressings have limitations in more proximal amputations.

4.3. Complications

In our study, complications were observed in patients who suffered a zone 3 amputation: nail dystrophy and ridged nail in a case of dorsal oblique amputation involving the nail bed. We found no infections or fingertip instability. Stiffness was also avoided because occlusive dressings allow early mobilization.

Other studies reported no complications, but they did not always measure sensory disorders and cold intolerance, which we believe are nearly unavoidable, especially in the first few months after healing. These complications occur both after conservative treatment and flap coverage [13].

4.4. Mechanisms of fingertip regeneration

Fingertip regeneration with a dressing is considered true regeneration [14] because no scab forms. Many studies on skin regeneration have been performed on animals such as zebra fish and axolotl, which are models of extremity, limb and tail regeneration [14].

In our study, we found growth factors involved in fingertip regeneration, but have no information about their actions or magnitude.

In an animal model, Ferguson and O'Kane [15] highlighted the role of various TGF-beta subtypes, ubiquitous growth factors involved in several regenerative and healing processes. These studies open new research avenues and encouraged us to measure the various types of TGF-beta fractions found locally. According to Ferguson and O'Kane, TGF-beta3 is a marker or effector of scar-free healing. This growth factor is found in large

quantities in regeneration models, contrary to TGF-beta1 and -2, which cause scarring without regeneration.

5. Conclusion

For cases of zone 1 and 2 fingertip amputations, healing with an occlusive dressing allows regeneration of the fingertip, with restoration of its shape and dermatoglyphic prints. This regeneration, which is better understood now, occurs with three to four occlusive dressings, thus 1 month of treatment. While certain studies report good cutaneous outcomes in zone 3 and zone 4 amputations, occlusive dressings cannot prevent hook-nail deformity in these zones without another procedure.

Conflict of interest:

Laurent Obert has established relationships with the following organizations: FX solutions, Zimmer, Medartis, Evolutis, Wright, Elsevier. None of the other authors have conflicts of interest related to this work.

References

1. Lasserre G, Bakkouch S, Pauchot J, Binda D, Robin S, Humbert P, et al. Fingertip reconstruction with occlusive dressing: clinical results and biological analysis of the dressing contents. *Chir Main* 2010;29:315-20.
2. Farrell RG, Disher WA, Nesland RS, Palmatier TH, Truhler TD. Conservative management of fingertip amputations. *J Am Coll Emerg Phys* 1977;6:243-6.
3. Merle M, Dautel G. Amputations d'attente et amputations définitives. In: *La main traumatique*. Tome 1. Paris: Masson; 1997: p. 251-3.
4. Mennen U, Wiese A. Fingertips injuries management with semi-occlusive dressing. *J Hand Surg Br* 1993;18:416-22.
5. Hoigné D, Hug U, Schürch M, Meoli M, von Wartburg U. Semi-occlusive dressing for the treatment of fingertip amputations with exposed bone: quantity and quality of soft-tissue regeneration. *J Hand Surg Eur* 2014;39:505-9.
6. Quell M, Neubauer T, Wagner M. Treatment of fingertip defect injuries with a semi-occlusive dressing. *Handchir Mikrochir Plast Chir* 1998;30:24-9.
7. Illingworth CM. Trapped fingers and amputated fingertips in children. *J Pediatr Surg* 1974;9:853-8.
8. Fox JW 4th, Golden GT, Rodeheaver G, Edgerton MT, Edlich RF. Nonoperative management of fingertip pulp amputation by occlusive dressings. *Am J Surg* 1977;133:255-6.
9. Hoigné D, Hug U. Amputations de la dernière phalange : régénération par film. *Forum Med Suisse* 2014;14:356-60.
10. Moberg E. Objective methods for determining the functional value of sensibility of the hand. *J Bone Joint Surg Br* 1958;40:454-76.
11. Louis DS, Palmer AK, Burney RE. Open treatment of digital tip injuries. *JAMA* 1980;244:697-8.
12. de Boer P, Collinson PO. The use of silver sulphadiazine occlusive dressings for

finger-tip injuries. *J Bone Joint Surg Br* 1981;63:545-7.

13. Dumontier C, Meningaud J, Hervé C. Connaissance des complications de la chirurgie des lambeaux pulpaire des doigts longs et information des patients – implications éthiques. *Chir Main* 2001;20:122-35.

15. Farah Z, Fan H, Liu Z, He JQ. A concise review of common animal models for the study of limb regeneration. *Organogenesis* 2016 2;12:109-18

14. Ferguson MWJ, O’Kane S. Scar-free healing: from embryonic mechanisms to adult therapeutic intervention. *Philos Trans R Soc Lond B Biol Sci* 2004;359:839-50.

Figure legends

Fig. 1. Application of occlusive dressing; the same method is used each time the dressing is changed. In the ideal case, the dressing does not capture the proximal interphalangeal joint to allow movement of the injured finger.

Fig. 2. Typical appearance of macerated skin after 1 week

Fig. 3. Female 46-year-old patient who suffered a zone 1 amputation and required 4 dressings. Appearance at D7, D14 and 3 months. The result was the same at 1 year. Weber = 4 mm, moderate dysesthesia and cold intolerance

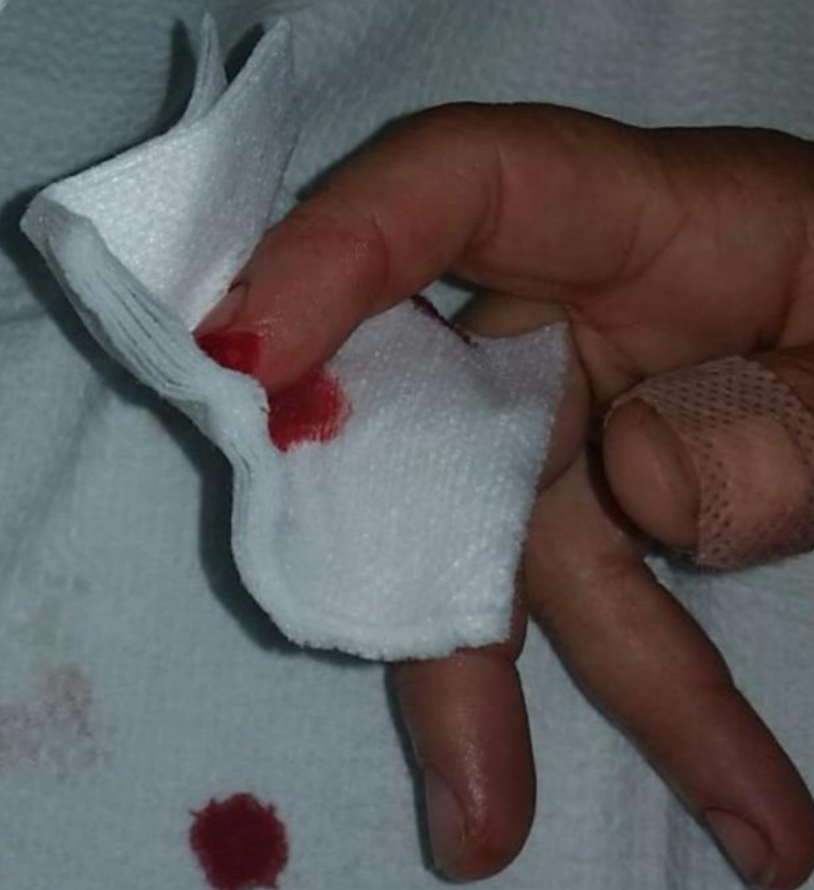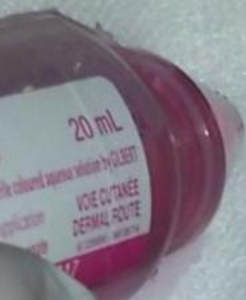Fig. 4. Male, 34-year-old patient who suffered a zone 2 amputation and required 4 dressings. Appearance at D0, D21 and 4 months. The result was the same at 1 year. Weber = 4 mm, returned to work after 5 weeks

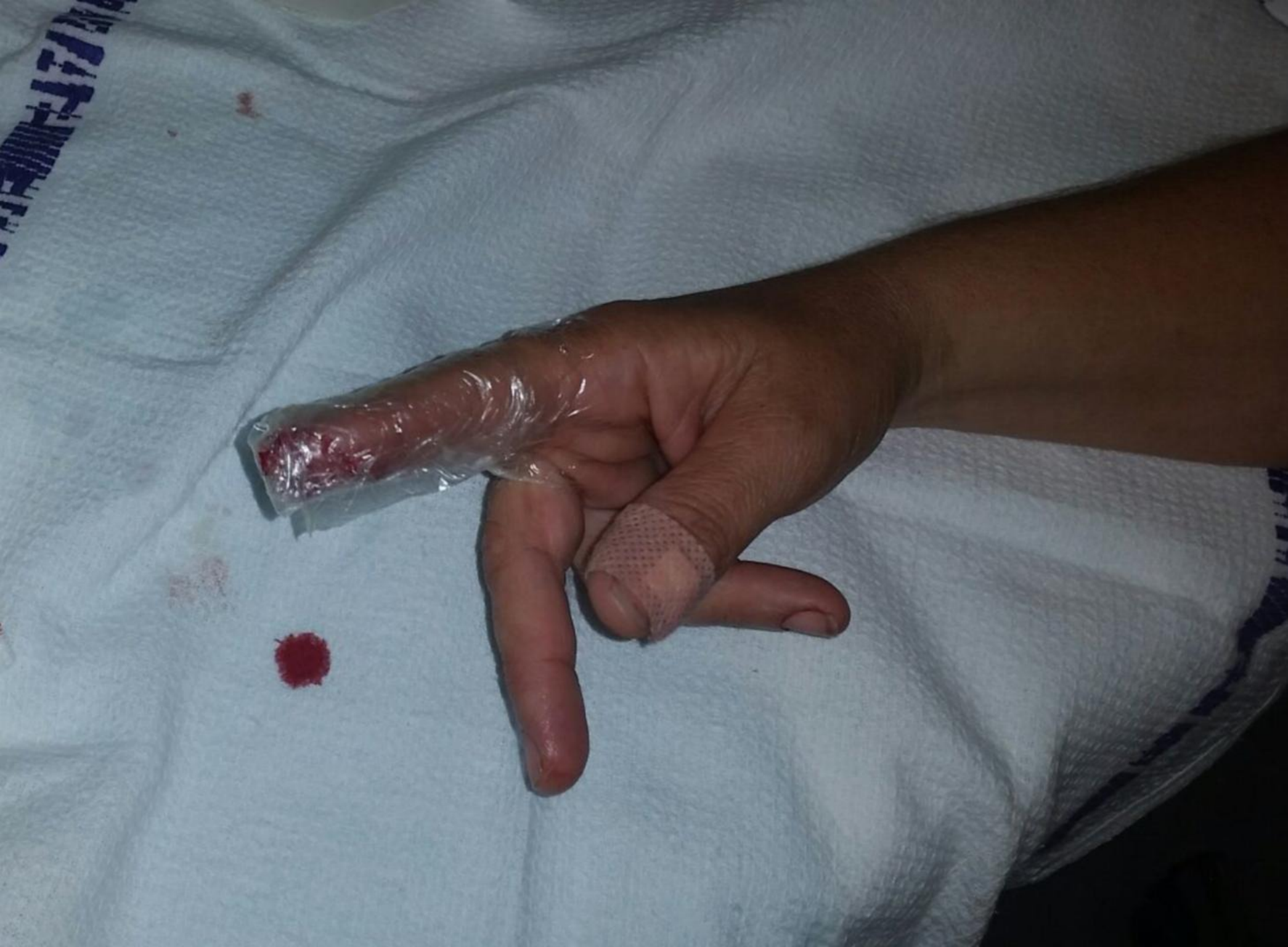Fig. 5. Male, 39-year-old patient who suffered a zone 3 amputation and required 4 dressings. Appearance at D7, D21 and 4 months. The result was the same at 1 year. Weber = 12 mm, returned to work after 3 weeks, moderate cold intolerance and hook-nail deformity

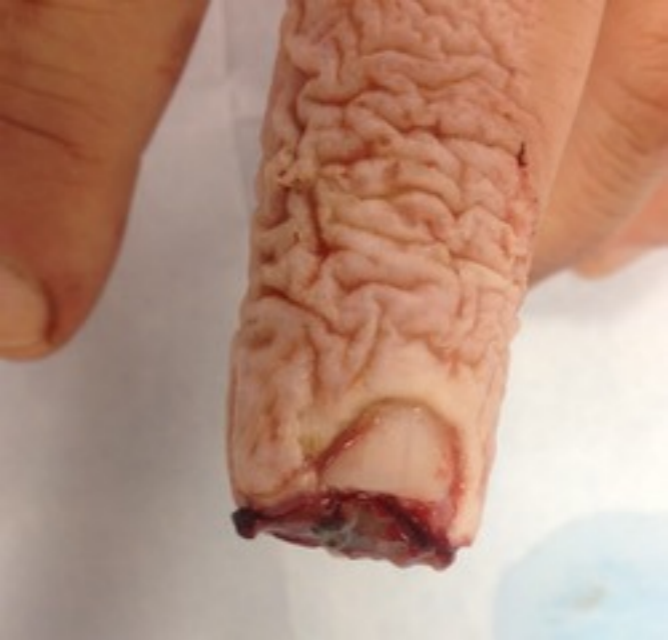Table titles

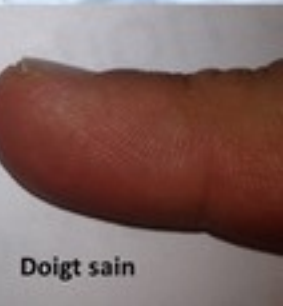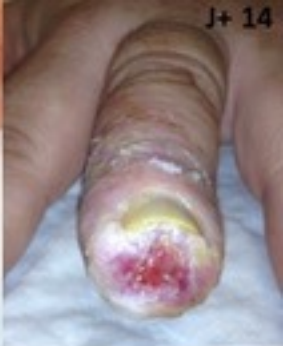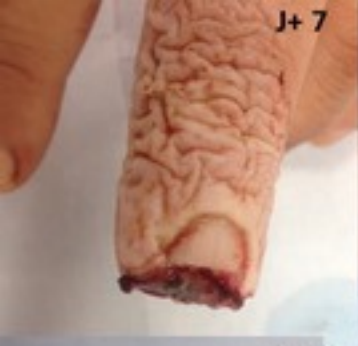Table 1. Characteristics of the patients included in our case series

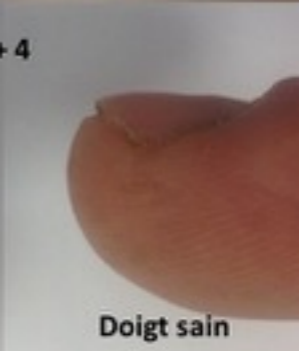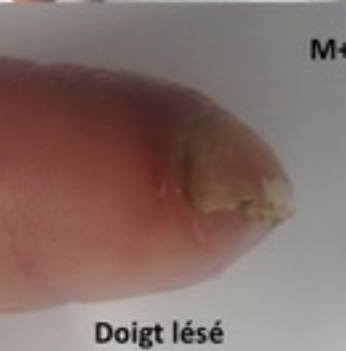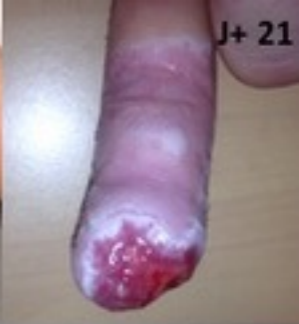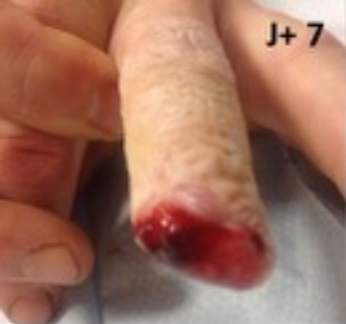Table 2. Main published studies on occlusive dressings for fingertip amputation (NR: not reported)







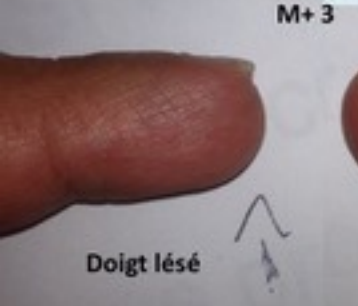



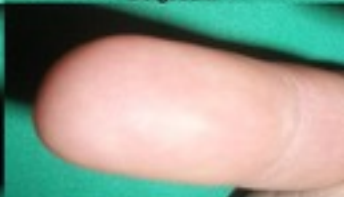
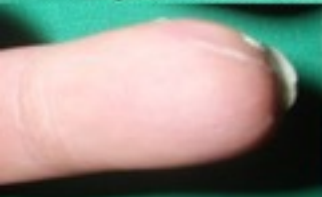
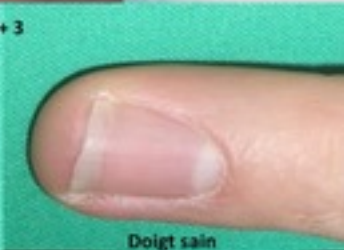
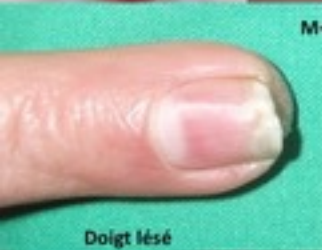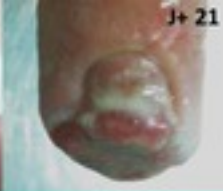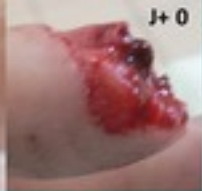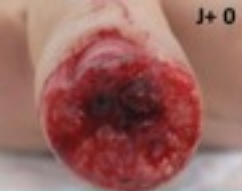Table 1. Characteristics of the patients included in our case series

Sample size	19 patients
Sex	2 women, 17 men
Age	47.3 years [22–73]
Affected finger	Thumb (2), index (2), middle (11), ring (4)
Mechanism	4 clean transection, 12 crush, 3 mutilation
Amputation zone	9 in zone 1, 6 in zone 2, 4 in zone 3

Table 2. Main published studies on occlusive dressings for fingertip amputation (NR: not reported)

Author # of cases	Amputation zone	# of dressings used	Complications	Time to healing	Results	Discomfort
Fox 1977 22 cases	Zone 1	4	None	4 weeks	Acceptable appearance	Less than 10 days
Farell 1977 21 cases	15 zone 1 6 with bone exposure / zone not listed	NR	2 stiffness 4 hypersensitivity 3 hypoesthesia	Zone 1: 15 days With bone exposure: 30 to 45 days	Attractive appearance	NR
Louis 1980 29 cases	Zone 1	3.5	4 cold intolerance + dysesthesia 3 cold intolerance only	NR	NR	1 day for 2/3 of patients
De Boer 1981 29 cases	25 zone 1 4 with bone exposure	NR	None (initial hypersensitivity)	12 days	Good	6 days
Mennen 1993 200 cases	NR	2.5	None	20 to 30 days	Nearly normal	A few days
Quell 1998 42 cases	26 zone 1 8 zone 2 8 zone 3	2 to 8	None	6 to 64 days	Good	NR
Lasserre 2010 19 cases	13 zone 1 5 zone 2 1 zone 3	3.8 (2 to 7)	None	20 days (15 to 35 days)	Excellent 30% Good 70%	NR
Hoigné 2014 19 cases	Zone 2 & 3	4	1 hypersensitivity at 6 months 1 neuroma 1 nail remainder	6.5 weeks (3 to 8 weeks)	Good with 90% fingertip reconstructed	NR