



**HAL**  
open science

## Reconsidering the central role of mucins in dry eye and ocular surface diseases

Christophe Baudouin, Maurizio Rolando, Jose M. Benitez del Castillo, Elisabeth M. Messmer, Francisco C. Figueiredo, Murat Irkec, Gysbert van Setten, Marc Labetoulle

### ► To cite this version:

Christophe Baudouin, Maurizio Rolando, Jose M. Benitez del Castillo, Elisabeth M. Messmer, Francisco C. Figueiredo, et al.. Reconsidering the central role of mucins in dry eye and ocular surface diseases. *Progress in Retinal and Eye Research*, 2019, 71, pp.68 - 87. 10.1016/j.preteyeres.2018.11.007 . hal-03487666

**HAL Id: hal-03487666**

**<https://hal.science/hal-03487666v1>**

Submitted on 20 Jul 2022

**HAL** is a multi-disciplinary open access archive for the deposit and dissemination of scientific research documents, whether they are published or not. The documents may come from teaching and research institutions in France or abroad, or from public or private research centers.

L'archive ouverte pluridisciplinaire **HAL**, est destinée au dépôt et à la diffusion de documents scientifiques de niveau recherche, publiés ou non, émanant des établissements d'enseignement et de recherche français ou étrangers, des laboratoires publics ou privés.



Distributed under a Creative Commons Attribution - NonCommercial 4.0 International License

## **Reconsidering the central role of mucins in dry eye and ocular surface diseases**

Christophe Baudouin,<sup>1</sup> Maurizio Rolando,<sup>2</sup> Jose M. Benitez Del Castillo,<sup>3</sup> Elisabeth M. Messmer,<sup>4</sup>  
Francisco C. Figueiredo,<sup>5</sup> Murat Irkeç,<sup>6</sup> Gysbert Van Setten,<sup>7</sup> Marc Labetoulle,<sup>8</sup>

1. Centre Hospitalier National d'Ophtalmologie des Quinze-Vingts, Paris, and University Versailles Saint Quentin en Yvelines, Paris, France
2. Ocular Surface & Dry Eye Center, ISPRE Ophthalmics, Genoa, Italy
3. University Complutense, Hospital Clinico San Carlos, Clinica Rementeria, Madrid, Spain
4. Department of Ophthalmology, Ludwig-Maximilians-University, Munich, Germany
5. Department of Ophthalmology, Royal Victoria Infirmary and Institute of Genetic Medicine, Newcastle University, Newcastle Upon Tyne, UK
6. Department of Ophthalmology, Hacettepe Faculty of Medicine, Ankara, Turkey
7. St. Eriks Eye Hospital, Stockholm, Sweden
8. Hôpital Bicêtre, APHP, South Paris University, Ophthalmology, Le Kremlin-Bicêtre, France

### **Corresponding author:**

Christophe Baudouin, MD, PhD, Quinze-Vingts National Ophthalmology Hospital, 28 rue de Charenton 75012 Paris, France

[cbaudouin@15-20.fr](mailto:cbaudouin@15-20.fr)

### **Financial disclosure:**

Christophe Baudouin: Consulting and/or research grants from Alcon, Allergan, Dompe, Horus Pharma, Santen and Théa. Patent shared on Eyeprim®

Maurizio Rolando: Consulting and/or research grants from Alcon-Novartis, Allergan, Bausch & Lomb, Dompé, Fidia, Medivis, OFF Italia, Santen, SHIRE, Sifi, Visufarma and Théa.

Jose M. Benitez-del-Castillo: Consulting and/or research grants from Alcon, Allergan, Angelini, Bausch & Lomb, Brill, Dompe, Santen and Théa.

Elisabeth M. Messmer: Consulting and/or research grants from Alcon, Allergan, Croma Pharma, Dompé, Farmigea, Oculus Optikgeräte, Santen, Théa, and Ursapharm

Francisco C. Figueiredo: Consulting and/or research grants from Chiesi, Dompe, Santen, Shire and Théa.

Murat Irkec: No conflict of interest.

Gysbert Van Setten: Consultant for Santen and Thea.

Marc Labetoulle: Consulting and/or research grants from Alcon, Allergan, Bausch & Lomb, Dompe, Novartis, Santen, Shire and Théa.

**TITLE:** New concepts in the diagnosis and management of choroidal metastases

## TABLE OF CONTENTS:

1. Introduction
2. Epidemiology of choroidal metastases
  - 2.1. Prevalence of ocular metastases
  - 2.2. Primary neoplasms found in choroidal metastases
  - 2.3. Other ocular localizations of metastases
3. Physiopathology of metastasis mechanism
  - 3.1. Anatomical-mechanical mechanism
  - 3.2. Seed and soil mechanism
  - 3.3. Wound-oncogene-wound-healing model
4. Diagnosis of choroidal metastases
  - 4.1. Clinical findings
    - 4.1.1. Symptoms
    - 4.1.2. Clinical examination
  - 4.2. Echography
  - 4.3. Angiography
  - 4.4. Optical coherence tomography
    - 4.4.1. Choroidal thickness estimated by optical coherence tomography
    - 4.4.2. Specific signs in optical coherence tomography
    - 4.4.3. Optical coherence tomography-angiography
  - 4.5. Neuro-imaging
5. Diagnosis work-up
  - 5.1. General work-up
  - 5.2. **Tumor** biopsy
    - 5.2.1. Rationale
    - 5.2.2. Technique
    - 5.2.3. Complications
    - 5.2.4. Guidelines
  - 5.3. Liquid biopsies
6. Multimodal treatment: the strategy
  - 6.1. Clinical context
  - 6.2. Systemic therapies
    - 6.2.1. Do systemic therapies effectively reach the choroid?
    - 6.2.2. Effective systemic treatments
      - 6.2.2.1. In lung cancer
      - 6.2.2.2. In breast cancer
      - 6.2.2.3. In other primary cancers
    - 6.2.3. Targeted therapies: can they replace local treatment?
  - 6.3. Radiotherapy for choroidal metastases
    - 6.3.1. Radiotherapy techniques
      - 6.3.1.1. Basic radiophysics and radiobiology
      - 6.3.1.2. Organs at risk in ocular radiation oncology
      - 6.3.1.3. Outcomes

- 6.3.1.4. Prescription
- 6.3.2. Stereotactic irradiation
- 6.3.3. Proton beam therapy
- 6.3.4. Plaque brachytherapy
- 6.4. Local treatment performed by ophthalmologists
  - 6.4.1. Photodynamic therapy
  - 6.4.2. Intravitreal injection
- 6.5. Decisional trees in a multimodal approach of choroidal metastases
  - 6.5.1. In cases of long life expectancy
  - 6.5.2. In cases of short life expectancy
- 7. Conclusion and future direction

## **ABSTRACT:**

The most frequent site of ocular metastasis is the choroid. **The occurrence of choroidal metastases** has increased steadily due to the longer survival of metastatic patients and the improvement of diagnostic tools. Fundoscopy, ultrasonography, and fluorescein angiography are now complemented by indocyanine green angiography and optical coherence tomography. Choroidal tumor biopsy may also confirm the metastatic nature of the tumor and help to determine the site of the primary malignancy.

There is currently no consensus on the treatment strategy. Most patients have **a** limited life expectancy and for these complex treatments are generally not recommended. However, recent advances in systemic therapy have significantly improved survival of certain patients who may benefit from an aggressive ocular approach that could preserve vision. Although external beam radiation therapy is the most widely used treatment, more advanced forms of radiotherapy that are associated with fewer side effects can be proposed in select cases.

In patients with a shorter life expectancy, **systemic therapies such as those targeting oncogenic drivers, or immunotherapy can induce a regression of the choroidal metastases, and** may be sufficient to **temporarily** decrease visual symptoms. However, they often acquire resistance to systemic treatment and ocular relapse usually requires radiotherapy for durable control. Less invasive office-based treatment, such as photodynamic therapy and intravitreal injection of anti-VEGF, may also help to preserve vision while reducing time spent in medical settings for patients in palliative care.

The aim of this review is to summarize the current knowledge on choroidal metastases, with emphasis on the most recent findings in epidemiology, pathogenesis, diagnosis and treatment.

**KEYWORDS:** Choroidal metastases; Ocular oncology; Optical coherence tomography; Radiotherapy; Tumor biopsy.



## 1. Introduction

The first case of choroidal metastasis (CM) was documented by Perls in 1872 (Perls, 1872).

Although CM have long been considered a rare entity, they are now known to be the most common intraocular malignancy (Albert et al., 1967b; Ferry and Font, 1974; Shields et al., 1997b). The increasing survival of patients with metastases and better diagnostic tools may explain these findings, yet the incidence of CM is probably even higher than reported due to underdiagnosis among patients with poor general condition. Nonetheless, CM is the first sign of a systemic malignancy in up to a third of patients with cancer (Konstantinidis et al., 2014). Given the visual consequences, the ophthalmologist should play a key role for prompt and accurate diagnosis to begin the general work-up. The methods for CM diagnosis have improved over recent decades. Fundoscopy, ultrasonography (US), and fluorescein angiography are now complemented by indocyanine green angiography (ICGA), optical coherence tomography (OCT), and, more recently, spectral domain-OCT (SD-OCT).

Histopathological diagnosis is also made possible by choroidal tumor biopsy that can confirm the nature of the tumor and help determine the site of the primary cancer.

There is still debate as to the best way to treat patients with CM. As most patients have a limited life expectancy, complex treatments are generally not recommended. Ocular treatment in a patient with multiple metastases is considered a palliative measure, and, as such, aims to save vision and prevent the development of pain in order to improve quality of life. Fulfilling this objective provides a double challenge: on the one hand, the treatment should be easy to implement and should have a low risk of complication, and on the other hand it should be effective and improve or stabilize vision, which is essential for end-of-life well-being.

However, recent advances in systemic therapies have significantly improved the survival of

metastatic patients. Such patients may benefit from an effective and durable ocular treatment that will preserve vision throughout their prolonged survival.

The present review will focus on recent findings that have enhanced the clinical understanding and the management of CM.

## 2. Epidemiology of choroidal metastases

### 2.1. Prevalence of choroidal metastases

Until the 1970s there was a belief that metastatic tumors in the uveal tissue were relatively rare but it has since been shown in several studies that these are the most common uveal malignancy; they are even more frequent than primary uveal melanoma (Albert et al., 1967a; Bloch and Gartner, 1971; Ferry and Font, 1974; Shields et al., 1997b).

The prevalence of intraocular metastases has been studied using two different methods: systematic post-mortem histopathological examination of ocular globes in cohorts of patients who died of cancer (Bloch and Gartner, 1971; Eliassi-Rad et al., 1996; Nelson et al., 1983), and complete ophthalmologic examination in cohorts of patients diagnosed with cancer (Albert et al., 1967a; Barak et al., 2007; Kreusel et al., 2002; Mewis and Young, 1982; Su et al., 2008; Wiegel et al., 1998). The prevalence of metastases estimated from post-mortem examination ranged from 4 to 10%. As expected, this was higher than the prevalence in patients living with cancer, which ranged from 2 to 7%, with the exception of Mewis et al. who reported a much higher prevalence that is likely to be related to the large proportion of symptomatic patients referred for examination (**Table 1**) (Mewis and Young, 1982).

Authors	Primary cancer	Number of patients	Number of patients with choroidal metastases
Albert et al. (Albert et al., 1967a)	All cancers	213	5 (2.3%) 10 patients with ocular metastases overall
Mewis et al. (Mewis and Young, 1982)	Breast	250	67 (26.8%)
Wiegel et al. (Wiegel et al., 1998)	Breast	120	6 (5.0%)
Kreusel et al. (Kreusel et al., 2002)	Lung	84	6 (7.1%)
Barak et al. (Barak et al., 2007)	Breast and Lung	169 patients (77 breast, 92 Lung)	2 (1.2%) Only among patients with breast cancer

Su et al. (Su et al., 2008)	Lung	8484	11 (<1%)
-----------------------------	------	------	----------

**Table 1:** Occurrence of choroidal metastases in patients with known cancer

## 2.2. Primary neoplasms associated with choroidal metastases

The most frequent primary tumor site of CM is breast, which is found in 40-53% of cases (Demirci et al., 2003; Ferry and Font, 1974; Freedman and Folk, 1987; Merrill et al., 1991; Shields et al., 1997b). The second most frequent is lung, which is found in 20-29% of cases (Ferry and Font, 1974; Freedman and Folk, 1987; Shah et al., 2014; Shields et al., 1997b).

Less frequent primary tumors include carcinomas of the gastrointestinal tract (4%), prostate (2%), kidney (2%), and skin (2%) (De Potter et al., 1993; Dieckert and Berger, 1982; Ferry and Font, 1974; Harbour et al., 1994; Shields et al., 1997b). There are also reports of tumors originating from the salivary glands (Gutmann et al., 1986; Shields et al., 2000a), thyroid (Avram et al., 2004; Besic and Luznik, 2013), testes (Ferry and Font, 1974; Freedman and Folk, 1987), female genital organs (Krohn-Hansen et al., 1999), and urothelial tract (Nabi et al., 2002). Ocular metastases from neuroendocrine tumors are rare, but given the scarcity of this cancer, ocular spread should be investigated (Eagle et al., 2000; Isidori et al., 2002; Schalenbourg et al., 2011). Sarcomas even more rarely metastasize to the choroid (Anderson et al., 2011; Feinstein et al., 2014; Jampol et al., 1973) (**Figure 1**).

CM may also follow cutaneous, mucosal, or choroidal melanomas (de Bustros et al., 1985; Font et al., 1967; Ramaesh et al., 1999). These metastases account for approximately 2-3% of ocular metastatic disease but their prevalence is probably underestimated. Post-mortem studies found ocular involvement in a third of patients who died from metastatic cutaneous melanoma (Fishman et al., 1976). In a series of 68 eyes of patients with cutaneous melanoma metastatic to the eye, Ramaesh *et al.* found 40% choroidal and 35% ciliary/iris involvement; moreover, 49% of patients had a vitreoretinal involvement, and 13% an anterior chamber involvement (Ramaesh et al., 1999).

Most patients have known systemic cancer at the time of CM diagnosis, but in 8-30% of cases the diagnosis of CM precedes that of systemic cancer. In these cases, a complete workup revealed lung cancer in 35-59% of cases and breast cancer in 7-15% of cases (Amer et al., 2004; Konstantinidis et al., 2014; Shields et al., 1997b). These findings suggest that the presence of uveal metastases in a patient without history of cancer should prompt a thorough investigation for lung and breast cancer. However, in the study reported by Shields *et al.*, the primary site was not found after initial general work-up in 51% of such patients (Shields et al., 1997b).

**Table 2** presents a comparison between CM from breast and lung cancer. It appears that clinical and epidemiological features could help identify the type of primary neoplasm. The bilateral and the multifocal involvement are more suggestive of breast cancer than of lung cancer. In cases of breast cancer, almost all are women, and **diagnosis of CM precedes that of primary tumor in about 10% of patients**. In cases of lung cancer, the majority of cases occur in men, and the primary tumor is known in about a half of cases (Demirci et al., 2003; Shah et al., 2014). The mean interval between diagnosis of primary neoplasm and CM is shorter for lung carcinomas than for breast cancers (Demirci et al., 2003; Freedman and Folk, 1987; Shah et al., 2014), as is the mean survival following CM diagnosis (Demirci et al., 2003; Freedman and Folk, 1987; Shah et al., 2014). **Most studies reporting CM of lung cancer did not differentiate between non-small cell and small cell carcinoma, although it is well known that small cell lung carcinoma preferentially affects younger patient and leads to worse prognosis than non-small cell carcinoma.**

	Breast	Lung
Mean age, range (year)	51-57	57-63
Sex, range (% Female)	99-100	22-45
Proportion of cases where diagnosis of CM preceded diagnosis of cancer, range (%)	3-15	44-59
Bilateral involvement, range (%)	24-48	17-25
Multifocal involvement, range (%)	20-48	23-24
Concurrent systemic metastases, range (%)	54-92	26-37
Mean interval between diagnosis of primary cancer and CM*, range (months)	36-65	9-31
Mean survival after diagnosis of CM, range (months)	9-22	6-12

**Table 2:** Comparison between choroidal metastases from breast (n=623 patients) and lung cancer (n=327 patients) (Demirci et al., 2003; Freedman and Folk, 1987; Konstantinidis et al., 2014; Mewis and Young, 1982; Shah et al., 2014; Shields et al., 1997b) \* When primary cancer is known at the time of ocular diagnosis. CM: choroidal metastasis

### 2.3. Other ocular localizations of metastases

Uveal metastases involves the choroid in 88-89% of cases, and less frequently the iris (9%) or ciliary body (2%); isolated involvement of the retina, optic disc, or vitreous are exceptional (Konstantinidis et al., 2014; Shields et al., 1997b).

In iris metastases, breast cancer origin is less frequent than in choroidal involvement (Demirci et al., 2003; Konstantinidis et al., 2014; Shah et al., 2014). Iris involvement is usually unilateral, with a synchronous choroidal localization in a third of cases (J. A. Shields et al., 1995). Ciliary body involvement is rare, and may be secondary to a choroidal localization. Optic disc metastases represent less than 5% of intraocular metastases and are in continuity with a juxtapapillary choroidal lesion in about 75% of cases. The other 25% are isolated optic nerve lesions in the pre- and retrolaminar portions (Shields et al., 2000b). Breast and pulmonary carcinomas are the most common causes of optic nerve metastases and their

prognosis is poor; mean survival is approximately one year (Shields et al., 2000b). Retinal metastases are rare and only a few cases have been described in the literature (Leys et al., 1990; Shields et al., 1997b; Spraul et al., 1995). Vitreous metastases are even more rare, and may occur via seeding from the retina secondary to inflammation of the internal limiting membrane (Young et al., 1979). Overall the incidence of extra-choroidal involvement is low, and this may be explained by a choroidal **preference** of metastatic cells.

### **3. Physiopathology of the metastasis mechanism**

Advances in membrane cell staining have led to a better understanding of the mechanisms involved in cancer metastasis (Kuhn et al., 2005; Paris and Sesboué, 2004), which consist of multiple steps that begin when tumor cells leave the extracellular matrix and invade the surrounding tissue. These migrate towards the blood supply and pass through thin-walled vessels to reach the systemic circulation. Tumor cells then form small aggregates that can be retained in distal microvascular beds and some of them may access the underlying tissue and interact with stromal cells which promote their growth (Langley and Fidler, 2011). With increasing metabolic needs associated with unrestrained cell division, tumor cells secrete proangiogenic factors that induce adjacent endothelial cells to form new vascular networks. The whole metastatic process is nonetheless highly inefficient, with less than 0.01% of circulating tumor cells eventually leading to secondary tumor growths (Fidler, 1970). Many studies have investigated potential limiting steps in this process and it appears that the most difficult step is initiating cell growth in secondary organs (Chambers et al., 1995). After exiting from the cell cycle, some tumor cells remain dormant in secondary organs (Barkan et al., 2010), while others are incapable of triggering the angiogenic switch necessary for tumor expansion (Hedley and Chambers, 2009). This complex series of interactions between metastatic cells and their target organ will determine whether metastatic growth occurs in a given organ.

There are two major theories attempting to explain the preferential target organ, and these are detailed below.

#### **3.1. Anatomical-mechanical mechanism**

The first mechanism suggests an important role of vascular and lymphatic drainage from the site of the primary tumor (Ewing, 1928). According to this hypothesis, tumor cells follow the



circulatory drainage from the primary tumor and are retained non-specifically in the capillary bed of the first organ **encountered**. This is supported by the higher frequency of metastases in the first organ “downstream” of the primary tumor. The typical example is liver metastases of colorectal tumors that drain through the portal vein directly into the liver (Bierman et al., 1951).

More specifically for CM, Duke-Elder and Perkins were the first to hypothesize that the short posterior ciliary arteries are the preferable route for embolic cells (Duke-Elder and Perkins, 1966). This would explain why the choroid is the most frequently involved ocular site. Ferry and Font then speculated that the abundant supply of posterior ciliary arteries to the posterior choroid is one of the causes of the predominant post-equatorial location of metastases in the choroid (Ferry and Font, 1974). This may explain the greater involvement of the choroid than the iris or ciliary body (Shields et al., 1997b). Moreover, the metastatic cells do not have to cross the blood-retinal barrier to reach the choroid, potentially explaining the low rate of retinal involvement.

The laterality of CM has been discussed by several authors. In some studies, the left eye was more frequently involved (De Ocampo and Espiritu, 1961; Jensen, 1970; Singh et al., 2012), and it has been proposed that this is related to the more direct path to the eye provided by the left common carotid that originates from the aorta. However, other studies found CM more frequently in the right eye (Amer et al., 2004; Goldberg et al., 1990; Kreusel et al., 2008) and large studies found no particular difference in laterality (Freedman and Folk, 1987; Konstantinidis et al., 2014; Shields et al., 1997b).

### **3.2. Seed and soil mechanism**

It is well known that breast metastases have particular organ preference. In the “seed and soil” theory proposed by Paget, metastatic growth does not occur randomly but is due to appropriate tumor cells (“seed”) needing suitable microenvironment (“soil”) to grow (Paget, 1889). This theory, **partially based on the work of Fuchs on emboli from uveal melanoma (Fuchs, 1882)**, suggests that metastases grow only if the seed is implanted in its suitable soil. Paget proposes that the microenvironment plays the most important role in regulating the growth of metastases. This concept is supported by multiple experimental studies in which metastatic cells were grafted into different target organs, showing good correlation between *in vitro* and *in vivo* organ preference (Auerbach et al., 1987; Greene and Harvey, 1964; Kinsey, 1960; Schackert and Fidler, 1988).

Blood flow through a given organ is an important factor in the “seeding” process, allowing a greater number of cells to be delivered in a given time, or more efficient “seeding”. Weiss proposed to quantify and compare the ability of different organs to promote metastatic growth depending on their blood flow. He developed the metastatic efficiency index (MEI), which is defined as the ratio between incidence of metastases in an organ and the organ’s blood flow (Weiss, 1992):

$$MEI = \frac{\% \text{ involvement of organ}}{\text{Blood flow of organ (ml/min)}}$$

Thus, high MEI indicates “fertile” seed and soil interactions, whereas low MEI indicates “hostile” seed and soil interactions. If the frequency of metastases in an organ is high compared to its blood flow (high MEI), there may be strong seed and soil interaction, indicating a good match between tumor type and target organ. On the other hand, a highly-vascularized organ with a low frequency of metastases (low MEI) could be explained by weak seed and soil interaction. (Weiss, 1992).

The choroid is one of the most vascularized tissues in the body, and although only 0.013% of cardiac output is directed to the eye (approximately 0.6-0.8 ml per minute), 80-85% of this flow is dedicated to the choroid, (Alm et al., 1973; Langham and Kramer, 1990). According to Weiss, the choroid has the highest MEI of any site in the body with a choroidal tissue involvement in 8-10% of metastatic cases (McCartney, 1993; Weiss, 1993). Comparison of the MEI value of the choroid for primary breast cancer (MEI = 13.5) with that of the adrenal glands (MEI = 0.347) is particularly interesting because the adrenal glands were previously considered to be the preferential target site for metastatic breast cancer; the same was found for primary lung and colorectal carcinomas (Weiss, 1993). This high affinity for the choroid may be due to specific vessel wall architecture, or interactions between adhesion molecules on the surface of the cancer cells and endothelial ligand sites (Albert et al., 1967b; McCartney, 1993). However, the “seed and soil” and the anatomical-mechanical hypothesis are not mutually exclusive, and it is possible that one or both models could be at play.

### **3.3. Wound-oncogene-wound-healing model**

A recent hypothesis, termed wound-oncogene-wound-healing (WOWH), proposes another type of metastasis which does not require cell migration (Meng et al., 2012). According to this theory, cancer is the result of an attempt of the body to heal a wound. At the site of the “abnormal” wound, oncogenes are activated, and various “wound” molecules are produced; these circulate through the body and are able to activate oncogenes in distant tissues. The cells with activated oncogenes will transform and overproliferate, leading to a metastatic foci on the remote site without primary cancer cell migration.

According to the WOWH mechanism, oncogenes are physiologically activated in some tissues, and the presence of circulatory wound molecules could stimulate this activity. This could explain why cancer cells are found in the brain despite the presence of the blood-brain

barrier, or why there is often no trail of cells on the path from the primary site to the distant metastatic sites (Nathoo et al., 2005) (**Figure 2**).

## **4. Diagnosis of choroidal metastases**

### **4.1. Clinical findings**

#### **4.1.1. Symptoms**

Blurred vision occurs in 55-70% of eyes and is often related to macular or juxtapapillary retinal involvement or due to foveal exudative retinal detachment (Konstantinidis et al., 2014; Shields et al., 1997b). Phosphenes and floaters are less frequent than in choroidal melanoma (12% of cases of CM), as are visual field defects (15.5% of cases of CM) (Konstantinidis et al., 2014; Shields et al., 1997b). Pain, outside the context of uveitis or glaucoma, is more frequently reported by patients with CM from lung cancer (12%) than breast cancer (6%) (Demirci et al., 2003; Konstantinidis et al., 2014; Shah et al., 2014). There remains 15-20% of patients who are non-symptomatic in which metastases are discovered by a routine exam or during a systemic evaluation of a generalized cancer (Demirci et al., 2003; Konstantinidis et al., 2014; Konstantinidis and Damato, 2017).

#### **4.1.2. Clinical examination**

CM generally appear as creamy white or pale yellow masses associated with subretinal fluid (SRF). Their appearance can be either flat or plateau shaped, but there are rare descriptions of CM that are mushroom shaped as result of Bruch's membrane rupture (Konstantinidis et al., 2014). An orange color can be seen in metastases that originate from carcinoid tumors (Harbour et al., 1994), renal cell (Freedman and Folk, 1987; Haimovici et al., 1997; Kindermann et al., 1981), or thyroid carcinomas (Ferry and Font, 1974; Freedman and Folk, 1987; Harbour et al., 1994) (**Figure 3**). A dark-brown color can be seen in case of CM from melanoma (cutaneous, mucosal, or uveal), which can appear clinically similar to primary choroidal melanoma (de Bustros et al., 1985; Font et al., 1967; Ramaesh et al., 1999) although they are more frequently multifocal with a faster growth pattern. Some CM have orange

lipofuscin pigment at the surface, mimicking choroidal melanoma, or dark pigment patches resembling “leopard skin” (Shields et al., 1997b) (**Figure 4**).

The most common associated feature of CM is SRF, which is observed in 28-73% of patients (Konstantinidis et al., 2014; Shields et al., 1997b). **This fluid, located between photoreceptor outer segments and retinal pigment epithelium (RPE), is preferentially perilesional or positional.**

Bilateral (15-50% of cases), multifocal (mean number of foci ranges from 1.4 to 1.6), and diffuse forms are more commonly associated with breast cancer (Demirci et al., 2003; Jardel et al., 2014; Konstantinidis et al., 2014; Maor et al., 1977; Mewis and Young, 1982; Röttinger et al., 1976; Rudoler et al., 1997b; Shields et al., 1997b) (**Figure 5**). Most CM are posterior to the equator (80%) (Shields et al., 1997b) and it has been reported that up to 40% are located in the macular region (Konstantinidis et al., 2014). The mean size of CM is 9 mm at the base and 3 mm in thickness, although thicker tumors can be found (Shields et al., 1997b) (**Figure 6**).

#### **4.2. Echography**

The clinical appearance of CM and amelanotic tumors (**for instance amelanotic melanoma or hemangioma**) is sometimes similar. In these cases, US is required to evaluate tumor reflectivity, internal structure, and degree of vascularization. US enables localization of the intraocular mass, estimation of its size, and characterization of its tissue reflectivity. It is a useful exam for measuring tumor dimensions, although the lateral margins of CM are frequently poorly defined (Konstantinidis and Damato, 2017). Sequential measurement of thickness is also important in the follow-up of patients and to assess treatment response.

The US features of CM are characterized by a flat or a slightly dome-shaped mass with a medium-to-high non-homogeneous reflectivity, unlike choroidal melanomas that are more frequently dome-shaped with a low-to-medium homogeneous reflectivity (Sobottka et al., 1998; Verbeek et al., 1994). **The typical melanoma A-scan ultrasonography shows high amplitude initial echoes with a low amplitude internal reflection compared to the moderate amplitude of spike in case of CM (Figure 7).**

Moreover, CM are often multilobular with an irregular surface (Sobottka et al., 1998). Exudative peritumoral or gravitational retinal detachment can be seen (Perri et al., 1992; Verbeek et al., 1994), with rare choroidal detachment (Sneed et al., 1991). The differences in US characteristics between CM and choroidal melanoma are explained by the histoarchitecture of the tumor. For example, CM from the breast has solid epithelial nests or glandular structures, which act as echo-producing interfaces, resulting in high reflectivity and an irregular internal structure in US (Perri et al., 1992; Verbeek et al., 1994). Melanomas, however, are dense cellular masses of low-to-moderate vascularization with only a few necrotic areas, thus containing few echo producing interfaces. As a result, these tumors are of low-to-medium reflectivity with a regular internal structure (Fuller et al., 1979; Goldberg and Hodes, 1977; Sobottka et al., 1998; Verbeek et al., 1994).

The growth pattern of CM differs to that of melanomas. While metastases appear to infiltrate diffusely the normal choroidal tissue, melanomas are tumors that grow slowly and usually expand through an intact Bruch membrane (Coleman et al., 1974; Ferry and Font, 1974; Sobottka et al., 1998). They grow in a nodular configuration, thickening the choroid, and progression ultimately leads to the rupture of Bruch's membrane, giving the classical mushroom shape (Coleman et al., 1974; Goldberg and Hodes, 1977; Sobottka et al., 1998).

This difference in growth pattern has been confirmed by US. Furthermore, CM are found as flat tumors with a large infiltration of the choroid that give an irregular shape in US (Perri et al., 1992). Conversely, choroidal melanoma has a higher mean tumor thickness, giving it a higher height to base ratio (HBR: 0.6) than metastases (HBR: 0.18) (Coleman et al., 1974; Sobottka et al., 1998). HBR determined by US potentially enables the discrimination of choroidal melanoma from CM (**Figure 8**).

Choroidal excavation is created by the difference in reflectivity between the abnormal tissue that replaces the choroid and the underlying normal choroid. **About two-thirds of melanoma lesions are associated with choroidal excavation, while it is found in only up to a fifth of CM.** (Coleman et al., 1974; Fuller et al., 1979; Sobottka et al., 1998; Verbeek et al., 1994).

**Choroidal hemangiomas are also associated with choroidal excavation in about a fifth of cases** (Verbeek et al., 1994).

As the resolution of US is about 50-200  $\mu\text{m}$  (Webb, 1988), it is more valuable as tumor thickness increases, and is thus mandatory for a precise measurement of large tumors.

However, the differentiation between small tumor entities can be challenging, as they could appear similar clinically; in such cases SD-OCT may help as its resolution is about 5  $\mu\text{m}$  (Leung et al., 2008) (see section 4.4).

Another application of US associated with Doppler technology is color flow mapping that can display blood flow on the background of the US image (Belden et al., 1995). Quantitative parameters do not seem useful to determine tumor type and their diagnostic value remains unclear at this time (Neudorfer et al., 2011; Wolff-Korman et al., 1992). Qualitative parameters seem to be more useful to differentiate choroidal melanomas from CM. Vascular features, such as hypovascularity, with a dominant centrally located vessel with blood flow is



typically associated with choroidal melanoma, whereas hypervascularity with lack of dominant vessel is typically associated with CM. Neudorfer et al. have described this ‘central pattern’ of blood flow in melanoma, contrasting with the ‘peripheral pattern’ in metastasis (Neudorfer et al., 2011).

### **4.3. Angiography**

Fluorescein angiography (FA) is generally not decisive for the diagnosis of CM (Meyer and Augsburger, 1999) because almost all choroidal tumors have the same angiographic features: usually hypofluorescent in the early phase and heterogeneously hyperfluorescent in the late phase. In some cases, pinpoint and leakage areas are seen on the mass (Konstantinidis and Damato, 2017) (**Figure 9**).

Conversely to FA, ICGA helps in the differential diagnosis of choroidal tumors. CM are usually defined as hypofluorescent at all phases on an underlying isofluorescent background (C. L. Shields et al., 1995a), and the “double circulation” pattern, first described in choroidal melanoma by Augsburger, is generally not found in CM (Augsburger et al., 1984; Konstantinidis and Damato, 2017). Furthermore, due to better visualization of the choroid, ICGA generally shows a larger area of choroidal involvement of the metastases than does clinical examination or FA (**Figure 10**).

Blue light fundus autofluorescence shows a heterogeneous pattern with areas of hypo and hyper-autofluorescence (Ishida et al., 2009; Natesh et al., 2010). This exam detects lipofuscin in the RPE, which is disturbed in cases of RPE alterations. This pattern is also found in hemangioma or choroidal melanoma.

### **4.4. Optical coherence tomography**

The small size and posterior location of most CM (Shields et al., 1997b) make these tumors ideal candidates for investigation using OCT. Anatomical features on SD-OCT, enhanced depth imaging (EDI)-OCT, and OCT-angiography (OCTA) can help identify the type of choroidal tumor, and are most useful for the follow-up of the tumor aspect, size, and retinal consequences.

#### **4.4.1. Choroidal thickness estimated by optical coherence tomography**

Time domain OCT was limited for the exploration of choroidal structures, including CM (Arevalo et al., 2005). SD-OCT with EDI, and more recently swept-source OCT, have improved our understanding of the choroid and provided detailed information about the morphological features of choroidal tumors (Demirci et al., 2014; Ferrara et al., 2016; Ishida et al., 2017). In EDI-OCT, CM has a low internal optical reflectivity, with an enlarged suprachoroidal space (Cennamo et al., 2017). The internal reflectivity can increase after treatment.

EDI-OCT is also more sensitive for the detection of very small CM before they are clinically visible (Al-Dahmash et al., 2014; Torres et al., 2011; Witkin et al., 2012) and it is estimated that 20% of CM are visible only on EDI-OCT (Demirci et al., 2014). For instance, in a series of 31 eyes with CM, tumors as small as 550  $\mu\text{m}$  were imaged using EDI-OCT but were not readily identified by US or ophthalmoscopy; they were located in the outer choroid, with a loss of large choroidal vessels (Al-Dahmash et al., 2014).

Although some lesions are visible both in US and EDI-OCT, US overestimates thickness by 55-133% according to tumor size (Al-Dahmash et al., 2014; Demirci et al., 2014; Shields et al., 2012) and the mean difference in tumor thickness between the two modalities was found to be 536  $\mu\text{m}$  (Demirci et al., 2014). This difference is explained by the greater axial resolution of EDI-OCT (Webb, 1988) compared to US (Leung et al., 2008) that allows a more

precise placement of calipers with respect to surrounding ocular structures, and which is most useful for very small choroidal lesions (**Figure 11**).

#### 4.4.2. Specific signs in optical coherence tomography

In addition to tumor thickness, OCT allows to visualize specific patterns associated with CM. The most noticeable feature is the irregular or “lumpy bumpy” anterior surface of the lesion, despite an apparently smooth surface on US (Al-Dahmash et al., 2014). This aspect is different from the smooth “mound” of nevus or the smooth “dome” of melanoma, and can help identify the type of choroidal tumor (**Table 3 and Figure 12**).

	<b>OCT features</b>
Choroidal nevus	Smooth mound shape
Small melanoma	Dome shape
Choroidal metastasis	Lumpy bumpy
Choroidal osteoma	Lamellar shape
Choroidal hemangioma	Abrupt smooth dome-shape

**Table 3:** Optical coherence tomography (OCT) features of the anterior surface of various choroidal tumors (according to (Al-Dahmash et al., 2014)).

Another sign frequently associated with CM is SRF. This is found in 67-95% of cases, mostly with hyper-reflective dots within the SRF that are known as speckles (Al-Dahmash et al., 2014; Demirci et al., 2014; Vishnevskia-Dai et al., 2016). These dots may be shed photoreceptor outer segments in longstanding SRF overlying CM (Demirci et al., 2014). The optical density or substance reflectivity of the SRF can also be measured by OCT, and can be indicative of the cause of SRF (Baek and Park, 2015; Neudorfer et al., 2012) as the optical density ratio of SRF was found to be significantly lower in CM than in melanoma (Leshno et al., 2017). This suggests that the composition of the SRF, mainly its protein content, is different between tumor types. As the composition may change over time, one can assume that fluid detected earlier would have a lower protein concentration and a lower optical density than fluid that is detected later during disease progression. Because CM are usually in

the posterior pole, they become symptomatic and are evaluated by OCT earlier than choroidal melanoma. This may explain why the SRF has a low optical density at time of evaluation. Conversely, choroidal melanoma **can be** peripheral and asymptomatic for a long time, **and therefore imaging may occur after a** longer duration of SRF secretion, when it has a higher optical density. Another explanation could be the difference in the vascular properties of the tumors. For instance, CM have been shown to be more hypervascularized than choroidal melanoma (Neudorfer et al., 2011) and a higher vascular permeability may affect the composition of the SRF and cause the lower optical density observed in metastasis. Other OCT features of metastatic tumors include shaggy photoreceptors, alteration of the ellipsoid zone, RPE changes (atrophy or hyperplasia), and choriocapillaris compression (Demirci et al., 2014) (**Table 4 and Figure 13**). Despite the variety of described OCT features in CM, we did not identify any difference in features according to the type of primary cancer.

OCT is also useful in the follow-up of choroidal lesions after therapy, especially to monitor changes in thickness, quantity of SRF, shaggy photoreceptor appearance and reflectivity, which can confirm the anatomical effectiveness of therapy. As mentioned earlier, the internal optical reflectivity of the tumor increases as the metastatic tumor becomes inactive, consistent with an increase in fibrotic tissue content (Demirci et al., 2014).

	<b>Frequency, range (%)</b>
Lumpy bumpy	64-81
Shaggy photoreceptors	79
Subretinal fluid	67-95
Alteration of ellipsoid zone	27-57
Low internal reflectivity	71
RPE changes (atrophy, hyperplasia)	43-80
Choriocapillaris compression	93-100

**Table 4:** Optical coherence tomography features of choroidal metastasis (according to (Al-Dahmash et al., 2014; Demirci et al., 2014; Vishnevskia-Dai et al., 2016)). RPE: retinal pigment epithelium.

#### **4.4.3. Optical coherence tomography-angiography**

OCT angiography (OCTA) is a non-invasive, high speed based imaging technique enabling visualization of blood flow in the retina and choroid through comparison of successive A-scans (Borrelli et al., 2018; Spaide et al., 2018). OCTA may help differentiate tumors as in CM there is a lack of flow at the level of the lesion and absence of pathological blood flow in the outer retinal layer, whereas in choroidal melanoma, hemangioma, and osteoma there may be a dense, irregular vascular network inside the tumor and even increased flow in the outer nuclear layer (Cennamo et al., 2017). This seems contradictory to US findings of hypervascularity in CM (Neudorfer et al., 2011), but the lack of flow detection may be explained by the masking effect of the RPE on the underlying tumor neovascularization, or by a fringe washout due to higher flow speed inside the tumor (Chen et al., 2016; Spaide et al., 2015) (**Figure 14**).

#### **4.5. Neuro-imaging: CT-scan and MRI**

Computed tomography (CT) is rarely useful in cases of ocular tumors. Magnetic resonance imaging (MRI) shows a well-defined choroidal mass that appears isointense on T1-weighted images and hypointense on T2-weighted images (Peyster et al., 1988). **The resolution of conventional MRI is limited when it comes to the eye, primarily because of motion artefacts due to blinking and gaze changes, but also because of field inhomogeneity at the air-cornea interface. Additionally, the use of head coils for imaging the eye produces a low signal-to-noise ratio (Atlas et al., 1987; Bilaniuk et al., 1985). High resolution MRI (HRMRI) limits motion artefacts by using conjugate gaze and cued blinking. Interface artefacts are limited by applying a wetted gauze on the eyelids (Bert et al., 2006). Surface coils and high magnetic fields (3 and 7 Tesla) also result in a better signal-to-noise ratio (Beenakker et al., 2013). Several HRMRI studies have been conducted on choroidal melanoma and retinoblastoma. In melanoma, both 1.5 Tesla and 7 Tesla HRMRI better reveal internal structure and scleral**

invasion than conventional MRI (Beenakker et al., 2013; Lemke et al., 1998; Lindner et al., 2015). In retinoblastoma, both 1.5 and 3 Tesla HRMRI are established as predictors of metastatic risk, based on scleral, choroidal, and optic nerve invasion (de Jong et al., 2015; Sirin et al., 2015). To date there are no published in vivo HRMRI patient studies on CM, but it is reasonable to believe that it would be useful when the tumor is not visible because of intravitreal or subretinal hemorrhage, or complete retinal detachment. As resolution increases, HRMRI may give insight on the histological type of the metastasis and help differentiate CM from a primary ocular tumor. Recently, a novel MRI modality, MR microscopy (MRM), was assessed ex vivo for the diagnosis of intraocular lesions. MRM provides resolution in the sub-millimeter range with an excellent signal-to-noise ratio, and has allowed the visualization of tumor ultrastructure with good correlation to histology. This could help differentiate CM from other tumors, but also identify the type of primary cancer (Falke et al., 2013).

## **5. Diagnosis work-up**

Up to a third of patients presenting with intraocular metastases have no known history of cancer (Konstantinidis et al., 2014; Shields et al., 1997b). It is therefore important to manage systemic work-up to identify the primary site of neoplasia. If no primary tumor has been found, biopsy for **cytological or histopathological analysis** should be considered. Unlike most organs where a biopsy is readily accessible, retrieving a biopsy from a small choroidal lesion requires a skilled and experienced surgeon and carries a risk of intraocular injury. Biopsy is further limited by the necessity of a qualified **pathologist** and often insufficient or inadequate retrieved material (Cohen et al., 2001). These limitations highlight the need for a non-invasive ancillary diagnostic test that will help characterize intraocular lesions.

### **5.1. General work-up**

The diagnostic work-up depends on whether there is a history of cancer and whether it is already generalized when CM is diagnosed. If the CM is very large (and enucleation is performed), the work-up is usually guided by the histological findings. If there is no history of primary tumor, a thorough medical history (including gender, smoking habit, previous breast cancer screening) and physical examination is required and these will guide the ophthalmologist in the search for primary tumor. In cases with known metastatic dissemination, past medical history is usually sufficient to guide ocular and general treatment. In cases where there is a history of cancer but no history of metastases, diagnostic work-up should be specific to the suspected cancer type; it may include mammograms, positron emission tomography (PET)-CT, etc.

### **5.2. Tumor biopsy**

#### **5.2.1. Rationale**

Histological proof of cancer is generally required by oncologists to guide treatment (Chin et al., 2007; Overgaard, 1996). The eye is, however, an exception to this rule, as intraocular tissues are not readily accessible for biopsy, and it is accepted to start treatment without cytological or histological confirmation in case of uveal melanoma (Foulds, 1992; Harbour, 2007). Tumor biopsy is nowadays widely used for the prognostication in choroidal melanoma and can help the oncologist determine the risk of metastasis (Damato, 2018; Damato et al., 2011). However, in CM, the aim is quite different because biopsy is mostly indicated to determine the type of primary tumor when it is still unknown after a thorough systemic work-up (Konstantinidis et al., 2014).

Although a tissue sample will support the diagnosis, obtaining it is not without risk for the vision or life of the patient, and the risk-benefit ratio must be considered. It is thought that intraocular biopsy may increase the risk of dissemination of malignant cells, and presents a risk of severe ocular complications, which may explain its limited use (Eide and Walaas, 2009). However, intraocular tumors are generally accessible to sampling using fine needle aspiration biopsy (FNAB) transsclerally or transvitreally (Augsburger et al., 2015; McCannel et al., 2012; Sellam et al., 2016; Singh et al., 2016). This technique does not consist of an actual biopsy, but rather cytological tissue sampling. The aim is to confirm the metastatic nature of the tumor, and to help determine the likely site of primary malignancy in order to plan imaging and complete workup accordingly (Eide and Walaas, 2009; Shields et al., 1993). One of the limitations of FNAB is the risk of inadequate sampling experience resulting in false negatives, which must be considered when dealing with small tumors. The of the cytopathologist is important to reduce this risk, as decisions need to be made on a small number of cells. Optimally, the cytologist should be present in the operating room to ensure that an adequate amount of biopsy material is obtained (Konstantinidis et al., 2014).



Another technique, more recently described, consists of an intraocular biopsy using the vitreous cutter or special forceps penetrating directly into the tumor and is highly effective in obtaining a tissue sample (Akgul et al., 2011; Bagger et al., 2013; Konstantinidis et al., 2014; Sen et al., 2006; Seregard et al., 2013). A transscleral incisional biopsy with forceps, recently described by Angi et al. in cases of choroidal melanomas, could yield more successful histological analysis (Angi et al., 2017).

Ocular tumor biopsy is most useful in patients with atypical clinical findings, when it is challenging to differentiate between CM and primary choroidal melanoma, or when systemic investigation has failed to identify primary malignancy. In our opinion, any discordance between non-invasive tests should warrant ocular tumor biopsy to confirm the histological nature of the tumor. For instance, in a group of patients with intraocular masses, major diagnostic uncertainty was reported in 2.4% of cases (159 of 6500 patients evaluated) (Shields et al., 1993). In these patients, a biopsy was required in order to establish the diagnosis and to initiate the appropriate treatment. FNAB yielded adequate cytological material in 88% of cases. Furthermore, when no primary tumor is identified by systemic workup, tissue sampling has been shown to successfully confirm the metastatic nature of the lesion and identify its origin in most cases (Akgul et al., 2011; Konstantinidis et al., 2014; Sen et al., 2006).

In addition to histological confirmation, tumor biopsy can also help to identify specific molecular alterations, some of which may be targeted by so-called targeted therapies. For example, in breast cancer, immunohistochemical evaluation can identify patients with HER2/neu-positive disease, which is associated with a higher risk of recurrence, and may benefit from adjuvant anti-HER2/neu-directed therapy (Wolff et al., 2007). Furthermore, histopathological evaluation can identify estrogen and/or progesterone receptor-positive

tumor cells, predicting benefit from endocrine therapy (Hammond et al., 2010). In non-small cell lung cancer, deoxyribose nucleic acid (DNA) can be extracted from the residual biopsy material and assessed for the presence of epidermal growth factor receptor (EGFR) mutations. When these are present, targeted therapy with EGFR-tyrosine kinase inhibitors, such as gefitinib and erlotinib, has been shown to increase survival in lung carcinoma patients (see section 6.2) (Lin and Yang, 2011; Rosell et al., 2012). *KRAS* mutation can also be tested, especially in cases where colorectal cancer is suspected (*KRAS* oncogene is mutated in 35-45% of colorectal cancer and is a biomarker of poor response to anti-EGFR therapy (Karapetis et al., 2008; Van Cutsem et al., 2009).

### **5.2.2. Technique**

FNAB of choroidal tumors takes practice, and sometimes several attempts before yielding useful material (McCannel, 2013). Depending on the tumor site, it may be performed by transscleral or transvitreal approach. The transscleral approach, which is easier and more widespread, is indicated for pre-equatorial lesions, and for large lesions away from the posterior pole (lesions > 10 mm at the base, > 3mm in height, and with the anterior border halfway between the equator and the optic disc) (Eide and Walaas, 2009). It involves placing the needle through the sclera and into the tumor after precise localization by transillumination and indirect ophthalmoscopy if necessary. This procedure can be performed at the same time as the placement of brachytherapy plaques or tantalum fiducials (for proton therapy). Small lesions with a posterior location, especially if they are thin, are more safely biopsied with a transvitreal approach (Shields et al., 2007a, 2007b). The transvitreal FNAB is performed by inserting a needle through a sclerotomy opposite the tumor, which is visualized directly with a wide-field lens. The needle is then inserted transretinally into the tumor and material aspirated (Augsburger et al., 2015; McCannel et al., 2012; Sellam et al., 2016; Singh et al., 2016).

The biggest challenge with FNAB is to obtain sufficient material for analysis. In general, the yield is greater for large tumors, but they may contain areas of necrotic material which is not useful for the pathologist. Several passes may be necessary in order to obtain sufficient material (McCannel, 2013).

A variation of transvitreal needle biopsy consists of aspirating inside the tumor using a 25 gauge vitrector, with (Bechrakis et al., 2002) or without prior vitrectomy (Bagger et al., 2013; Konstantinidis et al., 2014; Sen et al., 2006). This method was shown to yield larger tissue samples with a 92% chance of successful diagnosis (Sen et al., 2006). Another variation of this technique is to **use biopsy forceps after small incision at the chosen biopsy site (Akgul et al., 2011; Seregard et al., 2013).**

**Transvitreal choroidal biopsies for tissue sampling have become more common over recent years due to the improvement of surgical techniques such as sutureless 25-gauge vitrectomy that reduces surgical trauma.**

### **5.2.3. Complications**

It is accepted in oncology that a tumor biopsy carries a risk of tumor cell dissemination, increased rate of local recurrence, and increased risk of metastatic development. However, this has not been reported for biopsy of CM or choroidal melanoma. To the best of our knowledge there is no report of secondary tumor implantation at an eye wall entry site used for biopsy, nor any report of enucleation secondary to biopsy complication. Other local complications may include intravitreal hemorrhage or retinal detachment. For instance, in a series of FNAB reported by Augsburger *et al.*, about 60% of patients undergoing FNAB had any-grade vitreous hemorrhage (Augsburger et al., 2015). However, in a recent series reported by Grixti et al., only 20/739 eyes (2.7%) that underwent choroidal tumor biopsy required vitreoretinal surgery for biopsy-related complications including persistent vitreous

hemorrhage in 14 eyes, rhegmatogenous retinal detachment in 5 eyes, and endophthalmitis in 1 eye (Grixti et al., 2014).

#### **5.2.4. Guidelines**

Tumor biopsy should only be performed when it is likely to provide a diagnosis and this is largely determined by tumor thickness, especially for FNAB. There is a strong correlation between the rate of successful diagnosis from a FNAB and the thickness of the lesions on US (< 1.9 mm: 40%; 1.9-4 mm: 90%; > 4 mm: 98%) (Cohen et al., 2001), and it is also of note that sufficient aspirate was obtained in almost two-thirds of tumors that had a thickness of 1.5-3 mm (Augsburger et al., 2002). Overall, FNAB can be expected to give useful information in lesions > 3 mm in thickness, but is unreliable in lesions thinner than 2 mm (Eide and Walaas, 2009). No thickness cut-off has been described for transvitreal biopsy using the vitreous cutter or forceps (Damato, 2018).

As a rule of thumb, it is unnecessary to perform an eye biopsy in a patient with multi-organ metastases if the primary tumor is known. If it is not known but other systemic metastases are present, the more readily accessible metastasis should be favored for biopsy. Nevertheless, the risk of ocular complications associated with biopsy should always be taken into consideration in the decision and discussed with the patient prior to the procedure.

#### **5.3. Liquid biopsies**

When cytology of the CM cannot be obtained, liquid biopsy could provide additional diagnostic clues. This emerging non-invasive diagnostic method usually consists of blood samples (saliva and urine are also possible) that are used to identify biomarkers of microscopic tumor dissemination, such as circulating cancer cells or circulating tumor DNA, and are mostly used to guide treatment and to monitor response during follow-up (Heitzer et

al., 2015). For example, a liquid biopsy was used in a patient with bilateral CM to detect both circulating thyroid transcription factor 1 (TTF1) positive cells and EGFR mutation that allowed the diagnosis of lung cancer and the treatment by anti-EGFR therapy (Bouhlef et al., 2017). Moreover, circulating tumor DNA and its mutational load has been identified as a marker of effectiveness of systemic treatments in breast cancer and may be used to switch treatment line before clinically evident disease progression (Hench et al., 2018).

## 6. Multimodal treatment: the strategy

### 6.1. Clinical context

Complex treatments are generally controversial for CM because metastatic patients are believed to have limited life expectancy and thus derive minimal benefit from the treatment of CM. One should, however, consider the broad spectrum of metastatic disease. As emphasized by Hellman and Weichselbaum, survival can vary from weeks to years according to whether patients have widely diffuse metastases or oligometastatic disease (Hellman and Weichselbaum, 1995).

One of the aims of the treatment of metastatic disease is to improve progression-free survival. This palliative approach implies a short delay of care, short and minimally invasive procedures, rapid functional results, and a low rate of treatment-induced complications. Depending on the performance status of the patient and the type of primary cancer, the progression-free survival could, however, be drastically different. **Multimodal treatment of metastatic disease is also increasingly being used to cure patients. Zacharakis et al. have recently reported a complete and durable (more than 22 months) regression of a chemoresistant metastatic breast cancer treated by specific tumor-infiltrating lymphocytes (Zacharakis et al., 2018), and overall survival in cases of breast or renal cancer after more than ten years of metastatic disease is not unusual.**

Mortality in patients with CM is correlated with the presence of synchronous metastasis in the liver or lungs (d'Abbadie et al., 2003). For instance, patients with breast cancer had survival rates of 65% at 1 year, and 24% at 5 years after diagnosis of CM (Demirci et al., 2003). In another series reported by Shah *et al.*, 1-year survival was 46% in CM patients with lung cancer (Shah et al., 2014). In light of these data, the term “metastatic patient” needs to be cautiously interpreted. Taking into account personalized prognosis allows the most appropriate treatment strategy to be chosen, which is especially true in end-stage disease as

the primary goal of the physician must remain to do no harm; it implies weighing the potential benefits of a medical intervention against the annoyance it may cause, allowing the patient to retain the highest possible quality of life.

Although it is often overlooked in oncology, loss of visual function is a major issue in patients with ocular metastases as they may quickly lose autonomy. The treatment aims to prevent or reverse visual function loss in order to improve the patient's quality of life. It can also help prevent serious psychological consequences, by avoiding enucleation for example (Demirci et al., 2003; Shah et al., 2014). While it may be challenging for ophthalmologists to make a therapeutic decision in the context of metastases, one should not wait too long as the risk of irreversible blindness is probably related to the duration and severity of tissue injuries before treatment.

The decision to pursue local therapy for CM is multidisciplinary, involving the patient, oncologist, ophthalmologist, and radiation oncologist. Important considerations include overall health, life expectancy, location and extent of intraocular lesion, visual symptoms, and patient preference. A detailed office evaluation is performed before treatment (indirect ophthalmoscopy, fundus drawing, photography, FA, ICGA, OCT, and US) to measure tumor size and evaluate whether it threatens the optic disk or fovea.

*In case of isolated CM or oligometastatic disease: a local treatment is considered upfront.* If general prognosis and performance status are relatively good, and the available therapeutic resources are not too invasive, local treatment is proposed with a good chance to retain or restore visual function. In such cases, depending on histology and ocular extent, focalized radiation techniques may be proposed, such as brachytherapy or proton therapy, or stereotactic body radiation therapy with appropriate eye tracking.

*In case of multimetastatic disease threatening survival:* life threatening metastases are treated with a combination of systemic and sometimes local treatments. The local treatment of CM is usually postponed, definitively or until overall metastatic disease is properly controlled. There are exceptions if the ocular symptoms are very intense and there is a long delay before chemotherapy (due to organizational reasons); in such cases, short palliative radiotherapy can be done in the first place.

## **6.2. Systemic therapies**

### **6.2.1. Do systemic therapies effectively reach the choroid?**

There are three ways to deliver drugs to the eyes: topical, intraocular, and systemic. Topical drugs are quickly drained away and the intravitreal bioavailability is estimated to be 0.0001-0.0004% (Maurice, 2002), and in practice this route is not used for the delivery of oncological treatments for intraocular tumors. **The intraocular administration allows the highest intravitreal or intraretinal drug concentration, as it bypasses the blood-ocular barrier (Jordán and Ruíz-Moreno, 2013) that works as a filter between the general circulation and the retina to maintain a protected micro-environment around the neuro-retina. It is composed of the blood-aqueous barrier (anterior) and the blood-retinal barrier (posterior). The latter is divided into inner blood-retinal barrier, formed by tight junctions between the retinal capillary endothelial cells, and the outer-blood retinal barrier, formed by the tight junctions between the RPE cells (Hosoya and Tomi, 2005). The retina is therefore described as a “sanctuary” protected by barriers on both sides. Similarly to the blood-brain barrier, it makes it difficult for systemic drugs to reach the retina (Del Amo et al., 2017). As for the choroid itself, the notion of sanctuary is challenged by the presence of fenestrated endothelium in the highly**



vascularized choriocapillaris. This high permeability may allow rapid entry of drugs from the blood to the extravascular choroid (Bill et al., 1980).

## **6.2.2. Effective systemic treatments**

### **6.2.2.1. In lung cancer**

Molecular targeting has led to a paradigm shift in the treatment of several cancers, and there is an increasing number of publications reporting the effectiveness of systemic treatments on CM (**Table 5**). In non-small cell lung cancer for example, specific EGFR mutations make it sensitive to tyrosine kinase inhibitors such as gefitinib or erlotinib. Anaplastic lymphoma kinase (ALK) gene rearrangement can also be targeted with specific drugs such as crizotinib. As discussed above, liquid biopsies could become sufficient to detect activated oncogenes and drug susceptibility in the near future, allowing a precise diagnosis and targeted therapy without need for an invasive biopsy (Bouhlef et al., 2017).

Yang *et al.* reviewed the literature and found only 12 published cases (between 1995-2014) in which patients received systemic chemotherapy alone (several chemotherapy regimens) instead of local therapy. At least two cases had only CM and no other distant metastasis. Eight (66.7%) of them demonstrated CM regression after treatment with survival ranging from 3 to more than 18 months after CM diagnosis. They did not detail the delay nor the duration of the response (Yang et al., 2014). **Shah et al. described 22 patients with lung cancer treated by chemotherapy alone among which regression of CM was found in 68% of cases, whereas 15 eyes managed by observation only showed regression in only 20% of cases (Shah et al., 2014).**

Study	Number of patients	Histopathological type	Systemic treatment	Outcomes Comments
George <i>et al.</i> (George et al., 2009)	1	Large cell carcinoma	Gemcitabine + carboplatin + bevacizumab	Lung and CM regression. Survived more than 5 months after the diagnosis of CM.
Singh A <i>et al.</i> (Singh et al., 2010)	1	Adenocarcinoma	Gemcitabine + cisplatin	CM regression. Survived more than 13 months after the diagnosis of CM.
Singh N <i>et al.</i> (Singh et al., 2012)	1	Adenocarcinoma	Pemetrexed + cisplatin	Lung and CM regression. Survived more than 11 months after the diagnosis of CM.
Shah <i>et al.</i> (Shah et al., 2014)	NR (22 eyes)	NR	Chemotherapy (drugs not specified)	Tumor size: Regression of tumor size: 68%, Progression of tumor size: 32%.
Inoue <i>et al.</i> (Inoue et al., 2010)	1	Adenocarcinoma	Gefitinib	Improvement of vision at 3 months. Complete response of the right CM. No follow-up after 3 months.
Daniels <i>et al.</i> (Daniels et al., 2010)	1	Adenocarcinoma	First line carboplatin + paclitaxel Then, addition of erlotinib	Progression of the CM with carboplatin + paclitaxel. Three days after addition of erlotinib, improved vision and marked tumor regression at fundus. Complete response at 3 months. No follow-up thereafter.
Chen <i>et al.</i> (Chen et al., 2011)	1	Papillary carcinoma, mutation of EGFR	Erlotinib (7 months) Then docetaxel 10 cycles	Improvement of visual acuity from 20/60 to 20/25 after 2 months of erlotinib and decrease of tumor thickness by a third. CM progression at 7 months. Whole-brain radiotherapy for intracranial metastases. Stabilization of vision 2 years after diagnosis of CM.

Shimomura <i>et al.</i> (Shimomura et al., 2013)	1	Adenocarcinoma, mutation of EGFR	Gefitinib (first-line)	Slight improvement of visual acuity but floaters and blurred vision greatly improved at 3 weeks and remained stable for 5 months. Subsequent visual loss and brain relapse not improved by second-line cisplatin + pemetrexed.
Yang <i>et al.</i> (Yang et al., 2014)	4	Adenocarcinomas, mutation of EGFR for 1 patient (bilateral CM) and no mutation for 3 patients	Pemetrexed + cisplatin (3 patients)	Regression of tumor size after 1 to 2 months Two patients died at 3 and 6 months after the diagnosis of CM, one survived more than 16 months with no recurrence of his unique CM at 6 months.
			Gefitinib (1 patient)	General and CM progression Died 3 months after the diagnosis of CM
Maskell <i>et al.</i> (Maskell et al., 2017)	1	Adenocarcinoma, mutation of EGFR	Gefitinib	Improvement of visual acuity and tumor size at 3 weeks. After 5 months, progressive general disease but CM controlled.
Cui <i>et al.</i> (Cui et al., 2017)	1	Adenocarcinoma, wild-type EGFR, EML4/ALK rearrangement	Crizotinib (second-line)  Then Second generation of anti-ALK agent	Improvement of visual acuity at 2 weeks (20/200 to 20/50) and regression of CM. Recurrence at 16 months: new CM near the initial one revealing crizotinib resistance. Improvement of vision and decrease in tumor size with second-line anti-ALK.
Rao et al. (Rao and Gragoudas, 2015)	1	Adenocarcinoma, wild-type EGFR, EML4/ALK rearrangement	Crizotinib (third-line)	Choroidal and brain metastases detected 6 months after the introduction of crizotinib. The patient died 6 months after the diagnosis of CM.
Lu <i>et al.</i> (Lu et al., 2015)	1	Adenocarcinoma, wild-type EGFR, No mutation of ALK,	6 cycles of carboplatin + pemetrexed + bevacizumab	Partial systemic response but no improvement of vision with chemotherapy.

		ROS-1 rearrangement	and maintenance (pemetrexed + bevacizumab) for a total of 1 year. Then crizotinib	General and ocular response at 12 months with crizotinib. At 3 months, tumor size decreased by 39%. Improvement of vision 3 weeks after beginning crizotinib.
Okuma <i>et al.</i> (Okuma <i>et al.</i> , 2015)	1	Non-small cell lung cancer, EML4/ALK rearrangement, PD-L1 expressed	Third-line anti PD-L1	General and ocular disease progression.
			Fourth-line alectinib	General and ocular improvement in 1 week. Vision completely recovered within 2 weeks. Partial response for more than 5 months.
Funazo <i>et al.</i> (Funazo <i>et al.</i> , 2017)	1	Adenocarcinoma wild-type EGFR, EML4/ALK translocation	Alectinib (first-line)	General disease regression, improvement of vision after 5 months. Survived more than 15 months after the diagnosis of CM.

**Table 5:** Cases of patients with CM and lung cancer treated by systemic therapy only published in the last 10 years (English language). Crizotinib and alectinib are tyrosine kinase inhibitors indicated in lung cancer with rearrangement of Echinoderm Microtubule Associated Protein-like 4 (*EML4*) and anaplastic lymphoma kinase (*ALK*) genes; erlotinib and gefitinib are anti-epidermal growth factor receptor (EGFR) drugs. Gene mutations were identified in lung tumor before administration of the specific anti-tyrosine kinases; PD-L1: programmed death ligand 1; CM: choroidal metastases; NR: not reported.

### 6.2.2.2 In breast cancer

There are fewer reported cases of breast cancer CM responding to systemic treatment, and most of these concern patients with high tumor expression of estrogen and progesterone receptors. This represents about 80% of breast cancer cases, and is associated with better systemic prognosis, but also with a higher rate of choroidal involvement (Parrozzani *et al.*, 2016). Interestingly, the majority of such cases had a good ocular response to hormonal monotherapy (**Table 6 and Figure 15**). Human epidermal growth factor receptor 2 (HER2) - positive breast cancer is prone to brain metastases; whether it is also prone to CM is less well understood. HER2 inhibitors such as trastuzumab have been a major advance in oncology,

allowing to reverse the poor prognosis associated with HER2 overexpression. HER2 mutation can be associated with high hormonal receptor (HR) expression, and in such cases a combination of targeted drugs is used. In about 17% of cases, patients have triple negative breast cancer (*i.e.* HER2, estrogenic, and progesterone receptors are not expressed) (Dent et al., 2007; Haffty et al., 2006). These are more likely to develop metastases within 5 years of diagnosis and there are fewer effective systemic drugs. Current evidence shows that triple negative and HER2-positive breast cancers have a higher rate of brain metastases, but the hormonal receptor positive cases (especially the luminal B subtype) are more likely to develop CM (Parrozzani et al., 2016).

As a decision support tool, the overall survival rates of stage IV breast cancer according to the different subtypes are as follows (data from the USA) (Cronin et al., 2018; Howlader et al., 2018). All types: 26.5% at 5 years; HR-positive and HER2-negative (mostly luminal A subtype): 35.9% at 4 years; HR-positive and HER2-positive (luminal B subtype): 45.5% at 4 years (the difference between this subtype and the HR-positive/HER2-negative is likely to be due to the effectiveness of HER2-targeted therapies); HR-negative and HER2-positive (subtype HER2-enriched): approximately 34% at 4 years; HR-negative and HER2-negative (triple negative): 11.2% at 4 years.

<b>Authors</b>	<b>Number of patients</b>	<b>Systemic treatment</b>	<b>Outcomes Comments</b>
Demirci <i>et al.</i> (Demirci et al., 2003)	85	Systemic chemotherapy and/or hormone therapy (no additional detail)	Regression of CM 65%, recurrence 11%, stability 16%, progressive CM 8 % (mean follow-up 10 months)
Wong <i>et al.</i> (Wong et al., 2004)	1	Vinorelbine + trastuzumab (multiple synchronous nodal metastases)	Resolution of visual symptoms at 1 month with confirmation by fundus ophthalmoscopy.
Cohen <i>et al.</i> (Cohen et al., 2005)	1	Tamoxifen	Complete tumor regression at 4 months.

Shome <i>et al.</i> (Shome et al., 2007)	1	Tamoxifen	Complete tumor regression at 1 year.
Venkatesh <i>et al.</i> (Venkatesh and Garg, 2007)	1	Letrozole (no other metastasis)	Improvement of vision at 2 weeks, resolution of the subretinal fluid and regression of the tumor on fundus. Complete regression at 4 weeks.
Manquez <i>et al.</i> (Manquez et al., 2006)	17	Aromatase inhibitor	10 patients had regression of both systemic and CM (fundus) over a mean 20 months of follow-up.
Papageorgiou K <i>et al.</i> (Papageorgiou et al., 2009)	1	Paclitaxel + trastuzumab	Complete response at 9 months on optical coherence tomography, stable vision (6/9). The patient was previously treated by whole brain radiotherapy (20 Gray in 5 fractions) for solitary occipital metastasis.
Cancino R <i>et al.</i> (Cancino et al., 2011)	1	Letrozole	Complete regression of CM at 3 months (the patient remained asymptomatic)
Alzouebi M <i>et al.</i> (Alzouebi et al., 2014)	1	Paclitaxel + trastuzumab (Synchronous bone, liver, lung metastases)	Regression of tumor thickness from 1.5mm to 0.4mm at 2 months; complete regression at 6 months and after 18 months. Preservation of visual acuity.

**Table 6:** Cases of patients with CM from breast cancer treated by systemic therapy only that have been published in the last 20 years (English language). Expression of human epidermal growth factor receptor 2 (HER2) or hormonal receptors was identified in the tumor before administration of trastuzumab or hormone therapy (tamoxifen and aromatase inhibitors, including letrozole) respectively. CM: choroidal metastases.

### 6.2.2.3. In other primary cancers

There are very few reports of CM from malignancies other than breast or lung cancer, and most of these were managed by external beam radiation therapy (EBRT), with or without systemic therapy. Essadi *et al.* reported a case of a CM from clear-cell renal carcinoma successfully treated by everolimus alone (an inhibitor of mammalian target of rapamycin, mTOR,) as second-line systemic treatment (the patient also had lung metastases). The patient had complete recovery of vision at 4 months and partial response as assessed by tumor size

(Essadi et al., 2017). In CM from prostate cancer, some case reports have shown the effectiveness of hormonal blockade monotherapy (Primavera et al., 2008).

It should be kept in mind that the prognosis of stage IV disease status varies greatly among the various types of cancer. For instance, in a study of 1028 patients with metastatic renal cell carcinoma, those who had no identified risk factor survived several years (mean: 43.2 months) with a good quality of life (Heng et al., 2013), whereas in metastatic prostate cancer, one in four men survived more than five years (Wu et al., 2014). This illustrates the necessity of close cooperation between the ophthalmologist and the oncologist in order to properly consider the risks and benefits of CM treatment.

### **6.2.3. Targeted therapies: can they replace local treatment?**

The multiple reports of improvement or stabilization of vision under targeted therapy is encouraging, both for the patient and the ophthalmologist (**Tables 5 and 6**). In such cases, one may argue that local treatment, together with the risk of serious side effects it carries, is unnecessary. However, some limitations must be considered. For instance, evidence is only provided by case reports with limited follow-up (usually less than one year) and therefore the level of proof is not sufficient to assert the superiority of targeted treatments on CM. There may even be a reporting bias, as cases where systemic treatment was not effective on CM are probably under-reported. In the absence of randomized studies, and given the scarcity of oncological studies with a specific focus on CM, no definite conclusion can be drawn.

Furthermore, it appears that systemic treatment may have a lower rate of initial response and a higher rate of ocular relapse compared to local treatment (and results presented as positive after systemic treatment may not make the distinction between complete and partial clinical response). However, consolidative local treatment is helpful in achieving a higher response rate, and preventing ocular relapses. For instance, in a series of 194 patients with uveal

metastases of lung cancer, **partial response was reported in 68% of patients receiving systemic treatment alone, versus 82-86% of patients receiving additional local treatment by photon-based-EBRT or brachytherapy**; regrowth at one year occurred in 32% of patients receiving systemic therapy, versus 14-18% for patients who had local treatment (Shah et al., 2014).

Systemic molecular treatments are also subject to secondary resistance due to clonal selection, which is less the case for local physical treatments. Because of this, response to targeted therapies may not be durable, preventing the use of the same molecule in retreatment.

Illustrating this point is a case report of a patient with lung cancer who developed CM while receiving crizotinib, prompting the switch to another ALK inhibitor achieving only partial ocular response (Okuma et al., 2015). Similarly, Cui *et al.* reported the case of a single CM, also from ALK-mutated lung cancer, which was treated successfully with crizotinib but later became resistant and developed a second CM in the same eye. A switch to another ALK inhibitor led only to a partial response. **Visual acuity improved from 20/200 to 20/50 after treatment of the first CM, and from 20/200 to 20/60 after the treatment of the second CM** (Cui et al., 2017). These examples suggest that regression of CM is a good reflection of tumor sensitivity to the systemic therapy. However, this regression can be falsely reassuring, and postponing local treatment may have consequences on visual function. Thus, initial CM response may not be clinically relevant when deciding to treat locally or not. Finally, the possibility of adverse ophthalmological events with systemic treatments should not be forgotten (Liu et al., 2014). For instance, **mitogen-activated protein kinase kinase (MEK) inhibitors have been widely reported to be associated with uni- or pluri-focal serous detachments of the neurosensory retina, with spontaneous regression** (Francis et al., 2017; Weber et al., 2016). EGFR inhibitors are also associated with ocular toxicities, most



commonly dysfunctional tear syndrome, blepharitis, and eyelash changes (Borkar et al., 2013).

### **6.3. Radiotherapy for choroidal metastases**

#### **6.3.1. Radiotherapy techniques**

There are various forms of radiotherapy and various fractionation schemes depending on the local extent of the disease, its proximity to the macula, the number of lesions, the general prognosis, and the treatment goals. Another major factor is tumor radioresistance, in which case a higher total dose is required. There are also technical constraints governing the choice of the technique. They include dose conformality, dose spillage, treatment duration (beam delivery), the possibility to use numerous small doses or a single large dose, and of course access to the technique. All these integrate a patient-specific risk-benefit ratio, bearing in mind that healthy tissues are better spared with smaller doses per fraction while there is a spectrum of dose-response patterns for primary cancer. Radiotherapy techniques used to treat CM are presented below and include brachytherapy (contact brachytherapy with plaques) and external beam radiotherapy (EBRT) that itself includes tridimensional (conventional) EBRT, intensity modulated EBRT (IMRT), fractionated stereotactic EBRT (SBRT), stereotactic radiosurgery (single fraction SBRT), and proton beam therapy (PBT). Dose distributions, treatment planning and cost vary widely between these techniques. Conventional EBRT with photons is the most common treatment for CM as it is cost effective and readily accessible worldwide (it is commonly called EBRT).

Complications of radiotherapy may occur months or years after irradiation, which is relevant to long-term survivors. Depending on prognosis, the aims of radiotherapy are not only to control tumor growth, but also to preserve vision in the long term by sparing the macula and the optic disc. When possible, the anterior chamber is excluded from the irradiation field. CM

that occur secondary to radioresistant tumors (for instance melanoma, renal cancer, or sarcoma) are more likely to respond to high-dose radiotherapy. On the other hand, the macula is also sensitive to radiation dose. Thus, the radiotherapy technique and treatment scheme should be adapted carefully after evaluation of the risk-benefit ratio (**Figure 16**).

### **6.3.1.1. Basic radiophysics and radiobiology**

The cellular response to radiation is caused by interaction of ionizing radiation with DNA. Its clinical effect relies on differences in damage response pathways between tumor and normal tissues. At the molecular level, ionization of molecules through water radiolysis produces reactive free radicals which secondarily react with neighbouring materials, including DNA. DNA damage schematically includes single or double strand breaks and base/sugar damages. Higher linear energy transfer radiation, using charged particles (protons, carbon ions, etc.), also induces direct effects on molecules and higher concentration of ionizing events. It is more likely to produce complex DNA damage than low linear energy transfer radiation as achieved with EBRT, IMRT, SBRT, and brachytherapy. More complex DNA damage is associated with less efficient DNA repair and higher anti-tumor activity (Lomax et al., 2013). Intriguingly, the dose necessary to achieve CM control seems to be lower than that used for primary tumors. It may be that choroid tumor burden is limited but the precise mechanisms for such observations are unclear. The radiobiology of stereotactic radiosurgery is not fully understood but it is thought that it delivers a greater biologically equivalent dose, and that different molecular mechanisms are involved. This would account for a better local control rate than with conventional EBRT, even in radioresistant tumors (Shibamoto et al., 2016).

### **6.3.1.2. Organs at risk in ocular radiation oncology**

There is a dose-response relationship for the tissue effects of radiation therapy (**Table 7**) and therefore treatment decision is based on the tolerance of a given organ or tissue to a given dose based on previous knowledge. The dose threshold is either given as maximal or mean dose (and associated dose volume relationships) depending on whether the organ is considered to have “serial” or “parallel” architecture (by analogy with electricity). Serial organs are sensitive to hot spots while parallel organs are sensitive to relatively lower doses in larger portions of their volume. Fractionation plays a major role in the tolerance of healthy organs and tissues. Normofractionation of 2 Gray (Gy) fractions is the standard curative radiotherapy scheme. Alternative fractionation may be used in different situations, including metastases. Equieffective dose is then calculated from the dose per fraction and the duration of the treatment to estimate tumor response and normal tissue tolerance. For CM, the most common regimen of 30 Gy in 10 fractions is estimated to be equivalent to around 38-40 Gy in normofractionation (Kuperman, 2018). A total dose of 40 Gy is under the critical “toxic” threshold for maculopathy. This may explain the good visual preservation rate obtained with conventional EBRT using this common radiotherapy scheme for CM. However, pathological changes to the eye due to the CM or other health conditions may also influence the organ’s tolerance and visual preservation after radiotherapy.

<b>OCULAR TISSUES</b>	<b>DOSE OBJECTIVE (standard fractionation)</b>	<b>COMMENTS</b>
Lens (Thariat et al., 2017)	Mean lens dose < 0.5 Gy avoids lens opacities. Mean lens dose < 5-8 Gy avoids symptomatic cataract.	Acute lens toxicity is not seen. Radiation-induced cataract occurs generally 1 to 3 years after irradiation.
Cornea (Jeganathan et al., 2011)	Maximal dose to cornea < 40-60 Gy avoid risk of keratitis, ulcer or edema. Perforation is rare and seen only above 60 Gy	Acute toxicity is due to loss of the tear film and generally resolves within a few weeks.

Retina (Emami et al., 1991; Parsons et al., 1994)	Volume of retina receiving 45 Gy < 50%	Acute retinal toxicity is not seen. Significant retinopathy occurred typically 3 months to 3 years after radiotherapy, depending on the dose and other medical condition (diabetes).
Optic nerve (Bhandare et al., 2005; Parsons et al., 1994)	Maximal dose to optic nerve < 55Gy	Acute toxicity is not reported. Radiation-induced optic neuropathy occurs between 3 months and 8 years after treatment with a peak at 18 months.
Chiasma (Bhandare et al., 2005; Parsons et al., 1994)	Maximal dose to the chiasma < 55Gy	Chiasma is posterior and generally preserved in the treatment of CM.

**Table 7:** Organs at risk (OAR) in orbital radiation therapy. Standard fractionation = 1.8-2.0 Gy per fraction, 5 fractions per week.

Hypofractionation (*i.e.* fraction dose greater than 2.5 Gy and shorter treatment course) is associated with an increased risk of cataract (Belkacémi et al., 2001; Thariat et al., 2017). It can be reduced by lens shielding and lens-sparing techniques. The success rate for routine cataract surgery following radiation therapy is similar to that for the general population. In practice, the risk of cataract is not a limiting factor for delivering radiation therapy, neither in patients with a short life expectancy for whom there is a low probability of cataract occurrence (Rudoler et al., 1997b), nor in patients with long life expectancy to whom surgery could be proposed if necessary. Radio-induced cataract remains rare as the sparing of the anterior chamber of the eye is often possible: physical restraints, physical field measurements and dosimetric studies are quite precise and allow control of the dose clinically delivered to the lens.

In the study reported by Rudoler *et al.*, 12% of the eyes developed significant complications after EBRT (28/233 eyes) with 30 to 40 Gy in 2 to 3 Gy fractions to the posterior or entire globe. The median follow-up for the entire cohort was 5.8 months (range: 0.7-170.0 months). Sixteen eyes developed cataracts, 6 eyes retinopathy, 5 eyes neuropathy, 5 eyes keratopathy, and 4 eyes iris neovascularization. Two eyes had narrow-angle glaucoma (one required

enucleation). The authors concluded that the benefit of ocular EBRT for preservation of vision outweighed the risk of treatment complications (Rudoler et al., 1997a, 1997b).

### 6.3.1.3. Outcomes

EBRT for CM appears to yield good outcomes, although with a limited level of proof, as no randomized study against another treatment has been published and there are only two published prospective studies (Jardel et al., 2014). Despite short follow-up due to limited survival associated with metastatic cancer, radiation therapy seems to be an effective treatment for CM (**Table 8**). It is of note that clinical response to EBRT is often delayed (1 to 3 months or more) and the duration of improvement is of almost one year (Doig et al., 1992; Rosset et al., 1998; Röttinger et al., 1976) (**Figure 17**). In most cases, EBRT is performed after the initiation of a systemic therapy protocol (**Figure 18**). However, in some cases, especially when the primary cancer is not known at the time of CM diagnosis, EBRT can be performed prior to initiation of systemic treatment, possibly allowing for faster recovery of visual function (**Figure 19**).

<b>Authors</b>	<b>Number of patients</b>	<b>Primary Cancer</b>	<b>Follow-up (median)</b>	<b>Total Dose</b>	<b>Outcomes</b>
Rudoler <i>et al.</i> (Rudoler et al., 1997b)	188	Breast 53% Lung 23%	5.8 months	30-40 Gy in 2-3 fractions	57% improvement of visual acuity or stability
Demirci <i>et al.</i> (Demirci et al., 2003)	129	Breast 100%	10 months	20-64 Gy in 8-32 fractions	64% improvement 18% stable
D'Abbadie <i>et al.</i> (d'Abbadie et al., 2003)	97	Breast 71% Lung 9% (of the entire cohort, 123 patients)	NR	Most frequently 30 Gy in 10 fractions	Visual improvement at 3 months in 55% (EBRT) and 80% (chemotherapy + EBRT) of cases.

Shah <i>et al.</i> (Shah et al., 2014)	88	Lung 100%	12 months	NR	Among the eyes with follow-up information: -74% improvement and 12% stability with EBRT alone (27 eyes) -82% of improvement with chemotherapy + EBRT (22 eyes).
--	----	--------------	--------------	----	---

**Table 8:** The largest series of choroidal metastases treated by radiation therapy. EBRT: external beam radiotherapy; NR: Not reported

#### 6.3.1.4. Prescription

##### a) Timing of irradiation: pre- or post-chemotherapy?

Performing irradiation before any systemic treatment allows to define precisely the target and to manage patients with rapid loss of vision. Treatment may also be concomitant: for known associations, such as gefitinib and irradiation in lung cancer, both treatments may be given at the same time without concerns for safety (Bhardwaj et al., 2016; Jiang et al., 2016; Zheng et al., 2016); if there is no data on the combination, the 5-half-life rule for drug washout is recommended. In cases of life threatening progressive extra-choroidal metastases without rapid loss of vision, systemic treatment with re-evaluation of the need for choroidal irradiation after 3 to 6 courses is recommended; if progressive disease occurs with rapid loss of vision, as the volume of irradiation is limited the risk of toxicity should be reasonably low and may be worth taking.

##### b) EBRT planning

Few authors have reported the details of radiotherapy treatment planning and EBRT technique. The patient's head is immobilized using a personalized thermoplastic mask. To ensure a reproducible lens position it is easiest for the eyes to be closed, which is normally associated with a downward gaze. However, for a better control of macular position the patient is asked to look straight ahead or to fixate a light in a defined position (Bellmann et al., 2000). The metastasis, or gross tumor volume (GTV), is then identified on the dosimetric

CT-scan as a mass attached to the posterior edge of the eyeball; planar fundus images are used when available and a high-resolution MRI may be helpful for better delineation of the volumes using image fusion. The clinical target volume (CTV) includes probabilistic areas of microscopic invasion next to the GTV; **five millimeter expansions are applied around the GTV to create a CTV (Bellmann et al., 2000)**. Once the CTV is determined, a supplementary circumferential margin of 3-5 mm is applied to offset positional and physical uncertainties (planning target volume, PTV). Organs at risk are then delineated. Field geometry varies greatly in the literature and tumor targeting may be achieved using one or two beams, laterally or with non-coplanar oblique beams. The ultimate goal is to deliver at least 95% and up to 100% of the total dose to the target while the organs at risk receive the minimal achievable dose. The simplest field arrangement for a unilateral treatment could be a lateral 6 MV photon field (inclined and edged to avoid the lens); possibly together with a smaller dose to the anterior field for better dose homogeneity (**Figure 20**). A recent advance in EBRT for the treatment of CM is IMRT. Five to nine fields are used (instead of 1-3 with 3D EBRT) and modulated with a multileaf collimator. Complex concave dose distributions can be achieved, which may be better shaped in the high-dose regions, despite some low-dose spillage to the anterior chamber. The treatment planning process of IMRT is more complex and its use is usually limited to extended posterior pole metastases in patients with relatively good general prognosis.

### **c) Target**

**Pre-treatment evaluation.** For conventional 3D EBRT and SBRT, routine ophthalmological exams and visual evaluation are sufficient to diagnose the CM and to plan treatment. The aim is to not needlessly delay the treatment. Histological proof is not required, unless there is an

atypical clinical presentation. A brain MRI is nonetheless required to eliminate synchronous brain metastases.

**Bilaterality.** The risk of bilateral CM is well documented (see section 4.1.2). Bilateral CM can be synchronous or metachronous, symptomatic or not. Including the contralateral posterior orbital cone in a target volume is controversial. Some recommend unilateral treatment, arguing that the exit dose using a lateral beam is sufficient to eradicate microscopic disease (*i.e.* the fraction of dose received by the other eye due to its proximity and dose distribution with EBRT using photons). For instance, **in the German study ARO 95-08, none of the patients with unilateral CM irradiated with a unilateral field developed contralateral metastasis during a median follow-up of 5.8 months (Wiegel et al., 2002). However, this study was conducted in the 90's and less advanced irradiation techniques and conformation may have resulted in a higher dose delivery to the contralateral eye.** Others recommend bilateral fields (Rosset et al., 1998; Wiegel et al., 1999), **but there is no strong evidence to support prophylactic irradiation of an eye showing no sign of CM at baseline.** The complexity of treating the second eye at a later date is also dependent on the initial dose received.

**Risk of synchronous or metachronous brain metastases.** About two-thirds of patients with CM have extra-ocular metastases (Jardel et al., 2014). A high incidence of central nervous system involvement was reported in breast and lung cancer patients with CM: 32% of synchronous brain metastases in the series reported by Kreusel *et al.* (patients with lung cancer) and by Amer *et al.* (62% of patients with breast cancer) (Amer et al., 2004; Kreusel et al., 2008). MRI is thus recommended to look for concomitant brain metastases, the presence of which is technically challenging because there may be overlaps (and overdose, which may be associated with radiation-induced toxicity) between radiation fields for CM and brain metastases. For instance, when EBRT is performed for brain metastases or brain prophylaxis, the posterior orbits receive a significant dose of radiation which has to be taken into account



to minimize the risk of radiation-induced complications, especially on the central nervous system and optic nerves. Conversely, in case of isolated CM, the fields have to be carefully chosen to avoid overlapping with the brain, as whole-brain irradiation may be needed at a later date. In case of synchronous and symptomatic brain metastases, whole brain irradiation is indicated, and it will encompass the posterior orbits and choroids. EBRT is rapidly delivered, during the time needed to organize chemotherapy (radiation therapy is given during 5 to 10 consecutive working days). This is the best way to obtain a strong and rapid response on neurological symptoms as systemic treatments might be too slow, hindered by the blood-brain barrier. Moreover, radiotherapy decreases the risk of developing other brain metastases.

#### **d) EBRT Dose and fractionation**

In the largest published series to date, Rudoler *et al.* reported outcomes from 233 eyes irradiated for posterior uveal metastases. The majority (72%) of patients received total doses between 30-40 Gy in 2-3 Gy fractions corresponding to a biologically effective dose between 50-70 Gy (Rudoler *et al.*, 1997b). Another study reported by Demirci *et al.* described a series of patients treated by 20-64 Gy in 8 to 32 fractions (Demirci *et al.*, 2003). However, short hypofractionated palliative courses are often preferred for patients with short life expectancy; the most common regimens are 30 Gy in 10 fractions, or 20 Gy in 5 fractions. **For those with a life expectancy greater than one year, a normofractionated scheme could be considered in order to minimize the long-term side effects. Moreover, when OCT confirms involvement of the subfoveal region, a more conservative approach using a normofractionated scheme is justified and should be considered.**

#### **e) In case of choroidal metastasis relapse**

When CM relapses after initial radiation therapy, re-irradiation may not be possible owing to dose limiting constraints for sensitive ocular tissues irradiated during the initial treatment. There is a lack of data for ocular re-irradiation, but as is the case for other organs target volumes are usually limited to the recurrent GTV and careful evaluation of the risk-benefit ratio should be carried out (Mbeutcha et al., 2017); in CM, PBT, SBRT, or plaque brachytherapy may be used as they allow the delivery of a high dose in a smaller target volume with better sparing of surrounding tissues.

### **6.3.2. Stereotactic irradiation**

The principle of stereotactic irradiation is to deliver a high dose of radiation in a small tumor volume in a single fraction (radiosurgery) or a few fractions (hypofractionated stereotactic irradiation). It can be used as an alternative to PBT in unifocal CM, and is becoming widely available although it requires long treatment times and eye tracking capabilities, unless ocular immobilization is performed. Bellman *et al.* published a series of 10 patients treated for CM by stereotactic radiosurgery (12-20 Gy in one fraction) and long-term tumor control was achieved using shorter treatment course than with conventional EBRT. During follow-up (median: 26 months, range: 4 to 144 weeks) tumor regression was noted on ultrasound or MRI in 5/10 patients but only 4/10 patients had stabilization or improvement of their vision; no chronic side-effect was observed (Bellmann et al., 2000). A Korean study analyzed 7 cases of CM treated by Gamma Knife radiosurgery with a single dose (median: 20 Gy, range: 15-25Gy). Median follow-up was 8 months. Five patients had lung cancer; the other two had gastric and renal cell cancer. Interestingly, four patients had multiple brain metastases that were treated simultaneously with radiotherapy (SBRT or EBRT). Two patients even received repeated SBRT after the first treatment for new intracranial lesions. Six patients had visual

improvement after treatment; five CM disappeared completely on MRI. No acute complication attributable to the treatment itself was reported (Cho et al., 2018).

Several limitations are encountered with SBRT. It is minimally invasive but it implies complete immobilization of the eye to reduce the intra- and inter-fraction movements, thus reducing the volume to treat. This is made difficult by the length of the treatment session (always greater than 30 minutes) which requires perfect patient cooperation. For instance, in the study reported by Cho *et al.*, anesthetic ocular blocks and bridle suture were performed (Cho et al., 2018). The technique may not be applicable in patients with severe loss of vision as eye fixation is not possible. Taken together, stereotactic irradiation is feasible for CM treatment but its value has to be evaluated in larger series **and it may require invasive eye fixation tools.**

### **6.3.3 Proton beam therapy**

PBT is another radiotherapy technique that is effective in treating choroidal melanomas (Caujolle et al., 2010; Damato et al., 2005; Gragoudas et al., 1982). In the treatment of CM, it is usually reserved for patients with long life expectancy and relatively radioresistant tumors (sarcomas, melanomas, kidney carcinomas) or unifocal tumors. Due to the physical properties of protons, the energy is delivered with a sharp final peak known as the Bragg peak. This allows a very focused and high-dose volume with preservation of surrounding tissues. Ocular PBT is performed in a limited number of centers, although numerous construction projects are underway worldwide. Tsina *et al.* published a series of 63 patients with CM treated by PBT (Tsina et al., 2005); they received 2 fractions of 14 Gy corrected for the relative biologic effectiveness of protons compared to photons ( $Gy_{RBE}$ ). Eighty-four percent of treated tumors regressed completely within 5 months of treatment and there was no case of recurrence during follow-up (mean: 10 months). Complications occurred in 56% of cases and included minor

and major adverse effects: dermatitis (17%); madarosis (28%), dry eye syndrome (6%) keratitis (8%), cataract (11%), neovascular glaucoma (8%), maculopathy (19%), chorioretinal atrophy (3%), and papillopathy and optic atrophy (22%). Similarly, Kamran et al. described a retrospective cohort of 77 patients with CM mostly treated with 2 fractions of 10 Gy; median follow-up was 7.7 months and local control was achieved in 94% of patients. Treatment-related adverse effects were reported in 31% of patients and visual acuity improved or was stable in 38% of eyes treated (Kamran et al., 2014).

The main drawback of PBT as proposed in these series is the limited potential for macular sparing for tumors mainly located in the posterior pole. For patients with tumors next to the macula, PBT may be best performed in smaller doses per fraction that can be achieved by fractionated PBT, and helps spare normal tissues that are more easily damaged by high doses per fraction (**Figure 21**). However, the procedure may last 10 seconds to more than 2 minutes requiring therefore ocular gating or tracking. The use of fiducials ensures proper positioning of the eye before beam delivery; these are best placed around the metastasis to target the proton beam and better preserve sensitive tissues. Furthermore, an ocular gating system based on an infrared camera is also used for immediate interruption of the proton beam in case of gaze deviation.

Overall, PBT should be considered in cases of peripheral or radioresistant tumors, but additional studies are required. It is of note that the great majority of published data on ocular treatments concerns passive, single scattering, proton therapy with dedicated eyelines. There is very limited experience in ocular treatments with active, pencil beam scanning, or PBT using high energy equipment. Most centers are not properly equipped (from a technical and physical standpoint) to perform ocular treatments. However, beam quality, as reflected by dose gradient and sharpness in the Bragg peak area is expected to be lower with pencil beam scanning than with passive scattering. Similar to SBRT, such techniques are encouraging in

selected patients who have oligometastatic radioresistant disease with relatively good prognosis for whom visual preservation is an important objective.

#### 6.3.4 Plaque brachytherapy

The principle of plaque brachytherapy is to apply a radioactive isotope to the sclera that will deliver radiation over a short distance to the target tissue. It basically requires suturing a radioactive plaque onto the sclera, above the tumor. The plaque remains in place until the therapeutic dose is fully delivered (2-4 days). The patient can return home **after surgical removal of the plaque to avoid radiation risk to others** (Bell and Wilson, 2004; Lim and Petrovich, 2000). The first reports were published in the 1930s for the treatment of malignant tumors of the eye (Moore, 1930). A thin piece of metal (usually gold) is used, with radioactive seeds placed on one side. The dose distribution varies depending on the chosen isotope (Iodine-125, Palladium-103, Cobalt-60, Cesium-131, Ruthenium-106, Iridium-192 and Strontium-90, which have various profiles of radiation emission) and the way the metallic plaque is manufactured and shaped (Chiu-Tsao et al., 2012). The most widely used isotope is Iodine-125, which allows sparing of the adjacent tissues such as the lens and the retina due to its low energy photon-emitting profile (Shields, 1998). It also enables a safe surgical procedure as its radioactivity can be contained on a gold sheet a mere 0.5 mm thick (Earle et al., 1987; Echegaray et al., 2017; Packer et al., 1980; Packer and Rotman, 1980; Rotman et al., 1977). It may be used in select cases of CM such as solitary and well **delineated** anterior tumors. Indeed, while EBRT delivers a uniform dose to the whole eye structure, plaque brachytherapy delivers a much more heterogeneous dose from the sclera to the apex of the tumor. Shields *et al.* treated the largest series of patients (36 individuals) with CM by iodine-125 plaque brachytherapy. The mean treatment time was 86 hours, and the mean therapeutic dose was 68.80 Gy (45-70 Gy) to the tumor apex and 235.64 Gy to the tumor base. All tumors

regressed, and a complete response was found in 94% of cases. The metastases flattened while the exudative signs resolved. Recurrence occurred in only 2 cases over a mean follow-up period of 11 months. The overall complication rate was low, and included radiation retinopathy, optic neuropathy and cataract (Shields et al., 1997a).

Fifteen other studies are presented in **Table 9**. An objective response was achieved in most cases, generally within the first 3 months after treatment (C. L. Shields et al., 1995b; Shields et al., 1997a). Iodine-125 brachytherapy was used in most cases, with anecdotal use of Ruthenium-106, Iridium-192, Palladium-103, and Cobalt-60. It must be noted that a third of these patients had undergone EBRT and/or systemic chemotherapy beforehand. Only four studies reported radiation complications such as optic atrophy, radiation retinopathy, or cataract and iris neovascularization. This low complication rate might be due to the rather short life expectancy of metastatic patients. Overall, plaque radiotherapy can be considered as a more rapid alternative to EBRT, even if this irradiation technique remains invasive (Shields et al., 1997a). However, it is only available in some specialized radiation oncology departments.

Authors	Nb of tumors	Primary lesion	Previous treatment for CM	Concomitant treatment	Type of plaque used	VA after treatment	Mean thickness/diameter (mm)	Tumor response	Complication	Follow-up (months)
Trichopoulos <i>et al.</i> (Trichopoulos and Augsburg, 2006)	3	Neuroendocrine tumors	None	CT (2)	I-125	NR	5.8/11.3	Regression	NR	38
Brown <i>et al.</i> (Brown <i>et al.</i> , 1982)	2	NR	NR	NR	Co-60	NR	NR	NR	NR	NR
De Potter <i>et al.</i> (De Potter <i>et al.</i> , 1993)	1	Prostate	None	CT	I-125	NR	NR	Regression	NR	9
Shields <i>et al.</i> (Shields <i>et al.</i> , 1997a)	26	Breast (11) Lung (2) Prostate (2) Gastrointestinal (2) Thyroid (1) Kidney (1) Skin melanoma (2) Unknown (5)	35%: EBRT (6) CT (6)	NR	I-125 Co-60 Ru-106	Increased or stable: 58%	4.5/11	Regression (92%) Recurrence 2 cases: breast and unknown	11% radiation maculopathy and/or papillopathy	11
Shah <i>et al.</i> (Shah <i>et al.</i> , 2014)	28	Lung	NR	36% CT (9) EBRT (1)	NR	NR	NR	Regression 18/20 Progression 2/20	NR	NR
Demirci <i>et al.</i> (Demirci <i>et al.</i> , 2003)	15	Breast	NR	NR	NR	NR	NR	Regression: 53% Recurrence 13% Stable 33%	NR	25

Shields <i>et al.</i> (Shields et al., 2011)	2	Lung carcinoid	None	CT (1)	NR	NR	7.5/14	Regression (1) NR (1)	papillopathy and retinopathy (3)	8.5
Ritland <i>et al.</i> (Ritland et al., 1999)	1	Thyroid	None	Iodine-131 therapy	I-125	Unchanged	11/19	Regression	NR	3
Rapicetta <i>et al.</i> (Rapicetta et al., 2015)	1	Lung carcinoid	CT (3 months before)	None	NR	NR	8/13	NR	NR	NR
Lim <i>et al.</i> (Lim and Petrovich, 2000)	6	Breast (5) Pancreas (1)	EBRT (1)	NR	I-125 (4) Ir-192 (2)	Increased (2) Stable (1) Decreased (3)	3.6/10	Regression (5) Recurrence at other area of the choroid (1)	Radiation toxicity (2): papillopathy and retinopathy	12
Harbour <i>et al.</i> (Harbour et al., 1994)	3	Lung carcinoid	None	EBRT (1)	Ru 106 (2) I-125	NR	7.1/15.7	Regression	NR	19
Finger <i>et al.</i> (Finger et al., 2003)	1	Lung	None	None	Pd-103	NR	4/11	Regression	NR	4
Ayres <i>et al.</i> (Ayres et al., 2017)	1	Renal	None	CT	I-125	NT	7.2/12	Regression	NR	13
Ahmadi <i>et al.</i> (Ahmadi et al., 2001)	1	Thyroid	EBRT	CT	I-125	Decreased	NR	NR	Total retinal detachment	5
Anteby <i>et al.</i> (Anteby et al., 1993)	1	Skin melanoma	None	None	Ru-106	Increased	3	Regression	NR	12
Small <i>et al.</i> (Small et al., 1990)	1	Skin merkel cell carcinoma	EBRT	None	I-125	NR	5.2/10	Regression	NR	28



**Table 9:** Studies using plaque brachytherapy for the treatment of choroidal metastases. CM: Choroidal metastases; VA: Visual acuity; EBRT: external beam radiotherapy; CT: chemotherapy; NR: not reported

#### **6.4. Local treatment performed by ophthalmologists**

The goal in emerging “office-based” local therapies is to restore visual function while minimizing ocular toxicity, here defined as collateral damage to other parts of the eye. When metastatic patients have a short life expectancy, quality of life is preferred over the chance of remission, and conservative treatments which are able to preserve vision are required. Moreover, autonomy and improvement of quality of life are key goals in the management of ocular metastases.

##### **6.4.1. Photodynamic therapy**

Photodynamic therapy (PDT) is a minimally invasive treatment in which a nontoxic light-sensitive compound (photosensitizer) is administered and subsequently activated by light exposure. The photosensitive molecules accumulate in the target tissue and their activation produce photochemical effects in the tissue. Thus, PDT combines the benefits of a preferential concentration of the photosensitizer in a definite area and the specific activation by the light irradiation (Moan and Berg, 1992).

PDT is currently used to treat solid tumors and is approved by the Food and Drug Administration in the treatment of skin, esophageal, and non-small cell lung cancer. In ophthalmology, PDT is known to treat, with limited side-effects, choroidal lesions including choroidal neovascularization, choroidal hemangiomas, and chronic central serous chorioretinopathy (Newman, 2016).

While many photosensitizers are used in oncology, verteporfin (benzoporphyrin derivative monoacid ring A, BPD-MA) is the most used in ophthalmology. Verteporfin is a lipophilic photosensitizer and is more easily taken up by activated cells such as malignant cells (Allison

et al., 1994; Jamieson et al., 1990). Verteporfin is administered intravenously in a liposomal form. In the circulation, liposomal **verteporfin** (LV) binds to low density lipoprotein (LDL) with a strong affinity (Allison et al., 1990) and it is known that tumor tissue and cells have a higher number of LDL receptors than normal cells (Ho et al., 1978; Vitols et al., 1984) and a higher vascular permeability (Roberts and Hasan, 1992). Although there is limited published data regarding LV-LDL vectorization to human tumor tissue, in mice the administration of BPD premixed with LDL resulted in enhanced delivery to the tumor area and increased photosensitization compared with BPD administered in an aqueous solution (Allison et al., 1991; Schmidt-Erfurth et al., 1997). Moreover, LV is also selectively taken up by neovascular endothelium in mice (Roberts and Hasan, 1992). In summary, the mechanism for specific accumulation of verteporfin in tumors may be explained as follows: building of a complex with LV and LDL in the circulation, vectorization of the LV-LDL to the targeted tumor cell and adjacent neovascularization, and selective delivery and accumulation of the photosensitizer to the tumor by LDL receptor -mediated endocytosis (**Figure 22**).

Exposure to light then leads to activation of the photosensitizer, which produces reactive oxygen species (ROS) in the tissue microenvironment. There are 3 mechanisms of action for these ROS: direct tumor cytotoxic effect leading to cell death predominantly by apoptosis and necrosis (Dougherty et al., 1998); intraluminal thrombosis and destruction of peritumoral vasculature (Fingar et al., 1999); local inflammatory reaction resulting in increased autophagy. In the latter case, PDT induces an acute inflammation at the targeted site secondary to oxidative stress (Dougherty et al., 1998). The production of ROS and tumor cell death is accompanied by activation of the complement pathway and secretion of inflammatory cytokines. This leads to the recruitment of macrophages and dendritic cells, and the phagocytosis of tumor cell debris. Dendritic cells migrate to the local lymph nodes and

differentiate into professional antigen-presenting cells. Tumor antigen presentation within the lymph nodes is followed by clonal expansion of tumor-sensitized lymphocytes that home to the tumor and eliminate residual tumor cells (Agostinis et al., 2011)

Harbour *et al.* were the first to report the use of PDT for the treatment of CM in a patient with persistent ocular symptoms despite both chemotherapy and ocular EBRT in a context of pulmonary carcinoid tumor (Harbour, 2004). Few authors have subsequently reported cases of different types of primary tumor (Isola et al., 2006; Kaliki et al., 2012; Kawakami et al., 2013; Mauget-Fajssse et al., 2006; Soucek and Cihelkova, 2006). Ghodasra *et al.* treated 21 tumors in 13 eyes of 10 patients that led to 81% of total tumor resorption despite 70% systemic cancer progression in these patients (Ghodasra and Demirci, 2016). These data suggest that PDT provides reasonable rates of tumor regression with good safety (Ghodasra and Demirci, 2016; Kaliki et al., 2012). Multiple sessions of PDT may be necessary and well tolerated in cases of recurrence or inefficacy, suggesting that PDT is still effective while systemic treatment may not be (Ghodasra and Demirci, 2016; Kaliki et al., 2012; Soucek and Cihelkova, 2006) (**Figure 23**). Systematic analysis of the published literature on the treatment of CM by PDT as a first or second line of treatment suggests treating selected patients with one or two CM (**Table 10**). PDT seems to be more effective in treating retro-equatorial tumor with low to moderate exudative symptoms, and with a thickness less than 3 mm and diameter less than 10 mm. Lesions that are too thick might not be eligible for PDT, since the wavelength (689 nm) of the laser used will not penetrate the entire tumor. Moreover, visual acuity seems to improve after PDT probably due to the decrease of SRF.

<b>Authors</b>	<b>Nb of patients</b>	<b>Primary tumor</b>	<b>Mean Thickness/ Mean diameter (range, mm)</b>	<b>Mean percentage reduction after PDT (%)</b>	<b>Mean follow-up (months)</b>	<b>Complicati ons</b>	<b>Primary or secondary treatment</b>
Ghodasra <i>et al.</i> (Ghodasra and Demirci, 2016)	10	Breast (7) Thyroid (1) Lung (1) Pancreas (1)	1.3 (0-2.6)/8.6 (3-16)	81	12	0	Secondary (4)
Kaliki <i>et al.</i> (Kaliki et al., 2012)	8	Breast (4) Lung (4) Leiomyosarcoma (1)	2.9 (1.6-4)/7(2-13)	39	17	intraretinal hemorrhage (1)	Primary (8) Secondary (1)
Harbour <i>et al.</i> (Harbour, 2004)	1	Lung carcinoid	4.8/13	25	2	0	Secondary
Isola <i>et al.</i> (Isola et al., 2006)	1	Breast	NR	NR	4	0	Primary
Mauget-Fay�sse <i>et al.</i> (Mauget-Fay�sse et al., 2006)	1	Lung	3.0/7.4	100	6	0	Primary
Kawakami <i>et al.</i> (Kawakami et al., 2013)	1	Breast or lung carcinoid	NR	100	14	0	Primary
Soucek <i>et al.</i> (Soucek and Cihelkova, 2006)	1	Breast	2.2	100	6	0	Primary
Hua <i>et al.</i> (Hua et al., 2017)	1	Lung	4.2/8.7	NR (+23% in diameter)	3	0	Primary

Chu <i>et al.</i> (Chu and El-Annan, 2018)	1	Lung carcinoid	4.5/ 10.1	73	2	0	Secondary
--	---	----------------	-----------	----	---	---	-----------

**Table 10:** Studies using PDT for treatment of choroidal metastases. NR: not reported; PDT: photodynamic therapy

Despite these promising results, there are reports of PDT failures. Hua *et al.* describe the case of a patient with a 4.2 mm-thick CM of a lung cancer who received PDT treatment with no concomitant chemotherapy. Multimodal imaging at 3 weeks follow-up found an increase in tumor size and exudative signs. Systemic evaluation showed progression of the metastatic disease. Ghodasra *et al.* also described the failure of PDT treatment in one of ten patients with aggressive multi metastatic disease who did not receive any previous or concomitant chemotherapy (Ghodasra and Demirci, 2016). However, these failures might be explained by the large tumor size, the short duration of follow-up, the lack of adjuvant chemotherapy or the aggressive multimetastatic status of the patient.

The overall clinical effectiveness is rather promising, especially for patients who often have short survival rates and might be looking for time-sparing treatments. While EBRT takes weeks to treat ocular tumor, PDT allows treatment in a single day, which is desirable for the quality of life of these patients with limited survival. Furthermore, contrary to PBT or plaque brachytherapy, this treatment avoids interventional surgery and potential side effects of irradiation.

PDT should be performed at full-fluence: intravenous verteporfin (6 mg/m<sup>2</sup>) is infused over 10 minutes. Five minutes later, a 689 nm diode laser is delivered to the area of the CM for 83 seconds at an intensity of 600 mW/cm<sup>2</sup> (50 J/cm<sup>2</sup>). If multiple spots are required, they must be overlapping to cover the whole diameter of the tumor. Furthermore, a 1 mm free margin may be treated around the tumor area.

#### **6.4.2. Intravitreal injection**

Another local treatment that could be performed by ophthalmologists alone is intravitreal injection (IVI) of anti-vascular endothelial growth factor (VEGF). The pathogenesis of CM begins with the hematogenous spread of the primary tumor. Once implanted in the choroidal space, tumor cells secrete neovascular factors allowing the supply of nutrients and oxygen necessary for proliferation (Langley and Fidler, 2011). These are initially supplied from the host vascular system, but the demand soon exceeds the supply from this source, and therefore tumors develop their own functional vascular supply (Folkman, 1986) from the normal host vascular network by the process of angiogenesis (Bergers and Benjamin, 2003). Pathological angiogenesis is not auto-regulated and results from alterations in growth control. The induction of angiogenesis has been shown to correlate with the invasive properties of tumors and is associated with poor prognosis (Nishida et al., 2006).

VEGF is an angiogenic agent that increases vessel permeability and enhances endothelial cell growth, proliferation, migration, and differentiation (Johnstone and Logan, 2007). VEGF also promotes angiogenesis in different tumor types and may affect tumor growth, metastatic potential, and response to radiotherapy (Nishida et al., 2006). VEGF expression may prove to be an important prognostic factor in head and neck cancer as VEGF positivity is the most significant predictor of poor prognosis (Smith et al., 2000). Angiogenic factors and isoforms of VEGF were found to be over-expressed in choroidal melanoma (Boyd et al., 2002).

CM are not exempt of these rules and have been shown to have hypervascularity (Neudorfer et al., 2011). As primary tumor and CM growth seems to be strongly dependent on angiogenesis and VEGF, one can imagine that anti-VEGF therapy could lead to a reduction in tumor mass and exudation.

From a pharmacological standpoint, it is not clear how the anti-VEGF injected in the vitreous is able to reach the choroid that is protected by the outer blood-retinal barrier (see 6.2.1).

Some investigations on anti-VEGF clearance have shown that bevacizumab permeates



through the blood-retinal barrier and are found in the choroid (Heiduschka et al., 2007; Shahar et al., 2006; Stewart, 2014). Although mechanisms of barrier breakdown are still unknown, it is suspected that RPE alterations caused by the underlying choroidal tumor, which are clearly visible on FA, may lead to blood-retinal barrier disruption, facilitating drug access to the choroid.

The very first reports of intravitreal anti-VEGF use in CM found dramatic improvement; three out of 4 cases showed a nearly complete regression of the CM, and huge improvement in visual acuity a few months after the first injection (Kim et al., 2009; Kuo et al., 2008; Yao et al., 2010). Many authors have since reported cases of successful management of CM from various primary locations with systemic (George et al., 2009; Kourie et al., 2015) or intravitreal anti-VEGF (**Table 11**). Intravitreal anti-VEGF shows promising results, regarding both clinical outcome and quality of life of patients, as it is by far less invasive than conventional chemotherapy or radiation therapy. Combined with systemic chemotherapy, it allowed local control of the CM in most cases, often leading to complete regression of both tumor and exudative retinal detachment. Interestingly, FA after IVI shows a marked reduction of vascularity and leakage in the tumor bed, suggesting an antiangiogenic and antipermeability effect on the tumor neovessels (Kim et al., 2009; Kuo et al., 2008; Mansour and Alameddine, 2012).

Several IVI are sometimes needed to treat the tumor and an as-needed-regimen is used in this case. It should be noted that most of the patients treated by IVI were receiving systemic chemotherapy before or during intraocular treatment and therefore the true effectiveness of IVI may have been overestimated. However, in most patients, the immediate effect observed after IVI should be attributed to the intravitreal anti-VEGF and it can be effective even in cases refractory to conventional treatment (Lai et al., 2012; Yao et al., 2010). This therapy

could also be proposed in association with other local treatments to hasten fluid resorption and thus improve functional results. However, some failures have also been reported (Boss et al., 2016; Lin et al., 2010; Maturu et al., 2014; Maudgil et al., 2015); for these cases, systemic therapies were generally not given at the same time of IVI or failed to control other metastases.

<b>Authors</b>	<b>Nb of patients</b>	<b>Primary lesion</b>	<b>Previous treatment for CM</b>	<b>Concomitant treatment</b>	<b>Mean number of IVI (dosing)</b>	<b>VA after treatment</b>	<b>Tumor response/evolution of subretinal fluid</b>	<b>Follow-up (months)</b>
Amselem et al. (Amselem et al., 2007)	1	Breast	None	None	1 (4 mg)	Increase	Regression / Decrease	1
Fabrini et al. (Fabrini et al., 2009)	1 (both eyes)	Thyroid	Brachytherapie (concomitant) (1)	CT	1 (1.25 mg)	Stable (1) and Increase (1)	Stable (1) and regression (1) / Decrease (2)	20
Yasui et al. (Yasui et al., 2015)	1	Lung	None	CT	1 (1.25 mg)	NR	Regression / Decrease	1.3
Yao et al. (Yao et al., 2010)	1	Breast	None	CT	1 (2.5 mg)	Increase	Regression / Decrease	24
Maugdil et al. (Maugdil et al., 2015)	5	Caecum (2) Breast (2) Lung (1)	PDT (1) EBRT (1)	None (4) CT (1)	2.4 (1.25 mg)	NR (5)	Progression (4) and regression (1) / Progression (1) and NR (4)	2.2
Mansour et al. (Mansour and Alameddine, 2012)	1	Breast	None	None	9 (2.5 mg)	Decrease	Regression / Stable	22
Lai et al. (Lai et al., 2012)	1	Lung	None	CT	2 (2.5 mg)	Increase	Regression / Decrease	4
Kuo et al. (Kuo et al., 2008)	1	Colorectal	None	None	3 (1.25 mg)	Increase	Regression / Decrease	5
Kim et al. (Kim et al., 2009)	1	Lung	None	CT	3 (2.5 mg)	Increase	Regression / Decrease	4
Lin et al. (Lin et al., 2010)	1 (both eyes)	Colorectal	None	CT	1 and 4 (4 mg)	Stable and decrease	Regression and progression / NR	5
Lin and Tsai. (Lin and Tsai, 2015)	3 (both eyes for 2 patients)	Lung (small cell) (2) Breast (1)	Transpupillary thermotherapy (3)	CT (3)	3 (4 mg)	Increase (4), stable (2)	Regression (5) / Decrease (3)	6
Fenica et al. (Fenicia et al., 2014)	3	Breast (2) Lung (1)	None	CT (3)	2.7 (1.25 mg)	Increase (3)	Regression (3) / Decrease (1) and NR (2)	9

D'antonio et al. (D'Antonio et al., 2012)	1	Lung	None	CT	2 (1.25 mg)	Increase	Regression / Decrease	20
Bhattacharyya et al. (Bhattacharyya et al., 2013)	1	Lung	EBRT	CT	5 (2.5 mg)	Increase	NR / NR	6
Maturu et al. (Maturu et al., 2014)	2 (both eyes for 1 patient)	Lung (2)	None	CT (2)	3.3 (1.25 mg)	Increase (1) and decrease (2)	Regression (1), progression (1) and NR (1) / Decrease (1) and increase (2)	NR
de la Barquera Cordero et al. (de la Barquera Cordero and Hidalgo, 2010)	1	Lung	None	None	5 (2.5 mg)	Increase	Regression / No initial fluid	10
Nadiminti et al. (Nadiminti and Leone, 2016)	1 (both eyes)	Breast	Concomitant EBRT (1)	CT	2 (1.25 mg)	Increase (2)	Regression / NR	4
Augustine et al. (Augustine et al., 2014)	1	Breast	None	CT	4 (1.25 mg)	Increase	Regression / Decrease	8
Singh et al. (Singh et al., 2012)	2	Lung (2)	EBRT (concomitant)	CT (2)	7 and 5 (1.25 mg)	Increase (2)	Regression (2) / Decrease (2)	12.5
Detorakis et al. (Detorakis et al., 2012)	2	Lung (small cell) (1) Nasopharyngeal (1)	None	CT (1) NR (1)	3 Ranibizumab (0.5 mg)	Increase (1) NR (1)	Regression (2) / NR (2)	9
Boss et al. (Boss et al., 2016)	1	Colorectal (1)	None	CT	3 (1.25 mg)	NR	Progression / Increase	3

**Table 11:** Studies using intravitreal injection (IVI) of Bevacizumab (except one with Ranibizumab) for treatment of choroidal metastases. CM: choroidal metastases; VA: Visual acuity; NR: not reported; CT: chemotherapy; PDT: photodynamic therapy; EBRT: external beam radiotherapy.

Overall, IVI treatment might be a good therapeutic option for patients with a metastatic disease as it preserves the quality of life without reducing clinical effectiveness. Clear guidelines concerning the use of IVI are still to be determined. It may be suggested to begin with a single dose followed by a monthly as-needed regimen. Conversely to other local treatments, IVI has a very low rate of side effects, including the risk of endophthalmitis which, for this treatment, is about 1 in 2000 patients (Benoist d'Azy et al., 2016; Fileta et al., 2014); it could be proposed to multi-metastatic patients under systemic chemotherapy with short life expectancy, as it improves or preserves the vision in most cases without time-consuming treatment. Furthermore, unlike PDT, this treatment can be given in cases of exudative or large tumors.

#### **6.5. Decisional trees in a multimodal approach of choroidal metastases**

When dealing with a CM, several points should be raised: are the CM responsible for ocular symptoms; how is patient's life-expectancy; are there other metastases, are they life-threatening, and how should multimodal treatment be managed?

Most of the patients with CM have systemic molecular treatment for their primary tumor or metastatic spread. Patients with specific oncogenic driver mutations or translations may exhibit dramatic tumor response under specific targeted therapies, including a decrease in tumor mass and exudative syndrome (Demirci et al., 2003; Manquez et al., 2006; Shah et al., 2014; Yang et al., 2014). However, secondary resistance to systemic molecular treatments is common and may ultimately be associated with treatment failure after initial (transient) tumor response (Cui et al., 2017; Okuma et al., 2015). Therefore, it makes sense to propose local treatment concomitantly or after systemic therapy to provide a more sustainable response.

Depending on the life-expectancy, the number of CM, and their localization different approaches can be proposed to the patient, and these are described below.

#### **6.5.1. In cases of long life expectancy (Figure 24)**

When life expectancy is considered long, a more effective and durable response to treatment of the CM is preferred. The patient may be willing to undergo a multimodal treatment with numerous appointments (EBRT) or requiring eye surgery (PBT, Brachytherapy).

In cases of multiple and disseminated CM foci, and/or when bilateral CM metastases are present, EBRT is considered upfront. When the metastasis is unilateral and unique, a more localized treatment, such as PBT, plaque brachytherapy or SBRT should be considered as an alternative to conventional EBRT. Although PBT and plaque brachytherapy provide similar results for the majority of ocular tumors, plaque brachytherapy is less frequently used for tumors posterior to the equator due to the intra-operative accessibility, or in cases of large tumor diameter. More studies are needed to evaluate the effectiveness of SBRT and to define the place of this technique as ocular immobilization remains the main obstacle for its use. PBT is the treatment of choice for radioresistant tumors as the proton beam provides a high-dose volume with sharp dose deposition allowing the preservation of surrounding tissues. When the CM is very close to the macula, there is a risk for visual deterioration, but tumor control may be privileged in case of unilateral CM. It should be performed after fiducial implantation at the surface of the sclera to define tumor borders and for stereotactic modeling of eye orientation.

When the CM is near the macula or the optic disc area and primary cancer is relatively radiosensitive, EBRT may be preferred. PDT could be an alternative, but patients should be followed carefully due to the risk of relapse.

There are no guidelines about the treatment of asymptomatic CM; management depends on the area involved by the tumor. In case of asymptomatic lesions located in critical areas, such as macula and optic disc, the risk for iatrogenic complications from irradiation may outweigh the risk for vision loss in the short term. In such tumors, strict follow-up may help to determine whether the lesion is rapidly progressive or stable. If it is progressive, irradiation using a conservative approach may be recommended, such as normofractionated EBRT or PDT. If the lesion is stable, continued observation may be recommended provided that the patient is compliant to medical visits. In case of asymptomatic lesions located outside critical areas, a strict follow-up is recommended. In case of progression, high-dose irradiation may be used safely.

#### **6.5.2. In cases of short life expectancy (Figure 25)**

Local treatment in such cases should be carefully discussed with the patient and the oncologist. The priority is to maintain the quality of life, and this may include, for some patients, retaining some vision for the end of their life. When a treatment is proposed for a palliative-care patient it should include minimal time spent in a medical setting and should avoid redundant consultations. If systemic therapy fails to sustain sufficient vision, local treatment could be proposed. It should be prompt and effective to allow rapid vision gain. When patients have synchronous cerebral metastases requiring brain EBRT, the choroids can be treated at the same time. In cases of unilateral and unique CM, PDT and/or anti-VEGF IVI is proposed, knowing that PDT leads to poorer results if exudation is intense or in large and thick tumors as the laser beam does not penetrate as well. Follow-up of patients treated by anti-VEGF IVI should be regular because some failures are reported, especially in the absence of systemic therapy. A combined treatment with a few anti-VEGF IVI followed by PDT could be proposed to patients with an intense exudative lesion. In cases of multiple or bilateral CM,

a short palliative hypofractionated EBRT is proposed; if there are a few unilateral CM, anti-VEGF IVI and/or PDT can be considered.

## 7. Conclusion and future direction

Enhanced imaging of the retina and choroid allows a better understanding and precise diagnosis of CM, even before they are visible on fundus. This diagnosis is most often made using clinical findings in the context of a known cancer, with or without known metastases. However, up to a third of patients have no history of cancer at the time of CM diagnosis, and ocular manifestations are the first sign of systemic disease. Therefore, ophthalmologists must be familiar with the diagnostic features and general work up of CM, allowing prompt treatment of the primary cancer. When work-up fails to identify the primary cancer, **choroidal tumor biopsy** or liquid biopsy can help speed up the diagnosis. This is especially important since the emergence of targeted treatments in the past decade have greatly improved survival.

Several therapeutic options are available, but randomized studies comparing different approaches are still needed to guide optimized treatment schemes depending on cancer phenotypes and general status of the patient. In this review, we provide an overview of the treatment options available, their advantages and their limits. The common objectives of all treatments are to preserve or improve vision, avoid enucleation, and maintain quality of life. To date, radiotherapy remains the treatment of choice for CM: there is longstanding experience and good results are reported in the literature. It may be performed alone for solitary tumors located in the eye only, or it can be associated with systemic treatment in case of disseminated metastatic disease. Fractionated conventional lens sparing techniques can be considered as a gold standard. In selected patients, local irradiation techniques used to treat primary eye tumors may be considered for the management of CM, such as plaque



brachytherapy, PBT, or optimized photon-based techniques. Other local treatments, such as PDT or intravitreal anti-VEGF, are available and can decrease the need for radiation and its side effects, and reduce time spent in medical settings for multimetastatic patients. The effectiveness of systemic therapies, especially targeted agents, should be assessed more specifically, and their place in the treatment strategy should be discussed in future recommendations. Further identification of biomarkers is needed to unravel disease mechanisms and to tailor management of CM to the individual.

## REFERENCES

- Agostinis, P., Berg, K., Cengel, K.A., Foster, T.H., Girotti, A.W., Gollnick, S.O., Hahn, S.M., Hamblin, M.R., Juzeniene, A., Kessel, D., Korbelik, M., Moan, J., Mroz, P., Nowis, D., Piette, J., Wilson, B.C., Golab, J., 2011. Photodynamic therapy of cancer: an update. *CA. Cancer J. Clin.* 61, 250–281. <https://doi.org/10.3322/caac.20114>
- Ahmadi, M.A., Nicholes, D., Esmaeli, B., 2001. Late choroidal metastasis secondary to papillary thyroid carcinoma. *Am. J. Ophthalmol.* 132, 796–798.
- Akgul, H., Otterbach, F., Bornfeld, N., Jurklies, B., 2011. Intraocular biopsy using special forceps: a new instrument and refined surgical technique. *Br. J. Ophthalmol.* 95, 79–82. <https://doi.org/10.1136/bjo.2008.148395>
- Albert, D.M., Rubenstein, R.A., Scheie, H.G., 1967a. Tumor metastasis to the eye. I. Incidence in 213 adult patients with generalized malignancy. *Am. J. Ophthalmol.* 63, 723–726.
- Albert, D.M., Zimmermann, A.W., Zeidman, I., 1967b. Tumor metastasis to the eye. 3. The fate of circulating tumor cells to the eye. *Am. J. Ophthalmol.* 63, 733–738.
- Al-Dahmash, S.A., Shields, C.L., Kaliki, S., Johnson, T., Shields, J.A., 2014. Enhanced depth imaging optical coherence tomography of choroidal metastasis in 14 eyes. *Retina Phila. Pa* 34, 1588–1593. <https://doi.org/10.1097/IAE.0000000000000131>
- Allison, B.A., Pritchard, P.H., Levy, J.G., 1994. Evidence for low-density lipoprotein receptor-mediated uptake of benzoporphyrin derivative. *Br. J. Cancer* 69, 833–839.
- Allison, B.A., Pritchard, P.H., Richter, A.M., Levy, J.G., 1990. The plasma distribution of benzoporphyrin derivative and the effects of plasma lipoproteins on its biodistribution. *Photochem. Photobiol.* 52, 501–507.
- Allison, B.A., Waterfield, E., Richter, A.M., Levy, J.G., 1991. The effects of plasma lipoproteins on in vitro tumor cell killing and in vivo tumor photosensitization with benzoporphyrin derivative. *Photochem. Photobiol.* 54, 709–715.
- Alm, A., Bill, A., Young, F.A., 1973. The effects of pilocarpine and neostigmine on the blood flow through the anterior uvea in monkeys. A study with radioactively labelled microspheres. *Exp. Eye Res.* 15, 31–36.
- Alzouebi, M., Ramakrishnan, S., Rennie, I., Salvi, S., 2014. Use of systemic therapy in the treatment of choroidal metastases from breast cancer. *BMJ Case Rep.* 2014. <https://doi.org/10.1136/bcr-2013-009088>
- Amer, R., Pe'er, J., Chowers, I., Anteby, I., 2004. Treatment options in the management of choroidal metastases. *Ophthalmol. J. Int. Ophtalmol. Int. J. Ophthalmol. Z. Augenheilkd.* 218, 372–377. <https://doi.org/10.1159/000080939>
- Amselem, L., Cervera, E., Díaz-Llopis, M., Montero, J., Garcia-Pous, M., Udaondo, P., García-Delpech, S., Salom, D., 2007. Intravitreal bevacizumab (Avastin) for choroidal metastasis secondary to breast carcinoma: short-term follow-up. *Eye Lond. Engl.* 21, 566–567. <https://doi.org/10.1038/sj.eye.6702647>
- Anderson, M.F., Coupland, S.E., Bissett, D., Atta, H., Damato, B.E., 2011. Choroidal metastasis from primary pulmonary leiomyosarcoma. *Clin. Experiment. Ophthalmol.* 39, 705–707. <https://doi.org/10.1111/j.1442-9071.2011.02528.x>
- Angi, M., Kalirai, H., Taktak, A., Hussain, R., Groenewald, C., Damato, B.E., Heimann, H., Coupland, S.E., 2017. Prognostic biopsy of choroidal melanoma: an optimised surgical and laboratory approach. *Br. J. Ophthalmol.* 101, 1143–1146. <https://doi.org/10.1136/bjophthalmol-2017-310361>
- Anteby, I., Axer-Siegel, R., Pe'er, J., 1993. Choroidal metastasis of cutaneous malignant melanoma treated by ruthenium-106 plaque irradiation. *Ann. Ophthalmol.* 25, 339–341.
- Arevalo, J.F., Fernandez, C.F., Garcia, R.A., 2005. Optical coherence tomography characteristics of choroidal metastasis. *Ophthalmology* 112, 1612–1619.

<https://doi.org/10.1016/j.ophtha.2005.03.030>

Atlas, S.W., Grossman, R.I., Savino, P.J., Sergott, R.C., Schatz, N.J., Bosley, T.M., Hackney, D.B., Goldberg, H.I., Bilaniuk, L.T., Zimmerman, R.A., 1987. Surface-coil MR of orbital pseudotumor. *AJR Am. J. Roentgenol.* 148, 803–808. <https://doi.org/10.2214/ajr.148.4.803>

Auerbach, R., Lu, W.C., Pardon, E., Gumkowski, F., Kaminska, G., Kaminski, M., 1987. Specificity of adhesion between murine tumor cells and capillary endothelium: an in vitro correlate of preferential metastasis in vivo. *Cancer Res.* 47, 1492–1496.

Augsburger, J.J., Corrêa, Z.M., Augsburger, B.D., 2015. Frequency and implications of discordant gene expression profile class in posterior uveal melanomas sampled by fine needle aspiration biopsy. *Am. J. Ophthalmol.* 159, 248–256.

<https://doi.org/10.1016/j.ajo.2014.10.026>

Augsburger, J.J., Corrêa, Z.M., Schneider, S., Yassin, R.S., Robinson-Smith, T., Ehya, H., Trichopoulos, N., 2002. Diagnostic transvitreal fine-needle aspiration biopsy of small melanocytic choroidal tumors in nevus versus melanoma category. *Trans. Am. Ophthalmol. Soc.* 100, 225–232; discussion 232–234.

Augsburger, J.J., Golden, M.I., Shields, J.A., 1984. Fluorescein angiography of choroidal malignant melanomas with retinal invasion. *Retina Phila. Pa* 4, 232–241.

Augustine, H., Munro, M., Adatia, F., Webster, M., Fielden, M., 2014. Treatment of ocular metastasis with anti-VEGF: a literature review and case report. *Can. J. Ophthalmol. J. Can. Ophthalmol.* 49, 458–463. <https://doi.org/10.1016/j.jcjo.2014.06.008>

Avram, A.M., Gielczyk, R., Su, L., Vine, A.K., Sisson, J.C., 2004. Choroidal and skin metastases from papillary thyroid cancer: case and a review of the literature. *J. Clin. Endocrinol. Metab.* 89, 5303–5307. <https://doi.org/10.1210/jc.2004-0757>

Ayres, B., McClendon, T., Demirci, H., 2017. Cavitory Choroidal Metastasis from Clear Cell Renal Cell Carcinoma. *Optom. Vis. Sci. Off. Publ. Am. Acad. Optom.* 94, 851–853. <https://doi.org/10.1097/OPX.0000000000001097>

Baek, J., Park, Y.-H., 2015. Optical density ratio in the subretinal fluid: differentiating chronic central serous chorioretinopathy and polypoidal choroidal vasculopathy. *Am. J. Ophthalmol.* 159, 386–392. <https://doi.org/10.1016/j.ajo.2014.11.011>

Bagger, M., Tebering, J.F., Kiilgaard, J.F., 2013. The ocular consequences and applicability of minimally invasive 25-gauge transvitreal retinochoroidal biopsy. *Ophthalmology* 120, 2565–2572. <https://doi.org/10.1016/j.ophtha.2013.07.043>

Barak, A., Neudorfer, M., Heilweil, G., Merimsky, O., Lowenstein, A., Inbar, M., Yaal-Hahoshen, N., 2007. Decreased prevalence of asymptomatic choroidal metastasis in disseminated breast and lung cancer: argument against screening. *Br. J. Ophthalmol.* 91, 74–75. <https://doi.org/10.1136/bjo.2006.099416>

Barkan, D., Green, J.E., Chambers, A.F., 2010. Extracellular matrix: a gatekeeper in the transition from dormancy to metastatic growth. *Eur. J. Cancer Oxf. Engl.* 1990 46, 1181–1188. <https://doi.org/10.1016/j.ejca.2010.02.027>

Bechrakis, N.E., Foerster, M.H., Bornfeld, N., 2002. Biopsy in indeterminate intraocular tumors. *Ophthalmology* 109, 235–242.

Beenakker, J.W.M., van Rijn, G.A., Luyten, G.P.M., Webb, A.G., 2013. High-resolution MRI of uveal melanoma using a microcoil phased array at 7 T. *NMR Biomed.* 26, 1864–1869. <https://doi.org/10.1002/nbm.3041>

Belden, C.J., Abbitt, P.L., Beadles, K.A., 1995. Color Doppler US of the orbit. *Radiogr. Rev. Publ. Radiol. Soc. N. Am. Inc* 15, 589–608. <https://doi.org/10.1148/radiographics.15.3.7624565>

Belkacémi, Y., Touboul, E., Méric, J.B., Rat, P., Warnet, J.M., 2001. [Radiation-induced cataract: physiopathologic, radiobiologic and clinical aspects]. *Cancer Radiother. J. Soc. Francaise Radiother. Oncol.* 5, 397–412.

Bell, D.J., Wilson, M.W., 2004. Choroidal melanoma: natural history and management options. *Cancer Control J. Moffitt Cancer Cent.* 11, 296–303. <https://doi.org/10.1177/107327480401100503>

Bellmann, C., Fuss, M., Holz, F.G., Debus, J., Rohrschneider, K., Völcker, H.E., Wannemacher, M., 2000. Stereotactic radiation therapy for malignant choroidal tumors: preliminary, short-term results. *Ophthalmology* 107, 358–365.

Benoist d’Azy, C., Pereira, B., Naughton, G., Chiambaretta, F., Dutheil, F., 2016. Antibioprophylaxis in Prevention of Endophthalmitis in Intravitreal Injection: A Systematic Review and Meta-Analysis. *PLoS One* 11, e0156431. <https://doi.org/10.1371/journal.pone.0156431>

Bergers, G., Benjamin, L.E., 2003. Tumorigenesis and the angiogenic switch. *Nat. Rev. Cancer* 3, 401–410. <https://doi.org/10.1038/nrc1093>

Bert, R.J., Patz, S., Ossiani, M., Caruthers, S.D., Jara, H., Krejza, J., Freddo, T., 2006. High-resolution MR imaging of the human eye 2005. *Acad. Radiol.* 13, 368–378. <https://doi.org/10.1016/j.acra.2005.10.023>

Besic, N., Luznik, Z., 2013. Choroidal and orbital metastases from thyroid cancer. *Thyroid Off. J. Am. Thyroid Assoc.* 23, 543–551. <https://doi.org/10.1089/thy.2012.0021>

Bhandare, N., Monroe, A.T., Morris, C.G., Bhatti, M.T., Mendenhall, W.M., 2005. Does altered fractionation influence the risk of radiation-induced optic neuropathy? *Int. J. Radiat. Oncol. Biol. Phys.* 62, 1070–1077. <https://doi.org/10.1016/j.ijrobp.2004.12.009>

Bhardwaj, B., Revannasiddaiah, S., Bhardwaj, H., Balusu, S., Shwaiki, A., 2016. Molecular targeted therapy to improve radiotherapeutic outcomes for non-small cell lung carcinoma. *Ann. Transl. Med.* 4, 50. <https://doi.org/10.3978/j.issn.2305-5839.2015.10.35>

Bhattacharyya, T., Kapoor, R., Bahl, A., Yadav, B.S., Singh, U., Joshi, K., Rane, S., Sharma, S.C., 2013. Carcinoma lung presenting with choroidal metastasis as initial presentation: a rarity. *J. Cancer Res. Ther.* 9, 504–506. <https://doi.org/10.4103/0973-1482.119361>

Bierman, H.R., Byron, R.L., Kelley, K.H., Grady, A., 1951. Studies on the blood supply of tumors in man. III. Vascular patterns of the liver by hepatic arteriography in vivo. *J. Natl. Cancer Inst.* 12, 107–131.

Bilaniuk, L.T., Schenck, J.F., Zimmerman, R.A., Hart, H.R., Foster, T.H., Edelstein, W.A., Goldberg, H.I., Grossman, R.I., 1985. Ocular and orbital lesions: surface coil MR imaging. *Radiology* 156, 669–674. <https://doi.org/10.1148/radiology.156.3.4023227>

Bill, A., Törnquist, P., Alm, A., 1980. Permeability of the intraocular blood vessels. *Trans. Ophthalmol. Soc. U. K.* 100, 332–336.

Bloch, R.S., Gartner, S., 1971. The incidence of ocular metastatic carcinoma. *Arch. Ophthalmol. Chic. Ill* 1960 85, 673–675.

Borkar, D.S., Lacouture, M.E., Basti, S., 2013. Spectrum of ocular toxicities from epidermal growth factor receptor inhibitors and their intermediate-term follow-up: a five-year review. *Support. Care Cancer Off. J. Multinat. Assoc. Support. Care Cancer* 21, 1167–1174. <https://doi.org/10.1007/s00520-012-1645-y>

Borrelli, E., Sarraf, D., Freund, K.B., Sadda, S.R., 2018. OCT angiography and evaluation of the choroid and choroidal vascular disorders. *Prog. Retin. Eye Res.* <https://doi.org/10.1016/j.preteyeres.2018.07.002>

Boss, J.D., Lieu, P., Tewari, A., 2016. Effect of treatment of rectal cancer metastasis with intravitreal bevacizumab (Avastin) in patient with subretinal fluid and macular oedema: short-term follow-up. *BMJ Case Rep.* 2016. <https://doi.org/10.1136/bcr-2016-216273>

Bouhleb, L., Hofman, V., Maschi, C., Ilić, M., Allégra, M., Marquette, C.-H., Audigier-Valette, C., Thariat, J., Hofman, P., 2017. The liquid biopsy: a tool for a combined diagnostic and theranostic approach for care of a patient with late-stage lung carcinoma presenting with bilateral ocular metastases. *Expert Rev. Anticancer Ther.* 17, 1087–1092.

<https://doi.org/10.1080/14737140.2017.1398089>

- Boyd, S.R., Tan, D., Bunce, C., Gittos, A., Neale, M.H., Hungerford, J.L., Charnock-Jones, S., Cree, I.A., 2002. Vascular endothelial growth factor is elevated in ocular fluids of eyes harbouring uveal melanoma: identification of a potential therapeutic window. *Br. J. Ophthalmol.* 86, 448–452.
- Brown, G.C., Shields, J.A., Sanborn, G., Augsburger, J.J., Savino, P.J., Schatz, N.J., 1982. Radiation retinopathy. *Ophthalmology* 89, 1494–1501.
- Cancino, R., Vela, J.I., Sullivan, I., Buil, J.A., Muñoz, C.A., 2011. Regression of late onset choroidal metastasis from a breast carcinoma with letrozole. *Case Rep. Ophthalmol.* 2, 382–386. <https://doi.org/10.1159/000334937>
- Caujolle, J.-P., Mammar, H., Chamorey, E., Pinon, F., Herault, J., Gastaud, P., 2010. Proton Beam Radiotherapy for Uveal Melanomas at Nice Teaching Hospital: 16 Years' Experience. *Int. J. Radiat. Oncol. • Biol. • Phys.* 78, 98–103. <https://doi.org/10.1016/j.ijrobp.2009.07.1688>
- Cennamo, G., Romano, M.R., Breve, M.A., Velotti, N., Reibaldi, M., de Crecchio, G., Cennamo, G., 2017. Evaluation of choroidal tumors with optical coherence tomography: enhanced depth imaging and OCT-angiography features. *Eye Lond. Engl.* 31, 906–915. <https://doi.org/10.1038/eye.2017.14>
- Chambers, A.F., MacDonald, I.C., Schmidt, E.E., Koop, S., Morris, V.L., Khokha, R., Groom, A.C., 1995. Steps in tumor metastasis: new concepts from intravital videomicroscopy. *Cancer Metastasis Rev.* 14, 279–301.
- Chen, C.J., McCoy, A.N., Brahmer, J., Handa, J.T., 2011. Emerging treatments for choroidal metastases. *Surv. Ophthalmol.* 56, 511–521. <https://doi.org/10.1016/j.survophthal.2011.05.001>
- Chen, F.K., Viljoen, R.D., Bukowska, D.M., 2016. Classification of image artefacts in optical coherence tomography angiography of the choroid in macular diseases. *Clin. Experiment. Ophthalmol.* 44, 388–399. <https://doi.org/10.1111/ceo.12683>
- Chin, K., Finger, P.T., Kurli, M., Tena, L.B., Reddy, S., 2007. Second cancers discovered by (18)FDG PET/CT imaging for choroidal melanoma. *Optom. St Louis Mo* 78, 396–401. <https://doi.org/10.1016/j.optm.2007.03.013>
- Chiu-Tsao, S.-T., Astrahan, M.A., Finger, P.T., Followill, D.S., Meigooni, A.S., Melhus, C.S., Mourtada, F., Napolitano, M.E., Nath, R., Rivard, M.J., Rogers, D.W.O., Thomson, R.M., 2012. Dosimetry of (125)I and (103)Pd COMS eye plaques for intraocular tumors: report of Task Group 129 by the AAPM and ABS. *Med. Phys.* 39, 6161–6184. <https://doi.org/10.1118/1.4749933>
- Cho, K.R., Lee, K.M., Han, G., Kang, S.W., Lee, J.-I., 2018. Gamma Knife Radiosurgery for Cancer Metastasized to the Ocular Choroid. *J. Korean Neurosurg. Soc.* 61, 60–65. <https://doi.org/10.3340/jkns.2016.0606.003>
- Chu, C.-K., El-Annan, J., 2018. Photodynamic therapy for choroidal carcinoid metastasis. *Can. J. Ophthalmol. J. Can. Ophtalmol.* 53, e13–e16. <https://doi.org/10.1016/j.jcjo.2017.06.012>
- Cohen, V.M., Dinakaran, S., Parsons, M.A., Rennie, I.G., 2001. Transvitreal fine needle aspiration biopsy: the influence of intraocular lesion size on diagnostic biopsy result. *Eye Lond. Engl.* 15, 143–147. <https://doi.org/10.1038/eye.2001.48>
- Cohen, V.M.L., Moosavi, R., Hungerford, J.L., 2005. Tamoxifen-induced regression of a choroidal metastasis in a man. *Arch. Ophthalmol. Chic. Ill* 123, 1153–1154. <https://doi.org/10.1001/archophth.123.8.1153>
- Coleman, D.J., Abramson, D.H., Jack, R.L., Franzen, L.A., 1974. Ultrasonic diagnosis of tumors of the choroid. *Arch. Ophthalmol. Chic. Ill* 91, 344–354.
- Cronin, K.A., Lake, A.J., Scott, S., Sherman, R.L., Noone, A.-M., Howlader, N., Henley, S.J., Anderson, R.N., Firth, A.U., Ma, J., Kohler, B.A., Jemal, A., 2018. Annual Report to the

Nation on the Status of Cancer, part I: National cancer statistics. *Cancer* 124, 2785–2800. <https://doi.org/10.1002/cncr.31551>

Cui, Z.-H., Zhang, Y., Liang, L.-L., Li, Z.-H., Abramova, I., Hao, Q., 2017. Development of a new choroidal metastasis in resistance to crizotinib therapy in anaplastic lymphoma kinase-rearranged non-small cell lung cancer. *Int. J. Ophthalmol.* 10, 310–314. <https://doi.org/10.18240/ijo.2017.02.21>

d’Abbadie, I., Arriagada, R., Spielmann, M., Lê, M.G., 2003. Choroid metastases: clinical features and treatments in 123 patients. *Cancer* 98, 1232–1238. <https://doi.org/10.1002/cncr.11622>

Damato, B., 2018. Ocular treatment of choroidal melanoma in relation to the prevention of metastatic death - A personal view. *Prog. Retin. Eye Res.* <https://doi.org/10.1016/j.preteyeres.2018.03.004>

Damato, B., Eleuteri, A., Taktak, A.F.G., Coupland, S.E., 2011. Estimating prognosis for survival after treatment of choroidal melanoma. *Prog. Retin. Eye Res.* 30, 285–295. <https://doi.org/10.1016/j.preteyeres.2011.05.003>

Damato, B., Kacperek, A., Chopra, M., Campbell, I.R., Errington, R.D., 2005. Proton beam radiotherapy of choroidal melanoma: the Liverpool-Clatterbridge experience. *Int. J. Radiat. Oncol. Biol. Phys.* 62, 1405–1411. <https://doi.org/10.1016/j.ijrobp.2005.01.016>

Daniels, A.B., Miller, M.L., Kotecha, A., Abramson, D.H., 2010. Uveal metastasis from nonsmall cell lung carcinoma with dramatic response to erlotinib. *Retin. Cases Brief Rep.* 4, 390–393. <https://doi.org/10.1097/ICB.0b013e3181e180e6>

D’Antonio, C., Viterbo, A., Romiti, A., Enrici, M.M., Lauro, S., Marchetti, P., 2012. Complete regression of a non-small cell lung cancer choroidal metastasis with intravitreal bevacizumab. *J. Thorac. Oncol. Off. Publ. Int. Assoc. Study Lung Cancer* 7, 468–469. <https://doi.org/10.1097/JTO.0b013e3182398f7b>

de Bustros, S., Augsburger, J.J., Shields, J.A., Shakin, E.P., Pryor, C.C., 1985. Intraocular metastases from cutaneous malignant melanoma. *Arch. Ophthalmol. Chic. Ill* 1960 103, 937–940.

de Jong, M.C., de Graaf, P., Brisse, H.J., Galluzzi, P., Göricke, S.L., Moll, A.C., Munier, F.L., Popovic, M.B., Moulin, A.P., Binaghi, S., Castelijns, J.A., Maeder, P., European Retinoblastoma Imaging Collaboration (ERIC), 2015. The potential of 3T high-resolution magnetic resonance imaging for diagnosis, staging, and follow-up of retinoblastoma. *Surv. Ophthalmol.* 60, 346–355. <https://doi.org/10.1016/j.survophthal.2015.01.002>

de la Barquera Cordero, A.S., Hidalgo, R.A.C., 2010. Intravitreal bevacizumab for choroidal metastasis of lung carcinoma; a case report. *J. Ophthalmic Vis. Res.* 5, 265–268.

Del Amo, E.M., Rimpelä, A.-K., Heikkinen, E., Kari, O.K., Ramsay, E., Lajunen, T., Schmitt, M., Pelkonen, L., Bhattacharya, M., Richardson, D., Subrizi, A., Turunen, T., Reinisalo, M., Itkonen, J., Toropainen, E., Casteleijn, M., Kidron, H., Antopolsky, M., Vellonen, K.-S., Ruponen, M., Urtti, A., 2017. Pharmacokinetic aspects of retinal drug delivery. *Prog. Retin. Eye Res.* 57, 134–185. <https://doi.org/10.1016/j.preteyeres.2016.12.001>

Demirci, H., Cullen, A., Sundstrom, J.M., 2014. Enhanced depth imaging optical coherence tomography of choroidal metastasis. *Retina Phila. Pa* 34, 1354–1359. <https://doi.org/10.1097/IAE.0000000000000083>

Demirci, H., Shields, C.L., Chao, A.-N., Shields, J.A., 2003. Uveal metastasis from breast cancer in 264 patients. *Am. J. Ophthalmol.* 136, 264–271.

Dent, R., Trudeau, M., Pritchard, K.I., Hanna, W.M., Kahn, H.K., Sawka, C.A., Lickley, L.A., Rawlinson, E., Sun, P., Narod, S.A., 2007. Triple-negative breast cancer: clinical features and patterns of recurrence. *Clin. Cancer Res. Off. J. Am. Assoc. Cancer Res.* 13, 4429–4434. <https://doi.org/10.1158/1078-0432.CCR-06-3045>

De Ocampo, G., Espiritu, R., 1961. Bronchogenic metastatic carcinoma of the choroid. *Am. J.*

Ophthalmol. 52, 107–110.

De Potter, P., Shields, C.L., Shields, J.A., Tardio, D.J., 1993. Uveal metastasis from prostate carcinoma. *Cancer* 71, 2791–2796.

Detorakis, E.T., Agorogiannis, G., Drakonaki, E.E., Tsilimbaris, M.K., Pallikaris, I.G., 2012. Successful management of choroidal metastasis with intravitreal ranibizumab injections. *Ophthalmic Surg. Lasers Imaging Off. J. Int. Soc. Imaging Eye* 43 Online, e47–51. <https://doi.org/10.3928/15428877-20120517-03>

Dieckert, J.P., Berger, B.B., 1982. Prostatic carcinoma metastatic to choroid. *Br. J. Ophthalmol.* 66, 234–239.

Doig, R.G., Olver, I.N., Jeal, P.N., Bishop, J.F., 1992. Symptomatic choroidal metastases in breast cancer. *Aust. N. Z. J. Med.* 22, 349–352.

Dougherty, T.J., Gomer, C.J., Henderson, B.W., Jori, G., Kessel, D., Korbelik, M., Moan, J., Peng, Q., 1998. Photodynamic therapy. *J. Natl. Cancer Inst.* 90, 889–905.

Duke-Elder, S., Perkins, E., 1966. Diseases of the uveal tract, in: Volume IX: Diseases of the Uveal Tract, System of Ophthalmology. Duke-Elder S, St Louis, pp. 919–37.

Eagle, R.C., Ehya, H., Shields, J.A., Shields, C.L., 2000. Choroidal metastasis as the initial manifestation of a pigmented neuroendocrine tumor. *Arch. Ophthalmol. Chic. Ill* 1960 118, 841–845.

Earle, J., Kline, R.W., Robertson, D.M., 1987. Selection of iodine 125 for the Collaborative Ocular Melanoma Study. *Arch. Ophthalmol. Chic. Ill* 1960 105, 763–764.

Echegaray, J.J., Bechrakis, N.E., Singh, N., Bellerive, C., Singh, A.D., 2017. Iodine-125 Brachytherapy for Uveal Melanoma: A Systematic Review of Radiation Dose. *Ocul. Oncol. Pathol.* 3, 193–198. <https://doi.org/10.1159/000455872>

Eide, N., Walaas, L., 2009. Fine-needle aspiration biopsy and other biopsies in suspected intraocular malignant disease: a review. *Acta Ophthalmol. (Copenh.)* 87, 588–601. <https://doi.org/10.1111/j.1755-3768.2009.01637.x>

Eliassi-Rad, B., Albert, D.M., Green, W.R., 1996. Frequency of ocular metastases in patients dying of cancer in eye bank populations. *Br. J. Ophthalmol.* 80, 125–128.

Emami, B., Lyman, J., Brown, A., Coia, L., Goitein, M., Munzenrider, J.E., Shank, B., Solin, L.J., Wesson, M., 1991. Tolerance of normal tissue to therapeutic irradiation. *Int. J. Radiat. Oncol. Biol. Phys.* 21, 109–122.

Essadi, I., Lalya, I., Kriet, M., El Omrani, A., Belbaraka, R., Khouchani, M., 2017. Successful management of retinal metastasis from renal cancer with everolimus in a monophthalmic patient: a case report. *J. Med. Case Reports* 11. <https://doi.org/10.1186/s13256-017-1501-2>

Ewing, J., 1928. Neoplastic disease - A treatise on tumors. W.B. Saunders Co., Philadelphia.

Fabrini, M.G., Genovesi-Ebert, F., Perrone, F., De Liguoro, M., Giovannetti, C., Bogazzi, F., Rizzo, S., Martino, E., Cionini, L., 2009. A multimodal approach to the treatment of bilateral choroidal metastases from thyroid carcinoma. *Rare Tumors* 1. <https://doi.org/10.4081/rt.2009.e4>

Falke, K., Krüger, P., Hosten, N., Zimpfer, A., Guthoff, R., Langner, S., Stachs, O., 2013. Experimental differentiation of intraocular masses using ultrahigh-field magnetic resonance imaging--a case series. *PLoS One* 8, e81284. <https://doi.org/10.1371/journal.pone.0081284>

Feinstein, E., Kaliki, S., Shields, C.L., Ehya, H., Shields, J.A., 2014. Choroidal metastasis from leiomyosarcoma in two cases. *Oman J. Ophthalmol.* 7, 19–21. <https://doi.org/10.4103/0974-620X.127917>

Fenicia, V., Abdollahzadeh, S., Mannino, G., Verrilli, S., Balestrieri, M., Recupero, S.M., 2014. Intravitreal bevacizumab in the successful management of choroidal metastases secondary to lung and breast cancer unresponsive to systemic therapy: a case series. *Eye Lond. Engl.* 28, 888–891. <https://doi.org/10.1038/eye.2014.96>

Ferrara, D., Waheed, N.K., Duker, J.S., 2016. Investigating the choriocapillaris and choroidal

vasculature with new optical coherence tomography technologies. *Prog. Retin. Eye Res.* 52, 130–155. <https://doi.org/10.1016/j.preteyeres.2015.10.002>

Ferry, A.P., Font, R.L., 1974. Carcinoma metastatic to the eye and orbit. I. A clinicopathologic study of 227 cases. *Arch. Ophthalmol. Chic. Ill* 1960 92, 276–286.

Fidler, I.J., 1970. Metastasis: quantitative analysis of distribution and fate of tumor emboli labeled with <sup>125</sup>I-5-iodo-2'-deoxyuridine. *J. Natl. Cancer Inst.* 45, 773–782.

Fileta, J.B., Scott, I.U., Flynn, H.W., 2014. Meta-analysis of infectious endophthalmitis after intravitreal injection of anti-vascular endothelial growth factor agents. *Ophthalmic Surg. Lasers Imaging Retina* 45, 143–149. <https://doi.org/10.3928/23258160-20140306-08>

Fingar, V.H., Kik, P.K., Haydon, P.S., Cerrito, P.B., Tseng, M., Abang, E., Wieman, T.J., 1999. Analysis of acute vascular damage after photodynamic therapy using benzoporphyrin derivative (BPD). *Br. J. Cancer* 79, 1702–1708. <https://doi.org/10.1038/sj.bjc.6690271>

Finger, P.T., Marin, J.P., Berson, A.M., Kedhar, S., McCormick, S.A., 2003. Choroidal metastasis from adenoid cystic carcinoma of the lung. *Am. J. Ophthalmol.* 135, 239–241.

Fishman, M.L., Tomaszewski, M.M., Kuabara, T., 1976. Malignant melanoma of the skin metastatic to the eye. Frequency in autopsy series. *Arch. Ophthalmol. Chic. Ill* 1960 94, 1309–1311.

Folkman, J., 1986. How is blood vessel growth regulated in normal and neoplastic tissue? G.H.A. Clowes memorial Award lecture. *Cancer Res.* 46, 467–473.

Font, R.L., Naumann, G., Zimmerman, L.E., 1967. Primary malignant melanoma of the skin metastatic to the eye and orbit. Report of ten cases and review of the literature. *Am. J. Ophthalmol.* 63, 738–754.

Foulds, W.S., 1992. The uses and limitations of intraocular biopsy. *Eye Lond. Engl.* 6 ( Pt 1), 11–27. <https://doi.org/10.1038/eye.1992.3>

Francis, J.H., Habib, L.A., Abramson, D.H., Yannuzzi, L.A., Heinemann, M., Gounder, M.M., Grisham, R.N., Postow, M.A., Shoushtari, A.N., Chi, P., Segal, N.H., Yaeger, R., Ho, A.L., Chapman, P.B., Catalanotti, F., 2017. Clinical and Morphologic Characteristics of MEK Inhibitor-Associated Retinopathy: Differences from Central Serous Chorioretinopathy. *Ophthalmology* 124, 1788–1798. <https://doi.org/10.1016/j.ophtha.2017.05.038>

Freedman, M.I., Folk, J.C., 1987. Metastatic tumors to the eye and orbit. Patient survival and clinical characteristics. *Arch. Ophthalmol. Chic. Ill* 1960 105, 1215–1219.

Fuchs, E., 1882. *Das Sarcom des Uvealtractus*. W. Braumüller, Wien.

Fuller, D.G., Snyder, W.B., Hutton, W.L., Vaiser, A., 1979. Ultrasonographic features of choroidal malignant melanomas. *Arch. Ophthalmol. Chic. Ill* 1960 97, 1465–1472.

Funazo, T., Morita, K., Ikegami, N., Konishi, C., Nakao, S., Ariyasu, R., Taki, M., Nakagawa, K., Hwang, M.H., Yoshimura, C., Wakayama, T., Nishizaka, Y., 2017. Successful Treatment with Alectinib for Choroidal Metastasis in Anaplastic Lymphoma Kinase Rearranged Non-small Cell Lung Cancer. *Intern. Med.* 56, 2317–2320. <https://doi.org/10.2169/internalmedicine.8488-16>

George, B., Wirosko, W.J., Connor, T.B., Choong, N.W., 2009. Complete and durable response of choroid metastasis from non-small cell lung cancer with systemic bevacizumab and chemotherapy. *J. Thorac. Oncol. Off. Publ. Int. Assoc. Study Lung Cancer* 4, 661–662. <https://doi.org/10.1097/JTO.0b013e31819c9a73>

Ghadasra, D.H., Demirci, H., 2016. Photodynamic Therapy for Choroidal Metastasis. *Am. J. Ophthalmol.* 161, 104–109.e1–2. <https://doi.org/10.1016/j.ajo.2015.09.033>

Goldberg, M.F., Hodes, B.L., 1977. Ultrasonographic diagnosis of choroidal malignant melanoma. *Surv. Ophthalmol.* 22, 29–40.

Goldberg, R.A., Rootman, J., Cline, R.A., 1990. Tumors metastatic to the orbit: a changing picture. *Surv. Ophthalmol.* 35, 1–24.

Gragoudas, E.S., Goitein, M., Verhey, L., Munzenreider, J., Urie, M., Suit, H., Koehler, A.,



1982. Proton Beam Irradiation of Uveal Melanomas: Results of 5½-Year Study. *Arch. Ophthalmol.* 100, 928–934. <https://doi.org/10.1001/archopht.1982.01030030936007>

Greene, H.S., Harvey, E.K., 1964. THE RELATIONSHIP BETWEEN THE DISSEMINATION OF TUMOR CELLS AND THE DISTRIBUTION OF METASTASES. *Cancer Res.* 24, 799–811.

Grixti, A., Angi, M., Damato, B.E., Jmor, F., Konstantinidis, L., Groenewald, C., Heimann, H., 2014. Vitreoretinal surgery for complications of choroidal tumor biopsy. *Ophthalmology* 121, 2482–2488. <https://doi.org/10.1016/j.ophtha.2014.06.029>

Gutmann, S.M., Weiss, J.S., Albert, D.M., 1986. Choroidal metastasis of adenocystic carcinoma of the salivary gland. *Br. J. Ophthalmol.* 70, 100–103.

Haffty, B.G., Yang, Q., Reiss, M., Kearney, T., Higgins, S.A., Weidhaas, J., Harris, L., Hait, W., Toppmeyer, D., 2006. Locoregional relapse and distant metastasis in conservatively managed triple negative early-stage breast cancer. *J. Clin. Oncol. Off. J. Am. Soc. Clin. Oncol.* 24, 5652–5657. <https://doi.org/10.1200/JCO.2006.06.5664>

Haimovici, R., Gragoudas, E.S., Gregor, Z., Pesavento, R.D., Mieler, W.F., Duker, J.S., 1997. Choroidal metastases from renal cell carcinoma. *Ophthalmology* 104, 1152–1158.

Hammond, M.E.H., Hayes, D.F., Dowsett, M., Allred, D.C., Hagerty, K.L., Badve, S., Fitzgibbons, P.L., Francis, G., Goldstein, N.S., Hayes, M., Hicks, D.G., Lester, S., Love, R., Mangu, P.B., McShane, L., Miller, K., Osborne, C.K., Paik, S., Perlmutter, J., Rhodes, A., Sasano, H., Schwartz, J.N., Sweep, F.C.G., Taube, S., Torlakovic, E.E., Valenstein, P., Viale, G., Visscher, D., Wheeler, T., Williams, R.B., Wittliff, J.L., Wolff, A.C., 2010. American Society of Clinical Oncology/College Of American Pathologists guideline recommendations for immunohistochemical testing of estrogen and progesterone receptors in breast cancer. *J. Clin. Oncol. Off. J. Am. Soc. Clin. Oncol.* 28, 2784–2795. <https://doi.org/10.1200/JCO.2009.25.6529>

Harbour, J.W., 2007. Molecular prognostic testing in uveal melanoma: has it finally come of age? *Arch. Ophthalmol. Chic. Ill* 125, 1122–1123. <https://doi.org/10.1001/archopht.125.8.1122>

Harbour, J.W., 2004. Photodynamic therapy for choroidal metastasis from carcinoid tumor. *Am. J. Ophthalmol.* 137, 1143–1145. <https://doi.org/10.1016/j.ajo.2004.01.009>

Harbour, J.W., De Potter, P., Shields, C.L., Shields, J.A., 1994. Uveal metastasis from carcinoid tumor. Clinical observations in nine cases. *Ophthalmology* 101, 1084–1090.

Hedley, B.D., Chambers, A.F., 2009. Tumor dormancy and metastasis. *Adv. Cancer Res.* 102, 67–101. [https://doi.org/10.1016/S0065-230X\(09\)02003-X](https://doi.org/10.1016/S0065-230X(09)02003-X)

Heiduschka, P., Fietz, H., Hofmeister, S., Schultheiss, S., Mack, A.F., Peters, S., Ziemssen, F., Niggemann, B., Julien, S., Bartz-Schmidt, K.U., Schraermeyer, U., 2007. Penetration of Bevacizumab through the Retina after Intravitreal Injection in the Monkey. *Invest. Ophthalmol. Vis. Sci.* 48, 2814–2823. <https://doi.org/10.1167/iovs.06-1171>

Heitzer, E., Ulz, P., Geigl, J.B., 2015. Circulating Tumor DNA as a Liquid Biopsy for Cancer. *Clin. Chem.* 61, 112–123. <https://doi.org/10.1373/clinchem.2014.222679>

Hellman, S., Weichselbaum, R.R., 1995. Oligometastases. *J. Clin. Oncol. Off. J. Am. Soc. Clin. Oncol.* 13, 8–10. <https://doi.org/10.1200/JCO.1995.13.1.8>

Hench, I.B., Hench, J., Tolnay, M., 2018. Liquid Biopsy in Clinical Management of Breast, Lung, and Colorectal Cancer. *Front. Med.* 5, 9. <https://doi.org/10.3389/fmed.2018.00009>

Heng, D.Y.C., Xie, W., Regan, M.M., Harshman, L.C., Bjarnason, G.A., Vaishampayan, U.N., Mackenzie, M., Wood, L., Donskov, F., Tan, M.-H., Rha, S.-Y., Agarwal, N., Kollmannsberger, C., Rini, B.I., Choueiri, T.K., 2013. External validation and comparison with other models of the International Metastatic Renal-Cell Carcinoma Database Consortium prognostic model: a population-based study. *Lancet Oncol.* 14, 141–148. [https://doi.org/10.1016/S1470-2045\(12\)70559-4](https://doi.org/10.1016/S1470-2045(12)70559-4)

Hosoya, K., Tomi, M., 2005. Advances in the cell biology of transport via the inner blood-retinal barrier: establishment of cell lines and transport functions. *Biol. Pharm. Bull.* 28, 1–8.

Howlander, N., Cronin, K.A., Kurian, A.W., Andridge, R., 2018. Differences in Breast Cancer Survival by Molecular Subtypes in the United States. *Cancer Epidemiol. Biomark. Prev. Publ. Am. Assoc. Cancer Res. Cosponsored Am. Soc. Prev. Oncol.* 27, 619–626. <https://doi.org/10.1158/1055-9965.EPI-17-0627>

Ho, Y.K., Smith, R.G., Brown, M.S., Goldstein, J.L., 1978. Low-density lipoprotein (LDL) receptor activity in human acute myelogenous leukemia cells. *Blood* 52, 1099–1114.

Hua, R., Li, W., Wu, W., Tao, J., Peng, Q., 2017. Failure of ocular photodynamic therapy for secondary choroidal metastasis: a case report and literature review. *Oncotarget* 8, 95030–95035. <https://doi.org/10.18632/oncotarget.21847>

Inoue, M., Watanabe, Y., Yamane, S., Kobayashi, S., Arakawa, A., Tsukahara, T., Kaneko, T., Kadonosono, K., 2010. Choroidal metastasis with adenocarcinoma of the lung treated with gefitinib. *Eur. J. Ophthalmol.* 20, 963–965.

Ishida, T., Morohoshi, K., Takeuchi, Y., Soma, R., Uchida, M., Ohno-Matsui, K., 2017. Swept-source optical coherence tomographic findings in eyes with metastatic choroidal tumor. *Am. J. Ophthalmol. Case Rep.* 8, 44–47. <https://doi.org/10.1016/j.ajoc.2017.10.005>

Ishida, T., Ohno-Matsui, K., Kaneko, Y., Tobita, H., Hayashi, K., Shimada, N., Mochizuki, M., 2009. Autofluorescence of metastatic choroidal tumor. *Int. Ophthalmol.* 29, 309–313. <https://doi.org/10.1007/s10792-008-9234-2>

Isidori, A.M., Kaltsas, G., Frajese, V., Kola, B., Whitelocke, R. a. F., Plowman, P.N., Britton, K.E., Monson, J.P., Grossman, A.B., Besser, G.M., 2002. Ocular metastases secondary to carcinoid tumors: the utility of imaging with [(123)I]meta-iodobenzylguanidine and [(111)In]DTPA pentetreotide. *J. Clin. Endocrinol. Metab.* 87, 1627–1633. <https://doi.org/10.1210/jcem.87.4.8407>

Isola, V., Pece, A., Pierro, L., 2006. Photodynamic therapy with verteporfin of choroidal malignancy from breast cancer. *Am. J. Ophthalmol.* 142, 885–887. <https://doi.org/10.1016/j.ajo.2006.06.008>

Jamieson, C.H., McDonald, W.N., Levy, J.G., 1990. Preferential uptake of benzoporphyrin derivative by leukemic versus normal cells. *Leuk. Res.* 14, 209–219.

Jampol, L.M., Cottle, E., Fischer, D.S., Albert, D.M., 1973. Metastasis of Ewing's sarcoma to the choroid. *Arch. Ophthalmol. Chic. Ill* 1960 89, 207–209.

Jardel, P., Sauerwein, W., Olivier, T., Bensoussan, E., Maschi, C., Lanza, F., Mosci, C., Gastaud, L., Angellier, G., Marcy, P.-Y., Herault, J., Caujolle, J.-P., Dendale, R., Thariat, J., 2014. Management of choroidal metastases. *Cancer Treat. Rev.* 40, 1119–1128. <https://doi.org/10.1016/j.ctrv.2014.09.006>

Jeganathan, V.S.E., Wirth, A., MacManus, M.P., 2011. Ocular risks from orbital and periorbital radiation therapy: a critical review. *Int. J. Radiat. Oncol. Biol. Phys.* 79, 650–659. <https://doi.org/10.1016/j.ijrobp.2010.09.056>

Jensen, O.A., 1970. Metastatic tumours of the eye and orbit. A histopathological analysis of a Danish series. *Acta Pathol. Microbiol. Scand. Suppl.* 212, Suppl 212:201+.

Jiang, T., Min, W., Li, Y., Yue, Z., Wu, C., Zhou, C., 2016. Radiotherapy plus EGFR TKIs in non-small cell lung cancer patients with brain metastases: an update meta-analysis. *Cancer Med.* 5, 1055–1065. <https://doi.org/10.1002/cam4.673>

Johnstone, S., Logan, R.M., 2007. Expression of vascular endothelial growth factor (VEGF) in normal oral mucosa, oral dysplasia and oral squamous cell carcinoma. *Int. J. Oral Maxillofac. Surg.* 36, 263–266. <https://doi.org/10.1016/j.ijom.2006.09.017>

Jordán, J., Ruíz-Moreno, J.M., 2013. Advances in the understanding of retinal drug disposition and the role of blood-ocular barrier transporters. *Expert Opin. Drug Metab. Toxicol.* 9, 1181–1192. <https://doi.org/10.1517/17425255.2013.796928>

Kaliki, S., Shields, C.L., Al-Dahmash, S.A., Mashayekhi, A., Shields, J.A., 2012. Photodynamic therapy for choroidal metastasis in 8 cases. *Ophthalmology* 119, 1218–1222. <https://doi.org/10.1016/j.ophtha.2011.12.024>

Kamran, S.C., Collier, J.M., Lane, A.M., Kim, I., Niemierko, A., Chen, Y.-L.E., MacDonald, S.M., Munzenrider, J.E., Gragoudas, E., Shih, H.A., 2014. Outcomes of proton therapy for the treatment of uveal metastases. *Int. J. Radiat. Oncol. Biol. Phys.* 90, 1044–1050. <https://doi.org/10.1016/j.ijrobp.2014.08.003>

Karapetis, C.S., Khambata-Ford, S., Jonker, D.J., O’Callaghan, C.J., Tu, D., Tebbutt, N.C., Simes, R.J., Chalchal, H., Shapiro, J.D., Robitaille, S., Price, T.J., Shepherd, L., Au, H.-J., Langer, C., Moore, M.J., Zalcberg, J.R., 2008. K-ras mutations and benefit from cetuximab in advanced colorectal cancer. *N. Engl. J. Med.* 359, 1757–1765. <https://doi.org/10.1056/NEJMoa0804385>

Kawakami, S., Wakabayashi, Y., Goto, H., 2013. A case of presumed choroidal metastasis from carcinoid tumor treated by photodynamic therapy with verteporfin. *Clin. Ophthalmol. Auckl. NZ* 7, 2003–2006. <https://doi.org/10.2147/OPHTH.S51196>

Kim, S.-W., Kim, M.J., Huh, K., Oh, J., 2009. Complete regression of choroidal metastasis secondary to non-small-cell lung cancer with intravitreal bevacizumab and oral erlotinib combination therapy. *Ophthalmol. J. Int. Ophthalmol. Z. Augenheilkd.* 223, 411–413. <https://doi.org/10.1159/000229307>

Kindermann, W.R., Shields, J.A., Eiferman, R.A., Stephens, R.F., Hirsch, S.E., 1981. Metastatic renal cell carcinoma to the eye and adnexae: a report of three cases and review of the literature. *Ophthalmology* 88, 1347–1350.

Kinsey, D.L., 1960. An experimental study of preferential metastasis. *Cancer* 13, 674–676.

Konstantinidis, L., Damato, B., 2017. Intraocular Metastases--A Review. *Asia-Pac. J. Ophthalmol. Phila. Pa* 6, 208–214. <https://doi.org/10.22608/APO.201712>

Konstantinidis, L., Rospond-Kubiak, I., Zeolite, I., Heimann, H., Groenewald, C., Coupland, S.E., Damato, B., 2014. Management of patients with uveal metastases at the Liverpool Ocular Oncology Centre. *Br. J. Ophthalmol.* 98, 92–98. <https://doi.org/10.1136/bjophthalmol-2013-303519>

Kourie, H.R., Antoun, J., Schakal, A., Nasr, E., Sahyoun, M., Kattan, J., 2015. Complete Disappearance of Choroidal Metastasis from Lung Adenocarcinoma Treated with Bevacizumab and Chemotherapy. *Case Rep. Ophthalmol. Med.* 2015, 142408. <https://doi.org/10.1155/2015/142408>

Kreusel, K.-M., Bechrakis, N.E., Wiegel, T., Krause, L., Foerster, M.H., 2008. Incidence and clinical characteristics of symptomatic choroidal metastasis from lung cancer. *Acta Ophthalmol. (Copenh.)* 86, 515–519. <https://doi.org/10.1111/j.1600-0420.2007.01081.x>

Kreusel, K.-M., Wiegel, T., Stange, M., Bornfeld, N., Hinkelbein, W., Foerster, M.H., 2002. Choroidal metastasis in disseminated lung cancer: frequency and risk factors. *Am. J. Ophthalmol.* 134, 445–447.

Krohn-Hansen, D., Strøm, E.H., Charles, S.J., Bakken, K.E., 1999. Carcinoma of the ovary with primary presentation in the choroid. *Acta Ophthalmol. Scand.* 77, 713–716.

Kuhn, M., Shah, S., Natasha, T., Rittling, S.R., 2005. A mouse model of breast cancer metastasis to the choroid of the eye. *Clin. Exp. Metastasis* 22, 685–690. <https://doi.org/10.1007/s10585-006-9012-3>

Kuo, I.C., Haller, J.A., Maffrand, R., Sambuelli, R.H., Reviglio, V.E., 2008. Regression of a subfoveal choroidal metastasis of colorectal carcinoma after intravitreal bevacizumab treatment. *Arch. Ophthalmol. Chic. Ill* 126, 1311–1313. <https://doi.org/10.1001/archophthalmol.2008.2>

Kuperman, V.Y., 2018. Effect of radiation protraction in hypofractionated radiotherapy. *Med. Phys.* 45, 3442–3448. <https://doi.org/10.1002/mp.12936>

Lai, C.-L., Fan, K.-S., Lee, Y.-H., Chen, H.-C., Fan, W.-H., 2012. Intravitreal administration of bevacizumab in the treatment of choroidal metastasis in a patient with erlotinib-failed pulmonary adenocarcinoma. *Lung Cancer Amst. Neth.* 76, 496–498. <https://doi.org/10.1016/j.lungcan.2012.02.020>

Langham, M.E., Kramer, T., 1990. Decreased choroidal blood flow associated with retinitis pigmentosa. *Eye Lond. Engl.* 4 ( Pt 2), 374–381. <https://doi.org/10.1038/eye.1990.50>

Langley, R.R., Fidler, I.J., 2011. The seed and soil hypothesis revisited--the role of tumor-stroma interactions in metastasis to different organs. *Int. J. Cancer* 128, 2527–2535. <https://doi.org/10.1002/ijc.26031>

Lemke, A.J., Hosten, N., Bornfeld, N., Bechrakis, N.E., Frenzel, D., Richter, M., Felix, R., 1998. [Appearance of choroidal melanoma on high resolution MRI using 1.5T with a dedicated surface coil in 200 consecutive patients]. *ROFO. Fortschr. Geb. Rontgenstr. Nuklearmed.* 169, 471–478. <https://doi.org/10.1055/s-2007-1015322>

Leshno, A., Vishnevskia-Dai, V., Barak, A., Zur, D., Gabai, S., Moroz, I., Neudorfer, M., 2017. OPTICAL DENSITY RATIO OF THE SUBRETINAL FLUID IN CHOROIDAL MELANOMA AND METASTASIS. *Retina Phila. Pa.* <https://doi.org/10.1097/IAE.0000000000001998>

Leung, C.K., Cheung, C.Y., Weinreb, R.N., Lee, G., Lin, D., Pang, C.P., Lam, D.S.C., 2008. Comparison of macular thickness measurements between time domain and spectral domain optical coherence tomography. *Invest. Ophthalmol. Vis. Sci.* 49, 4893–4897. <https://doi.org/10.1167/iovs.07-1326>

Leys, A.M., Van Eyck, L.M., Nuttin, B.J., Pauwels, P.A., Delabie, J.M., Libert, J.A., 1990. Metastatic carcinoma to the retina. Clinicopathologic findings in two cases. *Arch. Ophthalmol. Chic. Ill* 1960 108, 1448–1452.

Lim, J.I., Petrovich, Z., 2000. Radioactive plaque therapy for metastatic choroidal carcinoma. *Ophthalmology* 107, 1927–1931.

Lin, C.-C., Yang, J.C.-H., 2011. Optimal management of patients with non-small cell lung cancer and epidermal growth factor receptor mutations. *Drugs* 71, 79–88. <https://doi.org/10.2165/11587560-000000000-00000>

Lin, C.-J., Li, K.-H., Hwang, J.-F., Chen, S.-N., 2010. The effect of intravitreal bevacizumab treatment on choroidal metastasis of colon adenocarcinoma--case report. *Eye Lond. Engl.* 24, 1102–1103. <https://doi.org/10.1038/eye.2009.257>

Lin, C.-J., Tsai, Y.-Y., 2015. The effect of intravitreal bevacizumab and transpupillary thermotherapy on choroidal metastases and literature review. *Indian J. Ophthalmol.* 63, 37–41. <https://doi.org/10.4103/0301-4738.151465>

Lindner, T., Langner, S., Falke, K., Walter, U., Krüger, P.-C., Pohlmann, A., Zimpfer, A., Stahnke, T., Hadlich, S., Guthoff, R., Erbersdobler, A., Niendorf, T., Stachs, O., 2015. Anatomic and pathological characterization of choroidal melanoma using multimodal imaging: what is practical, what is needed? *Melanoma Res.* 25, 252–258. <https://doi.org/10.1097/CMR.0000000000000156>

Liu, C.Y., Francis, J.H., Brodie, S.E., Marr, B., Pulido, J.S., Marmor, M.F., Abramson, D.H., 2014. Retinal toxicities of cancer therapy drugs: biologics, small molecule inhibitors, and chemotherapies. *Retina Phila. Pa* 34, 1261–1280. <https://doi.org/10.1097/IAE.0000000000000242>

Lomax, M.E., Folkes, L.K., O'Neill, P., 2013. Biological consequences of radiation-induced DNA damage: relevance to radiotherapy. *Clin. Oncol. R. Coll. Radiol. G. B.* 25, 578–585. <https://doi.org/10.1016/j.clon.2013.06.007>

Lu, S., Azada, M.C., Ou, S.-H.I., 2015. Choroidal metastasis response to crizotinib in a ROS1-rearranged NSCLC patient. *Lung Cancer Amst. Neth.* 87, 207–209. <https://doi.org/10.1016/j.lungcan.2014.12.011>

Manquez, M.E., Brown, M.M., Shields, C.L., Shields, J.A., 2006. Management of choroidal metastases from breast carcinomas using aromatase inhibitors. *Curr. Opin. Ophthalmol.* 17, 251–256. <https://doi.org/10.1097/01.icu.0000193105.22960.f6>

Mansour, A.M., Alameddine, R., 2012. Intravitreal bevacizumab for consecutive multiple choroidal breast metastatic lesions. *BMJ Case Rep.* 2012. <https://doi.org/10.1136/bcr.03.2012.6124>

Maor, M., Chan, R.C., Young, S.E., 1977. Radiotherapy of choroidal metastases: breast cancer as primary site. *Cancer* 40, 2081–2086.

Maskell, D., Geropantas, K., Kouroupis, M., Glenn, A., Ajithkumar, T., 2017. Treatment of choice for patients with EGFR mutation-positive non-small cell lung carcinoma presenting with choroidal metastases: radiotherapy or TKIs? *Can. J. Ophthalmol. J. Can. Ophthalmol.* 52, e22–e25. <https://doi.org/10.1016/j.jcjo.2016.09.010>

Maturu, V.N., Singh, N., Bansal, P., Rai Mittal, B., Gupta, N., Behera, D., Gupta, A., 2014. Combination of intravitreal bevacizumab and systemic therapy for choroidal metastases from lung cancer: report of two cases and a systematic review of literature. *Med. Oncol. Northwood Lond. Engl.* 31, 901. <https://doi.org/10.1007/s12032-014-0901-z>

Maudgil, A., Sears, K.S., Rundle, P.A., Rennie, I.G., Salvi, S.M., 2015. Failure of intravitreal bevacizumab in the treatment of choroidal metastasis. *Eye Lond. Engl.* 29, 707–711. <https://doi.org/10.1038/eye.2015.21>

Mauget-Faÿsse, M., Gambrelle, J., Quaranta-El Maftouhi, M., Moullet, I., 2006. Photodynamic therapy for choroidal metastasis from lung adenocarcinoma. *Acta Ophthalmol. Scand.* 84, 552–554. <https://doi.org/10.1111/j.1600-0420.2006.00648.x>

Maurice, D.M., 2002. Drug delivery to the posterior segment from drops. *Surv. Ophthalmol.* 47 Suppl 1, S41–52.

Mbeutcha, A., Chauveinc, L., Bondiau, P.-Y., Chand, M.-E., Durand, M., Chevallier, D., Amiel, J., Kee, D.L.C., Hannoun-Lévi, J.-M., 2017. Salvage prostate re-irradiation using high-dose-rate brachytherapy or focal stereotactic body radiotherapy for local recurrence after definitive radiation therapy. *Radiat. Oncol. Lond. Engl.* 12, 49. <https://doi.org/10.1186/s13014-017-0789-9>

McCannel, T.A., 2013. Fine-needle aspiration biopsy in the management of choroidal melanoma. *Curr. Opin. Ophthalmol.* 24, 262–266. <https://doi.org/10.1097/ICU.0b013e32835ff001>

McCannel, T.A., Chang, M.Y., Burgess, B.L., 2012. Multi-year follow-up of fine-needle aspiration biopsy in choroidal melanoma. *Ophthalmology* 119, 606–610. <https://doi.org/10.1016/j.ophtha.2011.08.046>

McCartney, A., 1993. Intraocular metastasis. *Br. J. Ophthalmol.* 77, 133.

Meng, X., Zhong, J., Liu, S., Murray, M., Gonzalez-Angulo, A.M., 2012. A new hypothesis for the cancer mechanism. *Cancer Metastasis Rev.* 31, 247–268. <https://doi.org/10.1007/s10555-011-9342-8>

Merrill, C.F., Kaufman, D.I., Dimitrov, N.V., 1991. Breast cancer metastatic to the eye is a common entity. *Cancer* 68, 623–627.

Mewis, L., Young, S.E., 1982. Breast carcinoma metastatic to the choroid. Analysis of 67 patients. *Ophthalmology* 89, 147–151.

Meyer, K., Augsburger, J.J., 1999. Independent diagnostic value of fluorescein angiography in the evaluation of intraocular tumors. *Graefes Arch. Clin. Exp. Ophthalmol. Albrecht Von Graefes Arch. Klin. Exp. Ophthalmol.* 237, 489–494.

Moan, J., Berg, K., 1992. Photochemotherapy of cancer: experimental research. *Photochem. Photobiol.* 55, 931–948.

Moore, R.F., 1930. CHOROIDAL SARCOMA TREATED BY THE INTRAOCULAR INSERTION OF RADON SEEDS. *Br. J. Ophthalmol.* 14, 145–152.

Nabi, G., Dadeya, S., Dogra, P.N., Lal, H., 2002. Eye metastasis form urothelial tumours. *Int. Urol. Nephrol.* 34, 51–54.

Nadiminti, K., Leone, J.P., 2016. Intraocular bevacizumab in the treatment of choroidal metastases from breast cancer. *BMJ Case Rep.* 2016. <https://doi.org/10.1136/bcr-2016-215719>

Natesh, S., Chin, K.J., Finger, P.T., 2010. Choroidal metastases fundus autofluorescence imaging: correlation to clinical, OCT, and fluorescein angiographic findings. *Ophthalmic Surg. Lasers Imaging Off. J. Int. Soc. Imaging Eye* 41, 406–412. <https://doi.org/10.3928/15428877-20100426-03>

Nathoo, N., Chahlavi, A., Barnett, G.H., Toms, S.A., 2005. Pathobiology of brain metastases. *J. Clin. Pathol.* 58, 237–242. <https://doi.org/10.1136/jcp.2003.013623>

Nelson, C.C., Hertzberg, B.S., Klintworth, G.K., 1983. A histopathologic study of 716 unselected eyes in patients with cancer at the time of death. *Am. J. Ophthalmol.* 95, 788–793.

Neudorfer, M., Waisbourd, M., Anteby, I., Liran, A., Goldenberg, D., Barak, A., Kessler, A., 2011. Color flow mapping: a non-invasive tool for characterizing and differentiating between uveal melanomas and choroidal metastases. *Oncol. Rep.* 25, 91–96.

Neudorfer, M., Weinberg, A., Loewenstein, A., Barak, A., 2012. Differential optical density of subretinal spaces. *Invest. Ophthalmol. Vis. Sci.* 53, 3104–3110. <https://doi.org/10.1167/iovs.11-8700>

Newman, D.K., 2016. Photodynamic therapy: current role in the treatment of chorioretinal conditions. *Eye Lond. Engl.* 30, 202–210. <https://doi.org/10.1038/eye.2015.251>

Nishida, N., Yano, H., Nishida, T., Kamura, T., Kojiro, M., 2006. Angiogenesis in Cancer. *Vasc. Health Risk Manag.* 2, 213–219.

Okuma, Y., Tanaka, Y., Kamei, T., Hosomi, Y., Okamura, T., 2015. Alectinib for choroidal metastasis in a patient with crizotinib-resistant ALK rearranged positive non-small cell lung cancer. *OncoTargets Ther.* 8, 1321–1325. <https://doi.org/10.2147/OTT.S83179>

Overgaard, J., 1996. Uveal malignant melanoma. An ophthalmological or oncological disease? *Acta Ophthalmol. Scand.* 74, 313.

Packer, S., Rotman, M., 1980. Radiotherapy of choroidal melanoma with iodine-125. *Ophthalmology* 87, 582–590.

Packer, S., Rotman, M., Fairchild, R.G., Albert, D.M., Atkins, H.L., Chan, B., 1980. Irradiation of choroidal melanoma with iodine 125 ophthalmic plaque. *Arch. Ophthalmol. Chic. Ill* 1960 98, 1453–1457.

Paget, S., 1889. The distribution of secondary growths in cancer of the breast. 1889. *Cancer Metastasis Rev.* 8, 98–101.

Papageorgiou, K.I., Sinha, A., Ioannidis, A.S., Davidson, N.G., 2009. Ocular metastases from HER2 positive breast carcinoma and the response to combination therapy with Paclitaxel and Trastuzumab: a case report. *Cases J.* 2, 9143. <https://doi.org/10.1186/1757-1626-2-9143>

Paris, S., Sesboué, R., 2004. Metastasis models: the green fluorescent revolution? *Carcinogenesis* 25, 2285–2292. <https://doi.org/10.1093/carcin/bgh219>

Parrozzani, R., Frizziero, L., Testi, I., Miglionico, G., Perrini, P., Pulze, S., Pilotto, E., Midena, E., 2016. Intraocular Metastases Secondary to Breast Carcinoma Correlates With Upregulation of Estrogen and Progesterone Receptor Expression in the Primary Tumor. *Invest. Ophthalmol. Vis. Sci.* 57, 3944–3948. <https://doi.org/10.1167/iovs.16-19695>

Parsons, J.T., Bova, F.J., Fitzgerald, C.R., Mendenhall, W.M., Million, R.R., 1994. Radiation optic neuropathy after megavoltage external-beam irradiation: analysis of time-dose factors. *Int. J. Radiat. Oncol. Biol. Phys.* 30, 755–763.

Perls, M., 1872. Beitrage zur geschwulstlehre. *Virschows Arch* 1, 437–67.

Perri, P., Chiarelli, M., Monari, P., Ravalli, L., Mazzeo, V., 1992. Choroidal metastases. Echographic experience from 42 patients. *Acta Ophthalmol. Suppl.* 96–98.

Peyster, R.G., Augsburger, J.J., Shields, J.A., Hershey, B.L., Eagle, R., Haskin, M.E., 1988. Intraocular tumors: evaluation with MR imaging. *Radiology* 168, 773–779. <https://doi.org/10.1148/radiology.168.3.3406407>

Primavera, V., Querques, G., Guigui, B., Turco, I., Iaculli, C., Russo, V., Delle Noci, N., 2008. [Choroidal metastasis from clinically regressed prostate adenocarcinoma: imaging of a rare case]. *J. Fr. Ophtalmol.* 31, 877–882.

Ramaesh, K., Marshall, J.W., Wharton, S.B., Dhillon, B., 1999. Intraocular metastases of cutaneous malignant melanoma: a case report and review of the literature. *Eye Lond. Engl.* 13 ( Pt 2), 247–250. <https://doi.org/10.1038/eye.1999.60>

Rao, R.C., Gragoudas, E.S., 2015. Choroidal Metastases From EML4-ALK-Positive Non-Small-Cell Lung Adenocarcinoma. *J. Clin. Oncol. Off. J. Am. Soc. Clin. Oncol.* 33, e112–114. <https://doi.org/10.1200/JCO.2013.50.2740>

Rapicetta, C., Falco, F., Roncali, M., Treglia, G., Carbonelli, C., Paci, M., Marchi, S., Lococo, F., 2015. Solitary choroidal metastasis from atypical carcinoid of the lung detected by (68)Ga DOTATATE PET/CT. *Clin. Nucl. Med.* 40, e319–320. <https://doi.org/10.1097/RLU.0000000000000660>

Ritland, J.S., Eide, N., Walaas, L., Høie, J., 1999. Fine-needle aspiration biopsy diagnosis of a uveal metastasis from a follicular thyroid carcinoma. *Acta Ophthalmol. Scand.* 77, 594–596.

Roberts, W.G., Hasan, T., 1992. Role of neovasculature and vascular permeability on the tumor retention of photodynamic agents. *Cancer Res.* 52, 924–930.

Rosell, R., Carcereny, E., Gervais, R., Vergnenegre, A., Massuti, B., Felip, E., Palmero, R., Garcia-Gomez, R., Pallares, C., Sanchez, J.M., Porta, R., Cobo, M., Garrido, P., Longo, F., Moran, T., Insa, A., De Marinis, F., Corre, R., Bover, I., Illiano, A., Dansin, E., de Castro, J., Milella, M., Reguart, N., Altavilla, G., Jimenez, U., Provencio, M., Moreno, M.A., Terrasa, J., Muñoz-Langa, J., Valdivia, J., Isla, D., Domine, M., Molinier, O., Mazieres, J., Baize, N., Garcia-Campelo, R., Robinet, G., Rodriguez-Abreu, D., Lopez-Vivanco, G., Gebbia, V., Ferrera-Delgado, L., Bombaron, P., Bernabe, R., Bearz, A., Artal, A., Cortesi, E., Rolfo, C., Sanchez-Ronco, M., Drozdowskyj, A., Queralt, C., de Aguirre, I., Ramirez, J.L., Sanchez, J.J., Molina, M.A., Taron, M., Paz-Ares, L., Spanish Lung Cancer Group in collaboration with Groupe Français de Pneumo-Cancérologie and Associazione Italiana Oncologia Toracica, 2012. Erlotinib versus standard chemotherapy as first-line treatment for European patients with advanced EGFR mutation-positive non-small-cell lung cancer (EURTAC): a multicentre, open-label, randomised phase 3 trial. *Lancet Oncol.* 13, 239–246. [https://doi.org/10.1016/S1470-2045\(11\)70393-X](https://doi.org/10.1016/S1470-2045(11)70393-X)

Rosset, A., Zografos, L., Coucke, P., Monney, M., Mirimanoff, R.O., 1998. Radiotherapy of choroidal metastases. *Radiother. Oncol. J. Eur. Soc. Ther. Radiol. Oncol.* 46, 263–268.

Rotman, M., Long, R.S., Packer, S., Moroson, H., Galin, M.A., Chan, B., 1977. Radiation therapy of choroidal melanoma. *Trans. Ophthalmol. Soc. U. K.* 97, 431–435.

Röttinger, E.M., Heckemann, R., Scherer, E., Vogel, M., Meyer-Schwickerath, G., 1976. Radiation therapy of choroidal metastases from breast cancer. *Albrecht Von Graefes Arch. Klin. Exp. Ophthalmol.* 200, 243–250.

Rudoler, S.B., Corn, B.W., Shields, C.L., De Potter, P., Hyslop, T., Shields, J.A., Curran, W.J., 1997a. External beam irradiation for choroid metastases: identification of factors predisposing to long-term sequelae. *Int. J. Radiat. Oncol. Biol. Phys.* 38, 251–256.

Rudoler, S.B., Shields, C.L., Corn, B.W., De Potter, P., Hyslop, T., Curran, W.J., Shields, J.A., 1997b. Functional vision is improved in the majority of patients treated with external-beam radiotherapy for choroid metastases: a multivariate analysis of 188 patients. *J. Clin. Oncol. Off. J. Am. Soc. Clin. Oncol.* 15, 1244–1251. <https://doi.org/10.1200/JCO.1997.15.3.1244>

Schackert, G., Fidler, I.J., 1988. Site-specific metastasis of mouse melanomas and a

fibrosarcoma in the brain or meninges of syngeneic animals. *Cancer Res.* 48, 3478–3484.

Schalenbourg, A., Moulin, A., Guillou, L., Zografos, L., 2011. Metastatic choroidal paraganglioma. *Ophthalmology* 118, 2238–2241. <https://doi.org/10.1016/j.ophtha.2011.04.017>

Schmidt-Erfurth, U., Diddens, H., Birngruber, R., Hasan, T., 1997. Photodynamic targeting of human retinoblastoma cells using covalent low-density lipoprotein conjugates. *Br. J. Cancer* 75, 54–61.

Sellam, A., Desjardins, L., Barnhill, R., Plancher, C., Asselain, B., Savignoni, A., Pierron, G., Cassoux, N., 2016. Fine Needle Aspiration Biopsy in Uveal Melanoma: Technique, Complications, and Outcomes. *Am. J. Ophthalmol.* 162, 28–34.e1. <https://doi.org/10.1016/j.ajo.2015.11.005>

Sen, J., Groenewald, C., Hiscott, P.S., Smith, P.A., Damato, B.E., 2006. Transretinal choroidal tumor biopsy with a 25-gauge vitrector. *Ophthalmology* 113, 1028–1031. <https://doi.org/10.1016/j.ophtha.2006.02.048>

Seregard, S., All-Ericsson, C., Hjelmqvist, L., Berglin, L., Kvanta, A., 2013. Diagnostic incisional biopsies in clinically indeterminate choroidal tumours. *Eye Lond. Engl.* 27, 115–118. <https://doi.org/10.1038/eye.2012.219>

Shahar, J., Avery, R.L., Heilweil, G., Barak, A., Zemel, E., Lewis, G.P., Johnson, P.T., Fisher, S.K., Perlman, I., Loewenstein, A., 2006. Electrophysiologic and retinal penetration studies following intravitreal injection of bevacizumab (Avastin). *Retina Phila. Pa* 26, 262–269.

Shah, S.U., Mashayekhi, A., Shields, C.L., Walia, H.S., Hubbard, G.B., Zhang, J., Shields, J.A., 2014. Uveal metastasis from lung cancer: clinical features, treatment, and outcome in 194 patients. *Ophthalmology* 121, 352–357. <https://doi.org/10.1016/j.ophtha.2013.07.014>

Shibamoto, Y., Miyakawa, A., Otsuka, S., Iwata, H., 2016. Radiobiology of hypofractionated stereotactic radiotherapy: what are the optimal fractionation schedules? *J. Radiat. Res. (Tokyo)* 57 Suppl 1, i76–i82. <https://doi.org/10.1093/jrr/rww015>

Shields, C.L., 1998. Plaque radiotherapy for the management of uveal metastasis. *Curr. Opin. Ophthalmol.* 9, 31–37.

Shields, C.L., Ganguly, A., Materin, M.A., Teixeira, L., Mashayekhi, A., Swanson, L.A., Marr, B.P., Shields, J.A., 2007a. Chromosome 3 analysis of uveal melanoma using fine-needle aspiration biopsy at the time of plaque radiotherapy in 140 consecutive cases: the Deborah Iverson, MD, Lectureship. *Arch. Ophthalmol. Chic. Ill* 125, 1017–1024. <https://doi.org/10.1001/archophth.125.8.1017>

Shields, C.L., Kaliki, S., Rojanaporn, D., Ferenczy, S.R., Shields, J.A., 2012. Enhanced depth imaging optical coherence tomography of small choroidal melanoma: comparison with choroidal nevus. *Arch. Ophthalmol. Chic. Ill* 130, 850–856. <https://doi.org/10.1001/archophthalmol.2012.1135>

Shields, C.L., Materin, M.A., Teixeira, L., Mashayekhi, A., Ganguly, A., Shields, J.A., 2007b. Small choroidal melanoma with chromosome 3 monosomy on fine-needle aspiration biopsy. *Ophthalmology* 114, 1919–1924. <https://doi.org/10.1016/j.ophtha.2007.04.054>

Shields, C.L., Say, E.A.T., Stanciu, N.A., Bianciotto, C., Danzig, C.J., Shields, J.A., 2011. Cavitory choroidal metastasis from lung neuroendocrine tumor: report of 3 cases. *Arch. Ophthalmol. Chic. Ill* 129, 102–104. <https://doi.org/10.1001/archophthalmol.2010.329>

Shields, C.L., Shields, J.A., De Potter, P., 1995a. Patterns of indocyanine green videoangiography of choroidal tumours. *Br. J. Ophthalmol.* 79, 237–245.

Shields, C.L., Shields, J.A., De Potter, P., Quaranta, M., Freire, J., Brady, L.W., Barrett, J., 1997a. Plaque radiotherapy for the management of uveal metastasis. *Arch. Ophthalmol. Chic. Ill* 115, 203–209.

Shields, C.L., Shields, J.A., De Potter, P., Singh, A.D., Hernandez, C., Brady, L.W., 1995b.



Treatment of non-resectable malignant iris tumours with custom designed plaque radiotherapy. *Br. J. Ophthalmol.* 79, 306–312.

Shields, C.L., Shields, J.A., Gross, N.E., Schwartz, G.P., Lally, S.E., 1997b. Survey of 520 eyes with uveal metastases. *Ophthalmology* 104, 1265–1276.

Shields, J.A., Carvalho, C., Shields, C.L., Singh, A.D., Wagner, D., 2000a. Bilateral choroidal metastasis from adenoid cystic carcinoma of the submandibular gland. *Retina Phila. Pa* 20, 406–407.

Shields, J.A., Shields, C.L., Ehya, H., Eagle, R.C., De Potter, P., 1993. Fine-needle aspiration biopsy of suspected intraocular tumors. The 1992 Urwick Lecture. *Ophthalmology* 100, 1677–1684.

Shields, J.A., Shields, C.L., Kiratli, H., de Potter, P., 1995. Metastatic tumors to the iris in 40 patients. *Am. J. Ophthalmol.* 119, 422–430.

Shields, J.A., Shields, C.L., Singh, A.D., 2000b. Metastatic neoplasms in the optic disc: the 1999 Bjerrum Lecture: part 2. *Arch. Ophthalmol. Chic. Ill* 1960 118, 217–224.

Shimomura, I., Tada, Y., Miura, G., Suzuki, T., Matsumura, T., Tsushima, K., Terada, J., Kurimoto, R., Sakaida, E., Sekine, I., Takiguchi, Y., Yamamoto, S., Tatsumi, K., 2013. Choroidal metastasis of non-small cell lung cancer that responded to gefitinib. *Case Rep. Ophthalmol. Med.* 2013, 213124. <https://doi.org/10.1155/2013/213124>

Shome, D., Jayadev, C., Gadgil, D., Natarajan, S., Jain, V., 2007. Systemic chemotherapy and tamoxifen induced regression of choroidal metastasis from a breast carcinoma in a male. *Indian J. Ophthalmol.* 55, 475–477.

Singh, A.D., Medina, C.A., Singh, N., Aronow, M.E., Biscotti, C.V., Triozzi, P.L., 2016. Fine-needle aspiration biopsy of uveal melanoma: outcomes and complications. *Br. J. Ophthalmol.* 100, 456–462. <https://doi.org/10.1136/bjophthalmol-2015-306921>

Singh, A., Singh, P., Sahni, K., Shukla, P., Shukla, V., Pant, N.K., 2010. Non-small cell lung cancer presenting with choroidal metastasis as first sign and showing good response to chemotherapy alone: a case report. *J. Med. Case Reports* 4, 185. <https://doi.org/10.1186/1752-1947-4-185>

Singh, N., Kulkarni, P., Aggarwal, A.N., Rai Mittal, B., Gupta, N., Behera, D., Gupta, A., 2012. Choroidal metastasis as a presenting manifestation of lung cancer: a report of 3 cases and systematic review of the literature. *Medicine (Baltimore)* 91, 179–194. <https://doi.org/10.1097/MD.0b013e3182574a0b>

Sirin, S., Schlamann, M., Metz, K.A., Bornfeld, N., Schweiger, B., Holdt, M., Temming, P., Schuendeln, M.M., Goericke, S.L., 2015. High-resolution MRI using orbit surface coils for the evaluation of metastatic risk factors in 143 children with retinoblastoma: Part 1: MRI vs. histopathology. *Neuroradiology* 57, 805–814. <https://doi.org/10.1007/s00234-015-1544-2>

Small, K.W., Rosenwasser, G.O., Alexander, E., Rossitch, G., Dutton, J.J., 1990. Presumed choroidal metastasis of Merkel cell carcinoma. *Ann. Ophthalmol.* 22, 187–190.

Smith, B.D., Smith, G.L., Carter, D., Sasaki, C.T., Haffty, B.G., 2000. Prognostic significance of vascular endothelial growth factor protein levels in oral and oropharyngeal squamous cell carcinoma. *J. Clin. Oncol. Off. J. Am. Soc. Clin. Oncol.* 18, 2046–2052. <https://doi.org/10.1200/JCO.2000.18.10.2046>

Sneed, S.R., Byrne, S.F., Mieler, W.F., Nicholson, D.H., Olsen, K., Hughes, J.R., 1991. Choroidal detachment associated with malignant choroidal tumors. *Ophthalmology* 98, 963–970.

Sobottka, B., Schlote, T., Krumpaszy, H.G., Kreissig, I., 1998. Choroidal metastases and choroidal melanomas: comparison of ultrasonographic findings. *Br. J. Ophthalmol.* 82, 159–161.

Soucek, P., Cihelkova, I., 2006. Photodynamic therapy with Verteporfin in subfoveal choroidal metastasis of breast carcinoma (a controlled case). *Neuro Endocrinol. Lett.* 27, 725–

728.

Spaide, R.F., Fujimoto, J.G., Waheed, N.K., 2015. IMAGE ARTIFACTS IN OPTICAL COHERENCE TOMOGRAPHY ANGIOGRAPHY. *Retina Phila. Pa* 35, 2163–2180.

<https://doi.org/10.1097/IAE.0000000000000765>

Spaide, R.F., Fujimoto, J.G., Waheed, N.K., Sadda, S.R., Staurenghi, G., 2018. Optical coherence tomography angiography. *Prog. Retin. Eye Res.* 64, 1–55.

<https://doi.org/10.1016/j.preteyeres.2017.11.003>

Spraul, C.W., Lang, G.E., Grossniklaus, H.E., Lang, G.K., 1995. Metastatic adenocarcinoma to the retina in a patient with Muir-Torre syndrome. *Am. J. Ophthalmol.* 120, 248–250.

Stewart, M.W., 2014. Pharmacokinetics, pharmacodynamics and pre-clinical characteristics of ophthalmic drugs that bind VEGF. *Expert Rev. Clin. Pharmacol.* 7, 167–180.

<https://doi.org/10.1586/17512433.2014.884458>

Su, H.-T., Chen, Y.-M., Perng, R.-P., 2008. Symptomatic ocular metastases in lung cancer. *Respirol. Carlton Vic* 13, 303–305. <https://doi.org/10.1111/j.1440-1843.2007.01203.x>

Thariat, J., Jacob, S., Caujolle, J.-P., Maschi, C., Baillif, S., Angellier, G., Mathis, T., Rosier, L., Carnicer, A., Hérault, J., Salleron, J., 2017. Cataract Avoidance With Proton Therapy in Ocular Melanomas. *Invest. Ophthalmol. Vis. Sci.* 58, 5378–5386.

<https://doi.org/10.1167/iovs.17-22557>

Torres, V.L.L., Brugnoli, N., Kaiser, P.K., Singh, A.D., 2011. Optical coherence tomography enhanced depth imaging of choroidal tumors. *Am. J. Ophthalmol.* 151, 586–593.e2.

<https://doi.org/10.1016/j.ajo.2010.09.028>

Trichopoulos, N., Augsburger, J.J., 2006. Neuroendocrine tumours metastatic to the uvea: diagnosis by fine needle aspiration biopsy. *Graefes Arch. Clin. Exp. Ophthalmol. Albrecht Von Graefes Arch. Klin. Exp. Ophthalmol.* 244, 524–528. <https://doi.org/10.1007/s00417-005-0113-5>

Tsina, E.K., Lane, A.M., Zacks, D.N., Munzenrider, J.E., Collier, J.M., Gragoudas, E.S., 2005. Treatment of metastatic tumors of the choroid with proton beam irradiation.

*Ophthalmology* 112, 337–343. <https://doi.org/10.1016/j.ophtha.2004.09.013>

Van Cutsem, E., Köhne, C.-H., Hitre, E., Zaluski, J., Chang Chien, C.-R., Makhson, A., D'Haens, G., Pintér, T., Lim, R., Bodoky, G., Roh, J.K., Folprecht, G., Ruff, P., Stroh, C., Tejpar, S., Schlichting, M., Nippgen, J., Rougier, P., 2009. Cetuximab and chemotherapy as initial treatment for metastatic colorectal cancer. *N. Engl. J. Med.* 360, 1408–1417.

<https://doi.org/10.1056/NEJMoa0805019>

Venkatesh, P., Garg, S., 2007. Regression of choroidal metastasis from breast carcinoma following Letrozole therapy. *Clin. Experiment. Ophthalmol.* 35, 492–494.

<https://doi.org/10.1111/j.1442-9071.2007.01520.x>

Verbeek, A.M., Thijssen, J.M., Cuypers, M.H., Brink, H., Deutman, A.F., 1994. Echographic classification of intraocular tumours. A 15-year retrospective analysis. *Acta Ophthalmol. (Copenh.)* 72, 416–422.

Vishnevskia-Dai, V., Zur, D., Yaacobi, S., Moroz, I., Newman, H., Neudorfer, M., 2016.

Optical Coherence Tomography: An Adjunctive Tool for Differentiating between Choroidal Melanoma and Metastasis. *J. Ophthalmol.* 2016, 9803547.

<https://doi.org/10.1155/2016/9803547>

Vitols, S., Gahrton, G., Ost, A., Peterson, C., 1984. Elevated low density lipoprotein receptor activity in leukemic cells with monocytic differentiation. *Blood* 63, 1186–1193.

Webb, S., 1988. Diagnostic ultrasound, in: *The Physics of Medical Imaging*. Philadelphia, pp. 319–388.

Weber, M.L., Liang, M.C., Flaherty, K.T., Heier, J.S., 2016. Subretinal Fluid Associated With MEK Inhibitor Use in the Treatment of Systemic Cancer. *JAMA Ophthalmol.* 134, 855–862.

<https://doi.org/10.1001/jamaophthalmol.2016.0090>

- Weiss, L., 1993. Analysis of the incidence of intraocular metastasis. *Br. J. Ophthalmol.* 77, 149–151.
- Weiss, L., 1992. Comments on hematogenous metastatic patterns in humans as revealed by autopsy. *Clin. Exp. Metastasis* 10, 191–199.
- Wiegel, T., Bottke, D., Kreusel, K.-M., Schmidt, S., Bornfeld, N., Foerster, M.H., Hinkelbein, W., German Cancer Society, 2002. External beam radiotherapy of choroidal metastases--final results of a prospective study of the German Cancer Society (ARO 95-08). *Radiother. Oncol. J. Eur. Soc. Ther. Radiol. Oncol.* 64, 13–18.
- Wiegel, T., Kreusel, K.M., Bornfeld, N., Bottke, D., Stange, M., Foerster, M.H., Hinkelbein, W., 1998. Frequency of asymptomatic choroidal metastasis in patients with disseminated breast cancer: results of a prospective screening programme. *Br. J. Ophthalmol.* 82, 1159–1161.
- Wiegel, T., Kreusel, K.M., Schmidt, S., Bornfeld, N., Foerster, M.H., Hinkelbein, W., 1999. Radiotherapy of unilateral choroidal metastasis: unilateral irradiation or bilateral irradiation for sterilization of suspected contralateral disease? *Radiother. Oncol. J. Eur. Soc. Ther. Radiol. Oncol.* 53, 139–141.
- Witkin, A.J., Fischer, D.H., Shields, C.L., Reichstein, D., Shields, J.A., 2012. Enhanced depth imaging spectral-domain optical coherence tomography of a subtle choroidal metastasis. *Eye Lond. Engl.* 26, 1598–1599. <https://doi.org/10.1038/eye.2012.201>
- Wolff, A.C., Hammond, M.E.H., Schwartz, J.N., Hagerty, K.L., Allred, D.C., Cote, R.J., Dowsett, M., Fitzgibbons, P.L., Hanna, W.M., Langer, A., McShane, L.M., Paik, S., Pegram, M.D., Perez, E.A., Press, M.F., Rhodes, A., Sturgeon, C., Taube, S.E., Tubbs, R., Vance, G.H., van de Vijver, M., Wheeler, T.M., Hayes, D.F., American Society of Clinical Oncology/College of American Pathologists, 2007. American Society of Clinical Oncology/College of American Pathologists guideline recommendations for human epidermal growth factor receptor 2 testing in breast cancer. *Arch. Pathol. Lab. Med.* 131, 18–43. [https://doi.org/10.1043/1543-2165\(2007\)131\[18:ASOCCO\]2.0.CO;2](https://doi.org/10.1043/1543-2165(2007)131[18:ASOCCO]2.0.CO;2)
- Wolff-Korman, P.G., Kormann, B.A., Hasenfratz, G.C., Spengel, F.A., 1992. Duplex and color Doppler ultrasound in the differential diagnosis of choroidal tumors. *Acta Ophthalmol. Suppl.* 66–70.
- Wong, Z.-W., Phillips, S.J., Ellis, M.J., 2004. Dramatic response of choroidal metastases from breast cancer to a combination of trastuzumab and vinorelbine. *Breast J.* 10, 54–56.
- Wu, J.N., Fish, K.M., Evans, C.P., Devere White, R.W., Dall’Era, M.A., 2014. No improvement noted in overall or cause-specific survival for men presenting with metastatic prostate cancer over a 20-year period. *Cancer* 120, 818–823. <https://doi.org/10.1002/cncr.28485>
- Yang, C.-J., Tsai, Y.-M., Tsai, M.-J., Chang, H.-L., Huang, M.-S., 2014. The effect of chemotherapy with cisplatin and pemetrexed for choroidal metastasis of non-squamous cell carcinoma. *Cancer Chemother. Pharmacol.* 73, 199–205. <https://doi.org/10.1007/s00280-013-2341-4>
- Yao, H.-Y., Horng, C.-T., Chen, J.-T., Tsai, M.-L., 2010. Regression of choroidal metastasis secondary to breast carcinoma with adjuvant intravitreal injection of bevacizumab. *Acta Ophthalmol. (Copenh.)* 88, e282–283. <https://doi.org/10.1111/j.1755-3768.2009.01684.x>
- Yasui, H., Sato, K., Takeyama, Y., Nishihara, H., Maeda, M., Gonda, H., Suzuki, R., 2015. Effective Treatment with Intravitreal Injection of Bevacizumab for Exudative Retinal Detachment Secondary to Choroidal Metastasis of Non-Small Cell Lung Carcinoma. *Am. J. Case Rep.* 16, 728–732.
- Young, S.E., Cruciger, M., Lukeman, J., 1979. Metastatic carcinoma to the retina: case report. *Ophthalmology* 86, 1350–1354.
- Zacharakis, N., Chinnasamy, H., Black, M., Xu, H., Lu, Y.-C., Zheng, Z., Pasetto, A.,

Langhan, M., Shelton, T., Prickett, T., Gartner, J., Jia, L., Trebska-McGowan, K., Somerville, R.P., Robbins, P.F., Rosenberg, S.A., Goff, S.L., Feldman, S.A., 2018. Immune recognition of somatic mutations leading to complete durable regression in metastatic breast cancer. *Nat. Med.* 24, 724–730. <https://doi.org/10.1038/s41591-018-0040-8>

Zheng, M., Sun, H., Xu, J., Yang, G., Huo, L., Zhang, P., Tian, J., Yang, K., 2016. Combining Whole-Brain Radiotherapy with Gefitinib/Erlotinib for Brain Metastases from Non-Small-Cell Lung Cancer: A Meta-Analysis. *BioMed Res. Int.* 2016, 5807346. <https://doi.org/10.1155/2016/5807346>

## **FIGURE CAPTIONS:**

**Figure 1: Most common primary source of choroidal metastases.**

**Figure 2: Wound oncogene wound healing mechanism.** Oncogenes that have physiological activity in some tissues can be stimulated by persistently circulatory wound molecules derived from the cancer wounds. The cells with activated oncogenes will transform and over-proliferate, leading to another cancer mass on the remote site without primary cancer cell migration (adaptated from Meng et al. (Meng et al., 2012)).

**Figure 3: Color features of choroidal metastases may indicate the primary source of cancer.** Color fundus photography: **A.** Lung carcinoma: pale yellow color; **B.** Breast carcinoma: lobular creamy white color; **C.** Prostate carcinoma: amelanotic mass; **D.** Renal carcinoma: temporal orange-color mass associated to another pale yellow juxtapapillary mass; **E.** Lung carcinoid tumor: Orange color. **F.** Thyroid tumor: subfoveal orange-color mass associated to another inferior white mass.

**Figure 4: Choroidal metastases with a “leopard skin” pattern.** Color fundus photography of choroidal metastases: **A.** From breast cancer; **B, C.** From lung cancer.

**Figure 5: Bilaterality and multifocality of choroidal metastases (CM).** **A.** Widefield retinophotography of bilateral CM from lung cancer; **B.** Retinophotography montage of bilateral CM from breast cancer: diffuse form.

**Figure 6: Voluminous choroidal metastases (CM).** **A.** Retinophotography of CM from a nasopharyngeal cancer; **B, C.** Retinophotography of CM from a neuroendocrine tumor, and

corresponding ultrasonography. Yellow caliper: thickness (height); green caliper: diameter (base)

**Figure 7: Comparison of tumor reflectivity in ultrasonography between choroidal melanoma and metastasis. B-scan and corresponding A-scan. A. Choroidal melanoma.**

*B-scan*: dome shaped melanoma with a regular hyporeflective internal structure associated to a choroidal excavation seen as a low reflective step down within the concave highly reflective posterior pole. *A scan*: the tumor surface-spike is high, followed by quickly decreasing amplitude in the tumor, until the scleral spike; **B. Choroidal metastasis.** The medium to high reflectivity seen on B-scan is demonstrated on A-scan by moderate variable amplitude of spike following the high amplitude of the tumor surface.

**Figure 8: Differences in choroidal features between choroidal melanoma (A) and choroidal metastases (B) on ultrasonography.** higher reflectivity and lower height-to-base ratio are common features of choroidal metastases on ultrasonography. Yellow caliper: thickness (height); green caliper: diameter (base).

**Figure 9: Angiographic features of choroidal metastases. A.** Retinophotography; **B.** Early phase (1 minutes) of fluorescein angiogram (FA): hypofluorescent; **C.** Middle phase (4 minutes) of FA: heterogeneous fluorescence; **D.** Late phase (8 minutes) of FA: pinpoint and leakage areas are seen on the mass; **E.** Blue light fundus autofluorescence: hypo- and hyper-autofluorescence; **F.** Early phase (1 minutes) of indocyanine green angiography (ICGA): hypofluorescence; **G.** Late phase (22 minutes) of ICGA: hypofluorescence.

**Figure 10: Comparison of choroidal metastasis and melanoma between fundus examination, fluorescein angiography (FA) and indocyanine green angiography (ICGA).**

**A,B,C : Choroidal metastasis :** **A.** Retinophotography; **B.** Intermediate phase FA showing heterogeneous hyperfluorescence; **C.** ICGA showing a larger area involved by the choroidal metastasis. **D,E,F : Choroidal melanoma.** **D.** Retinophotography using ultra-wide field scanning laser ophthalmoscopy. Note the green hue of melanotic lesions due to red-green laser imaging; **E.** Intermediate phase FA showing patchy hyperfluorescence with typical hyperfluorescent pinpoint; **F.** ICGA showing less well defined boundaries, a size matching that of the fundus, and no intratumoral vessels in this case.

**Figure 11: Detection of small choroidal metastases by optical coherence tomography (OCT).** **A.** Indocyanine green angiography (ICGA) showing a hypofluorescent spot; **B.** B-scan OCT corresponding to the green line on ICGA: hyporeflective choroidal mass of approximately 600  $\mu\text{m}$  with overlying subretinal fluid.

**Figure 12: Optical coherence tomography features of various choroidal tumors.** **A<sub>1</sub>** and **A<sub>2</sub>.** Metastasis: lumpy bumpy, associated to subretinal fluid (SRF); **B.** Osteoma: lamellar-shape, associated to SRF; **C.** Hemangioma: abrupt smooth dome-shaped, no retinal pigment epithelium (RPE) changes; **D.** Nevus: smooth mound-shaped, can be associated with RPE changes; **E.** Melanoma: dome-shaped, RPE changes, outer retina alterations

**Figure 13: Optical coherence tomography (OCT) features of choroidal metastases.** **A.** Infrared (IR) imaging; **B.** B-scan OCT corresponding to the green line on IR; **C.** B-scan OCT corresponding to the green dotted line on IR. Metastatic tumor appears as low internal reflective mass with overlying choriocapillaris thinning. The anterior tumor surface show a

typical lumpy bumpy shape associated with retinal pigment epithelium changes. There is alteration of the ellipsoid zone with “shaggy” photoreceptors, and shallow subretinal fluid with speckles.

**Figure 14: Swept-source optical coherence tomography-angiography (OCTA) of choroidal metastases.** OCTA of the choroid shows a relative lack of flow inside the tumor compared to the adjacent choroid.

**Figure 15: Choroidal effectiveness of systemic therapy (Tamoxifen) in a patient treated for multi metastatic breast carcinoma. A.** Retinophotography at baseline; **B.** Retinophotography four months after the beginning of the therapy: an atrophic change, that appears larger than the initial tumor, was seen in place of the gross tumor volume. Visual acuity increased from 0.6 to 0.9

**Figure 16: Techniques of radiation therapy and corresponding radar charts.**

**Brachytherapy (A) External beam radiotherapy techniques (B, C and D). A.**

Brachytherapy is a conformal technique that does not deliver any dose outside the eye. The principle is to apply radioactive isotope to the sclera that will deliver radiation over a short distance to the tissue. The plaque delivers a heterogeneous dose from the sclera to the apex of the tumor; **B.** Conventional 3D radiotherapy delivers a uniform dose to the eye using 1 to 3 fields. Intensity modulated radiotherapy (IMRT) uses instead 5 to 9 fields and a multileaf collimator, allowing complex concave dose distribution; **C.** Stereotactic beam radiotherapy (SBRT) delivers radiotherapy from many different positions around the organ so that the beams meet at the tumor. The tumor receives a high dose of radiation and the healthy tissues around it only receive a low dose; **C.** Proton beam therapy (PBT) allows a very focused and



high-dose volume due to the physical properties of protons. The energy is delivered with a sharp final peak allowing preservation of surrounding tissues.

**Figure 17: External beam radiotherapy (EBRT) for bilateral choroidal metastases.** **A.** Retinophotography at baseline. **Initial visual acuity was 0.6 in right eye and 1.0 in left eye;** **B.** Retinophotography 6 months after EBRT at 30 Gray showing atrophic changes after therapy that appears larger than the choroidal metastases. **Visual acuity remained stable in both eyes with final acuity at 0.6 in right eye and 1.0 in left eye.**

**Figure 18: External beam radiotherapy (EBRT) following initiation of systemic therapy for choroidal metastases from lung cancer.** **A.** Retinophotography at baseline showing the inferior mass. **B.** Retinophotography 4 months after EBRT at 30 Gray showing the atrophic changes in place of the tumor. **Visual acuity increased from 0.8 to 1.0.**

**Figure 19: External beam radiotherapy (EBRT) for choroidal metastases from lung adenocarcinoma few weeks before treatment by gefitinib.** **A.** Retinophotography at baseline; **B.** Retinophotography 6 months after EBRT at 30 Gray, showing a flattening of the tumors with slight atrophic changes. Visual acuity increased from 0.1 to 1.0 in both eye within 2 months

**Figure 20: External Beam Radiation Therapy planning.** Example of simple dosimetric study with one single lateral field, slightly oblique to avoid the lenses. The contralateral choroid received approximately 50% of the prescribed dose (inside the green line).

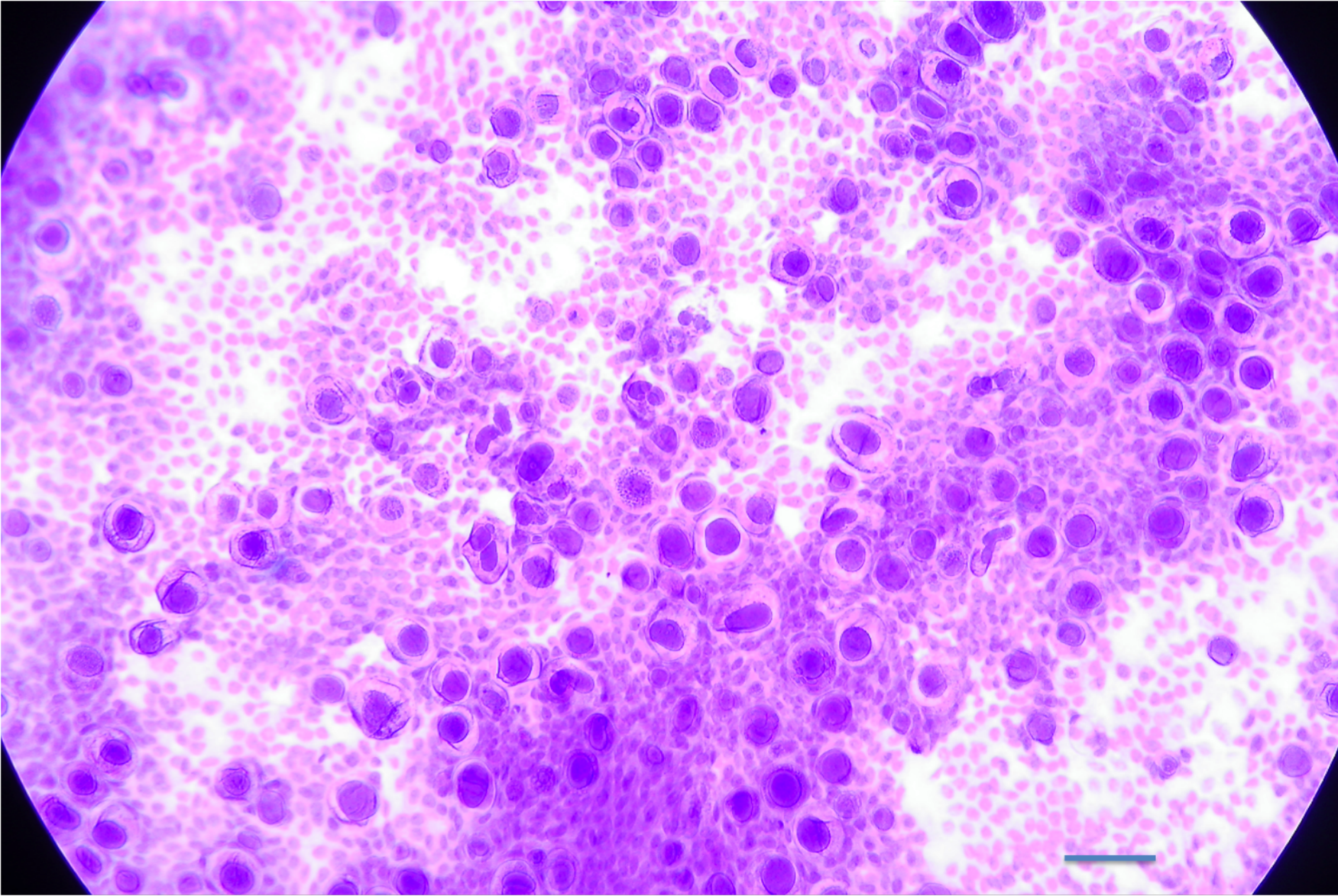
**Figure 21: Proton beam therapy at 20 Cobalt equivalent Gray for choroidal metastases from lung neuro-endocrine tumor.** Retinophotography: **A.** At baseline; **B.** 4 months after therapy; **C.** 3 years after therapy showing a flattening of the tumors with atrophic changes. Ultrasonography: **D.** At baseline; **E.** 3 years after therapy. Visual acuity increased from 0.1 to 1.0 in both eye.

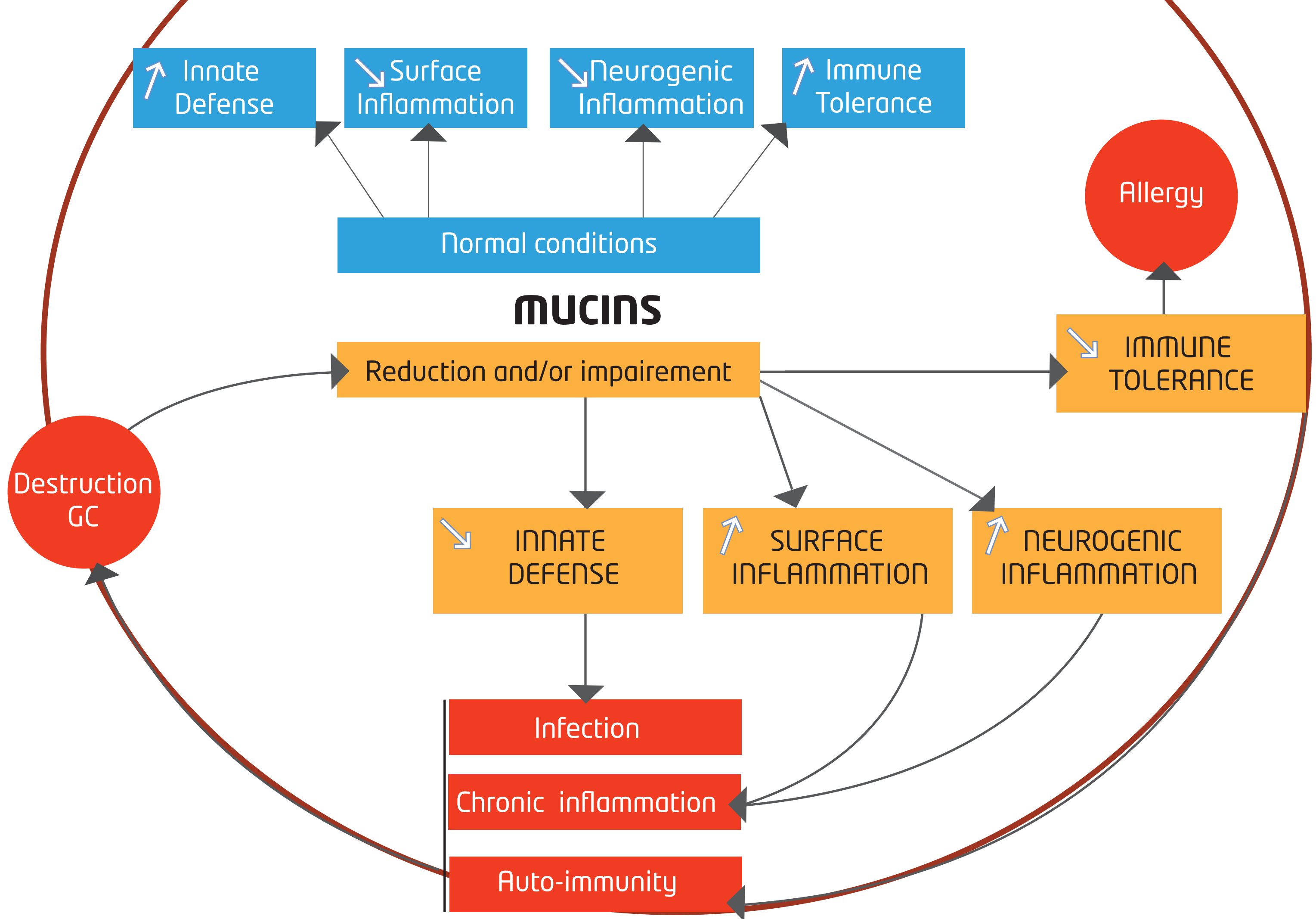
**Figure 22: Mechanism of action of PDT.** After intravenous injection of verteporfin and building of the complex with LDL (LV-LDL) (1), verteporfin molecules accumulate in the tumor through LDL receptors (LDL Rc) (2). Then a 689 nm light exposition (3) on the tumor bed leads to activation of the molecules of verteporfin, producing reactive oxygen species (ROS) (4).

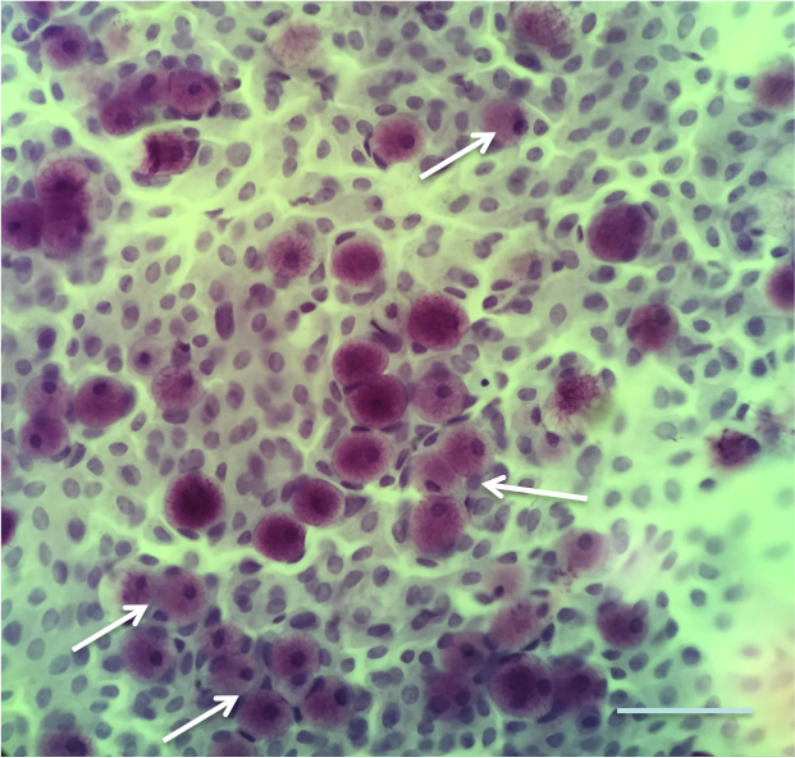
**Figure 23: Effectiveness of photodynamic therapy for a choroidal metastasis from thyroid carcinoid tumor.** **A.** Retinophotography at baseline and 6 months (M6) after therapy. Before treatment tumor had a red-orange color that became atrophic at the end of follow-up. **B.** Optical coherence tomography showing the decrease of the tumor thickness at 2 (M2), 4 (M4) and 6 (M6) months after therapy.

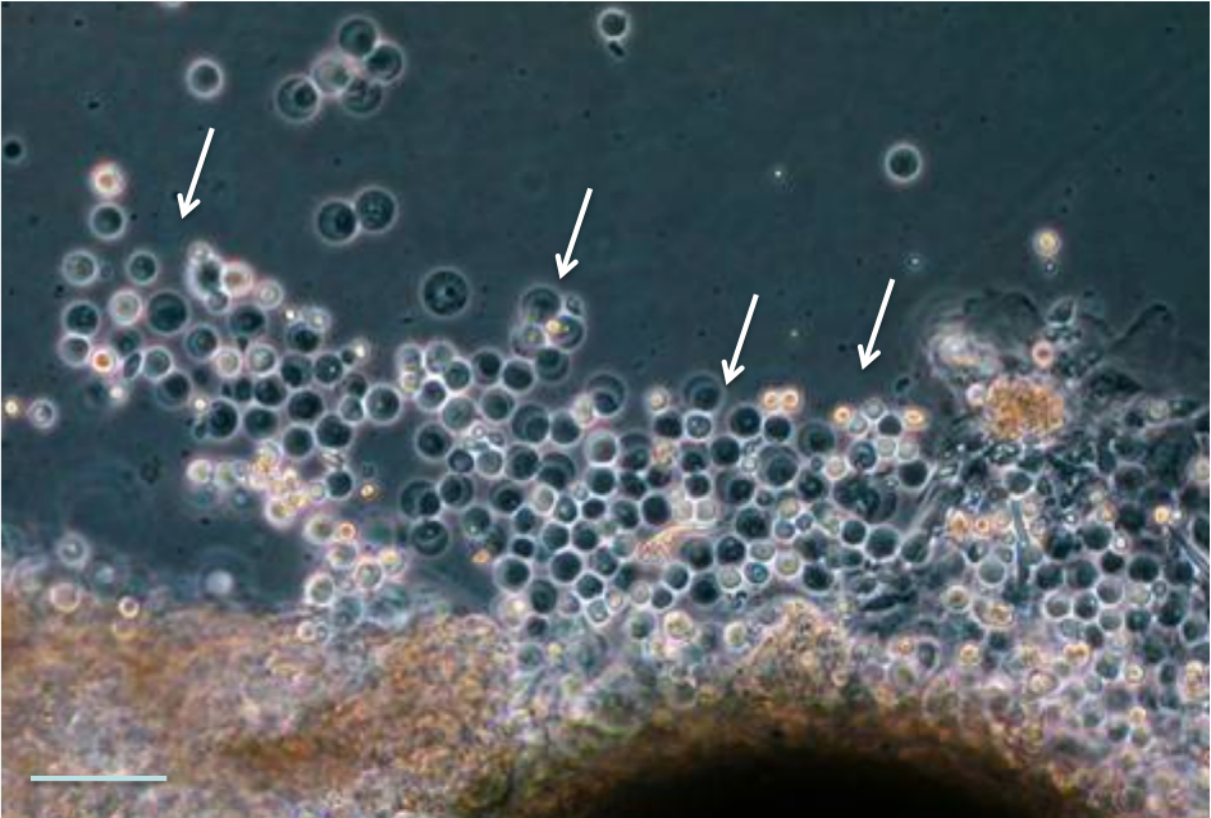
**Figure 24: Decision tree in case of long life expectancy.** In addition to treatment for choroidal metastases, systemic therapy is recommended if there are other extrachoroidal metastases. \* Proton beam therapy (PBT) should be performed after fiducial placement to ensure the correct positioning of the eye. IVI: intravitreal injection; PDT: photodynamic therapy; EBRT: photon-based external beam radiotherapy; SBRT: stereotactic beam radiotherapy

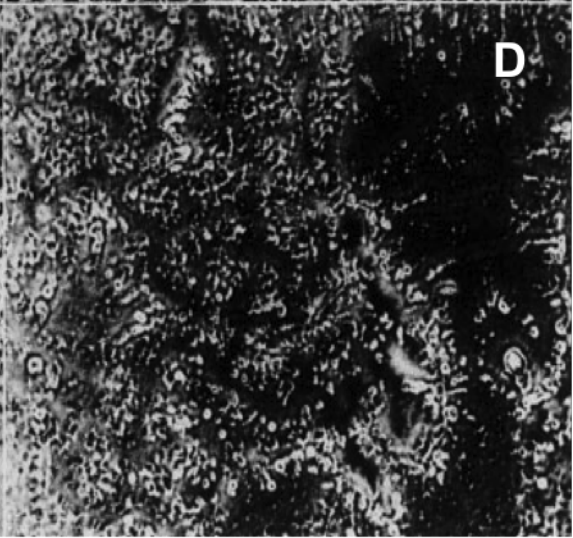
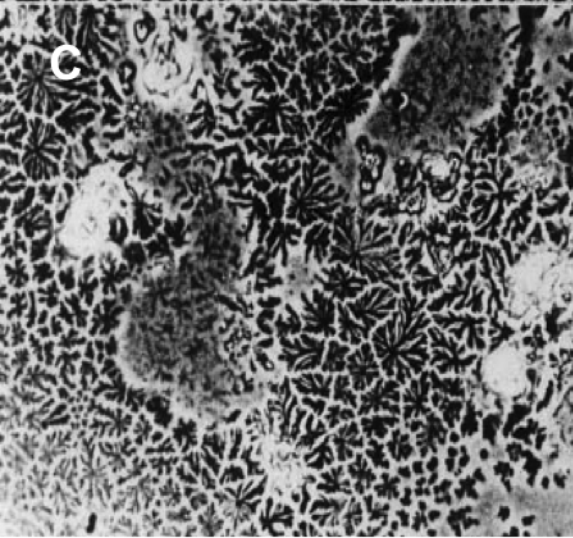

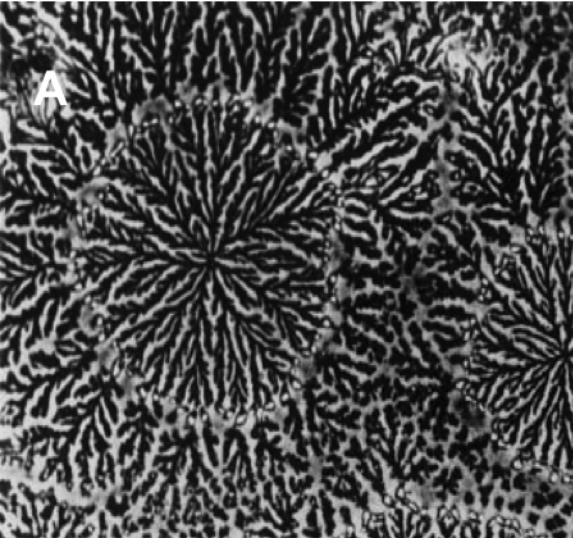
**Figure 25: Decision tree in case of short life expectancy.** IVI: intravitreal injection; PDT: photodynamic therapy; EBRT: photon-based external beam radiotherapy;



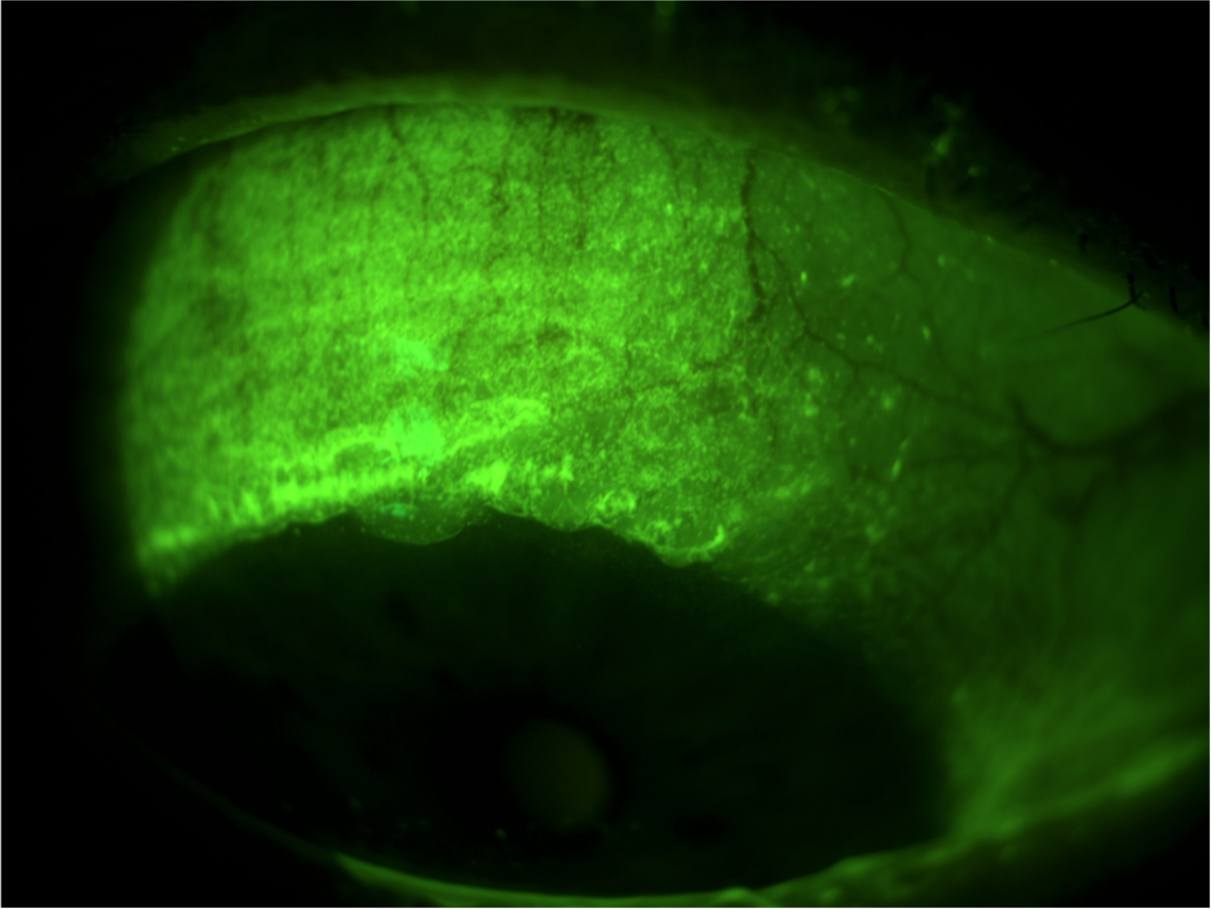


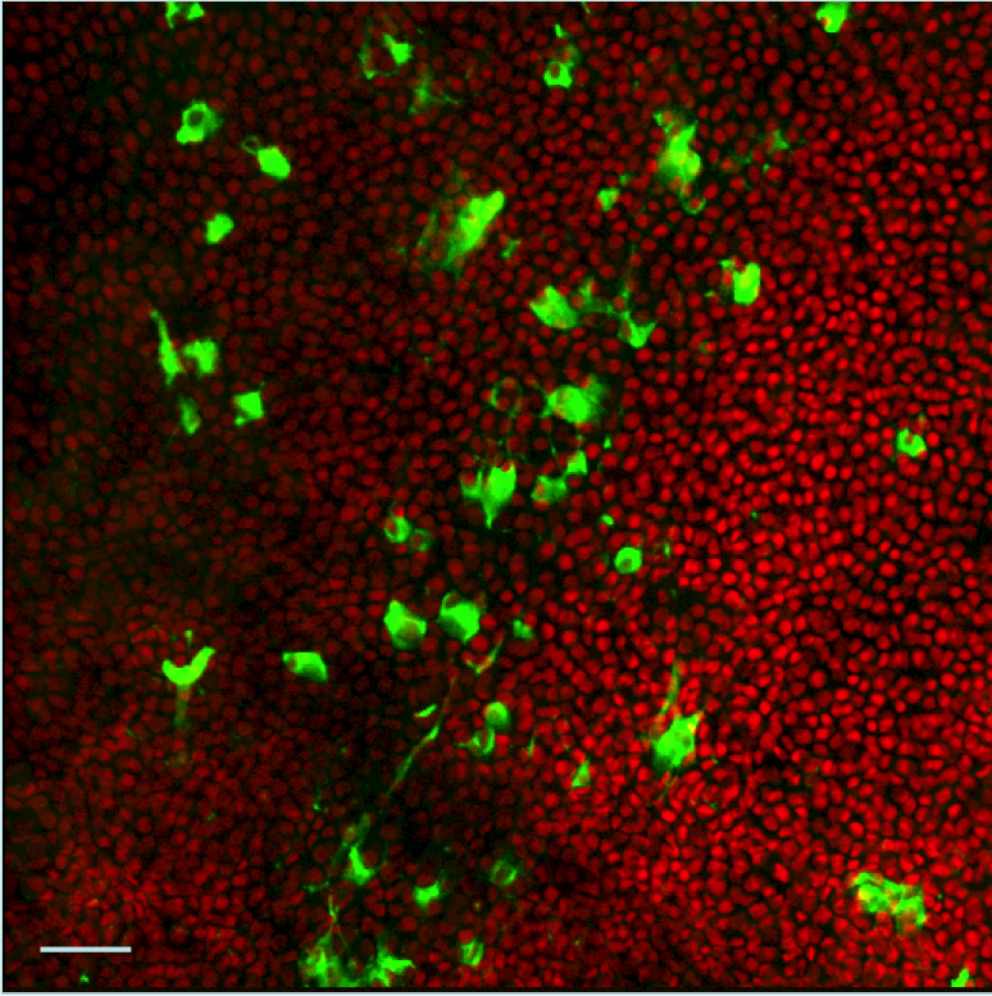


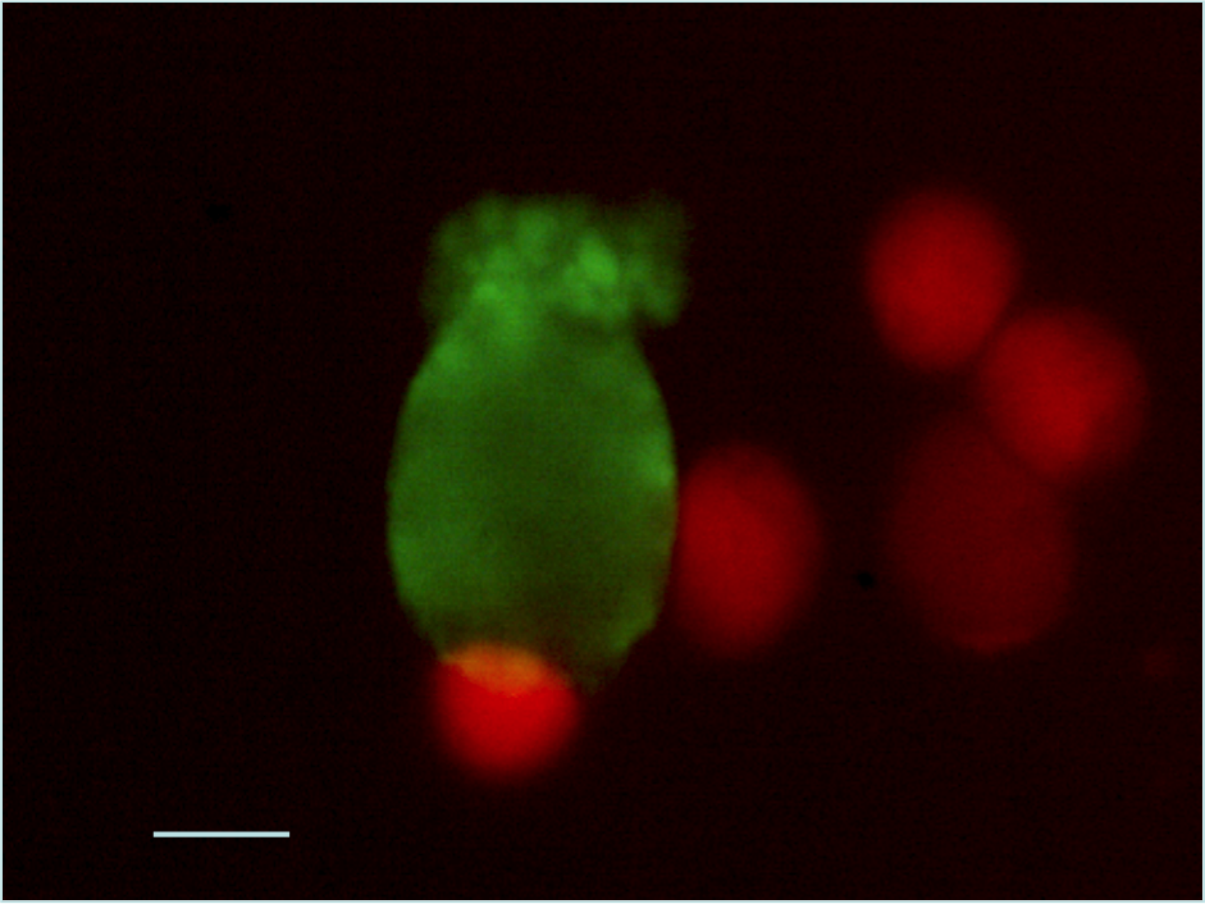

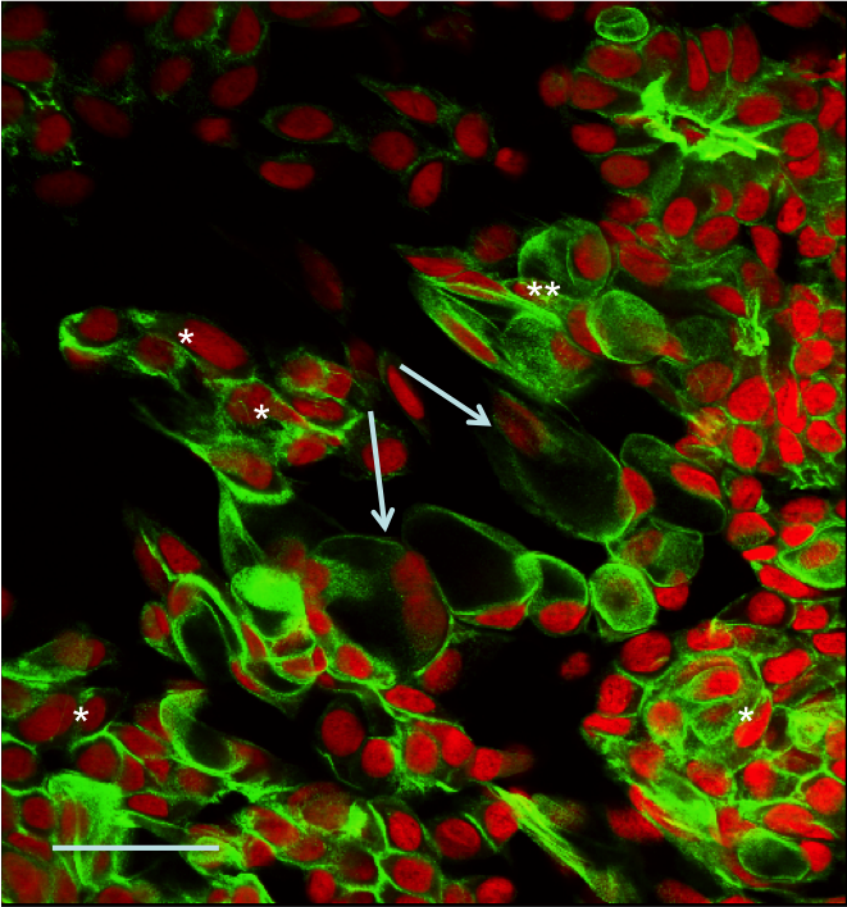


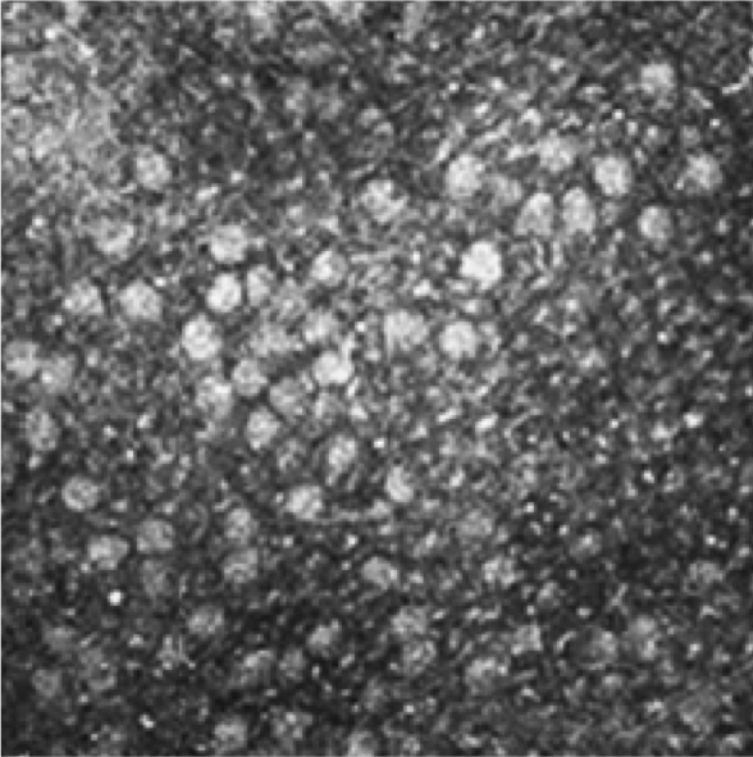


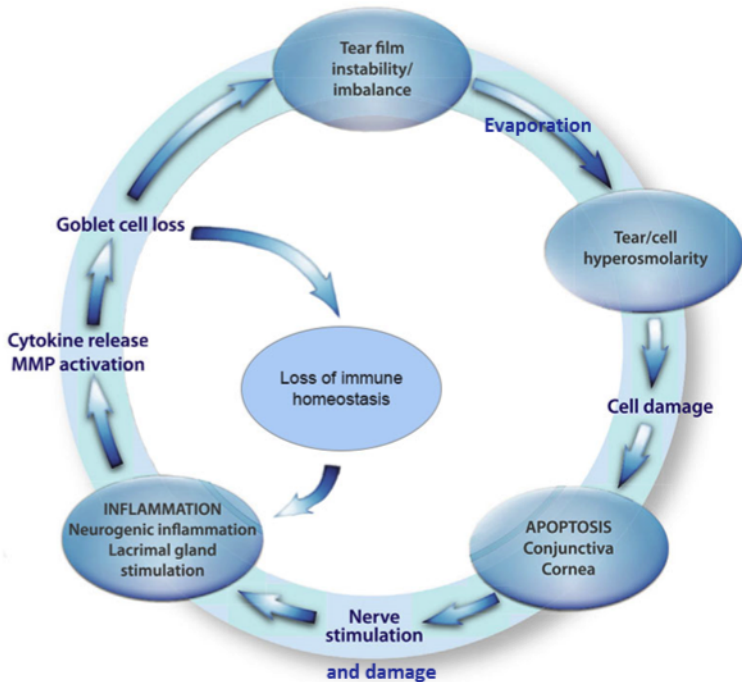




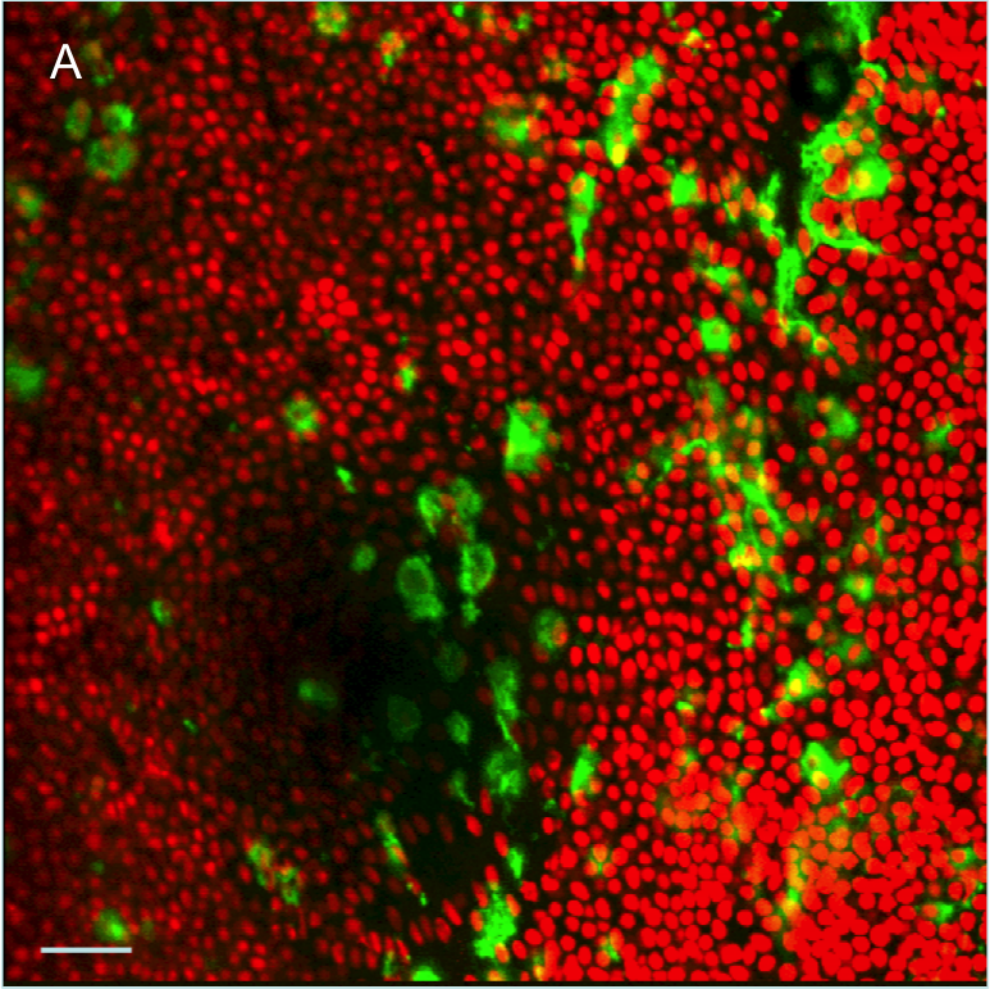








A



B

