HAL open science

Dirofilariasis: a parasitic cause of subcutaneous nodule

D. Wendum, P. Campa, M. Develoux, M. Zmuda, M. Putterman, C. Hennequin

▶ **To cite this version:**

D. Wendum, P. Campa, M. Develoux, M. Zmuda, M. Putterman, et al.. Dirofilariasis: a parasitic cause of subcutaneous nodule. Clinical Microbiology and Infection, 2019, 25, pp.1231 - 1232. 10.1016/j.cmi.2019.06.015 . hal-03487659

HAL Id: hal-03487659

https://hal.science/hal-03487659v1

Submitted on 21 Dec 2021

HAL is a multi-disciplinary open access archive for the deposit and dissemination of scientific research documents, whether they are published or not. The documents may come from teaching and research institutions in France or abroad, or from public or private research centers.

L'archive ouverte pluridisciplinaire **HAL**, est destinée au dépôt et à la diffusion de documents scientifiques de niveau recherche, publiés ou non, émanant des établissements d'enseignement et de recherche français ou étrangers, des laboratoires publics ou privés.

Distributed under a Creative Commons Attribution - NonCommercial 4.0 International License

Version of Record: https://www.sciencedirect.com/science/article/pii/S1198743X19303404
Manuscript_729a8e94bbcd558ffb0eb5b13516261e

Dirofilariasis: a parasitic cause of subcutaneous nodule

D. Wendum[1], P. Campa[2], M. Develoux[3], M. Zmuda[4], M. Putterman[5], C. Hennequin[6]

1 Service d'Anatomo-Pathologie, Hôpital St Antoine, AP-HP, 75012 Paris, France

2 Service des Maladies Infectieuses et Tropicales, Hôpital St Antoine, AP-HP, 75012 Paris, France

3 Service de Parasitologie-Mycologie, Hôpital St Antoine, AP-HP, 7F-5012 Paris, France

4 Cabinet Ophtalmologie, F-75015 Paris, France

5 Cabinet Anatomo-Pathologie, F-75017 Paris, France

6 Sorbonne Université, Inserm, Centre de Recherche Saint-Antoine, CRSA, AP-HP, Hôpital Saint-Antoine, F-75012 Paris, France

Corresponding author: Dr C. Hennequin, Service de Parasitologie, Hôpital St Antoine, 34 rue Crozatier, 75012 Paris, France

Phone : +33 1 49 28 34 12 Fax : + 33 1 49 28 24 72

Email : christophe.hennequin@upmc.fr

© 2019 published by Elsevier. This manuscript is made available under the CC BY NC user license
https://creativecommons.org/licenses/by-nc/4.0/

An 87-year-old French woman presented with a 2 cm in diameter nodule of the infra-orbital edge. The nodule was subcutaneous, mobile with respect to the underlying structures, and had never been neither inflammatory nor painful. The patient had no particular past medical history or habitus except the fact she spent each year 3 months in Italy with her dog. Due to a recent discomfort, surgical excision was performed. Anatomical pathology showed a fibro-inflammatory reaction containing some eosinophils surrounding sections of a worm with a diameter of ca. 500µm and ornamented with longitudinal ridges along the cuticle (Figures 1-2). This led us to the diagnosis of dirofilariasis.

Dirofilariasis is a parasitic zoonosis due to nematodes of the *Dirofilaria* genus [1]. Those worms are transmitted by many different mosquito species (*Aedes, Culex, Anopheles, Mansonia, Culiseta, Simulium*) to domestic and wild canids and, incidentally to humans, that mostly represent a dead-end host [2]. *Dirofilaria immitis* and *Dirofilaria repens* are the most frequently involved species. Human cases due to the former have been mostly reported in the United States. In contrast, *D. repens* is more cosmopolite, and an increasing incidence of human cases is reported from Southern European countries, especially Italy, where our patient may have been infected. Contrary to *D. immitis*, which can be responsible for deep-organ infections, notably at the lungs and the heart level, *D. repens* usually develops into a single subcutaneous nodule, mostly located in ocular and facial regions. The demonstration of longitudinal ridges along the cuticle, allowing to rule out *D. immitis*, combined with the geographical probable area of contamination, supports the identification of *D. repens*. Surgical removal of the nodule is the definitive and curative treatment of dirofilariasis.

Supplementary picture: a sub-optimal (but unique) photograph of the patient nodule. Obtained with the permission of the patient's daughter

Transparency declaration: The authors declared no conflict of interest

No funding was received for this study

References

1. Capelli G, Genchi C, Baneth G, et al. Recent advances on Dirofilaria repens in dogs and humans in Europe. Parasit Vectors **2018**; 11(1): 663.
2. Diaz JH. Increasing risks of human dirofilariasis in travelers. J Travel Med **2015**; 22(2): 116-23.

Figures legends

Figure 1: Hematoxylin and eosin stain of the excised nodule (×100 magnification).

Figure 2: Other section of the worm showing a: two genital tubes b: the muscle layer c: detail of the cuticule with characteristic external longitudinal ridges (Hematoxylin and eosin stain x400 magnification)

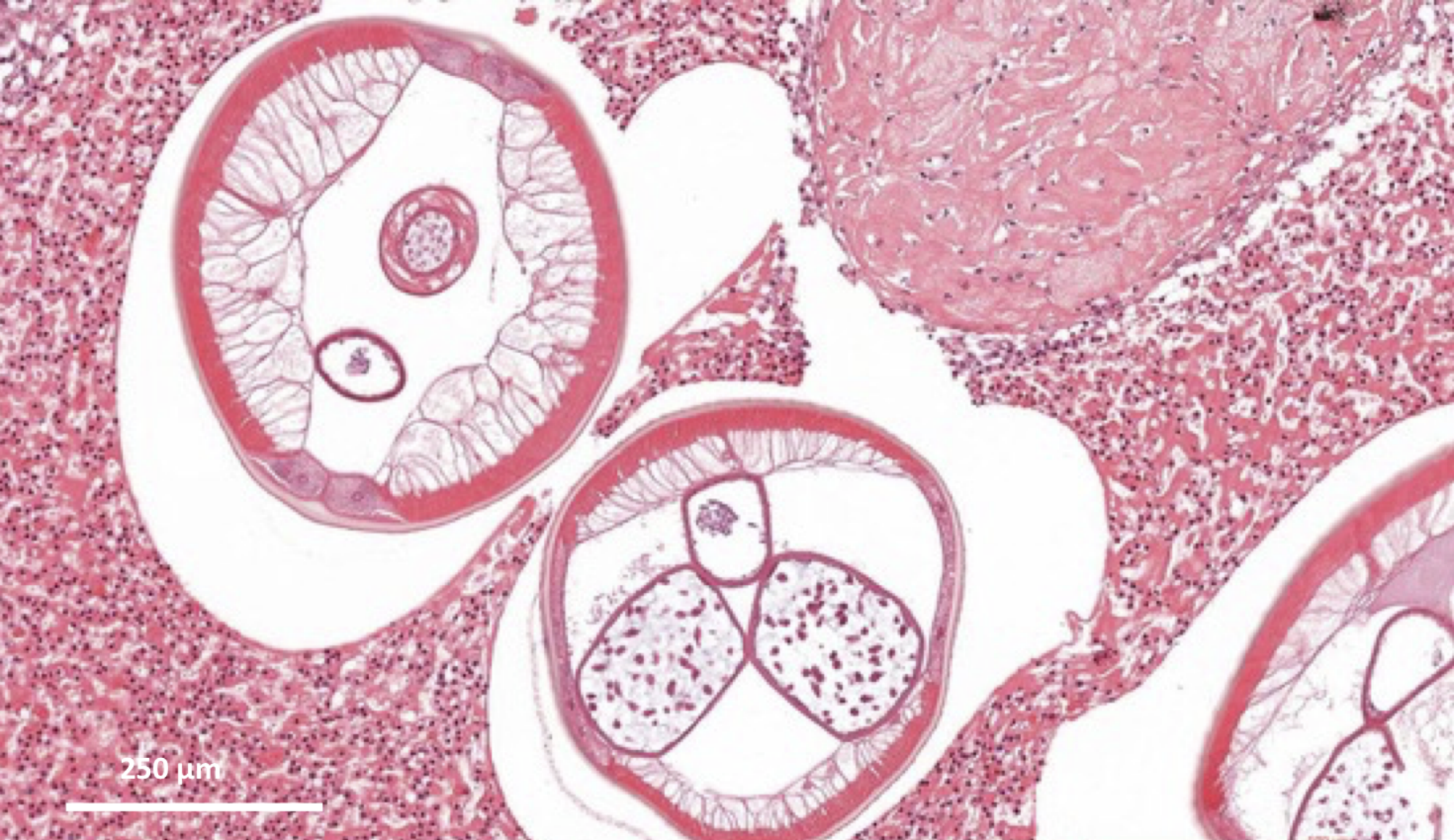
250 µm

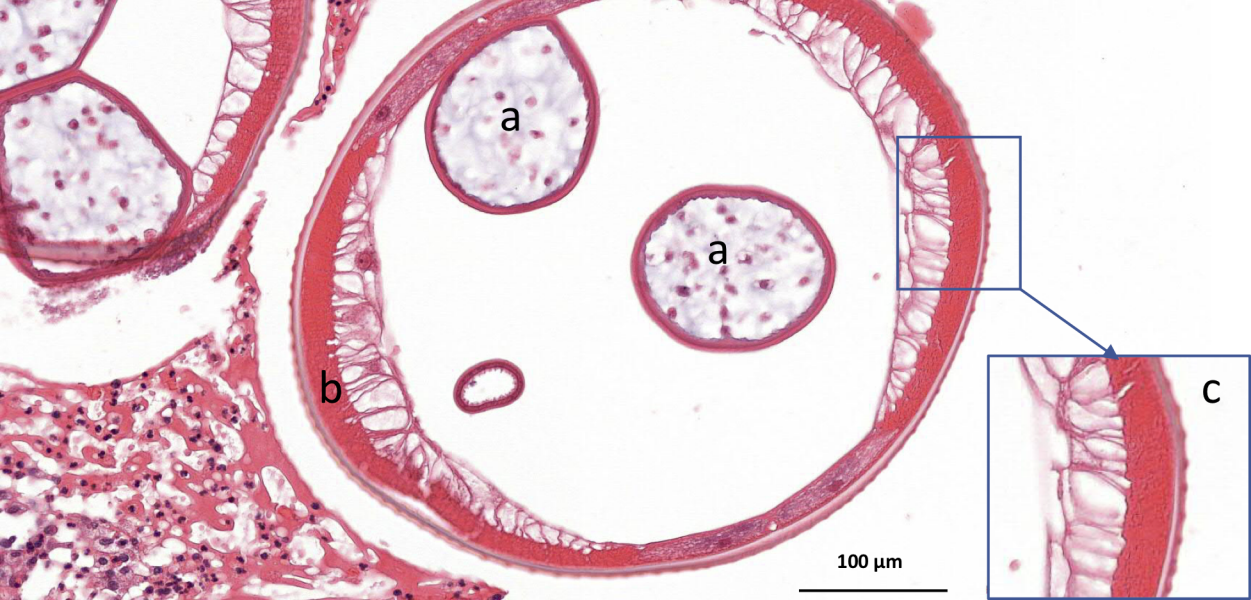
a
a
b
c
100 µm