



HAL
open science

Bag-in-the-lens implantation helps avoid posterior synechiae of the iris after phacovitrectomy

Clément Auchère Lavayssiere, Anne-Laure Lux, Guillaume Beraud, Alice Degoumois, Christian Billotte, Éric Denion

► To cite this version:

Clément Auchère Lavayssiere, Anne-Laure Lux, Guillaume Beraud, Alice Degoumois, Christian Billotte, et al. Bag-in-the-lens implantation helps avoid posterior synechiae of the iris after phacovitrectomy. *Journal of Cataract and Refractive Surgery*, 2019, 45, pp.1386 - 1392. 10.1016/j.jcrs.2019.05.054 . hal-03487459

HAL Id: hal-03487459

<https://hal.science/hal-03487459>

Submitted on 20 Jul 2022

HAL is a multi-disciplinary open access archive for the deposit and dissemination of scientific research documents, whether they are published or not. The documents may come from teaching and research institutions in France or abroad, or from public or private research centers.

L'archive ouverte pluridisciplinaire **HAL**, est destinée au dépôt et à la diffusion de documents scientifiques de niveau recherche, publiés ou non, émanant des établissements d'enseignement et de recherche français ou étrangers, des laboratoires publics ou privés.



Distributed under a Creative Commons Attribution - NonCommercial 4.0 International License

Title:

Bag-in-the-lens implantation avoids posterior synechiae of the iris after phacovitrectomy

Authors:

Clément AUCHÈRE LAVAYSSIERE^{1,2} MD, Anne-Laure LUX^{1,2} MD, Guillaume BERAUD^{3,4,5} MD/PhD, Alice DEGOUMOIS^{1,2} MD, Christian BILLOTTE^{1,2} MD, Éric DENION^{1,6,7} MD/PhD

Affiliation of each author:

1- CHU de Caen, Department of Ophthalmology, Caen, F-14000, France.

2- Université Caen Normandie, Medical School, Caen, F-14000, France.

3- Médecine Interne et Maladies Infectieuses, CHU de Poitiers, 86000 Poitiers, France.

4- EA2694, Université Droit et Santé Lille 2, 59000 Lille, France.

5- Interuniversity Institute for Biostatistics and statistical Bioinformatics, Hasselt University, Hasselt, Belgium.

6- Centre Ophtalmologique du Pays des Olonnes (COPO), Olonne-sur-Mer, F-85340, France.

7- INSERM, U 1075 COMETE, Pôle de formation et de recherche en santé, Caen, F-14000, France.

City, country:

Caen, FRANCE

Name and address of author to receive reprint requests:

AUCHÈRE LAVAYSSIERE Clément, 5 rue Monplaisir, 14000 CAEN, FRANCE

Financial disclosure:

None of the authors have a financial or proprietary interest in any material or method mentioned.

Acknowledgment:

The authors thank Jeffrey Arsham, a medical translator, for reading and reviewing the original English-language text.

ABSTRACT

Purpose:

To compare the rate of occurrence of posterior synechiae of the iris (PSI) after phacovitrectomy between a group with Lens-In-the-Bag (LIB) implantation, i.e. implantation in the capsular bag and a group with Bag-In-the-Lens (BIL) implantation.

Setting:

CHU de Caen, Department of Ophthalmology, Caen, F-14000, France.

Design:

Comparative retrospective study.

Methods:

Inclusion of 100 consecutive cases of phacovitrectomies, conducted between May 2013 and July 2016. Retrospective analysis of the occurrence rate of posterior synechiae of the iris (PSI) in the LIB group and in the BIL group, using multivariate analysis including multiple risk factors such as pre-operative synechiae; proliferative diabetic retinopathy; use of 20G vitrectomy; use of gas or silicone tamponade; use of endophotocoagulation.

Results:

One hundred eyes of 92 patients were included in this study: 55 eyes in the LIB group and 45 in the BIL group. The occurrence of PSI was significantly lower in the BIL group with 1 case (2%) versus 22 cases (40%) in the LIB group ($p < .001$). Among the risk factors studied, pre-operative synechiae and the use of retinal endophotocoagulation were almost significantly associated with the occurrence of posterior synechiae of the iris ($p = .068$ and $.087$ respectively). In the LIB group, these PSI led to one case of acute elevation of intraocular pressure by pupillary seclusion and the use of laser iridotomy in 8 cases.

Conclusions:

The use of BIL rather than LIB implantation in phacovitrectomy practically eliminates PSI.

INTRODUCTION

The Bag-In-the-Lens (BIL) implantation technique was described by Tassignon et al. in 2002¹. The technique involves production of an anterior and posterior capsulorhexis of the same diameter followed by insertion of a specially designed implant so that the two capsules are positioned in the groove of the implant, at 360° (Figure 1). Application of this technique avoids any occurrence of posterior capsular opacification and anterior capsular contraction², thereby eliminating any need for laser capsulotomy³.

As regards pediatric cataract surgery, the interest of this technique is well-established. It avoids visual axis re-opacification, which despite posterior continuous curvilinear capsulorhexis and intraoperative vitrectomy can occur with a prevalence of up to 40%⁴. The technique also seems to have benefits in vitreoretinal surgery. Following combined phacovitrectomy surgery, posterior synechiae of the iris (PSI) are a frequent complication, occurring in nearly a quarter of cases⁵. More often than not, they constitute a connection between the posterior surface of the iris and the residual anterior crystalloid, or at times with the anterior surface of the implant⁵. These synechiae may cause a decrease in visual acuity, photophobia or acute elevation of intraocular pressure by pupillary seclusion^{6,7}. These synechiae also have the effect of limiting pupillary dilation, rendering it difficult and sometimes impossible to carry out ophthalmoscopic examination of the retinal periphery, which has an important role in postoperative follow-up of a vitrectomy.

Our study consisted in a retrospective comparison of the occurrence rate of PSI after phacovitrectomy between a group with a Lens-In-the Bag (LIB) implantation (LIB group),

i.e. implantation in the capsular bag and a group with implantation using the Bag-In-the-Lens technique (BIL group).

MATERIALS AND METHODS

In this comparative retrospective study, all patients subjected to phacovitrectomy with no complications between May 2013 and July 2016 in the ophthalmology department of Caen University Hospital (France), indiscriminately of the surgical technique, were included in this study. Patients with follow-up of less than 3 months were excluded from the study. All surgeries were performed by two surgeons (E.D. and A.D.) and the choice of surgical technique was left to the discretion of the surgeon. The implant used in the BIL group (Type 89A, Morcher, Stuttgart, Germany) was a hydrophilic acrylic lens with a 5 mm central, round optic surrounded by 2 perpendicular haptics (7.5 mm) separated by a circular equatorial groove in which both lens capsules should settle (figure 2). In the LIB group, different intraocular lenses (IOLs) were used: 39 AcrySof © SN60WF implant (Alcon), 12 AcrySof © MA50BM implant (Alcon), 3 Tecnis © ZCB00 implant (AMO) and 1 Eye-Cee © implant (Nidek). The anterior capsulorhexis diameter was 5 mm in both groups. In the BIL group, it involved use a ring caliper⁸, i.e. a thin plastic ring (with an internal diameter of 5 mm), transitionally apposed to the anterior capsule surface to serve as a guide for anterior capsulorhexis. In the LIB group, anterior capsulorhexis diameter was always slightly inferior to that of the IOL optic.

One hundred and fifty-six successive phacovitrectomies (147 patients) were performed over the course of the study. Among those excluded were 24 cases in which the IOL could not be inserted correctly in the bag (16 cases of ocular trauma with posterior zonal or posterior

capsular injury, 8 cases of intraoperative posterior capsular rupture), one case in which the BIL implant could not be inserted correctly (only the anterior capsule was inserted), one case with posterior dislocation of the BIL lens (due to anterior proliferative vitreoretinopathy and gas tamponade), and 31 cases with postoperative follow-up of less than 3 months. The 100 eyes included in the study were those of 92 patients. Four patients were bilaterally implanted with a BIL lens. Two patients were bilaterally implanted with a LIB lens. Two patients had a BIL lens on one side and a LIB lens on the other side. Fifty-five eyes (53 patients) were included in the LIB group and 45 eyes (41 patients) in the BIL group.

Postoperative follow-up consisted of three visits within two months of the operation, followed by a visit every two months. Postoperative anti-inflammatory treatment was similar in both groups. It consisted in dexamethasone eyedrops tapered over 8 weeks and dexamethasone ointment at night for 4 weeks. It also involved antibiotic eye drops (azithromycin or tobramycin), artificial tears and intraocular pressure-lowering eye drops, depending on the case. Contrary to the BIL group, the LIB group received tropicamide treatment three times a day for one month.

The assessment criteria were collected *a posteriori* in the medical records of each patient. The primary assessment criterion was the presence of PSI detected by slit lamp during postoperative follow-up examinations. This criterion was validated if it was observed after pupillary dilatation, and on the occasion of at least two different examinations. The other collected criteria were: characteristics and history of the patient, presence of preoperative posterior synechiae of the iris, the surgical indication, the intraoperative procedures (endophotocoagulation, intraocular tamponade) applied, the size used for the vitrectomy (20, 23 or 25 gauge), type of implant used, the time when PSI appeared, occurrence of

complications PSI-related, use of a postoperative laser iridotomy, occurrence of posterior capsule opacification (PCO) formation and anterior capsular contraction, and use of laser capsulotomy.

Quantitative variables were compared with Student t test, qualitative variables with Fisher test. The threshold for significance in all calculations was $p < .05$. A logistic regression was conducted to assess the influence of implant type (BIL versus LIB) and various risk factors on the occurrence of postoperative PSI with a general linear model. The risk factors included in the multivariate analysis were: age, indication for the phacovitrectomy, presence of pre-operative PSI; presence of a proliferative diabetic vitreoretinopathy (PDR); use of 20G vitrectomy (as opposed to use of 23 or 25G vitrectomy); use of a gas or silicone tamponade; use of endophotocoagulation (all types, including panphotocoagulation). In the LIB group, the influence of the type of IOL on the rate of PSI was studied using Fisher's Exact Test. A stepwise regression was conducted to identify the best model according to the Akaike Information Criteria (AIC). The full model including all available variables is presented along with the best model. No interactions were found between risk factors and type of implant. "Individuals" were not strictly independent as 16 operated eyes involved 8 patients (see the "Results" section). Consequently, a similar analysis was conducted on the dataset after exclusion of these 8 patients and led to exactly the same results. The results presented here are issued from the analysis with the whole dataset. Statistical analyses were conducted with R software version 3.4.3^A. Implementation of this study complied with the National Commission for Data Protection (CNIL) recommendations and was approved by a local Institutional Review Board.

RESULTS

Average postoperative follow-up duration was 623 +/- 346 days (11 visits) in the LIB group and 432 +/- 326 days (8 visits) in the BIL group. Operative indications in the LIB and the BIL groups differed significantly ($p < .001$) with more epiretinal membranes, more vitreomacular traction syndromes and no intraocular foreign body in the BIL group. Sclerotomy caliber also differed between the two groups with more 20 G sclerotomies and no 25G sclerotomies in the LIB group and more 23G sclerotomies in the BIL group ($p < .001$). The two groups also significantly differed as regards use of intraocular tamponade ($p = .027$), which was more frequently reported in the LIB group. Characteristics of the two groups are summarized in Table 1.

The occurrence of PSI was significantly lower in the BIL group with 1 case (2%) versus 22 cases (40%) in the LIB group ($p < .001$). In the BIL group, PSI consisted in a thin strand between the posterior surface of the iris and the anterior surface of the implant, not the anterior residual capsule.

In univariate analysis (Table 2), PSI was favored by use of a LIB implantation ($p < .001$), a postoperative gas or silicone tamponade ($p < .001$), endophotocoagulation ($p < .001$) and with a trend towards significance concerning use of 20 G vitrectomy ($p = .051$) and pre-operative PSI ($p = .070$). Indications also differed significantly in occurrence of postoperative synechiae ($p < .001$). In multivariate analysis, only use of a LIB implantation ($p = .004$) was associated with PSI, with a trend towards significance for pre-operative PSI ($p = .068$) and endophotocoagulation ($p = .087$). We have distinguished cases undergoing panretinal endophotocoagulation – expected to trigger a massive post-operative inflammatory response

– from other cases of endophotocoagulation. However, use of panretinal endophotocoagulation was not significantly associated with postoperative PSI in univariate analysis.

Observation time of the PSI ranged from 4 to 90 days following surgery (23 days on average). In the LIB group, the type of IOL used had no significant influence on the occurrence of PSI ($p = .431$).

In terms of PSI-related complications, one case of acute elevation of intraocular pressure caused by pupillary seclusion was observed in the LIB group ($p = 1.000$). Laser iridotomy to avoid this complication was necessary in 9 patients in the LIB group with extensive PSI, while there were no cases in the BIL group ($p = .003$).

There were no cases of PCO in the 45 patients in the BIL group versus 26 out of 55 in the LIB group ($p < .001$). Laser capsulotomy was performed in 20 out of 55 cases (36.4%) in the LIB group. There were no cases of anterior capsular contraction among the 45 participants in the BIL group versus 6 out of 55 cases (10.9%) in the LIB group ($p = .031$). Radial Nd: Yag laser incisions of the anterior capsule were carried out to release the anterior capsular contraction in 4 cases in the LIB group ($p = .125$).

DISCUSSION

The present study shows that BIL implantation in phacovitrectomies can prevent posterior synechiae of the iris (PSI). Only one case out of 45 of limited PSI occurred in the BIL group compared to 22 out of 55 cases in LIB group. In the BIL group, the case involved only a thin

strand between the posterior surface of the iris and the anterior surface of the implant, not the anterior residual capsule. In the LIB group, rate of occurrence of posterior synechiae of the iris was 40%, which was higher than that found in the literature (between 19 and 24%)^{5,9-14}. This difference may be related to the fact that in the literature, the presence of synechiae was validated only if it was spread over at least 30° whereas in our study, it was validated for any degree of spread.

The formation of synechiae between the posterior surface of the iris and the implant or the residual anterior capsule is secondary to proliferation and metaplasia of the crystalline epithelial cells and the stroma of the iris¹⁵⁻¹⁷. This phenomenon is stimulated by intraoperative and postoperative inflammation and by proximity between the posterior surface of the iris and the implant¹⁸. The known risk factors for posterior synechiae formation in combined surgeries are intraocular tamponade by gas or silicone oil, use of endophotocoagulation (especially if the power is substantial), presence of proliferative diabetic retinopathy, use of 20G compared to 23G vitrectomy, intervention duration, presence of preoperative synechiae or presence of fibrin in the anterior chamber postoperatively^{5,10,11,19}. All of these risk factors have been taken into account in our study, and were included in the univariate and multivariate statistical analyses. Among these factors, in univariate analysis use of endophotocoagulation and gas or silicone tamponade were significantly associated with occurrence of PSI ($p < .001$). It seems possible that any action promoting intraocular inflammation is potentially a risk factor for PSI. Hence, peeling of the internal limiting membrane (which frequently results in a breakdown of the blood-retinal barrier with superficial retinal petechiae), peeling of adherent epiretinal membranes, retinectomy, or the placement of iris retractors may be risk factors. The multivariate statistical analysis performed in the present study showed that only LIB implantation was

significantly associated with PSI ($p = .004$). The other risk factors analyzed through multivariate statistical analysis were not significantly associated with postoperative PSI, although there was a trend toward significance for pre-operative PSI and endophotocoagulation. Panretinal endophotocoagulation is expected to result in a massive inflammatory response. However, this risk factor was not significantly associated with postoperative PSI, possibly owing to the small number of cases (6 in the LIB group and 5 in the BIL group). This result shows that BIL implantation in phacovitrectomy almost totally avoids postoperative PSI, even in patients with proliferative diabetic retinopathy, when 20G vitrectomy or a gas or silicone tamponade is used.

In the BIL technique the anterior and posterior capsules are inserted into the implant groove at 360° . The anterior capsule is located behind the anterior surface of the implant and is distant from the posterior surface of the iris, even when a tamponade, causing a postero-anterior thrust, is in place²⁰. In addition, the technique creates a confinement space for crystalline epithelial cells. These cells are trapped between the contiguous capsules and the groove of the implant, which limits their proliferation and metaplasia²¹⁻²³ (Figure 1). This principle of confinement makes it possible to prevent PCO formation and anterior capsular contraction^{2,4,24}. It also avoids the inflammatory reaction linked to the release of epithelial cells in the aqueous humor²⁵, and thereby contributes to the prevention of posterior synechiae of the iris. In addition, unlike the LIB implantation, the BIL implantation involves no contact with the sulcus and the ciliary body, which reduces the micro-trauma that can cause inflammation⁴.

The double optic capture technique described by DeBroff and Nihalini²⁶ entails – after anterior vitrectomy – optic capture behind the fused anterior and posterior capsules, with haptics in the sulcus. It efficiently prevents posterior capsule opacification but results in a more anterior final IOL location than in-the-bag placement. This may promote capsule

contact with the posterior surface of the iris, thereby making the technique less effective than BIL implantation as a means of preventing posterior synechiae formation.

The haptic tuck for reverse optic capture technique described by Gimbel and Marzouk²⁷ entails implantation of the IOL optic in front of the anterior capsule, with the haptics behind the anterior capsule. With this technique, most of the anterior capsule is kept at a distance of the posterior iris except for the two diametrically opposed zones where the anterior capsule straddles the haptics. Contact of the anterior capsule with the posterior iris may occur at these two zones, thereby possibly rendering this technique less effective than BIL implantation as a means of preventing posterior synechiae formation.

In the LIB group, the type of IOL used had no significant influence on the rate of PSI. The size of the anterior capsulorhexis was similar (5 mm) in both groups making their comparison with regard to PSI occurrence relevant. In patients having LIB implantation, the use of larger continuous curvilinear anterior capsulorhexis has been suggested (but has not proved its efficiency) as a means of minimizing PSI¹¹. This capsulorhexis should be large enough to enable postoperative examination and render treatment possible despite PSI¹³, but not so large as to entail IOL displacement (especially with gas tamponade) and its consequences: poor IOL centration and early PCO.

In our study, we chose to exclude patients with follow-up duration of less than 3 months after post op. This period corresponds to that used in the literature^{5,9,10,19} and it is most relevant to our study, with 100% of the cases of PSI being observed within the 3 months following the phacovitrectomy.

In the only case of postoperative PSI in the BIL group, they were minimal (thin fibrous strand between the posterior surface of the iris and the implant) and the patient previously presented several pro-inflammatory factors: preoperative synechiae, an intraocular gas tamponade, endophotocoagulation and peeling of the internal limiting membrane. In addition, the synechiae appeared after recurrence of retinal detachment that did not benefit from surgical revision because of poor prognosis. Furthermore, we excluded one case from our study, in which the BIL implant was not positioned according to the usual BIL technique. It involved a retinal detachment surgery patient with early recurrence due to lower anterior vitreoretinal proliferation, which entailed severe lower pulling of the posterior capsule²⁸, the result of which was posterior dislocation of the BIL implant and occurrence of PSI between the iris and the anterior capsule. The dislocated BIL implant led to a lack of cellular confinement and distance from the posterior side of the iris, which explained occurrence of the synechiae.

In our study, the two groups were not fully equivalent in terms of surgical indication, vitrectomy size and pre-operative risk factors (Table 1). The 20G caliber was more frequently used in the LIB group ($p < .001$). Multivariate analysis showed that its use was not a risk factor for PSI. Lens-in-the-bag implantation was more frequent in emergency surgery, such as retinal detachments or intraocular foreign bodies, whereas the BIL technique was more frequent in less urgent surgery, such as epiretinal membranes or vitreomacular traction syndrome ($p < .001$). This is partially due to the fact that before June 2015, BIL implants had to be ordered (no stock available), which limited their use in emergency surgery. It is also explained by the fact that proper BIL implantation cannot be used on previously vitrectomized eyes, at least when the vitrectomy had involved opening of the anterior hyaloid. In such cases it is not possible to have the anterior and posterior capsules affixed (pressed against one another), while it remains possible to fix the BIL IOL by fitting the

anterior capsule alone into the groove. In our cases, this type of fixation was not carried out. Despite this difference between the two groups, multivariate analysis showed that BIL implantation significantly reduced PSI ($p = .004$). Furthermore, contrary to the BIL group, the LIB group received tropicamide treatment three times daily. This treatment has been shown to reduce posterior synechiae after phacovitrectomy¹¹. And yet, the rate of synechiae in the LIB group was 22 out of 55 cases. The total surgical time was unfortunately not recorded and therefore could not be compared between the two groups. However, BIL implantation requires several additional steps (use of a ring caliper; injection of viscoelastic substance in the Berger space posterior capsulorhexis) the implementation of which results in approximately 3 minutes of additional surgical time compared to LIB implantation. Accordingly, for a given surgical procedure, total surgical time may be higher in the BIL group. This tends to corroborate our hypothesis that BIL implantation avoids PSI, total operating time being a known risk factor for PSI¹⁹.

In the present study, no PCO or anterior capsular contraction occurred in the 45 eyes in the BIL implantation group compared to 26 out of 55 eyes ($p < .001$) and 6 out of 55 eyes ($p = .031$) in the LIB implantation group respectively. By avoiding limitation of pupillary dilatation by posterior synechiae, PCO or anterior capsular contraction, BIL implantation durably facilitates retinal visualization up to the periphery and treatment (e.g.: photocoagulation or vitrectomy). Several publications have shown that unlike LIB implantation, BIL implantation makes it possible to completely avoid postoperative PCO^{2,3,24}. This has been demonstrated in a pediatric population who have had their cataract operated on with an average follow-up of more than 6 years⁴ and our study seems to confirm this result with regard to phacovitrectomies. This is particularly important insofar as PCO is more frequent in phacovitrectomies than in cataract surgery alone^{29,30} and given the fact that in cases where a silicone oil tamponade has been used, laser capsulotomy will not be feasible.

Better visualization of the fundus is a major asset in patients whose retina is at greater risk of complications than the general population.

Prevention of posterior synechiae formation avoids acute elevation of intraocular pressure by pupillary seclusion, which is a known complication of phacovitrectomies^{6,7}. One such case occurred in LIB implantation. Moreover, in 9 cases in the same group, we performed laser peripheral iridotomy to avoid this complication. In addition, a patient with an implant in the capsular bag, who was excluded from the study due to insufficient follow-up duration (deceased), had presented with acute elevation of intraocular pressure by pupillary seclusion.

The BIL technique is safe and does not pose a higher risk compared to the LIB technique^{2,31}.

Furthermore, it is generally possible to revert to LIB implantation during the surgical procedure. While BIL implantation entails a learning curve, we reckon that for an experienced surgeon, harming the anterior hyaloids is exceedingly rare (less than 1% of cases). In the present study, after correct placement of the BIL IOL, the anterior hyaloid was removed at the beginning of the vitrectomy. This step allowed cleaning of the viscoelastics trapped in Berger's space and liable to induce optic aberrations harming fundus visualization.

Posterior capsule opening does not entail opening of the anterior hyaloid and therefore does not lead to vitreous body prolapse in the anterior segment³². The only limitations of this technique are poor intraoperative visibility (e.g.: dense vitreous hemorrhage with no red reflex), significant zonal laxity, and a history of vitrectomy, at least when the anterior hyaloid has been opened. In such cases, after opening the posterior capsule absence of Berger space renders it impossible to achieve apposition of the 2 capsules by viscoelastic injection. For 7 cases in our LIB group, it was initially planned to use the BIL technique, but poor visibility for posterior capsulorhexis led the surgeon to change technique intraoperatively. In 6 cases there was insufficient pupil glow associated with intravitreal hemorrhage and corneal

transparency was insufficient. In the preoperative examination, special care should be taken to detect phacodonesis, as during BIL implantation the capsules are stretched and the zonule is under tension¹. In case of excessively high laxity, posterior capsulorhexis may result in an increased risk of zonular disinsertion.

During postoperative follow-up after placement of a BIL implant, pupillary dilatation should be monitored when a gas tamponade is used because there is a risk of capture of the implant by the iris due to the gas thrust. In the present study, one case of BIL IOL occurred. The patient had high myopia and was operated on for floaters and corticonuclear cataract. Fluid-air exchange was performed at the end of the procedure. Five days after surgery the patient consulted at the emergency room and was inadvertently dilated by a resident. Air filled approximately 60% of the vitreous cavity and IOL capture ensued. It resulted in complete IOL capture with IOP rise. The IOL was repositioned at the slit lamp using a 30G needle.

In conclusion, application of the BIL technique during phacovitrectomies significantly reduces posterior synechiae of the iris. Finally, the present study seems to confirm that the BIL technique permits complete absence of PCO formation and anterior capsular contraction.

WHAT WAS KNOWN

- The BIL technique can prevent occurrence of posterior capsular opacification.
- It is a useful technique in cataract surgery for children.

WHAT THIS PAPER ADDS

- Application of the BIL technique during phacovitrectomies practically eliminates the occurrence of posterior synechiae of the iris.

REFERENCES

1. Tassignon M-JBR, De Groot V, Vrensen GFJM. Bag-in-the-lens implantation of intraocular lenses. *J Cataract Refract Surg* 2002; 28:1182-1188
2. Tassignon M-J, Gobin L, Mathysen D, Van Looveren J, De Groot V. Clinical outcomes of cataract surgery after bag-in-the-lens intraocular lens implantation following ISO standard 11979-7:2006. *J Cataract Refract Surg* 2011; 37:2120-2129
3. Leysen I, Coeckelbergh T, Gobin L, Smet H, Daniel Y, De Groot V, Tassignon M-J. Cumulative neodymium:YAG laser rates after bag-in-the-lens and lens-in-the-bag intraocular lens implantation: comparative study. *J Cataract Refract Surg* 2006; 32:2085-2090
4. Van Looveren J, Ní Dhubhghaill S, Godts D, Bakker E, De Veuster I, Mathysen DGP, Tassignon M-J. Pediatric bag-in-the-lens intraocular lens implantation: long-term follow-up. *J Cataract Refract Surg* 2015; 41:1685-1692
5. Kim S-W, Oh J, Song J-S, Kim YY, Oh I, Huh K. Risk factors of iris posterior synechia formation after phacovitrectomy with three-piece acrylic IOL or single-piece acrylic IOL. *Ophthalmologica* 2009; 223:222-227
6. Makhzoum O, Crosby NJ, Hero M. Secondary angle-closure glaucoma due to posterior synechiae formation following phacovitrectomy. *Int Ophthalmol* 2011; 31:481-482
7. Raj P, Kumar K, Chandnani N, Agarwal A, Agarwal A. Secondary Angle-Closure Glaucoma Due to Posterior Synechiae of Iris Following Combined Phacoemulsification and 23-Gauge Transconjunctival Vitrectomy. *Semin Ophthalmol* 2016; 32:537-542
8. Tassignon M-J, Rozema JJ, Gobin L. Ring-shaped caliper for better anterior capsulorhexis sizing and centration. *J Cataract Refract Surg* 2006; 32:1253-1255
9. Shinoda K, O'hira A, Ishida S, Hoshide M, Ogawa LS, Ozawa Y, Nagasaki K, Inoue M, Katsura H. Posterior synechia of the iris after combined pars plana vitrectomy, phacoemulsification, and intraocular lens implantation. *Jpn J Ophthalmol* 2001; 45:276-280
10. Rudnisky CJ, Cheung J, Nanji JA. Intraocular lens capture in combined cataract extraction and pars plana vitrectomy: comparison of 1-piece and 3-piece acrylic intraocular lenses. *J Cataract Refract Surg* 2010; 36:1645-1649
11. Lee SB, Lee DG, Kwag JY, Kim JY. The effect of mydriatics on posterior synechia after combined pars plana vitrectomy, phacoemulsification, and intraocular lens implantation. *Retina* 2009; 29:1150-1154
12. Honjo M, Ogura Y. Surgical results of pars plana vitrectomy combined with phacoemulsification and intraocular lens implantation for complications of proliferative diabetic retinopathy. *Ophthalmic Surg Lasers* 1998; 29:99-105

13. Lahey JM, Francis RR, Kearney JJ. Combining phacoemulsification with pars plana vitrectomy in patients with proliferative diabetic retinopathy: a series of 223 cases. *Ophthalmology* 2003; 110:1335-1339
14. Heiligenhaus A, Holtkamp A, Koch J, Schilling H, Bornfeld N, Lösche CC, Steuhl KP. Combined phacoemulsification and pars plana vitrectomy: clear corneal versus scleral incisions: prospective randomized multicenter study. *J Cataract Refract Surg* 2003; 29:1106-1112
15. Lavin M, Jagger J. Pathogenesis of pupillary capture after posterior chamber intraocular lens implantation. *Br J Ophthalmol* 1986; 70:886-889
16. McDonnell PJ, Zarbin MA, Green WR. Posterior capsule opacification in pseudophakic eyes. *Ophthalmology* 1983; 90:1548-1553
17. Odrich MG, Hall SJ, Worgul BV, Trokel SL, Rini FJ. Posterior capsule opacification: experimental analyses. *Ophthalmic Res* 1985; 17:75-84
18. Amon M, Menapace R. In vivo documentation of cellular reactions on lens surfaces for assessing the biocompatibility of different intraocular implants. *Eye Lond Engl* 1994; 8:649-656
19. Oh J-H, Na J, Kim S-W, Oh J, Huh K. Risk factors for posterior synechiae of the iris after 23-gauge phacovitrectomy. *Int J Ophthalmol* 2014; 7:843-849
20. Iwase T, Sugiyama K. Investigation of the stability of one-piece acrylic intraocular lenses in cataract surgery and in combined vitrectomy surgery. *Br J Ophthalmol* 2006; 90:1519-1523
21. De Keyzer K, Leysen I, Timmermans J-P, Tassignon M-J. Lens epithelial cells in an in vitro capsular bag model: lens-in-the-bag versus bag-in-the-lens technique. *J Cataract Refract Surg* 2008; 34:687-695
22. Werner L, Tassignon M-J, Gobin L, Rozema J, Davis D, Brubaker J. Bag-in-the-lens: first pathological analysis of a human eye obtained postmortem. *J Cataract Refract Surg* 2008; 34:2163-2165
23. Werner L, Tassignon M-J, Zaugg BE, De Groot V, Rozema J. Clinical and histopathologic evaluation of six human eyes implanted with the bag-in-the-lens. *Ophthalmology* 2010; 117:55-62
24. De Groot V, Leysen I, Neuhann T, Gobin L, Tassignon M-J. One-year follow-up of bag-in-the-lens intraocular lens implantation in 60 eyes. *J Cataract Refract Surg* 2006; 32:1632-1637
25. Stifter E, Menapace R, Kriechbaum K, Vock L, Luksch A. Effect of primary posterior continuous curvilinear capsulorhexis with and without posterior optic buttonholing on postoperative anterior chamber flare. *J Cataract Refract Surg* 2009; 35:480-484
26. DeBroff BM, Nihalani BR. Double Optic Capture With Capsular Bag Fusion: A New Technique for Pediatric Intraocular Lens Implantation. *Tech Ophthalmol* 2008; 6:31-34

27. Gimbel HV, Marzouk HA. Haptic tuck for reverse optic capture of a single-piece acrylic toric or other single-piece acrylic intraocular lenses. *J Cataract Refract Surg* 2019; 45:125-129
28. Hirose T. Proliferative Vitreoretinopathy. In: Schepens CL, Hartnett ME, Hirose T, eds, *Schepens' Retinal Detachment and Allied Diseases* 2nd ed. Boston, Mass, Butterworth-Heinemann, 2000; 395-420
29. Li W, Sun G, Wu R, Wang X, Xu M, Sun C. Longterm results after phacovitrectomy and foldable intraocular lens implantation. *Acta Ophthalmol* 2009; 87:896-900
30. Iwase T, Oveson BC, Nishi Y. Posterior capsule opacification following 20- and 23-gauge phacovitrectomy (posterior capsule opacification following phacovitrectomy). *Eye* 2012; 26:1459-1464
31. Tassignon M-J, Van den Heurck JJI, Boven KBM, Van Looveren J, Wouters K, Bali E, Ní Dhubhghaill S, Mathysen DGP. Incidence of rhegmatogenous retinal detachment after bag-in-the-lens intraocular lens implantation. *J Cataract Refract Surg* 2015; 41:2430-2437
32. De Groot V, Hubert M, Van Best JA, Engelen S, Van Aelst S, Tassignon MJ. Lack of fluorophotometric evidence of aqueous-vitreous barrier disruption after posterior capsulorhexis. *J Cataract Refract Surg* 2003; 29:2330-2338

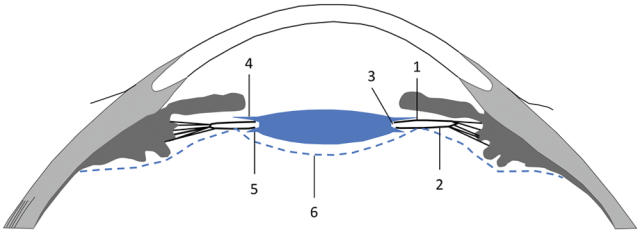
OTHER CITED MATERIAL

- A. R Core Team (2017). *R : A language and environment for statistical computing*. R Foundation for statistical computing, Vienna, Austria. URL: <https://www.r-project.org/>

FIGURE LEGENDS

Figure 1: Schematic cross-section of the anterior segment showing bag-in-the-lens implantation : 1 = anterior capsule; 2 = posterior capsule; 3 = groove into which both capsules are affixed; 4 = anterior haptic; 5 = posterior haptic; 6 = anterior hyaloid.

Figure 2: Schematic bag-in-the-lens IOL : 1 = optic; 2 = groove; 3 = posterior haptic; 4 = anterior haptic.



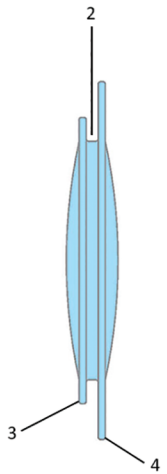
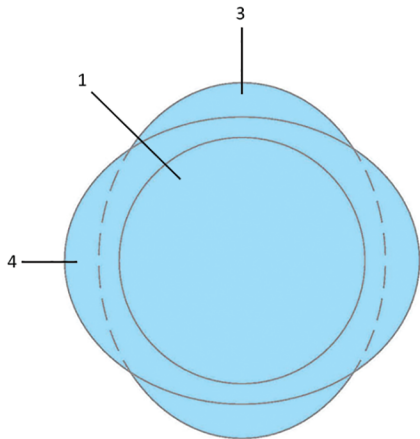


Table 1: Comparison of the two groups

	LIB % (n)	BIL % (n)	p-value
Age in years, mean (SD)	64,0 (13.4)	67.0 (10.2)	.197
Postoperative synechiae	40.0 (22)	2.2 (1)	<.001
Operative indication			<.001
Epiretinal membrane	7.3 (4)	31.1 (14)	
Vitreomacular traction syndrome	5.5 (3)	31.1 (14)	
Complicated proliferative diabetic retinopathy	18.2 (10)	15.6 (7)	
Retinal detachment (not including DR)	32.7 (18)	15.6 (7)	
Intravitreal hemorrhage (not including DR)	12.7 (7)	2.2 (1)	
Intraocular foreign body	14.5 (8)	0.0 (0)	
Uveitis	1.8 (1)	2.2 (1)	
Floater	0.0 (0)	2.2 (1)	
Silicon oil removal	7.3 (4)	0.0 (0)	
Size of the sclerotomies			<.001
20G Vitrectomy	69.1 (38)	11.1 (5)	
23G Vitrectomy	30.9 (17)	84.4 (38)	
25G Vitrectomy	0.0 (0)	4.4 (2)	
Presence of pre-operative synechiae	16.4 (9)	8.9 (4)	.373
Intraocular tamponade (gas or silicone)	65.5 (36)	42.2 (19)	.027
Endophotocoagulation (all types)	70.9 (39)	55.6 (25)	.144
Endophotocoagulation (PRP)	10.9 (6)	11.1 (5)	1.000
Proliferative diabetic retinopathy	18.2 (10)	15.5 (7)	.794

LIB = Lens-In-the-Bag ; BIL = Bag-In-the-Lens ; DR = Diabetic Retinopathy ; PRP = Panretinal Photocoagulation

Table 2: Univariate and multivariate analyses for postoperative synechiae risk factors

	Univariate analysis			Multivariate analysis			
	Presence of postoperative synechiae % (n)	Absence of postoperative synechiae % (n)	p-value	Full model		Best model	
				OR (95% CI)	p-value	OR (95% CI)	p-value
Age, mean (SD)	62.9 (11.4)	66.1 (12.2)	.252	1.06 (0.99; 1.14)	.100		
Indication			<.001				
Complicated proliferative diabetic retinopathy	13.0 (3)	18.2 (14)		-	-		
Epiretinal membrane	0.0 (0)	23.4 (18)		0.00 (0.00; inf.)	.994		
Retinal detachment (not including DR)	56.5 (13)	15.6 (12)		1.15 (0.08; 15.04)	.914		
Intravitreal hemorrhage (not including DR)	0.0 (0)	10.4 (8)		0.00 (0.00; inf.)	.995		
Intraocular foreign body	17.4 (4)	5.2 (4)		1.34 (0.06; 27.72)	.845		
Uveitis	0.0 (0)	2.6 (2)		0.00 (0.00; inf.)	.998		
Floater	0.0 (0)	1.3 (1)		0.00 (0.00; inf.)	.998		
Silicon oil removal	4.3 (1)	3.9 (3)		0.33 (0.00; 13.39)	.576		
Vitreomacular traction syndrome	8.7 (2)	19.5 (15)		NA	NA		
Implant: LIB (vs BIL)	95.7 (22)	42.9 (33)	<.001	65.21 (5.88; 1920.80)	.003	24.94 (4.18; 498.70)	.004
Pre-operative PSI	26.9 (6)	9.1 (7)	.070	5.93 (0.68; 91.07)	.145	6.04 (1.01; 54.77)	.068
PDR	13.0 (3)	18.2 (14)	.755	0.10 (0.00; 2.47)	.176		
Vitrectomy							
With 20G	65.2 (15)	36.4 (28)	.051	-	-		

	With 23G	34.8 (8)	61.0 (47)		1.89 (0.33, 13.16)	.484		
	With 25G	0.0 (0)	2.6 (2)		0.00 (0.00; inf.)	.998		
Use of gas or silicone tamponade		91.3 (21)	44.2 (34)	<.001	1.57(0.20; 16.87)	.681	4.34 (0.75; 39.49)	.130
Endophotocoagulation (all types)		95.7 (22)	54.5 (42)	<.001	24.01 (1.51; 1042.35)	.046	9.23 (0.99; 232.86)	.087
Endophotocoagulation (PRP)		8.7 (2)	11.7 (9)	1.000	2.47 (0.14; 78.66)	.552		

LIB = Lens In the Bag ; PSI = Posterior Synechiae of the Iris ; PDR = Proliferative Diabetic Retinopathy ; PRP = Panretinal Photocoagulation

Odds ratio being the exponential of the regression coefficient, a coefficient close to 0 resulted in a confidence interval for the coefficient ranging from a negative value to a very high value, therefore an odds ratio ranging from 0 to almost infinite, noted as 0.00 (0.00; inf.). For the vitromacular traction syndrome indication, there was considerable collinearity with other variables, which meant that this indication added no information to the model that had not previously been provided by other variables; for that reason, the odds ratio was not estimated.