



HAL
open science

A systematic review and meta-analysis of margins in transoral surgery for oropharyngeal carcinoma

Philippe Gorphe, Christian Simon

► To cite this version:

Philippe Gorphe, Christian Simon. A systematic review and meta-analysis of margins in transoral surgery for oropharyngeal carcinoma. *Oral Oncology*, 2019, 98, pp.69 - 77. 10.1016/j.oraloncology.2019.09.017 . hal-03487444

HAL Id: hal-03487444

<https://hal.science/hal-03487444v1>

Submitted on 20 Jul 2022

HAL is a multi-disciplinary open access archive for the deposit and dissemination of scientific research documents, whether they are published or not. The documents may come from teaching and research institutions in France or abroad, or from public or private research centers.

L'archive ouverte pluridisciplinaire **HAL**, est destinée au dépôt et à la diffusion de documents scientifiques de niveau recherche, publiés ou non, émanant des établissements d'enseignement et de recherche français ou étrangers, des laboratoires publics ou privés.



Distributed under a Creative Commons Attribution - NonCommercial 4.0 International License

A systematic review and meta-analysis of margins in transoral surgery for oropharyngeal carcinoma

Philippe Gorphe ^a, Christian Simon ^b

^a Department of Head and Neck Oncology, Institute Gustave Roussy, University Paris-Saclay, Villejuif, France

^b Department of Otolaryngology – Head and Neck Surgery, CHUV, University of Lausanne, Lausanne, Switzerland

Corresponding author:

Dr. Philippe Gorphe, Department of Head and Neck Oncology, 114 rue Edouard Vaillant, Gustave Roussy, 94800 Villejuif, France

Email: Philippe.gorphe@gustaveroussy.fr

Keywords:

Transoral surgery; transoral robotic surgery, transoral laser microsurgery; oropharyngeal carcinoma; margins

Abstract

Background: The objective of this study was to conduct a systematic review and meta-analysis of the incidence of positive surgical margins after transoral surgery for oropharyngeal carcinoma, as well as the factors associated with positive margins and their impact on local tumor control.

Method: An electronic search of English-language literature databases was conducted, and a systematic review was performed in accordance with the PRISMA guidelines.

Results: A total of 42 articles were included in the analysis. The overall rate of positive margins using transoral conventional surgery (CTS), transoral laser microsurgery (TLM), or transoral robotic surgery (TORS) was 7.8% in a cumulative total of 3,619 patients. A positive margin status was associated with a reduction in local control. Assessment of intraoperative frozen sections was associated with a reduced risk of definitive positive margins, whereas a T4 classification was associated with an increased risk of definitive positive margins. Neither the primary site (the tonsillar fossa versus the base of the tongue), nor the HPV status, were associated with the margin status. The level of heterogeneity between the various studies was very high.

Conclusion: The currently used transoral procedures are safe in regard to proper tumor resection and they should continue to be part of the armamentarium of surgical techniques used in head and neck surgery. The very high level of heterogeneity between studies calls for a definition consensus for margin status assessments in transoral surgery.

Keywords

Oropharyngeal carcinoma; transoral surgery; transoral laser microsurgery; transoral robotic surgery; margin status; positive margins; meta-analysis

Introduction

Head and neck cancers are the 6th most common cancer worldwide, with 630,000 new cases annually [1]. More than half of all head and neck cancer patients require primary surgical treatment, and typically more than two-thirds will have to undergo a surgery at some point during their treatment [2]. Due to the biological properties of epithelial cancers, namely their invasive growth, comprehensive and radical resection of the primary tumor with a minimal risk of residual disease often requires a large cuff of macroscopically healthy tissue around the tumor. In more than one-third of all surgical cases, the patients ultimately have positive or cut-through margins as a consequence of the infiltrative growth patterns of the tumor, or due to restrictions during the resection owing to confinements of the anatomy as a result of nearby vital structures [3]. As a result, there is often the persistence of residual disease in the surgical wound bed. These typically give rise to loco-regional recurrences that can ultimately lead to death of the patient. The decision-making for potential intensification of the postoperative treatment with concurrent chemoradiation, therefore, relies, amongst other factors, on assessment of the surgical margin in order to assess the risk for microscopically residual disease [4]. Traditional open surgical resection in head and neck cancer mandated free microscopic margins of at least five millimeters to be considered negative, like used in the EORTC 22931 trial [4]. However, the development of transoral techniques for minimal-invasive surgery in narrow spaces has challenged this concept of 5-mm free margins due to anatomical limitations, without decrease in disease control reported. For example, in endoscopic laser microsurgery for early laryngeal glottic tumors, negative margins down to one millimeter have been shown to be oncologically safe for some authors [3, 5]. With recent developments in minimal-invasive transoral surgery for pharyngeal cancer, this has led to considerable heterogeneity amongst institutions and authors with how to define adequate margins [3].

Actually, transoral surgery is a surgical treatment strategy for selected head and neck cancers that are amenable to transoral exposure and resection [6]. This is nowadays performed either with conventional instruments (transoral conventional surgery, TCS), a CO₂-laser (transoral laser microsurgery, TLM), or a robotic surgical system (transoral robotic surgery, TORS). While the head and neck surgeon during open trans-cervical procedures operates from the outside to the inside and needs to be fully acquainted with the specific anatomy, the transoral surgeon needs to master an “inside-out” approach and the changing anatomy and landmarks inherent with this approach [6, 7]. In selected patients, transoral surgery may offer significant advantages based on the fact that it helps avoid transcervical access trauma, it reduces the healing time, and it allows for better and faster functional recovery. While all of these advantages are certainly of benefit to the patient, transoral approaches can result in intraoperative situations whereby visibility of critical structures and tissue handling is hampered as a

consequence of the confined workspace and thus can impact on the adequacy of the surgical resection. It is, therefore, of critical importance to analyze the available data regarding the surgical margin status after this type of intervention.

In this systematic review, we investigated the incidence of positive surgical margins after transoral surgery for oropharyngeal carcinoma, as well as the factors associated with positive margin and their impact on local tumor control.

Material and Methods

This systematic review was carried out in accordance with the Cochrane handbook for systematic reviews of interventions, and the results are reported according to the Preferred Reporting of Systematic Reviews and Meta-Analyses (PRISMA) guidelines. Records were identified by searching the MEDLINE database, using the keywords (TRANSORAL [All Fields] OR LASERS [MeSH Terms] OR LASERS [All Fields] OR LASER [All Fields] OR ROBOTICS [MeSH Terms] OR ROBOTICS [All Fields] OR ROBOTIC [All Field] OR TORS [All Fields]) AND (OROPHARYNX [MeSH Terms] OR OROPHARYNX [All Field] OR OROPHARYNGEAL [All Fields]). The results were restricted to English-language studies. The records were screened for exclusion criteria, which comprised: articles not dedicated to transoral surgery in oropharyngeal cancer; articles other than case-series; case-series with fewer than ten patients; histologies other than squamous-cell carcinoma; case-series with multiple head and neck cancer localizations such as the hypopharynx and the supraglottic larynx; and reports in which the margins were not indicated. The available full-text articles were assessed for eligibility before they were included in the final qualitative analysis. Potential additional records were identified by screening of the references in the full-text articles included in the final qualitative synthesis. They were then checked for duplicates, screened for the exclusion criteria, and assessed for eligibility. The initial search was performed on the 1st of November 2018, with a follow-up search to identify newly published articles on the 1st of May 2019. The data were reviewed by two reviewers (PG and CS). The extracted data comprised: the number of patients operated; an oropharyngeal primary tumor subsite (the tonsillar fossa, the base of tongue, the soft palate, or the pharyngeal wall); the primary T classification; the surgical approach (conventional transoral surgery, transoral laser microsurgery, or transoral robotic surgery); the type of margins reported for positive/close/negative or positive/negative; the definition of the perioperative macroscopic surgical margins; assessment of intraoperative frozen sections; the outcomes of the definitive microscopic analyses; the threshold

for close margins; the number of definitive positive/close/negative margins; and the number of patients with local recurrence. The statistical analysis was based on the cumulative number of patients, using IBM SPSS Statistics for Windows version 23 software (IBM Corp., Armonk, NY, USA) and Comprehensive Meta-Analysis version 3.3.070 software (Biostat Inc., Englewood, NJ, USA). Dichotomous outcomes were compared using risk ratios (RRs) and 95% confidence intervals. Heterogeneity across the studies was evaluated by the chi-squared statistic and the Fisher's exact test. The I^2 test was used to measure the degree of inconsistency between the results. Meta-analysis was carried out using the random effects model.

Results

Study selection and margins

A total of 42 articles were included in the analysis (Figure 1): 3 series of conventional transoral surgery (CTS) [8-10], 4 series of CTS or TLM [11-14], 10 series of TLM [15-24], 1 series of CTS or TORS [25], and 24 series of TORS [26-49]. One series with CTS and TLM procedures also comprised of a small number of patients treated by an open approach [14]. Some authors published several articles, resulting in a risk of cross-matching data [9, 10, 16, 17, 19-21, 24, 26, 31, 40, 41, 44, 48, 49]. The cumulative number of patients was 3,725 (Table 1). Of the 2,299 patients evaluated for HPV status in 27/42 series, 1,810 patients (78.7%) were considered HPV-positive due to either positive p16 immunohistochemistry or positive genotyping.

Four articles out of 42 provided the intraoperative macroscopic margins of the healthy tissue around the primary tumor. This was 10 mm in three series [18, 43, 46] and 10-15 mm in one series [21]. In 14/42 articles (33.3%), definitive margins were categorized as positive, close, or negative. The definition of close margins was 1 mm in one series [20], 2 mm in 5 series [13, 29, 36, 39, 45], 3 mm in two series [40, 46], and 5 mm in four series [14, 22, 34, 37]. In one series, the definition was not provided [8], and in one series close margins were defined as 5 mm for infiltrative carcinomas or 3 mm for tumors with "pushing" borders [35]. Two articles [39, 45] did not report the rate of close margins separately from positive margins. For patients from these series, the margins were positive in 84 patients (12%) and negative in 614 patients (88%), of whom 96 had close margins (13.8%) and 518 were reported to have clear margins (74.2%). In the remaining 28 articles, definitive margins were reported as being either positive or negative. The total cumulative number of patients analyzed for margin status was 3,619. The margins were positive in 283 patients (7.8%) and negative in 3,336 patients (92.2%). Factors analyzed in univariate analysis for a risk of positive margins were the primary tumor site, the primary tumor T-

classification, the HPV status, the transoral surgical procedure, and assessment of intraoperative frozen sections (Figure 2).

The primary tumor site and positive margins

The primary tumor subsites were the tonsillar fossa in 58.3% of the patients, the base of the tongue in 32.2%, the soft palate in 7.4%, and the pharyngeal wall in 2.2%. The margin status was reported in 677 patients with tonsillar carcinoma and 254 patients with tongue base carcinoma. The rates of positive margins were 4% and 5.9%, respectively, and they were not significantly different (two-tailed Fisher's exact test, $p=0.217$; RR, 1.48; 95% CI, 0.80 to 2.74).

The primary tumor T-classification and positive margins

The T classification of the primary tumor, when reported, was T1 in 44.4% of cases, T2 in 41.5%, T3 in 9.4%, and T4 in 4.6%. The rate of positive margins was higher in the patients with T4 OPSCC (13.2%) than in the patients with T1-3 carcinoma (two-tailed Fisher's exact test, $p=0.0248$; RR, 2.54; 95% CI, 1.21 to 5.33), whereas there was no difference between T3 OPSCC and T1-2 tumors (two-tailed Fisher's exact test, $p=1.000$; RR, 1.31; 95% CI, 0.42 to 4.11).

HPV status and positive margins

The margin status according to the HPV status was available in five series [14, 18, 23, 29, 33]. The margins were positive in 13 patients out of 283 HPV-positive cases (4.6%), and they were positive in 10 out of 118 HPV-negative cases (8.5%). The HPV-positive and the HPV-negative tumors exhibited similar rates of positive margins (two-tailed Fisher's exact test, $p=0.1565$; RR, 1.78; 95% CI, 0.80 to 3.95).

Frozen sections and positive definitive margins

The series were categorized as series reporting systematic intraoperative frozen sections analysis, series reporting on demand intraoperative frozen sections analysis, and series that did not report frozen sections. Among the 24 studies which reported frozen section, ten reported specimen-based frozen section [18-21, 26-28, 30, 48, 49], four reported patient-based frozen section [15, 22, 45, 46], and ten did not specifically describe the method used [9, 10, 16, 17, 23, 24, 31, 32, 36, 37]. Eight series reported systematic frozen section analysis [9, 10, 15, 17, 20, 31, 32, 37]. The cumulative number of patients was 501, of whom 25 (5%) had positive final margins. Sixteen series reported on demand frozen section analysis, depending on the intraoperative assessment

of the quality of the resection [16, 18, 19, 21-24, 26-28, 30, 36, 45, 46, 48, 49]. The cumulative number of patients was 2,046, of whom 69 (4.6%) had positive final margins. Thirteen series did not report frozen section analysis, with a cumulative number of patients of 1,367, of whom 169 (12.3%) had positive final margins. The chi-squared comparison test was significant ($p < 0.0001$). The rates of final positive margins were significantly higher in the patients in series where frozen section analyses were not reported (Chi-squared with Yates' correction, $p < 0.0001$; RR, 2.64; 95% CI, 2.07 to 3.37).

The transoral surgical procedure and positive margins

When the patients were combined, the cumulative number of patients operated via CTS with an available margin status was 301, of whom 20 had positive margins (6.6%) and 281 had negative margins (93.4%). The cumulative number of analyzed patients who underwent TLM with an available margin status was 1,012, of whom 48 had positive margins (4.7%) and 964 had negative margins (95.3%). The cumulative number of analyzed patients who underwent TORS with an available margin status was 1,676, of whom 135 had positive margins (8.1%) and 1,541 had negative margins (91.9%). The chi-squared comparison test was significant ($p=0.0042$). The reported rate of positive margins was lower in the TLM patients than in the CTS or the TORS patients (Chi-squared with Yates' correction, $p=0.0019$; RR, 1.65; 95% CI, 1.21 to 2.27).

Multivariate analysis

Out of the 12 TLM series, three series reported systematic intraoperative use of frozen sections, nine series reported intraoperative use of frozen sections when requested, and none of the TLM series were categorized as not reporting intraoperative use of frozen sections. Meanwhile, out of 24 TORS series, three reported systematic intraoperative use of frozen sections, nine reported intraoperative use of frozen sections when requested, and 12 did not report intraoperative use of frozen sections. As expected, frozen section analysis was reported more frequently in the TLM series than in the TORS series ($p=0.0025$). A meta-regression was not feasible on the cumulative number of patients with positive and negative margins depending on the T-classification, the intraoperative use of frozen sections, and on the surgical approach (Figure 3). We performed a two-way independent analysis of variance with a Bonferroni post-hoc tests, using the rates of positive margins per series as a dependent variable (Figure 4). There was no significant difference in the rates of positive margins ($p=1.000$) according to the surgical approach.

The influence of definitive margins on the oncological outcomes

Five series provided data on local control, with 63 patients in the positive margins arm and 664 patients in the negative margins arm, respectively [8, 12, 14, 21, 22]. Four series reported no definitive positive margins [15, 17, 23, 26]. Three series reported no local recurrences [20, 25, 35]. No data on recurrence-free survival, disease-specific survival, or overall survival were available for a pooled analysis. When the data of the five series reporting data on local control were pooled, there was a very small level of heterogeneity among the studies (Q-value; 0.606; $I^2=93.4\%$). The overall pooled effect with an odds ratio of 3.651 [1.691, 7.882] showed that there was a significant difference between the patients with positive margins and the patients with negative margins in terms of local control (Figure 5 and Figure 6).

Three series reported outcomes of patients with close margins, with 48 patients in the close margins arm and 249 patients in the clear margins arm, respectively [8, 37, 39]. Definition of close margins was not provided in one series [8], was two millimeters in one series [39], and five millimeters in one series [37]. When the data of the three series reporting data on local control were pooled, there was a very small level of heterogeneity among the studies (Q-value, 0.646; $I^2=96.9\%$). The overall pooled effect with an odds ratio of 1.768 [6.671, 4.660] showed no difference between the patients with close margins and the patients with clear margins in terms of local control, given the limits of heterogeneity bias, and the influence of postoperative treatment (Figure 7 and Figure 8). The heterogeneity statistic I^2 must be interpreted very cautiously when a meta-analysis has few studies such as this one, given the risk of bias and underestimation [50].

Discussion

Transoral surgery in the oropharynx is a relatively new surgical strategy to access and resect tumors of the oropharynx directly through the mouth. Compared to transcervical approaches, direct access to the tumor helps avoid the morbidity of the open approaches and thus allows for faster recovery of function, of which swallowing is the most important. Although many series have been published on the efficacy of transoral surgery, either as series on TORS, TLM, or CTS, there has been no large-scale analysis to date of the margin status after this type of surgery in the oropharynx to assess its safety. In this systematic review, the overall rate of positive margins using various types of transoral procedures was 7.8% in a population of 3,619 patients. This relatively low rate suggests that transoral procedures are safe in terms of proper tumor resection and should continue to be part of the armamentarium of surgical techniques used in head and neck surgery. We found that positive margins were associated with a reduction in local tumor control while close margins were not. The assessment of frozen sections taken during the transoral procedure was associated with a reduced risk of definitive positive margins, whereas the T4 classification of the primary tumor was associated with an increased risk of definitive positive margins. Neither the primary site (the tonsillar fossa, the base of the tongue), nor the HPV status, were associated with the margin status. Our review also highlights that there is a high level of heterogeneity regarding how margins are defined in the literature. Two-thirds of the included series reported the margins as being either positive or negative. One-third of the included articles reported an analysis of close versus clear margins, and their definition of a close margin was highly variable.

Our finding that a T4 classification was associated with a 2.54 relative risk of positive margins compared to a T1-3 classification is consistent with previous publications that have emphasized the higher risk of inadequate resection in deep connective tissues than in mucosal tissues [3, 51]. In oropharyngeal carcinoma specifically, few studies to date have investigated this issue. Woolgar and Triantafyllou reviewed 301 carcinoma specimens, of which 48 were oropharyngeal cancer (OPSCC), using the guidelines of the UK Royal College of Pathologists [51]. The margins were involved in 18/48 (37.5%) of the OPSCCs, of which 15 (83.3%) were pT3-T4 lesions. The involved margin was mucosal in just a single patient, while they were mucosal and deep soft tissues in three patients, bone and deep soft tissues in one patient, and deep soft tissues only in 13 patients. For 14/48 of the OPSCCs, the margins were clear (29.2%), of which 10 (71.4%) were pT1-T2 lesions. The association of the pT stage with the rate of positive margins was significant. Invasive local extension of oropharyngeal carcinoma into the medial pterygoid muscle or the extrinsic muscles of the tongue can represent a challenge with transoral approaches due to the absence of reliable haptic feedback. The association of TLM with a lower rate of positive

margins than for TCS or TORS in this study may then be explained by a high rate of systematic intraoperative use of frozen sections in TLM, due to the piecemeal resection described in the Steiner's landmark TLM procedure with analysis of successive frozen sections until a clear resection is achieved [15]. On the other hand, "en-bloc" resection of the primary tumor with a cuff of healthy surrounding tissues, as performed in open surgery, is the standard procedure in TCS as well as in TORS, and the final quality of the resection depends on the intraoperative evaluation of the local extensions [7, 27, 52]. However, when comparing margins in series that reported the use of frozen sections irrespective of the procedure, there was no longer a difference in our findings between TLM, TCS, and TORS. The adjusted results confirm that the main methodological factor associated with a reduced risk of definitive positive margins is the intraoperative assessment of the quality of the resection with frozen sections, and not the surgical procedure itself. Close collaboration between the surgeon and the pathologist is hence paramount to ensure that the patient will benefit from the best standard-of-care [6]. Moreover, our review found discrepancies between authors with regards to methods used for margin assessment when using frozen section analysis, notably between specimen-driven or patient-driven margins. This issue has been thoroughly investigated in oral cancer surgery, showing intraoperative frozen margins from the specimen to better predict the risk of local recurrence than frozen margins from the tumor bed [53, 54]. Therefore, specimen-based frozen sections are probably the best method for intraoperative assessment of comprehensiveness of the disease resection, and should be systematically recommended.

It is difficult to adequately evaluate the association of margins with oncological endpoints in transoral surgery for oropharyngeal carcinoma in single-institution series given the small number of events reported as a result of the high rate of HPV-related tumors, which exhibit a lower risk of recurrence at any site [55]. Our meta-analysis findings that the margin status was associated with local control is consistent with results in other head and neck carcinoma localizations [3]. In oropharyngeal carcinoma specifically, few series to date have reported assessment of margins in open surgery. Sessions et al. analyzed 262 patient with carcinoma of the base of the tongue, of whom 177 had a T1-T2 lesion [56]. There were 202 cases that were treated with surgery. The margins were defined as clear (≥ 5 mm) in 54.6% of the patients, close (< 5 mm) in 13%, or positive (microscopically involved) in 32.4%. Close and/or involved margins were associated with an increased risk of local failure. Kwok et al. reviewed data from 417 patients with oral (n=83), oropharyngeal (n=180), or hypopharyngeal (n=154) carcinoma [57]. Failure to achieve clear margins, despite the use of frozen sections, was associated with reduced survival, in the global cohort as well as specifically in the T1-T2 and in the T3-T4 cancer patients. Iyer et al. analyzed 201 OPSCC patients treated surgically with or without adjuvant radiotherapy [58]. The subsites were

the base of the tongue, the tonsillar fossa, and the soft palate, in 44%, 33%, and 23% of the patients. Seventy percent of the patients had a T1-T2 lesion. A close/positive versus a negative margin status was associated with overall survival, disease-specific survival, and recurrence-free survival in p16-negative OPSCC patients. Roux et al. reviewed data from 44 OPSCC patients treated surgically with or without postoperative radiotherapy [59]. Positive margins (27%) were associated with reduced disease-specific survival. To the best of our knowledge, no publication to date has addressed whether there is an association of the margin status with the oncological endpoints in HPV-related OPSCC treated by open surgery. Given the very high rate of HPV-related tumors included in our analysis (78.7%), we can assume that the association of the margin status with local control still holds true in HPV-related OPSCC. An adequate resection of the primary tumor in head and neck cancer is a challenging balance between the physician's attempts at a complete resection and the patient's expectations that local sequelae that can dramatically reduce the quality of life are minimized. The estimated risk of residual tumor associated with adverse features on a definitive pathological examination such as microscopic margins directly influences the indication for adjuvant therapy [4, 60]. However, an association of this risk with close margins in head and neck cancer is difficult to assess in a meta-analysis given the retrospective and heterogeneous data as well as the limited number of publications reporting margins sizes. A high level of caution is warranted since the calculated I^2 meant that more than 90% of the variance was deemed attributable to study heterogeneity. As summarized in a clinical review by Hinni et al., the margin distance should always be measured in millimeters and recorded on the surgical pathology report [3]. We believe that close margins should also be systematically reported in publications along with the threshold used. In an international American Head and Neck Society member survey in 2005, Meier et al. investigated practices in surgical margin determination in head and neck oncology [61]. The most frequent definition of a clear margin was > 5 mm on microscopic examination. This is consistent with the National Comprehensive Cancer Network (NCCN) Guidelines, for which a clear margin is defined as a distance from the invasive tumor front that is 5 mm or more from the resected margin [60]. However, the value of this empirical threshold in oropharynx has yet to be validated given its specific anatomical boundaries and the paucity of publications in this regard. Future results of cooperative trials such as EORTC-1420, PATHOS, or ECOG 3311, will probably help clarify the significance of a "close" margin.

Our study has several limitations that should be kept in mind. First of all, our results were based mainly on retrospective case-series, with a subsequent risk of multiple biases. This issue should be addressed in large and multicentric prospective clinical trials, with published protocols that allow for precise evaluation of the influence

of margins, and with both available per-protocol results and intention-to-treat results. However, the expected heterogeneity of the surgical methods and procedures as well as of the pathological margin assessments between expert centers makes it very difficult to generate a reliable pooled analysis of the influence of close margins on outcomes. Secondly, the validity of our conclusions relies on the quality and the exhaustivity of the reported outcomes. The very high rate of negative margins in our pooled analysis (92.2%) was unexpectedly better than the reported rates of positive margins in comparable situations such as oral carcinoma [62]. This could conceivably be due to the high rate of intraoperative use of frozen sections. However, the most probable reason for this low rate of positive margins is that most of the publications were from expert teams in high-volume facilities such as academic centers. Hanna et al. recently published the results of a national quality study investigating NCDB data from 2,661 patients who underwent TORS in the USA. Thus, this study involved nearly one thousand patients more than the cumulative number of TORS patients from the studies included in our analysis [63]. The overall rate of positive margins was 16.9%, which is considerably higher than the 8.1% cumulative rate that we encountered. They, in fact, confirmed that the risk of a positive margin status was lower in high-volume facilities compared to medium- and low-volume facilities and that it was also lower in academic centers compared to nonacademic ones, leading to a strong publication bias in our study. Finally, masked confounding factors may interact with the performance of an analysis of frozen sections, such as the difference between patient-directed and specimen-directed sampling. Nevertheless, the processing of frozen sections during the surgical procedure to intraoperatively determine the quality of the resection was significantly associated with the final margin status in our study. It is indeed to be expected that definitive margins should be better in a given patient when frozen sections are generated and assessed intraoperatively so that further resection can be performed if needed, irrespective of the methodology used.

Conclusion

In a cumulative total of 3,619 patients who underwent transoral surgery for oropharyngeal carcinoma in published studies, the rate of positive margins was 7.8%. A positive margin status was associated with reduced local control. A close margin was not associated with decreased local control as compared to clear margins. The main factor associated with a lower risk of a positive margin was the use of frozen sections to intraoperatively determine the margin status. The degree of heterogeneity was very high among the various studies, thus calling for a definition of standards for margin status assessment in transoral surgery. Future results of cooperative trials will help clarify the significance of close margins.

Conflict of interest statement

PG is consultant (Proctor) for Intuitive Surgical Inc.

Acknowledgements

The authors are very grateful to Dr. Pierre Blanchard for his advice regarding the statistical analyses, and to Mrs. Sophie Domingues for English editing.

Funding

This research did not receive any specific grant from funding agencies in the public, commercial, or not-for-profit sectors.

References

- [1] Parkin DM, Bray F, Ferlay J, Pisani P. Global cancer statistics, 2002. *CA Cancer J Clin.* 2005;55:74-108.
- [2] Bozec A, Culie D, Poissonnet G, Dassonville O. Current role of primary surgical treatment in patients with head and neck squamous cell carcinoma. *Curr Opin Oncol.* 2019;31:138-45.
- [3] Hinni ML, Ferlito A, Brandwein-Gensler MS, Takes RP, Silver CE, Westra WH, et al. Surgical margins in head and neck cancer: a contemporary review. *Head Neck.* 2013;35:1362-70.
- [4] Bernier J, Cooper JS, Pajak TF, van Glabbeke M, Bourhis J, Forastiere A, et al. Defining risk levels in locally advanced head and neck cancers: a comparative analysis of concurrent postoperative radiation plus chemotherapy trials of the EORTC (#22931) and RTOG (# 9501). *Head Neck.* 2005;27:843-50.
- [5] Ansarin M, Santoro L, Cattaneo A, Massaro MA, Calabrese L, Giugliano G, et al. Laser surgery for early glottic cancer: impact of margin status on local control and organ preservation. *Arch Otolaryngol Head Neck Surg.* 2009;135:385-90.
- [6] Tirelli G, Boscolo Nata F, Piovesana M, Quatela E, Gardenal N, Hayden RE. Transoral surgery (TOS) in oropharyngeal cancer: Different tools, a single mini-invasive philosophy. *Surg Oncol.* 2018;27:643-9.
- [7] Holsinger FC, McWhorter AJ, Menard M, Garcia D, Laccourreye O. Transoral lateral oropharyngectomy for squamous cell carcinoma of the tonsillar region: I. Technique, complications, and functional results. *Arch Otolaryngol Head Neck Surg.* 2005;131:583-91.
- [8] Laccourreye O, Hans S, Menard M, Garcia D, Brasnu D, Holsinger FC. Transoral lateral oropharyngectomy for squamous cell carcinoma of the tonsillar region: II. An analysis of the incidence, related variables, and consequences of local recurrence. *Arch Otolaryngol Head Neck Surg.* 2005;131:592-9.
- [9] Moore EJ, Henstrom DK, Olsen KD, Kasperbauer JL, McGree ME. Transoral resection of tonsillar squamous cell carcinoma. *Laryngoscope.* 2009;119:508-15.
- [10] Henstrom DK, Moore EJ, Olsen KD, Kasperbauer JL, McGree ME. Transoral resection for squamous cell carcinoma of the base of the tongue. *Arch Otolaryngol Head Neck Surg.* 2009;135:1231-8.
- [11] Karatzanis AD, Psychogios G, Waldfahrer F, Zenk J, Velegrakis GA, Iro H. Surgical management of T1 oropharyngeal carcinoma. *Head Neck.* 2012;34:1277-82.
- [12] Psychogios G, Mantsopoulos K, Agaimy A, Koch M, Zenk J, Waldfahrer F, et al. Prognostic factors in limited (T1-2, N0-1) oropharyngeal carcinoma treated with surgery +/- adjuvant therapy. *Head Neck.* 2013;35:1752-8.
- [13] Chauhan P, Byrne H, Taylor E, Sheahan P. Oncological and functional outcomes of transoral surgery for the treatment of oropharyngeal cancer. *Ir J Med Sci.* 2015;184:825-30.
- [14] Molony P, Kharytaniuk N, Boyle S, Woods RSR, O'Leary G, Werner R, et al. Impact of positive margins on outcomes of oropharyngeal squamous cell carcinoma according to p16 status. *Head Neck.* 2017;39:1680-8.
- [15] Steiner W, Fierek O, Ambrosch P, Hommerich CP, Kron M. Transoral laser microsurgery for squamous cell carcinoma of the base of the tongue. *Arch Otolaryngol Head Neck Surg.* 2003;129:36-43.
- [16] Grant DG, Salassa JR, Hinni ML, Pearson BW, Perry WC. Carcinoma of the tongue base treated by transoral laser microsurgery, part two: Persistent, recurrent and second primary tumors. *Laryngoscope.* 2006;116:2156-61.
- [17] Grant DG, Hinni ML, Salassa JR, Perry WC, Hayden RE, Casler JD. Oropharyngeal cancer: a case for single modality treatment with transoral laser microsurgery. *Arch Otolaryngol Head Neck Surg.* 2009;135:1225-30.

- [18] Rich JT, Milov S, Lewis JS, Jr., Thorstad WL, Adkins DR, Haughey BH. Transoral laser microsurgery (TLM) +/- adjuvant therapy for advanced stage oropharyngeal cancer: outcomes and prognostic factors. *Laryngoscope*. 2009;119:1709-19.
- [19] Hinni ML, Zarka MA, Hoxworth JM. Margin mapping in transoral surgery for head and neck cancer. *Laryngoscope*. 2013;123:1190-8.
- [20] Patel SH, Hinni ML, Hayden RE, Wong WW, Dueck AC, Zarka MA, et al. Transoral laser microsurgery followed by radiation therapy for oropharyngeal tumors: the Mayo Clinic Arizona experience. *Head Neck*. 2014;36:220-5.
- [21] Haughey BH, Hinni ML, Salassa JR, Hayden RE, Grant DG, Rich JT, et al. Transoral laser microsurgery as primary treatment for advanced-stage oropharyngeal cancer: a United States multicenter study. *Head Neck*. 2011;33:1683-94.
- [22] Melong JC, Rigby MH, Bullock M, Hart RD, Trites JR, Taylor SM. Transoral laser microsurgery for the treatment of oropharyngeal cancer: the Dalhousie University experience. *J Otolaryngol Head Neck Surg*. 2015;44:39.
- [23] Wilkie MD, Upile NS, Lau AS, Williams SP, Sheard J, Helliwell TR, et al. Transoral laser microsurgery for oropharyngeal squamous cell carcinoma: A paradigm shift in therapeutic approach. *Head Neck*. 2016;38:1263-70.
- [24] Sinha P, Haughey BH, Kallogjeri D, Jackson RS. Long-term analysis of transorally resected p16 + Oropharynx cancer: Outcomes and prognostic factors. *Laryngoscope*. 2018.
- [25] Lee SY, Park YM, Byeon HK, Choi EC, Kim SH. Comparison of oncologic and functional outcomes after transoral robotic lateral oropharyngectomy versus conventional surgery for T1 to T3 tonsillar cancer. *Head Neck*. 2014;36:1138-45.
- [26] Moore EJ, Olsen KD, Kasperbauer JL. Transoral robotic surgery for oropharyngeal squamous cell carcinoma: a prospective study of feasibility and functional outcomes. *Laryngoscope*. 2009;119:2156-64.
- [27] Weinstein GS, O'Malley BW, Jr., Snyder W, Sherman E, Quon H. Transoral robotic surgery: radical tonsillectomy. *Arch Otolaryngol Head Neck Surg*. 2007;133:1220-6.
- [28] Weinstein GS, O'Malley BW, Jr., Cohen MA, Quon H. Transoral robotic surgery for advanced oropharyngeal carcinoma. *Arch Otolaryngol Head Neck Surg*. 2010;136:1079-85.
- [29] Cohen MA, Weinstein GS, O'Malley BW, Jr., Feldman M, Quon H. Transoral robotic surgery and human papillomavirus status: Oncologic results. *Head Neck*. 2011;33:573-80.
- [30] Weinstein GS, Quon H, Newman HJ, Chalian JA, Malloy K, Lin A, et al. Transoral robotic surgery alone for oropharyngeal cancer: an analysis of local control. *Arch Otolaryngol Head Neck Surg*. 2012;138:628-34.
- [31] Moore EJ, Olsen SM, Laborde RR, Garcia JJ, Walsh FJ, Price DL, et al. Long-term functional and oncologic results of transoral robotic surgery for oropharyngeal squamous cell carcinoma. *Mayo Clin Proc*. 2012;87:219-25.
- [32] Dziegielewski PT, Teknos TN, Durmus K, Old M, Agrawal A, Kakarala K, et al. Transoral robotic surgery for oropharyngeal cancer: long-term quality of life and functional outcomes. *JAMA Otolaryngol Head Neck Surg*. 2013;139:1099-108.
- [33] Quon H, Cohen MA, Montone KT, Ziober AF, Wang LP, Weinstein GS, et al. Transoral robotic surgery and adjuvant therapy for oropharyngeal carcinomas and the influence of p16 INK4a on treatment outcomes. *Laryngoscope*. 2013;123:635-40.
- [34] Ford SE, Brandwein-Gensler M, Carroll WR, Rosenthal EL, Magnuson JS. Transoral robotic versus open surgical approaches to oropharyngeal squamous cell carcinoma by human papillomavirus status. *Otolaryngol Head Neck Surg*. 2014;151:606-11.
- [35] van Loon JW, Smeele LE, Hilgers FJ, van den Brekel MW. Outcome of transoral robotic surgery for stage I-II oropharyngeal cancer. *Eur Arch Otorhinolaryngol*. 2015;272:175-83.
- [36] Dabas S, Dewan A, Ranjan R, Dewan AK, Puri A, Shah SH, et al. Transoral robotic surgery in management of oropharyngeal cancers: a preliminary experience at a tertiary cancer centre in India. *Int J Clin Oncol*. 2015;20:693-700.

- [37] Lorincz BB, Mockelmann N, Busch CJ, Knecht R. Functional outcomes, feasibility, and safety of resection of transoral robotic surgery: single-institution series of 35 consecutive cases of transoral robotic surgery for oropharyngeal squamous cell carcinoma. *Head Neck*. 2015;37:1618-24.
- [38] Choby GW, Kim J, Ling DC, Abberbock S, Mandal R, Kim S, et al. Transoral robotic surgery alone for oropharyngeal cancer: quality-of-life outcomes. *JAMA Otolaryngol Head Neck Surg*. 2015;141:499-504.
- [39] Kaczmar JM, Tan KS, Heitjan DF, Lin A, Ahn PH, Newman JG, et al. HPV-related oropharyngeal cancer: Risk factors for treatment failure in patients managed with primary transoral robotic surgery. *Head Neck*. 2016;38:59-65.
- [40] Ling DC, Chapman BV, Kim J, Choby GW, Kabolizadeh P, Clump DA, et al. Oncologic outcomes and patient-reported quality of life in patients with oropharyngeal squamous cell carcinoma treated with definitive transoral robotic surgery versus definitive chemoradiation. *Oral Oncol*. 2016;61:41-6.
- [41] Gildener-Leapman N, Kim J, Abberbock S, Choby GW, Mandal R, Duvvuri U, et al. Utility of up-front transoral robotic surgery in tailoring adjuvant therapy. *Head Neck*. 2016;38:1201-7.
- [42] Achim V, Bolognone RK, Palmer AD, Graville DJ, Light TJ, Li R, et al. Long-term Functional and Quality-of-Life Outcomes After Transoral Robotic Surgery in Patients With Oropharyngeal Cancer. *JAMA Otolaryngol Head Neck Surg*. 2017.
- [43] Park YM, Kim HR, Cho BC, Keum KC, Cho NH, Kim SH. Transoral robotic surgery-based therapy in patients with stage III-IV oropharyngeal squamous cell carcinoma. *Oral Oncol*. 2017;75:16-21.
- [44] Albergotti WG, Gooding WE, Kubik MW, Geltzeiler M, Kim S, Duvvuri U, et al. Assessment of Surgical Learning Curves in Transoral Robotic Surgery for Squamous Cell Carcinoma of the Oropharynx. *JAMA Otolaryngol Head Neck Surg*. 2017;143:542-8.
- [45] Rubek N, Channir HI, Charabi BW, Lajer CB, Kiss K, Nielsen HU, et al. Primary transoral robotic surgery with concurrent neck dissection for early stage oropharyngeal squamous cell carcinoma implemented at a Danish head and neck cancer center: a phase II trial on feasibility and tumour margin status. *Eur Arch Otorhinolaryngol*. 2017;274:2229-37.
- [46] Morisod B, Venara V, II, Alzuphar S, Monnier Y, Bongiovanni M, Hagmann P, et al. Minimizing adjuvant treatment after transoral robotic surgery through surgical margin revision and exclusion of radiographic extracapsular extension: A Prospective observational cohort study. *Head Neck*. 2017;39:965-73.
- [47] Sethia R, Yumusakhuylu AC, Ozbay I, Diavolitsis V, Brown NV, Zhao S, et al. Quality of life outcomes of transoral robotic surgery with or without adjuvant therapy for oropharyngeal cancer. *Laryngoscope*. 2018;128:403-11.
- [48] Persky MJ, Albergotti WG, Rath TJ, Kubik MW, Abberbock S, Geltzeiler M, et al. Positive Margins by Oropharyngeal Subsite in Transoral Robotic Surgery for T1/T2 Squamous Cell Carcinoma. *Otolaryngol Head Neck Surg*. 2018;158:660-6.
- [49] Moore EJ, Van Abel KM, Price DL, Lohse CM, Olsen KD, Jackson RS, et al. Transoral robotic surgery for oropharyngeal carcinoma: Surgical margins and oncologic outcomes. *Head Neck*. 2018;40:747-55.
- [50] von Hippel PT. The heterogeneity statistic I(2) can be biased in small meta-analyses. *BMC Med Res Methodol*. 2015;15:35.
- [51] Woolgar JA, Triantafyllou A. A histopathological appraisal of surgical margins in oral and oropharyngeal cancer resection specimens. *Oral Oncol*. 2005;41:1034-43.
- [52] O'Malley BW, Jr., Weinstein GS, Snyder W, Hockstein NG. Transoral robotic surgery (TORS) for base of tongue neoplasms. *Laryngoscope*. 2006;116:1465-72.
- [53] Buchakjian MR, Tasche KK, Robinson RA, Pagedar NA, Sperry SM. Association of Main Specimen and Tumor Bed Margin Status With Local Recurrence and Survival in Oral Cancer Surgery. *JAMA Otolaryngol Head Neck Surg*. 2016;142:1191-8.
- [54] Kain JJ, Birkeland AC, Udayakumar N, Morlandt AB, Stevens TM, Carroll WR, et al. Surgical margins in oral cavity squamous cell carcinoma: Current practices and future directions. *Laryngoscope*. 2019.

- [55] Rasmussen JH, Gronhoj C, Hakansson K, Friberg J, Andersen E, Lelkaitis G, et al. Risk profiling based on p16 and HPV DNA more accurately predicts location of disease relapse in patients with oropharyngeal squamous cell carcinoma. *Ann Oncol*. 2019.
- [56] Sessions DG, Lenox J, Spector GJ, Chao C, Chaudry OA. Analysis of treatment results for base of tongue cancer. *Laryngoscope*. 2003;113:1252-61.
- [57] Kwok P, Gleich O, Hubner G, Strutz J. Prognostic importance of "clear versus revised margins" in oral and pharyngeal cancer. *Head Neck*. 2010;32:1479-84.
- [58] Iyer NG, Dogan S, Palmer F, Rahmati R, Nixon IJ, Lee N, et al. Detailed Analysis of Clinicopathologic Factors Demonstrate Distinct Difference in Outcome and Prognostic Factors Between Surgically Treated HPV-Positive and Negative Oropharyngeal Cancer. *Ann Surg Oncol*. 2015;22:4411-21.
- [59] Roux M, Dassonville O, Ettaiche M, Poissonnet G, Sudaka A, Bozec A. Transoral-transcervical oropharyngectomy without mandibulotomy, associated to fasciocutaneous radial forearm free-flap reconstruction, for oropharyngeal cancer: Postoperative course, oncologic and functional results, and prognostic factors. *Eur Ann Otorhinolaryngol Head Neck Dis*. 2017;134:71-6.
- [60] Colevas AD, Yom SS, Pfister DG, Spencer S, Adelstein D, Adkins D, et al. NCCN Guidelines Insights: Head and Neck Cancers, Version 1.2018. *J Natl Compr Canc Netw*. 2018;16:479-90.
- [61] Meier JD, Oliver DA, Varvares MA. Surgical margin determination in head and neck oncology: current clinical practice. The results of an International American Head and Neck Society Member Survey. *Head Neck*. 2005;27:952-8.
- [62] Smits RW, Koljenovic S, Hardillo JA, Ten Hove I, Meeuwis CA, Sewnaik A, et al. Resection margins in oral cancer surgery: Room for improvement. *Head Neck*. 2016;38 Suppl 1:E2197-203.
- [63] Hanna J, Morse E, Brauer PR, Judson B, Mehra S. Positive margin rates and predictors in transoral robotic surgery after federal approval: A national quality study. *Head Neck*. 2019.

Table 1. Characteristics of studies included in the systematic review.

Reference	No. of patients	Oropharyngeal subsites				T classification				Frozen sections	Surgical procedure	Margins (No. of patients)			
		T F	BO T	S P	P W	T 1	T 2	T 3	T 4			Positive	Close	CLEAR	Negative
LACCOURREY 2005	166	166				60	87	19		NR	TCS	13	8	142	150
MOORE 2009	102	102				50	36	16		SYS	TCS	3	-	-	99
HENSTROM 2009	20		20			8	8	1	3	SYS	TCS	2	-	-	18
KARATZANIS 2011	223	87	34	83	19	223				-	TCS (66) or TLM (21)	18	-	-	205
PSYCHOGIOS 2013	266	100	45	94	27	139	127			NR	TCS (200) or TLM (66)	11	-	-	255
CHAUHAN 2014	12	9	1	1	1	8	4			NR	TCS or TLM (not specified)	1	3	8	11
MOLONY 2017	55	40	8	7		36	16	3		NR	TCS (51) or TLM (4)	21	28	6	34
STEINER 2003	48		48			1	12	7	28	SYS	TLM	0	-	-	48
GRANT 2006	59		36			16	23	12	8	OD	TLM	2	-	-	57
GRANT 2009	69	28	29*	4	8	25	30	12	2	SYS	TLM	0	-	-	69
RICH 2009	84	38*	46			29	33	15	7	OD	TLM	5	-	-	79
HINNI 2013	128	128								OD	TLM	2	-	-	126
PATEL 2014	80	35	45			42	31			SYS	TLM	8	6	66	72
HAUGHEY 2011	204	98	106			61	74	45	24	OD	TLM	14	-	-	190
MELONG 2015	39	19	20			9	23	27		OD	TLM	4	1	34	35
WILKIE 2016	153	96	38	21		42	74	37		OD	TLM	0	-	-	153
SINHA 2018	171					62	53	32	24	OD	TLM	14	-	-	157

WEINSTEIN 2007	27	27				5	16	6		OD	TORS	0	Questionnaire in 7.4%		25
MOORE 2009	45	19	26			15	18	3	9	OD	TORS	0	-	-	45
WEINSTEIN 2010	47	23	23	1		13	23	9	2	OD	TORS	1	-	-	46
COHEN 2011	50	23	24	2	1	15	24	8	3	NR	TORS	1	2	47	49
WEINSTEIN 2012	30	14	12*	3	1	9	16	4	1	OD	TORS	1	-	-	29
MOORE 2012	66	40	26			30	26	3	3	SYS	TORS	2	-	-	64
DZIEGIELE WSKI 2013	81	65	16			34	39	6	2	SYS	TORS	8	-	-	73
QUON 2013	48					14	23	8	3	NR	TORS	1	-	-	47
LEE 2014	43	43				16	21	6		NR	TCS (16) or TORS (27)	3	-	-	40
FORD 2014	65	38	51		6	21	36	6	2	NR	TORS	10	8	47	55
VANLOON 2014	18	9	6	2	1	8	10			NR	TORS	4	2	12	14
DABAS 2014	60	24	30*	6		21	31	4		OD	TORS	2	2	56	58
LORINCZ 2015	35	13	19*	3		19	15	1		SYS	TORS	2	14	19	33
CHOBY 2015	34	16	15	2	1	20	13	1		NR	TORS	1	-	-	33
KACZMAR 2015	114	6	43					6	4	NR	TORS	26		88	
LING 2016	92	38	47	1	2	53	35			NR	TORS	14	15	63	78
GILDENER 2016	76	35	36			34	25	2	1	NR	TORS	7	-	-	63
ACHIM 2017	74	42	31			43	30			NR	TORS	17	-	-	57
PARK 2017	80	66	13	1		21	30	1/5	1/4	NR	TORS	14	-	-	66
ALBERGOTTI 2017	160	54	58			63	77	1/7	1	NR	TORS	22	-	-	138
RUBEK 2017	30	21	7		2	13	17			OD	TORS	1		29	
MORISOD 2017	29	29	15	1/2	2	29				OD	TORS	4	7	18	25
SETHIA 2018	111	79	19			43	60	5	2	NR	TORS	3	-	-	108
PERSKY 2018	140	89	51			64	76			OD	TORS	14	-	-	126
MOORE 2018	314	204	0			130	143	23	14	OD	TORS	7	-	-	306

TF, tonsillar fossa; BOT, base of the tongue; SP, soft palate; PW, pharyngeal wall; CTS, conventional transoral surgery; TLM, transoral laser microsurgery; TORS, transoral robotic surgery.

- *LORINCZ 2015: five cases of tonsillolingual sulcus included as base of the tongue*

- *DABAS 2014: ten cases of greater tubercle sulcus and two cases of vallecule included as base of the tongue*
- *RICH 2009: "tonsil and soft palate"*
- *WEINSTEIN 2012: three cases of glossotonsillar sulcus included as base of the tongue*

Figure 1. PRISMA 2009 Flow diagram.

Figure 2. The criteria included in the univariate analysis for a reported risk of positive microscopic margins in transoral surgery for oropharyngeal carcinoma.

Figure 3. The rates of positive margins among the cumulative total number of patients who underwent transoral surgery for oropharyngeal carcinoma, depending on the surgical approach used and on the reported intraoperative use of frozen sections. (TCS, transoral conventional surgery; TLM, transoral laser microsurgery; TORS, transoral robotic surgery).

Figure 4. The rates of reported positive margins according to the surgical approach, in series of transoral surgery for oropharyngeal carcinoma.

Figure 5. Forest plot of the comparison between positive margins and negative margins in series of transoral surgery for oropharyngeal carcinoma with respect to local control.

Figure 6. Publication bias in comparison between positive and negative margins in series of transoral surgery for oropharyngeal carcinoma with respect to local control. Funnel plot of standard error by log odds ratio.

Figure 7. Forest plot of the comparison between close margins and clear margins in series of transoral surgery for oropharyngeal carcinoma with respect to local control.

Figure 8. Publication bias in comparison between close and clear margins in series of transoral surgery for oropharyngeal carcinoma with respect to local control. Funnel plot of standard error by log odds ratio.

Identification

Records identified through database searching
(n = 956)

Additional records identified through other sources
(n = 18)

Screening

Records after duplicates removed
(n = 963)

Records screened
(n = 963)

Records excluded
(n = 915)

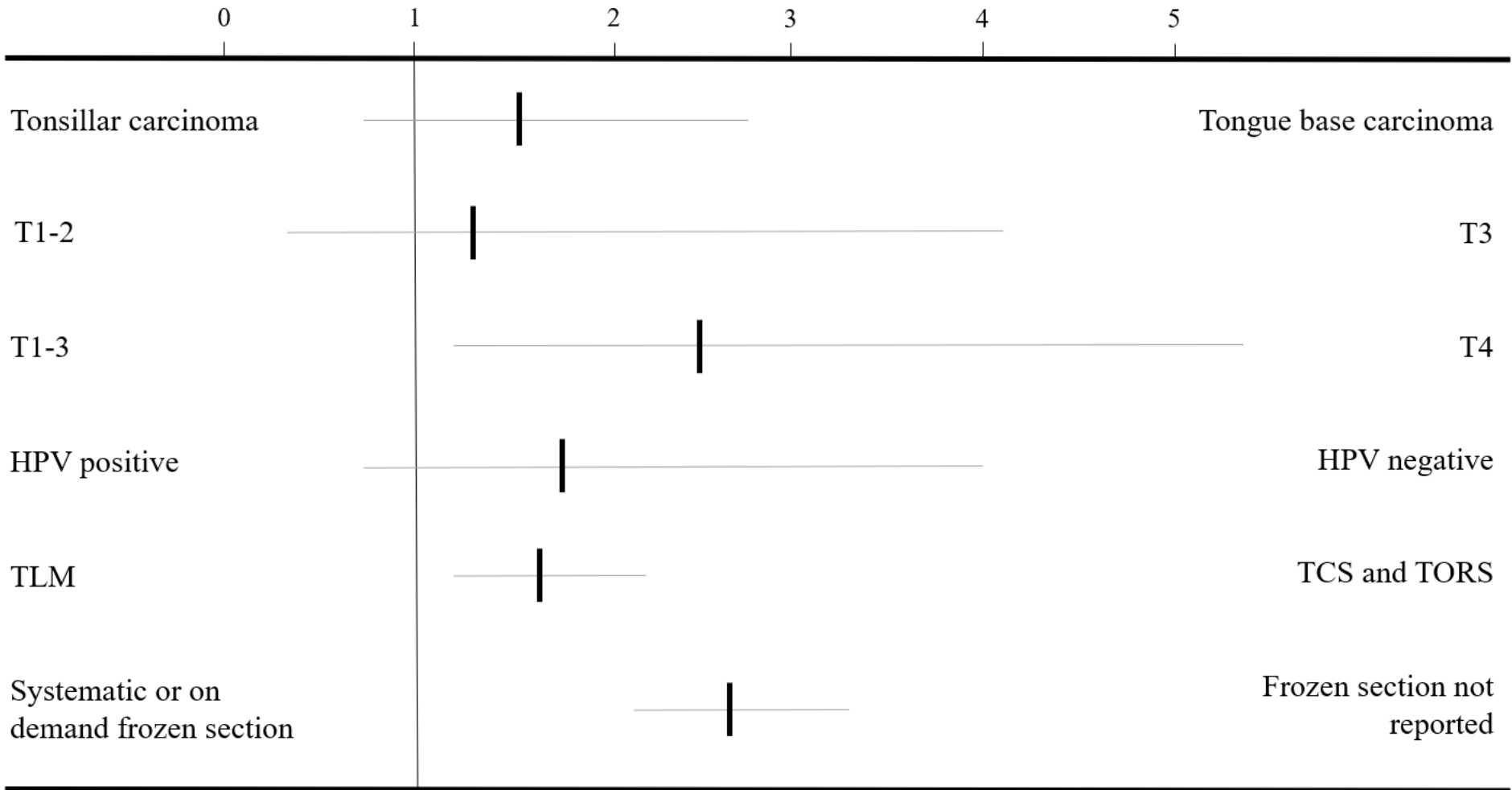
Eligibility

Full-text articles assessed for eligibility
(n = 49)

Full-text articles excluded
(n = 7)

Included

Studies included in qualitative synthesis
(n = 42)



decreased



Relative risk (and 95% CI) of positive margins

increased



