



HAL
open science

Punctal and canalicular plugs: Indications, efficacy and safety

A.-L. Best, M. Labetoulle, M. Legrand, M. M'garrech, E. Barreau, A. Rousseau

► To cite this version:

A.-L. Best, M. Labetoulle, M. Legrand, M. M'garrech, E. Barreau, et al.. Punctal and canalicular plugs: Indications, efficacy and safety. *Journal Français d'Ophtalmologie*, 2019, 42, pp.e95 - e104. <10.1016/j.jfo.2018.12.003>. <hal-03486935>

HAL Id: hal-03486935

<https://hal.science/hal-03486935v1>

Submitted on 20 Dec 2021

HAL is a multi-disciplinary open access archive for the deposit and dissemination of scientific research documents, whether they are published or not. The documents may come from teaching and research institutions in France or abroad, or from public or private research centers.

L'archive ouverte pluridisciplinaire HAL, est destinée au dépôt et à la diffusion de documents scientifiques de niveau recherche, publiés ou non, émanant des établissements d'enseignement et de recherche français ou étrangers, des laboratoires publics ou privés.



Distributed under a Creative Commons CC BY-NC 4.0 - Attribution - Non-commercial use - International License

Punctal and canalicular plugs: indications, efficacy and safety

Anne-Laurence Best¹, Marc Labetoulle^{1,2}, Marine Legrand¹, Mohamed M'garrech¹,
Emmanuel Barreau¹, Antoine Rousseau^{1,2*}

¹ Ophthalmology Service, Hôpital Bicêtre, Assistance Publique – Hôpitaux de Paris, Université Paris-Sud, Division of Vision and Disabilities, OPHTARA rare eye disease referral center, 78 rue du Général Leclerc, 94275 Le Kremlin-Bicêtre Cedex, France

² Viral and autoimmune disease immunology (IMVA / Infrastructure IDMIT) UMR 1184, CEA, Fontenay-aux-Roses, France.

***Correspondence:**

Antoine ROUSSEAU

Service d'ophtalmologie, Hôpital de Bicêtre, Assistance Publique – Hôpitaux de Paris, Université Paris-Sud, France, 78 rue du Général Leclerc, 94275 Le Kremlin-Bicêtre Cedex, France

Telephone: 33 1 45 21 27 99

Fax: 33 1 45 21 22 46

E-mail: antoine.rousseau@aphp.fr

Short title: punctal and canalicular plugs

Abstract

Lacrimal occlusion with punctal or canalicular plugs have been used to treat dry eye disease for more than 40 years. Indeed, punctal plugs constitute a safe and effective tool to retain the natural tear film and prolong the effect of tear substitutes. A wide variety of plugs is available, differing in their design, location (punctal versus canalicular) and their resorbability. Their indications have increasingly broadened, and they are now one of the treatment options for numerous ocular surface diseases. Current research focuses on using punctal plugs for extended delivery of drugs to the ocular surface. This review addresses physiology of lacrimal drainage, available models of punctal plugs, their indications, practical details of prescribing and placing punctal and canalicular plugs, and possible complications.

Keywords

Punctal plug, intracanalicular plug, dry eye, lacrimal apparatus, canaliculitis.

Introduction

The principle of lacrimal occlusion is based on obstruction of the lacrimal drainage so as to retain tears on the ocular surface. Occlusion, originally performed surgically, by suture and then by punctal cautery [1], has been largely replaced by silicone punctal plugs, introduced by Freeman in the 1970's, and their efficacy for treatment of signs and symptoms of dry eye were quickly demonstrated [2].

Moderate to severe aqueous deficiency dry eye is the primary indication for punctal plugs. They allow for improvement of the clinical signs and status of the ocular surface while decreasing the use of tear substitutes, which they complement in poorly controlled patients. They can also be combined with other topical treatments for the ocular surface, such as cyclosporine or autologous serum eyedrops [3].

The development of new biocompatible followed by absorbable materials has considerably improved the tolerability of these devices. They can be placed easily, most often with disposal systems, in a few moments at the time of an exam. These improvements have broadened the indications to include numerous ocular surface diseases [4], for which they constitute one of the important aspects of management. In this review, we first touch on the anatomy and physiology of the upper lacrimal pathways, then the characteristics of available punctal and canalicular plugs, their indications, practical methods of use and finally their possible complications.

Anatomy and physiology of the upper lacrimal pathways

Anatomy of the upper lacrimal pathways

Lacrimal puncta

The superior and inferior lacrimal puncta are narrow orifices (0.25 to 0.3 mm) which constitute the point of entry into the lacrimal canaliculi. They are situated in the medial portion of the upper and lower lid margins in the lash line. They are found at

the tip of triangular excrescences known as the lacrimal papillae and are permanently open due to the fibroelastic ring which surrounds them. They are oriented posteriorly, in contact with the bulbar conjunctiva and the tear lake [5]. In the resting position with the eyes open, the superior and inferior lacrimal puncta are situated 6 and 6.5 mm respectively from the medial canthus. On lid closure, the two puncta touch each other through the action of the muscle of Duverney-Horner, which tips them back toward the tear meniscus [6, 7] (**Figure 1**).

Lacrimal canaliculi

These begin at the lacrimal punctum and run for about 1 cm within the superior and inferior lid margin, uniting to form the common canaliculus. Each canaliculus is composed of a short vertical portion (1 to 2 mm), beginning as a narrow funnel (or infundibulum), the tip of which measures 0.1 mm in diameter. The next segment is horizontal. It measures 6 mm in length for the superior canaliculus and 7 to 10 mm for the inferior canaliculus, with a diameter of 0.3 to 0.5 mm [5, 7]. The canaliculi run through the lid margin within the muscle of Duverney-Horner, then exit the muscle posteriorly toward the posterior lacrimal crest, thus running between the muscle of Duverney-Horner posteriorly and the medial canthal tendon anteriorly. Finally, they meet at a 25° angle to form the common canaliculus (**Figure 1**).

Physiology of lacrimal drainage

Drainage of tears through the lacrimal drainage system constitutes by far the predominant mechanism of evacuation of tears from the ocular surface. Its efficacy depends on the anatomic configuration, the lacrimal drainage system, the role in the pumping mechanism played by contraction of the orbicularis muscle upon blinking, physical phenomena such as the Venturi effect, capillary action, and respiration [8-

10]. Evaporation by itself represents approximately 10 % of the elimination of tears in young patients and 20 % in the elderly [5].

The lacrimal puncta are kept empty by the canalicular pump, which aspirates tears through negative pressure as well as capillary action from the tear lake (Krehbiel's phenomenon). Gravity and the Venturi effect (through circulation of air in the nasal cavities) also play a role in the flow of tears through this pathway [11]. Upon blinking, the superior and inferior puncta touch, thus preventing any reflux and allowing the lacrimal pump in the palpebral canaliculi to function. The canaliculi are thus emptied, by contraction of the muscle of Duverney-Horner which surrounds them, into the lacrimal sac, which is then emptied by contraction of the orbicularis muscle into the nasolacrimal duct. The tears are not resorbed in the canaliculi. Upon opening of the lids, the puncta are no longer in contact; they resume their shape, creating a transient negative pressure. The concomitant relaxation of the orbicularis and the muscle of Duverney-Horner leads to a decompression of the canaliculi and thus a negative pressure. The valve of Rosenmüller situated between the common canaliculus and the lacrimal sac plays an anti-reflux role [12].

The respective roles of the inferior and superior canaliculi in lacrimal drainage remains controversial. Some authors claim that the flow is equal between the two canaliculi (lacrimal scintigraphy has not demonstrated a significant difference in flow between the two canaliculi [13]), while Murgratroyd et al., using a measurement of residual tear volume after instillation of normal saline and alternate occlusion of the superior and inferior puncta, found a slight predominance of evacuation by the inferior canaliculus, on the order of 60 % [14]. Finally, Chen et al. found no difference in efficacy between occlusion of the superior and inferior canaliculi in dry eye patients [15].

The various lacrimal plugs

Punctal plugs

Punctal plugs allow complete occlusion of the lacrimal punctum. They are visible at the slit lamp and easily removable. They carry a low risk of migration into the lacrimal passageways but a high risk of loss by extrusion (see complications). Various designs of punctal plugs have been developed to increase their efficacy and decrease their complications [16]. They are typically composed of a collarette, a neck and a head (**Figure 2A**). The collarette facilitates removal when necessary. All currently available punctal plugs are made of biocompatible silicone. The collarette can form a reservoir to increase retention of tears and/or be inclined to improve plug stability. There are one-size-fits-all punctal plugs, while other models are available in different sizes to better adapt to the morphology of the punctum (**figure 3**). Certain plugs are stretched over a guide wire to enable their placement without prior dilation (**figure 3**). Studies on whether to first occlude the inferior or superior punctum have not allowed a conclusion on which to do in particular [17]. Nonetheless, the inferior punctum is traditionally occluded first.

Canalicular plugs

Canalicular plugs are small cylinders placed in the canaliculus. Depending on the model, they may obstruct the vertical or horizontal segment of the canaliculus (**Figures 2 B and C**). To obtain complete occlusion, the materials make use of properties of hydration or thermal sensitivity, which leads to their expansion within the canaliculus. There are no studies directly comparing vertical to horizontal canalicular plugs, but their efficacy appears to be comparable in terms of symptom reduction in the treatment of dry eye, improvement in break-up time, comfort, and sparing of tear

substitutes [18]. In addition, these new materials theoretically limit the rate of bacterial adhesion and thus infection risk. Canalicular plugs may be permanent or absorbable. Among the latter, there are fast-absorbing plugs (4 to 14 days, made of collagen) and slow-absorbing plugs (2 to 6 months), which may be composed of various materials such as glycolic acid or polydioxanone (**Figure 4**).

The main disadvantages of canalicular plugs are i) difficulty seeing them and evaluating their positioning (in this regard, only the *Herrick plug*, a permanent canalicular plug in the shape of a golf tee, happens to be radiopaque); ii) complexity of removing them; and iii) a higher rate of canaliculitis.

Indications

Aqueous-deficient dry eye

Punctal plugs are a validated treatment option in the management of moderate to severe aqueous-deficient dry eye, and more generally for ocular surface diseases which may benefit from tear retention [16]. The first studies performed in this context quickly demonstrated the ability of punctal plugs to decrease tear film osmolarity [2]. A recent review of the literature concluded that use of punctal plugs improves symptoms and the status of the ocular surface and decreases use of tear substitutes in dry eye patients unrelieved by artificial tears [18]. However, in the meta-analysis published by Ervin *et al.*, heterogeneity in the methodologies used in clinical studies prohibited robust scientific conclusions [19].

Meibomian gland dysfunction

The use of punctal plugs in Meibomian gland dysfunction (MGD) is contested. However, the number of publications on the subject is very limited. Goto *et al.* analyzed the homogeneity of spreading of the tear film and the thickness of the lipid

layer in 17 patients with aqueous-deficient dry eye, of which 12 also had MGD (without major lid inflammation) before and after placement of punctal plugs [20]. With or without MGD, plugs resulted in a more homogeneous spreading of the tear film and an increase in lipid layer thickness. The authors concluded that homeostasis of the lipid layer is dependent upon the aqueous phase. These results suggest the potential usefulness of punctal plugs in MGD without major inflammation, especially when there is associated aqueous deficiency. If concomitant lid hygiene is prescribed, it must be explained to the patient to be gentle with the medial canthal area so as not to dislodge the plugs.

Dry eye associated with immune diseases involving the ocular surface

Punctal occlusion is a very useful adjuvant therapy for immune diseases with ocular surface involvement. The efficacy of punctal plugs has been demonstrated for dry eye associated with Goujerot-Sjögren syndrome [21, 22] (**Figure 5**). Their use is recommended for ocular involvement in graft vs. host disease (GVH), even though no study on this specific topic has been performed [23]. In both of these contexts, particularly in GVH disease, punctal occlusion is only one aspect of the often complex management of these very severe cases of dry eye. Thus, punctal plugs are often combined with other treatments such as autologous serum eye drops, immunomodulatory eye drops (cyclosporine, tacrolimus), and even scleral contact lenses [23-25], and are not placed until surface inflammation is reduced. In the context of GVH, the puncta must be carefully inspected, since spontaneous occlusion can occur in nearly 1 % of cases [26].

Punctal occlusion also has a place in the management of fibrosing conjunctivitis associated with skin diseases (Lyell or Stevens-Johnson syndromes) [27], or ocular

cicatricial pemphigoid. Again, the severity of these diseases requires a combination of therapeutic approaches [28].

Superior limbic keratoconjunctivitis

Tear deficiency or at least poor ocular surface lubrication may play a role in the pathophysiology of this multifactorial condition which is difficult to manage [29]. On this subject, Yang et al. were the first to demonstrate efficacy of punctal occlusion (by either cautery or suture depending on the case) in patients refractory to tear substitutes [30]. Out of a series of 11 patients, they found not only an improvement in conjunctival and corneal staining, but also a decrease in superior limbal conjunctival squamous metaplasia on conjunctival impression cytology. In a large study including various ocular surface diseases, Tai et al. reported encouraging results in the few patients with superior limbic keratoconjunctivitis (SLK) treated with silicone punctal plugs [31]. In addition, punctal occlusion can be used in forms of SLK associated with GVH, almost systematically associated with a major aqueous deficiency [32].

Although the role of punctal occlusion in this disease is not clearly defined, it may constitute a non-invasive option to be considered prior to other more serious treatments (such as topical immunosuppressants or conjunctival resection).

Neurotrophic keratitis and delayed epithelial healing

Punctal occlusion may be beneficial along with other therapeutic measures in the context of treatment of neurotrophic keratitis and delayed epithelial healing. These pathologies are most often associated with decreased tearing (due to a disruption in the feedback loop for reflex tearing) [33]. Again, it would seem logical to place

punctal plugs after controlling ocular surface inflammation with immunomodulatory eye drops (steroids and/or topical cyclosporine).

Recurrent corneal erosion syndrome

Punctal occlusion may be of benefit in this context if recurrent corneal erosion syndrome is associated with an aqueous deficiency.

Punctal plugs and refractive surgery

Punctal plugs may be used for prevention of post-refractive surgery dry eye, especially in patients whose preoperative work-up shows an aqueous tear deficiency [34]. Postoperatively, they may be combined with other dry eye treatments, to get over the hump of this incapacitating but fortunately transient dry eye in the majority of patients [35]. In this context, punctal plugs increase goblet cell density and improve optical aberrations caused by tear film instability, one of the causes of patient dissatisfaction [36]. Absorbable canalicular plugs appear to be rather practical in this context.

Punctal plugs for contact lens use

Punctal plugs may improve comfort in contact lens wearers with symptomatic dry eye [37]. However, one must not forget that severe dry eye is a contraindication to conventional contact lens wear.

Punctal plugs to increase the effect or tolerability of topical medications

By decreasing tear clearance, punctal occlusion increases the time of contact and potentially the effect of an active topical medication. In ocular surface disease, this is the case for tear substitutes (punctal plugs allow for a decrease in the number instilled) or topical anti-inflammatories (although no robust published study has

compared the effect of adding punctal plugs on the efficacy of cyclosporine or steroids). In glaucoma patients on a prostaglandin analogs, a recently published controlled study showed that punctal occlusion with silicone plugs resulted, on the one hand, in improved intraocular pressure control (modest but statistically significant). On the other hand, the authors observed an improvement in the status of the ocular surface (Oxford score, tear film break-up time, tear osmolarity, OSDI score) in patients in the group treated by punctal occlusion [38]. While the sub-group analysis performed in this study did not find a difference between preserved and unpreserved prostaglandin drops, common sense would seem to suggest that, over the long term in polymedicated patients, preservatives in prolonged contact with the ocular surface might have a deleterious effect [39].

Punctal plugs to limit systemic effects of ocular medications

This use appears very intuitive to limit systemic absorption of certain drops, such as beta-blockers, similarly to digital compression of the lacrimal puncta. However, in the only available publication on the subject, on a limited number of patients, Bartlett et al. found no significant difference in blood pressure or heart rate in patients treated with timolol drops with or without punctal plugs [40]. These unfortunately insufficient data do not allow this practice to be recommended [41].

Drug eluting punctal plugs

The idea of combining punctal plugs with the delivery of pharmacologically active substances to the ocular surface seems very logical. From this perspective, several teams have developed models of punctal plugs able to progressively release cyclosporine. Gupta et al. have introduced a punctal plug consisting of a silicone cylinder containing a matrix of hydroxymethylacrylate saturated with cyclosporine

microparticles. According to experimental pharmacologic models, this device was able to deliver a quantity of drug equivalent to that obtained by instillation of eye drops for 3 months [42]. More recently, Xie et al. reported encouraging results obtained experimentally with resorbable hydrogel canalicular plugs saturated with cyclosporine microparticles [43]. As of now, no clinical data has confirmed efficacy and tolerability of these devices.

This principle of extended release from punctal plugs has been approached in the area of glaucoma where compliance may pose a problem. Phase 2 studies are in progress with punctal plugs of extended release travoprost or latanoprost [44]. Preliminary results, available for the travoprost implant, appear promising [45].

Contraindications

Punctal and canalicular plugs are contraindicated in patients with an allergy to the plug material, an obstruction of the lacrimal pathways, an ectropion or an active ocular infection (conjunctivitis, keratitis). Severe ocular surface and lid inflammation such as blepharitis must be treated prior to placing punctal plugs [16].

Prescription and placement

The clinical evaluation of the patient and his or her history may suggest the indication for placement of punctal plugs. Several factors must be specified for the choice of plugs:

1. The number of lacrimal puncta/canaliculi to be occluded.
2. The desired duration of action of the plug: temporary (3 months or 6 months) or permanent.
3. The location of the plug: punctal or canalicular (vertical or horizontal).
4. The size of the plug.

Of course, the patient must be informed of possible complications, and contraindications must be ruled out. Typically, the inferior lacrimal pathways are occluded first, since access is easier and the extrusion rate is lower, and this is often sufficient to decrease symptoms and use of tear substitutes. The method of insertion depends on the type of plug chosen (with or without prior dilation). Local anesthesia is desirable to improve the patient's comfort. Placement of canalicular plugs in the horizontal segment does not require prior dilation. A quick check of the position of the punctal plugs at the slit lamp verifies good positioning of the collarette. Prior to placement of the punctal plugs, anti-inflammatory treatment (steroid or cyclosporine drops) is given if there is any clinically obvious or even suspected ocular surface inflammation. However, it is not always possible to achieve optimal control of the inflammation in the setting of certain severe ocular surface diseases [4].

Complications of punctal plugs

Loss and partial extrusion

By far, the most common complication of punctal plugs is loss, with a rate between 30 and 50 % in the first few months [46, 47]. The risk is higher for superior punctal plugs [48]. It may be decreased by choosing a larger size punctal plug. Partial extrusion may result in conjunctival irritation or even keratitis (**Figure 6**). In the case of recurrent loss, canalicular plugs may be an option. In certain countries, punctal cautery or suture are also suggested in this situation, but this procedure is not well accepted in others [49, 50].

Toxic tear syndrome

It is commonly accepted that placement of punctal plugs on an inflamed ocular surface creates a risk of stagnation of tears rich in cytokines and inflammatory

mediators. This can result in inefficacy of punctal occlusion or even aggravation of the condition, known as toxic tear syndrome. This theoretical concept has been partially validated in studies by Tong et al. In a first work, the authors showed that placement of punctal plugs did not significantly decrease levels of pro-inflammatory cytokines or metalloproteinases (MMP-9) in the tears [51]. In a second study, however, they showed that proteins associated with inflammation decreased in the subgroup of patients with very low Schirmer's values prior to occlusion [52]. These results suggest the necessity of anti-inflammatory treatment prior to placing punctal plugs if there is any question of inflammation (sometimes subclinical) of the ocular surface.

Pyogenic granuloma

This is a rare complication [18]. The lesion most often takes on the appearance of a fleshy bud emanating from the lacrimal punctum (**Figure 7**) but may also pass for a papilloma and be associated with canaliculitis [53]. The development of a granuloma might be associated with surface irregularities in the silicone and a larger sized punctal plug [54]. Removal of the plug, irrigation of the lacrimal pathways and topical antibiotic-steroid treatment is usually sufficient. In case of failure, surgical removal may be proposed [55].

Epiphora

This complication, most often inconsequential, is reported in all studies on punctal plugs. Rates vary between 1.5 and 36.5 % depending on the study and are overall higher with punctal plugs than canalicular plugs [18, 56].

Punctal stenosis

Punctal stenosis after loss or removal of a punctal plug is a relatively frequent complication. The pathophysiology is uncertain, but the position of the collarette and accumulation of debris around it might result in inflammation of the punctal mucosa as the cause of the stenosis [57].

Local irritation

The collarette of certain punctal plugs, especially in the case of partial extrusion, may cause conjunctival or even corneal irritation. Symptoms may require repositioning or even removal of the plug.

Distal migration

With most punctal plugs, this is related to choosing a plug too small for the punctum, or possibly too much pressure upon placement. The main risk is late canaliculitis. For this reason, if the collarette enters the lacrimal system at the time of placement, the plug must quickly be removed with forceps.

Canaliculitis

This is more frequent with intracanalicular plugs (6 to 60 %, depending on the model, the series and the duration of follow-up) [58, 59] than with punctal plugs (0 to 6 %) [56]. Similarly, the risk of infection appears greater with silicone plugs than with acrylic plugs [60]. Notably, several publications have reported particularly high rates of canaliculitis with the *Herrick Plug* and *Smart Plug* canalicular plugs [58, 59]. The most commonly used treatment is surgical, by performance of a canaliculotomy and removal of the plug, with bacterial culture; lavage of the plug by canalicular irrigation is rarely sufficient. Broad spectrum antibiotic therapy is administered, subsequently adjusted according to the lab results. The duration of treatment is 3 to 4 weeks.

Conclusion

Punctal plugs are useful not only in the management of aqueous-deficient dry eye but also for numerous other ocular surface diseases [4], for which they represent useful therapeutic adjuvants. New models, designed to improve tolerability or efficacy, allow them to be used in most situations. The safety profiles are unique to each model and must be known to the prescriber. Long term follow-up is necessary, since late complications are possible.

Acknowledgements

The authors wish to sincerely thank Mrs. Manon Escoda (Nanonna) for the illustrations, and Mrs. Susanne Englisch and Mr. Nicolas Beguin-Vincent for the careful proof-reading of certain lines in tables 1 and 2.

Disclosure of interest

The authors report no conflicts of interest in relation to this article.

References:

- [1] Punctal occlusion for the dry eye. Three-year revision. American Academy of Ophthalmology. *Ophthalmology*. 1997;104:1521-4.
- [2] Gilbard JP, Rossi SR, Azar DT, Heyda KG. Effect of punctal occlusion by Freeman silicone plug insertion on tear osmolarity in dry eye disorders. *Clao j*. 1989;15:216-8.
- [3] Jehangir N, Bever G, Mahmood SM, Moshirfar M. Comprehensive Review of the Literature on Existing Punctal Plugs for the Management of Dry Eye Disease. *Journal of ophthalmology*. 2016;2016:9312340.
- [4] Song JS, Woo IH, Eom Y, Kim HM. Five Misconceptions Related to Punctal Plugs in Dry Eye Management. *Cornea*. 2018; epub.
- [5] Orbit, Eyelids, and Lacrimal System: American Academy of Ophthalmology; 2017.
- [6] Adenis J, Morax S. Pathologies orbito-palpébrales. Paris: Masson; 1998. p. 17.
- [7] Ducasse A, Adenis J, Fayet B, George G, Ruban J. Anatomie macroscopique des voies lacrymales. In: Ducasse A, editor. *Les Voies Lacrymales, rapport de la Société Française d'Ophtalmologie*. Paris: Masson; 2006. p. 19-23.
- [8] Paulsen F, Thale A, Kohla G, Schauer R, Rochels R, Parwaresch R, et al. Functional anatomy of human lacrimal duct epithelium. *Anat Embryol (Berl)*. 1998;198:1-12.
- [9] Paulsen FP, Schaudig U, Thale AB. Drainage of tears: impact on the ocular surface and lacrimal system. *Ocul Surf*. 2003;1:180-91.
- [10] Tomlinson A, Trees GR, Occhipinti JR. Tear production and evaporation in the normal eye. *Ophthalmic Physiol Opt*. 1991;11:44-7.
- [11] Sisler HA. One-way flow in the lacrimal drainage system: determinants from the basic sciences. *Annals of ophthalmology*. 1982;14:76-7.

- [12] Ducasse A, Adenis J, Fayet B, George G, Ruban J. Physiologie des voies lacrymales. In: Ducasse A, editor. Les Voies Lacrymales, rapport de la Société Française d'Ophtalmologie. Paris: Masson; 2006. p. 57-66.
- [13] White WL, Glover AT, Buckner AB, Hartshorne MF. Relative canalicular tear flow as assessed by dacryoscintigraphy. *Ophthalmology*. 1989;96:167-9.
- [14] Murgatroyd H, Craig JP, Sloan B. Determination of relative contribution of the superior and inferior canaliculi to the lacrimal drainage system in health using the drop test. *Clin Exp Ophthalmol*. 2004;32:404-10.
- [15] Chen F, Wang J, Chen W, Shen M, Xu S, Lu F. Upper punctal occlusion versus lower punctal occlusion in dry eye. *Investigative ophthalmology & visual science*. 2010;51:5571-7.
- [16] Jones L, Downie LE, Korb D, Benitez-Del-Castillo JM, Dana R, Deng SX, et al. TFOS DEWS II Management and Therapy Report. *Ocul Surf*. 2017;15:575-628.
- [17] Kaido M, Ishida R, Dogru M, Tsubota K. Visual function changes after punctal occlusion with the treatment of short BUT type of dry eye. *Cornea*. 2012;31:1009-13.
- [18] Marcet MM, Shtein RM, Bradley EA, Deng SX, Meyer DR, Bilyk JR, et al. Safety and Efficacy of Lacrimal Drainage System Plugs for Dry Eye Syndrome: A Report by the American Academy of Ophthalmology. *Ophthalmology*. 2015;122:1681-7.
- [19] Ervin AM, Law A, Pucker AD. Punctal occlusion for dry eye syndrome. *Cochrane Database Syst Rev*. 2017;6:CD006775.
- [20] Goto E, Tseng SC. Kinetic analysis of tear interference images in aqueous tear deficiency dry eye before and after punctal occlusion. *Investigative ophthalmology & visual science*. 2003;44:1897-905.

- [21] Liu Y, Hirayama M, Cui X, Connell S, Kawakita T, Tsubota K. Effectiveness of Autologous Serum Eye Drops Combined With Punctal Plugs for the Treatment of Sjogren Syndrome-Related Dry Eye. *Cornea*. 2015;34:1214-20.
- [22] Sakamoto A, Kitagawa K, Tatami A. Efficacy and retention rate of two types of silicone punctal plugs in patients with and without Sjogren syndrome. *Cornea*. 2004;23:249-54.
- [23] Shikari H, Antin JH, Dana R. Ocular graft-versus-host disease: a review. *Survey of ophthalmology*. 2013;58:233-51.
- [24] Magro L, Gauthier J, Richet M, Robin M, Nguyen S, Suarez F, et al. Scleral lenses for severe chronic GvHD-related keratoconjunctivitis sicca: a retrospective study by the SFGM-TC. *Bone marrow transplantation*. 2017;52:878-82.
- [25] Shih KC, Lun CN, Jhanji V, Thong BY, Tong L. Systematic review of randomized controlled trials in the treatment of dry eye disease in Sjogren syndrome. *J Inflamm (Lond)*. 2017;14:26.
- [26] Kamoi M, Ogawa Y, Dogru M, Uchino M, Kawashima M, Goto E, et al. Spontaneous lacrimal punctal occlusion associated with ocular chronic graft-versus-host disease. *Current eye research*. 2007;32:837-42.
- [27] Kaido M, Goto E, Dogru M, Tsubota K. Punctal occlusion in the management of chronic Stevens-Johnson syndrome. *Ophthalmology*. 2004;111:895-900.
- [28] Romero-Rangel T, Stavrou P, Cotter J, Rosenthal P, Baltatzis S, Foster CS. Gas-permeable scleral contact lens therapy in ocular surface disease. *Am J Ophthalmol*. 2000;130:25-32.
- [29] Cher I. Superior limbic keratoconjunctivitis: multifactorial mechanical pathogenesis. *Clin Exp Ophthalmol*. 2000;28:181-4.

- [30] Yang HY, Fujishima H, Toda I, Shimazaki J, Tsubota K. Lacrimal punctal occlusion for the treatment of superior limbic keratoconjunctivitis. *Am J Ophthalmol.* 1997;124:80-7.
- [31] Tai MC, Cosar CB, Cohen EJ, Rapuano CJ, Laibson PR. The clinical efficacy of silicone punctal plug therapy. *Cornea.* 2002;21:135-9.
- [32] Sivaraman KR, Jivrajka RV, Soin K, Bouchard CS, Movahedan A, Shorter E, et al. Superior Limbic Keratoconjunctivitis-like Inflammation in Patients with Chronic Graft-Versus-Host Disease. *Ocul Surf.* 2016;14:393-400.
- [33] Dua HS, Said DG, Messmer EM, Rolando M, Benitez-Del-Castillo JM, Hossain PN, et al. Neurotrophic keratopathy. *Prog Retin Eye Res.* 2018;
- [34] Toda I, Asano-Kato N, Hori-Komai Y, Tsubota K. Ocular surface treatment before laser in situ keratomileusis in patients with severe dry eye. *Journal of refractive surgery (Thorofare, NJ : 1995).* 2004;20:270-5.
- [35] Jabbur NS, Sakatani K, O'Brien TP. Survey of complications and recommendations for management in dissatisfied patients seeking a consultation after refractive surgery. *J Cataract Refract Surg.* 2004;30:1867-74.
- [36] Huang B, Mirza MA, Qazi MA, Pepose JS. The effect of punctal occlusion on wavefront aberrations in dry eye patients after laser in situ keratomileusis. *Am J Ophthalmol.* 2004;137:52-61.
- [37] Li M, Wang J, Shen M, Cui L, Tao A, Chen Z, et al. Effect of punctal occlusion on tear menisci in symptomatic contact lens wearers. *Cornea.* 2012;31:1014-22.
- [38] Sherwin JC, Ratnarajan G, Elahi B, Bilkiewicz-Pawelec A, Salmon JF. Effect of a punctal plug on ocular surface disease in patients using topical prostaglandin analogues: a randomized controlled trial. *Clin Exp Ophthalmol.* 2018;

- [39] Baudouin C, Labbe A, Liang H, Pauly A, Brignole-Baudouin F. Preservatives in eyedrops: the good, the bad and the ugly. *Prog Retin Eye Res.* 2010;29:312-34.
- [40] Bartlett JD, Boan K, Corliss D, Gaddie IB. Efficacy of silicone punctal plugs as adjuncts to topical pharmacotherapy of glaucoma--a pilot study. *Punctal Plugs in Glaucoma Study Group. Journal of the American Optometric Association.* 1996;67:664-8.
- [41] Xu L, Wang X, Wu M. Topical medication instillation techniques for glaucoma. *Cochrane Database Syst Rev.* 2017;2:Cd010520.
- [42] Gupta C, Chauhan A. Ophthalmic delivery of cyclosporine A by punctal plugs. *Journal of controlled release : official journal of the Controlled Release Society.* 2011;150:70-6.
- [43] Xie J, Wang C, Ning Q, Gao Q, Gao C, Gou Z, et al. A new strategy to sustained release of ocular drugs by one-step drug-loaded microcapsule manufacturing in hydrogel punctal plugs. *Graefes Arch Clin Exp Ophthalmol.* 2017;255:2173-84.
- [44] Aref AA. Sustained drug delivery for glaucoma: current data and future trends. *Current opinion in ophthalmology.* 2017;28:169-74.
- [45] Perera SA, Ting DS, Nongpiur ME, Chew PT, Aquino MC, Sng CC, et al. Feasibility study of sustained-release travoprost punctum plug for intraocular pressure reduction in an Asian population. *Clinical ophthalmology (Auckland, NZ).* 2016;10:757-64.
- [46] Burgess PI, Koay P, Clark P. SmartPlug versus silicone punctal plug therapy for dry eye: a prospective randomized trial. *Cornea.* 2008;27:391-4.
- [47] Mansour K, Leonhardt CJ, Kalk WW, Bootsma H, Bruin KJ, Blanksma LJ, et al. Lacrimal punctum occlusion in the treatment of severe keratoconjunctivitis Sicca caused by Sjogren syndrome: a uniocular evaluation. *Cornea.* 2007;26:147-50.

- [48] Balaram M, Schaumberg DA, Dana MR. Efficacy and tolerability outcomes after punctal occlusion with silicone plugs in dry eye syndrome. *Am J Ophthalmol.* 2001;131:30-6.
- [49] Ohba E, Dogru M, Hosaka E, Yamazaki A, Asaga R, Tatematsu Y, et al. Surgical punctal occlusion with a high heat-energy releasing cautery device for severe dry eye with recurrent punctal plug extrusion. *Am J Ophthalmol.* 2011;151:483-7.e1.
- [50] Yaguchi S, Ogawa Y, Kamoi M, Uchino M, Tatematsu Y, Ban Y, et al. Surgical management of lacrimal punctal cauterization in chronic GVHD-related dry eye with recurrent punctal plug extrusion. *Bone marrow transplantation.* 2012;47:1465-9.
- [51] Tong L, Beuerman R, Simonyi S, Hollander DA, Stern ME. Effects of Punctal Occlusion on Clinical Signs and Symptoms and on Tear Cytokine Levels in Patients with Dry Eye. *Ocul Surf.* 2016;14:233-41.
- [52] Tong L, Zhou L, Beuerman R, Simonyi S, Hollander DA, Stern ME. Effects of punctal occlusion on global tear proteins in patients with dry eye. *Ocul Surf.* 2017;15:736-41.
- [53] Ahn HB, Seo JW, Roh MS, Jeong WJ, Park WC, Rho SH. Canaliculitis with a papilloma-like mass caused by a temporary punctal plug. *Ophthalmic Plast Reconstr Surg.* 2009;25:413-4.
- [54] Kim BM, Osmanovic SS, Edward DP. Pyogenic granulomas after silicone punctal plugs: a clinical and histopathologic study. *Am J Ophthalmol.* 2005;139:678-84.
- [55] Huang CJ, Lu CJ, Tu WH, Hou YC, Wang IJ, Hu FR, et al. Analysis of SmartPlug Insertion-Related Complications. *Eye Contact Lens.* 2018;
- [56] Kaido M, Ishida R, Dogru M, Tsubota K. A new punctal plug insertion technique to prevent intracanalicular plug migration. *Am J Ophthalmol.* 2009;147:178-82 e1.

- [57] Horwath-Winter J, Thaci A, Gruber A, Boldin I. Long-term retention rates and complications of silicone punctal plugs in dry eye. *Am J Ophthalmol.* 2007;144:441-4.
- [58] Management of complications after insertion of the SmartPlug punctal plug: a study of 28 patients. *Ophthalmology.* 2006;113:1859.e1-6.
- [59] Jones CE, Anklesaria M, Gordon AD, Prouty RE, Rashid R, Singla RK, et al. Retrospective safety study of the herrick lacrimal plug: a device used to occlude the lacrimal canaliculus. *Clao j.* 2002;28:206-10.
- [60] Tost FH, Geerling G. Plugs for occlusion of the lacrimal drainage system. *Developments in ophthalmology.* 2008;41:193-212.

Legends of figures/tables/videos

Figure 1: Anatomy of the upper lacrimal drainage system.

Figure 2: Schematic representation of the positioning of the main types of punctal plugs in the lacrimal pathways. A) Punctal plug with collarette. B) Absorbable canalicular plug in the horizontal segment of the canaliculus. C) Non-resorbable canalicular plug in the vertical segment of the canaliculus. No study has allowed a robust comparison of the clinical efficacy of these different types of plugs. However, differences in terms of tolerability and complications between punctal and canalicular plugs are well described (cf. paragraphs “the various punctal plugs” and “complications”), notably with a higher rate of canaliculitis for non-resorbable canalicular plugs.

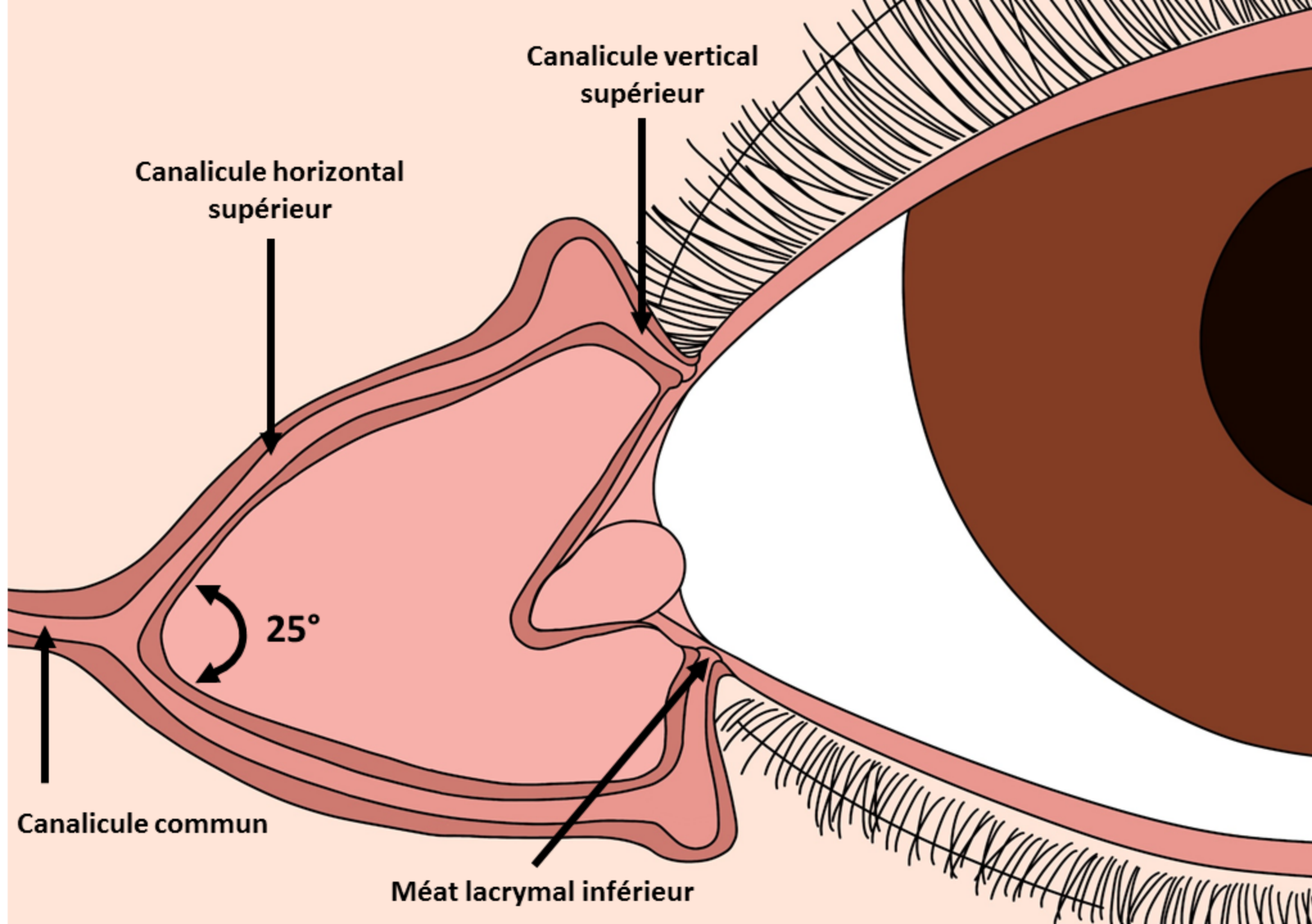
Figure 3: The various punctal plugs available in France.

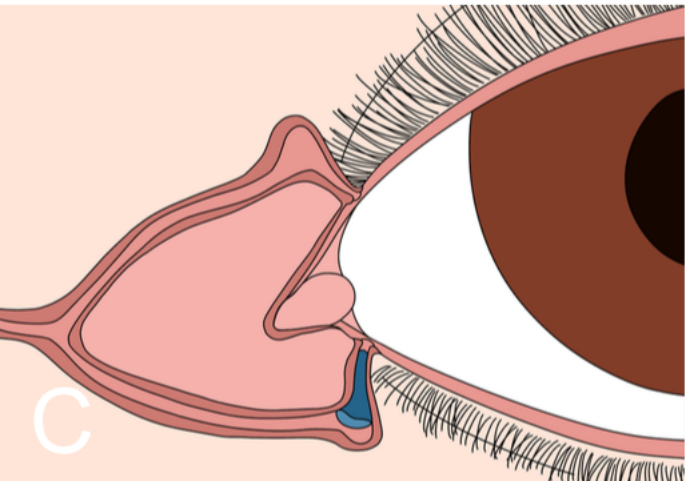
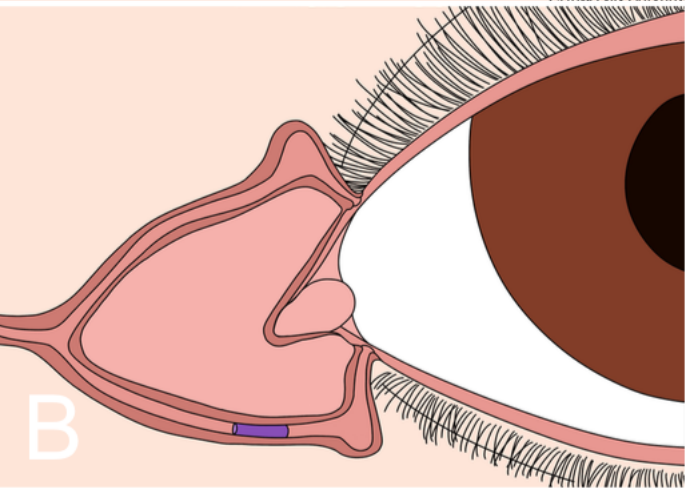
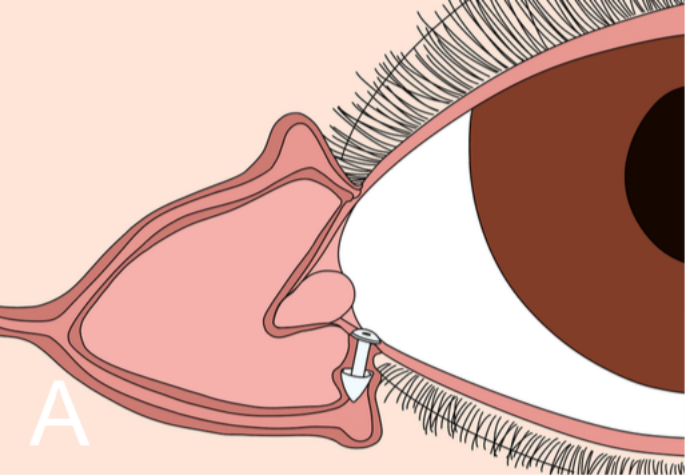
Figure 4 The various canalicular plugs available in France.







Figure 5: Photograph of the ocular surface in a patient with Goujerot-Sjögren’s syndrome treated with punctal plugs and topical 2 % cyclosporine, 2 drops per day. A) Prior to placement of superior and inferior plugs, confluent superficial punctate keratopathy, stage 4 according to the simplified Oxford classification. B) 3 months after placement of plugs with continuation of topical 2 % cyclosporine treatment. Note the clear reduction in the superficial punctate keratopathy, improving to Oxford stage 1 (persistent conjunctival punctate staining not visible on the photograph).





Figure 6: Partial extrusion of a superior punctal plug with canalicular inflammation.

Figure 7: Pyogenic granuloma developing from the superior punctum in a patient with severe dry eye in the setting of graft vs. host disease.





Name	Distributor / Manufacturer	Size	Preloaded	Material	Temporary or permanent	Characteristics
Painless Plug® 	FCI / FCI	One size fits all	Yes	Silicone	Permanent	Dilation not required
Plug 1® 	Ophta France / Eagle vision Katena products Inc	One size fits all (for lacrimal puncta 0.5 to 0.8 mm in diameter)	Yes	Silicone	Permanent	Dilation not required, ultra fine soft collarette
Punctal plugs 	FCI / FCI	5 sizes	Yes	Silicone	Permanent	Dilation required, slanted collarette
Soft Plug® 	Ophta France / Eagle vision Katena products Inc	5 sizes (0.4 - 0.5 - 0.6- 0.7- 0.8 mm)	Yes	Silicone	Permanent	Dilation required, straight collarette
Flex Plug® 	Ophta France / Eagle vision Katena products Inc	6 sizes (0.4 - 0.5 - 0.6- 0.7- 0.8 - 0.9 mm)	Yes	Silicone	Permanent	Flexible body
Parasol® punctal plug 	Larm-o-tec / Beaver Visitec	4 sizes XS (0.25 mm – 0.35 mm), S (0.35 mm – 0.65 mm), M (0.6 mm – 0.85 mm), L (0.9 mm +)	Yes	Silicone	Permanent	Dilation required

Name	Distributor / Manufacturer	Size	Preloaded	Material	Temporary or permanent	Characteristics
Form Fit® 	Ophta France / Eagle vision Katena products Inc	single diameter (0.3 mm) by 2.5 mm long (in dry state)	yes	Hydrogel	Permanent	Expands upon hydration, removed by flushing saline through lacrimal passages
Extended Duration Plug® 	Ophta France / Eagle vision Katena products Inc	3 sizes 0.3 - 0.4 and 0.5 mm	no	Vicryl	Temporary - 3 months	Placed with forceps, effective for 3 months, package of 2 units
Herrick plug® 	Larm-o-tec Lacrimedics	2 sizes: 0.5 and 0.7 mm	yes	Silicone	Permanent	Radiopaque, in shape of golf tee, easier to insert but propensity toward infection
Visiplug® 	Larm-o-tec Lacrimedics	2 sizes: 0.4 and 0.5 mm	Placed with provided forceps	PDS	Temporary	Prior dilation, Lasts up to 6 months

