



HAL
open science

Sterile keratitis following standard corneal collagen crosslinking: A case series and literature review

D. Mereaux, J. Knoeri, L. Jouve, L. Laroche, V. Borderie, N. Bouheraoua

► **To cite this version:**

D. Mereaux, J. Knoeri, L. Jouve, L. Laroche, V. Borderie, et al.. Sterile keratitis following standard corneal collagen crosslinking: A case series and literature review. *Journal Français d'Ophtalmologie*, 2019, 42, pp.603 - 611. 10.1016/j.jfo.2018.11.015 . hal-03486932

HAL Id: hal-03486932

<https://hal.science/hal-03486932>

Submitted on 20 Dec 2021

HAL is a multi-disciplinary open access archive for the deposit and dissemination of scientific research documents, whether they are published or not. The documents may come from teaching and research institutions in France or abroad, or from public or private research centers.

L'archive ouverte pluridisciplinaire **HAL**, est destinée au dépôt et à la diffusion de documents scientifiques de niveau recherche, publiés ou non, émanant des établissements d'enseignement et de recherche français ou étrangers, des laboratoires publics ou privés.



Distributed under a Creative Commons Attribution - NonCommercial 4.0 International License

Sterile keratitis following standard corneal collagen crosslinking: a case series
and literature review.

Infiltrats cornéens stériles après crosslinking du collagène conventionnel : séries
de cas et revue de la littérature.

David Mereaux, MD¹, Juliette Knoeri, MD¹, Lea Jouve, MD¹, Laurent Laroche, MD^{1,2},
Vincent Borderie, MD, PhD^{1,2}, Nacim Bouheraoua, MD, PhD^{1,2*}.

¹Quinze-Vingts National Ophthalmology Hospital, Paris, France. Sorbonne Université -
UPMC Univ Paris 06.

²Institut de la Vision, Paris, France, Sorbonne Université, UPMC Univ Paris 06, UMR S 968.

Running title: Sterile keratitis following corneal crosslinking.

***Corresponding author:** Nacim Bouheraoua, MD, PhD. Quinze-Vingts National
Ophthalmology Hospital, Paris, France. 28 rue de Charenton, 75012 Paris, France.

Tel: 00 33 6 21 50 63 99; Fax: 00 33 1 40 02 15 99.

E-mail: nacim.bouheraoua@gmail.com

Running head : Sterile keratitis following standard corneal collagen crosslinking

Abstract

Standard corneal collagen crosslinking (S-CXL) is a safe, approved procedure, but it may result in severe pain, early vision loss and possible complications, such as infectious or sterile keratitis, in some cases. We describe four cases of sterile infiltrates after uneventful S-CXL for keratoconus, from diagnosis to medical management with six months of follow-up, reporting their pathophysiological features, and comparing our findings with published reports. We discuss various possibilities for diagnosing sterile infiltration more rapidly. In terms of the pathophysiology of sterile infiltrate formation, we separated our patients into two types, one with sterile infiltrate from an antigen reaction and the other with sterile infiltrate due to excessive scarring. Early local steroid treatment resulted in a good visual outcome in our cases.

Keys words: Cornea; Crosslinking; Keratoconus; Sterile keratitis; Complication

Résumé

Le crosslinking du collagène conventionnel (S-CXL) est une procédure sûre et approuvée, mais elle peut entraîner une douleur intense, une perte précoce de la vision et des complications possibles, comme la kératite infectieuse ou stérile, dans certains cas. Nous décrivons quatre cas d'infiltrats stériles après une S-CXL sans incident pour le kératocône, du diagnostic à la prise en charge médicale avec six mois de suivi, en rapportant leurs caractéristiques physiopathologiques et en comparant nos résultats aux rapports publiés. Nous discutons des différentes possibilités pour diagnostiquer plus rapidement l'infiltration stérile. Pour ce qui est de la physiopathologie de la formation d'infiltrat stérile, nous avons séparé nos patients en deux types, l'un avec infiltrat stérile provenant d'une réaction antigénique et l'autre avec infiltrat stérile dû à une cicatrisation excessive. Le traitement stéroïde local précoce a eu un bon résultat visuel dans nos cas.

Mots-clés : Cornée ; réticulation ; kératocône ; kératocône ; kératite stérile ; complication

Introduction

Keratoconus is a bilateral, progressive, non-inflammatory corneal ectasia. It is the most common dystrophy, affecting 1 in 2000 individuals in the working-age population [1]. It usually leads to progressive corneal deformation and a loss of vision [2]. Corneal collagen crosslinking is a surgical procedure that is used to halt the progression of keratoconus by increasing corneal strength. Standard corneal collagen crosslinking (S-CXL), an epi-off protocol using riboflavin and UVA irradiation, is the only procedure currently well validated [3-5]. Although S-CXL is authorized and considered safe, it may, in some cases, cause severe pain, early vision loss and complications, such as infectious or sterile keratitis [6-9]. Koller et al. [7] reported the occurrence of sterile infiltrates in 7.6% of the treated eyes in a large series of keratoconic patients undergoing S-CXL. This condition was resolved by four weeks of treatment with dexamethasone administered four times daily.

We describe four cases of sterile infiltrates after uneventful S-CXL for keratoconus. We report the diagnostic pathway, the medical management of these cases, with six months of follow-up, and their pathophysiology, deciphered by comparisons with published findings.

Case descriptions

Case 1

A 29-year-old woman presented with progressive keratoconus of the right eye, with a Kmax increasing by 1.6 D and a minimum pachymetry decreasing by 25 μm over the course of six months, in an atopic background with a history of latex allergy. Before surgery, best spectacle-corrected visual acuity (BSCVA) was 20/25 for the right eye and 20/20 for the left eye. For the right eye, minimal corneal thickness was 468 μm and maximum keratometry (Kmax) was 50.2 D. S-CXL was performed on the right eye, under topical anesthesia and in

strictly sterile conditions, after the mechanical debridement of 9 mm of the epithelium, as shown in table 1.

A soft bandage contact lens (BCL) was placed on the eye at the end of surgery and was left in place until complete re-epithelialization was achieved. After surgery, the patient was asked to instill topical tobramycin four times daily for one week, and topical dexamethasone and hyaluronate eye drops four times daily for one month. However, 48 hours after the procedure, the patient presented with pain, redness, and vision loss in the right eye. At the time of presentation, BSCVA was hand motion for the right eye and 20/20 for the left eye. Slit-lamp examination showed diffuse conjunctival injection, with multiple central and paracentral infiltrates in the corneal stroma, fluorescein negative in regards of infiltrate and fluorecein positive in the cornea center where the corneal ulceration was not yet closed. Mild anterior chamber reactions with keratic precipitates were observed, together with a 1 mm hypopyon (Figure 1A, B). On optical coherence tomography (OCT; RTVue[®], Optovue Inc., Fremont, USA), the anterior stroma was visible as a hyperreflection corresponding to the infiltrates (Figure 1 C). The patient was still wearing the bandage contact lens, which was removed and sent for microbiological studies, together with corneal scraping.

The patient was admitted and topical treatment with fortified antibiotics (piperacillin, gentamycin and vancomycin) was initiated at a dose of one drop of each per hour. Corneal scraping revealed a *Streptococcus oralis* sensitive to levofloxacin and rifamycin, so the topical antibiotics initially used were replaced by these molecules, administered at a frequency of eight drops per day. After 7 days of topical antibiotic treatment, given the lack of significant improvement and the initial presentation with a major inflammatory reaction, hypopyon and multiple infiltrates occurring only 48 hours after S-CXL, we hypothesized that the infiltrates might actually be sterile, with a false-positive results obtained for the corneal scraping. Local antibiotic treatment was stopped and the patient was treated with three drops

per day of dexamethasone (Dexafree, 1 mg/ml) gradually decreased over the course of three weeks. Furthermore, aminoglycoside can participate in the delayed healing by its intrinsic toxicity. This treatment eliminated the signs of inflammation within a few days, and the infiltrates resolved, with only small opacities remaining in the anterior stroma as a sequel by the end of treatment (Figure 1 D, E). At the six-month follow-up visit, the patient had recovered a BSCVA of 20/25; Kmax had increased from 50.2 D to 51.9 D and minimum pachymetry had increased from 468 to 457 μm (Figure 1 F, G, H, I). This change in Kmax may be accounted for by fibrosis.

Case 2

A 13-year-old boy presented with progressive keratoconus of the right eye, with a Kmax increasing by 1.3 D and a minimum pachymetry decreasing by 14 μm over a period of four months. Before surgery, BSCVA was 20/40 for the right eye and 20/32 for the left eye. The right eye had a minimal cornea thickness of 479 μm and a Kmax of 51.7 D. This patient had a history of vernal keratoconjunctivitis treated with local corticosteroids and 0.05% levocabastine hydrochloride. Uneventful S-CXL was performed on the right eye, with the procedure described in table 1. However, 48 hours after the procedure, the patient presented with photophobia, redness, and blurred vision in the right eye. On presentation, the bandage contact lens, which was still on the eye, was removed and sent for microbiological studies, together with the corneal scraping. The BSCVA of the right eye was 20/200. Slit-lamp examination revealed diffuse conjunctival injection with submillimeter central subepithelial infiltrates and superficial punctate keratitis (Figure 2 A, B). OCT showed well-delineated subepithelial hyperreflectivity (Figure 2 C). The patient was admitted and local treatment with fortified antibiotics (piperacillin, gentamycin and vancomycin) was initiated at a dose of one drop of each antibiotic per hour after corneal scraping. After three days of hospitalization, the

results for all samples and for confocal microscopy were negative and oriented for an absence of infection. The absence of pain, the appearance and history of vernal keratoconjunctivitis suggested a sterile infiltrate. Antibiotic treatment was, therefore, stopped, specially aminoglycoside can participate in the delayed healing by its intrinsic toxicity and treatment with three drops per day of dexamethasone (Dexafree, 1 mg/ml) was instigated and gradually decreased over the course of three weeks. This treatment resulted in a gradual resolution of the keratitis. At six months, the patient had recovered his preoperative BSCVA of 20/40, but two paracentral stromal infiltrates remained (Figure 2 D). Kmax increased from 51.7 to 54.9 D and minimum pachymetry decreased from 479 to 460 μm (Figure 2 F, G, H, I). On OCT, subepithelial hyperreflectivity remained but was less intense, with stromal thinning compensated by epithelial thickening (Figure 2 E). The observed change in Kmax could also be explained by fibrosis.

Case 3

A 34-year-old man presented with progressive keratoconus of the right eye, with Kmax increasing by 1.7 D and minimum pachymetry decreasing by 23 μm over a period of six months. Before surgery, BSCVA was 20/40 for the right eye and 20/32 for the left eye. For the right eye, minimal corneal thickness was 402 μm and Kmax was 57.9D. Uneventful S-CXL was performed on the right eye. However, 48 hours after the procedure, the patient presented with pain, redness, blurred vision, and a BSCVA of hand motion. Slit-lamp examination revealed diffuse conjunctival injection, with a central corneal infiltrate of 1.5 millimeters in diameter staining positively with fluorescein (Figure 3 A, B). On OCT, hyperreflection corresponding to the infiltrates was observed in the anterior stroma (Figure 3 C).

The patient was admitted and topical treatment with fortified antibiotics (piperacillin, gentamycin and vancomycin) was initiated at a dose of one drop of each per hour. The

corneal scraping was positive at *Staphylococcus epidermidis* sensitive to levofloxacin and rifamycin, so the fortified antibiotics initially used were replaced by these molecules, at a frequency of eight drops per day. After five days of treatment, no improvement was observed and the inflammatory signs persisted. Given this lack of improvement, the small probability of a large abscess occurring only 48 hours after S-CXL, the high probability of contamination of the corneal scraping and the possible participation of aminoglycoside in the delayed healing therefore the topical antibiotics were stopped and treatment with three drops per day of dexamethasone (Dexafree, 1 mg/ml) was instigated and gradually decreased over the course of three weeks. This led to a clearing of the patient's cornea and the development of an avascular stromal scar, thanks to the gradual decrease in topical corticosteroid dose (Figure 3 D). At six months, the patient had recovered his preoperative BSCVA of 20/40, and Kmax had stabilized, decreasing slightly, from 57.9 D to 55.1 D, while minimum pachymetry had decreased from 402 to 394 μm (Figure 3 F, G, H, I). OCT revealed hyperreflectivity throughout the stromal layer, corresponding to fibrosis (Figure 3 E). This fibrosis may have contributed to the stabilization of Kmax.

Case 4

A 15-year-old boy presented with progressive keratoconus of the right eye, with Kmax increasing by 0.8 D and a minimum pachymetry decreasing by 15 μm over a period of three months. Before surgery, BSCVA was 20/32 for the right eye and 20/20 for the left eye, and the right eye had a minimal corneal thickness of 449 μm and a Kmax of 47.8 D. Uneventful S-CXL was performed on the right eye. The patient presented with blurred vision, but no pain, 48 hours after the procedure. At the time of presentation, BSCVA was 20/100 for the right eye. On the slit-lamp examination, a stromal infiltrate was visible, with a corneal edema and no epithelial defect (Figure 4 A, B). On OCT, hyperreflectivity was observed in all

stromal layers. (Figure 4 C) The patient was admitted and topical treatment with fortified antibiotics (piperacillin, gentamycin and vancomycin) was initiated at a dose of one drop of each antibiotic per hour after corneal scraping. The results for all samples and for confocal microscopy were negative, indicating for an absence of infection. We therefore concluded that the infiltration was due to excessive scarring, and we switched the patient on to treatment with dexamethasone (Dexafree, 1 mg/ml) at a dose of three drops per day gradually decreased over the course of three weeks. This cleared the patient's cornea and led to the formation of an avascular stromal scar, thanks to the gradual decrease in topical corticosteroid dose (Figure 4 D). Six months after surgery, the patient had recovered his preoperative BSCVA of 20/32, and Kmax had stabilized, decreasing from 47.8 D to 46.1 D. The cornea was also thinner, with a decrease in minimum from 449 to 406 μm (Figure 4 F,G,H,I). On OCT, hyperreflectivity persistent in all stromal layers, accompanied by a flattening and thinning of the cornea (Figure 4 E).

Discussion

S-CXL has been shown to be an effective and safe procedure, but a few cases of bacterial or sterile keratitis after cross-linking have been reported. The frequency of sterile keratitis varies between studies, with values of 0.97% [10] or 2.7% [11] reported in retrospective studies and a value of 6.7% [7] reported in a prospective study. Many possible reasons for these differences have been put forward, including the difficulty of diagnosing sterile keratitis, predisposing factors present in the patients before surgery and the type of cross-linking performed with or without removal of the epithelium.

As illustrated by our cases, it is not always easy to distinguish between bacterial and sterile keratitis, and this can delay initiation of the correct corticosteroid-based treatment. The points

common to our four cases that prompted us to consider the possibility of sterile keratitis were a lack of efficacy of the antibiotics against the keratitis and inflammatory signs (only local corticosteroid treatment improved the symptoms), the short time to appearance of the infiltrate, and the type of infiltrate on slit-lamp examination (large mostly fluorescein-negative infiltrates), good recovery with no major sequelae and the absence of substantial thinning of the cornea after surgery. Table 2 summarizes the difference in semiology and evolution between sterile infiltrate and infected one.

We separated the patients into two types according to the most likely cause of sterile keratitis. The first two cases were probably due to an antigenic reaction [12-13], whereas the last two appear to have been caused by excessive scarring [11]. Sterile corneal stromal infiltrates have been reported to result from enhanced cell-mediated immunity to staphylococcal antigens deposited at high concentrations in areas of static tear pooling [12]. The clues to the antigenic origin of the first two cases were the atopic background with multiple allergies, the initial presentation as photophobia and redness, the slit-lamp presentation with a major inflammatory reaction after only 48 hours and multiple infiltrates all over the cornea corresponding to the area covered by the bandage contact lens (BCL). In these cases, the BCL probably served as a reservoir of antigens [12]. A few similar cases have been reported following photorefractive keratectomy (PKT) [14-15], but at a lower frequency than for S-CXL. This may be due to a higher frequency of allergy in the population of patients with keratoconus, exposure to UVA during the procedure, the thinner cornea of these patients and the postoperative treatment administered. The presence of a BCL probably increases the frequency of such infiltrates, but is not the only factor favoring their development, as sterile infiltrates have also been reported in patients who have undergone PKT without the application of a BCL [14]. It is therefore unclear whether it would be beneficial not to apply a BCL, but the absence of a BCL might reasonably be expected to decrease the frequency of

sterile infiltrates. Moreover, BCL has been identified as the most significant risk factor for the development of bacterial keratitis [16-17].

For the last two cases, the clues suggesting that excessive scarring might be responsible were the absence of pain after the intervention, with no signs of inflammation and no photophobia, the localization of the scar to the thinnest part of the cornea and diffuse lamellar keratitis on OCT-SA corresponding to fibrosis. This type of sterile keratitis probably results from colonization by new keratocytes after debridement. This new population of keratocytes develops into myofibroblasts, which increase the density of the extracellular matrix by synthesizing new collagen fibers [18], accounting for the development of diffuse lamellar sterile keratitis. Lam and coworkers [11] reported four similar cases in a group of seven patients. After analysis of the characteristics of the patients, the UVA lamp and riboflavin drops, the only factor significantly predictive of sterile infiltrates was the combination of a corneal thickness of less than 425 μm and a steepness of more than 60 D. They suggested that exposure to UVA radiation was toxic to the corneal endothelium, but they found no difference in endothelial cell densities before and three months after surgery. Case 3 was the only one of our patients with similar characteristics. Furthermore, Lam and coworkers used a transepithelial crosslinking technique, suggesting that this type of keratitis may occur regardless of the type of cross-linking protocol. This type of keratitis has already been reported in an epi-off protocol [18], but with a loss of vision necessitating corneal transplantation. Our patients recovered their preoperative BSCVA because of the paracentral location of the scars and good regression of the condition on local corticosteroid treatment introduced early.

In our opinion, all cases of infiltration should initially be considered potentially infected. Corneal scraping should therefore be performed, together with OCT and confocal microscopy, but in the absence of improvement after a few days, the diagnosis should be

reconsidered and the possibility of a sterile infiltrate explored, particularly if other suggestive signs are present. Also, high doses of antibiotics specially aminoglycoside can play a role in the delayed healing from its toxicity to corneal epithelial cells membrane [19-20]. In our first two cases, the corneal scraping results may have retarded diagnosis and initiation of the correct treatment. Corneal samples guide the diagnosis with a sensitivity of 68% on a large series of infectious keratitis [21]. Thus, clinical examination is essential to determine the infectious or inflammatory origin of the infiltrate. Confocal microscopy was performed for each patient and gave an extra argument for the absence of an infection due to amebae and fungi with a sensibility of 85.7% and specificity of 81.4% [22, 23]. Once sterile keratitis was diagnosed, it was treated by applying three drops of dexamethasone (1 mg/ml) locally to the eye and gradually decreased over the course of three weeks. This led to resolution of the signs of inflammation within a few days, with the formation of a light avascular stromal scar at the end of treatment.

In conclusion, S-CXL is an effective procedure, but complications, such as sterile infiltrates, may occur. Careful selection of the patients undergoing this procedure is therefore required. Preventive action can also be taken. For example, patients with vernal keratoconjunctivitis or an atopic background should undergo treatment for their allergies before surgery and should receive local corticosteroid treatment after surgery. For patients with advanced keratoconus, precautions should be taken to prevent the formation of large scars likely to lead to a profound loss of vision, such as decreasing the time of UVA exposure or irradiance, to minimize endothelial exposure. An epi-on protocol might appear to be the most appropriate solution, but cases have been reported with such techniques. Nevertheless, surgeons should not be reticent to perform this procedure when indicated, because the frequency of complications is low and vision loss in cases of correct management.

Conflict of interest

The authors have no financial support or financial conflict of interest to declare.

References

1. Rabinowitz YS. Keratoconus. *Surv Ophthalmol.* 1998;42:297-319.
2. Tuori AJ, Virtanen I, Aine E, Kalluri R, Miner JH, Uusitalo HM. The immunohistochemical composition of corneal basement membrane in keratoconus. *Curr Eye Res.* 1997;16:792-801.
3. Wollensak G, Spoerl E, Seiler T. Riboflavin/ultraviolet-A-induced collagen crosslinking for the treatment of keratoconus. *Am J Ophthalmol.* 2003;135:620-7.
4. Ghanem RC, Santhiago MR, Berti T, Netto MV, Ghanem VC. Topographic, corneal wavefront, and refractive outcomes 2 years after collagen crosslinking for progressive keratoconus. *Cornea.* 2014;33:43-8.
5. Raiskup F, Theuring A, Pillunat LE, Spoerl E. Corneal collagen crosslinking with riboflavin and ultraviolet-A light in progressive keratoconus: ten-year results. *J Cataract Refract Surg.* 2015;41:41-6.
6. Ghanem VC, Ghanem RC, de Oliveira R. Postoperative pain after corneal collagen crosslinking. *Cornea.* 2013;32:20-4.
7. Koller T, Mrochen M, Seiler T. Complication and failure rates after corneal crosslinking. *J Cataract Refract Surg.* 2009;35:1358-62.
8. Arora R, Jain P, Gupta D, Goyal JL. Sterile keratitis after corneal collagen crosslinking in a child. *Contact Lens Anterior Eye J Br Contact Lens Assoc.* 2012;35:233-5.
9. Sharma N, Maharana P, Singh G, Titiyal JS. *Pseudomonas* keratitis after collagen crosslinking for keratoconus: case report and review of literature. *J Cataract Refract Surg.* 2010;36:517-20.

10. Ghanem RC, Netto MV, Ghanem VC, Santhiago MR, Wilson SE. Peripheral sterile corneal ring infiltrate after riboflavin-UVA collagen cross-linking in keratoconus. *Cornea*. 2012;31:702-5.
11. Lam FC, Geourgoudis P, Nanavaty MA, Khan S, Lake D. Sterile keratitis after combined riboflavin-UVA corneal collagen cross-linking for keratoconus. *Eye Lond Engl*. Nov 2014;28:1297-303.
12. Koppen C, Vryghem JC, Gobin L, Tassignon M-J. Keratitis and corneal scarring after UVA/riboflavin cross-linking for keratoconus. *J Refract Surg*. 2009;25:S819-823.
13. Kymionis GD, Bouzoukis DI, Diakonis VF, Portaliou DM, Pallikaris AI, Yoo SH. Diffuse lamellar keratitis after corneal crosslinking in a patient with post-laser *in situ* keratomileusis corneal ectasia. *J Cataract Refract Surg*. 2007;33:2135-7.
14. Rao SK, Fogla R, Rajagopal R, Sitalakshmi G, Padmanabhan P. Bilateral corneal infiltrates after excimer laser photorefractive keratectomy. *J Cataract Refract Surg*. 2000;26:456-9.
15. Al-Amry MA. Severe bilateral paralimbal sterile infiltrates after photorefractive keratectomy. *Middle East Afr J Ophthalmol*. 2014;21:83-5.
16. Schaefer F, Bruttin O, Zografos L, Guex-Crosier Y. Bacterial keratitis: a prospective clinical and microbiological study. *Br J Ophthalmol*. 2001;85:842-7.
17. Ly CN, Pham JN, Badenoch PR et al. Bacteria commonly isolated from keratitis specimens retain antibiotic susceptibility to fluoroquinolones and gentamicin plus cephalothin. *Clin Experiment Ophthalmol*. 2006;34:44-50.
18. Rodríguez-Ausín P, Gutiérrez-Ortega R, Arance-Gil A, Romero-Jimenez M, Fuentes-Páez G. Keratopathy after cross-linking for keratoconus. *Cornea*. 2011;30:1051-3.
19. Matsumoto S, Stern ME. Effect of anti-infective ophthalmic solutions on corneal cells in vitro. *Adv Ther*. 2000;17:148-51.

- 20.** Alfonso EC, Albert DM, Kenyon KR, Robinson NL, Hanninen L, D'Amico DJ. In vitro toxicity of gentamicin to corneal epithelial cells. *Cornea*. 1990;9:55-61.
- 21.** Yeh DL, Stinnett SS, Afshari NA. Analysis of bacterial cultures in infectious keratitis, 1997 to 2004. *Am J Ophthalmol*. 2006;142:1066-8.
- 22.** Goh JWY, Harrison R, Hau S, Alexander CL, Tole DM, Avadhanam VS. Comparison of In Vivo Confocal Microscopy, PCR and Culture of Corneal Scrapes in the Diagnosis of Acanthamoeba Keratitis. *Cornea*. 2018;37:480-5.
- 23.** Chidambaram JD, Prajna NV, Larke N, Macleod D, Srikanthi P, Lanjewar S, et al. In vivo confocal microscopy appearance of Fusarium and Aspergillus species in fungal keratitis. *Br J Ophthalmol*. 2017;101:1119-23.

Table 1: S-CXL Methods

Treatment target	Ectasia
Fluence (total) (J/cm ²)	5.4
Soak time and interval (minutes)	30
Intensity	3
Treatment time (minutes)	30
Epithelium status	Off
Chromophore	Riboflavin
Chromophore carrier	Dextran
Chromophore osmolality	Iso-osmolar
Chromophore concentration	0.1%
Light source	Sooft
Irradiation mode (interval)	Continuous
Protocol abbreviation in manuscript	S-CXL

Table 2: sterile infiltrate vs infected infiltrate

	Sterile infiltrate	Infected infiltrate
Delay	24-48h	>48h
Fluorescein	Not matching with infiltrate	Matching with infiltrate
Intensity inflammatory signs	Straight high	Gradually growing
Corticosteroids	efficiency	No efficiency
Visual acuity	Good recuperation	Sequelae

Figure legends

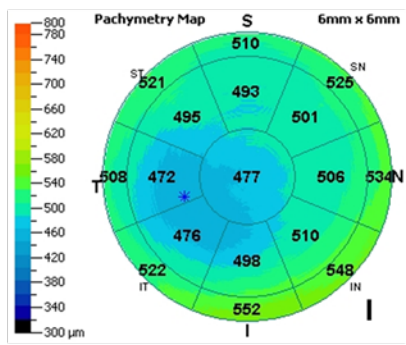
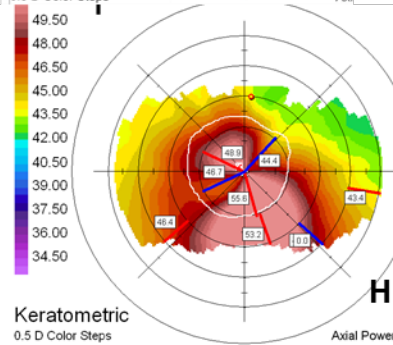
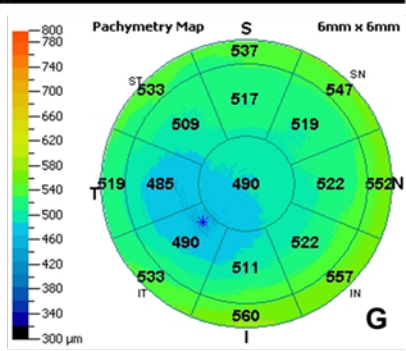
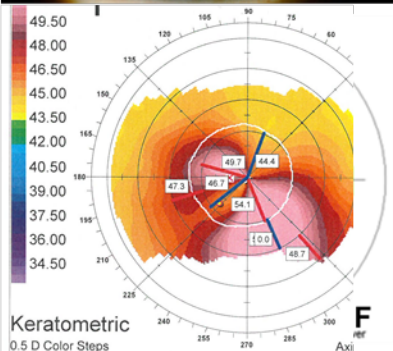
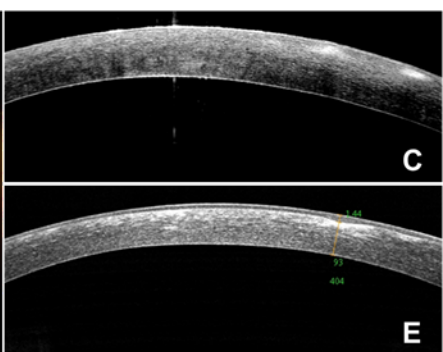
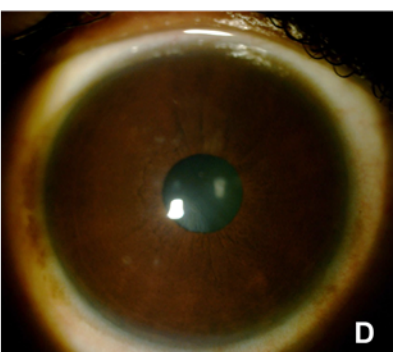
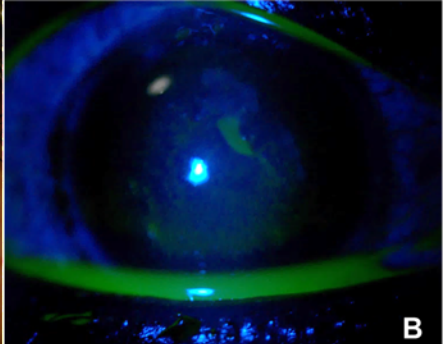
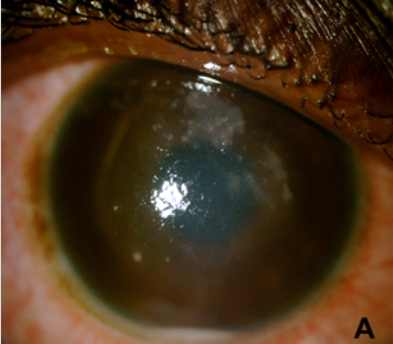
Figure 1. (A, B) 48 hours post-S-CXL, multiple fluorescein-negative corneal stromal paracentral infiltrates associated with anterior chamber reactions, keratic precipitates and a 1 mm hypopyon on slit-lamp examination. (C) 48 hours post S-CXL, SA-OCT showing that only the anterior stroma is affected. (D) Six months after treatment, small opacities are visible in the anterior stroma on slit-lamp examination. (E) Six months after treatment, hyperreflectivity is evident in the anterior stroma on SA-OCT. (F, G) Orbscan topography and pachymetry SA-OCT before surgery. The Kmax is 50.2 D and the minimum pachymetry is 468 μm . (H, I) Orbscan topography and pachymetry SA-OCT six months after S-CXL, with a Kmax of 51.9 D and a minimum pachymetry of 457 μm .

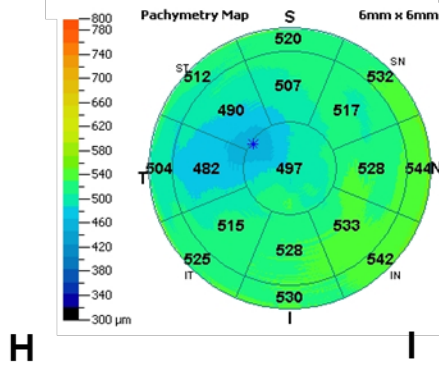
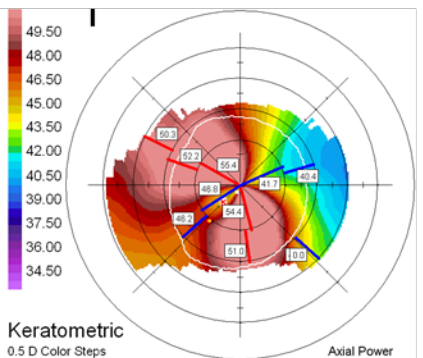
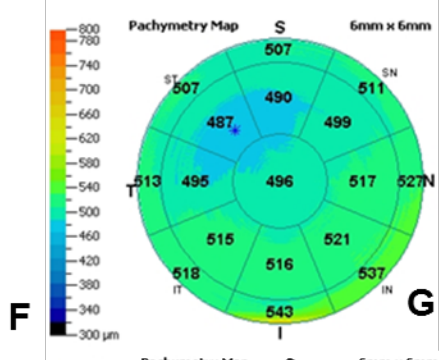
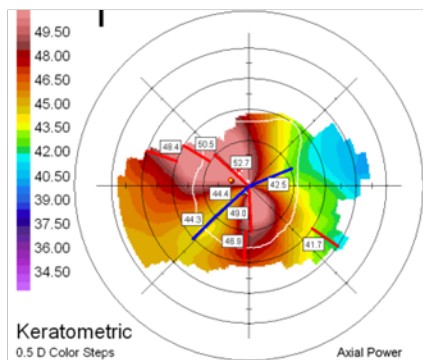
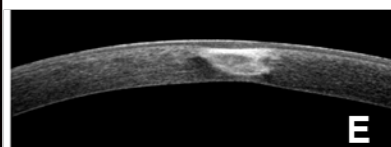
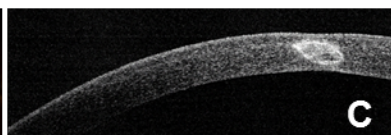
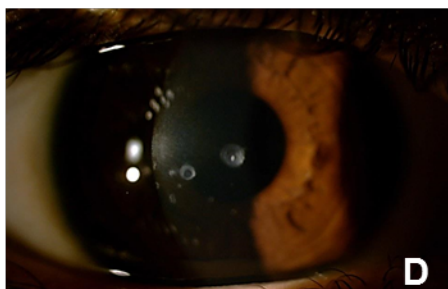
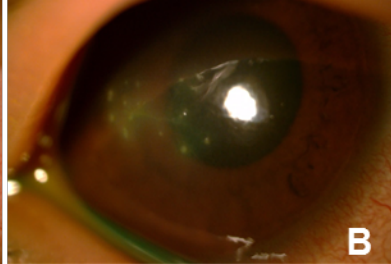
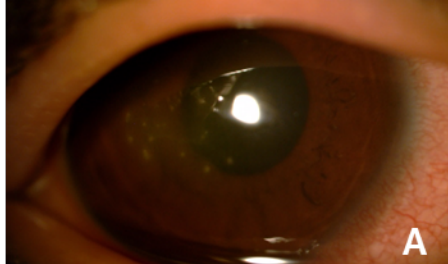
Figure 2. (A, B) 48 hours post S-CXL, submillimeter infiltrates in the center of the subepithelium, with superficial punctate keratitis on slit-lamp examination. (C) SA-OCT shows well-delimited subepithelial hyperreflectivity. (D) Six months after treatment, a paracentral avascular stromal scar is visible on slit-lamp examination. (E) Six months after treatment, less well-delimited stromal hyperreflectivity can be seen, with corneal thinning. (F, G) Orbscan topography and pachymetry SA-OCT before S-CXL, with a Kmax of 51.7 D and a minimum pachymetry of 479 μm . (H, I) Orbscan topography and pachymetry SA-OCT six months after S-CXL, with a Kmax of 54.9 D and a minimum pachymetry of 460 μm .

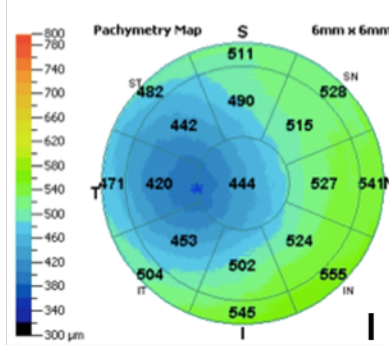
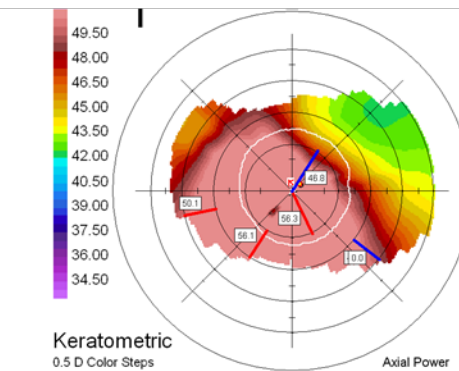
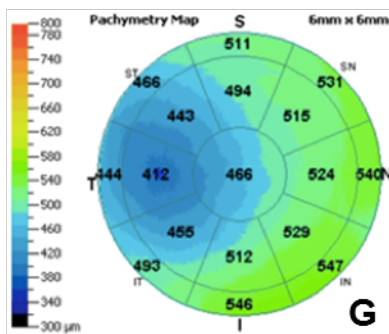
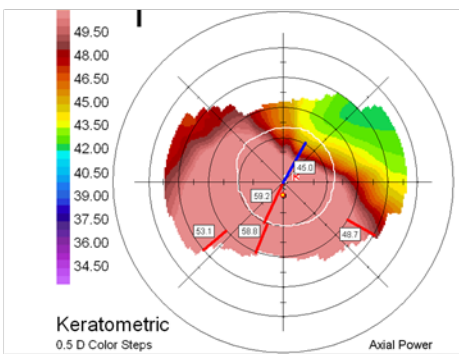
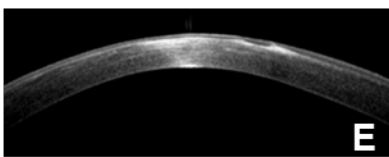
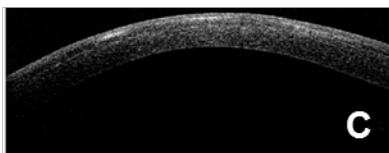
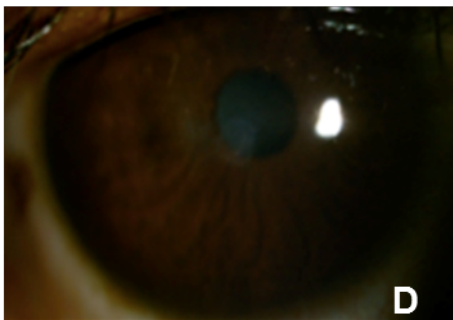
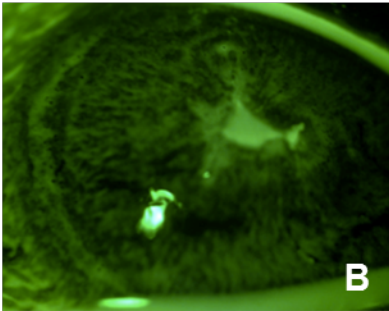
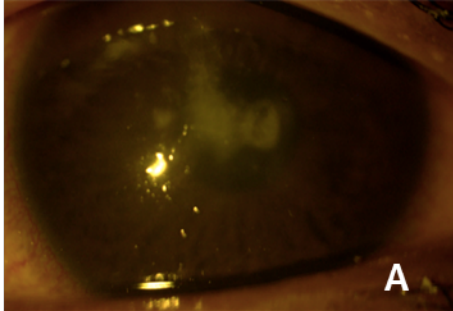
Figure 3. (A, B) 48 hours post-S-CXL, a fluorescein-positive central corneal infiltrate of 1.5 millimeters in diameter is visible on slit-lamp examination. (C) SA-OCT shows that only the anterior stroma is affected. (D) Six months after treatment, a light avascular stromal scar is visible on slit-lamp examination. (E) On SA-OCT six months after treatment, hyperreflectivity corresponding to fibrosis is visible in all stromal layers. (F, G) Orbscan

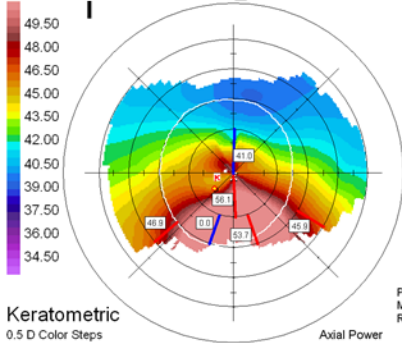
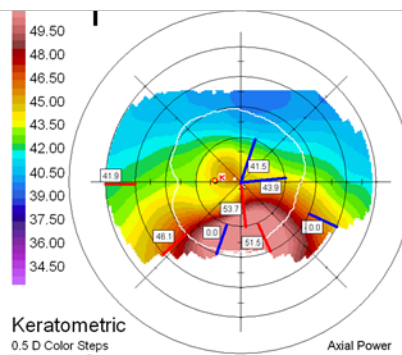
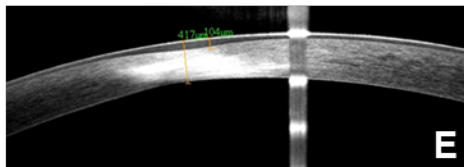
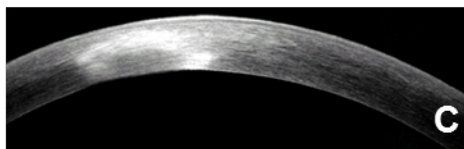
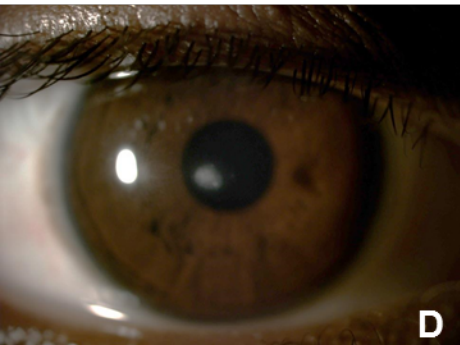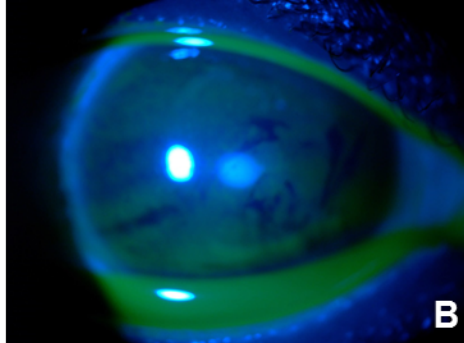
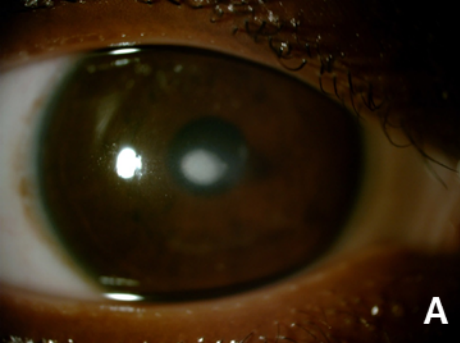topography and pachymetry SA-OCT before S-CXL, with a Kmax of 57.9D and a minimum pachymetry of 402 μm . (H, I) Orbscan topography and pachymetry SA-OCT six months after S-CXL, with a decrease in Kmax to 55.1D, probably due to fibrosis, and a minimum pachymetry of 394 μm .

Figure 4. (A, B) 7 days post-S-CXL, stromal infiltrate, with a corneal edema and no epithelial defect on the slit-lamp examination. (C) SA-OCT shows that layers of the stroma are affected. (D) Six months after treatment, an avascular paracentral stromal scar is evident. (E) Six months after treatment, SA-OCT shows a hyperreflectivity of all the stromal layers, with a flattening and thinning of the cornea. (F, G) Orbscan topography and pachymetry SA-OCT before S-CXL, with a Kmax of 547.8 D and a minimum pachymetry of 449 μm . (H, I) Orbscan topography and pachymetry SA-OCT six months after S-CXL, with a Kmax of 46.1 D and a minimum pachymetry of 406 μm .

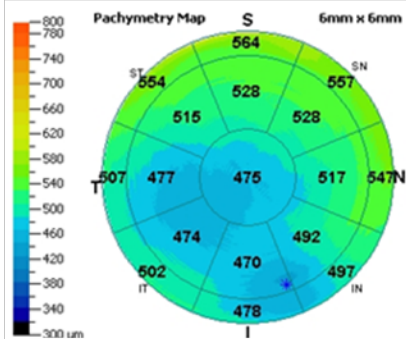






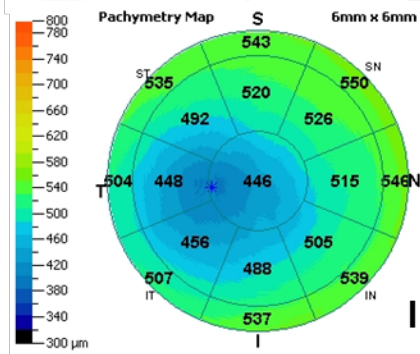


F



G

H



I