



**HAL**  
open science

## ***Veillonella parvula* spondylodiscitis**

H. Gouze, L. Noussair, I. Padovano, E. Salomon, M. de Laroche, C. Duran, A. Felter, R. Carlier, M. Breban, A. Dinh

► **To cite this version:**

H. Gouze, L. Noussair, I. Padovano, E. Salomon, M. de Laroche, et al.. *Veillonella parvula* spondylodiscitis. *Médecine et Maladies Infectieuses*, 2019, 49, pp.54 - 58. 10.1016/j.medmal.2018.10.001 . hal-03486836

**HAL Id: hal-03486836**

**<https://hal.science/hal-03486836>**

Submitted on 20 Dec 2021

**HAL** is a multi-disciplinary open access archive for the deposit and dissemination of scientific research documents, whether they are published or not. The documents may come from teaching and research institutions in France or abroad, or from public or private research centers.

L'archive ouverte pluridisciplinaire **HAL**, est destinée au dépôt et à la diffusion de documents scientifiques de niveau recherche, publiés ou non, émanant des établissements d'enseignement et de recherche français ou étrangers, des laboratoires publics ou privés.



Distributed under a Creative Commons Attribution - NonCommercial 4.0 International License

## **Spondylodiscite à *Veillonella parvula***

### ***Veillonella parvula* spondylodiscitis**

Hélène Gouze<sup>1,2</sup>, Ilaria Padovano<sup>2</sup>, Elsa Salomon<sup>3</sup>, Marine de Laroche<sup>1</sup>, Clara Duran<sup>1</sup>, Adrien Felter<sup>4</sup>, Robert Carlier<sup>4</sup>, Maxime Breban<sup>2</sup>, Aurélien Dinh<sup>1</sup>

<sup>1</sup> Unité de maladies infectieuses, CHU Ambroise Paré, UVSQ, AP-HP, Boulogne-Billancourt, France

<sup>2</sup> Département de Rhumatologie, CHU Ambroise Paré, UVSQ, AP-HP, Boulogne-Billancourt, France

<sup>3</sup> Laboratoire de Microbiologie, CHU Ambroise Paré, UVSQ, AP-HP, Boulogne-Billancourt, France

<sup>4</sup> Département de Radiologie, CHU Ambroise Paré, UVSQ, AP-HP, Boulogne-Billancourt, France

#### **Corresponding author**

Aurélien Dinh

Email address: aurelien.dinh@aphp.fr

Phone number: +33 1 47 10 44 32

Fax: +33 1 47 10 77 90

**Mots clés :** spondylodiscite, *Veillonella*, *Veillonella parvula*

**Keywords:** spondylodiscitis, *Veillonella*, *Veillonella parvula*

## Résumé

**Objectifs.** *Veillonella parvula* est un micro-organisme anaérobie type Gram-négatif, rarement impliqué dans les infections ostéoarticulaires.

**Patients et méthodes.** Nous rapportons le cas d'une spondylodiscite à *Veillonella parvula* chez une patiente sans facteur de risque et présentons une revue de la littérature des infections ostéoarticulaires à *Veillonella*.

**Résultats.** La ponction biopsie disco-vertébrale réalisée a objectivé la présence de *Veillonella*. Dans la littérature, les spondylodiscites infectieuses (SDI) à *Veillonella* sont rares et surviennent essentiellement chez les patients immunodéprimés. La durée d'évolution des symptômes peut aller jusqu'à quatre mois. La fièvre est souvent absente. Le traitement médical seul était suffisant dans la moitié des cas.

**Conclusions.** Les SDI à *Veillonella* peuvent survenir chez des patients non immunodéprimés et se présenter comme des affections mécaniques.

## **Abstract**

**Objectives.** *Veillonella parvula* is an anaerobic Gram-negative coccus rarely involved in bone and joint infections.

**Patients and method.** We report the case of a *Veillonella parvula* vertebral osteomyelitis (VO) in a female patient without any risk factor.

**Results.** The 35-year-old patient was immunocompetent and presented with *Veillonella parvula* VO. She was admitted to hospital for inflammatory lower back pain. The discovertebral sample was positive for *Veillonella parvula*. Literature data on *Veillonella* VO is scarce. Reported cases usually occurred in immunocompromised patients. Diagnosis delay can be up to four months. Patients are usually afebrile. Outcome with antimicrobial treatment alone is favorable in half of cases. Other patients must undergo surgery.

**Conclusions.** *Veillonella* VO may occur in immunocompetent patients and have a clinical spectrum of mechanical lower back pain.

## Introduction

*Veillonella parvula* is an anaerobic Gram-negative coccus found in the normal human flora as part of the oral biofilm. *Veillonella* species are considered commensal microorganisms but have been occasionally reported as responsible for infections in humans, especially in immunocompromised patients [1]. We report a rare case of spondylodiscitis due to *Veillonella parvula* in a 35-year-old immunocompetent woman without any known risk factors.

## Case presentation

A 35-year-old woman was admitted to the Rheumatology department for morphine-resistant mechanical lower back pain. Her symptoms had been slowly worsening for five months, lacking typical inflammatory features such as nocturnal awakening or morning stiffness, and were not relieved by morphine intake. The patient was afebrile and did not present any other complaint. She had no significant medical history, except for obesity with a body mass index of 34 (weight: 94 kg, height: 1.68 m).

The physical examination revealed lumbar pain at pressure (visual analogue scale of 7/10) and stiffness at mobilization (but negative Lasègue's and Léri's signs, Schober's test of 10+3 cm). The neurological examination, including sensory/motor/sphincter function, and reflex examination were normal. There was no heart murmur.

Blood tests showed an elevated C-reactive protein level of 77 mg/L, reduced hemoglobin level of 10 g/dL, and normal leukocyte count (9.3 G/L).

Lumbar spine x-rays were normal. The initially suspected diagnosis was inflammatory lumbar discopathy.

As non-steroidal anti-inflammatory drugs (NSAID) and corticosteroid treatments were inefficient on pain, magnetic resonance imaging (MRI) was performed and showed typical features of spondylodiscitis: fluid signal of the disk, bone edema of vertebral endplates and vertebral body (hypointense T1 signal, hyperintense T2 fat-sat signal with marked gadolinium enhancement), gadolinium enhancement of perivertebral soft tissues and epiduritis (enhancement of the anterior epidural space). No abscess of soft tissues was observed (Figure 1).

Given the suspicion of infectious spondylodiscitis, a vertebral biopsy using fluoroscopy was performed and two samples of each vertebral endplates and one sample of the disk were obtained.

Vertebral biopsy specimens were sent for microbiological analysis and were processed with continuously monitored broth enrichment. Samples were topped with sterile distilled water and beadmilled for 150 seconds on a Retsch MM300 system (Verder, France) with stainless steel beads. The resulting suspension was plated on Columbia agar medium with 5% sheep blood and incubated for five days at 36°C in aerobic and anaerobic conditions, and 6 mL were injected in Bactec Peds Plus/F and Lytic/10 Anaerobic/F blood culture vials for 14 days in a Bactec FX automated blood culture system (BD Diagnostics, Le Pont de Claies, France). Growth was detected on anaerobic blood agar plates on Day 2, with translucent small colonies. All samples yielded positive cultures for Gram-negative cocci. The cocci were identified by mass spectrometry (Biotyper v3.1 on a Microflex LT, Bruker Daltonics, Bremen, Germany) as *Veillonella parvula* with a score of 2.35, and later confirmed by 16S rRNA gene

sequencing using previously described primers [2]. Antimicrobial susceptibility testing by agar disk diffusion method (Bio-Rad, Marnes-la-Coquette, France) using the French microbiology society 2013 guidelines (French acronym CA-SFM), showed susceptibility to amoxicillin, cefotaxime, rifampicin, fluoroquinolones, clindamycin, and metronidazole and resistance to amikacin and macrolides. Four of the five disco-vertebral samples tested positive for *Veillonella parvula*. Blood cultures were all negative.

The primary site of infection seemed to be dental: two infected teeth were observed with chronic pulpitis and apical cyst, without gingivitis. Thoraco-abdominal-pelvic tomography showed no other infection site but confirmed an impairment of L4 and L5 vertebrae with mirror-like erosions (Figure 2). The echocardiography was normal, with no sign of infective endocarditis. No biological evidence for immunosuppression was observed: leukocyte immune-phenotyping, and serum protein electrophoresis were normal; HIV and hepatitis B and C serologies were negative.

The patient first received an empirical intravenous treatment with ceftriaxone 2 g daily and metronidazole 500 mg every 8 hours for two days. Following antimicrobial susceptibility test results, the antibiotic therapy was switched for oral antibiotic therapy with amoxicillin 10 g daily for six weeks. The patient was also immobilized with a lumbar corset.

The clinical outcome was favorable. The C-reactive protein level was negative after two weeks of treatment, and the control imaging at three months showed signs of favorable outcome: osteosclerosis of vertebral endplate, narrowed disk, and the beginning of a spinal fusion (Figure 2). No surgery or drainage was required.

The patient was considered cured 12 months after treatment completion. She presented with mild residual lumbar pain, but without any fever and the C-reactive protein level was negative. The control MRI only showed sequelae of the spondylodiscitis.

## Discussion

*Veillonella* spp. are anaerobic micro-organisms, Gram-negative cocci, usually found in the oral, gastrointestinal, and genito-urinary tracts of humans. Six species of *Veillonella* have been described: *Veillonella alcalescens*, *Veillonella atypica*, *Veillonella dispar*, *Veillonella parvula*, *Acidaminococcus fermentans*, and *Megasphaera elsdenii*. *Veillonella parvula* is the most frequently identified subtype. Its pathogenicity is not clearly established as it accounts for approximately 5% of the commensal oral flora, but it is hardly ever responsible for infections [1, 2]. It is cultivated at a temperature of 30°C to 37°C in anaerobic culture media. Determination of the subtype requires analysis of PCR-amplified 16S ribosomal DNA.

Most reported cases focus on immunocompromised patients. As only a few cases of *Veillonella* infections have been reported, the prevalence is difficult to compute. Cases of meningitis, endocarditis, bacteremia, pulmonary infections, orchiepididymitis, osteomyelitis, and hip infection have been reported [3–5].

Less than 10 cases of spinal infections have been reported (Table 1) [1, 6–12]. The age of patients ranged from 27 to 76 years, consistent with the usual median age for spondylodiscitis of 69 years [13]. Pain duration ranged from 1 week to 4 months, consistent with a usual diagnostic delay of two months [14]. Patients had few symptoms other than back pain. They had no fever and were thus often initially misdiagnosed despite being



usually described for pyogenic spondylodiscitis [15]. Three patients were immunosuppressed [1, 9, 11]. Associated diseases were cancer (n=1), autoimmune diseases (n=1), esophageal rupture (n=1), rectal biopsy (n=1), and one case of carious dentition in a 74-year-old man. Only one case involved the cervical spine; all other cases involved lumbar infections. Patients recovered with antibiotics alone in half of cases; the other half required associated spinal surgery. Antibiotics were penicillin (n=1), amoxicillin (n=2), amoxicillin/clavulanic acid (n=1), cefoxitin (n=1), ceftriaxone (n=1), or cefotaxime (n=1), two of which (amoxicillin/clavulanic acid and cefotaxime) combined with metronidazole. Treatment durations ranged from 6 to 11 weeks [16]. *Veillonella parvula* was the most frequently described subtype as it was identified in five of the reported cases [1, 7, 10, 11].

*Veillonella* sp. is one of the most prevalent species in the oral microbiome. Its main characteristic is its ability to ferment sugar and use lactic acid as a carbon source, thus contributing to the formation of oral biofilm [2]. *Veillonella parvula* is thus frequently involved in early parodontal disease and in dental impairment. Many studies reported an association between *Veillonella* spp. and dental caries [17]. These studies suggested that *Veillonella* spp. played a major role in endodontic infections, and more precisely at infection onset. The spondylodiscitis of our patient was concomitant to endodontic failure onset [18].

Less than 10 cases of *Veillonella* spinal infections have been described. This type of infection seems very rare in immunocompetent patients. Physicians must therefore be reminded that dental infections may be a portal of entry for bacteremia and/or deep infections.

## **Conclusion**

In case of severe pain with suspicion of inflammatory vertebral lesion, a disco vertebral puncture should be performed – even in young obese patients with no sign of infection – to rule out spondylodiscitis.

#### **Declaration of interest**

The authors declare no competing interests.

#### **Contribution of authors**

HG, IP, CD, MB, and AD substantially contributed to the conception of the work, the acquisition, analysis, and interpretation of data, and to drafting and critically revising the work. AF, RC, EL, and ML substantially contributed to drafting and critically revising the work. All authors approved the final version to be published and agree to be accountable for all aspects of the work.

## References

1. Chen Y-C, Ko P-H, Yang C-J, Chen Y-C, Lay C-J, Tsai C-C, et al. Epidural abscess caused by *Veillonella parvula*: Case report and review of the literature. *J Microbiol Immunol Infect*. 2016 Oct;49(5):804–8.
2. Mashima I, Nakazawa F. Interaction between *Streptococcus* spp. and *Veillonella tobetsuensis* in the Early Stages of Oral Biofilm Formation. O'Toole GA, editor. *J Bacteriol*. 2015 Jul 1;197(13):2104–11.
3. Zaninetti-Schaerer A, Van Delden C, Genevay S, Gabay C. Total hip prosthetic joint infection due to *Veillonella* species. *Joint Bone Spine*. 2004 Apr;71(2):161–3.
4. Al-Otaibi FE, Al-Mohizea MM. Non-vertebral *Veillonella* species septicemia and osteomyelitis in a patient with diabetes: a case report and review of the literature. *J Med Case Reports* [Internet]. 2014 Dec [cited 2017 Apr 25];8(1). Available from: <http://jmedicalcasereports.biomedcentral.com/articles/10.1186/1752-1947-8-365>
5. Borchardt KA, Baker M, Gelber R. *Veillonella parvula* septicemia and osteomyelitis. *Ann Intern Med*. 1977 Jan;86(1):63–4.
6. Kishen TJ, Lindstrom ST, Etherington G, Diwan AD. *Veillonella* spondylodiscitis in a healthy 76-year-old lady. *Eur Spine J*. 2012 Jun;21(S4):413–7.
7. Marriott D, Stark D, Harkness J. *Veillonella parvula* Discitis and Secondary Bacteremia: a Rare Infection Complicating Endoscopy and Colonoscopy? *J Clin Microbiol*. 2007 Feb 1;45(2):672–4.

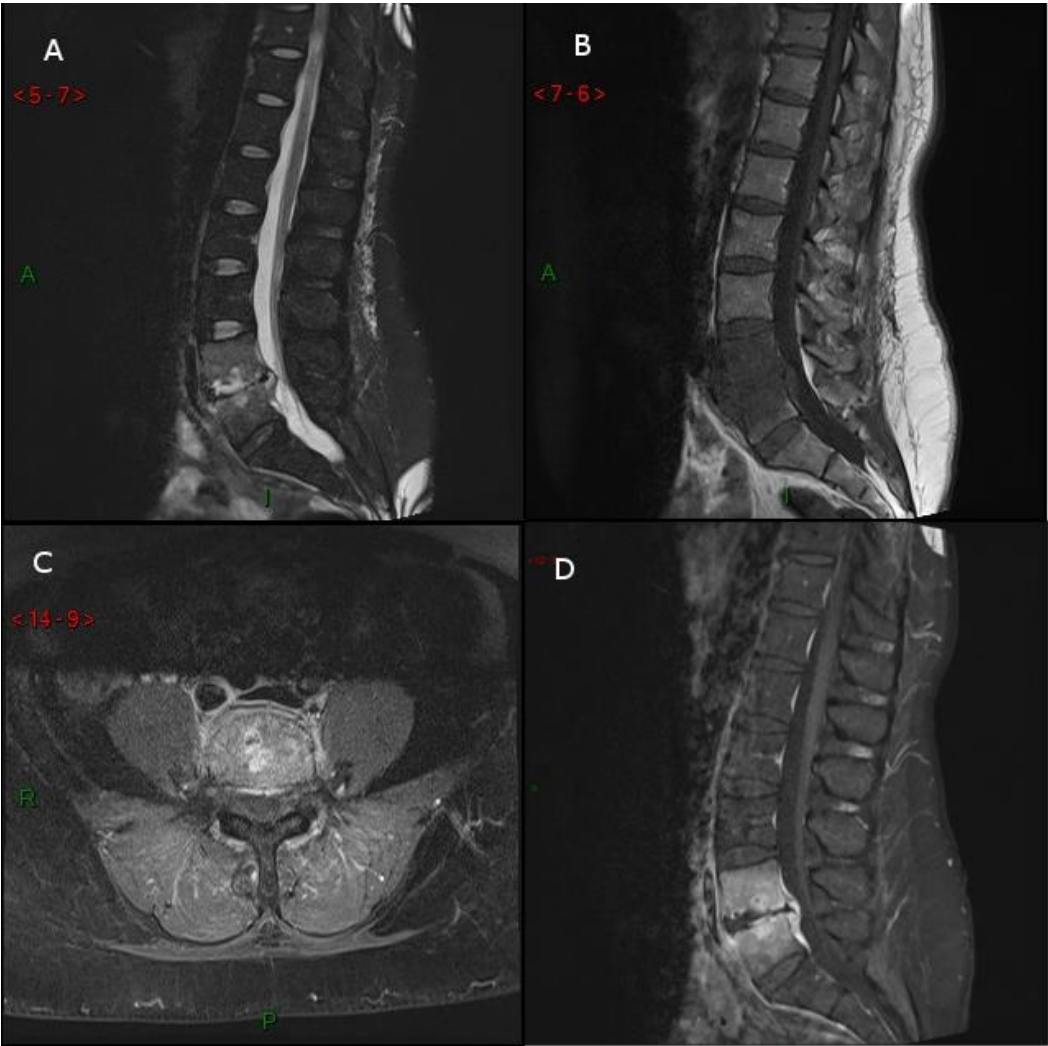
8. Isner-Horobeti M-E, Lecocq J, Dupeyron A, De Martino SJ, Froehlig P, Vautravers P. Veillonella discitis. A case report. *Jt Bone Spine Rev Rhum*. 2006 Jan;73(1):113–5.
9. Barnhart RA, Weitekamp MR, Aber RC. Osteomyelitis caused by Veillonella. *Am J Med*. 1983 May;74(5):902–4.
10. Bongaerts GPA, Schreurs BW, Lunel FV, Lemmens JAM, Pruszczynski M, Merkx MAW. Was isolation of Veillonella from spinal osteomyelitis possible due to poor tissue perfusion? *Med Hypotheses*. 2004 Jan;63(4):659–61.
11. Singh N, Yu VL. Osteomyelitis due to Veillonella parvula: case report and review. *Clin Infect Dis Off Publ Infect Dis Soc Am*. 1992 Jan;14(1):361–3.
12. Hidalgo C, Piédrola G, Guzmán M, Jiménez-Alonso JF. [Backache in a 70-yr-old man]. *Enferm Infecc Microbiol Clin*. 2000 May;18(5):241–2.
13. Grammatico L, Baron S, Rusch E, Lepage B, Surer N, Desenclos JC, et al. Epidemiology of vertebral osteomyelitis (VO) in France: analysis of hospital-discharge data 2002-2003. *Epidemiol Infect*. 2008 May;136(5):653–60.
14. Jean M, Irisson J-O, Gras G, Bouchand F, Simo D, Duran C, et al. Diagnostic delay of pyogenic vertebral osteomyelitis and its associated factors. *Scand J Rheumatol*. 2017 Jan;46(1):64–8.
15. Bernard L, Dinh A, Ghout I, Simo D, Zeller V, Issartel B, et al. Antibiotic treatment for 6 weeks versus 12 weeks in patients with pyogenic vertebral osteomyelitis: an open-label, non-inferiority, randomised, controlled trial. *Lancet Lond Engl*. 2015 Mar 7;385(9971):875–82.

16. Libertin CR, Peterson JH, Brodersen MP, Huff T. A Case of Penicillin-Resistant *Veillonella* Prosthetic Joint Infection of the Knee. *Case Rep Orthop*. 2016;2016:1–5.
17. Arif N, Sheehy EC, Do T, Beighton D. Diversity of *Veillonella* spp. from Sound and Carious Sites in Children. *J Dent Res*. 2008 Mar;87(3):278–82.
18. Sundqvist G. Associations between microbial species in dental root canal infections. *Oral Microbiol Immunol*. 1992 Oct;7(5):257–62.

**Figure 1.** IRM du rachis lombaire

**Figure 1.** MRI of the lumbar spine

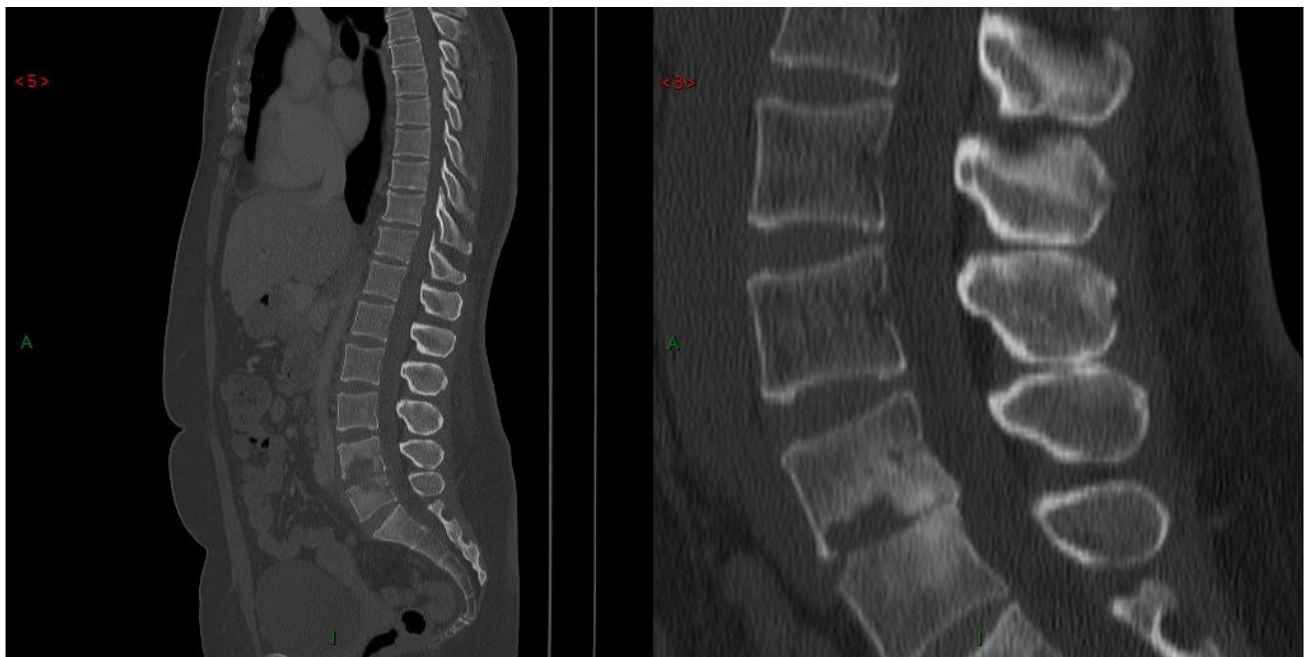MRI aspect at the diagnosis of L4-L5 spondylodiscitis. A: hypersignal of vertebral endplates on sagittal T2 image. B: hyposignal on sagittal T1 image. C: enhancement of perivertebral tissues in axial L4-L5 centered image after gadolinium injection. D: sagittal image after gadolinium injection.



**Figure 2.** TDM du rachis lombaire

**Figure 2.** Lumbar spine CT scan

Left image: mirror-like erosions of the L4 and L5 vertebrae endplates at diagnosis. Right image: CT scan aspect 3 months after the antibiotic therapy showing signs of scarring: osteosclerosis of vertebral endplates, narrowed disk, and the beginning of a spinal fusion.



**Tableau 1.** Cas cliniques d'infections ostéoarticulaires à *Veillonella* spp.

**Table 1.** Reported cases of *Veillonella* bone and joint infections

Cases	Age (years)/sex	Predisposing factors	Diagnosis	Symptoms /duration	Bacteriologic al diagnosis	Bacterial identification	Antibiotic therapy	Surgery
<b>1 Kishen, 2012, [6]</b>	76/F	None	Spondylodiscitis (L1-L2)	Back pain/3 weeks	Blood/tissue	<i>Veillonella</i> spp.	cefotaxime + metronidazole 4 weeks then amoxicillin/clavulanic acid + metronidazole 6 weeks	Yes
<b>2 Marriott,</b>	55/M	Rectal biopsy	Spondylodiscitis (L2-L3)	Back pain/3 months	Blood/tissue	<i>Veillonella parvula</i>	ceftriaxone 6 weeks then	No



<b>2007, [7]</b>							amoxicillin/cla		
							vulanic acid 6		
							weeks		
<b>3</b>	27/M	None	Spondylodiscitis	Back pain/2	Tissue	<i>Veillonella</i>	amoxicillin 11	No	
<b>Isner-</b>			(L4-L5)	months		spp.	weeks		
<b>Horobeti,</b>									
<b>2006, [8]</b>									
<b>4</b>	31/M	Esophageal	Spondylodiscitis	Back pain/3	Tissue	<i>Veillonella</i>	penicillin 6	Yes	
<b>Barnhart,</b>		rupture	(cervical spine)	weeks		spp.	weeks		
<b>1983, [9]</b>									
<b>5</b>	74/M	Dental caries	Spondylodiscitis	Neck pain,	Tissue	<i>Veillonella</i>	penicillin 6	No	
<b>Bongaerts,</b>			(T12-L1)	odynophagia / 3		<i>parvula</i>	weeks		
<b>2004, [10]</b>				days					
<b>6</b>	61/F	Rheumatoid	Spondylodiscitis	Back pain/4	Blood/tissue	<i>Veillonella</i>	ceftriaxone 6	Yes	

<b>Singh, 1992, [11]</b>		arthritis and Sjogren's disease	(L5-S1)	months		<i>parvula</i>	weeks	
<b>7</b>	70/M	None	Spondylodiscitis	Back pain/1	Tissue	<i>Veillonella</i>	Unknown	No
<b>Hidalgo, 2000, [12]</b>			(L3-L4)	month		spp.		
<b>8</b>	68/M	Sinus sarcoma	Spondylodiscitis	Back pain/3	Blood/pus	<i>Veillonella</i>	amoxicillin/cla	Yes
<b>Chen, 2014, [1]</b>			(L1-L2)	weeks		<i>parvula</i>	vulanic acid 6 weeks	
<b>9</b>	35/F	Obesity	Spondylodiscitis	Back pain/5	Tissue	<i>Veillonella</i>	amoxicillin 6	No
<b>Present case</b>		Tooth infection	(L4-L5)	months		<i>parvula</i>	weeks	
<b>Total</b>	Median age: 61	Immunocompromised: 3/9	Lumbar spine localization: 8/9	Median symptom duration: 1 month	Diagnostic samples: 4/9	Identification of <i>Veillonella parvula</i> : 5/9	Antibiotic prescription: penicillin n= 5/8	Surgery: 4/9

ratio

Tissue : 9/9

cephalosporin

F:H: 3:6

n= 3/8

Median

duration: 6

weeks

F: female, M: male