



HAL
open science

Topical use of mammalian target of rapamycin inhibitors in dermatology: A systematic review with meta-analysis

Sophie Leducq, Bruno Giraudeau, Elsa Tavernier, Annabel Maruani

► To cite this version:

Sophie Leducq, Bruno Giraudeau, Elsa Tavernier, Annabel Maruani. Topical use of mammalian target of rapamycin inhibitors in dermatology: A systematic review with meta-analysis. *Journal of The American Academy of Dermatology*, 2019, 80, pp.735 - 742. 10.1016/j.jaad.2018.10.070 . hal-03486726

HAL Id: hal-03486726

<https://hal.science/hal-03486726v1>

Submitted on 20 Dec 2021

HAL is a multi-disciplinary open access archive for the deposit and dissemination of scientific research documents, whether they are published or not. The documents may come from teaching and research institutions in France or abroad, or from public or private research centers.

L'archive ouverte pluridisciplinaire **HAL**, est destinée au dépôt et à la diffusion de documents scientifiques de niveau recherche, publiés ou non, émanant des établissements d'enseignement et de recherche français ou étrangers, des laboratoires publics ou privés.



Distributed under a Creative Commons Attribution - NonCommercial 4.0 International License

TITLE PAGE

Article type: Original article

Title: Topical use of mammalian target of rapamycin inhibitors in dermatology: a systematic review with meta-analysis

Sophie Leducq^{1,2}, MD; Bruno Giraudeau^{1,3}, PhD; Elsa Tavernier^{1,3}, PhD; Annabel Maruani^{1,2}, MD, PhD

¹Universities of Tours and Nantes, INSERM 1246 – SPHERE, 37000 Tours, France

²Department of Dermatology and Reference Center for Rare Diseases and Vascular Malformations (MAGEC), CHRU Tours, 37044 Tours Cedex 9, France

³Clinical Investigation Center, INSERM 1415, CHRU Tours, 37000 Tours, France

Corresponding author

Dr Sophie Leducq, Department of Dermatology, CHRU Tours, Avenue de la République, 37044 Tours Cedex 9, France

Tel: +33 2 47 47 90 80

Fax: +33 2 47 47 82 47

Email: soleducq@gmail.com

Funding sources: None

Conflicts of Interest: None declared

Manuscript word count: 1976

Abstract word count: 200

Capsule summary word count: 50

References: 49

Figures: 3

Tables: 1

Attachments: PRISMA checklist

Key words: mTOR inhibitor, rapamycin, sirolimus, topical, systematic review, dermatology

ABSTRACT

Background: Systemic mammalian target of rapamycin (mTOR) inhibitors are currently used in many dermatological indications. Their topical use is recent and poorly codified.

Objective: To provide an overview of the topical use of mTOR inhibitors in dermatologic conditions and to evaluate efficacy and safety.

Methods: A literature search was performed in January 2017. Reports of all studies investigating the use of topical mTOR inhibitors in any dermatology diseases were included. Exclusion criteria were systemic use and mucosal administration.

Results: We included 40 studies with a total of 262 patients. Eleven dermatologic conditions were found, the most frequent being angiofibromas linked to tuberous sclerosis complex (TSC) (157 patients). Topical mTOR inhibitors were significantly more efficient than placebo for angiofibromas (RR, 2.52, 95% CI [1.27; 5.00]; $I^2 = 0\%$). The median concentration of sirolimus was 0.1%, with a median treatment duration of 12 weeks. Topical mTOR inhibitors were well tolerated, with only mild or moderate local side effects reported, mostly irritative. Sirolimus blood level was not detected in 90% patients.

Limitations: High heterogeneity in most studies.

Conclusion: This systematic review supports the efficacy of topical sirolimus for angiofibromas linked to TSC, with only local side effects reported. Other indications require further research.

CAPSULE SUMMARY

- Topical use of mammalian target of rapamycin inhibitors is recent and poorly codified.
- This meta-analysis supports the efficacy of topical sirolimus in adults and children for facial angiofibromas linked to tuberous sclerosis complex. Only local adverse effects were reported, mostly irritative, and no significant blood level of sirolimus was found.

Body of manuscript

INTRODUCTION

Mammalian target of rapamycin (mTOR) inhibitors are systemic drugs used in various conditions. mTOR is a serine/threonine protein kinase that belongs to the phosphoinositide-3 kinase (PI3K)-related kinase family. It is a catalytic subunit of two biochemically distinct complexes called mTORC1 and mTORC2. mTORC1 controls cell autonomous growth in response to nutrient availability and growth factors, whereas mTORC2 mediates cell proliferation and cell survival.¹ mTOR inhibitors include sirolimus (also called rapamycin), which was first developed in the 1990s, and rapalogs such as everolimus, temsirolimus and deforolimus. Sirolimus is currently approved by the US Food and Drug Administration for preventing allograft rejection in renal transplantation.² It is also used to treat renal and brain tumors linked to tuberous sclerosis complex (TSC).³ Rapalogs are mainly used in therapies for various cancers.⁴

Oral sirolimus is increasingly used in dermatologic conditions, especially vascular tumors and complicated vascular malformations, because of its antiproliferative and anti-angiogenic and -lymphangiogenic properties.^{5,6} Topical sirolimus administration has been tested since 2010 in facial angiofibromas linked to TSC, and is increasingly being tested in varied cutaneous conditions.⁷⁻⁹ As topical sirolimus is not yet marketed, modalities of its use are heterogeneous, with widespread uncontrolled use.

The aim of this systematic review was to provide an overview of the dermatologic indications of topical mTOR inhibitors, with a meta-analysis aggregating data from randomized trials to estimate their efficacy and safety.

METHODS

Search strategy

We searched electronic databases including MEDLINE via PubMed, CENTRAL, LILACS, and EMBASE from inception to January 2017 by using the terms “mTOR inhibitor”, “sirolimus”, “rapamycin”, “everolimus”, “TOR serine-threonine kinases/antagonists”, combined with “topical”, “local”, “ointment”, “cream” and “gels”.

Inclusion and exclusion criteria

We included all original reports whatever the language, describing use of any topical mTOR inhibitor, alone or in association with other treatments, in any cutaneous condition, in humans. Reports of systemic use and mucosal administration (oral or conjunctival) were excluded, as were reports with non-extractable data (on drug or condition).

Study selection strategy and data extraction

Two authors (SL, AM) independently selected studies based on their title and abstract, then examined the full texts of articles. They independently extracted data which included: first author, publication year, journal, characteristics of the study and of patients, condition, drug modalities, drug efficacy and side effects, blood level of mTOR inhibitor, co-interventions and follow-up. Any disagreements in selection or extraction were resolved by consensus.

Quality and risk of bias assessment

Two authors (SL, AM) independently assessed the risk of bias of each randomized controlled trial (RCT) by using the Cochrane Collaboration Risk of Bias tool. In case of disagreement, a methodologist (ET) gave the final decision.

Statistical analyses

Descriptive data are expressed with median and quartiles [Q1; Q3] for quantitative data and number (%) for categorical data. A meta-analysis was planned if we could pool data from randomized controlled trials (RCTs). It was performed by computing relative risks (RRs) using random-effects model. RR and 95% confidence intervals (CIs) were calculated. Heterogeneity of results across RCTs was assessed by the Q and I^2 statistics, and any heterogeneity was predefined as $p < 0.05$ for

the Q statistic or I^2 value $\geq 50\%$. Statistical analyses involved use of R v3.3.1 and SAS 9.4 (SAS Inst. Inc., Cary, NC).

RESULTS

Characteristics of included reports (Table 1)

Among 1 042 reports identified, we included 40 reports of studies involving 262 patients (Figure 1) that were published between 2005 and 2017: 33 were observational studies (n=128 patients) and 7 were RCTs (n=134 patients). The median [Q1; Q3] age of participants was 25.5 years [12; 33]; 124/246 (50.4%) were male.

Eleven dermatologic conditions were identified, including tumors (angiofibromas, subungual fibromas and hypomelanotic macules linked to TSC, fibrofolliculomas, trichoepitheliomas, familial discoid fibromas, Kaposi's sarcoma), inflammatory diseases (psoriasis plaques, lichen planus) and vascular malformations (port-wine stain [PWS] and cutaneous microcystic lymphatic malformations). Among the 40 reports, 39 reported the use of sirolimus and 1 everolimus.

Assessment of risk of bias

Figure 2 summarizes the assessment of risk of bias of the 7 RCTs, including the 2 on angiofibromas which were meta-analyzed.

Results for efficacy

Angiofibromas in TSC

Overall, 26 reports (157 patients) described the use of a topical mTOR inhibitor for angiofibromas in TSC (3 RCTs and 23 observational studies).^{7,10-34} Among 141 patients, 100 (70.9%) were children and 66 (46.8%) were male. Median age was 14.5 years [11; 38]. The median mTOR inhibitor concentration was 0.1% [0.1; 0.2], with a median number of 2 applications per day. The median treatment time was 16 weeks [12; 24]. Clinical criteria considering efficacy were heterogenous and were mainly the Facial Angiofibroma Severity Index (FASI)³⁵ and physician assessment. Topical

mTOR inhibitors were reported as efficient in 115/121 (95.0%) patients. Follow-up data were available for 20 patients; 18 experienced recurrence between 2 and 12 weeks after withdrawal of the drug.^{13,16,22-24}

We pooled data from 2 RCTs (n=39 patients treated) comparing patient self-assessment of efficacy of topical sirolimus versus placebo, which was the only common outcome (Figure 3). Topical sirolimus use was associated with improved patient self-assessment (RR=2.52, 95% CI [1.27;5.00]).

Hypomelanotic macules and subungual fibromas linked to TSC

Two reports described the benefit of topical sirolimus 0.2% applied for 12 weeks in 7 of 8 patients with hypomelanotic macules linked to TSC.^{36,37} One report described the complete regression of subungual fibromas after 6 months' daily application of topical sirolimus 0.1%.³⁸

Skin tumors

One double-blind, facial left-right controlled trial evaluated 0.1% sirolimus solution applied for 6 months for facial fibromas in 19 patients with Birt-Hogg-Dubé syndrome and showed no significant improvement with sirolimus.³⁹ Sirolimus 1% was also tested in 2 children with multiple familial trichoepithelioma syndrome and led to reduced growth of new lesions after 24 and 48 weeks.⁴⁰ Also, one case report described efficacy of 0.1% sirolimus for familial multiple discoid fibromas,⁴¹ and another described a 73-year-old man with Kaposi's sarcoma healed after 16 weeks of 0.5% sirolimus ointment.⁴²

Inflammatory skin diseases

One vehicle-controlled, split-body RCT included 24 patients with chronic plaque psoriasis; 2.2% topical sirolimus was applied for 6 weeks and 8% topical sirolimus for 6 additional weeks.⁹ Results showed a slight improvement with treatment versus vehicle at 12 weeks. One case report of a 79-year-old male with plantar erosive lichen planus treated with 0.1% sirolimus solution during 20 weeks⁴³ showed a significant reduction in pain after 4 weeks and lesions healed after 20 weeks.

Vascular malformations

Four reports (2 RCTs and 2 observational studies) involving 47 patients described the efficacy of topical sirolimus for PWS, which was used as adjunct therapy to pulsed dye laser (PDL) treatment in all studies.⁴⁴⁻⁴⁷ All patients were at least 17 years old (median age 33 years [29; 33]). The most frequent regimen was 1% sirolimus, applied once daily for 11 weeks. Efficacy outcomes were heterogeneous and did not allow aggregating data. In the observational studies, sirolimus as add-on treatment to PDL seemed efficient in 2 out of 7 patients.^{44,46} In the RCTs, when the outcome was assessed with colorimetric tools,⁴⁵ percentage clearance did not differ between PDL+ topical sirolimus versus PDL+ placebo; when the outcome was based on photographs, PDL+ topical sirolimus were more efficient than PDL+ placebo.⁴⁷ In one case report, a man in his 20s who had lymphangiectasias of genitals treated with 0.8% sirolimus petrolatum showed nearly complete regression after 12 weeks.⁸

Results for safety

Adverse effects

Safety data were reported in 37/40 reports (n=212 patients): 120 adverse effects (AEs) were reported, involving 50 patients (23.6%). All were local AEs, mainly irritation (Table 1). No related general or biological AEs were reported.

Systemic passage of sirolimus

Detection of the blood level of sirolimus was described in 22 reports (n=170 patients). Overall, 17 patients (10.0%) were positive for blood sirolimus concentration, but in all cases, blood levels were below the level required for immunosuppression (4 ng/ml).^{2,6} The highest blood sirolimus concentration was 3.39 ng/ml after 6-week treatment with 0.1% sirolimus on facial PWS previously treated with PDL.⁴⁷

DISCUSSION

Main results

Our systematic review included 40 reports involving 262 patients who received topical application of mTOR inhibitors, mostly sirolimus, for 11 dermatologic conditions. The most frequent was facial angiofibromas linked to TSC, for which treatment seemed efficient. The most frequent regimen was 0.1% sirolimus, with 1 or 2 applications per day for 12 weeks. Local AEs were frequent (120 AEs in 212 patients), mainly consisting of local irritation, and seemed related to the formulation rather than sirolimus concentration. Sirolimus was detected in blood in 10.0% of patients analyzed and in all cases were below the level required for immunosuppression.

Comments

Topical sirolimus is mainly used in facial angiofibromas in TSC, for which it seems efficient. Indeed, TSC results from mutations in the TSC1 and TSC2 genes leading to overactivation of the mTOR signaling pathway, which controls cell growth, proliferation, and survival.¹ Several reports suggested that in this indication, topical sirolimus was more effective in young than old patients, but this was not evidenced in our review. The underlying hypothesis is that sirolimus would be efficient in proliferative tumors with less fibrosis. The second most frequent indication is PWS, for which topical sirolimus is usually given as an adjunct to PDL to minimize post-laser revascularization. Indeed, sirolimus has anti-angiogenic properties by downregulating hypoxia-inducible factor 1 α , a transcriptional factor that regulates vascular endothelial growth factor expression.⁴⁸ Besides its use for these 2 main indications, topical sirolimus has been anecdotally reported in other dermatologic conditions and seems promising for subungual fibromas and lymphangiectasias.

This review showed heterogeneity of the treatment regime in terms of concentration, number of applications per day and duration. This high heterogeneity is linked to lack of a marketed drug. Topical sirolimus is produced with sirolimus in tablets, solution and powder form combined with ointment, cream or gel to obtain a topical preparation. Bouguéon et al. developed a 0.1% sirolimus cream formulation with solubilized sirolimus in a solvent (Transcutol®), which is an excellent permeation agent that enhances drug diffusion through the skin.⁴⁹

Topical sirolimus was generally well tolerated; most symptoms reported by patients were mild to moderate irritation limited to the site of application. We found no systemic AEs related to the treatment. Indeed, in this systematic review, we found a positive blood sirolimus concentration in only 10.0% of patients with the dosage, both in children and adults, with different concentrations, frequencies of application per day and formulations. In all cases, blood levels were below the level required for immunosuppression. Sirolimus has a high molecular weight, 914.17 Dalton²⁶, which allows for diffusion limited to the skin. However, absorption could be enhanced by additional physical treatment, PDL for instance, or with wide surface application. The surface area of application was never indicated in any studies.

Sirolimus was the mTOR inhibitor used in all patients, except one, who used everolimus.¹⁵ This high use is probably due to sirolimus being the oldest mTOR inhibitor, with a well-known safety profile. However, Dill et al. chose everolimus because of presumed advantages (better water solubility because of its additional hydroxy group and shorter half-life).

Finally, long-term maintenance therapy might be necessary, but in our reports, data on recurrence after treatment were too few to assess the frequency and time to recurrence.

Study limitations

The first limitation is that most RCT data could not be pooled for meta-analysis. Criteria for assessing efficacy were heterogeneous: only a few studies used objective scoring systems (eg FASI); most used subjective criteria. Second, the systematic review showed 95.0% efficacy of a topical mTOR inhibitor for facial angiofibromas in TSC, which might be overestimated. Indeed, reports showing treatments as effective are usually published as compared with negative reports (publication bias). Third, formulations of topical sirolimus, concentrations, duration and monitoring were heterogeneous, so comparisons were difficult.

Conclusions

This systematic review and meta-analysis supports the efficacy of topical sirolimus in adults and children for facial angiofibromas linked to TSC. The treatment appears to be safe and non-invasive but locally often irritative, especially when using solutions. Other indications require further research.

REFERENCES

1. Saxton RA, Sabatini DM. mTOR signaling in growth, metabolism, and disease. *Cell*. 2017;168(6):960–76.
2. Kasap B. Sirolimus in pediatric renal transplantation. *Pediatr Transplant*. 2011;15(7):673–85.
3. Sasonko TH, Ismail NFD, Zabidi-Hussin Z. Rapamycin and rapalogs for tuberous sclerosis complex. *Cochrane Database Syst Rev*. 2016;7:CD011272.
4. Faivre S, Kroemer G, Raymond E. Current development of mTOR inhibitors as anticancer agents. *Nat Rev Drug Discov*. 2006;5(8):671-88.
5. Hammill AM, Wentzel M, Gupta A, Nelson S, Lucky A, Elluru R, et al. Sirolimus for the treatment of complicated vascular anomalies in children. *Pediatr Blood Cancer*. 2011;57(6):1018–24.
6. Nadal M, Giraudeau B, Tavernier E, Jonville-Bera A-P, Lorette G, Maruani A. Efficacy and safety of mammalian target of rapamycin inhibitors in vascular anomalies: a systematic review. *Acta Derm Venereol*. 2016;96(4):448–52.
7. Haemel AK, O'Brian AL, Teng JM. Topical rapamycin: a novel approach to facial angiofibromas in tuberous sclerosis. *Arch Dermatol*. 2010;146(7):715–8.
8. Ivars M, Redondo P. Efficacy of topical sirolimus (rapamycin) for the treatment of microcystic lymphatic malformations. *JAMA Dermatol*. 2017;153(1):103–5.

9. Ormerod AD, Shah S a. A, Copeland P, Omar G, Winfield A. Treatment of psoriasis with topical sirolimus: preclinical development and a randomized, double-blind trial. *Br J Dermatol.* 2005;152(4):758-64.
10. Amin S, Lux A, O'Callaghan F. Novel treatment option of sirolimus ointment for facial angiofibromas in individuals with tuberous sclerosis complex (TSC). *Arch Dis Child.* 2016;101:A143.
11. Bae-Harboe Y-SC, Geronemus RG. Targeted topical and combination laser surgery for the treatment of angiofibromas. *Lasers Surg Med.* 2013;45(9):555-7.
12. Bloemen-boot MCT, Toonstra J, van Steensel MAM, Pasmans GMA. Topicale rapamycine voor de behandeling van faciale angio bromen bij tubereuzesclerosecomplex. *Ned Tijdschr Dermatol Venereol.* 2014;24(5):323-6.
13. Cinar SL, Kartal D, Bayram AK, Canpolat M, Borlu M, Ferahbas A, et al. Topical sirolimus for the treatment of angiofibromas in tuberous sclerosis. *Indian J Dermatol Venereol Leprol.* 2017 Feb;83(1):27-32.
14. DeKlotz CMC, Ogram AE, Singh S, Dronavalli S, MacGregor JL. Dramatic improvement of facial angiofibromas in tuberous sclerosis with topical rapamycin: optimizing a treatment protocol. *Arch Dermatol.* 2011;147(9):1117-8.
15. Dill PE, De Bernardis G, Weber P, Lösch U. Topical everolimus for facial angiofibromas in the tuberous sclerosis complex. A first case report. *Pediatr Neurol.* 2014;51(1):109-13.
16. Ebrahimi-Fakhari D, Müller CSL, Meyer S, Flotats-Bastardas M, Vogt T, Pföhler C. Topical rapamycin for facial angiofibromas in a child with Tuberous Sclerosis Complex (TSC): a case report and long-term follow-up. *Dermatol Ther.* 2017;7(1):175-179.
17. Foster RS, Bint LJ, Halbert AR. Topical 0.1% rapamycin for angiofibromas in paediatric patients with tuberous sclerosis: a pilot study of four patients. *Australas J Dermatol.* 2012;53(1):52-6.

18. Kaufman McNamara E, Curtis AR, Fleischer AB. Successful treatment of angiofibromata of tuberous sclerosis complex with rapamycin. *J Dermatol Treat.* 2012;23(1):46–8.
19. Knöpfel N, Martín-Santiago A, Bauza A, Hervás JA. Topical 0.2% rapamycin to treat facial angiofibromas and hypomelanotic macules in tuberous sclerosis. *Actas Dermosifiliogr.* 2014;105(8):802–3
20. Koenig MK, Hebert AA, Roberson J, Samuels J, Slopis J, Woerner A, et al. Topical rapamycin therapy to alleviate the cutaneous manifestations of tuberous sclerosis complex. *Drugs R D.* 2012 12(3):121-6.
21. Mutizwa MM, Berk DR, Anadkat MJ. Treatment of facial angiofibromas with topical application of oral rapamycin solution (1mg/mL(-1)) in two patients with tuberous sclerosis. *Br J Dermatol.* 2011;165(4):922–3.
22. Park J, Yun S-K, Cho Y-S, Song K-H, Kim H-U. Treatment of angiofibromas in tuberous sclerosis complex: the effect of topical rapamycin and concomitant laser therapy. *Dermatol Basel Switz.* 2014;228(1):37–41.
23. Pynn EV, Collins J, Hunasehally PRY, Hughes J. Successful topical rapamycin treatment for facial angiofibromata in two children. *Pediatr Dermatol.* 2015;32(3):e120-123.
24. Rodrigo-Nicolas B, Gimeno-Carpio E, Quecedo-Estébanez E, Millán-Parrilla F, Armengot-Carbó M, Molés-Poveda P, et al. Topical rapamycin in facial angiofibromas: assessment of clinical improvement and patient satisfaction in a series of 4 cases. *J Am Acad Dermatol.* 2013;68(4):AB182.
25. Salido R, Garnacho-Saucedo G, Cuevas-Asencio I, Ruano J, Galán-Gutierrez M, Vélez A, et al. Sustained clinical effectiveness and favorable safety profile of topical sirolimus for tuberous sclerosis – associated facial angiofibroma. *J Eur Acad Dermatol Venereol.* 2012;26(10):1315–8.

26. Tanaka M, Wataya-Kaneda M, Nakamura A, Matsumoto S, Katayama I. First left-right comparative study of topical rapamycin vs. vehicle for facial angiofibromas in patients with tuberous sclerosis complex. *Br J Dermatol.* 2013;169(6):1314–8.
27. Truchuelo T, Díaz-Ley B, Ríos L, Alcántara J, Jaén P. Facial angiofibromas treated with topical rapamycin: an excellent choice with fast response. *Dermatol Online J.* 2012;18(1):15.
28. Tu J, Foster RS, Bint LJ, Halbert AR. Topical rapamycin for angiofibromas in paediatric patients with tuberous sclerosis: follow up of a pilot study and promising future directions. *Australas J Dermatol.* 2014;55(1):63-9
29. Valerón-Almazán P, Vitiello M, Abuchar A, Kerdel FA. Topical rapamycin solution to treat multiple facial angiofibromas in a patient with tuberous sclerosis. *Actas Dermosifiliogr.* 2012;103(2):165–6.
30. Vasani RJ. Facial angiofibromas of tuberous sclerosis treated with topical sirolimus in an indian patient. *Indian J Dermatol.* 2015;60(2):165–9.
31. Viswanath V, Thakur P, Pund P. Use of topical rapamycin in facial angiofibromas in Indian skin type. *Indian J Dermatol.* 2016;61(1):119.
32. Wataya-Kaneda M, Tanaka M, Nakamura A, Matsumoto S, Katayama I. A topical combination of rapamycin and tacrolimus for the treatment of angiofibroma due to tuberous sclerosis complex (TSC): a pilot study of nine Japanese patients with TSC of different disease severity. *Br J Dermatol.* 2011;165(4):912–6.
33. Wataya-Kaneda M, Nakamura A, Tanaka M, Hayashi M, Matsumoto S, Yamamoto K, et al. Efficacy and safety of topical sirolimus therapy for facial angiofibromas in the tuberous sclerosis complex : a randomized clinical trial. *JAMA Dermatol.* 2017;153(1):39–48.
34. Wheless JW, Almoazen H. A novel topical rapamycin cream for the treatment of facial angiofibromas in tuberous sclerosis complex. *J Child Neurol.* 2013;28(7):933–6.

35. Salido-Vallejo R, Ruano J, Garnacho-Saucedo G, Godoy-Gijón E, Llorca D, Gómez-Fernández C, et al. Facial Angiofibroma Severity Index (FASI): reliability assessment of a new tool developed to measure severity and responsiveness to therapy in tuberous sclerosis-associated facial angiofibroma. *Clin Exp Dermatol*. 2014;39(8):888–93.
36. Wataya-Kaneda M, Tanaka M, Yang L, Yang F, Tsuruta D, Nakamura A, et al. Clinical and histologic analysis of the efficacy of topical rapamycin therapy against hypomelanotic macules in tuberous sclerosis complex. *JAMA Dermatol*. 2015;151(7):722-30.
37. Wataya-Kaneda M, Tanaka M, Nakamura A, Matsumoto S, Katayama I. A novel application of topical rapamycin formulation, an inhibitor of mTOR, for patients with hypomelanotic macules in tuberous sclerosis complex. *Arch Dermatol*. 2012;148(1):138–9.
38. Muzic JG, Kindle SA, Tollefson MM. Successful treatment of subungual fibromas of tuberous sclerosis with topical rapamycin. *JAMA Dermatol*. 2014;150(9):1024–5.
39. Gijzen LMC, Vernooij M, Martens H, Oduber CEU, Henquet CJM, Starink TM, et al. Topical rapamycin as a treatment for fibrofolliculomas in Birt-Hogg-Dubé syndrome: a double-blind placebo-controlled randomized split-face trial. *PLoS One*. 2014;9(6):e99071.
40. Tu JH, Teng JMC. Use of topical sirolimus in the management of multiple familial trichoepitheliomas. *Dermatol Ther*. 2017;30(2).
41. Wee JS, Chong H, Natkunarajah J, Mortimer PS, Moosa Y. Familial multiple discoid fibromas: unique histological features and therapeutic response to topical rapamycin. *Br J Dermatol*. 2013;169(1):177–80.
42. Díaz-Ley B, Grillo E, Ríos-Buceta L, Paoli J, Moreno C, Vano-Galván S, et al. Classic Kaposi's sarcoma treated with topical rapamycin. *Dermatol Ther*. 2015 Feb;28(1):40–3.
43. Munidasa D, Espinosa O, Burge SM. Topical sirolimus: a novel treatment for chronic erosive plantar lichen planus. *Br J Dermatol*. 2012;167(suppl 1):30.

44. Doh EJ, Ohn J, Kim MJ, Kim YG, Cho S. Prospective pilot study on combined use of pulsed dye laser and 1% topical rapamycin for treatment of nonfacial cutaneous capillary malformation. *J Dermatol Treat.* 2017;28(7):672-677.
45. Greveling K, Prens EP, van Doorn MB. Treatment of port wine stains using Pulsed Dye Laser, Erbium YAG Laser, and topical rapamycin (sirolimus)-A randomized controlled trial. *Lasers Surg Med.* 2017;49(1):104-9.
46. Griffin TD, Foshee JP, Finney R, Saedi N. Port wine stain treated with a combination of pulsed dye laser and topical rapamycin ointment. *Lasers Surg Med.* 2016;48(2):193–6.
47. Marqués L, Núñez-Córdoba JM, Aguado L, Pretel M, Boixeda P, Nagore E, et al. Topical rapamycin combined with pulsed dye laser in the treatment of capillary vascular malformations in Sturge-Weber syndrome: phase II, randomized, double-blind, intraindividual placebo-controlled clinical trial. *J Am Acad Dermatol.* 2015;72(1):151-8.e1.
48. Karar J, Maity A. PI3K/AKT/mTOR Pathway in Angiogenesis. *Front Mol Neurosci.* 2011;4:51.
49. Bouguéon G, Lagarce F, Martin L, Pailhories H, Bastiat G, Vrignaud S. Formulation and characterization of a 0.1% rapamycin cream for the treatment of Tuberous Sclerosis Complex-related angiofibromas. *Int J Pharm.* 2016;509(1–2):279–84.

FIGURE LEGENDS

Figure 1. Flow chart of included reports

Figure 2. Risk of bias assessment of the included RCTs by the Cochrane Risk of Bias tool

Figure 3. Forest plot showing the effect of topical sirolimus in facial angiofibromas linked to tuberous sclerosis complex

TABLES

Table 1. Characteristics of reports included in the systematic review

ABBREVIATIONS USED

AEs: adverse effects

CI: confidence intervals

FASI: facial angiofibroma severity index

mTOR: mammalian target of rapamycin

PDL: pulsed dye laser

PWS: port wine stain

RCT: randomized controlled trial

RRs: risk ratios

TSC: tuberous sclerosis complex

A portion of this report's results was orally presented at *Journées Dermatologiques de Paris*, Paris, France, December 2017.

Table I: Characteristics of reports included in systematic review

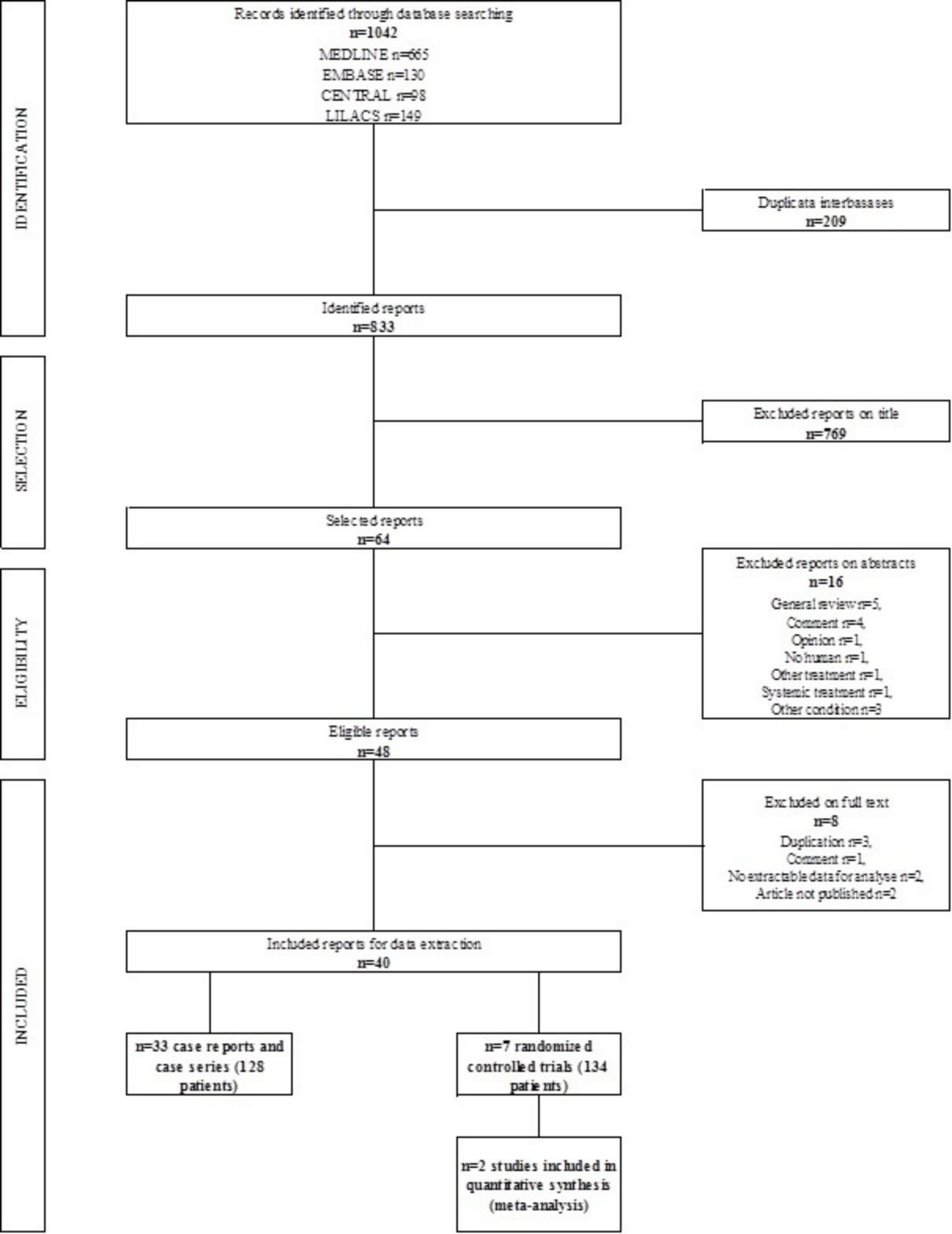
Indications		Total number of publications (number of RCTs)	Total number of patients (number of patients included in RCTs)	Median of drug concentration in % [IQR]	Duration of treatment median of weeks [IQR]	Safety (number of AEs*)
<i>Angiofibromas in TSC</i>	Angiofibromas	26 (3)	157 (51)	0.1 [0.1;0.2]	16 [12;24]	Irritation (38) Local pruritus (1)
	Hypomelanotic macules	2 (0)	8 (0)	0.2	12	0
<i>Hypomelanotic macules and subungual fibromas linked to TSC</i>	Subungual fibromas	1 (0)	1 (0)	0.1	24	0
	Fibrofolliculomas	1 (1)	19 (19)	0.1	24	Irritation (29) Local pruritus (3)
<i>Benign cutaneous tumors</i>	Trichoepitheliomas	1 (0)	2 (0)	1	38 [28;48]	0
	FMDF	1 (0)	1 (0)	0.1	16	Irritation (1)
<i>Kaposi's sarcoma</i>	Kaposi's sarcoma	1 (0)	1 (0)	0.5	16	Local pruritus (1)
<i>Inflammatory skin diseases</i>	Chronic plaque psoriasis	1 (1)	24 (24)	2.2 then 8	12	Topical allergy (3)
	Lichen plan	1 (0)	1 (0)	0.1	20	0
<i>Vascular malformations</i>	Port wine stain	4 (2)	47 (40)	1 [0.1;1]	11 [10;12]	Irritation (14) Local pruritus (12) Facial acne (8) Transient numbness (4) Sores (3) Topical allergy (2) Herpes infection (1)
	CMLM	1 (0)	1 (0)	0.8	12	0

Abbreviations

AEs: Adverse events
CMLM: cutaneous microcystic lymphatic malformation
FMDF: familial multiples discoid fibromas
IQR: interquartile range
RCTs: randomized controlled trials
TSC: Tuberous Sclerosis Complex

Median and IQR were not mentioned in case of small effective

*Adverse events with possible or probable causal relationship with topical mTOR inhibitors



	Random sequence generation (selection bias)	Allocation concealment (selection bias)	Blinding of participants and personnel (performance bias)	Blinding of outcome assessment (detection bias)	Incomplete outcome data (attrition bias)	Selective reporting (reporting bias)
Cinar et al., 2016						
Gjezen et al., 2014						
Greveling et al., 2016						
Koenig et al., 2012						
Marques et al., 2014						
Omerod et al., 2005						
Wataya et al., 2016						

