



HAL
open science

Forearm lengthening and prosthetic management in children with transverse congenital forearm deficiency

C. Klein, V. Ferrari, F. Deroussen, M. Juvet-Segarra, R. Gouron

► **To cite this version:**

C. Klein, V. Ferrari, F. Deroussen, M. Juvet-Segarra, R. Gouron. Forearm lengthening and prosthetic management in children with transverse congenital forearm deficiency. *Hand Surgery and Rehabilitation*, 2019, 38, pp.129 - 134. 10.1016/j.hansur.2018.12.005 . hal-03486600

HAL Id: hal-03486600

<https://hal.science/hal-03486600v1>

Submitted on 20 Dec 2021

HAL is a multi-disciplinary open access archive for the deposit and dissemination of scientific research documents, whether they are published or not. The documents may come from teaching and research institutions in France or abroad, or from public or private research centers.

L'archive ouverte pluridisciplinaire **HAL**, est destinée au dépôt et à la diffusion de documents scientifiques de niveau recherche, publiés ou non, émanant des établissements d'enseignement et de recherche français ou étrangers, des laboratoires publics ou privés.



Distributed under a Creative Commons Attribution - NonCommercial 4.0 International License

Forearm lengthening and prosthetic management in children with transverse congenital forearm deficiency

Allongement de l'avant-bras et utilisation des prothèses chez les enfants présentant une agénésie antébrachiale

C. Klein, V. Ferrari, F. Deroussen, M. Juvet-Segarra, R. Gouron

Department of pediatric orthopedic surgery. Amiens University Hospital and Jules Verne University of Picardy, CHU Amiens, Groupe Hospitalier Sud, F-80054 Amiens Cedex 1, France

Corresponding author:

Dr Céline KLEIN

Service d'Orthopédie Pédiatrique, CHU Amiens, Groupe Hospitalier Sud, F-80054 Amiens Cedex 1, France

Tel.: +33 322-087-570

Fax: +33 322-089-741

Email: celinekleinfr@yahoo.fr

Other authors:

Vittorio Ferrari, MD

Francois Deroussen, MD

Marie Juvet-Segarra, MD

Richard Gouron, MD, PhD

Disclosure of interest :

All authors declare they have no conflict of interest and no financial support.

The manuscript has been read and approved by all the authors.

The manuscript represents honest work .

All authors contributed to this manuscript.

CK and MJS wrote the manuscript

VF designed the data and statistics

FD and RG revised the manuscript.

No submissions and previous reports that might be regarded as redundant publication of the same or very similar work were reported.

Forearm lengthening and prosthetic management in children with transverse congenital forearm deficiency

Allongement de l'avant-bras et utilisation des prothèses chez les enfants présentant une agénésie antébrachiale

Abstract

In cases of transverse congenital forearm deficiency, achieving a good prosthesis fit during childhood remains a challenge. Ulnar lengthening is a treatment option for improving the prosthesis fit. The objective of this study was to evaluate surgical ulnar lengthening and the subsequent prosthesis fit.

We reviewed four cases of ulnar lengthening in children with transverse congenital forearm deficiency. The procedure was evaluated in terms of the duration of lengthening, increase in ulnar length and healing index. The elbow range of motion, functional outcome (Prosthetic Upper Extremity Functional Index, PUF) and time spent using the prosthesis per day were evaluated.

The mean age at the time of the lengthening procedure was 3.5 years, the mean duration of lengthening was 58.3 days, the mean length gain was 21 mm, and the mean healing index was 70.1 days/cm. Elbow range of motion was restricted in one patient (100-140°) and full in the other three patients. Based on the PUF, 88.4% of activities were performed without the prosthesis. Children only used their prosthesis to perform specific tasks.

Given the high complication rate and the lack of prosthesis use during daily activities, the main indication for forearm lengthening is a very short forearm that prevents prosthesis fitting. This procedure should be performed later in life – in adolescence.

Résumé

Le port de prothèse dans les agénésies antébrachiales congénitales reste un défi pendant l'enfance. L'allongement de l'ulna est une option thérapeutique pour améliorer le port de la prothèse. Le but de l'étude était d'évaluer l'allongement de l'ulna et le port de prothèse après la chirurgie.

Quatre enfants avec une agénésie antébrachiale ont été inclus rétrospectivement. Le protocole d'allongement de l'ulna a été évalué: la durée, le gain d'allongement, l'indice de consolidation. Nous avons évalué les amplitudes articulaires du coude, le score fonctionnel des membres supérieurs prothétiques (PUFI) et l'utilisation et le type de prothèse par jour.

L'âge moyen au moment de l'allongement était de 3,5 ans. La durée moyenne de l'allongement était de 58,3 jours. Le gain d'allongement moyen était de 21 mm. L'indice moyen de guérison était de 70,1 jours/cm. Durant l'allongement, il a été noté une consolidation prématurée et une luxation radio-humérale. L'amplitude des mouvements du coude était limitée chez un patient (100-140°). Le pourcentage moyen d'activités réalisées sans prothèse au PUFI était de 88,4 %. Les enfants n'utilisaient leurs prothèses que pour des tâches spécifiques, jamais dans les activités quotidiennes.

Au vu de notre petit échantillon et de nos résultats, il apparaît que l'allongement de l'avant-bras ne doit pas être effectué systématiquement pendant l'enfance mais être réservé en cas d'avant-bras très court lorsque le port de la prothèse pour une tâche spécifique reste impossible.

Keywords: Forearm lengthening; Prosthesis; Child

Mots-clés : Allongement ; Avant-bras ; Prothèse ; Enfant

1. Introduction

Transverse congenital forearm deficiency is a very rare upper limb malformation caused by developmental failure or amniotic band syndrome [1]. There are few treatment options during childhood for this type of pathology, and children are usually fitted with a prosthesis before the age of 2 [2–4]. The prosthetic fit depends on elbow range of motion and forearm length. Progressive forearm lengthening (based on distraction osteogenesis) is reportedly an effective means for increasing forearm length and thus prosthesis use [5–8].

The primary objective of our study was to evaluate the radiological and clinical outcomes of ulnar lengthening in a case series of children with transverse congenital forearm deficiency. The secondary objective was to assess prosthesis use after ulnar lengthening in children.

2. Materials and methods

We performed a prospective study of all children with transverse congenital forearm deficiency who underwent forearm lengthening in our pediatric orthopedic surgery department between 2005 and 2017. The study protocol was approved by our local independent ethics committee, and the children's parents gave their informed consent. Four children were regularly monitored and included in the study. The family medical histories were unremarkable. All children had a unilateral transverse congenital forearm deficiency. The main exclusion criteria were above-elbow deficiency, missing data, and loss to follow-up.

2.1 Surgical technique

All the patients underwent surgical lengthening of the forearm using a monorail external fixator (Orthofix®). Iliac crest growth plate transfer was performed to increase the length before ulnar lengthening [9]. The first step in the surgical procedure was recipient site preparation. A skin incision was made on the distal extremity of the stump. Subcutaneous dissection then created a space for insertion of the graft. The second step consisted of removal of a bone and cartilage graft (including periosteum) from the growing iliac crest. The

graft was sized to fit the recipient site. The iliac crest's cartilaginous side was placed against the radial and ulnar joint surfaces. The graft was then stabilized with K-wires.

Ulnar lengthening was performed a few years later, using a monorail external fixator. The procedure began with the fluoroscopy-guided insertion of four 2-mm wires into the ulna's frontal plane, perpendicular to the bone axis. Mid-shaft osteotomy of the radius and ulna was then performed, and the periosteum was closed before skin closure. The body of the external fixator was applied, and the osteotomy was distracted by a few millimeters before the external fixator was locked. X-rays of the forearm were taken in the immediate postoperative period. The lengthening was initiated 7 days after surgery. A weekly radiological and clinical examination was performed throughout the treatment period. The distraction speed was 0.5 mm per day (a quarter clockwise turn of the threaded screw twice per day). Radiological measurements of the forearm were made before and after surgery, and during follow-up (Fig. 1).

The ulnar length was measured between the proximal physis and distal extremity. The measurements after external fixator removal were compared with the pre-operative measurements, and the healing index was calculated. Complications during lengthening were noted. In all cases, a cosmetic prosthesis was provided 2 months after lengthening. During the clinical examination, we assessed the elbow's range of motion and recorded the patient's age at the time of prosthesis fitting, the type of prosthesis, and the number of hours of daily prosthesis use. Prosthesis use after lengthening was rated as daily use, occasional use or no use. If applicable, we sought to establish the reason for lack of use (e.g. inconvenient, no functional gain, technical limitations or skin problems). A successful prosthesis fitting was defined a child and parents who continued to attend the follow-up visits and who stated at the time of the most recent follow-up that the prosthesis had been worn for any period of time, based on Davids et al. [10]. An unsuccessful outcome was defined as a child lost to follow-up or who never wore the prosthesis. We also asked the children to verbally rate their level of pain.

Functional outcomes were evaluated using the Prosthetic Upper Extremity Functional Index (PUFI) (Table 1) [11,12]. This index evaluates upper limb performance in activities of daily living and has been validated in children. First, the child or parent is asked whether the activity has been performed (“yes” or “no”). If the answer is “no”, one moves to the next activity. If the answer is “yes”, the method of performance is then evaluated. If a prosthesis was not worn for a particular activity, we modified the first two answers of the “method of performance” category as follows: 1) the answer “using the prosthesis actively” was replaced by “using the operated limb actively”, and 2) the answer “using the prosthesis passively” was replaced by “using the operated limb passively”. Next, the ease of performance (with or without a prosthesis) is evaluated. The final “ease of performance” score was obtained by adding the points and converting the sum to a value between 0 and 100.

3. Results

Four patients (two girls and two boys) with transverse congenital forearm deficiency (left arm in two cases and right arm in the two other cases) and progressive ulnar lengthening were included in the study. The deficiency was congenital in three cases and caused by amniotic band syndrome in one case. The mean follow-up period was 6.2 years (range 4.6–8.9) and the mean age at last follow-up was 10 years (range 7.1–15).

The mean age at the time of the first prosthesis fitting was 2.6 years (range 9 months-4 years). Data for each patient are summarized in Table 2.

An iliac graft transfer was performed in three cases (at a mean age of 11 months (range 9–12) and the mean length gain was 13.7 mm (range 13–15). The average age at the first lengthening was 3.5 years (range 2.3–6.2). The mean number of lengthening procedures per patient was 1.5 (range 1–3). The mean length of the ulna before surgery was 46.2 mm (range 40–55) (Fig. 2-3). After surgery, the mean length gain was 21 mm (range 15–27), which corresponded to 46% of the initial forearm length. The mean duration of lengthening was 58.3 days (range 50–70). The mean duration of treatment (between the application and removal of the external fixator) was 143.3 days (120–190). The mean healing index was 70.1

days/cm (57–80). A pin infection occurred in one patient, which was treated with antibiotics and local wound care. Premature union was reported in one case, prompting repeat ulna osteotomy. In one case, ulno-humeral dislocation was observed during the second lengthening and required joint reduction. One patient presented with an irreducible limitation of elbow extension after the third lengthening, and no improvement was noted after physical therapy. No skin problems were reported. At last follow-up, three patients had a full elbow range of motion (Fig. 4) and one patient had restricted elbow range of motion (from 100° to 140°). None of the children reported having pain.

None of the children used the prosthesis in activities of daily living. Three patients wore their prosthesis occasionally; the duration of prosthesis use per day could not be determined. Three patients wore a functional prosthesis to ride a bicycle, and one of them occasionally wore a cosmetic prosthesis for social reasons. A successful prosthesis outcome (for specific tasks only) was reported in three cases, with an improvement in the prosthesis fit after surgery. In all cases, the first cosmetic prosthesis after lengthening was rejected during the first year. The reason for rejection was the absence of functional gain in three cases and a technical limitation (because of decreased elbow range of motion) in the other case.

With regard to the functional outcome (i.e. the PUF1), we were not able to rate the “ease of performance with prosthesis” or the “usefulness of prosthesis” categories because none of the patients used their prosthesis in activities of daily living.

Activities were performed without a prosthesis in 88.4% of cases (range: 73.7%–96.2%). The methods used to perform these activities are summarized in Table 3. The mean \pm standard deviation (range) ease of performance without the prosthesis was $92.1\% \pm 8.52\%$ (80–100). The distribution of responses for ease of performance is shown in Table 4.

4. Discussion

Congenital deficiency of the upper limb is rare, and there are few published long-term studies of surgical and functional outcomes in this context. The management of transverse congenital forearm deficiency is a real challenge; hence, the goal of bone lengthening is to

improve prosthesis fit and maintain the elbow's natural range of motion [13]. In the current study, we assessed the clinical and functional outcomes of seven progressive ulnar lengthening procedures in four patients with transverse congenital forearm deficiency. We found that none of the children used the prosthesis on a daily basis.

Our study has several limitations. Firstly, we performed a prospective study of a small number of patients (n=4), which limited the statistical power. Secondly, a longer follow-up period (i.e. into adulthood) would ideally have been required. The outcome of forearm lengthening is known to depend on the cause of the deficiency (club hand, Madelung disease, osteochondroma, etc.) and the shape of the shortened forearm [5].

Iliac crest transfer was first described in cases of transverse congenital wrist deficiency, with to the aim of increasing the stump length [9]. In the current study, we confirmed that iliac crest autografting increases the stump length before ulnar lengthening with an external fixator [9]. But the distraction length achieved at a young age was very small (mean 21 mm, range 15–27) and will likely require repeated lengthening at a later age.

As previously reported, we chose to use a uniplanar external fixator because of the ease of installation, the reduced likelihood of vascular and nervous complications and the low bulk within a small child's forearm [4]. This fixator did not enable three-plane correction and radius lengthening. In the literature, the Ilizarov device has been used more frequently, and provides good lengthening results [6–8]. An annular device has the advantage of allowing the radius and ulna to be fixed independently. Popkov and Popkov prefer to use an Ilizarov frame to lengthen both bones, shape a rounded stump, and thus obtain a better prosthesis fit than is possible with the conical stump obtained by ulnar lengthening only [8]. For this reason, Milliez et al. added an inguinal flap on the distal end of the stump after lengthening in a case of traumatic forearm amputation [14]. In our four patients, the shape of the stump was never a reason for prosthesis non-use. The healing index observed in our study (70.1 days/cm) was higher than previously reported (34.1 days/cm in the Popkov and Popkov study and 61.9 days/cm in the Launay et al study) [5,8]. This difference might have been due to the use of intramedullary guide wires in the two previous studies; we intend to use a guide

wire in the future. Our complication rate was similar to that observed in other studies [3–5,8,13,15]. Elbow contracture can be avoided by performing biceps tenotomy during the surgical procedure [16] and then providing the patient with intensive physical therapy [8]. Several studies have reported elbow subluxations; this is a frequent complication of progressive forearm lengthening because the proximal radio-ulnar joint is destabilized; accordingly, radiological monitoring is essential to preventing this problem [6,7].

Brooks et al. suggested that orthopedic devices should be fitted early in the child's life (on the basis that "earlier might be better") and reported a successful fit in 80% of cases before the age of 2 but less than 54% after the age of 2 [17]. Davids et al. recommended that the first prosthetic fitting should take place before the age of 3 but after the child had started to walk [10]. Although Huizing et al. observed longer use of the prosthesis when the first prosthesis was fitted during the first year of life ("fit when they sit"), the functional outcome was not correlated with the age at first prosthetic fitting [18]. We generally perform lengthening early in life—most of our patients are fitted with a prosthesis before 2 years of age—but our findings suggest that this procedure should be performed later (i.e. in adolescence) [10,19].

Our findings are in line with the reports by James et al. and Huizing et al., in which the PUF1 scores with and without a prosthesis were similar [18,20]. Given the high complication rate and the lack of prosthesis use in daily activities, the main indication for forearm lengthening is a very short forearm that prevents prosthesis fitting. This procedure should be carried out later in life—in adolescence, for example. Hadders-Algra et al. reported that children have considerable adaptability with their affected limb [21]. We found that the children used their prosthesis as a tool for performing a specific task (like riding a bicycle), rather than in general activities of daily living.

Most children do not use their prosthesis because of the latter's weight, bulkiness and lack of sensitivity [7]. Furthermore, Reinkingh et al. recently reported that the stump is often highly sensitive, which might explain rejection of the prosthesis [22]. In recent years, new functional prostheses have been developed. The use of three-dimensional (3D) printing

techniques (e.g. E-Nable® and Open Bionics®) enable the child to design and print his/her own prosthetic upper limb [23,24]. These prosthetics are lightweight, customized, cheap to produce, and are likely to fit well. However, the long-term acceptance, use and effectiveness of 3D-printed prosthetics must now be assessed in a randomized, controlled trial [25,26].

5. Conclusion

Congenital forearm deficiencies are rare pathologies with complex treatment. Distraction lengthening in early childhood results in an unacceptably high complication rate, even after a two-stage procedure with an iliac crest graft. This study confirms that a high initial rejection rate of the cosmetic prosthesis must be anticipated after fitting in early childhood (100% in our case series). Initial prosthetic fitting may be delayed until a later age when the child asks for a prosthesis. This enables an initial fitting with a functional or myoelectric prosthesis and might result in a higher acceptance of the prosthesis. Such protocols would reduce the numbers of lengthening procedures to only those who ultimately wish to have a prosthesis. Necessary distraction lengthening a later age allows a bigger initial distraction.

Conflict of Interest:

The authors declare they have no conflicts of interest.

Funding:

This study did not receive any specific grant from funding agencies in the public, commercial, or not-for-profit sector.

Ethical approval:

This article does not contain any studies with human participants or animals performed by any of the authors.

Informed consent:

Informed consent was obtained from all individual participants included in the study.

References

1. Jain S, Lakhtakia PK. Profile of congenital transverse deficiencies among cases of congenital orthopaedic anomalies. *J Orthop Surg* 2002;10:45–52.
2. Dabaghi-Richerand A, Haces-García F, Capdevila-Leonori R. Prognostic factors of a satisfactory functional result in patients with unilateral amputations of the upper limb above the wrist that use an upper limb prosthesis. *Rev Espanola Cirugia Ortop Traumatol* 2015;59:343–7.
3. Seitz WH, Shimko P, Patterson RW. Long-term results of callus distraction-lengthening in the hand and upper extremity for traumatic and congenital skeletal deficiencies. *J Bone Joint Surg Am* 2010;92 Suppl 2:47–58.
4. Abe M, Shirai H, Okamoto M, Onomura T. Lengthening of the forearm by callus distraction. *J Hand Surg Br* 1996;21:151–63.
5. Launay F, Jouve JL, Guillaume JM, Viehweger E, Jacquemier M, Bollini G. Progressive forearm lengthening in children: 14 cases. *Rev Chir Orthop Reparatrice Appar Mot* 2001;87:786–95.
6. Jasiewicz B, Tesiorowski M, Kacki W, Kasprzyk M, Zarzycki D. Lengthening of congenital forearm stumps. *J Pediatr Orthop B*. 2006;15:198–201.
7. Bernstein RM, Watts HG, Setoguchi Y. The lengthening of short upper extremity amputation stumps. *J Pediatr Orthop* 2008;28:86–90.
8. Popkov D, Popkov A. Progressive lengthening of short congenital forearm stump in children for prosthetic fitting. *Int Orthop* 2016;40:547–54.
9. Deroussen F, Gouron R, Juvet-Segarra M, Maes-Clavier C, Plancq MC, Collet LM. Use of an iliac crest growth plate for the development of a neo-articulation for congenital transverse deficiencies at the wrist. *J Hand Surg Am* 2012;37:2061–7.
10. Davids JR, Wagner LV, Meyer LC, Blackhurst DW. Prosthetic management of children with unilateral congenital below-elbow deficiency. *J Bone Joint Surg Am* 2006;88:1294–300.

11. Sköld A, Hermansson LN, Krumlinde-Sundholm L, Eliasson A-C. Development and evidence of validity for the Children's Hand-use Experience Questionnaire (CHEQ). *Dev Med Child Neurol* 2011;53:436–42.
12. Wright FV, Hubbard S, Naumann S, Jutai J. Evaluation of the validity of the prosthetic upper extremity functional index for children. *Arch Phys Med Rehabil.*2003;84:518–27.
13. Alekberov C, Karatosun V, Baran O, Günal I. Lengthening of congenital below-elbow amputation stumps by the Ilizarov technique. *J Bone Joint Surg Br* 2000;82:239–41.
14. Milliez PY, Auquit I, Biga N, Thomine JM. Elongation and coverage of an inguinal flap over a short forearm traumatic amputation stump. *Ann Chir Main Memb Super* 1995;14:28–32.
15. Yun AG, Severino R, Reinker K. Attempted limb lengthenings beyond twenty percent of the initial bone length: results and complications. *J Pediatr Orthop* 2000;20:151–9.
16. Launay F, Pesenti S. Forearm lengthening: management of elbow and wrist. *J Child Orthop* 2016; 10: 593–5.
17. Brooks MB, Shaperman J. Infant prosthetic fitting. A study of the results. *Am J Occup Ther* 1965;19:329–34.
18. Huizing K, Reinders-Messelink H, Maathuis C, Hadders-Algra M, van der Sluis CK. Age at first prosthetic fitting and later functional outcome in children and young adults with unilateral congenital below-elbow deficiency: a cross-sectional study. *Prosthet Orthot Int* 2010;34:166–74.
19. Crandall RC, Tomhave W. Pediatric unilateral below-elbow amputees: retrospective analysis of 34 patients given multiple prosthetic options. *J Pediatr Orthop* 2002;22:380–3.
20. James MA, Bagley AM, Brasington K, Lutz C, McConnell S, Molitor F. Impact of prostheses on function and quality of life for children with unilateral congenital below-the-elbow deficiency. *J Bone Joint Surg Am* 2006;88:2356–65.
21. Hadders-Algra M, Reinders-Messelink HA, Huizing K, van den Berg R, van der Sluis CK, Maathuis CGB. Use and functioning of the affected limb in children with unilateral congenital below-elbow deficiency during infancy and preschool age: a longitudinal

observational multiple case study. *Early Hum Dev* 2013;89:49–54.

22. Reinkingh M, Reinders-Messelink HA, Dijkstra PU, Maathuis KGB, van der Sluis CK.

Stump sensibility in children with upper limb reduction deficiency. *J Rehabil Med*

2014;46:51–8.

23. Zuniga JM, Carson AM, Peck JM, Kalina T, Srivastava RM, Peck K. The development of a low-cost three-dimensional printed shoulder, arm, and hand prostheses for children.

Prosthet Orthot Int 2017;41:205–9.

24. Gretsch KF, Lather HD, Peddada KV, Deeken CR, Wall LB, Goldfarb CA.

Development of novel 3D-printed robotic prosthetic for transradial amputees. *Prosthet Orthot*

Int 2016;40:400–3.

25. Ten Kate J, Smit G, Breedveld P. 3D-printed upper limb prostheses: a review. *Disabil*

Rehabil Assist Technol 2017;12:300–14.

26. Diment LE, Thompson MS, Bergmann JH. Three-dimensional printed upper-limb

prostheses lack randomised controlled trials: A systematic review. *Prosthet Orthot Int*

2018;42:7–13.

Figure legends

Fig. 1. Plain radiograph of patient 4 at the age of 7 months, showing a very short ulna (24 mm in length).

Fig. 2. Radiographs of patient 4 immediately after surgery (A), after 1 month of lengthening (B), and after 3 months of lengthening (C).

Fig. 3. Radiographs of patient 4 at 7 years of age (at last follow-up), showing an ulna measuring 77 mm in length.

Fig. 4. Patient 4 at 7 years of age.

Table titles

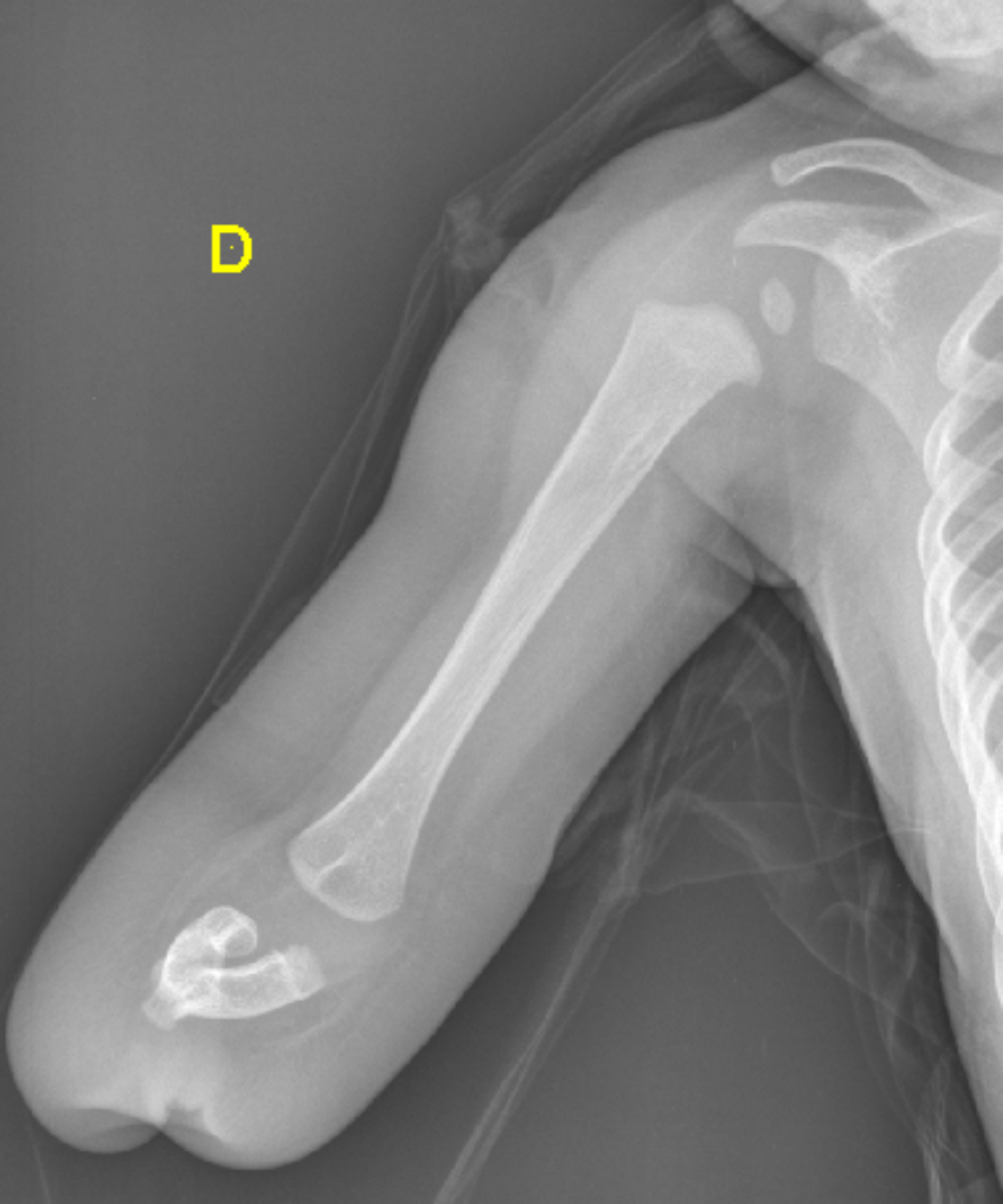
Table 1. Scoring for the Prosthetic Upper Extremity Functional Index (PUFI)

Table 2. Data for each patient

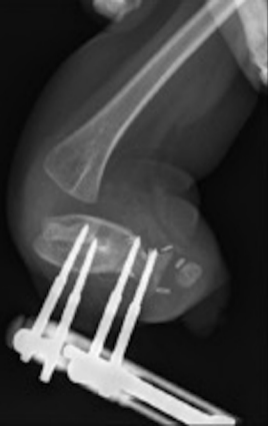Table 3. The PUFI “method of performance” score, averaged for the four patients

Table 4. The PUFI “ease of performance” score, averaged for the four patients

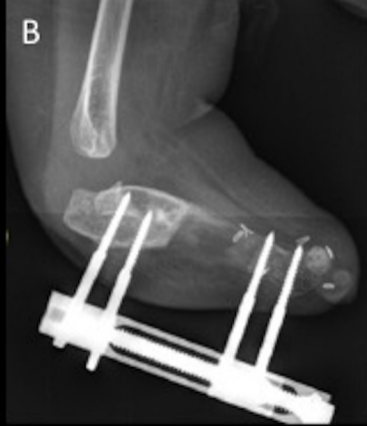D



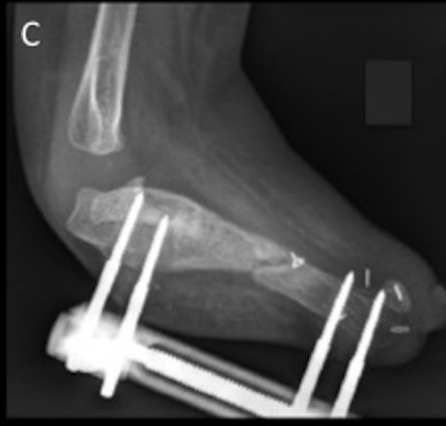A



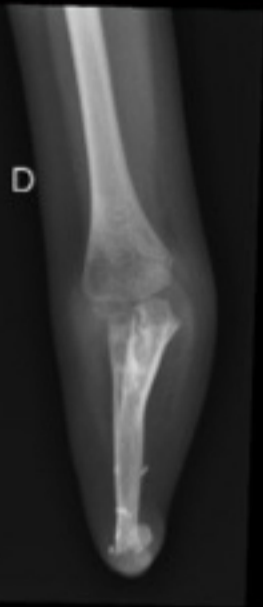B



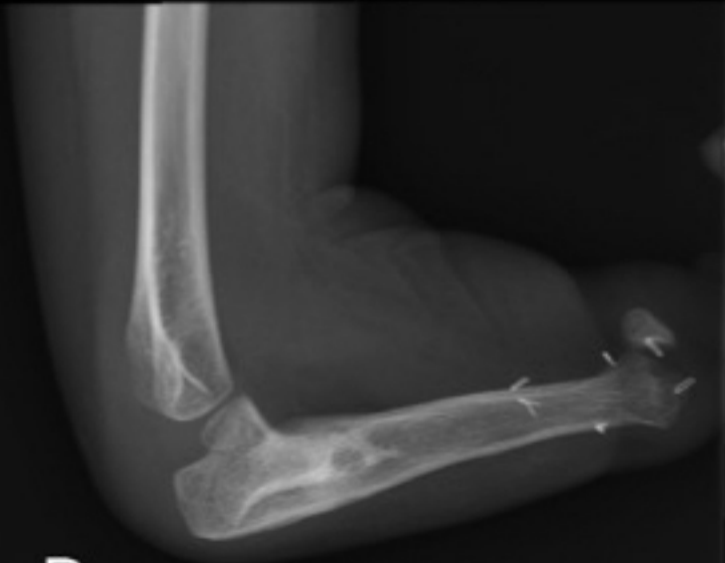C



D



D



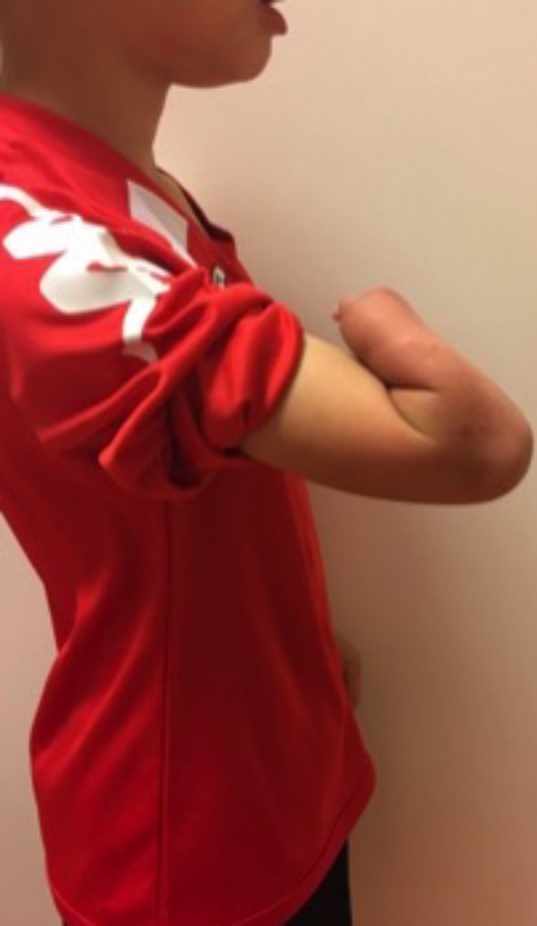

Table 1. Scoring for the Prosthetic Upper Extremity Functional Index (PUFI)

	“Method of performance”	“Ease of performance”
5	uses the operated limb actively	no difficulty
4	uses the operated limb passively	some difficulty
3	with the residual limb	great difficulty
2	without the prosthesis (with the non-prosthetic hand only)	with help from someone else
1	needs someone’s assistance	cannot do
0	cannot do, even with help	<i>not applicable</i>

Table 2. Data for each patient

Patient Number	1	2	3	4
Sex	F	F	M	M
Pathology	Amniotic band syndrome	Developmental failure	Developmental failure	Developmental failure
Follow-up (years)	8.8	5.6	5.7	4.6
Age at last follow-up	15	8.5	9.4	7.1
Age at first prosthesis (months)	48	24	24	9
ICT	no	yes	yes	yes
Age at ICT(months)	NA	12	12	9
Lengthening after ICT	NA	13	15	13
Number of UL	3	2	1	1
Ulnar length before UL	40	55	47	43
Age at UL (years)	6.2/8.5/9.5	2.9/6.8	3.7	2.5
Gain after UL (mm)	24/15/19	21/20	21	27
Lengthening duration (days)	70/50/50	60/68	60	60
Treatment duration (days)	190/120/150	120/152	150	130
Healing index	79/80/79	57/76	71	48
Complications of UL	premature union	ulno-humeral dislocation	none	infection
ROM before surgery	complete	complete	complete	complete
Elbow extension	100	0	0	0
Elbow flexion	140	140	140	140
Prosthesis used	cosmetic	functional	functional	functional
Reason first prosthesis was rejected	no functional gain	inconvenient	inconvenient	inconvenient

UL: ulna lengthening; *ICT*: iliac crest transfer

Table 3. The PUFI “method of performance” score, averaged for the four patients

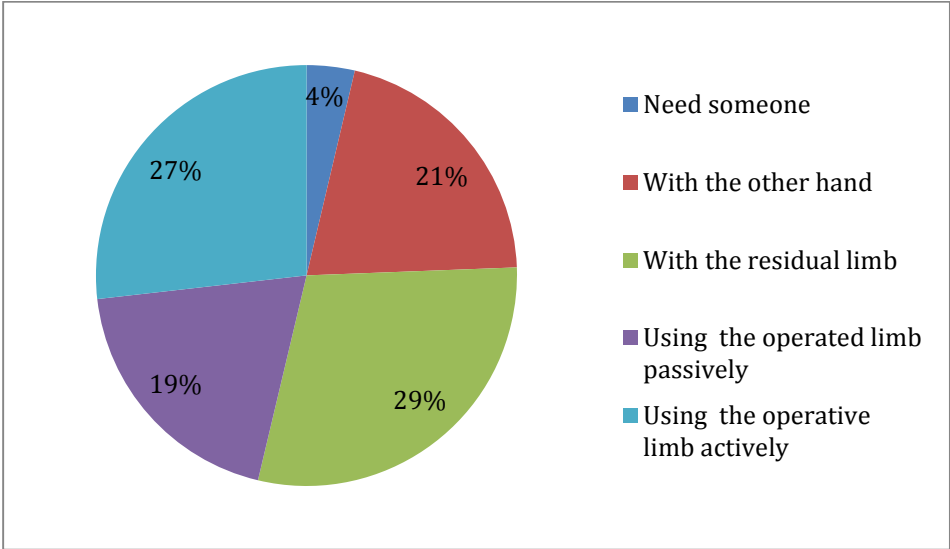


Table 4. The PUF1 “ease of performance” score, averaged for the four patients

