



HAL
open science

Interest of video-otoscopy for the general practitioner

L. Damery, E. Lescanne, K. Reffet, C. Aussedat, D. Bakhos

► To cite this version:

L. Damery, E. Lescanne, K. Reffet, C. Aussedat, D. Bakhos. Interest of video-otoscopy for the general practitioner. *European Annals of Otorhinolaryngology, Head and Neck Diseases*, 2019, 136, pp.13 - 17. <10.1016/j.anorl.2018.10.016>. <hal-03486488>

HAL Id: hal-03486488

<https://hal.science/hal-03486488v1>

Submitted on 20 Dec 2021

HAL is a multi-disciplinary open access archive for the deposit and dissemination of scientific research documents, whether they are published or not. The documents may come from teaching and research institutions in France or abroad, or from public or private research centers.

L'archive ouverte pluridisciplinaire HAL, est destinée au dépôt et à la diffusion de documents scientifiques de niveau recherche, publiés ou non, émanant des établissements d'enseignement et de recherche français ou étrangers, des laboratoires publics ou privés.



Distributed under a Creative Commons CC BY-NC 4.0 - Attribution - Non-commercial use - International License

Interest of video-otoscopy for the general practitioner

L. Damery¹; E. Lescanne¹⁻²; K. Reffet²; C. Aussedat²; D. Bakhos^{1-2*}

1- Faculté de Médecine de Tours, Université François-Rabelais de Tours, CHRU de Tours, 2 Boulevard Tonnellé, 37044 Tours, France.

2- Service ORL et Chirurgie Cervico-Faciale, CHRU de Tours, Boulevard Tonnellé, 37044 Tours, France

* Corresponding author:

e-mail: david.bakhos@univ-tours.fr (David Bakhos)

Service d'ORL, INSERM-U930, CHRU Tours, 2 boulevard Tonnellé, 37000 Tours, France

Tel: +33 247 474 785

Fax: +33 247 473 600

Abstract

Introduction: General practitioners (GPs) play an essential role in the management of ear disease, but their diagnosis of pathologic eardrums is inadequate. The aim of this study was to compare the quality of otoscopic diagnosis by GPs using a conventional otoscope versus a video-otoscope.

Subjects and method: Eleven GPs included 124 patients with ear complaints (193 otoscopies). Examination successively used conventional otoscopy and video-otoscopy. After each type of examination, a 10-criterion assessment questionnaire was filled out and a diagnosis was proposed. Two blinded ENT specialists reviewed the video-otoscopy images and filled out the same grid questionnaire to make their diagnosis. GPs also completed a Likert-scale satisfaction questionnaire on video-otoscopy.

Results: There were no significant differences in overall examination results between the three groups (GP conventional otoscopy, GP video-otoscopy and ENT specialist). However, focusing exclusively on pathologic eardrums, there was a significant difference in results between ENT specialists and GPs using a conventional otoscope ($p = 0.0032$); this was not the case when GPs used video-otoscopy ($p = 0.0754$). All GPs expressed enthusiastic interest in video-otoscopy, even when not convinced to make the purchase.

Conclusion: Video-otoscopy showed superiority over conventional otoscopy in assessing pathological eardrums.

Key-words: otoscopy; video-otoscopy; general practitioners; ENT; assessment

Introduction

Otoscopy is a routine examination not only for ENT specialists but also for general practitioners (GPs) and pediatricians. It is an essential step in clinical examination for ear complaints. Functional and general signs are indispensable to diagnosis, but are neither sensitive nor specific, especially in children presenting with acute otitis media (AOM) [1]. According to the French health products safety agency (AFSSAPS), otoscopy is the key step in diagnosis [2, 3]. However, clinical examination using a conventional speculum otoscope is not easy, hindered by malpositioning of the instrument, poor luminosity, cerumen blockage, otorrhea or only partial eardrum visualization [4]. Eardrum visualization needs to be at least 75% for diagnosis according to the AFSSAPS [3]; this corresponds to the area accessible to conventional otoscopy in everyday practice, and requires the practitioner to manipulate to speculum so as to assess the entire eardrum.

In pediatrics, these difficulties are compounded by the child's narrow outer ear canal (OEC), the orientation of the eardrum and the child's restlessness.

These limitations of conventional otoscopy add to the uncertainty of diagnosis, whereas correct diagnosis is essential in determining treatment strategy. Overdiagnosis can lead to unnecessary prescription of antibiotics, systematic use of which increases the risk of side-effects and resistance [5, 6]. Misdiagnosis equally may have serious consequences. AOM rates in adults are only 0.25% (7), but delayed treatment can incur very severe complications: mastoiditis, meningitis or brain abscess [7-10].

In young children, diagnosis of otitis media with effusion (OME) is often delayed. The child is asymptomatic, with no complaints, yet the pathology impacts oral language acquisition [11, 12]. OME increases the risk of learning difficulties [13] due to conduction hearing loss [14] by retrotympenic effusion.

Given the high frequency of ear disease, GPs play an essential role in optimal management; however, they use conventional otoscopes, with their inherent limitations.

For some years now, video-otoscopy has enabled a video camera to be introduced in the OEC, optimizing visualization and allowing images of the eardrum to be taken.

The aim of the present study was to compare GPs' otoscopic performance using, successively, a conventional otoscope and a video-otoscope.

Subjects and method

A descriptive qualitative study was conducted over a 3-month period, with review board approval from Tours University Hospital (project number: 2016 048).

Subjects

Twenty GPs were contacted for the study, 11 of whom agreed to participate. Mean age was 38 ± 12.62 years, with mean professional experience of 9.82 ± 9.64 years. The mean number of otoscopies per day per GP was 5.63 ± 5.14 .

Method

The study protocol was explained in individual interviews.

GPs were requested, when performing otoscopy for etiological purposes or as routine examination, notably in young children, to follow conventional otoscopy by video-otoscopy (AURICAL[®] OTOcam 300). The video equipment was lent to them at the initial interview.

After the conventional examination, the GP filled out a questionnaire (Appendix 1) with 10 items and a total score out of 10 (1 point per item). Thus, for each otoscopic examination, the score could range from 0 (normal eardrum) to 10, corresponding to abnormalities found on examination. The GP then immediately made a diagnosis. These data constituted the "GP conventional" group. The reason for consultation and relevant clinical information were also recorded. In the same consultation, in agreement with the patient,

video-otoscopy was then performed, with an image of the eardrum. The GP again filled out the same questionnaire, and again made a diagnosis. These data constituted the “GP video” group. If the GP failed to perform one of the two examinations, the patient was excluded from the study.

At the end of the 2-week loan period, the GP was asked to make a qualitative assessment of the video-otoscopy equipment, on a 5-item Likert-scale questionnaire (Appendix 2).

At the end of the study, the video-otoscopy images were analyzed in double blind by two ENT specialists. They filled out the same questionnaire as the GPs, and were aware of the reason for consultation. Their scores and diagnoses constituted the “ENT” group.

Statistical analysis

Groups were compared on Wilcoxon signed ranks test.

Results

One hundred and twenty four patients (193 otoscopies) were included, with a mean age of 41 ± 22.7 years. Only 163 otoscopies and video-otoscopies, for 108 patients with a mean age of 42 ± 22 years, were analyzed, in view of video-otoscopy image quality; the video-otoscopy failure rate was 16%. Reasons for consultation comprised: otalgia (35%), hypoacusis (16%), peripheral vertigo (9%), tinnitus (9%), sinonasal infection (6%), ENT infection (13%), otorrhea (< 1%), bleeding otorrhea (<1%), outer ear canal pruritus (2%), isolated fever (3%), pinna pain (2%), and barotrauma (<2%).

Otoscopic performance

In the ENT group, the mean score on the 163 otoscopies was 0.84 ± 1.16 . Seventy-nine were pathologic (score > 0), with a mean score of 1.73 ± 1.12 : OME (N=5), AOM grade 6

(N=4), congestive AOM (grades 3,4 and 5) (N=11), erythematous eardrum (N=11), retraction (N=11), perforation (N=1), cerumen blockage (N=16), external otitis (N=5), cholesteatoma (N=1), OEC erythema (N=9), OEC osteoma (N=2), and tympanic remodeling (N=3).

In the GP Conventional group, the mean score was 0.77 ± 1.14 for all otoscopies included in the study, and 1.37 ± 1.34 for pathological otoscopies.

In the GP Video group, the mean score was 0.83 ± 1.22 overall, and 1.59 ± 1.3 for pathological otoscopies.

There was no significant difference in overall otoscopy score between the Conventional and Video groups (*Figure 1*).

Analysis per item, on the other hand, found significant differences for erythematous eardrum ($W=63$; $p=0.023$), convex eardrum ($W=-35$; $p=0.039$) and OEC erythema ($W=45$; $p=0.0039$). The same differences were found between the ENT and GP conventional groups, plus retrotympenic effusion ($W=-95$; $p=0.031$). The only significant difference between the ENT and GP Video groups was for retrotympenic effusion ($W=-119$; $p=0.0005$).

In pathologic otoscopies (*Figure 2*), there were no significant differences between the ENT and GP Video groups ($W=220$; $p=0.08$), while there were significant differences between the ENT and GP Conventional ($W=557$; $p=0.003$) and GP Conventional and GP Video groups ($W=322$; $p=0.039$).

Item comparison between the GP Conventional and GP Video groups found a significant difference for OEC erythema ($W=36$; $p=0.008$). The ENT and GP Conventional groups differed significantly on eardrum erythema ($W=119$; $p=0.0005$), convex eardrum ($W=-21$; $p=0.031$) and OEC erythema ($W=168$; $p=0.0004$). The ENT and GP Video groups

differed significantly on retrotympanic effusion ($W=-77$; $p= 0.003$) and OEC erythema ($W=52$; $p= 0.039$).

In 33 of the 163 otoscopies, diagnosis differed between conventional and video GP examination (20%). In 18 of these cases, the GP video diagnosis agreed with the ENT diagnosis (55%, or 11% of all otoscopies), unlike the conventional GP diagnosis. In 9 cases the conventional GP diagnosis agreed with the ENT diagnosis but not with the GP video diagnosis (27% of discordant diagnoses, or 5.5% of all otoscopies).

Video equipment satisfaction

Table 1 presents GPs' satisfaction with the video-otoscopy equipment. The vast majority found it improved performance and that it was easy to use. However, a majority did not find it interesting from the point of view of telemedicine or interaction with the patient.

Results according to GP experience

Mean overall otoscopy score was 0.8 ± 1.2 for GPs aged <38 years versus 0.95 ± 1.1 for GPs aged >38 years; for pathological otoscopies, mean scores were respectively 1.54 ± 1.4 and 1.74 ± 1 .

There was no significant difference according to age for overall ($W=2271$; $p=0.2303$) or pathologic otoscopy score ($W=512$; $p= 0.1472$).

On the satisfaction questionnaire, younger GPs rated all items higher, except for the interest of video-otoscopy for telemedicine, which was rated higher by over 38-year-olds.

Discussion

In the present study, video-otoscopy proved superior to conventional otoscopy for the analysis of pathologic eardrum images. GPs were also very largely enthusiastic about this diagnostic technique.

Several studies highlighted the inadequacy of GPs' otoscopic performance [4, 15]. AOM was reported to be overdiagnosed by GPs in 22% of cases [16], and even more when examination conditions are difficult. On conventional otoscopy, GPs diagnose AOM with certainty in 67% of under-2 year-olds, compared to 75% in over-2 year-olds [4]. Factors for uncertainty comprise: incomplete eardrum visualization, child's restlessness, faulty otoscope orientation, and lack of luminosity [4]. In the present study, AOM was overdiagnosed in 3 cases of congestive eardrum without retrotympenic effusion.

GPs were reported to diagnose OME in 53% of cases [15]. In the present study, OME was overdiagnosed in 15 cases in the GP Conventional group, compared to 12 cases in the GP Video group. This diagnosis is not easy to make, as GPs do not find the otoscopic criteria consensual, and a certain learning curve is required [17]. Nevertheless, in the present study, age and years of practice were not significant factors, suggesting that experience in itself does not make up for lack of primary training in otoscopy [15].

The above diagnostic failings can delay treatment and lead to complications, and remedying this is an international concern [18]. In the present study, scores were better overall with video-otoscopy than conventional otoscopy, and diagnoses were more reliable. There were no significant differences between the ENT and GP Video groups. These findings are in agreement with previous reports [19].

While conventional otoscopy visualizes only three-quarters of the eardrum [3], video-otoscopy provides a complete view of both eardrum and OEC. Moreover, the images facilitate retrospective interpretation by respecting colors and allowing enlargement, improving

diagnosis and enabling a second opinion to be sought if necessary. On the other hand, in 16% of cases the images could not be used due to poor quality, and no diagnosis could be made, which would not be the case in conventional otoscopy.

Despite their enthusiasm, most GPs were not prepared to actually buy a video-otoscope, for reasons of: price, the necessity of accompanying IT material (whether laptop or desktop), and ergonomic factors such as cable length. Also, having the patient lying on an examination table can make it difficult to see the screen displaying the otoscopy. At the outset of the study, it was clear that GPs hesitated to spend time to familiarize themselves with the equipment.

Some authors report that image quality improves with practice [20] and acquisition time shortens [21]. We think it is preferable to begin with adult patients before trying to record young children, who may be uncooperative.

Apart from these reservations, all GPs agreed that video-otoscopy improved interaction with the patient and the patient's understanding of his or her pathology, resulting in better compliance. These findings are in agreement with the literature [21].

Video-otoscopy is a useful tool for telemedicine so long as the digital images are of good quality and the clinical information is precise enough to guide the ENT specialist [22]. Remote diagnosis by a specialist relying on images was shown to be as good as that achieved in direct specialist consultation [19, 23]. This is an interesting option for patients with reduced mobility.

Resort to specialist opinion is increasingly common, with consequent delays to treatment. Video-otoscopy could ease the present referral bottleneck [24], reducing geographical and demographic limitations by developing innovative forms of healthcare organization [25].

The present study had several limitations, including the low GP response rate despite the number originally contacted, and the fact that half of the otoscopies showed normal results, certainly because of the wide inclusion criteria. None of the GPs used video-otoscopy in under-3 year-olds. It should be noted that otoscopy in GP consultation can be difficult in young children, and that examination sometimes needs repeating to establish diagnosis. Video-otoscopy with image recording allows the examination to be reviewed and a second opinion sought in case of doubt.

Conclusion

The present study sought to compare GP interpretation of otoscopy using two techniques: conventional and video.

Video-otoscopy provided better interpretation of pathologic eardrums. It improved GPs' diagnostic performance and enhanced interaction with the patient by describing the otoscopy in consultation. It may also be useful in telemedicine, especially in areas with poor medical cover, where access to specialists is difficult.

Video-otoscopy helps improve GOP diagnosis. However, lack of GP training in otology hinders diagnostic quality. Continuous training sessions using video images of pathological eardrums would be beneficial for GPs.

Disclosure of Interest: The authors declare that they have no conflicts of interest concerning this article

References

- [1] Niemela M, Uhari M, Jounio-Ervasti K, Luotonen J, Alho OP, Vierimaa E. Lack of Specific Symptomatology in Children with Acute Otitis Media. *Pediatr Infect Dis J.* 1994 ; 13(9): 765-8.
- [2] Weiss J. C, Yates GR, Quinn LD. Acute Otitis Media: Making an Accurate Diagnosis. *Am Fam Physician.* 1996 ; 53(4) : 1200-6.
- [3] Agence française de sécurité sanitaire des produits de santé. Antibiothérapie par voie générale en pratique courante dans les infections respiratoires hautes de l'adulte et de l'enfant. *Argumentaire*, novembre 2011 p14.
- [4] Jensen, PM, Lous J. Criteria, performance and diagnostic problems in diagnosing acute otitis media. *Fam Pract.* 1999; 16(3) 262-8.
- [5] Venekamp RP, Sanders SL, Glasziou PP, Del Mar CB, Rovers MM. Antibiotics for Acute Otitis Media in Children. *The Cochrane Database Syst Rev.* 2015; 23:6: CD000219.
- [6] Costelloe C, Metcalfe C, Lovering A, Mant D, Hay AD. Effect of Antibiotic Prescribing in Primary Care on Antimicrobial Resistance in Individual Patients: Systematic Review and Meta-Analysis. *BMJ.* 2010 ; 18 :340 :c2096.
- [7] Schwartz LE, Brown RB. Purulent Otitis Media in Adults. *Arch Intern Med.* 1992; 152 (11): 2301-4.
- [8] Heah H, Soon SR, Yuen HW. A Case Series of Complicated Infective Otitis Media Requiring Surgery in Adults. *Singapore Medical J.* 2016; 57(12): 681-5.
- [9] Hafidh MA, Keogh I, Walsh RM, Walsh M, Rawluk D. Otogenic Intracranial Complications. a 7-Year Retrospective Review. *Am J Otolaryngol.* 2006; 27(6): 390-5.

- [10] Leskinen, K, Jero J. Acute Complications of Otitis Media in Adults. *Clin Otolaryngol* 30(6): 511-6.
- [11] Uclés P, Alonso MF, Aznar E, Lapresta C. The Importance of Right Otitis Media in Childhood Language Disorders. *Int J Otolaryngol*. 2012 ;2012 :818927.
- [12] Zumach A, Gerrits E, Chenault M, Anteunis L. Long-Term Effects of Early-Life Otitis Media on Language Development. *J Speech Lang Hear Res*. 2010;53(1): 34-43.
- [13] Williams CJ, Jacobs AM. The Impact of Otitis Media on Cognitive and Educational Outcomes. *Med J Aust*. 2009 ; 191(9 Suppl): S69-72.
- [14] Gravel, J. S., et I. F. Wallace. Effects of Otitis Media with Effusion on Hearing in the First 3 Years of Life. *J Speech Lang Hear Res*. 2000; 43 (3):631-44.
- [15] Buchanan CM, Pothier D. Recognition of Paediatric Otopathology by General Practitioners. *Int J Pediatr Otorhinolaryngol*. 2008 ; 72(5): 669-73.
- [16] Legros JM, Hitoto H, Garnier F, Dagorne C, Parot-Schinkel E, Fanello S. Clinical Qualitative Evaluation of the Diagnosis of Acute Otitis Media in General Practice. *Int J Pediatr Otorhinolaryngol*. 2008 72(1): 23-30.
- [17] Jones WS, Kaleida PH, Lopreiato JO. Assessment of Pediatric Residents' Otolaryngologic Interpretive Skills by Videotaped Examinations. *Ambul Pediatr*. 2004; 4(2): 162-5.
- [18] Dowell, Scott F., S. Michael Marcy, William R. Phillips, Michael A. Gerber, et Benjamin Schwartz. Otitis Media—Principles of Judicious Use of Antimicrobial Agents. *Pediatrics*. 1998; 101(1): 165-71.

- [19] Biagio L, Swanepoel de W, Laurent C, Lundberg T. Video-Otoscopy Recordings for Diagnosis of Childhood Ear Disease Using Telehealth at Primary Health Care Level. *J Telemed Telecare*. 2014 ; 20(6): 300-306.
- [20] Biagio L, Swanepoel de W, Adeyemo A, Hall JW, Vinck B. Asynchronous Video-Otoscopy with a Telehealth Facilitator. *Telemed J EHealth*. 2013; 19(4): 252-8.
- [21] Rimon O, Avraham Y, Sharabi-Nov A, Luder A, Krupik D, Gilbey P. Video-Otoscopy in Children and Patient-Centered Care: A Randomized, Controlled Study. *Int J Pediatr Otorhinolaryngol*. 2015; 79(12):2286-9.
- [22] Eikelboom RH, Mbaomn, Coates HL, Atlas MD, Gallop MA. Validation of Tele-Otology to Diagnose Ear Disease in Children. *Int J Pediatr Otorhinolaryngol*. 2005; 69(6): 739-44.
- [23] Smith AC, Dowthwaite S, Agnew J, Wootton R. Concordance between Real-Time Telemedicine Assessments and Face-to-Face Consultations in Paediatric Otolaryngology. *Medical J Aust*. 2008 ; 188(8) : 457-60.
- [24] Swanepoel de W, Hall JW. A Systematic Review of Telehealth Applications in Audiology. *Telemedicine Journal and E-Health: The Official Journal of the American Telemedicine Association*. 2010; 16(2): 181-200.
- [25] Govender SM, Mars M. The Use of Telehealth Services to Facilitate Audiological Management for Children: A Scoping Review and Content Analysis. *J Telemed Telecare*. 2017 ; 23(3) :392-401.

Table 1: GP assessment of video-otoscopy equipment

	Completely agree N (%)	Agree N (%)	Neither agree nor disagree N (%)	Disagree N (%)	Completely disagree N (%)
Video-otoscopy could help improve your diagnostic performance	4 (36.4%)	4 (36.4%)	2 (18.2%)	1 (9%)	0 (0%)
The equipment is easy to use	1 (9%)	7 (63.8%)	2 (18.2%)	1 (9%)	0 (0%)
You would be prepared to purchase it	0 (0%)	4 (36.4%)	0 (0%)	7 (63.8%)	0 (0%)
Video-otoscopy could be useful for telemedicine	6 (54.6%)	5 (45.4%)	0 (0%)	0 (0%)	0 (0%)
Video-otoscopy could be useful for interaction with the patient	9 (81.8%)	2 (18.2%)	0 (0%)	0 (0%)	0 (0%)

Figure 1: Mean scores of 3 groups for all otoscopies.

Mean ENT: mean otoscopy performance of ENT specialists; Mean GP video: mean otoscopy performance of GPs using video-otoscopy; Mean GP conv: mean otoscopy performance of GPs using conventional otoscopy

Figure 2: Mean scores of 3 groups for pathological otoscopies.

Mean ENT: mean otoscopy performance of ENT specialists; Mean GP video: mean otoscopy performance of GPs using video-otoscopy; Mean GP conv: mean otoscopy performance of GPs using conventional otoscopy; NS: non-significant; * significant difference

Appendix 1: Ooscopic criteria (grade out of 10)

	YES	NO
Erythematous eardrum		
Loss of relief		
Retrotympanic effusion		
Convex eardrum		
Perforated eardrum		
Eardrum retraction		
Scales, epidermal debris		
Otorrhea		
OEC erythema		
Cerumen blockage		
Your diagnosis		

Appendix 2: Qualitative assessment of video-otoscopy equipment

A. Video-otoscopy could help **improve your diagnostic performance**

1. Completely agree
2. Agree
3. Neither agree nor disagree
4. Disagree
5. Completely disagree

B. The equipment is **easy to use**

1. Completely agree
2. Agree
3. Neither agree nor disagree
4. Disagree
5. Completely disagree

C. You would be prepared to **purchase it**

1. Completely agree
2. Agree
3. Neither agree nor disagree
4. Disagree
5. Completely disagree

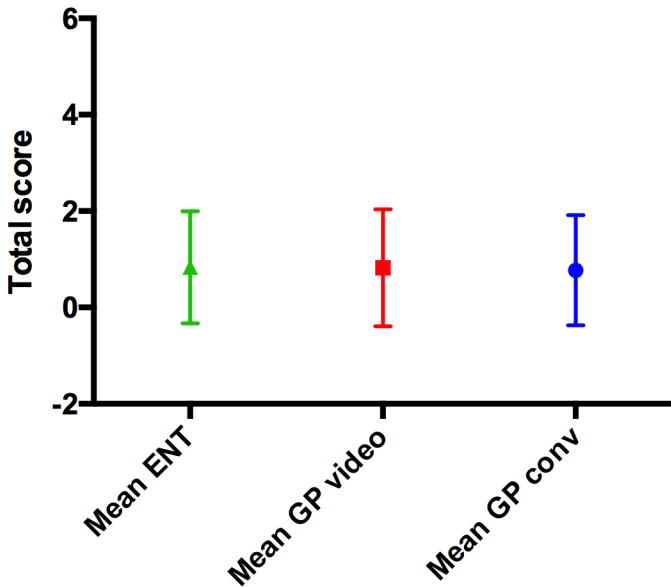
D. Video-otoscopy could be **useful for telemedicine**

1. Completely agree
2. Agree
3. Neither agree nor disagree
4. Disagree
5. Completely disagree

E. Video-otoscopy could be **useful for interaction with the patient**, including helping him or her understand the pathology

1. Completely agree
2. Agree
3. Neither agree nor disagree
4. Disagree
5. Completely disagree

Otosopic performance: inter-group comparison



Otosopic performance: inter-group comparison

