



HAL
open science

Gain of exposure provided by extended incision in lateral rhinotomy approach: A cadaveric study

A. Dinnoo, C. Vacher, P. Herman, B. Verillaud

► To cite this version:

A. Dinnoo, C. Vacher, P. Herman, B. Verillaud. Gain of exposure provided by extended incision in lateral rhinotomy approach: A cadaveric study. *Morphologie*, 2019, 103, pp.32 - 36. 10.1016/j.morpho.2018.10.003 . hal-03486444

HAL Id: hal-03486444

<https://hal.science/hal-03486444>

Submitted on 20 Dec 2021

HAL is a multi-disciplinary open access archive for the deposit and dissemination of scientific research documents, whether they are published or not. The documents may come from teaching and research institutions in France or abroad, or from public or private research centers.

L'archive ouverte pluridisciplinaire **HAL**, est destinée au dépôt et à la diffusion de documents scientifiques de niveau recherche, publiés ou non, émanant des établissements d'enseignement et de recherche français ou étrangers, des laboratoires publics ou privés.



Distributed under a Creative Commons Attribution - NonCommercial 4.0 International License

GAIN OF EXPOSURE PROVIDED BY EXTENDED INCISION IN LATERAL
RHINOTOMY APPROACH: A CADAVERIC STUDY

APPORTS DES TRAITS DE REFEND A LA VOIE DE RHINOTOMIE LATERALE : UNE
ETUDE SUR SUJETS ANATOMIQUES.

Authors:

A. Dinnoo¹, C. Vacher², P. Herman¹, B. Verillaud¹.

¹Department of Otorhinolaryngology, Hôpital Lariboisière, AP-HP, Université Paris 7, 2 rue
Ambroise Paré, 75010 Paris, France.

²Department of Maxillo-facial surgery, Hôpital Beaujon, AP-HP, Université Paris 7,
Boulevard du Général Leclerc, 92110 Clichy, France.

Corresponding author:

Aïna Dinnoo

ainadinnoo@yahoo.fr

Tel : +33 6 99 88 89 00

Fax : +33 1 49 95 80 63

Conflit d'intérêts : aucun.

No conflict of interest.

Key words: lateral rhinotomy, weber ferguson, exposure, cadaveric study

APPORTS DES TRAITS DE REFEND A LA VOIE DE RHINOTOMIE LATÉRALE : UNE ETUDE SUR SUJETS ANATOMIQUES.

RESUME

Objectif : évaluer le gain supplémentaire en termes d'exposition apporté par l'ajout d'un trait de refend (sous-ciliaire, labial ou mixte : voie de Weber-Fergusson) à la voie de rhinotomie latérale (RL), et comparer les champs d'exposition offerts par ces incisions. L'objectif final est d'affiner les indications de ces différentes voies transfaciales.

Matériels et méthodes : Etude prospective sur sujets anatomiques frais congelés. Etait d'abord réalisée une incision de RL, puis des traits de refend sous-ciliaire et/ou labial. Pour chaque situation, l'exposition du squelette antérieur et des espaces profonds rétromaxillaires (fosse ptérygopalatine et fosse infratemporale) était évaluée, en mesurant notamment la distance entre l'os propre du nez et la zone la plus latérale de l'exposition.

Résultats : 4 têtes ont été disséquées avec 7 voies de RL : 3 avec refend sous-ciliaire, 3 avec refend labial, 4 voies de Weber-Fergusson. La voie de RL n'offrait qu'un accès limité au rebord orbitaire externe, à l'arcade zygomatique et à la tubérosité maxillaire. Les traits de refend sous-ciliaire et labial donnaient accès au rebord orbitaire externe et à l'arcade zygomatique, mais seul le refend labial donnait un accès correct à la tubérosité maxillaire. L'incision de Weber-Fergusson offrait une exposition équivalente à la voie de RL avec refend labial. Les voies de RL avec ou sans refend permettaient une exposition équivalente des espaces profonds étudiés.

Conclusion : Le trait de refend labial permettait d'obtenir une exposition maximale, équivalente à celle offerte par une voie de Weber-Fergusson. Aucun refend n'apportait de bénéfice dans l'exposition des espaces profonds.

Mots clés : Voie transfaciale ; voie paralatéronasale ; voie de rhinotomie latérale, voie de Weber-Fergusson ; maxillectomie ; étude cadavérique

GAIN OF EXPOSURE PROVIDED BY EXTENDED INCISION IN LATERAL RHINOTOMY APPROACH: A CADAVERIC STUDY

ABSTRACT

Objective: to assess the gain of exposure provided by extensions of the lateral rhinotomy (LR) incision, including subciliary extension, lip-splitting extension, or both (Weber-Fergusson incision), by comparing the surgical field obtained with every incision. The final goal is to better delineate the indications of each approach.

Materials and methods: Prospective study on fresh frozen specimens. A LR incision was first performed, and then extended by subciliary and/or lip-splitting incisions. The exposure of the anterior facial skeleton and of the deep retromaxillar spaces (pterygopalatine fossa and infratemporal fossa) were assessed. The distance between the nasal bone and the most lateral part of the exposure was measured.

Results: Dissection was performed on 4 specimens, with 7 LR. Three LR incisions were extended with subciliary incision, 3 with lip-splitting incision, and 4 with Weber-Fergusson incision. LR incision alone gave only limited access to the lateral orbital rim, the zygomatic arch and the maxillary tuberosity. Both subciliary and lip-splitting incisions gave access to the lateral orbital rim and to the zygomatic arch, but only upper lip incision provided a good access to the maxillary tuberosity. Weber-Fergusson did not significantly increase the surgical field obtained with lip-splitting extension alone. The exposure of the deep retromaxillar spaces was the same in all cases.

Conclusion: LR incision with lip-splitting extension provided an optimal access to the anterior facial skeleton and to the maxillary tuberosity. In terms of exposure, it was equivalent to Weber-Fergusson approach. The exposure of deep spaces was the same regardless of the incision.

Key words: Transfacial approach; lateral rhinotomy; Weber-Fergusson; maxillectomy; cadaveric study

Introduction:

The surgical management of tumors of the sinonasal cavities and deep retromaxillar spaces has deeply evolved with the advent of endoscopic techniques [1]. However open approaches remain necessary in certain situations. Several incisions derived from the basic lateral rhinotomy (LR) incision have been described, including the subciliary incision, the lip-splitting incision, and the combination of both (Weber-Fergusson incision) [2]. Depending on the authors, the indications of these approaches sometimes overlap, and the final choice of the best incision is not always easy. The aim of this study was to assess precisely the differences in terms of exposure provided by the extensions of the LR incision, in order to better define the indication of every approach.

Materials and methods:

This was a prospective study on fresh frozen specimens. Dissections were performed at the « Laboratoire d'anatomie des Saint Pères, UFR Biomédicale de l'Université Paris Descartes » and at the « Ecole de chirurgie du Fer à moulin de l'Assistance Publique - Hôpitaux de Paris (AP-HP) ». A basic RL incision was performed first, and then extended with subciliary incision, upper-lip incision, or Weber-Fergusson incision. The infraorbital nerve (V2) was systematically preserved. In every situation, the exposure of the following structures was assessed: nasal bone, piriform aperture, inferior/lateral orbital rim, infraorbital foramen, zygomatic arch, and maxillary tuberosity. Measurements were made to assess the distance between the nasal bone and the most lateral part of the anterior exposure. The exposure of deep retro-maxillar spaces, e.g. pterygopalatine fossa (PPF) and infratemporal fossa (ITF), was assessed after removal of the anterior and posterior/lateral wall of the maxillary sinus [3]. An endoscope was used at this step to allow better visualization of the anatomical structures within the deep spaces. The Student test was used to compare continuous quantitative variables. An α risk <0.05 was tolerated. Statistical analysis was performed with R software.

Results:

Dissections were performed on 4 specimens (3 men and 1 woman), with 7 LR incisions. LR was then extended with subciliary incision (n=3), upper lip incision (n=3) or Weber-Fergusson incision (n=4). Examples of these incisions are displayed on Figure 1-3. The surgical field exposures obtained with every incision are summarized in Table 1. LR incision alone provided only limited access to the lateral orbital rim, the zygomatic arch and the maxillary tuberosity. Both subciliary and upper lip incisions gave access to the lateral orbital

rim and to the zygomatic arch, but only upper lip incision provided a good access to the maxillary tuberosity. Weber-Fergusson did not significantly increase the surgical field obtained with lip-splitting extension alone. Measurements displayed in Table 2 confirmed that all extensions provided a better access to the lateral aspects of the anterior skeleton than LR alone, though statistical significance was only reached for lip-splitting incision and Weber-Fergusson in this small sample (6.87 and 6.9 respectively, vs 4.9 cm for RL alone). There was no statistical difference between lip-splitting incision and Weber-Fergusson incision.

The exposure of the deep retromaxillar spaces was the same in all cases. An example of the exposures obtained with LR alone and with Weber-Fergusson incision is displayed in Figure 4.

Discussion:

Midfacial approaches have been developed to address a large range of pathologies, including benign and malignant tumors of the maxilla, of the nasal and paranasal cavities, and of the deep spaces (PPF and ITF). Several incisions have been described, including the LR incision by Moure and Sébilleau in 1902 and LR with subciliary incision by Leroux-Robert in 1951 [4]; these incisions are variations of the original Weber-Fergusson incision, used since the 19th century, which combines a LR incision with additional subciliary and lip-splitting incisions. [5]

Several complications of these approaches have been described: in particular, subciliary incision entails a significant risk of eyelid complications such as eyelid ectropion, lymphedema, or epiphora [6]. Lip-splitting incision may result in lip deformities, oral incompetence, aesthetic compromise, as well as impaired mastication, deglutition, and speech [7]. A retrospective multicentric study on transfacial approaches reported complication rates as high as 19.8%, with an increased risk in patients treated by radiotherapy [8]. Though providing adequate exposure remains the main stake of the approach, it is therefore important to minimize the transfacial incision as much as possible. In this study, we show that LR with lip-splitting incision may be sufficient to provide a good access to the anterior facial skeleton including its more lateral aspects (lateral orbital rim, zygomatic arch), and to the maxillary tuberosity. Subciliary incision didn't add any significant gain in exposure. This would therefore obviate the need for subciliary incision in many situations. If a larger exposure of the orbital walls is needed, several authors have proposed alternatives to the subciliary incision to avoid post-operative eyelid complications: these include subconjunctival incision or extension of the RL incision toward the medial brow (Lynch-type). [3]

Of note, the infraorbital nerve was systematically preserved in our dissections. If a malignant tumor involves V2 in the PPF or in the maxillary sinus, it has to be cut: it is then possible to further dissect the lateral part of the anterior wall of the maxillary sinus, even through a simple LR incision. On the other hand, if V2 is invaded more anteriorly at its exit from the infraorbital foramen, or if the tumor reaches the anterior wall of the maxillary sinus, lip-splitting incision still needs to be performed to allow proper exposure of the tumor and dissection of the anterior facial soft-tissues.

The other conclusion of our study is that extensive transfacial incisions are not needed to access the deep retromaxillar spaces. Indeed, we were able to access the ITF and the PPF in all cases, even through LR incision alone. The endoscope allowed an excellent visualization of the anatomical structures. This is consistent with many reports of endoscope-assisted dissection of the ITF published over the past 15 years [9–12]. Indeed, purely endoscopic approaches are now used routinely for the management of benign lesions of the PPF and ITF [13]. The endoscopic treatment of malignant tumours, however, remains difficult and sometimes controversial. [14] In our opinion, a combined approach should be considered in cases of malignant tumors involving the hard palate, the anterior facial skeleton, the facial soft-tissues, and/or with significant invasion of the orbit. In these situations, the transfacial incision gives access to the anterior part of the tumor, and the endoscope is of great help to dissect the posterior regions behind the tumor (such as the the PPF, the pterygoid plates, or the skull base), and to control possible bleeding from the internal maxillary artery. [9,15]

Conclusion:

In summary, the results of this study suggest that a lip-splitting extension of the LR incision may be sufficient to expose the whole anterior wall of the maxilla up to the zygomatic arch laterally, and to the maxillary tuberosity inferiorly. Subciliary incision performed either alone or in combination with lip-splitting incision (Weber-Fergusson) does not provide additional exposure. Combined with endoscopy, LR approach provides an adequate access to PPF and ITF.

REFERENCES

- [1] Verillaud B, Lize F, Lisan Q, Le Clerc N, Kania R, Froelich S, et al. Chirurgie de la fosse infratemporale et du rhinopharynx par voie antérieure. *EMC - Techniques chirurgicales - Tête et cou* 2016;0(0):1-13 [Article 46-039] n.d.
- [2] Cohen J, Clayman G. *Atlas of Head and Neck Surgery*. United States of America: Saunders;2011. n.d.
- [3] Ehab H. Transfacial approaches: lateral rhinotomy and Weber-Fergusson. Cohen J Clayman G *Atlas Head Neck Surg.*, United States of America: Saunders; n.d., p. 411–8.
- [4] Leroux-Robert J, Ennuyer A. [Cancers of the ethmoid and maxillary bones; anatomoclinical classification; methods of surgical and radiosurgical therapy; results; 104 cases]. *Ann Oto-Laryngol* 1951;68:617–88.
- [5] Fergusson null. King's College Hospital: Excision of the Superior Maxillary Bone. *Prov Med Surg J* 1842;3:381.
- [6] Vural E, Hanna E. Extended lateral rhinotomy incision for total maxillectomy. *Otolaryngol--Head Neck Surg Off J Am Acad Otolaryngol-Head Neck Surg* 2000;123:512–3. doi:10.1067/mhn.2000.108277.
- [7] Eley KA, Watt-Smith SR. The nasolabial approach: a potential alternative to the lip-splitting incision for maxillectomy. *Br J Oral Maxillofac Surg* 2012;50:e6–8. doi:10.1016/j.bjoms.2011.06.005.
- [8] Ganly I, Patel SG, Singh B, Kraus DH, Bridger PG, Cantu G, et al. Complications of craniofacial resection for malignant tumors of the skull base: report of an International Collaborative Study. *Head Neck* 2005;27:445–51. doi:10.1002/hed.20166.
- [9] Roche PH, Fournier HD, Laccourreye L, Mercier P. Surgical anatomy of the infratemporal fossa using the transmaxillary approach. *Surg Radiol Anat SRA* 2001;23:209–13.
- [10] Alfieri A, Jho H-D, Schettino R, Tschabitscher M. Endoscopic endonasal approach to the pterygopalatine fossa: anatomic study. *Neurosurgery* 2003;52:374–8; discussion 378–80.
- [11] Theodosopoulos PV, Guthikonda B, Brescia A, Keller JT, Zimmer LA. Endoscopic approach to the infratemporal fossa: anatomic study. *Neurosurgery* 2010;66:196–202; discussion 202–3. doi:10.1227/01.NEU.0000359224.75185.43.
- [12] Hartnick CJ, Myseros JS, Myer CM. Endoscopic access to the infratemporal fossa and skull base: a cadaveric study. *Arch Otolaryngol Head Neck Surg* 2001;127:1325–7.
- [13] Battaglia P, Turri-Zanoni M, Dallan I, Gallo S, Sica E, Padoan G, et al. Endoscopic endonasal transpterygoid transmaxillary approach to the infratemporal and upper parapharyngeal tumors. *Otolaryngol--Head Neck Surg Off J Am Acad Otolaryngol-Head Neck Surg* 2014;150:696–702. doi:10.1177/0194599813520290.
- [14] Oakley GM, Harvey RJ. Endoscopic Resection of Pterygopalatine Fossa and Infratemporal Fossa Malignancies. *Otolaryngol Clin North Am* 2017;50:301–13. doi:10.1016/j.otc.2016.12.007.
- [15] Rivera-Serrano CM, Terre-Falcon R, Duvvuri U. Combined approach for extensive maxillectomy: technique development and cadaveric dissection. *The Laryngoscope* 2010;120 Suppl 4:S178. doi:10.1002/lary.21642.

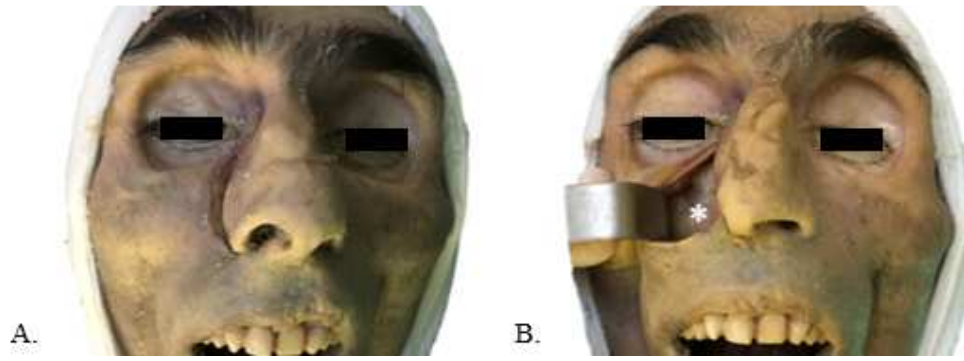


Figure 1. Right lateral rhinotomy approach. A: incision. B: exposure of the anterior wall of the maxilla (white asterisk).

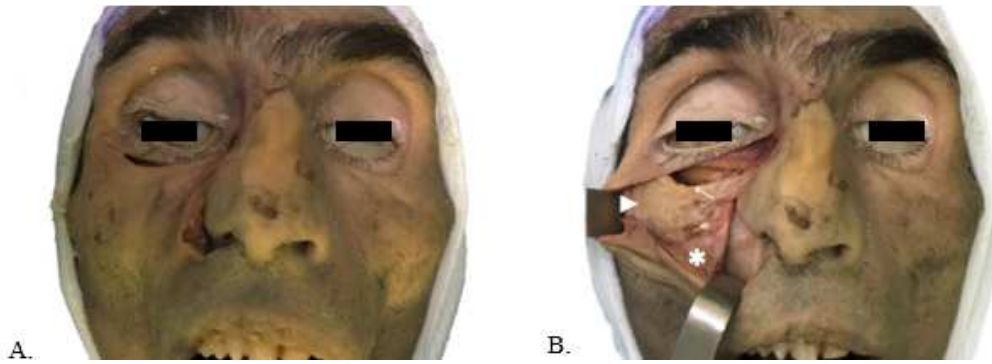


Figure 2. Right lateral rhinotomy approach with subciliary extension. A: incision. B: exposure of the anterior wall of the maxilla (white asterisk), inferior orbital rim (white arrow), and zygomatic bone (white arrowhead)

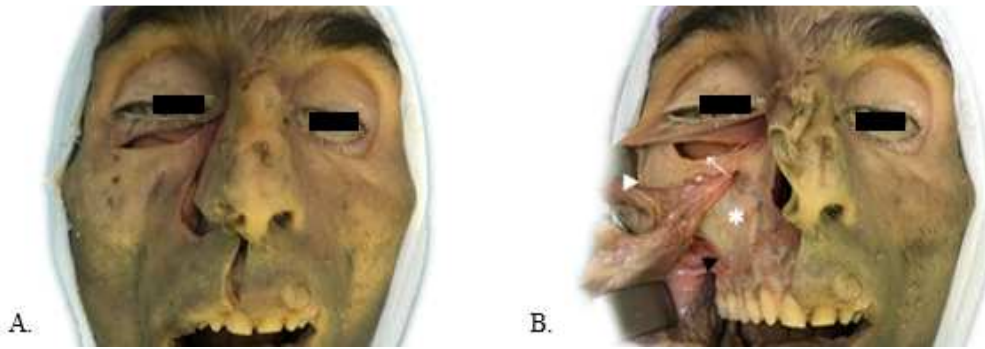


Figure 3. Right Weber-Fergusson approach. A: incision. B: exposure of the anterior wall of the maxilla (white asterisk), inferior orbital rim (white arrow), zygomatic bone (white arrowhead) and maxillary tuberosity (black arrowhead)

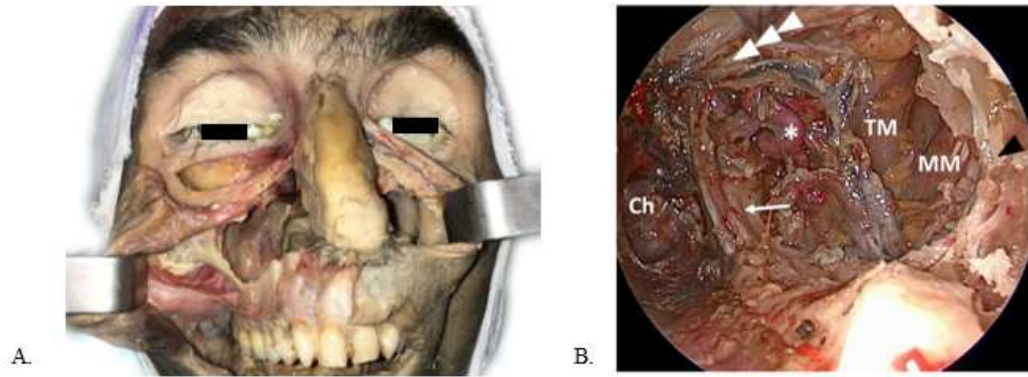


Figure 4. Exposure of the deep spaces. A: comparison of a right Weber-Fergusson approach and a left lateral rhinotomy approach; the exposure of the lateral and posterior walls of the maxillary sinus are equivalent. B: Endoscopic view of the pterygopalatine fossa and of the infratemporal fossa (left side); exposure of internal maxillary artery (white asterisk), pterygoid plates (white arrow), infraorbital nerve (white arrowheads) and lateral wall of the maxillary sinus (black arrowhead); Ch: choana; TM: temporalis muscle; MM: masseter muscle.

		LR	LR + subciliary incision	LR + lip-splitting incision	WF
Anterior skeleton	Nasal bone	7/7	4/4	3/3	4/4
	Piriform aperture	7/7	4/4	3/3	4/4
	Inferior orbital rim	7/7	4/4	3/3	4/4
	Lateral orbital rim	3/7	4/4	3/3	4/4
	Infraorbital foramen	7/7	4/4	3/3	4/4
	Zygomatic arch	1/7	4/4	3/3	4/4
	Maxillary tuberosity	3/7	1/4	3/3	4/4
Deep spaces	PPF and ITF	7/7	4/4	3/3	4/4

Table 1: Exposure of the anterior facial skeleton and of the deep retromaxillar spaces (LR: lateral rhinotomy ; WF: Weber-Fergusson ; PPF: pterygopalatine fossa ; ITF: infratemporal fossa)

	LR	LR + subciliary incision	LR + lip-splitting incision	WF
Dmax	4,9	6,4	6,87	6,9
p		0.25	0.001	0.0006

Table 2: maximal distance (Dmax) between the nasal bone and the most lateral part of the exposure. (LR: lateral rhinotomy ; WF: Weber-Fergusson)