



HAL
open science

First Outcomes of the ZSI 475 FtM, a Specific Prosthesis Designed for Phalloplasty

Paul Neuville, Nicolas Morel-Journal, Delphine Cabelguenne, Alain Ruffion,
Philippe Paparel, Jean-Etienne Terrier

► **To cite this version:**

Paul Neuville, Nicolas Morel-Journal, Delphine Cabelguenne, Alain Ruffion, Philippe Paparel, et al.. First Outcomes of the ZSI 475 FtM, a Specific Prosthesis Designed for Phalloplasty. *Journal of Sexual Medicine*, 2019, 16, pp.316 - 322. <10.1016/j.jsxm.2018.11.013>. <hal-03486339>

HAL Id: hal-03486339

<https://hal.science/hal-03486339v1>

Submitted on 20 Dec 2021

HAL is a multi-disciplinary open access archive for the deposit and dissemination of scientific research documents, whether they are published or not. The documents may come from teaching and research institutions in France or abroad, or from public or private research centers.

L'archive ouverte pluridisciplinaire **HAL**, est destinée au dépôt et à la diffusion de documents scientifiques de niveau recherche, publiés ou non, émanant des établissements d'enseignement et de recherche français ou étrangers, des laboratoires publics ou privés.



Distributed under a Creative Commons CC BY-NC 4.0 - Attribution - Non-commercial use - International License

First outcomes of the ZSI[®] 475 FtM, a specific prosthesis designed for phalloplasty.

Running title: A specific prosthesis for phalloplasty

Authors

Paul Neuville^a, Nicolas Morel-Journel^a, MD, Delphine Cabelguenne^b, PhD, Alain Ruffion^a, MD, PhD, Philippe Paparel^a, MD, PhD Jean-Etienne Terrier^{a,c}, MD.

a : Department of Urology, Centre hospitalier Lyon-Sud, Hospices Civils de

Lyon, Pierre-Bénite Cedex, France

b : Pharmaceutical Service, Centre hospitalier Lyon-Sud, Hospices Civils de

Lyon, Pierre-Bénite Cedex, France

c : Hospices Civils de Lyon, Pôle IMER, Lyon, F-69003, France; Université de Lyon,

Equipe d'Accueil HESPER 7425, F-69003 Lyon, France

Word count

Text : 2732

Abstract : 335

Keywords

Gender reassignment; Erectile Device; Phalloplasty; Female-to-Male Transsexualism; Gender

dysphoria ; Neophallus; Penile Prosthesis; Transsexual.

Corresponding author

Jean-Étienne Terrier, MD

Department of Urology, Centre hospitalier Lyon-Sud, Hospices civils de Lyon,

165 chemin du grand revoyet, Pierre-Bénite Cedex 69495, France.

Tel: fl 33-0-4767-8808; Fax: fl 33-0-472-678-810;

E-mail: jean-etienne.terrier01@chu-lyon.fr

Conflicts of Interest

Dr Terrier is consultant for Boston Scientific and Coloplast.

Dr Morel-Journal is a consultant for ZSI, Boston Scientific and Coloplast.

Pr Ruffion is a consultant for Boston Scientific.

Title First outcomes of the ZSI[®] 475 FtM, a specific prosthesis designed for phalloplasty.

ABSTRACT

Background: The ZSI[®] (Zephyr Surgical Implants) 475FtM is a new prosthesis that has recently been specifically designed for phalloplasty. It has several functions that have been conceived to answer the challenges of implantation after phalloplasty: a large base for pubic bone fixation, realistically shaped hard glans, and a pump shaped like a testicle.

Aim: To assess the safety, feasibility, and patient satisfaction of the ZSI[®] 475 FtM.

Methods: Surgical outcomes were analyzed after implantation of the prosthesis between June 2016 and September 2017 (single institution, single surgeon). Patients were then asked to answer a satisfaction questionnaire that included the IIEF-5 (International Index of Erectile Function), EDITS (Erectile Dysfunction Inventory of Treatment Satisfaction), and SEAR (Self-Esteem and Relationship), as well as other non-validated questions.

Outcomes: Complication rates and the scores of the different questionnaires.

Results: Twenty patients who had gender dysphoria and were operated on for a female-to-male procedure were included. The mean age was 37.9 years. Complications included: 2 (10%) infections which were medically treated (Clavien II), 1 (5%) infection treated by explantation (Clavien IIIb), and 2 (10%) mechanical failures (Clavien IIIb) and 1 (5%) malpositioning (Clavien IIIb). The mean follow-up was 8.9 months (SD 4.0), with 50% of the implanted patients having over 12 months of follow-up.

Fourteen patients (70%) answered the satisfaction questionnaire. Twelve patients (85.7%) had regular penetrative sexual intercourse. The mean IIEF-5 score was 20.2/25 (SD 7.9), the mean SEAR score was 84.5/100 (SD 9.9) and the mean EDITS score was 82/100 (SD 17.5).

Thirteen patients (92.8%) were *satisfied* or *very satisfied* with the prosthesis.

Clinical implications: This new innovative prosthesis could better answer the challenges faced by the implantation of an erectile device by phalloplasty.

Strengths and limitations: Our study is the first to report data on this new prosthesis. The main limitation is the small number of patients and the short follow-up.

Conclusions: Preliminary results for the ZSI[®] 475 FtM are encouraging. Safety seems to be satisfactory and patient satisfaction is high. Long-term studies are needed for further analysis.

Keywords

Erectile Device; Phalloplasty; Female-to-Male Transsexualism; Gender dysphoria;
Neophallus; Penile Prosthesis

INTRODUCTION

Phalloplasty is a complex surgery that has undergone several improvements in the past few years in order to better respond to its established aims¹: esthetic and complete genitals, voiding while standing, and rigidity. Obtaining rigidity is an important goal of the neophallus reconstruction as it allows penetrative sexual intercourse.

Implantation of an erectile prosthesis after phalloplasty faces many challenges. Due to the absence of a corpora cavernosa albuginea⁸, there is no solid and protective anchored tissue. The neophallus is less vascularized and less resistant. The distality of the prosthesis is not protected by the glans in a neophallus.

The first reported prosthesis implantation after phalloplasty was in 1978 (Puckett and Montie²) and used the three-piece Scott penile inflation device designed 6 years earlier³.

Only a few publications have since reported the outcomes of penile prosthesis implantations^{4, 5, 6, 7}.

The three largest of the most recent retrospective studies^{5, 6, 7} used up to 8 different types of prosthesis, all conceived for a penis with corpus cavernosum. A new type of prosthesis, the inflatable three-piece ZSI 475FtM[®] (Zephyr Surgical Implants Manufacturer), has recently been specifically designed for the neophallus. It has several functions that have been conceived to answer the challenges of prosthesis implantation: a large implantation base for pubic bone fixation, a realistically shaped hard glans, and a pump shaped like a testicle (Figure 1). This prosthesis seems to have several advantages but no safety data is currently available.

The aim of this study was to describe the feasibility, safety and patient satisfaction of the ZSI[®] 475FtM.

MATERIAL AND METHODS

Patients

From June 2016 to November 2017, implantation of the ZSI 475 FtM[®] was proposed to patients who needed a penile prosthesis. All types of phalloplasty were included, and were mainly performed in our institution. There were no exclusion criteria. Patients were informed that there were no long-term outcomes for this new prosthesis. The pharmacological and medical device department of our institution approved the use of this new prosthesis. Patient characteristics and surgical outcomes were collected from the patients' hospital files. Patients were asked to answer a questionnaire at least 3 months after the surgery.

Ethical considerations

All patients accepted that their data could be published or used for scientific purposes in accordance with the Declaration of Helsinki on human rights and ethical standards of research. This study obtained ethical approval from the Ethical Committee of Urology Research (CERU) of the French Association of Urology (AFU) and is registered under CERU number 2018/004.

Penile implant (Figure 1)

The inflatable ZSI 475 FtM[®] penile implant is manufactured by Zephyr Surgical Implants (Switzerland, EC certificate n°15749) and has been available on the European market since March 2016. The device is made of a single inflatable cylinder with 3 layers for better resistance, stability and filling (2 layers in silicon and one in polyester). Four lengths are available: 120, 150, 180 and 210 millimeters.

The proximal part of the cylinder is made of stainless steel and silicone for fixation onto the pubic bone. The main body, the central part, has a diameter of 21-22 mm, while the distal part, the glans, has a diameter of 25mm. The implant was conceived with an optimized erection angle. The device is sterilized with ethylene oxide.

The manufacturer's technical guarantee for the mean length of time before failure of this implant is 10 years, with a mean cycle before failure of more than 3000 cycles (one cycle corresponding to one erection).

Surgery (Figure 2)

Different types of phalloplasty were performed⁹, with the two principal techniques being the forearm free flap and the suprapubic phalloplasty¹⁰. Implantation of the erectile prosthesis was carried out at least 6 months after the last genital surgery. If patients had undergone urethroplasty we waited for a stable urination mode before considering implantation.

The aseptic techniques followed the recommendations of our institution: shower with an antiseptic solution before surgery and two 5-minute washes in the operating room.

The incision was performed laterally to the neo-scrotum after insertion of a urethral catheter, and dissection was performed to the pubic symphysis. A cautious progressive expansion was made in the neophallus using Mayo scissors and Hegar dilators. The shaped glans of the ZSI[®] 475FtM prosthesis (figure 1) required an expansion until a dilation using the 21Fr dilator was reached. If a large expansion was impossible (often due to the proximity of the neo-urethra or to the phalloplasty diameter), the glans could be carved in order to reduce the required dilatation until dilatation with the 18Fr dilator was reached. The bladder was then emptied and a space created in a pre-peritoneal space using the same incision in order to place the penile pump reservoir.

When the removal of a prosthesis and the placement of a new one was performed at the same time, we used abundant washing derived from the previously described⁶ prosthesis salvage operation¹¹.

The prosthesis and the reservoir were implanted after 10 minutes of soaking in a rifampicin solution. Fixation of the prosthesis was performed using 3 to 4 separated stitches of non-resorbable wire (Mersuture™) through the large implantation base of the ZSI® 475FtM (figure 1) onto the pubic symphysis periosteum. When necessary, a testicular prosthesis was inserted through a separate incision.

The urethral catheter was removed the day after surgery and patients were given oral antibiotic therapy for 5 days (amoxicillin/clavulanic acid 875mg/125mg).

Prosthesis activation took place 6 weeks after implantation.

Questionnaire.

We used different validated questionnaires to analyze the sexual outcomes and patient satisfaction:

- The IIEF-5¹² (International Index of Erectile Function) for assessing erectile function of the phalloplasty with the prosthesis. The score of this five-item index ranges from 0 to 25 for classifying erectile dysfunction: absent (25 – 21), mild (20 – 16), moderate (15 – 11), severe (10 – 5) or uninterpretable (5 – 1).
- The patient version of the EDITS questionnaire (Erectile Dysfunction Inventory of Treatment Satisfaction)¹³. This 11-item questionnaire focuses more on treatment satisfaction than treatment efficacy. Scores range from 0 (extremely low treatment satisfaction) to 100 (extremely high treatment satisfaction).

- The SEAR questionnaire (Self Esteem and Relationship), which has been validated for evaluating erectile dysfunction and includes confidence and self-esteem evaluations¹⁴. It has 14 items, and yields five different scores (the total SEAR score, the sexual relationship satisfaction domain score, and the confidence domain score, which includes the self-esteem and overall relationship satisfaction subscores). The score components are standardized in a scale from 0 to 100 with a higher score indicating a more favorable response (0=least favorable, 100=most favorable).

We added specific non-validated questions to analyze the prosthesis (inflation facility, deflation facility, comparison to previous prostheses), with items scored on a five-point Likert scale. The complete questionnaire is detailed in **annex 1**.

RESULTS

Twenty patients had 21 ZSI[®] 475 FtM implantations. Patient characteristics are presented in **Table 1**. All patients had gender dysphoria and were operated for a female-to-male procedure. The mean age at surgery was 37.9 years (SD=7.6; range 26 - 50). Mean follow-up was 8.9 months (SD=4.0).

Eleven patients had previously undergone implantation surgery and all ancient prostheses were the AMS Ambicor[®]. Reasons for the change were: 5 mechanical failures, 3 malpositions and 3 infections. In 72.8% of these cases (n=8), the ZSI[®] 475 FtM implantation was performed during the same operation as the removal of the previous prosthesis.

Surgical outcomes are presented in **Table 2**. Two patients presented a urinary tract infection during the month following surgery. Those infections were medically treated but needed hospitalization and broad-spectrum antibiotherapy (Clavien II). Two mechanical failures were encountered: one leakage and one activation defect.

We implanted different sizes of the ZSI[®] 475 FtM: 12cm (n=1), 15cm (n=9), 18cm (n=10) or 21 cm (n=1). For 33% of the prostheses, we had to carve the prosthesis glans for implantation.

The overall revision rate was 23.8% (n=5), resulting from 1 infection (4.7%), 3 mechanical failures (14.3%) and 1 malpositioning (4.7%). At the end of the follow-up, 15 patients still had their ZSI 475FtM prosthesis.

Fourteen patients completely answered the questionnaire in full (70.0%). The outcomes of the questionnaire are presented in **Table 3**. Twelve patients (85.7%) had active penetrative sexual intercourse with their prosthesis, and 8 patients (57.1%) “regularly” or “frequently” reached orgasm. Thirteen patients (92.8%) were either “satisfied” or “very satisfied” with this prosthesis. Thirteen patients (92.8%) were also “satisfied” or “very satisfied” by the inflation maneuverability of the prosthesis, and 9 patients (64.3%) were “satisfied” or “very satisfied” by the deflation maneuverability.

Eight patients who answered the questionnaire had undergone previous implantation of the AMS Ambicor[®], with 6 (75.0%) finding the new prosthesis “better” or “a lot better”.

The reported reasons for improvement were better stability (5 patients), harder glans (6 patients), reduced inopportune deflation (6 patients). Concerning “the free text question”, four patients spontaneously reported a gain of rigidity.

DISCUSSION

Our study is the first to report data on this new innovative prosthesis. In order to overcome the difficulties of implantation of a penile prosthesis after phalloplasty, new techniques have been developed. Large et al. described an anchoring technique to the pubis¹⁵. Use of a vascular graft prosthesis housing the penile prosthesis cylinder has been described to prevent hypermobility and erosion, but the results suggest that it could increase mechanical

failure⁶. The incorporated anchorage system of the ZSI[®] 475 FtM might be a real improvement for device lifespan, especially in a young sexually active population. The hard shaped glans may also be helpful for penetration, enhancing rigidity at the distal end of the prosthesis. The shaped glans of the initial ZSI[®] 475FtoM prosthesis needs an expansion until a dilation using the 21French dilatator is reached, which could be difficult in a phalloplasty. In order to reduce the dilatation until the 18Fr dilatator, we carved the glans with the agreement of the manufacturer. A new version of the prosthesis has been developed and allows dilatation only up to 18Fr.

The ZSI[®] 475 FtM might also answer aesthetic issues due to its testicle shaped pump. Complication rates of penile prosthesis implantation are much higher in neophallus compared to native penis. Overall, rates of infection, erosion and dysfunction in a native phallus are less than 2%¹⁶. The three largest retrospective studies^{5, 6, 7} of penile prosthesis implantation after phalloplasty reported homogeneous complication rates: overall revision rates from 37.7% to 43.3%, infection rates from 8.4% to 11.9%, dysfunction rates from 12.6% to 19.4% and mechanical failure rates from 10.5% to 15.4%. In this study, we report complication rates for the ZSI[®] 475 FtM that seem to be lower than those reported in the literature (4.7% were the result of infection, 9.5% were due to mechanical failure, and 4.7% were the result of malpositioning). This is certainly due to the short follow-up period of our study (8.9 months compared to 20 to 48 months in the largest studies). In the largest study by Falcone⁷, the overall 5-year survival rate of the implants was 78%. The survival rate of the ZSI[®] 475 FtM seems lower, even if comparison is difficult due to the small number of patients and the short follow-up period of our study.

Evaluating patient satisfaction after penile prosthesis implantation in a neophallus faces some difficulties. In a literature review of penile prosthesis satisfaction in biological men, Akakpo et al. found that 66.2% of the studies used non-validated questionnaire¹⁷. In 43% of the studies, the most frequent questionnaires used were the IIEF-5 questionnaire and the EDITS questionnaire. In the largest study analyzing the outcomes of penile prosthesis insertion⁷, Falcone et al. used 7 non-validated questions. We chose the most frequently used questionnaires (IIEF-5 and EDITS) for reproducibility and added specific questions that allowed the mechanical function of the prosthesis to be evaluated.

In our study, the mean IIEF-5 score was high (20.2 ± 7.9), which is close to a normal erectile function (21-25). In a satisfaction study in 69 cis men after penile prosthesis, Vakalopoulos et al.¹⁸ found an improvement in the IIEF-5 from 8.88 ± 3.75 to 20.97 ± 4.37 . The IIEF5 score after implantation of the ZSI[®] 475 FtM may be due to the sustainable rigidity of the prosthesis. All patients answered « not difficult » or « slightly difficult » to the fourth question of the IIEF5 (“During sexual intercourse, how difficult was it to maintain your erection to completion of intercourse?”). This may be an indicator of the lessening of inopportune deflation, which is a frequent problem with the two-piece AMS Ambicor[®]. In a study analyzing outcomes with the AMS[®] Ambicor, Ko and Bennet found that spontaneous deflation was seen in approximately 25% of patients¹⁹.

In our study we report high overall satisfaction with a mean EDITS score of 82/100 and 100% of patients with an EDITS score > 50. In a study of 69 cis men after penile prosthesis, Vakalopoulos¹⁸ reported that the mean EDITS score was 75.48 ± 20.54 . In a study that analyzed treatment satisfaction in men who had undergone penile prosthesis surgery following robot-assisted radical prostatectomy, Pillay et al.²⁰ found that 94% of men reported satisfaction with the treatment (EDITS score > 50). In a population of 190 cis men

that underwent penile prosthesis implantation, Lledo-Garcia et al.²¹ reported satisfactory sexual intercourse (very or moderately satisfied) for 79% of patients. Satisfaction after penile prosthesis implantation seems significant, possibly due to the rigorous selection of patients who undergo that surgery, and our study strengthens those results.

In this study we report a noteworthy median SEAR score (84.5/100). In a comparative study of cis men, Cappelleri²² found a mean SEAR score of 47.6 ± 21.6 in the group suffering from erectile dysfunction ($n = 93$) and a score of 77.5 ± 22.1 in the control group ($n=94$). Chertin et al.²³ evaluated sexual function and psychosexual adjustment in adults who underwent hypospadias repair in childhood and reported a mean SEAR score of over 80/100 for all types of hypospadias. The high SEAR score reported in our study may reflect the good self-esteem and optimism of patients who undergo a long surgical process.

Evaluation of satisfaction after phalloplasty often uses non-validated questionnaires due to the special features of the reconstruction. Young et al.²⁴ analyzed sexual function and quality of life after penile prosthesis implantation following radial forearm flap phalloplasty in 21 patients who underwent phalloplasty for penile deficiency. They found that 80.9% of patients were sexually active and the median erectile function domain score of the IIEF was 26 out of 30. Callens et al.²⁵ studied the sexual quality of life after total phalloplasty in 10 patients who also underwent phalloplasty for penile deficiency. They reported that 83% of patients were sexually active, and 50% were dissatisfied with their penile appearance.

Falcone et al.⁷ reported 88% of patients were fully satisfied with the cosmetic and functional outcomes after total phallic reconstruction (including penile prosthesis). In a study analyzing the outcomes after suprapubic phalloplasty, Terrier et al.¹⁰ reported a satisfaction with current sex life in almost 80% of the patients and a frequency of sexual activity of 85%. In

our study, 85.7% of patients were sexually active. We report a high satisfaction rate (all patients were satisfied with penile appearance, 92.8% were satisfied of the penile prosthesis). All of our patients underwent phalloplasty for gender dysphoria, leading to a satisfaction with the surgery that was generally higher than patients who had congenital or acquired penile deficiency.

Satisfaction results might be over evaluated because 30% of patients didn't answer the questionnaire. One patient had no sexual intercourse before answering the questionnaire, and another patient was experiencing severe depression. One patient had the prosthesis removed one month after implantation due to material infection. Two patients experienced mechanical dysfunction (one experienced a leak) shortly after implantation. Another patient couldn't use the prosthesis because access to the pump was difficult. We are currently working on pump positioning and a new technique of scrotoplasty that will facilitate the handling of the prosthesis. Maneuverability satisfaction was very high for prosthesis inflation (92.8%) and lower (64.3%) for prosthesis deflation.

Twenty patients were implanted, with a mean follow-up of 8.9 months. This is certainly the weakest point of our study, but preliminary results were needed in order to assess the safety of the implantation.

CONCLUSION

Our study is the first to report outcomes for a new type of prosthesis, the ZSI[®] 475 FtM, which is specifically designed for phalloplasty. The safety and feasibility of the prosthesis implantation seem acceptable, and patient satisfaction is high. Other studies with longer

follow-up periods are needed, and we will pursue implantation and following-up of this new prosthesis.

REFERENCES

- [1] Hage JJ, Bout CA, Bloem JJ, Megens JA. Phalloplasty in female-to-male transsexuals: what do our patients ask for? *Ann Plast Surg* 1993;30:323.
- [2] Puckett CL, Montie JE. Construction of male genitalia in the transsexual, using a tubed groin flap for the penis and a hydraulic inflation device. *Plast Reconstr Surg* 1978;61:523-530.
- [3] Scott FB, Bradley WE, Timm GW. Management of erectile impotence. Use of implantable inflatable prosthesis. *Urology* 1973;2:80-82.
- [4] Hoebeke PB, de Cuypere G, Ceulemans P, Monstrey S. Obtaining rigidity in total phalloplasty: experience with 35 patients. *J Urol* 2003;169:221-223.
- [5] Hoebeke PB, Decaestecker K, Beysens M, Opdenakker Y, Lumen N, Monstrey S. Erectile implants in female-to-male transsexuals: our experience in 129 patients. *Eur Urol* 2010;57:334-340.
- [6] Neuville P, Morel-Journel N, Maucort-Boulch D, Ruffion A, Paparel P, Terrier JE. Surgical outcomes of erectile implants after phalloplasty : retrospective analysis of 95 procedures. *J Sex Med* 2016;13:1758-1764.

- [7] Falcone M, Garaffa G, Gillo A, Dente D, Christopher AN, Ralph DJ. The outcomes of inflatable penile prosthesis insertion in 247 patients completing female to male gender reassignment surgery. *BJU Int* 2017;14027.
- [8] Hage JJ, Bloem JJ, Bouman FG. Obtaining rigidity in the neophallus of female-to-male transsexuals : a review of the literature. *Ann Plast Surg* 1993;30:327-33.
- [9] Courtois F, Terrier JÉ, Brassard P, Ruffion A, Morel-Journal N. Development of surgical phalloplasty techniques: is there a gold standard? *Sexologies* 2012;21:55-59.
- [10] Terrier JÉ, Courtois F, Ruffion A, Morel-Journal N. Surgical outcomes and patients satisfaction with suprapubic phalloplasty. *J Sex Med* 2014;11:288-298.
- [11] Brant MD, Ludlow JK, Mulcahy JJ. The prosthesis salvage operation: immediate replacement of the infected penile prosthesis. *J Urol* 1996;155:155-157
- [12] Rosen RC, Cappelleri JC, Smith MD, Lipsky J, Pena BM. Development and evaluation of an abridged, 5-item version of the International Index of Erectile Function (IIEF-5) as a diagnostic tool for erectile dysfunction. *Int J Impot Res* 1999;11 :319-26.
- [13] Althof SE, Corty EW, Levine SB, Levine F, Burnett AL, McVary K, et al. EDITS : development of questionnaires for evaluating satisfaction with treatments for erectile dysfunction. *Urology* 1999;53(4):793-9
- [14] Cappelleri JC, Althof SE, Siegel RL, Shpilsky A, Bell SS, Duttgupta S. Development and validation of the self-esteem and relationship (SEAR) questionnaire in erectile dysfunction. *Int J Impot Res* 2004;16(1):30-8.
- [15] Large MC, Gottlieb LJ, Wille MA, DeWolfe M, Bales GT. Novel technique for proximal anchoring of penile prostheses in female-to-male transsexual. *Urology* 2009;74:419-421.

- [16] Carson CC III, Mulcahy JJ, Harsch MR. Long-term infection outcomes after original antibiotic impregnated inflatable penile prosthesis implants: up to 7.7 years of followup. *J Urol* 2011;185:614-618.
- [17] Akakpo W, Pineda MA, Burnett AL. Critical analysis of satisfaction assessment after penile prosthesis surgery. *Sex Med Rev* 2017;5(2):244-251.
- [18] Vakalopoulos I, Kampantais S, Ioannidis S, Laskaridis L, Dimopoulos P, Toutziaris C, et al. High patient satisfaction after inflatable penile prostheses implantation correlates with female partner satisfaction. *J Sex Med* 2013;10(11):2774-81.
- [19] Ko OS, Bennett NE Jr. Ambicor Two-Piece Inflatable Penile Prosthesis: Background and Contemporary Outcomes. *Sex Med Rev* 2017;S2050-0521(17)30094-X.
- [20] Pillay B, Moon D, Love C, Meyer D, Ferguson E, Crowe H, et al. Quality of Life, Psychological Functioning, and Treatment Satisfaction of Men Who Have Undergone Penile Prosthesis Surgery Following Robot-Assisted Radical Prostatectomy. *J Sex Med* 2017 Dec;14(12):1612-1620
- [21] Lledo-Garcia E, Jara-Rascon J, Moncada Iribarren I, Pinero-Sanchez J, Aragon-Chamizo J, Hernandez-Fernandez C. Penile prosthesis first and replacement surgeries: analysis of patient and partner satisfaction. *J Sex Med* 2015;12(7):1646-53
- [22] Cappelleri JC, Bell SS, Althof SE, Siegel RL, Stecher VJ. Comparison between sildenafil-treated subjects with erectile dysfunction and control subjects on the Self-Esteem And Relationship questionnaire. *J Sex Med* 2006;3:274–82.
- [23] Chertin B, Natsheh A, Ben-Zion I, Prat D, Kocherov S, Farkas A, et al. Objective and subjective sexual outcomes in adult patients after hypospadias repair performed in childhood. *J Urol*. 2013 Oct;190(4 Suppl):1556-60.

[24] Young EE, Friedlander D, Lue K, Anele UA, Khurgin JL, Bivalacqua TJ, et al. Sexual function and quality of life before and after penile prosthesis implantation following radial forearm flap phalloplasty. *Urology* 2017;104:204-208

[25] Callens N, De Cuypere G, T'Sjoen G, Monstrey S, Lumen N, Van Laecke E, et al. Sexual quality of life after total phalloplasty in men with penile deficiency: an exploratory study. *World J Urol* 2015;33(1):137-43

Conflicts of Interest

Dr Terrier and Dr Morel-Journal are consultants for AMS Boston Scientific and Colloplast.

Pr Ruffion is a consultant for AMS Boston Scientific.

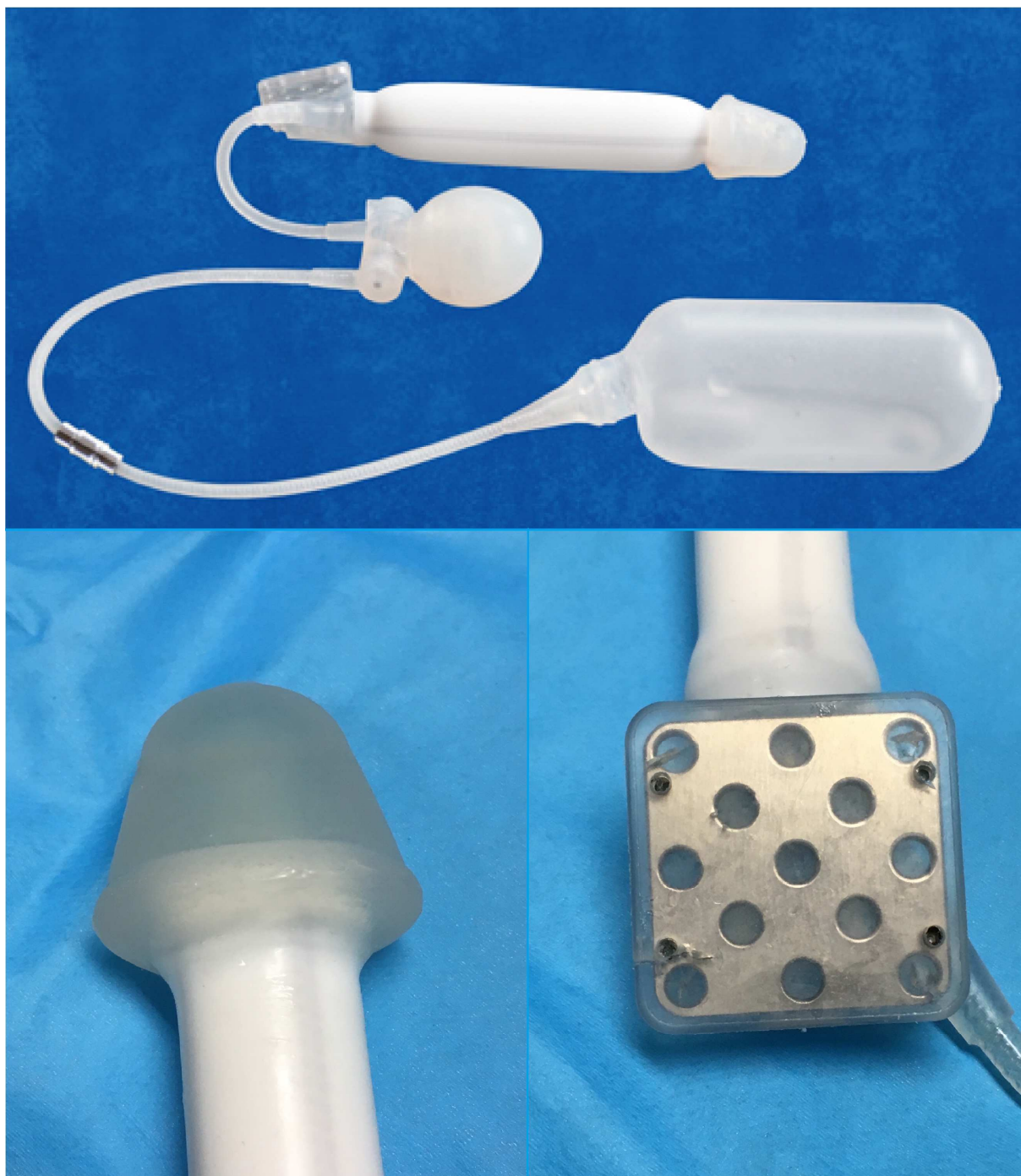

Figure 1: The ZSI[®] 475 FtM

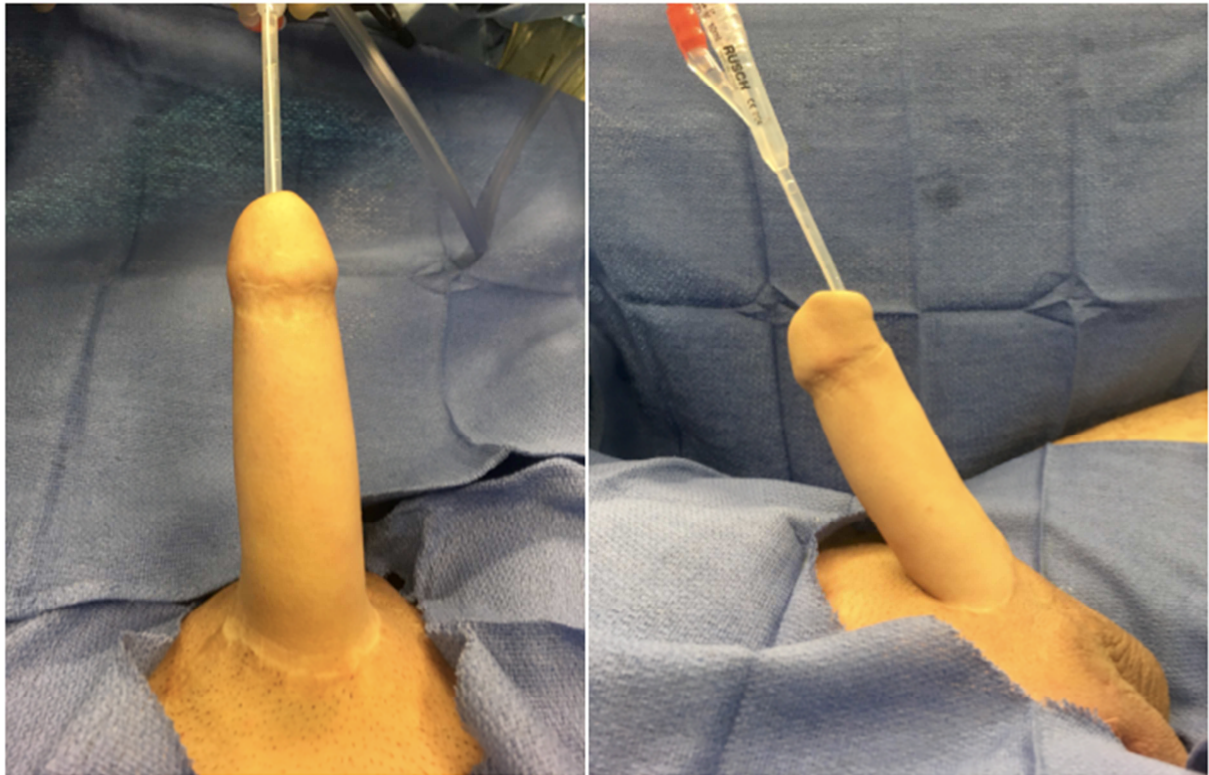


Figure 2 : Post-operative photograph

Mean age at surgery (SD)	37.9 (7.6)
Phalloplasty n(%)	
- forearm flap	15 (75%)
- suprapubic	4 (20%)
- pedicled inguinal flap	1 (5%)
Urethroplasty n(%)	17 (85%)
Implants per patients n(%)	
- first	9 (45%)
- second	4 (20%)
- >2	7 (35%)

Table 1: Patients' characteristics

Mean prosthesis size (cm) (SD)	16.7 (1.8)
Mean duration of surgery (min) (SD)	102.6 (13.2)
Average duration of hospitalization (days) (SD)	2.6 (0.5)
Complications n(%)	
- medically treated infection (Clavien II)	2 (9.5%)
- infection with explantation needed (Clavien IIIb)	1 (4.7%)
- mechanical failure (Clavien IIIb)	2 (9.5%)
- malposition (Clavien IIIb)	1 (4.7%)

Table 2: Surgical results

Active sexual relation n(%)	12 (85.7%)
IIEF-5 mean(SD)	20.2 (7.9)
SEAR mean (SD)	84.5 (9.9)
- sexual relationship	78.8 (21.3)
- confidence	93.3 (5.5)
- self esteem	91.0 (6.5)
- overall relationship	97.5 (6.2)
EDITS mean (SD)	82 (17.5)

Table 3: Questionnaire outcomes