



HAL
open science

Usefulness of head-up tilt test combined with video electroencephalogram to investigate recurrent unexplained atypical transient loss of consciousness

Sandro Ninni, Claude Kouakam, William Szurhaj, Guillaume Baille, Didier Klug, Dominique Lacroix, Philippe Derambure

► To cite this version:

Sandro Ninni, Claude Kouakam, William Szurhaj, Guillaume Baille, Didier Klug, et al.. Usefulness of head-up tilt test combined with video electroencephalogram to investigate recurrent unexplained atypical transient loss of consciousness. Archives of cardiovascular diseases, 2019, 112, pp.82 - 94. 10.1016/j.acvd.2018.08.004 . hal-03486329

HAL Id: hal-03486329

<https://hal.science/hal-03486329v1>

Submitted on 20 Dec 2021

HAL is a multi-disciplinary open access archive for the deposit and dissemination of scientific research documents, whether they are published or not. The documents may come from teaching and research institutions in France or abroad, or from public or private research centers.

L'archive ouverte pluridisciplinaire **HAL**, est destinée au dépôt et à la diffusion de documents scientifiques de niveau recherche, publiés ou non, émanant des établissements d'enseignement et de recherche français ou étrangers, des laboratoires publics ou privés.



Distributed under a Creative Commons Attribution - NonCommercial 4.0 International License

Usefulness of head-up tilt test combined with video electroencephalogram to investigate recurrent unexplained atypical transient loss of consciousness

Intérêt du tilt test couplé à l'électro-encéphalogramme dans le diagnostic étiologique des pertes de connaissances récidivantes atypiques inexplicées

Abbreviated title: Combined HUT/video EEG in the evaluation of atypical T-LOC

Sandro Ninni^{a,*}, Claude Kouakam^a, William Szurhaj^b, Guillaume Baille^b, Didier Klug^a, Dominique Lacroix^a, Philippe Derambure^b

^a *Clinique de Cardiologie, Institut Cœur-Poumon, CHRU Lille, Boulevard du Professeur Jules Leclercq, 59037 Lille, France*

^b *Service de Neurophysiologie Clinique, CHRU de Lille, Hôpital Roger Salengro, Avenue du Professeur Emile Laine, 59037 Lille, France*

* Corresponding author at: Clinique de Cardiologie, Institut Cœur Poumon, CHRU Lille, 59037 Lille CEDEX, France.

E-mail address: sandro.ninni@chru-lille.fr (S. Ninni).

Summary

Background – Convulsive syncope and epileptic seizure share many similar clinical features. Early diagnosis is critical for choosing the appropriate management strategy.

Aim. – Our aim was to evaluate the diagnostic yield of an innovative diagnostic strategy – combined head-up tilt test (HUT)/video electroencephalogram (EEG) monitoring – in patients with unexplained seizure-like transient loss of consciousness (T-LOC).

Methods. – Combined HUT/video EEG was performed in patients with unexplained atypical T-LOC with both syncope and seizure characteristics remaining undiagnosed after a first-line investigation. T-LOC diagnosis was achieved in case of reproduction of usual symptoms. Events were classified as vasovagal, psychogenic or epilepsy. The link between EEG abnormalities and T-LOC was determined by an epilepsy specialist. Clinical follow-up was performed to assess T-LOC recurrence.

Results. – 101 consecutive patients were prospectively enrolled (median age 26 [19; 46] years; 72% female) and underwent combined HUT/video EEG between 2007 and 2015. Antiepileptic drugs were being prescribed in 42% of patients. Combined HUT/video EEG was diagnostic in 67% of patients, leading to diagnosis of vasovagal syncope in 59 patients and psychogenic pseudosyncope in nine cases. Antiepileptic drugs were discontinued in 18 patients without epilepsy. Independent predictors of a definitive diagnosis were the presence of prodromal symptoms (odds ratio 5.97, 95% confidence interval 1.37–26; $P = 0.017$) and a history of myoclonic jerks during T-LOC (odds ratio 4.36, 95% confidence interval 1.71–11.15; $P = 0.002$).

Conclusions. – Combined HUT/video EEG is useful for investigating recurrent unexplained atypical seizure-like T-LOC, especially in patients with a history of myoclonic jerks or with documented interictal non-specific EEG abnormalities.

Résumé

Contexte. – Les syncopes convulsivantes et les crises d'épilepsies sont des évènements cliniques présentant des caractéristiques cliniques communes pouvant aboutir à un diagnostic erroné en pratique courante.

Objectif. – Le but de cette étude est d'évaluer la valeur diagnostique du tilt test couplé à l'électroencéphalogramme sur une cohorte de patients présentant des pertes de connaissance transitoires atypiques inexpliquées récidivantes.

Méthodes. – Un tilt test couplé à un électroencéphalogramme a été réalisé sur une cohorte de patients présentant des pertes de connaissances atypiques, récidivantes, et inexplicables malgré une 1^{ère} ligne d'investigation. Le diagnostic était retenu en cas de reproduction de la symptomatologie habituelle au cours du test. Les diagnostics pouvaient être : une syncope vagale, une perte de connaissance psychogène ou une crise épileptique. Le lien entre l'EEG et la clinique était déterminé par un neurologue spécialisé en neurophysiologie. Un suivi clinique a été réalisé afin d'évaluer l'incidence des récurrences de perte de connaissance après le test.

Résultats. – 101 patients ont été inclus prospectivement (âge 26 [19 ; 46] ans ; sexe féminin 72 %) et ont bénéficié de la réalisation d'un tilt test couplé à un électroencéphalogramme entre 2007 et 2015. Un traitement antiépileptique était prescrit chez 42 % des patients. Le tilt test couplé à l'EEG a permis d'établir un diagnostic chez 67 % des patients avec 59 syncopes vasovagales et 9 pertes de connaissance psychogène. Les traitements antiépileptiques ont été interrompus chez 18 patients considérés épileptiques avant le test. Les facteurs prédictifs indépendants de poser un diagnostic étaient la présence de prodromes (OR 5,97, IC95 % 1,37–26 ; $P = 0,017$) et la présence de mouvements anormaux rapportés par les témoins durant la perte de connaissance (OR 4,36, IC95 % 1,71–11,15 ; $P = 0,002$).

Conclusions. – Le tilt test couplé à l'EEG peut être utile dans l'exploration diagnostique des pertes de connaissances atypiques récidivantes sans diagnostic étiologique établi. Cette performance diagnostique est d'autant plus importante chez les patients aux antécédents de mouvements anormaux lors des épisodes cliniques.

KEYWORDS

Transient loss of consciousness;

Syncope;

Epilepsy;

Tilt test;

Electroencephalogram

MOTS CLÉS

Perte de connaissance transitoire ;

Syncope ;

Epilepsie ;

Tilt test ;

Electroencéphalogramme

Abbreviations: AED, antiepileptic drug; BP, blood pressure; CI, confidence interval; EEG, electroencephalogram; HUT, head-up tilt test; OR, odds ratio; T-LOC, transient loss of consciousness.

Background

Transient loss of consciousness (T-LOC) is a common event in the general population, accounting for 3–6% of emergency department admissions [1], and is very often caused by syncope (i.e. has a rapid onset, short duration and spontaneous complete recovery). T-LOC leads to hospitalization in approximately 40% of cases, and has high direct and indirect social costs [2-4]. Recent guidelines for the management of syncope have improved diagnosis efficiency for T-LOC aetiology, in order to define the exact mechanism [5]. However, despite thorough investigation, some cases of T-LOC remain undiagnosed. Most of the time, these unexplained cases of T-LOC are the result of an atypical clinical history reported by the patient or an eyewitness, with syncope and seizure characteristics [6-8].

On a pathophysiological basis, syncope is caused by transient global cerebral hypoperfusion, as opposed to epileptic seizures, which are related to an abnormal paroxysmal neuronal discharge. These two entities, although pathophysiologicaly different, can lead to the same confusing presentation, sometimes with common clinical features, such as prolonged loss of consciousness, stiffness, myoclonic jerks or a long time to recovery of consciousness [9-12]. In some cases, unusual epileptic cardiac asystole can lead to haemodynamic changes and T-LOC resulting from increased parasympathetic flow [13-16].

An electroencephalogram (EEG) is commonly used to diagnose epileptic seizures, by displaying abnormal paroxysmal activities correlated with clinical symptoms [17]. In some cases, there is a lack of specificity, and “epileptiform” activities may be observed in healthy subjects in 0.5–2.4% of cases [18, 19]. Therefore, patients with unexplained seizure-like T-LOC and “epileptiform” activities recorded on an EEG outside of a clinical event can be wrongly considered as having epilepsy and incorrectly treated with antiepileptic drugs (AEDs). A head-up tilt test (HUT) is usually used to investigate unexplained T-LOC in the absence of structural cardiac disease, especially when a reflex syncope is suspected [5, 20-22]. HUT has also been evaluated in patients with frequent T-LOC suspected to be of psychogenic origin [23], and in the elderly, to help distinguish syncope from falls [24]. In the setting of atypical unexplained T-LOC with syncope and seizure characteristics, the usual “separated” cardiological or neurological diagnostic approach has its limits. In this regard, the contribution of EEG may be of value to study brain function during tilt-induced T-LOC, as shown by studies of EEG changes during tilt-induced vasovagal syncope [10, 25, 26]. Therefore, it can be assumed that a

combined “heart/brain” approach could be useful to establish a definitive diagnosis by using concomitant HUT with EEG and video data (video EEG).

To date, only two studies have investigated this combined diagnostic strategy: the first study was by LaRoche et al. in 40 patients with unexplained atypical T-LOC, with 65% diagnosis and discontinuation of AEDs in seven patients [27]; the second study was by Yilmaz et al. in 19 children with unexplained T-LOC, with AED disruption in six cases [28]. Despite these preliminary studies, the clinical situation that will derive potential benefit from this combined strategy and the usefulness of EEG recording during HUT remain unclear.

Consequently, we aimed: (1) to determine the overall diagnostic value of this “heart/brain” strategy in a large population of patients presenting with atypical recurrent unexplained seizure-like T-LOC who remained undiagnosed after a first-line investigation; (2) to identify the predictors for making a definitive diagnosis; and (3) to evaluate the impact of AED disruption during follow-up.

Methods

Study design and patient selection

This single-centre multidisciplinary open study evaluating an innovative diagnostic strategy was performed in the Cardiology Department and Epilepsy Specialist Unit of Lille University Hospital from 2007 to 2015. All patients with atypical unexplained T-LOC with syncope and seizure characteristics were considered eligible and were enrolled consecutively. Combined HUT/video EEG was performed in patients who remained undiagnosed after first-line standard neurological and/or cardiological investigations. Selected data on demographics, medical history and clinical characteristics were recorded. For patients with a history of “epileptic seizure”, additional diagnostic criteria were recorded. Patients with a misdiagnosis related to fall, drop attacks, cataplexy, drunkenness or stroke were excluded. In accordance with French legislation, our non-interventional study was registered with the National Data Protection Commission (Commission Nationale de l'Informatique et des Libertés, reference DEC16-61).

An atypical T-LOC diagnostic algorithm was developed by a consensus group, which included all active investigators of the study, to consider: (1) all published guidelines on syncope; (2) overall yield of available diagnostic procedures in syncope; (3) estimations of prevalence of various causes of

syncope; (4) the specific experience of the investigators. The diagnostic approach and diagnostic sequences are reported in [Fig. 1A](#) and [Fig. 1B](#), respectively.

Epilepsy subpopulations

For patients initially diagnosed with “epilepsy”, we distinguished two patterns of confirmed or presumed epilepsy depending on symptoms and abnormalities recorded during the EEG. The indication for combined HUT/video EEG was based on the relevance of the diagnosis, as illustrated in [Fig. 1A](#). In some cases, epilepsy was confirmed by at least one EEG recorded during seizure. A different T-LOC picture resembling syncope was also reported by patients in the “true epileptic” subpopulation or an eyewitness, and combined HUT/video EEG was performed to determine the exact nature of the T-LOC, and to assess if a relationship between epilepsy and vasovagal syncope could be found.

In other cases, the diagnosis of epilepsy was just presumed, sometimes based on the association of clinical description with interictal EEG findings, or clinical suspicion with empirical prescription of AEDs, despite a lack of EEG evidence of epilepsy. For patients in this “presumed epileptic” subpopulation, combined HUT/video EEG aimed to investigate the relationship between clinical symptoms and EEG changes, and to determine if vasovagal or psychogenic syncope was the cause of T-LOC.

Combined HUT/video EEG protocol and definitions

HUT was performed according to a standardized previously described protocol [5, 21]. Subjects were tested in the absence of any active cardiovascular drug, in a quiet room. Heart rate and blood pressure (BP) were monitored continuously using non-invasive finger arterial plethysmography Nexfin® (BMEYE B.V., Amsterdam, The Netherlands). Baseline measurements were obtained after 15 minutes in the supine position; patients were then tilted upright to 70 ° for 30 minutes. HUT was considered positive if a vasovagal reaction occurred (BP fall and/or bradycardia). If no symptoms occurred at the end of the passive phase, HUT was sensitized with isoproterenol (1–3 µg/min intravenously) and/or nitroglycerine (400 µg sublingually). Vasovagal responses were classified as vasodepressor (BP fall without bradycardia), cardioinhibitory (heart rate ≤ 40 bpm for > 10 seconds or asystole ≥ 3 seconds) or mixed (BP fall following moderate bradycardia ≥ 40 bpm). Synchronously

during HUT, standard EEG SystemPLUS® equipment and software with a digital video camera (Micromed S.p.A., Mogliano Veneto, Italy) were used to assess brain activity. All EEGs were performed by using 19 disc electrodes attached to the scalp (according to the international 10–20 system) with conductive paste, a sampling frequency of 256 Hz, a band pass filter of 0.5–70 Hz and two electrodes for continuous electrocardiogram co-registration [17]. EEG abnormalities were classified as paroxysmal activities or slow/flat waves, and their location was noted. All EEG recordings were interpreted independently by a blinded expert neurologist, and abnormal activities were correlated with the video recording.

Classification of combined HUT/video EEG results

Diagnosis, at the end of test, was achieved in case of reproduction of the patient's usual symptoms, as illustrated in [Fig. 1B](#). A diagnosis of vasovagal syncope was made in case of haemodynamic changes (BP fall and/or bradycardia) reproducing the patient's symptoms. A diagnosis of pseudopsychogenic syncope was made in case of reproduction of the patient's symptoms without haemodynamic changes or EEG abnormalities. When slow waves occurred after haemodynamic changes, we concluded that the patient was experiencing cerebral hypoperfusion. If EEG abnormalities occurred before haemodynamic changes, we determined if there was a link with haemodynamic changes and/or clinical events using video monitoring and real-time haemodynamic monitoring.

Outcomes

After testing, patients with vasovagal syncope were reassured and instructed to recognize premonitory symptoms (if any), avoid provocative situations and increase salt intake; they were also instructed to perform physical counter manoeuvres, such as leg crossing, combined with leg, buttock and abdominal muscle tensing, and isometric arm exercises to improve venous return and abort vasovagal reactions. We recorded if the result led to disruption of AEDs in the “presumed epileptic” subpopulation, and if patients experienced another T-LOC or seizure confirmed by EEG. After discharge, follow-up was performed in all patients every 6–12 months at our outpatient cardiology or neurology clinic. Primary endpoints were the recurrence of T-LOC and the number of episodes.

Statistical analysis

Continuous variables are expressed as means and standard deviations for cases approximated by a normal distribution or as medians [interquartile ranges] otherwise. A Shapiro-Wilk test was performed to assess normality for continuous variables. Qualitative variables are expressed as frequencies and percentages. Comparisons between groups were performed using the Mann-Whitney U test for continuous variables and the χ^2 test or Fisher's exact test for categorical variables. Factors associated with a diagnosis were determined using standard logistic regression with a stepwise analysis.

Variables included in the multivariable analysis were those reaching a significance level of $P \leq 0.1$ in the bivariate analysis, to avoid excessive variables in the model. Results of the multivariable analysis are reported as odds ratios (ORs) with corresponding 95% confidence intervals (CIs) and P values. All statistical analyses were performed using SPSS software, version 22.0 (SPSS Institute, Inc., Chicago, IL, USA). A P value < 0.05 was considered statistically significant.

Results

Study population characteristics

From 2007 to 2015, 112 consecutive patients were referred for atypical unexplained recurrent T-LOC with both syncope and seizure characteristics, undiagnosed at initial evaluation. One hundred and one patients underwent HUT combined with video EEG (a technical problem with the EEG recording occurred during three tests, and eight patients did not attend their appointment). All of these patients had a first-line standard cardiological or neurological evaluation. Baseline characteristics are reported in [Table 1](#). Follow-up was performed for a median of 3 years. Patients were predominantly female (72%), and the median age was 26 [19; 46] years. In 45 patients, a history of "epileptic seizure" episodes was reported; among these, a diagnosis of epilepsy was confirmed in 11 patients, who also reported different kinds of T-LOC ("true epileptic" subpopulation), and presumed in 34 patients, 20 with documented interictal paroxysmal EEG activities and 14 taking AEDs only based on clinical suspicion ("presumed epileptic" subpopulation). Overall, AEDs were prescribed for 42% of the population for a mean duration of 1 year (11 in the "true epileptic" subpopulation and 31 in the "presumed epileptic" subpopulation). History of psychiatric illness was present in 10% of patients.

T-LOC characteristics at first-line presentation (Table 2)

T-LOC was reported for a median duration of 24 months. Most patients experienced numerous atypical unexplained T-LOC episodes (58% had more than five episodes), with syncope and seizure characteristics. Duration of T-LOC was > 1 minute in 45% of patients. Ninety per cent described prodromal symptoms, especially hot flushing, blurred vision and dizziness. Abnormal movements were reported in 60% of patients.

Initial standard “separated” cardiological and/or neurological investigations

Investigations performed during initial diagnostic phase are detailed Table 3. Most patients had had first-line neurological investigations (95%), especially standard EEG (86%) and neuroimaging (75%). Only 39% had undergone cardiological investigations. Standard HUT had been performed previously in 21 patients. Few patients had experienced more invasive investigations (electrophysiological study, $n = 3$; implantable loop recorder, $n = 7$).

Diagnostic value of the combined HUT/video EEG strategy

Combined HUT/video EEG was diagnostic in 68 patients, including 59 cases of vasovagal syncope and nine cases of psychogenic pseudosyncope. Overall, 66 patients had haemodynamic changes, including seven false positives (i.e. haemodynamic changes without reproduction of the patient's usual symptoms). About 40% of patients with vasovagal response had myoclonic jerks related to convulsive syncope, probably similar to their usually reported seizure-like episodes. Cardioinhibitory response was observed in 16 patients (including six with prolonged asystole > 10 seconds), mixed response in 21 patients and vasodepressive response in 22 patients. All patients with cardioinhibitory response and mixed syncope had a history of myoclonic jerks. No patient had seizures.

Abnormal EEG activities were recorded in 44 patients during HUT, mostly generalized slow waves related to cerebral hypoperfusion during vasovagal syncope ($n = 26$). Analysis of the EEG recording was particularly informative in the “presumed epileptic” subpopulation. When presumption of epilepsy was only based on the clinical description, the EEG could easily demonstrate typical generalized slowing and even generalized suppression during an asystolic event, to explain the seizure-like episodes (Fig. 2). When the presumption was based on interictal EEG documentation, an accurate diagnosis could be achieved by the reproduction of previously syncopal symptoms in the

tilted position most of the time. Indeed, abnormal EEG activities were present from the beginning of test in 15 of these patients' profiles, but no link with vasovagal syncope could be established. None of the EEGs had epileptiform discharges, and those activities (mostly paroxysmal spike waves) were considered non-specific (Fig. 3). The haemodynamic and EEG data recorded during testing are detailed in Table 4, and final diagnoses are illustrated in Fig. 4.

A definitive diagnosis was achieved in 76% of the "presumed epileptic" subpopulation: 16/20 of those with interictal paroxysmal EEG activities; and 10/14 of those for whom prescription of AEDs was only based on clinical presumption. Among the 11 patients in the "confirmed epileptic" subpopulation, dual diagnosis of epilepsy and vasovagal syncope was established in eight cases by the combined strategy, without a need to change AED medication.

Bivariate predictors for a positive diagnosis were female sex (OR 3.98, 95% CI 1.6–9.9; $P = 0.023$), prodromal symptoms (OR 10.6, 95% CI 2.09–53.19; $P = 0.0018$) and jerking movements reported by an eyewitness during T-LOC (OR 6.9, 95% CI 2.74–17.37; $P < 0.0001$). In multivariable analysis, after adjustment for sex, prodrome and myoclonic jerks, independent predictors of a positive diagnosis were the presence of prodromal symptoms (OR 5.97, 95% CI 1.37–26; $P = 0.017$) and a history of myoclonic jerks during T-LOC (OR 4.36, 95% CI 1.71–11.15; $P = 0.002$).

Follow-up

After combined HUT/video EEG, AEDs were disrupted in 16/26 patients in the "presumed epileptic" subpopulation with a positive test and 2/8 with a negative test. During a median follow-up of 3 years, true epilepsy occurred in only one of these patients. Among the 59 patients with vasovagal syncope, only six had recurrent episodes (Fig. 5).

Discussion

Syncope is a common event in general population, with a lifetime prevalence of 3.5% and a cumulative incidence of 37% in young subjects [29]. In the absence of cardiovascular disease, vasovagal syncope is the most frequent aetiology. Epilepsy is another clinical condition with high prevalence rates in the general population, with a cumulative lifetime incidence of 3% [6]. Although the underlying pathophysiological processes are distinct, syncope and seizures share some clinical characteristics that may lead to diagnostic confusion [6-8]. The patient's history is crucial for the

diagnosis, but the diagnostic value of individual semiologic features is limited. Adding to the diagnostic complexity is the fact that seizures and syncope may co-exist in the same patient. Patients with misdiagnosis are often investigated excessively, treated inappropriately and have unnecessary restrictions placed on driving and employment.

HUT is particularly interesting in atypical and/or convulsive syncope [10, 12], but alone, it can fail to provide clinical details that may help to distinguish epileptic seizures and psychogenic events from convulsive syncope in patients who are diagnostic dilemmas [26-28, 30]. EEG plays an important role in the differential diagnosis of seizures. Non-specific EEG abnormalities, however, are very common, and the overinterpretation of EEGs is an important contributor to the misdiagnosis of epilepsy [18, 31, 32]. Confounding factors are thus numerous, either as a result of the atypical picture (myoclonic jerks, long T-LOC duration and postictal confusion related to intensity of cerebral hypoperfusion) or the recording of interictal abnormal EEG traces of undetermined clinical significance.

The main results of the study are: (1) the excellent diagnostic yield of the combined HUT/video EEG strategy in patients with unexplained seizure-like T-LOC; (2) the independent predictive value for a positive diagnosis of prodromal symptoms and jerking movements during T-LOC; (3) the good prognosis after AED disruption following the test results.

Diagnostic value of the “heart/brain” strategy in atypical unexplained T-LOC

In this study, the diagnostic yield of the combined HUT/video EEG approach was 67%, which could be considered high in patients previously undiagnosed. These results validate our “heart/brain” multidisciplinary diagnostic approach in such problematic patients, and are in accordance with those of LaRoche et al., who reported a 65% diagnostic yield in a similar adult patient population [27]. Despite these interesting results, combined HUT/EEG cannot be proposed for first-line evaluation, as the patients included in the study had had numerous investigations before testing, which suggests that they were highly selected. Otherwise, in the great majority of situations, HUT alone is good enough in the setting of unexplained T-LOC, even if convulsive. Recognition of the potential benefit of this innovative diagnostic tool, however, is likely to improve the evaluation of patients with atypical problematic T-LOC.

Diagnostic value of prodromal symptoms and jerking movements during T-LOC

In this study, the presence of prodromal symptoms and the description of myoclonic jerks during episodes by eyewitnesses were both predictors of a positive diagnosis. Symptoms such as seizure-like activity are often used to diagnose a seizure disorder. Even if prodromal symptoms are suggestive of vasovagal syncope, the differentiation of epileptic seizures from non-epileptic ones is sometimes problematic. Basically, epilepsy is a clinical diagnosis. Unless one happens to observe a seizure while recording the EEG, which is a rare event in general clinical practice, the diagnosis relies on the judgment of a physician or other healthcare providers. This judgment ultimately rests on the history provided by the patient or others. This critical point highlights the difficulty that physicians (even those who are well trained) can sometimes face when attempting to differentiate convulsive syncope from seizure. Many of the misdiagnosed patients had been initially diagnosed with epilepsy, and were prescribed AEDs, with potential adverse effects. Combined HUT/video EEG, by precisely analysing the diagnostic sequence “haemodynamic changes ⇨ EEG changes ⇨ T-LOC ⇨ myoclonus”, is often critical for making an accurate diagnosis, and subsequently selecting the appropriate treatment.

Great value of EEG recording in patients with a presumed diagnosis of epilepsy

In most atypical occurrences of T-LOC, a single HUT is useful for making the diagnosis, but if there is one subgroup in which the value of EEG recording during HUT cannot be questioned, it is the subgroup of patients with a presumed diagnosis of epilepsy. Indeed, the EEG recording was particularly informative within the subgroup of patients with interictal abnormal EEG traces. Without precise analysis of the semiologic sequence during the induced convulsive syncope, as already pointed out, it would have been impossible to achieve a definitive diagnosis in order to avoid unnecessary morbidity. In some of these patients, AEDs were continued despite a diagnostic standard HUT, because doubts persisted about the clinical significance of the abnormal interictal traces. It was then necessary to reproduce the patients' usual symptoms with concomitant analysis of cerebral activity. In the present study, a definitive diagnosis of convulsive vasovagal syncope was achieved in 16/20 patients with such a profile at the end of the combined test. As a consequence, AEDs, which had sometimes been prescribed for a long period, were disrupted. In the same way, an association between epilepsy and vasovagal syncope, rather than epilepsy worsening, was found in 8/11 patients

in the “true epileptic” subpopulation, and it was not necessary to increase or change their AED. Another important point relates to patients in whom pseudopsychogenic syncope could be definitively diagnosed because of the lack of haemodynamic and cerebral activity changes, despite a perfect simulation, in some cases, of usual pseudoseizure T-LOC.

Study limitations

Monitoring was carried out only during programmed in-hospital visits (no contact by telephone), and it is possible that some data were missed between two visits. We report a single-centre experience with trained physicians, and reproducibility of the test should be verified.

Conclusions

HUT combined with video EEG is useful to investigate atypical unexplained T-LOC with syncope and seizure characteristics as a second-line investigation, especially in case of myoclonic jerks and/or interictal EEG abnormalities. This suggests the need for closer and ongoing collaboration between neurologists and cardiologists, to provide optimal care for patients with the diagnostic dilemma of syncope or epileptic seizures.

Sources of funding

None.

Disclosure of interest

The authors declare that they have no conflicts of interest concerning this article.

References

- [1] Ganzeboom KS, Mairuhu G, Reitsma JB, Linzer M, Wieling W, van Dijk N. Lifetime cumulative incidence of syncope in the general population: a study of 549 Dutch subjects aged 35-60 years. *J Cardiovasc Electrophysiol* 2006;17:1172-6.
- [2] Blanc JJ, L'Her C, Gosselin G, Cornily JC, Fatemi M. Prospective evaluation of an educational programme for physicians involved in the management of syncope. *Europace* 2005;7:400-6.
- [3] Blanc JJ, L'Her C, Touiza A, Garo B, L'Her E, Mansourati J. Prospective evaluation and outcome of patients admitted for syncope over a 1 year period. *Eur Heart J* 2002;23:815-20.
- [4] Brignole M, Menozzi C, Bartoletti A, et al. A new management of syncope: prospective systematic guideline-based evaluation of patients referred urgently to general hospitals. *Eur Heart J* 2006;27:76-82.
- [5] Task Force for the Diagnosis and Management of Syncope, European Society of Cardiology, European Heart Rhythm Association, et al. Guidelines for the diagnosis and management of syncope (version 2009). *Eur Heart J* 2009;30:2631-71.
- [6] McKeon A, Vaughan C, Delanty N. Seizure versus syncope. *Lancet Neurol* 2006;5:171-80.
- [7] Sheldon R. How to Differentiate Syncope from Seizure. *Cardiol Clin* 2015;33:377-85.
- [8] Sheldon R, Rose S, Ritchie D, et al. Historical criteria that distinguish syncope from seizures. *J Am Coll Cardiol* 2002;40:142-8.
- [9] Boule S, Kouakam C, Brigadeau F. Very prolonged episode of self-terminating ventricular fibrillation in a patient with Brugada syndrome. *Can J Cardiol* 2013;29:1742 e1-3.
- [10] Grubb BP, Gerard G, Roush K, et al. Differentiation of convulsive syncope and epilepsy with head-up tilt testing. *Ann Intern Med* 1991;115:871-6.
- [11] Lacroix D, Kouakam C, Klug D, et al. Asystolic cardiac arrest during head-up tilt test: incidence and therapeutic implications. *Pacing Clin Electrophysiol* 1997;20:2746-54.
- [12] Zaidi A, Clough P, Cooper P, Scheepers B, Fitzpatrick AP. Misdiagnosis of epilepsy: many seizure-like attacks have a cardiovascular cause. *J Am Coll Cardiol* 2000;36:181-4.
- [13] Benditt DG, van Dijk G, Thijs RD. Ictal asystole: life-threatening vagal storm or a benign seizure self-termination mechanism? *Circ Arrhythm Electrophysiol* 2015;8:11-4.
- [14] Bestawros M, Darbar D, Arain A, et al. Ictal asystole and ictal syncope: insights into clinical management. *Circ Arrhythm Electrophysiol* 2015;8:159-64.

- [15] Kouakam C, Daems C, Guedon-Moreau L, et al. Recurrent unexplained syncope may have a cerebral origin: report of 10 cases of arrhythmogenic epilepsy. *Arch Cardiovasc Dis* 2009;102:397-407.
- [16] van der Lende M, Surges R, Sander JW, Thijs RD. Cardiac arrhythmias during or after epileptic seizures. *J Neurol Neurosurg Psychiatry* 2016;87:69-74.
- [17] Andre-Obadia N, Lamblin MD, Sauleau P. French recommendations on electroencephalography. *Neurophysiol Clin* 2015;45:1-17.
- [18] Trojaborg W. EEG abnormalities in 5,893 jet pilot applicants registered in a 20-year period. *Clin Electroencephalogr* 1992;23:72-8.
- [19] Zivin L, Marsan CA. Incidence and prognostic significance of "epileptiform" activity in the eeg of non-epileptic subjects. *Brain* 1968;91:751-78.
- [20] Benditt DG, Ferguson DW, Grubb BP, et al. Tilt table testing for assessing syncope. *American College of Cardiology. J Am Coll Cardiol* 1996;28:263-75.
- [21] Kenny RA, Ingram A, Bayliss J, Sutton R. Head-up tilt: a useful test for investigating unexplained syncope. *Lancet* 1986;1:1352-5.
- [22] Morillo CA, Ellenbogen KA, Fernando Pava L. Pathophysiologic basis for vasodepressor syncope. *Cardiol Clin* 1997;15:233-49.
- [23] Blad H, Lamberts RJ, van Dijk GJ, Thijs RD. Tilt-induced vasovagal syncope and psychogenic pseudosyncope: Overlapping clinical entities. *Neurology* 2015;85:2006-10.
- [24] Heitterachi E, Lord SR, Meyerkort P, McCloskey I, Fitzpatrick R. Blood pressure changes on upright tilting predict falls in older people. *Age Ageing* 2002;31:181-6.
- [25] Savage DD, Corwin L, McGee DL, Kannel WB, Wolf PA. Epidemiologic features of isolated syncope: the Framingham Study. *Stroke* 1985;16:626-9.
- [26] van Dijk JG, Thijs RD, van Zwet E, et al. The semiology of tilt-induced reflex syncope in relation to electroencephalographic changes. *Brain* 2014;137:576-85.
- [27] LaRoche S, Taylor D, Walter P. Tilt table testing with video EEG monitoring in the evaluation of patients with unexplained loss of consciousness. *Clin EEG Neurosci* 2011;42:202-5.
- [28] Yilmaz S, Gokben S, Levent E, Serdaroglu G, Ozyurek R. Syncope or seizure? The diagnostic value of synchronous tilt testing and video-EEG monitoring in children with transient loss of consciousness. *Epilepsy Behav* 2012;24:93-6.

- [29] Ganzeboom KS, Colman N, Reitsma JB, Shen WK, Wieling W. Prevalence and triggers of syncope in medical students. *Am J Cardiol* 2003;91:1006-8, A8.
- [30] Ammirati F, Colivicchi F, Di Battista G, Garelli FF, Santini M. Electroencephalographic correlates of vasovagal syncope induced by head-up tilt testing. *Stroke* 1998;29:2347-51.
- [31] Gregory RP, Oates T, Merry RT. Electroencephalogram epileptiform abnormalities in candidates for aircrew training. *Electroencephalogr Clin Neurophysiol* 1993;86:75-7.
- [32] Matur Z, Baykan B, Bebek N, Gurses C, Altindag E, Gokyigit A. The evaluation of interictal focal EEG findings in adult patients with absence seizures. *Seizure* 2009;18:352-8.

Figure legends

Figure 1. A. Flow chart for the diagnostic approach to patients with atypical transient loss of consciousness (T-LOC). The study population also included patients with epilepsy undergoing long-term follow-up at the epilepsy unit to re-evaluate if recurrent T-LOCs were syncopal rather than epileptic (e.g. different T-LOC picture or poor response to antiepileptic drugs). B. Different possible diagnostic sequences during combined “heart/brain” testing, i.e. head-up tilt test (HUT)/video electroencephalogram (EEG): each timeline represents a diagnostic possibility, taking into account HUT-induced haemodynamic changes and EEG abnormalities.

Figure 2. Electroencephalogram (EEG) recording during head-up tilt test (HUT) in patients in the “presumed-epileptic” subpopulation treated with antiepileptic drugs (AEDs) based only on clinical suspicion of epilepsy (normal EEGs). HUT induced convulsive transient loss of consciousness with generalized myoclonus related to malignant vasovagal syndrome, with cardiac asystole of 10-second duration (see the electrocardiogram channel in pink). The EEG demonstrated generalized slowing as a result of cerebral hypoperfusion, followed by generalized suppression during asystole and generalized slowing again on resumption of sinus rhythm (“slow-flat-slow” pattern). In this case, malignant vasovagal syncope was associated with features closely mimicking seizures, and combined HUT/video EEG proved to be useful to achieve a definite correct diagnosis and to disrupt unnecessary AEDs.

Figure 3. Electroencephalogram (EEG) during head-up tilt test (HUT) in a patient in the “presumed-epileptic” subpopulation treated with antiepileptic drugs (AEDs) based on atypical presentation with documented interictal abnormal EEG. In this case, HUT induced convulsive transient loss of consciousness (T-LOC) related to severe bradycardia and hypotension, making the diagnosis cardioinhibitory vasovagal syncope. Paroxysmal diffuse sharp waves had been previously registered outside any recurrent T-LOC, causing the misdiagnosis of epilepsy. At the beginning of the examination, the same sharp waves were registered, but without any clinical significance (top of figure). At the onset of induced syncope, the EEG demonstrated generalized slowing as a result of cerebral hypoperfusion (bottom of figure). Convulsive vasovagal syncope was associated with

features closely mimicking seizures, and combined HUT/video EEG proved to be useful to achieve a definite correct diagnosis and to stop AEDs. Without the use of a combined “heart/brain” test it would probably have been impossible to determine the precise mechanism of the underlying disorders, in particular the correlation between the “epileptiform” interictal activities documented and T-LOC episodes.

Figure 4. Definite diagnosis in patient with symptom reproduction according to the predetermined diagnostic strategy flow chart. Each timeline represents a diagnostic sequence. EEG: electroencephalogram; HUT: head-up tilt test; T-LOC: transient loss of consciousness.

Figure 5. Outcome of patients with a positive diagnosis. AED: antiepileptic drug; EEG: electroencephalogram; HUT: head-up tilt test; T-LOC: transient loss of consciousness.

Table 1 Demographic and baseline characteristics of the study population.

	Total (<i>n</i> = 101)	No diagnosis (<i>n</i> = 33; 33%)	Positive diagnosis (<i>n</i> = 68; 67%)	<i>P</i>
Age (years)	26 [19; 46]	23 [19; 49]	27 [19; 46]	0.89
Female sex ^a	72 (72)	17 (52)	55 (81)	0.0022
Cardiovascular co-morbidities ^a	17 (17)	6 (18)	11 (16)	0.8
Hypertension	9	1	8	
Cardiac valvulopathy	2	2	0	
Myocardial infarction	1	1	0	
Congenital cardiopathy	1	1	0	
Accessory pathway	1	0	1	
Peripheral arteriopathy	1	1	0	
Congenital long QT syndrome	1	0	1	
Neurological diseases ^a	19 (19)	7 (21)	12 (18)	0.67
Migraine without aura	9	3	6	
Migraine with aura	1	1	0	
Multiple sclerosis	2	1	1	
Stroke	2	1	1	

Tumour	3	1	2	
Viral encephalitis	1	0	1	
History of "epileptic seizure" ^a	45 (45)	11 (33)	34 (50)	0.11
EEG abnormalities correlated with seizure (confirmed epilepsy) ^b	11 (11)	3 (9)	8 (12)	1
Documented interictal paroxysmal EEG activities (presumed epilepsy) ^b	20 (20)	4 (12)	16 (24)	0.18
AED treatment despite normal EEG (presumed epilepsy) ^b	14 (14)	4 (12)	10 (15)	1
Psychiatric illness ^b	10 (10)	4 (12)	6 (9)	0.72
AED-treated patients ^a	42 (42)	10 (30)	32 (47)	0.11
AED treatment duration (years)	1 [0.4; 3]	1 [0; 1]	1.5 [0.4; 3]	0.13
Antihypertensive treatment ^b	14 (14)	6 (18)	8 (12)	0.38
ACE-I	7 (7)	3 (9)	4 (6)	
Beta-blocker	7 (7)	3 (9)	4 (6)	
Diuretic	3 (3)	2 (6)	1 (1)	
Calcium channel blocker	3 (3)	0	3 (4)	

Data are expressed as median [interquartile range], number (%) or number. AED: antiepileptic drug; ACE-I: angiotensin-converting-enzyme inhibitor;

EEG: electroencephalogram.

^a χ^2 test.

^b Fischer's exact test.

Table 2 Details of transient loss of consciousness characteristics in the study population.

	Total	No diagnosis	Positive diagnosis	<i>P</i>
	(<i>n</i> = 101)	(<i>n</i> = 33; 33%)	(<i>n</i> = 68; 67%)	
Duration of symptoms (months)	24 [10; 54]	24 [5; 66]	24 [12; 45]	0.81
Number of T-LOC episodes				
1	6 (6)	2 (6)	4 (6)	
2–5	35 (35)	14 (42)	21 (31)	
> 5	59 (58)	14 (42)	45 (66)	
T-LOC duration > 1 min ^a	46 (45)	12 (36)	24 (35)	0.54
Prodromal symptoms ^a	91 (90)	25 (76)	66 (97)	0.0018
Hot flushing	36	8	28	
Ringing in the ears (tinnitus)	17	7	10	
Blurred or faded vision	34	13	21	
Diaphoresis	10	2	8	
Dizziness/light-headedness	30	12	18	
Nausea/epigastric discomfort	17	3	14	
Paraesthesias	19	6	13	
Headache	5	2	3	
History of myoclonic jerks ^b	61 (60)	10 (30)	51 (75)	< 0.0001

Postictal confusion ^b	30 (30)	10 (30)	20 (29)	0.93
----------------------------------	---------	---------	---------	------

Data are expressed as median [interquartile range], number (%) or number. T-LOC: transient loss of consciousness.

^a Fischer's exact test.

^b χ^2 test.

Table 3 Details of cardiological and neurological assessment during first-line standard evaluation.

	Total	No diagnosis	Positive diagnosis	<i>P</i>
	(<i>n</i> = 101)	(<i>n</i> = 33; 33%)	(<i>n</i> = 68; 67%)	
Cardiological investigations ^a	39 (39)	14 (42)	25 (37)	0.58
Echocardiography	26 (26)	9 (27)	17 (25)	
Stress test	12 (12)	7 (21)	5 (7)	
Head-up tilt test	12 (12)	3 (9)	9 (13)	
Ambulatory Holter ECG	21 (21)	9 (27)	12 (18)	
Ambulatory BP monitoring	3 (3)	2 (6)	1 (1)	
Implantable loop recorder	7 (7)	3 (9)	4 (6)	
Electrophysiological study	3 (3)	2 (6)	1 (1)	
Neurological investigations ^b	95 (95)	30 (91)	65 (96)	0.39
MRI scan	63 (62)	18 (55)	45 (66)	
CT scan	13 (13)	2 (6)	11 (16)	
Standard EEG recording	87 (86)	26 (79)	61 (90)	
Prolonged video EEG	27 (27)	8 (24)	19 (28)	

Data are expressed as number (%). BP: blood pressure; CT: computed tomography; ECG: electrocardiogram; EEG: electroencephalogram; MRI: magnetic resonance imaging.

^a χ^2 test.

^b Fischer's exact test.

Table 4 Head-up tilt test and electroencephalogram data collected during combined head-up tilt test/video electroencephalogram testing.

	Total (<i>n</i> = 101)	No diagnosis (<i>n</i> = 33; 33%)	Positive diagnosis (<i>n</i> = 68; 67%)	<i>P</i>
HUT data				
Haemodynamic (HR/BP) changes ^a	66 (65)	7 (23)	59 (83)	< 0.0001
True positive	59	0	59	
False positive	7	7	0	
No haemodynamic (HR/BP) changes	35 (35)	26 (87)	9 (13)	
Sensitization ^a	71 (70)	29 (88)	42 (48)	0.007
Isoproterenol ^a	61 (60)	25 (76)	36 (50)	0.027
Nitroglycerine ^a	26 (26)	13 (39)	13 (18)	0.029
Positive HUT responses				
Delay of positivity (minutes)	30 [16; 40]	33 [17; 40] ^b	30 [16; 40]	
Cardioinhibitory response	10 (10)	0 ^b	10 (14)	
Prolonged asystole	6 (6)	0 ^b	6 (9)	
Mixed response	23 (23)	2 (7) ^b	21 (31)	
Vasodepressive response	27 (27)	5 (17) ^b	22 (32)	
Myoclonic jerks	22 (22)	0 ^b	22 (32)	
Video EEG data				

Patients with abnormal EEG activity ^a	44 (44)	10 (30)	34 (50)	0.06
Details of EEG abnormalities				
Slow waves	26 (26)	3 (9)	23 (34)	
Slow waves and paroxysmal activities	3 (3)	0	3 (4)	
Paroxysmal activities	15 (15)	7 (21)	8 (12)	
Sequence of EEG abnormalities in patients with positive HUT and HMD changes				
After T-LOC	18 (18)	0 ^b	18 (26)	
Before and after T-LOC	17 (17)	2 (6) ^b	15 (22)	
EEG abnormalities without any HMD changes	9 (9)	8 (24)	1 (1)	

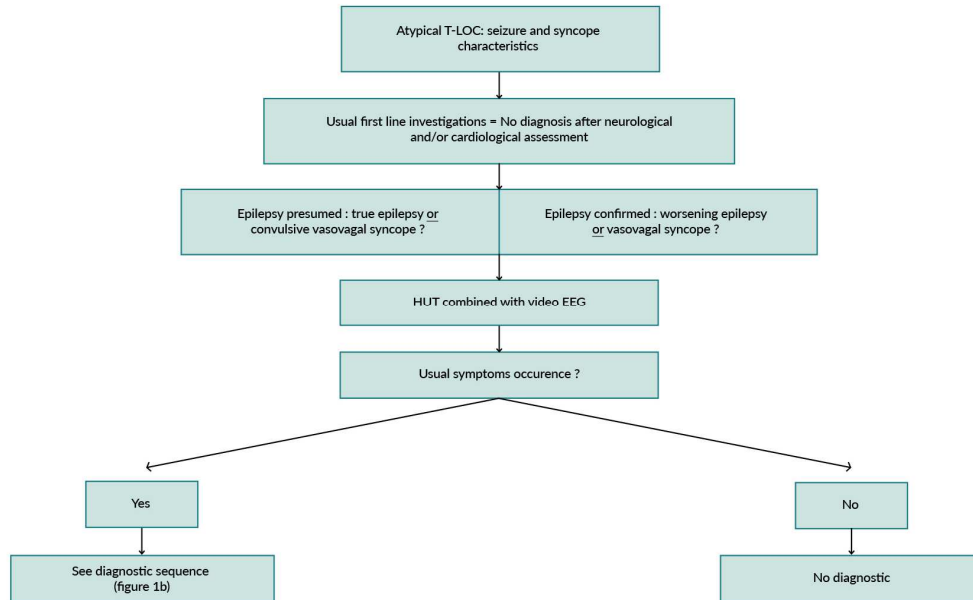
Data are expressed as number (%), number or median [interquartile range]. BP: blood pressure; EEG: electroencephalogram; HR: heart rate; HMD: haemodynamic; HUT: head-up tilt test; T-LOC: transient loss of consciousness.

^a χ^2 test.

^b Data from false positive responses

Figure 1

A



B

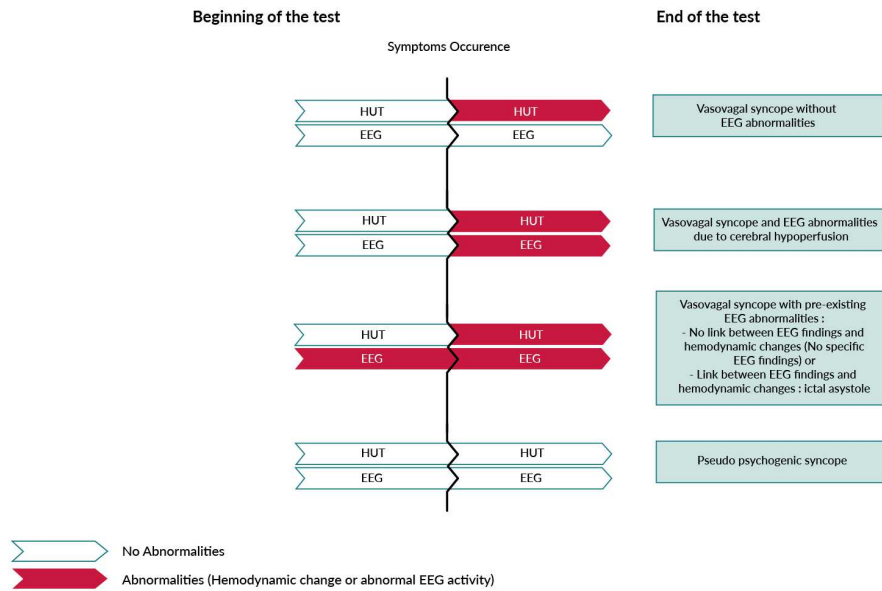


Figure 2

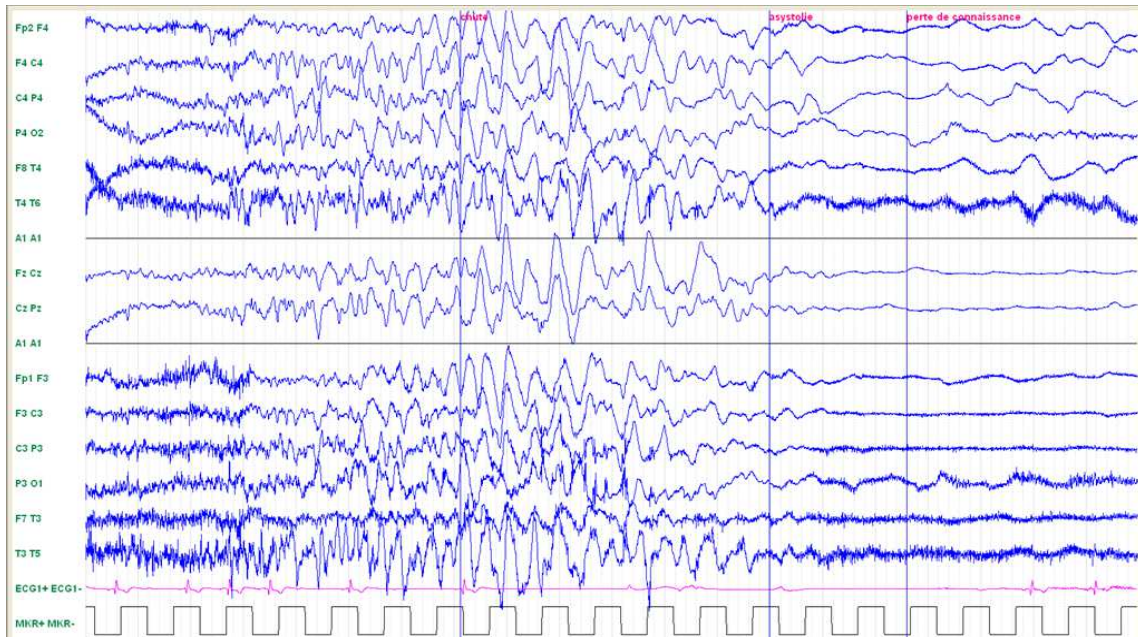


Figure 3

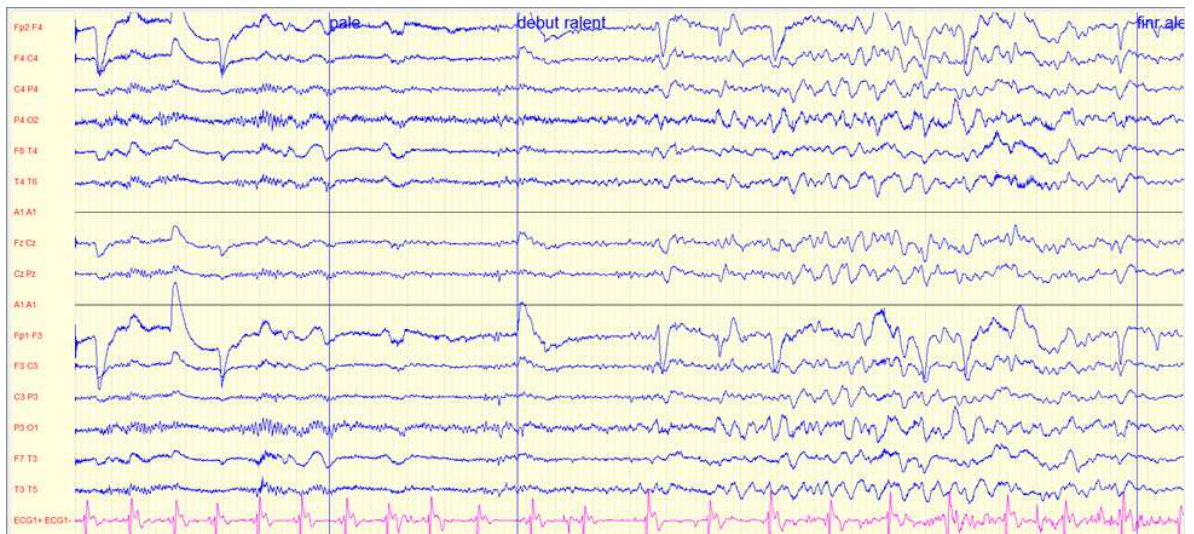
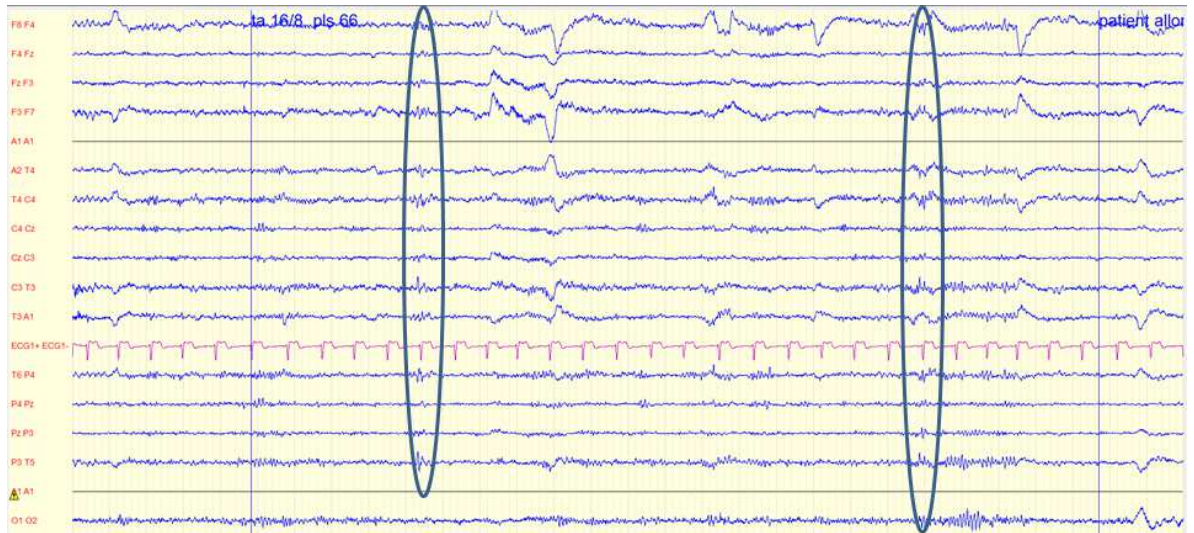


Figure 4

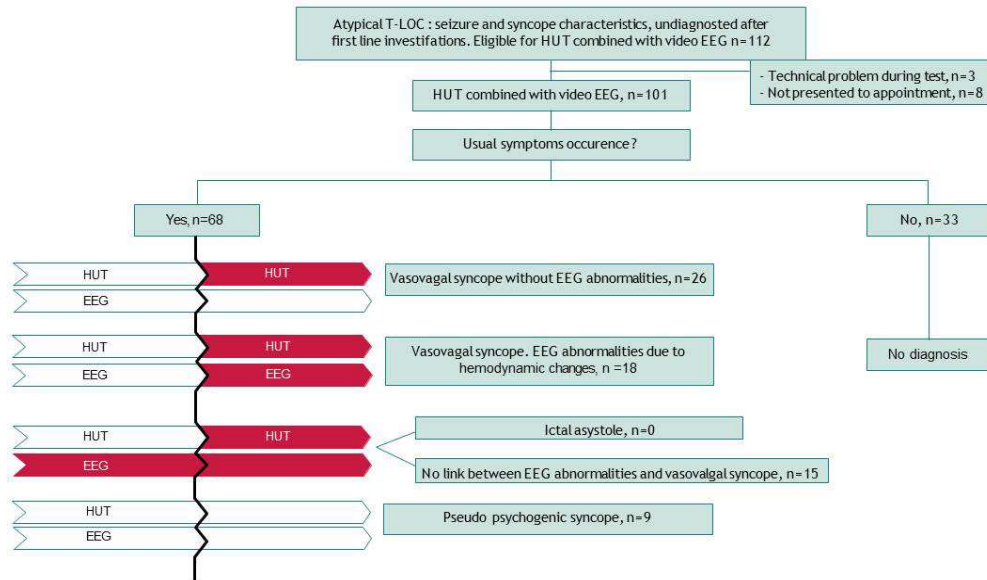


Figure 5

