



## **A novel nonsense PIEZO2 mutation in a family with scoliosis and proprioceptive defect**

Marion Masingue, Julien Fauré, Guilhem Solé, Tanya Stojkovic, Sarah Léonard-Louis

### **► To cite this version:**

Marion Masingue, Julien Fauré, Guilhem Solé, Tanya Stojkovic, Sarah Léonard-Louis. A novel nonsense PIEZO2 mutation in a family with scoliosis and proprioceptive defect. *Neuromuscular Disorders*, 2019, 29, pp.75 - 79. 10.1016/j.nmd.2018.10.005 . hal-03486192

**HAL Id: hal-03486192**

**<https://hal.science/hal-03486192>**

Submitted on 20 Dec 2021

**HAL** is a multi-disciplinary open access archive for the deposit and dissemination of scientific research documents, whether they are published or not. The documents may come from teaching and research institutions in France or abroad, or from public or private research centers.

L'archive ouverte pluridisciplinaire **HAL**, est destinée au dépôt et à la diffusion de documents scientifiques de niveau recherche, publiés ou non, émanant des établissements d'enseignement et de recherche français ou étrangers, des laboratoires publics ou privés.



Distributed under a Creative Commons Attribution - NonCommercial 4.0 International License

1    **A novel nonsense *PIEZO2* mutation in a family with scoliosis and proprioceptive defect**

2    Marion Masingue<sup>1</sup>

3    Julien Faure<sup>2, 3</sup>

4    Guilhem Solé<sup>4</sup>

5    Tanya Stojkovic<sup>1</sup>

6    Sarah Léonard-Louis<sup>1</sup>

7    <sup>1</sup>Centre de Référence de Pathologie Neuromusculaire Nord/Est/Ile de France, Institut de

8    Myologie, CHU La Pitié-Salpêtrière, APHP, Paris, France

9    <sup>2</sup>University Grenoble Alpe F-38000 France

10    <sup>3</sup>CHU Grenoble, Biochimie et Génétique Moléculaire, Grenoble, F-38000 France

11    <sup>4</sup>Centre de référence des maladies neuromusculaires AOC, Hôpital Pellegrin, CHU de

12    Bordeaux, Bordeaux, France

13

14    **Corresponding author:** Marion Masingue [marion.masingue@aphp.fr](mailto:marion.masingue@aphp.fr)

15

**16 ABSTRACT**

17 *PIEZO2* mutations have been described in dominant arthrogryposis, but homozygous  
18 mutations of *PIEZO2* may also be responsible for more complex clinical patterns, associating  
19 distal arthrogryposis, neonatal respiratory insufficiency, scoliosis and proprioceptive  
20 impairment. We report here two sisters presenting with these clinical and genetic features.  
21 They had a similar phenotype, with severe hypotonia and respiratory distress at birth, delayed  
22 acquisition of motor milestones and need of scoliosis surgery. Hypotonia and alteration of  
23 proprioception were at the forefront of clinical examination for both, along with areflexia,  
24 hyperlaxity, *cutis laxa*, and discrete facial dysmorphism. Electrophysiological studies, including  
25 electroneuromyography and sensory evoked potentials, showed a mild sensory axonopathy  
26 without any myopathic features, but revealed a peripheral proximal lemniscal defect. Creatine  
27 kinase, muscular MRI and biopsy were normal, as well as cerebral MRI and neurometabolic  
28 biological explorations. They had a moderate restrictive syndrome on respiratory function  
29 tests and cardiac function was normal. Molecular studies performed on a panel of genes  
30 involved in distal arthrogryposis disclosed a nonsense homozygous c.3241C>T (p.Arg1051\*)  
31 mutation in the *PIEZO2* gene, which was also present at the heterozygous state in their  
32 mother's DNA. This new *PIEZO2* mutation was in accordance with the phenotype combining  
33 arthrogryposis, scoliosis, hyperlaxity and proprioceptive impairment.

34

**35 HIGHLIGHTS**

36 Arthrogryposis and proprioceptive defects suggests a recessive *PIEZO2* mutation

37 Patients with arthrogryposis should be screened for *PIEZO2* mutations

38 Dominant PIEZO2 mutations are mostly missense whereas recessive cases are truncating

39 **KEYWORDS**

40 PIEZO2

41 Arthrogryposis

42 Proprioceptive impairment

43

44 **Abbreviations**

45 ENMG: Electroneuromyography; SEP: Sensory Evoked Potentials; DA: Distal

46 Arthrogryposis; MWS: Marden-Walker Syndrome;

## 1. INTRODUCTION

Arthrogryposis is defined by reduced mobility of multiple joints and highly heterogeneous, with more than 400 genes described. Arthrogryposis can be of both dominant and recessive inheritance, and associated with other clinical features, namely orthopedic malformations, facial deformities, central nervous system (CNS) abnormalities, peripheral neuropathy or myopathy. [1] Among these genes, heterozygous missense *PIEZO2* mutations have been associated with either distal Gordon Syndrome (Distal arthrogryposis (DA) type 3 or DA type 5 or Marden-Walker Syndrome (MWS) [5]. Later on, homozygous nonsense mutations in the *PIEZO2* gene have been held responsible for arthrogryposis, scoliosis and, strikingly, proprioception defects [6], neonatal respiratory insufficiency [7, 8] and muscle weakness [9].

*PIEZO* polypeptides are mechanosensitive transmembrane cation channels [2,3]. They are expressed in several mechanosensitive tissues, such as neurons of the dorsal root ganglia, endothelium and visceral tissues, including lungs. Mouse models lacking *PIEZO2* in mechanosensory neurons showed impaired limb coordination, and unstable gait [4].

We describe here the cases of two sisters prominently characterized by distal arthrogryposis and proprioception loss; a clinical phenotype which led us to find a novel nonsense homozygous mutation in the *PIEZO2* gene.

64

## 2. MATERIALS AND METHODS

### 2.1. Patients

We report the cases of two twin sisters of Tunisian origin, followed from age 20 to 24 years (Patient II.3 and II.4), the first one (Patient II.3) at the Neuromuscular Reference Center of

69 Pitié Salpêtrière Hospital (Paris) and the other (Patient II.4) at the Neuromuscular Reference  
70 Center in the University Hospital of Bordeaux.

## 71 2.2.Clinical, electrophysiological and muscle Magnetic Resonance Imaging features

72 Both sisters have undergone clinical examination, extended neurophysiological evaluations,  
73 including electroneuromyography (ENMG) and sensory evoked potentials (SEP). Routine  
74 biological analyses, including lysosomal enzymes and vitamin dosages, have been performed,  
75 as well as respiratory function tests, cardiac explorations (Patient II.3 and II.4), muscle  
76 Magnetic Resonance Imaging (MRI) (Patient II.3). and biopsy (Patient II.3 and II.4).

## 77 2.3.Genetic studies

78 All samples were processed after informed consents for molecular diagnosis had been  
79 obtained from the patients. Mutations in the probands' DNA have been screened on a panel of  
80 eleven genes involved in distal arthrogryposis. The design of the gene panel was realized with  
81 the AmpliSeq Designer tool (Thermo Fischer Scientific) and libraries for Next Generation  
82 Sequencing (NGS) were prepared according to manufacturer recommendations and analyzed  
83 on IonTorrent PGM instrument (Thermo Fischer Scientific). The coverage for the *PIEZO2*  
84 gene (NM\_022068) was 99.3 % with a mean depth of 390X (ranging from 34 to 1486).  
85 Results of the sequencing were processed with the Torrent Suite 5.0 (Thermo Fischer  
86 Scientific) and annotation of the variants performed with a homemade script based on the  
87 Variant Effect Predictor tool [10]. The presence of the mutation was controlled by Sanger  
88 sequencing using specific primer designed to amplify exon 22 of the *PIEZO2* gene and an  
89 ABI PRISM Big Dye Terminator Cycle Sequencing (V3.0) reaction kit with an analysis on an  
90 ABI 3130 DNA Analyzer (Thermo Fischer Scientific).

## 91 3. RESULTS

### 92 3.1.Clinical, electrophysiological and muscle MRI features

93 Our 2 patients were born from healthy parents, who were not known to be consanguineous.  
94 They had 5 siblings, including one sister (II.2) who died at six years of age, with similar  
95 symptoms. Their father died in a car accident at age 32 (Figure 1)

96 Pregnancy was uneventful, but the 2 sisters were severely hypotonic at birth and experienced  
97 transient neonatal respiratory failure. Later on, they displayed delayed acquisitions of motor  
98 skills and started walking independently at 5 (Patient II.4) and 7 (Patient II.3) years only.

99 From the onset of the disease, gait was very unstable, and a wheelchair was needed early on  
100 during childhood. They also had severe scoliosis, requiring arthrodesis in both cases.

101 There was no cognitive impairment, and both sisters were able to pursue higher studies.

102 On examination, at age 20, hypotonia was still at the fore. Both patients displayed diffuse  
103 distal wasting along with muscular deficit and discrete fingers and wrist retractions,  
104 compatible with arthrogryposis. Hyperlaxity was noticed in multiple joints. Proprioceptive  
105 abnormalities were major, with diffuse apallesthesia, positive Romberg sign, and unsteady  
106 wide-based gait, as well as dysmetria appearing with eyes closed. Tendon reflexes were  
107 abolished in the four limbs. There was no facial involvement, no cerebellar ataxia, no  
108 pyramidal or bulbar syndrome, and no ocular motor impairment. Patient II.3 also displayed  
109 *cutis laxa* (Figure 2)

110 ENMG showed a mild sensory axonal neuropathy in patient II.3 and was normal in patient  
111 II.4. There was no myopathic feature in both sisters. SEP revealed bilateral impairment of  
112 lemniscal sensory pathways for both (Figure 3). Cerebral and medullar MRI were normal,  
113 apart from the scoliosis. Muscular MRI showed no abnormality in patient II.3. Muscular  
114 biopsy was normal for patient II.3 and showed mild muscular abnormalities for patient II.4:  
115 type 2 fiber predominance and rare isolated concentric lamellar bodies.

Respiratory function tests revealed a mild restrictive syndrome. The forced vital capacity was 46% (Patient II.3) and 69% (Patient II.4) of predicted value. No other functional studies were realized to assess diaphragmatic function.

Echocardiography and electrocardiogram were normal.

### 3.2.Molecular findings

Patient 1 was first screened for the *FKBP14* gene, known to be responsible for Ehlers-Danlos Syndrome with progressive kyphoscoliosis and myopathy [11]. No mutation was found, and DNA of the patient was then screened for genes involved in distal arthrogryposis on a gene panel with an IonTorrent PGM instrument. The mean coverage for a minimal depth of 30X for the 11 genes explored was 92.45 %. The analysis of SNP with an allelic frequency under a threshold of 0.5% in the EXAC database identified only the c.3241C>T;p.Arg1051\* variation in the exon 22 of the *PIEZO2* gene at the homozygous state. This variation resulted in a premature STOP codon in exon 22 and in a biallelic loss-of-function of the *PIEZO2* gene. The segregation of the variation performed on the DNA of the probands' mother and sister showed compatibility with a recessive mode on inheritance. The father's DNA was not available.

## 4. DISCUSSION

A recessive condition associating arthrogryposis and a proprioception defect with transient respiratory failure, scoliosis, hypotonia, hyperlaxity is highly evocative of *PIEZO2* biallelic loss-of-function mutation, as established by previously published works [6-9] (Table 1). The clinical phenotype of our two patients, encompassing these features, led us to a specific DNA sequencing targeting the *PIEZO2* gene, and allowed us to identify a novel homozygous mutation, without using whole exome or mendeliome sequencing as previously described [6-



9]. It is worth noticing that our two patients, although most of our symptoms were similar, displayed some phenotypical differences: age of motor skills achievement, ENMG and biopsy findings. The fact that they were followed in two different centers could account for those findings, this might suggest that there is some variability in the clinical expression of the disease.

#### 4.1. Two types of *PIEZO2* mutations inducing two different phenotypes

*PIEZO2* gene mutations are particularly interesting and may cause two very distinguishable phenotypes according to the type of mutation and their mode of inheritance. Homozygous recessive mutations lead to a loss of function of the gene, whereas heterozygous dominant mutations cause a gain of function. Consequently, those two mechanisms induce very different conditions: although they share some clinical characteristics, namely arthrogryposis and scoliosis, there are distinguished by the presence of severe alterations of proprioception in the **biallelic** *PIEZO2* whereas the heterozygous mutations correspond to a purer form of distal arthrogryposis, such as Gordon Syndrome, Marden-Walker Syndrome, or Distal Arthrogryposis Type 5 [2,5].

#### 4.2. *PIEZO2* and proprioception

So far, mutations of *PIEZO2* seem to be the only possible genetic cause of proprioception impairment with arthrogryposis. In humans, specialized mechanosensory neurons called proprioceptors convey information about the stretch and tension experienced by muscles, tendons, skin, and joints. *PIEZO* polypeptides are mechanosensitive cation channels and are activated in response to mechanical displacement of the cell surface membrane. [3]

*PIEZO2* is expressed, in particular, at the endings of somatosensory neurons, which convey information about tension and stretch experienced by joints, skin, muscles and tendons [4, 8]. Mice models have evidenced that *PIEZO2* is responsible for the transduction of rapidly-

adapting mechanically-activated currents in the neurons of the dorsal root ganglia [2]. These findings explain why *PIEZO2* loss-of-function mutations cause a very specific phenotype with a characteristic proprioceptive defect

The mild axonal neuropathy observed in Patient II.3 seems to be a frequent characteristic of patients with biallelic *PIEZO2* mutations [7-9], although not explaining the proprioceptive defect in itself.

#### 4.3. Possible mechanisms for other clinical features encountered in *PIEZO2* mutations

It has been suggested that *PIEZO2* mutations may cause dysregulation of mechanotransduction affecting both cartilage constitution [12] and development of skeletal muscles [5] possibly leading to arthrogryposis and orthopedic abnormalities.

As a matter of fact, in patient 2, muscle biopsy revealed non-specific mild myopathic features, findings that have been described previously in recessive *PIEZO2* mutations [9].

Respiratory impairment has also been described and is at least partially explained in adulthood by severe scoliosis and diaphragmatic weakness, whereas in cases of neonatal respiratory failure, it is more likely the consequence of diaphragmatic weakness only.

Alternatively, a role for *PIEZO2* was suggested as a mechanosensor required for correct lung development [13].

#### 4.4. A unique cause for proprioceptive defects and arthrogryposis

Hereditary proprioceptive defect is caused by numerous hereditary sensory neuropathies but usually with severe axonal neuropathy. It has much more rarely been described when caused by proximal lemniscal pathways impairment. Neurometabolic diseases such as Friedreich ataxia, Vitamin E deficiency or hypobetalipoproteinemia may show posterior cord involvement on SEPs, but patients also display central nervous system symptoms [14,15]. A

case of hereditary sensory ataxic neuropathy has been reported in a Japanese family with a mild sensory axonal neuropathy but significantly prolonged central conduction time on SEPs. Patients were not screened for *PIEZO2* mutations, but, unlike ours, their sensory complaints went beyond sole ataxia, proximal muscle weakness was systematic, age at onset was much older (after 40 years), and there was neither scoliosis nor respiratory failure. [16].

More recently, mutations in *RFN170* coding for the Ring Finger Protein 170 have been described, responsible for progressive sensory ataxia linked to degeneration of the posterior columns of the spinal cord. Patients with *RFN170* mutations had, however, a progressive, isolated, form of ataxia predominating in the legs; they were older, and inheritance was dominant. [17]. Mutations in the *FLVCR1* gene also cause posterior column ataxia, sometimes associated with scoliosis and *retinis pigmentosa*, but ENMG reveals a ganglionopathy [18].

Finally, secondary arthrogryposis may occur in several neuromuscular disorders, and thus could be associated with conditions causing proprioceptive defects and neuropathy. However, in those cases, it tends to appear later on in the course of the disease than in our patients.

*PIEZO2* is a unique gene with two very distinct phenotypes corresponding to the inheritance mode. As heterozygous dominant mutations are responsible for arthrogryposis multiplex congenita, *PIEZO2* biallelic mutations have a typical clinical presentation, with scoliosis and proprioceptive deficit as main symptoms, together with arthrogryposis, hypotonia and transient neonatal respiratory failure. The role of *PIEZO2* as a mechanosensitive receptor in somatosensory neurons and its implication in bones and joint development as well as lung development probably intervene in the occurrence of those symptoms. The association of these clinical features is highly evocative and should prompt practitioners to screen *PIEZO2*

209 gene, as few other disorders display the same characteristics.

210

211

## 212 **DECLARATIONS**

213 **Ethics approval and consent to participate:** Authors declare that this work received all  
214 necessary ethical approvals and that all the patients involved consented to participate.

215 **Consent for publication:** Yes.

216 **Availability of data and material:** Please contact author for data requests.

217 **Competing interests:** Authors declare no financial or non-financial competing interests in  
218 relation to this manuscript.

219 **Funding:** No funding was necessary

220 **Author contributions:** MM, JF, GS, TS, SLL were involved in conception and design of the  
221 research project, in analysis and interpretation of the data. MM, TS and SLL were involved  
222 and writing of the first draft of the manuscript. SLL and GS were involved in the acquisition  
223 of clinical data and JF was involved in the acquisition of molecular data. All authors read and  
224 approved the final manuscript.

225

226

227 **REFERENCES**

228 [1] Hall, JG. Arthrogryposis (multiple congenital contractures): diagnostic approach to  
 229 etiology, classification, genetics, and general principles. Eur J Med Genet. 2014;57(8):464-72

230 [2] Coste B, Mathur J, Schmidt M, Earley TJ, Ranade S, Petrus Mj, et al. Piezo1 and Piezo2  
 231 are essential components of distinct mechanically-activated cation channels. Science. 2010  
 232 October 1; 330(6000): 55–60.

233 [3] Alper SL. Genetic Diseases of PIEZO1 and PIEZO2 dysfunction. Curr Top Membr.  
 234 2017;79:97-134

235 [4] Woo SH, Lukacs V, De Nooij JC, Zaytseva D, Criddle CR, Francisco A, et al. Piezo2 is  
 236 the principal mechanotransduction channel for proprioception. Nat Neurosci.  
 237 2015;18(12):1756-62

238 [5] McMillin, M. J., Beck, A. E., Chong, J. X., Shively, K. M., Buckingham, K. J.,  
 239 Gildersleeve, H. I et al. Mutations in PIEZO2 cause Gordon syndrome, Marden-Walker  
 240 syndrome, and distal arthrogryposis type 5. Am J of Hum Gen. 2014;94(5):734-44.

241 [6] Mahmud AA, Nahid NA, Nassif C, Sayeed MSB, Ahmed MU, Parvee M, et al. Loss of  
 242 the proprioception and touch sensation channel PIEZO2 in siblings with a progressive form of  
 243 contractures. Clin Genet. 2017;91(3):470-75

244 [7] Delle Vedove A, Storberck M, Heller R, Hölker I, Hebbbar M, Shukla A, et al. Biallelic  
 245 loss of proprioception-related PIEZO2 causes muscular atrophy with perinatal respiratory  
 246 distress, arthrogryposis and scoliosis. Am J of Hum Gen. 2016;99(5):1206-16

247 [8] Chelser AT, Szczot M, Bharucha-Goebel D, Ceko M, Donkervoort S, Laubacher C et al.  
 248 The role of PIEZO2 in Human Mechanosensation. N Engl J Med. 2016;375(14):1355-64

- 249 [9] Haligolu G, Becker K, Temucin C, Talim B, Kuçukçahin N, Pergande M, et al. Recessive  
250 PIEZO2 stop mutation causes distal arthrogryposis with distal muscle weakness, scoliosis and  
251 proprioception defects. *J Hum Genet.* 2017;62(4):497-501
- 252 [10] McLaren W, Gil L, Hunt SE, Riat HS, Ritchie GR, Thormann A, et al. The Ensembl  
253 Variant Effect Predictor. *Genome Biol.* 2016;17:122
- 254 [11] Baumann M, Giunta C, Krabichler B, Rüschendorf F, Zoppi N, Colombi M et al.  
255 Mutations in FKBP14 cause a variant of Ehlers-Danlos syndrome with progressive  
256 kyphoscoliosis, myopathy, and hearing loss. *Am J Hum Genet.* 2012;10;90(2):201-16.
- 257 [12] Lee W, Leddy HA, Chen Y, Hee Lee S, Zelenski A, McNulty AI et al. Synergy between  
258 Piezo1 and Piezo2 channels confers high-strain mechanosensitivity to articular cartilage. *Proc*  
259 *Natl Acad Sci U S A.* 2014;111(47):E5114-22
- 260 [13] Nonomura K, Woo SH, Chang RB, Gillich A, Qiu Z, Francisco AG. Piezo2 senses  
261 airway stretch and mediates lung inflation-induced apnoea. *Nature.* 2017;541(7636):176-81.
- 262 [14] Tsuji S, Uozumi T, Ito Y, Ohnishi A, Murai Y. Serial somatosensory evoked potentials  
263 in a patient with familial hypobetalipoproteinemia and vitamin E deficiency. *Jpn J Med*  
264 *1990;29(6):628-32*
- 265 [15] Zouari M, Feki M, Ben Hamida C, Larmaout A, Turki I, Belal S et al. Electrophysiology  
266 and nerve biopsy: comparative study in Friedreich's ataxia and Friedreich's ataxia phenotype  
267 with vitamin E deficiency. *Neuromuscul Disord.* 1998;8(6):416-25
- 268 [16] Murakami T, Fukai Y, Rikimaru M, Henmi S, Ohsawa Y, Sunada Y. Hereditary sensory  
269 ataxic neuropathy associated with proximal muscle weakness in the lower extremities. *J*  
270 *Neurol Sci.* 2010;291(1-2):121-3

- 271 [17] Valdmanis PN, Dupré N, Lachance M, Stochmanski SJ, Belzil VV, Dion PA et al. A  
272 mutation in the RNF170 gene causes autosomal dominant sensory ataxia. *Brain*. 2010;134(Pt  
273 2):602-7
- 274 [18] Rajadhyaksha AM, Elemento O, Puffenberger EG, Schierberl KC, Xiang JZ, Putorti ML  
275 et al. Mutations in FLVCR1 cause posterior column ataxia and retinitis pigmentosa. *Am J*  
276 *Hum Genet*. 2010;87(5):643-54
- 277
- 278



**Table 1:** Genetic and clinical characteristics of previously published recessive mutations in the *PIEZO2* Gene

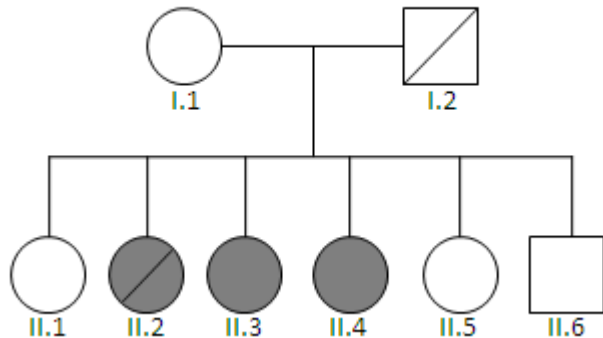
**Figure 1:** Family pedigree

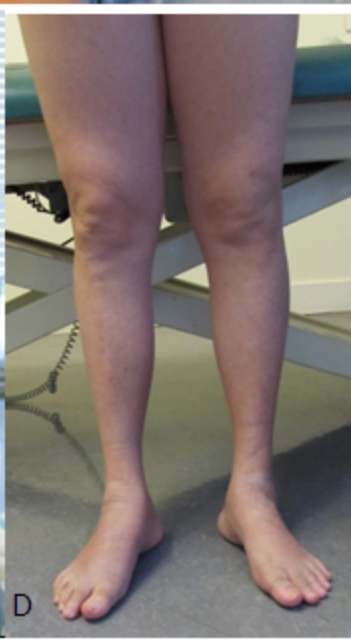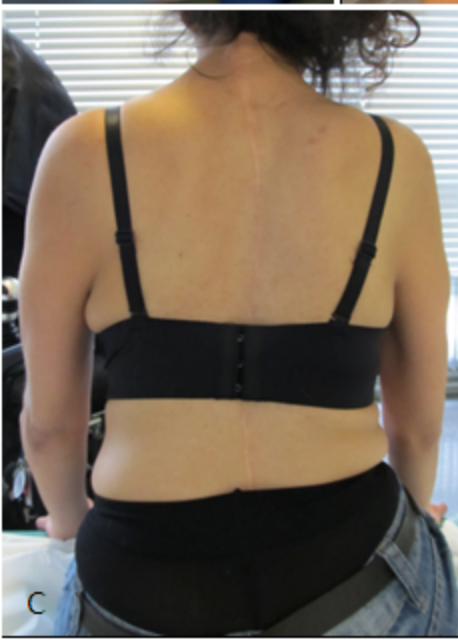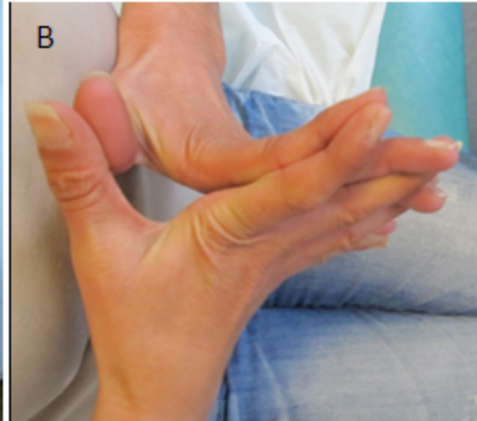
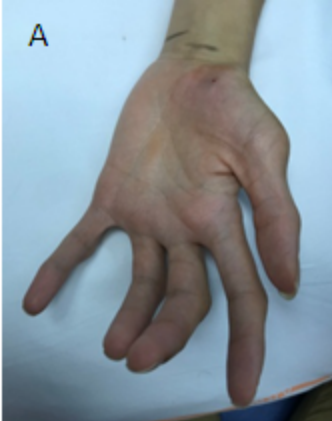**Figure 2:** Patients clinical features

Both patients displayed distal wasting and arthrogryposis (A and D), hyperlaxity (B) and severe scoliosis (C).

**Figure 3:** Sensory Evoked Potentials in the upper limbs of Patient 1

Peripheral conduction was normal (N5). N13 amplitude was reduced on the left upper limb (A, white circle) and absent on the right (B, white arrow). Bulbar components (N/P14 – black circle) were reduced and latency of cortical components (N9-N20) were extended, indicating bilateral impairment of the lemniscal pathways.





A

VCN  
10uV/D 5ms/D

Erb's-Fz  
5uV/D 5ms/D

C7-Cou  
5uV/D 5ms/D

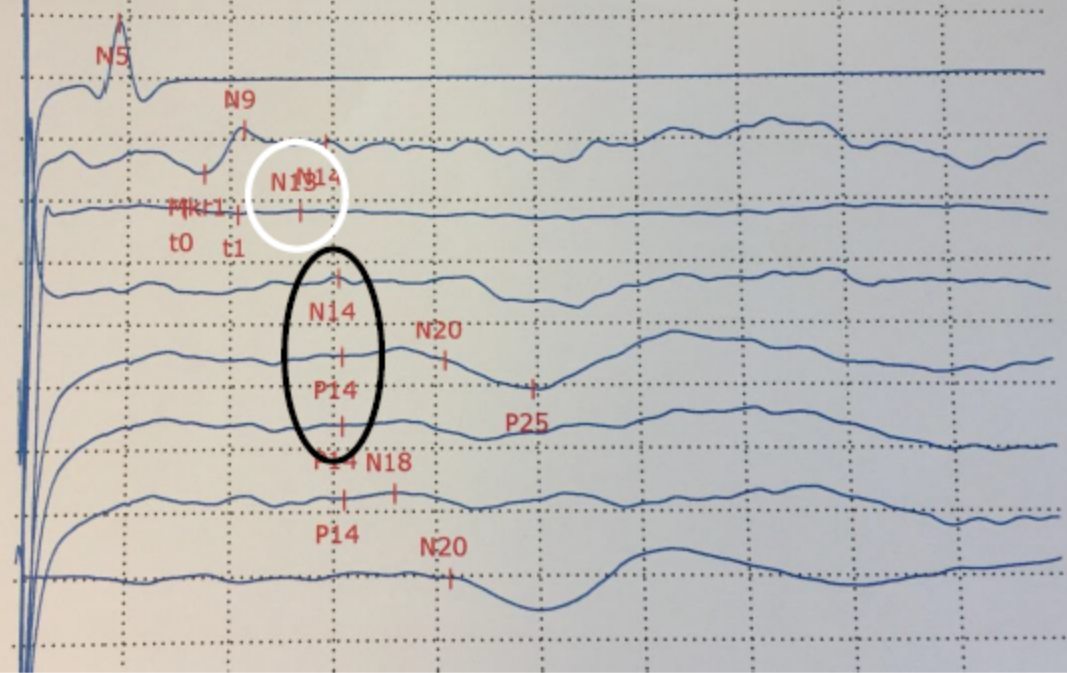
C7-Fz  
5uV/D 5ms/D

ParD-ErbD  
5uV/D 5ms/D

Cz-Erbcontra  
5uV/D 5ms/D

ParG-ErbD  
5uV/D 5ms/D

PaD-PaG  
5uV/D 5ms/D



B

VCN  
10uV/D 5ms/D

Erb's-Fz  
5uV/D 5ms/D

C7-Cou  
5uV/D 5ms/D

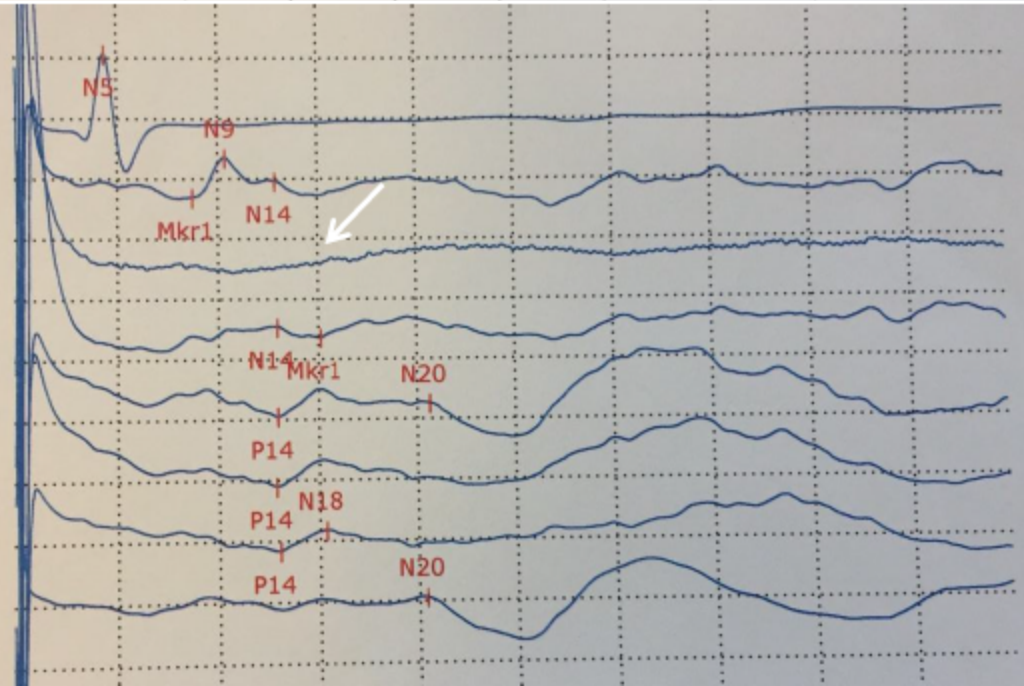
C7-Fz  
5uV/D 5ms/D

ParG-ErbG  
5uV/D 5ms/D

Cz-Erbcontra  
5uV/D 5ms/D

ParD-ErbG  
5uV/D 5ms/D

PaG-PaD  
5uV/D 5ms/D



	<b>Clinical Features</b>	<b>Mutation</b>
<b>Delle Vedove et al. 2016</b>	10 individuals, 4 families Arthrogryposis, spontaneously resolving respiratory insufficiency at birth, muscular atrophy > distal lower limbs, scoliosis, mild sensory involvement	- c.5621delT (p.Leu1874Argfs*5) homozygous - c.3019_3029del(p.Pro1007Leufs*3) homozygous - c.1550_1552delGCTinsCGAA (p.Ser517Thrfs*48) homozygous - c.493-?_917+?del (p0?) homozygous
<b>Chelser et al. 2016</b>	2 subjects, 2 families Scoliosis, hypotonia and shallow breathing during infancy, unsteady gait with proprioceptive defect	- c.4723>T (p.R1575*)/ c.5053C>T (p.R1685*) - c.5054G>C (p.R1685P)/ c.5053C>T (p.R1685*)
<b>Haligolu et al. 2017</b>	Hypotonia, distal laxity, contractures, muscle weakness, scoliosis, proprioceptive defect	c.1384C>T, (p.R462*) homozygous
<b>Mahmud et al. 2017</b>	Scoliosis, contractures involving distal joints, proprioception and touch sensation defects	c.2708C>G; p.S903* homozygous