



HAL
open science

A novel nonsense PIEZO2 mutation in a family with scoliosis and proprioceptive defect

Marion Masingue, Julien Fauré, Guilhem Solé, Tanya Stojkovic, Sarah Léonard-Louis

► **To cite this version:**

Marion Masingue, Julien Fauré, Guilhem Solé, Tanya Stojkovic, Sarah Léonard-Louis. A novel nonsense PIEZO2 mutation in a family with scoliosis and proprioceptive defect. *Neuromuscular Disorders*, 2019, 29, pp.75 - 79. <10.1016/j.nmd.2018.10.005>. <hal-03486192>

HAL Id: hal-03486192

<https://hal.science/hal-03486192v1>

Submitted on 20 Dec 2021

HAL is a multi-disciplinary open access archive for the deposit and dissemination of scientific research documents, whether they are published or not. The documents may come from teaching and research institutions in France or abroad, or from public or private research centers.

L'archive ouverte pluridisciplinaire **HAL**, est destinée au dépôt et à la diffusion de documents scientifiques de niveau recherche, publiés ou non, émanant des établissements d'enseignement et de recherche français ou étrangers, des laboratoires publics ou privés.



Distributed under a Creative Commons CC BY-NC 4.0 - Attribution - Non-commercial use - International License

1 **A novel nonsense *PIEZO2* mutation in a family with scoliosis and proprioceptive defect**

2 Marion Masingue¹

3 Julien Faure^{2,3}

4 Guilhem Solé⁴

5 Tanya Stojkovic¹

6 Sarah Léonard-Louis¹

7 ¹Centre de Référence de Pathologie Neuromusculaire Nord/Est/Ile de France, Institut de

8 Myologie, CHU La Pitié-Salpêtrière, APHP, Paris, France

9 ²University Grenoble Alpe F-38000 France

10 ³CHU Grenoble, Biochimie et Génétique Moléculaire, Grenoble, F-38000 France

11 ⁴Centre de référence des maladies neuromusculaires AOC, Hôpital Pellegrin, CHU de

12 Bordeaux, Bordeaux, France

13

14 **Corresponding author:** Marion Masingue marion.masingue@aphp.fr

15

16 ABSTRACT

17 *PIEZO2* mutations have been described in dominant arthrogyrosis, but homozygous
18 mutations of *PIEZO2* may also be responsible for more complex clinical patterns, associating
19 distal arthrogyrosis, neonatal respiratory insufficiency, scoliosis and proprioceptive
20 impairment. We report here two sisters presenting with these clinical and genetic features.
21 They had a similar phenotype, with severe hypotonia and respiratory distress at birth, delayed
22 acquisition of motor milestones and need of scoliosis surgery. Hypotonia and alteration of
23 proprioception were at the forefront of clinical examination for both, along with areflexia,
24 hyperlaxity, *cutis laxa*, and discrete facial dysmorphism. Electrophysiological studies, including
25 electroneuromyography and sensory evoked potentials, showed a mild sensory axonopathy
26 without any myopathic features, but revealed a peripheral proximal lemniscal defect. Creatine
27 kinase, muscular MRI and biopsy were normal, as well as cerebral MRI and neurometabolic
28 biological explorations. They had a moderate restrictive syndrome on respiratory function
29 tests and cardiac function was normal. Molecular studies performed on a panel of genes
30 involved in distal arthrogyrosis disclosed a nonsense homozygous c.3241C>T (p.Arg1051*)
31 mutation in the *PIEZO2* gene, which was also present at the heterozygous state in their
32 mother's DNA. This new *PIEZO2* mutation was in accordance with the phenotype combining
33 arthrogyrosis, scoliosis, hyperlaxity and proprioceptive impairment.

34

35 HIGHLIGHTS

36 Arthrogyrosis and proprioceptive defects suggests a recessive *PIEZO2* mutation

37 Patients with arthrogyrosis should be screened for *PIEZO2* mutations

38 Dominant PIEZO2 mutations are mostly missense whereas recessive cases are truncating

39 **KEYWORDS**

40 PIEZO2

41 Arthrogryposis

42 Proprioceptive impairment

43

44 **Abbreviations**

45 ENMG: Electroneuromyography; SEP: Sensory Evoked Potentials; DA: Distal

46 Arthrogryposis; MWS: Marden-Walker Syndrome;

47 **1. INTRODUCTION**

48 Arthrogryposis is defined by reduced mobility of multiple joints and highly heterogeneous,
49 with more than 400 genes described. Arthrogryposis can be of both dominant and recessive
50 inheritance, and associated with other clinical features, namely orthopedic malformations,
51 facial deformities, central nervous system (CNS) abnormalities, peripheral neuropathy or
52 myopathy. [1] Among these genes, heterozygous missense *PIEZO2* mutations have been
53 associated with either distal Gordon Syndrome (Distal arthrogryposis (DA) type 3 or DA type
54 5 or Marden-Walker Syndrome (MWS) [5]. Later on, homozygous nonsense mutations in the
55 *PIEZO2* gene have been held responsible for arthrogryposis, scoliosis and, strikingly,
56 proprioception defects [6], neonatal respiratory insufficiency [7, 8] and muscle weakness [9].

57 PIEZO polypeptides are mechanosensitive transmembrane cation channels [2,3]. They are
58 expressed in several mechanosensitive tissues, such as neurons of the dorsal root ganglia,
59 endothelium and visceral tissues, including lungs. Mouse models lacking *PIEZO2* in
60 mechanosensory neurons showed impaired limb coordination, and unstable gait [4].

61 We describe here the cases of two sisters prominently characterized by distal arthrogryposis
62 and proprioception loss; a clinical phenotype which led us to find a novel nonsense
63 homozygous mutation in the *PIEZO2* gene.

64

65 **2. MATERIALS AND METHODS**

66 2.1. Patients

67 We report the cases of two twin sisters of Tunisian origin, followed from age 20 to 24 years
68 (Patient II.3 and II.4), the first one (Patient II.3) at the Neuromuscular Reference Center of

69 Pitié Salpêtrière Hospital (Paris) and the other (Patient II.4) at the Neuromuscular Reference
70 Center in the University Hospital of Bordeaux.

71 2.2. Clinical, electrophysiological and muscle Magnetic Resonance Imaging features

72 Both sisters have undergone clinical examination, extended neurophysiological evaluations,
73 including electroneuromyography (ENMG) and sensory evoked potentials (SEP). Routine
74 biological analyses, including lysosomal enzymes and vitamin dosages, have been performed,
75 as well as respiratory function tests, cardiac explorations (Patient II.3 and II.4), muscle
76 Magnetic Resonance Imaging (MRI) (Patient II.3). and biopsy (Patient II.3 and II.4).

77 2.3. Genetic studies

78 All samples were processed after informed consents for molecular diagnosis had been
79 obtained from the patients. Mutations in the probands' DNA have been screened on a panel of
80 eleven genes involved in distal arthrogyrosis. The design of the gene panel was realized with
81 the AmpliSeq Designer tool (Thermo Fischer Scientific) and libraries for Next Generation
82 Sequencing (NGS) were prepared according to manufacturer recommendations and analyzed
83 on IonTorrent PGM instrument (Thermo Fischer Scientific). The coverage for the *PIEZO2*
84 gene (NM_022068) was 99.3 % with a mean depth of 390X (ranging from 34 to 1486).
85 Results of the sequencing were processed with the Torrent Suite 5.0 (Thermo Fischer
86 Scientific) and annotation of the variants performed with a homemade script based on the
87 Variant Effect Predictor tool [10]. The presence of the mutation was controlled by Sanger
88 sequencing using specific primer designed to amplify exon 22 of the *PIEZO2* gene and an
89 ABI PRISM Big Dye Terminator Cycle Sequencing (V3.0) reaction kit with an analysis on an
90 ABI 3130 DNA Analyzer (Thermo Fischer Scientific).

91 3. RESULTS

92 3.1. Clinical, electrophysiological and muscle MRI features

93 Our 2 patients were born from healthy parents, who were not known to be consanguineous.
94 They had 5 siblings, including one sister (II.2) who died at six years of age, with similar
95 symptoms. Their father died in a car accident at age 32 (Figure 1)

96 Pregnancy was uneventful, but the 2 sisters were severely hypotonic at birth and experienced
97 transient neonatal respiratory failure. Later on, they displayed delayed acquisitions of motor
98 skills and started walking independently at 5 (Patient II.4) and 7 (Patient II.3) years only.
99 From the onset of the disease, gait was very unstable, and a wheelchair was needed early on
100 during childhood. They also had severe scoliosis, requiring arthrodesis in both cases.

101 There was no cognitive impairment, and both sisters were able to pursue higher studies.

102 On examination, at age 20, hypotonia was still at the fore. Both patients displayed diffuse
103 distal wasting along with muscular deficit and discrete fingers and wrist retractions,
104 compatible with arthrogryposis. Hyperlaxity was noticed in multiple joints. Proprioceptive
105 abnormalities were major, with diffuse apallesthesia, positive Romberg sign, and unsteady
106 wide-based gait, as well as dysmetria appearing with eyes closed. Tendon reflexes were
107 abolished in the four limbs. There was no facial involvement, no cerebellar ataxia, no
108 pyramidal or bulbar syndrome, and no ocular motor impairment. Patient II.3 also displayed
109 *cutis laxa* (Figure 2)

110 ENMG showed a mild sensory axonal neuropathy in patient II.3 and was normal in patient
111 II.4. There was no myopathic feature in both sisters. SEP revealed bilateral impairment of
112 lemniscal sensory pathways for both (Figure 3). Cerebral and medullar MRI were normal,
113 apart from the scoliosis. Muscular MRI showed no abnormality in patient II.3. Muscular
114 biopsy was normal for patient II.3 and showed mild muscular abnormalities for patient II.4:
115 type 2 fiber predominance and rare isolated concentric lamellar bodies.

116 Respiratory function tests revealed a mild restrictive syndrome. The forced vital capacity was
117 46% (Patient II.3) and 69% (Patient II.4) of predicted value. No other functional studies were
118 realized to assess diaphragmatic function.

119 Echocardiography and electrocardiogram were normal.

120 3.2.Molecular findings

121 Patient 1 was first screened for the *FKBP14* gene, known to be responsible for Ehlers-Danlos
122 Syndrome with progressive kyphoscoliosis and myopathy [11]. No mutation was found, and
123 DNA of the patient was then screened for genes involved in distal arthrogyriposis on a gene
124 panel with an IonTorrent PGM instrument. The mean coverage for a minimal depth of 30X
125 for the 11 genes explored was 92.45 %. The analysis of SNP with an allelic frequency under a
126 threshold of 0.5% in the EXAC database identified only the c.3241C>T;p.Arg1051* variation
127 in the exon 22 of the *PIEZO2* gene at the homozygous state. This variation resulted in a
128 premature STOP codon in exon 22 and in a biallelic loss-of-function of the *PIEZO2* gene. The
129 segregation of the variation performed on the DNA of the probands' mother and sister showed
130 compatibility with a recessive mode on inheritance. The father's DNA was not available.

131

132 4. DISCUSSION

133 A recessive condition associating arthrogyriposis and a proprioception defect with transient
134 respiratory failure, scoliosis, hypotonia, hyperlaxity is highly evocative of *PIEZO2* biallelic
135 loss-of-function mutation, as established by previously published works [6-9] (Table 1). The
136 clinical phenotype of our two patients, encompassing these features, led us to a specific DNA
137 sequencing targeting the *PIEZO2* gene, and allowed us to identify a novel homozygous
138 mutation, without using whole exome or mendeliome sequencing as previously described [6-

139 9]. It is worth noticing that our two patients, although most of our symptoms were similar,
140 displayed some phenotypical differences: age of motor skills achievement, ENMG and biopsy
141 findings. The fact that they were followed in two different centers could account for those
142 findings, this might suggest that there is some variability in the clinical expression of the
143 disease.

144 4.1. Two types of *PIEZO2* mutations inducing two different phenotypes

145 *PIEZO2* gene mutations are particularly interesting and may cause two very distinguishable
146 phenotypes according to the type of mutation and their mode of inheritance. Homozygous
147 recessive mutations lead to a loss of function of the gene, whereas heterozygous dominant
148 mutations cause a gain of function. Consequently, those two mechanisms induce very
149 different conditions: although they share some clinical characteristics, namely arthrogryposis
150 and scoliosis, there are distinguished by the presence of severe alterations of proprioception in
151 the **biallelic** *PIEZO2* whereas the heterozygous mutations correspond to a purer form of distal
152 arthrogryposis, such as Gordon Syndrome, Marden-Walker Syndrome, or Distal
153 Arthrogryposis Type 5 [2,5].

154 4.2. *PIEZO2* and proprioception

155 So far, mutations of *PIEZO2* seem to be the only possible genetic cause of proprioception
156 impairment with arthrogryposis. In humans, specialized mechanosensory neurons called
157 proprioceptors convey information about the stretch and tension experienced by muscles,
158 tendons, skin, and joints. *PIEZO* polypeptides are mechanosensitive cation channels and are
159 activated in response to mechanical displacement of the cell surface membrane. [3]

160 *PIEZO2* is expressed, in particular, at the endings of somatosensory neurons, which convey
161 information about tension and stretch experienced by joints, skin, muscles and tendons [4, 8].
162 Mice models have evidenced that *PIEZO2* is responsible for the transduction of rapidly-

163 adapting mechanically-activated currents in the neurons of the dorsal root ganglia [2]. These
164 findings explain why *PIEZO2* loss-of-function mutations cause a very specific phenotype
165 with a characteristic proprioceptive defect

166 The mild axonal neuropathy observed in Patient II.3 seems to be a frequent characteristic of
167 patients with biallelic *PIEZO2* mutations [7-9], although not explaining the proprioceptive
168 defect in itself.

169 4.3. Possible mechanisms for other clinical features encountered in *PIEZO2* mutations

170 It has been suggested that *PIEZO2* mutations may cause dysregulation of
171 mechanotransduction affecting both cartilage constitution [12] and development of skeletal
172 muscles [5] possibly leading to arthrogryposis and orthopedic abnormalities.

173 As a matter of fact, in patient 2, muscle biopsy revealed non-specific mild myopathic features,
174 findings that have been described previously in recessive *PIEZO2* mutations [9].

175 Respiratory impairment has also been described and is at least partially explained in
176 adulthood by severe scoliosis and diaphragmatic weakness, whereas in cases of neonatal
177 respiratory failure, it is more likely the consequence of diaphragmatic weakness only.

178 Alternatively, a role for *PIEZO2* was suggested as a mechanosensor required for correct lung
179 development [13].

180 4.4.A unique cause for proprioceptive defects and arthrogryposis

181 Hereditary proprioceptive defect is caused by numerous hereditary sensory neuropathies but
182 usually with severe axonal neuropathy. It has much more rarely been described when caused
183 by proximal lemniscal pathways impairment. Neurometabolic diseases such as Friedreich
184 ataxia, Vitamin E deficiency or hypobetalipoproteinemia may show posterior cord
185 involvement on SEPs, but patients also display central nervous system symptoms [14,15]. A

186 case of hereditary sensory ataxic neuropathy has been reported in a Japanese family with a
187 mild sensory axonal neuropathy but significantly prolonged central conduction time on SEPs.
188 Patients were not screened for *PIEZO2* mutations, but, unlike ours, their sensory complaints
189 went beyond sole ataxia, proximal muscle weakness was systematic, age at onset was much
190 older (after 40 years), and there was neither scoliosis nor respiratory failure. [16].

191 More recently, mutations in *RFN170* coding for the Ring Finger Protein 170 have been
192 described, responsible for progressive sensory ataxia linked to degeneration of the posterior
193 columns of the spinal cord. Patients with *RFN170* mutations had, however, a progressive,
194 isolated, form of ataxia predominating in the legs; they were older, and inheritance was
195 dominant. [17]. Mutations in the *FLVCR1* gene also cause posterior column ataxia, sometimes
196 associated with scoliosis and *retinis pigmentosa*., but ENMG reveals a ganglionopathy [18].

197 Finally, secondary arthrogyrosis may occur in several neuromuscular disorders, and thus
198 could be associated with conditions causing proprioceptive defects and neuropathy. However,
199 in those cases, it tends to appear later on in the course of the disease than in our patients.

200

201 *PIEZO2* is a unique gene with two very distinct phenotypes corresponding to the inheritance
202 mode. As heterozygous dominant mutations are responsible for arthrogyrosis multiplex
203 congenita, *PIEZO2* biallelic mutations have a typical clinical presentation, with scoliosis and
204 proprioceptive deficit as main symptoms, together with arthrogyrosis, hypotonia and
205 transient neonatal respiratory failure. The role of *PIEZO2* as a mechanosensitive receptor in
206 somatosensory neurons and its implication in bones and joint development as well as lung
207 development probably intervene in the occurrence of those symptoms. The association of
208 these clinical features is highly evocative and should prompt practitioners to screen *PIEZO2*

209 gene, as few other disorders display the same characteristics.

210

211

212 **DECLARATIONS**

213 **Ethics approval and consent to participate:** Authors declare that this work received all
214 necessary ethical approvals and that all the patients involved consented to participate.

215 **Consent for publication:** Yes.

216 **Availability of data and material:** Please contact author for data requests.

217 **Competing interests:** Authors declare no financial or non-financial competing interests in
218 relation to this manuscript.

219 **Funding:** No funding was necessary

220 **Author contributions:** MM, JF, GS, TS, SLL were involved in conception and design of the
221 research project, in analysis and interpretation of the data. MM, TS and SLL were involved
222 and writing of the first draft of the manuscript. SLL and GS were involved in the acquisition
223 of clinical data and JF was involved in the acquisition of molecular data. All authors read and
224 approved the final manuscript.

225

226

227 **REFERENCES**

228 [1] Hall, JG. Arthrogyrosis (multiple congenital contractures): diagnostic approach to
229 etiology, classification, genetics, and general principles. *Eur J Med Genet.* 2014;57(8):464-72

230 [2] Coste B, Mathur J, Schmidt M, Earley TJ, Ranade S, Petrus Mj, et al. Piezo1 and Piezo2
231 are essential components of distinct mechanically-activated cation channels. *Science.* 2010
232 October 1; 330(6000): 55–60.

233 [3] Alper SL. Genetic Diseases of PIEZO1 and PIEZO2 dysfunction. *Curr Top Membr.*
234 2017;79:97-134

235 [4] Woo SH, Lukacs V, De Nooij JC, Zaytseva D, Criddle CR, Francisco A, et al. Piezo2 is
236 the principal mechanotransduction channel for proprioception. *Nat Neurosci.*
237 2015;18(12):1756-62

238 [5] McMillin, M. J., Beck, A. E., Chong, J. X., Shively, K. M., Buckingham, K. J.,
239 Gildersleeve, H. I et al. Mutations in PIEZO2 cause Gordon syndrome, Marden-Walker
240 syndrome, and distal arthrogyrosis type 5. *Am J of Hum Gen.* 2014;94(5):734-44.

241 [6] Mahmud AA, Nahid NA, Nassif C, Sayeed MSB, Ahmed MU, Parvee M, et al. Loss of
242 the proprioception and touch sensation channel PIEZO2 in siblings with a progressive form of
243 contractures. *Clin Genet.* 2017;91(3):470-75

244 [7] Delle Vedove A, Storberck M, Heller R, Hölker I, Hebbar M, Shukla A, et al. Biallelic
245 loss of proprioception-related PIEZO2 causes muscular atrophy with perinatal respiratory
246 distress, arthrogyrosis and scoliosis. *Am J of Hum Gen.* 2016;99(5):1206-16

247 [8] Chelser AT, Szczot M, Bharucha-Goebel D, Ceko M, Donkervoort S, Laubacher C et al.
248 The role of PIEZO2 in Human Mechanosensation. *N Engl J Med.* 2016;375(14):1355-64

- 249 [9] Haligolu G, Becker K, Temucin C, Talim B, Kuçukçahin N, Pergande M, et al. Recessive
250 PIEZO2 stop mutation causes distal arthrogryposis with distal muscle weakness, scoliosis and
251 proprioception defects. *J Hum Genet.* 2017;62(4):497-501
- 252 [10] McLaren W, Gil L, Hunt SE, Riat HS, Ritchie GR, Thormann A, et al. The Ensembl
253 Variant Effect Predictor. *Genome Biol.* 2016;17:122
- 254 [11] Baumann M, Giunta C, Krabichler B, Rüschemdorf F, Zoppi N, Colombi M et al.
255 Mutations in FKBP14 cause a variant of Ehlers-Danlos syndrome with progressive
256 kyphoscoliosis, myopathy, and hearing loss. *Am J Hum Genet.* 2012;10;90(2):201-16.
- 257 [12] Lee W, Leddy HA, Chen Y, Hee Lee S, Zelenski A, McNulty AI et al. Synergy between
258 Piezo1 and Piezo2 channels confers high-strain mechanosensitivity to articular cartilage. *Proc*
259 *Natl Acad Sci U S A.* 2014;111(47):E5114-22
- 260 [13] Nonomura K, Woo SH, Chang RB, Gillich A, Qiu Z, Francisco AG. Piezo2 senses
261 airway stretch and mediates lung inflation-induced apnoea. *Nature.* 2017;541(7636):176-81.
- 262 [14] Tsuji S, Uozumi T, Ito Y, Ohnishi A, Murai Y. Serial somatosensory evoked potentials
263 in a patient with familial hypobetalipoproteinemia and vitamin E deficiency. *Jpn J Med*
264 *1990;29(6)628-32*
- 265 [15] Zouari M, Feki M, Ben Hamida C, Larmaout A, Turki I, Belal S et al. Electrophysiology
266 and nerve biopsy: comparative study in Friedreich's ataxia and Friedreich's ataxia phenotype
267 with vitamin E deficiency. *Neuromuscul Disord.* 1998;8(6):416-25
- 268 [16] Murakami T, Fukai Y, Rikimaru M, Henmi S, Ohsawa Y, Sunada Y. Hereditary sensory
269 ataxic neuropathy associated with proximal muscle weakness in the lower extremities. *J*
270 *Neurol Sci.* 2010;291(1-2)121-3

- 271 [17] Valdmanis PN, Dupré N, Lachance M, Stochmanski SJ, Belzil VV, Dion PA et al. A
272 mutation in the RNF170 gene causes autosomal dominant sensory ataxia. *Brain*. 2010;134(Pt
273 2):602-7
- 274 [18] Rajadhyaksha AM, Elemento O, Puffenberger EG, Schierberl KC, Xiang JZ, Putorti ML
275 et al. Mutations in FLVCR1 cause posterior column ataxia and retinitis pigmentosa. *Am J*
276 *Hum Genet*. 2010;87(5):643-54
- 277
- 278

279 **Table 1:** Genetic and clinical characteristics of previously published recessive mutations in
280 the *PIEZO2* Gene

281

282 **Figure 1:** Family pedigree

283

284

285

286 **Figure 2:** Patients clinical features

287 Both patients displayed distal wasting and arthrogryposis (A and D), hyperlaxity (B) and
288 severe scoliosis (C).

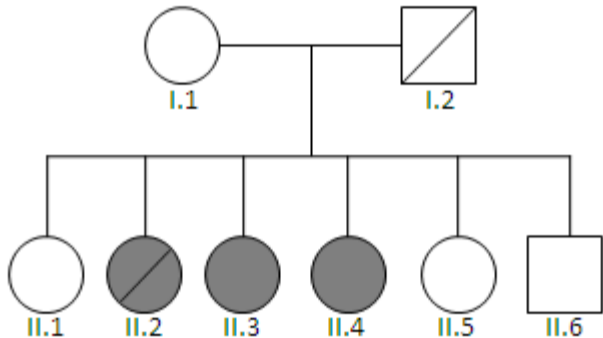
289

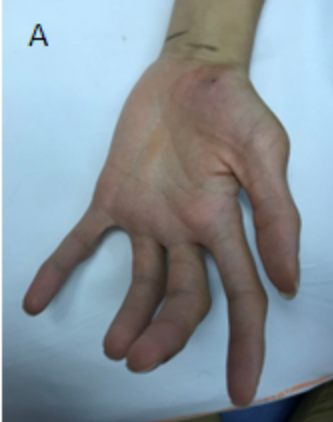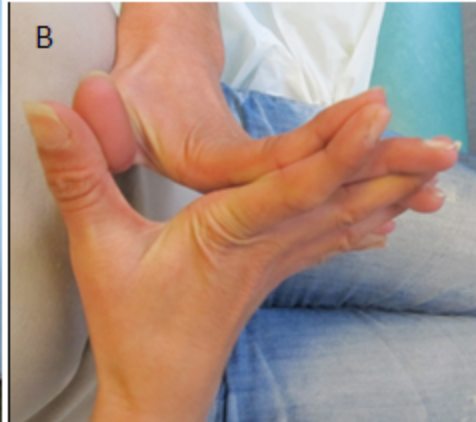
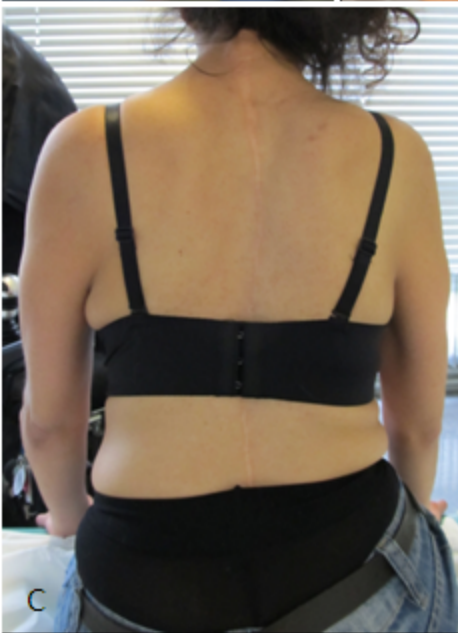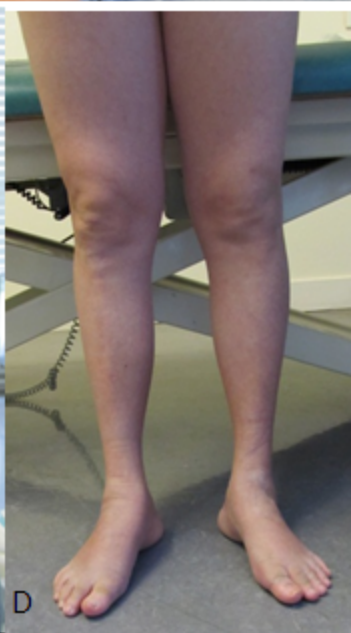290

291 **Figure 3:** Sensory Evoked Potentials in the upper limbs of Patient 1

292 Peripheric conduction was normal (N5). N13 amplitude was reduced on the left upper limb
293 (A, white circle) and absent on the right (B, white arrow). Bulbar components (N/P14 – black
294 circle) were reduced and latency of cortical components (N9-N20) were extended, indicating
295 bilateral impairment of the lemniscal pathways.

296



A**B****C****D**

A

VCN
10 μ V/D 5ms/D

Erb's-Fz
5 μ V/D 5ms/D

C7-Cou
5 μ V/D 5ms/D

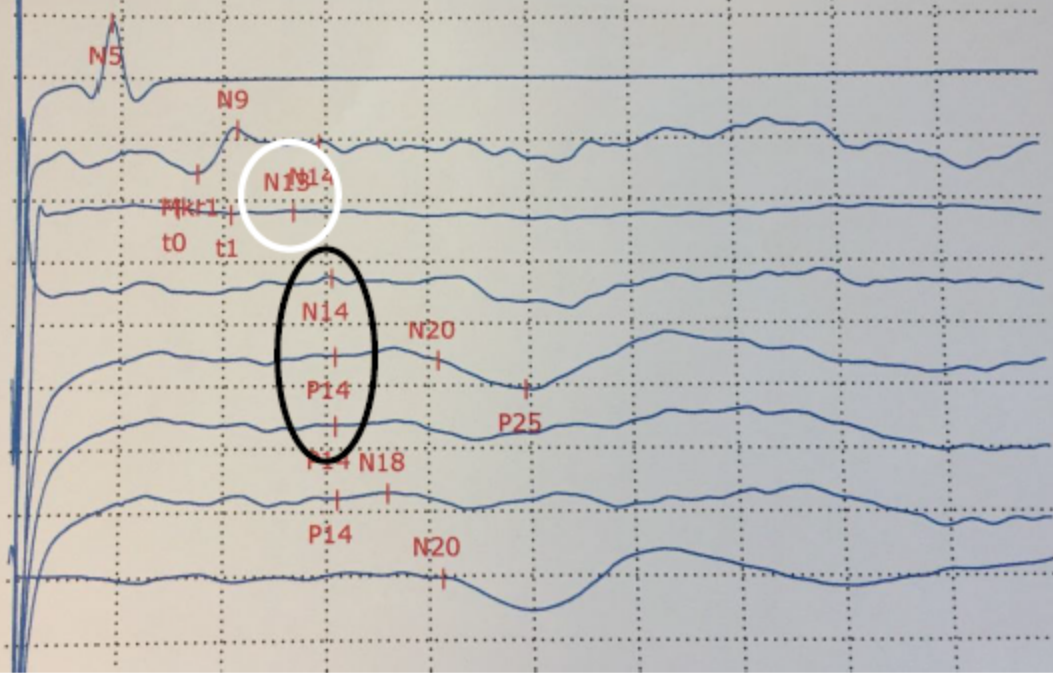
C7-Fz
5 μ V/D 5ms/D

ParD-ErbD
5 μ V/D 5ms/D

Cz-Erbcontra
5 μ V/D 5ms/D

ParG-ErbD
5 μ V/D 5ms/D

PaD-PaG
5 μ V/D 5ms/D

**B**

VCN
10 μ V/D 5ms/D

Erb's-Fz
5 μ V/D 5ms/D

C7-Cou
5 μ V/D 5ms/D

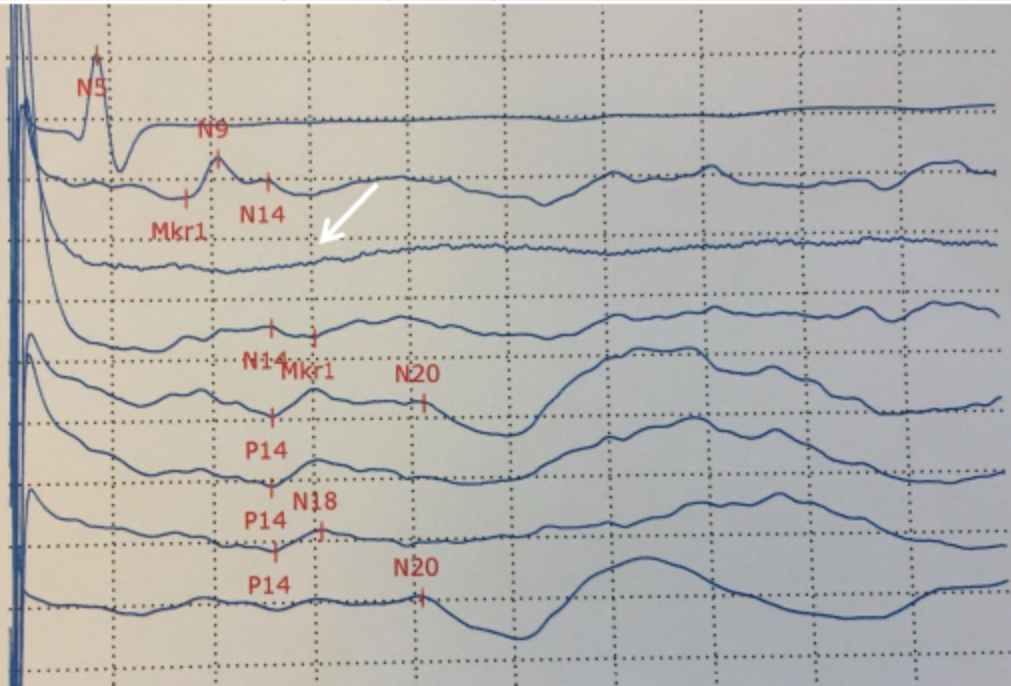
C7-Fz
5 μ V/D 5ms/D

ParG-ErbG
5 μ V/D 5ms/D

Cz-Erbcontra
5 μ V/D 5ms/D

ParD-ErbG
5 μ V/D 5ms/D

PaG-PaD
5 μ V/D 5ms/D



	Clinical Features	Mutation
Delle Vedove et al. 2016	10 individuals, 4 families Arthrogryposis, spontaneously resolving respiratory insufficiency at birth, muscular atrophy > distal lower limbs, scoliosis, mild sensory involvement	- c.5621delT (p.Leu1874Argfs*5) homozygous - c.3019_3029del(p.Pro1007Leufs*3) homozygous - c.1550_1552delGCTinsCGAA (p.Ser517Thrfs*48) homozygous - c.493-?_917+?del (p0?) homozygous
Chelser et al. 2016	2 subjects, 2 families Scoliosis, hypotonia and shallow breathing during infancy, unsteady gait with proprioceptive defect	- c.4723>T (p.R1575*)/ c.5053C>T (p.R1685*) - c.5054G>C (p.R1685P)/ c.5053C>T (p.R1685*)
Haligolu et al. 2017	Hypotonia, distal laxity, contractures, muscle weakness, scoliosis, proprioceptive defect	c.1384C>T, (p.R462*) homozygous
Mahmud et al. 2017	Scoliosis, contractures involving distal joints, proprioception and touch sensation defects	c.2708C>G; p.S903* homozygous