



**HAL**  
open science

## Protocol Adaptation of Optical Coherence Tomography in Lower Limb Arteries Revascularization

Maxime Dubosq, Benjamin O. Patterson, Richard Azzaoui, Thomas Mesnard,  
Agathe de Préville, Jonathan Sobocinski

► **To cite this version:**

Maxime Dubosq, Benjamin O. Patterson, Richard Azzaoui, Thomas Mesnard, Agathe de Préville, et al.. Protocol Adaptation of Optical Coherence Tomography in Lower Limb Arteries Revascularization. *Annals of Vascular Surgery*, 2019, 57, pp.257 - 260. 10.1016/j.avsg.2018.09.031 . hal-03486076

**HAL Id: hal-03486076**

**<https://hal.science/hal-03486076v1>**

Submitted on 20 Dec 2021

**HAL** is a multi-disciplinary open access archive for the deposit and dissemination of scientific research documents, whether they are published or not. The documents may come from teaching and research institutions in France or abroad, or from public or private research centers.

L'archive ouverte pluridisciplinaire **HAL**, est destinée au dépôt et à la diffusion de documents scientifiques de niveau recherche, publiés ou non, émanant des établissements d'enseignement et de recherche français ou étrangers, des laboratoires publics ou privés.



Distributed under a Creative Commons Attribution - NonCommercial 4.0 International License

1 **Protocol adaptation of OCT in lower limb arteries revascularisation**

2 M Dubosq<sup>1</sup>, BO Patterson<sup>2</sup>, R Azzaoui<sup>1</sup>, T Mesnard<sup>1,3</sup>, A De Préville<sup>1</sup>, J Sobocinski<sup>1,3</sup>

3

4 <sup>1</sup>Vascular surgery, Aortic centre, CHU Lille, France

5 <sup>2</sup>St George's Vascular Institute, NHS Trust, London

6 <sup>3</sup>Inserm U1008, University of Lille, France

7

8 Conflicts of interest:

9 J Sobocinski received speaker fees from AbbottVascular

10

11 **Abstract**

12 In lower limb arteries, assessment of stent apposition and/or the single opening of the  
13 diseased artery remains poor since this relies on 2D angiogram. Extrapolating experience  
14 gained with coronary arteries, optical coherence tomography (OCT) could provide 3D  
15 reconstructions of the arterial wall and the stent implanted. A modified protocol of OCT  
16 acquisition, which usually includes large amount of iodine contrast flush, is presented here in  
17 3 patients with long and complex occlusion of the superficial femoral artery (SFA). Its  
18 potential benefits and wider application to improve patient outcomes are discussed.

19

20

21 **Introduction:**

22 2D angiogram is used to assess intraoperative results of balloon angioplasty and/or stenting.  
23 It is probably an acceptable modality in short lesions but is not able to provide 3D  
24 appreciation of long complex arterial lesions. This could contribute toward some early &

25 mid-term procedural failures<sup>1</sup>. IVUS provides accurate intravascular evaluation of  
26 inadequate stent positioning or significant recoil missed with 2D angiogram<sup>2,3,4</sup>. Its use has  
27 not been widespread so far mainly due to its unproven cost-effectiveness<sup>4</sup>.

28 Optical Coherence Tomography is another endovascular imaging technique initially used in  
29 coronary arteries<sup>5</sup>. OCT is a recent technology for cross-sectional and 3D-imaging in  
30 biological systems with ultra-high resolution approaching that of histology. It provides  
31 endoluminal images and controls spatial opening of the stenotic/occluded artery after  
32 treatment. This lightening technology is based on echo lead-time measure and the intensity  
33 of a coherent light source in the near-infrared region instead of acoustic waves in IVUS<sup>4,6</sup>.  
34 Study comparison (to IVUS) in popliteal and infrapopliteal vessels showed OCT provided an  
35 excellent image quality and better visualisation of arterial wall layers of the different plaque  
36 components<sup>3</sup>. In coronary arteries, OCT seems even better in detecting stent malapposition  
37 and edge dissections, but similar to IVUS in the assessment of lumen and stent dimensions<sup>5</sup>.  
38 Two major limitations are usually described for arterial OCT in other situations: vessel  
39 diameter >5mm<sup>4</sup> & the need for iodine contrast injection to flush the artery for each OCT  
40 acquisition<sup>4,7</sup>.

41 Arterial lesions in lower limb may be up to 50cm long and maximum current length of OCT  
42 probes available in one imaging run is 7.5cm, meaning the single final control would require  
43 an unacceptable amount of iodine contrast.

44 We proposed and validated an adaptation of the OCT protocol based on isotonic saline in 3  
45 patients treated for critical limb ischemia with complex superficial femoral artery (SFA)  
46 lesions.

47

48 Case :

49 Three patients presented with TASC C (n=1) and D (n=2) lesions of the SFA were treated at  
50 Lille University Hospital on March 2018. Procedures were performed with flat-panel mobile  
51 detector (Elite, GE Healthcare). Parameters of the imaging system were configured to  
52 achieve a compromise between imaging quality and low radiation exposure. All procedures  
53 were performed under local anaesthesia with sedation. Controlateral puncture of the  
54 common femoral artery is our preferred option for SFA lesions. After placement of a 6Fr by  
55 55mm sheath (Flexor Ansel-1, CookMedical) with US guidance, patients received 50UI/kg of  
56 heparin. Initial 2D cine fluroscopic run confirmed the lesions depicted with preoperative US  
57 and/or CTA. All lesions were successfully crossed using either .018" CTO wire in 2 or using a  
58 subintimal approach with .035" stiff hydrophilic guidewire in 1. Prolonged (>3minutes) and  
59 progressive balloon angioplasties (diameter 5mm) at 8atm were performed in all 3 patients.  
60 2D-cine fluoroscopy and OCT acquisitions were then executed to evaluate the need of re-  
61 ballooning or stent implantation.

62 OCT acquisitions require the use of OCT catheter (DragonFly Optis, AbbottVascular) and  
63 dedicated generator (Illumien, AbbottVascular).

64 The protocol of OCT acquisitions comprised a first step where the shaft of the catheter was  
65 flushed with 2cc of iodine contrast and then a second step where the treated segment of  
66 artery was flushed via an automatic power injection of 80cc of isotonic saline at 10cc/sec  
67 through the long sheath positioned just above the lesion to be evaluated. The OCT catheter  
68 was previously positioned at the level of the arterial segment being evaluated; it  
69 automatically detected the saline bolus arrival and launch the acquisition over a maximum  
70 length of 7.5cm segment. In both control imaging modalities further stenting was required in  
71 all patients due to significant recoil and focal occlusive dissection.

72 A 6mm by 100mm ABSOLUTE stent (AbbottVascular) was implanted in patient with TASC C  
73 lesion; 1 patient with TASC D lesions received a 5mm by 200mm SUPERA stents  
74 (AbbottVascular) + 2 ABSOLUTE stents 6mm by 150mm proximally while the last patient  
75 received 2 ABSOLUTE stents: 5mm-150mm and 6mm-100mm for long F1-F2 lesion. Post-  
76 implantation balloon inflation of the ABSOLUTE stent (AbbottVascular) was systematically  
77 performed but not for the SUPERA stent.

78 Final 2D cine fluoroscopy showed a good result with appropriate stent expansions (images)  
79 in all cases.

80 New OCT acquisitions showed discrepancies in stenting results in 2 patients:

81 In the TASC C patient, appearance of stent malapposition of the ABSOLUTE stent at some  
82 points and significant stenosis of the native proximal SFA that was thought to be free of  
83 lesions were depicted. Additional stent implantation after balloon angioplasty of the native  
84 proximal SFA and re-ballooning of the ABSOLUTE stent with a 6mm balloon were performed  
85 [Figure 1].

86 The one TASC D patient required re-ballooning of the ABSOLUTE stents [Figure 2].

87

88 Median amount of isotonic saline volume injected per patient for OCT acquisitions was  
89 400cc [400 to 480cc]. Median Iodine contrast (Xenetix 300mg/mL, Guerbet, France) volume  
90 injected was 27cc [20cc to 40cc]; median Dose Area Product was 14mGycm<sup>2</sup> [8-21].

91 Procedural time was 115min [85 to 140min].

92

93 The postoperative course was uneventful for all patients. Postoperative US duplex showed  
94 excellent flow restoration within the femoro-popliteal artery in all 3 patients. Patients were  
95 discharged under dual antiplatelet therapy for at least 2 months.

96 The 3-month follow-up visit exhibited good patency of the revascularised femoropopliteal  
97 segment.

98

99 Discussion:

100

101 The “gold standard” imaging control modality after endovascular revascularisation is 2D-  
102 angiography. Despite poor image resolution, 2D-angiography remains easy to use at low  
103 cost. The benefit of OCT technique in this setting would be to improve the accuracy and the  
104 quality of the initial revascularisation, since it visualises and characterizes the wall of the  
105 artery, visualising not only atherosclerotic plaque characteristics after stent implantation but  
106 also late restenosis phenomena<sup>6</sup>. Applications in the coronary arteries are well established  
107 but few authors reported its use in the lower limb<sup>5,8</sup>.

108 (Frequency-Domain)-OCT, used in the 3 patients described, is able to detect intimal tears  
109 and dissections after infra-inguinal angioplasty, which appears crucial for high-quality  
110 imaging in long segments of larger arteries, such as femoral arteries. Moreover, super-fast  
111 image acquisition helps to reduce the lead-time and flushing bolus required for blood  
112 replacement. Most of OCT acquisitions in the artery are frequency-domain based; reducing  
113 the noise and thus the definition of images provided.

114 OCT requires intra-arterial injection of contrast agent to flush and clean the arterial lumen  
115 during data acquisition. This represents a huge limitation when the arterial segment treated  
116 is long. The use of Dextran and isotonic saline has already been proposed as an alternative to  
117 contrast agent to reduce nephrotoxicity<sup>8</sup>, but no practical details or results on their  
118 applicability and feasibility in clinical practice have been published so far.

119 Two main elements in the method here presented enable it to be achieved:

120 First, the use of automatic power injection able to standardise the rate and volume injected,  
121 then the placement of the long sheath close to the lesion and OCT probe avoiding flow  
122 dilution and reducing the remaining blood streaks.

123 From our experience, the OCT acquisitions with hand-injected saline are not workable – the  
124 flow-rate and volume injected are too low and not good enough to clean the arterial lumen  
125 compatible with good OCT images quality.

126 By extension, the amount of saline volume injected for the whole procedure due to OCT  
127 acquisitions could reach up to 1.5L for long SFA lesions and should be taken into account in  
128 patients with cardiac insufficiency – after discussion with the anaesthesiologist’s team.

129 Moreover, in our practice, we only flush catheters and sheaths with isotonic heparinised  
130 saline during procedure. In this specific setting, unprepared isotonic saline without  
131 additional heparin was used for OCT acquisitions to avoid massive anticoagulation of the  
132 patient that would expose them to an excessive bleeding risk.

133

134 In these first 3 patients, OCT depicted defects in stent expansion and *de novo* lesions not  
135 seen with the initial 2D angiogram or the preoperative duplex scan. This tool potentially  
136 helped to improve the outcomes of these patients by reducing the risk of postoperative  
137 early thrombosis; this also represent a valuable tool in determining the need for additional  
138 stenting and/or balloon angioplasty.

139 Although OCT is an expensive technique there is potential for preventing early postoperative  
140 failure and subsequent re-intervention. The protocol proposed in this work based on the  
141 injection of isotonic saline would extend its applicability to lower limb revascularisation. This  
142 could be worthwhile assessing as part of a prospective randomized study on clinical  
143 perspectives but also health economical aspects.





145 References:

146

147 1. Paraskevopoulos I, Spiliopoulos S, Davlouros P, Karnabatidis D, Katsanos K,  
148 Alexopoulos D, et al. Evaluation of Below-the-Knee Drug-Eluting Stents With Frequency-  
149 Domain Optical Coherence Tomography: Neointimal Hyperplasia and Neointimal Hyperplasia and Neoatherosclerosis.  
150 J Endovasc Ther 2013;20:80–93

151 2. Karnabatidis D, Katsanos K, Paraskevopoulos I, Diamantopoulos A, Spiliopoulos S,  
152 Siablis D. et al Frequency-Domain Intravascular Optical Coherence Tomography of the  
153 Femoropopliteal Artery. Cardiovasc Intervent Radiol. 2011;34:1172–1181

154 3. Eberhardt KM, Treitl M, Boesenecker K, Maxien D, Reiser M, Rieger J. Prospective  
155 Evaluation of Optical Coherence Tomography in Lower Limb Arteries Compared with  
156 Intravascular Ultrasound. J Vasc Interv Radiol 2013; 24:1499–1508

157 4. Spiliopoulos S, Kitrou P, Katsanos K, Karnabatidis D. FD-OCT and IVUS intravascular  
158 imaging modalities in peripheral vasculature. Expert Review of Medical Devices,  
159 2017;14:127-134

160 5. Fujino Y, Bezerra HG, Attizzani GF, Wang W, Yamamoto H, Chamié D, et al.  
161 Frequency-domain optical coherence tomography assessment of unprotected left main  
162 coronary artery disease-a comparison with intravascular ultrasound. Catheter Cardiovasc  
163 Interv. 2013;82:E173-83

164 6. Meissner OA, Rieber J, Babaryka G, Oswald M, Reim S, Siebert U, et al. Intravascular  
165 Optical Coherence Tomography: Comparison with Histopathology in Atherosclerotic  
166 Peripheral Artery Specimens. J Vasc Interv Radiol 2006; 17:343–349

167 7. Farooq MU, Khasnis A, Majid A, Kassab MY. The role of optical coherence  
168 tomography in vascular medicine. Vascular Medicine 2009; 14: 63–71

- 169 8. Ozaki Y, Kitabata H, Tsujioka H, Hosokawa S, Kashiwagi M, Ishibashi K, et al.  
170 Comparison of contrast media and low-molecular-weight dextran for frequency-domain  
171 optical coherence tomography *Circ J.* 2012;76:922-7
- 172 9. Schwindt AG, et al. Lower Extremity Revascularization Using Optical Coherence  
173 Tomography–Guided Directional Atherectomy: Final Results of the Evaluation of the  
174 PantheriS Optical COherence Tomography ImagiNg Atherectomy System for Use in the  
175 Peripheral Vasculature (VISION) Study *J Endovasc Ther.* 2017;24:355-366
- 176
- 177

178 Figures legend

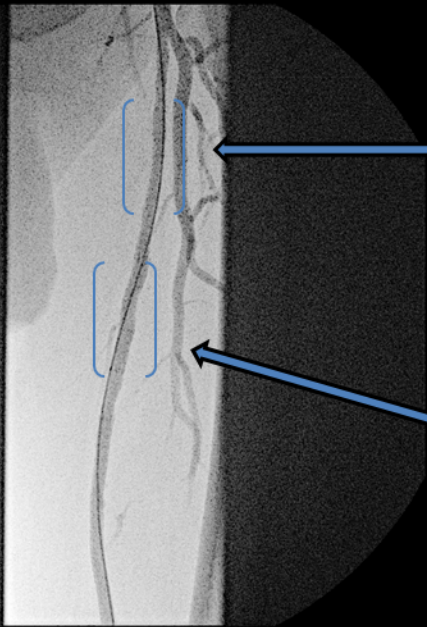
179

180 Figure 1: patient with TASC C lesion; control OCT after initial stenting showed malapposition  
181 of the laser-cut stent and stenosis of the proximal native artery (centre) missed with the 2D  
182 cine fluoroscopic run (left) . The final angiogram was satisfying (right).

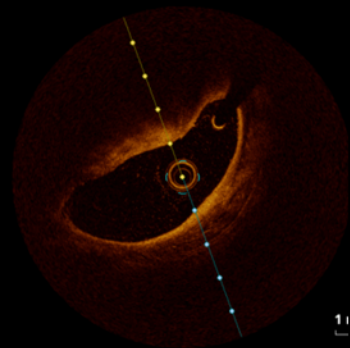
183 Figure 2: patient with TASC D lesion; the distal part of the SFA received a woven self-  
184 expansible stent (left). The final OCT control before (left) and after (centre and right) a  
185 second prolonged balloon angioplasty.

71 kVp  
0,76 mA

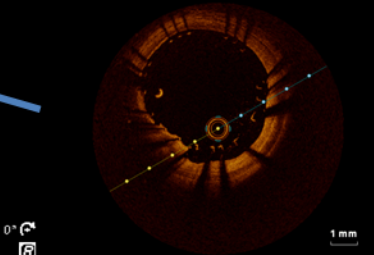
161D



64  
51



11



0°



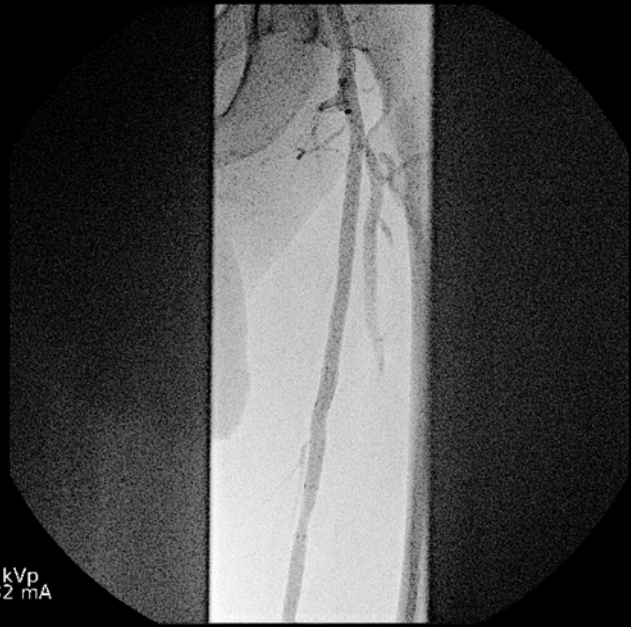OEC



1 mm

74 kVp  
0,82 mA

167D

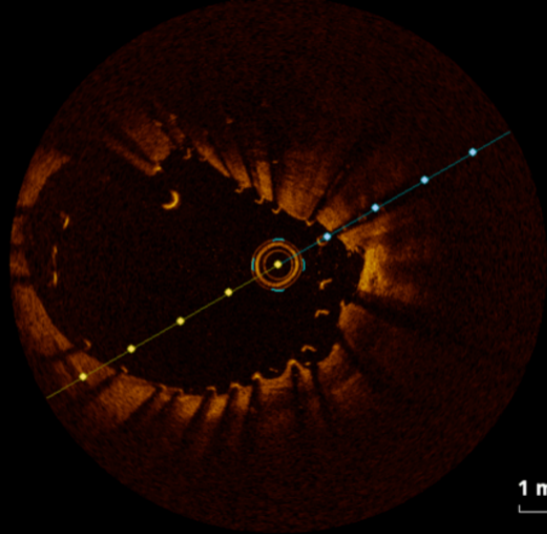


60  
54

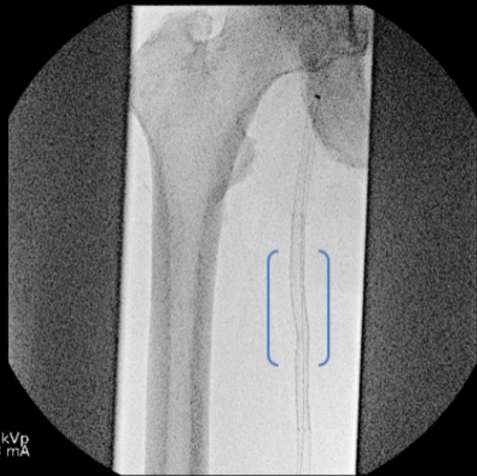

OEC





70 kVp  
6,3 mA  
180C



19  
47

OEC

