



HAL
open science

Pancreatic cancer surgical management

Florence Jeune, Romain Coriat, Frédéric Prat, Bertrand Dousset, Jean-Christophe Vaillant, Sébastien Gaujoux

► **To cite this version:**

Florence Jeune, Romain Coriat, Frédéric Prat, Bertrand Dousset, Jean-Christophe Vaillant, et al.. Pancreatic cancer surgical management. *La Presse Médicale*, 2019, 48, pp.e147 - e158. <10.1016/j.lpm.2019.02.027>. <hal-03486067>

HAL Id: hal-03486067

<https://hal.science/hal-03486067v1>

Submitted on 20 Dec 2021

HAL is a multi-disciplinary open access archive for the deposit and dissemination of scientific research documents, whether they are published or not. The documents may come from teaching and research institutions in France or abroad, or from public or private research centers.

L'archive ouverte pluridisciplinaire **HAL**, est destinée au dépôt et à la diffusion de documents scientifiques de niveau recherche, publiés ou non, émanant des établissements d'enseignement et de recherche français ou étrangers, des laboratoires publics ou privés.



Distributed under a Creative Commons CC BY-NC 4.0 - Attribution - Non-commercial use - International License

LPM

QMR Pancreatic cancer

Pancreatic cancer surgical management

Florence Jeune¹, Jacques Belghiti², Sébastien Gaujoux³

1-Department of hepatobiliary surgery, pancreatic surgery and liver transplantation, Pitié Salpêtrière hospital, APHP- Pierre and Marie Curie University, Paris VI, France.

2-Department of digestive, hepatobiliary and pancreatic surgery, Cochin Hospital, APHP- Paris Descartes Faculty of Medicine, Paris V, France.

3-Department of digestive, hepatobiliary and pancreatic surgery, Cochin Hospital, APHP- Paris Descartes Faculty of Medicine, Paris V, France.

In this issue

Editorial : Pancreatic cancer is still waiting for the big leap forward

S Gaujoux, J Belghiti (France)

Pancreatic cancer epidemiology
P.Maisonneuve (Italy)

Diagnostic strategy with a solid pancreatic mass
G.Guarneri et al (Italy)

Pancreatic cancer surgical management
F.Jeune et al (France)

Pancreatic cancer : Chemotherapy
C.Springfeld et al (United Kingdom, Germany)

Pancreatic cancer : Best supportive care
AL Védie et al (France)

Pancreatic cancer : What' next
R.Salvia et al (Italy)

SUMMARY:

Pancreatic ductal adenocarcinoma (PDAC) remains a dismal prognosis and surgery is the only chance for cure. However, only few of the patients have localized tumor eligible for curative complete resection. Preoperative management and well-staging of the disease are the cornerstone for appropriate surgery and major issues to define the best therapeutic strategy.

With 279 000 new diagnoses each year worldwide, pancreatic ductal adenocarcinoma (PDAC) is the 4th leading cause of cancer-related deaths in the western world. With its rapidly increasing incidence, it should become the second cause of cancer mortality after 2030¹. Only 10-15% of patients are diagnosed with a localized disease allowing a R0-surgical management. The curative resection of PDAC associated with perioperative systemic therapy is currently the best and only chance for cure for resectable and borderline resectable disease with a 5-year overall up to 25%^{2,3}. Surgical and perioperative management has significantly evolved during the last years. Improvement in the management of surgical complications and surgical procedures has led to a very low perioperative mortality in specialized centers, in contrast with nationwide data. Preoperative diagnosis and accurate staging as well as surgical and oncological expertise are crucial issues in the management of patients with PDAC. This review focus on the surgical and optimal perioperative management of PDAC and summarizes updates data on the subject.

I-PREOPERATIVE INVESTIGATIONS:

Imaging Modalities

A high-quality preoperative imaging and assessment is a key point to define the best tailored strategies and selected patients eligible for curative surgery. The 3 challenging steps of the preoperative investigations are the early diagnosis, definition of local resectability and detection of distant metastasis. Multidetector CT-scan (MDCT) with contrast and pancreatic protocol is the best-available first modality imaging for suspicion of PDAC and evaluation of vascular (venous and arterial) invasion and resectability (table 1). The MDCT pancreatic protocol is a triphasic submillimeter section thickness technique without and with enhanced-contrast including pancreatic parenchymal phase (40-50s) and portal venous phase (65-70s)^{4,5}. The reported sensitivity of MDCT to detect PDAC is 85-97% but decrease to 65-75% for small tumor <2cm. The evaluation of vascular resectability should assess the involvement of major arteries: the superior mesenteric artery, hepatic artery and coeliac trunk. Criteria of Venous invasion focus on portal vein, splenic and mesenteric superior vein. MDCT has an accuracy of 85-95% defining resectability^{6,7}. However, MDCT can be inaccurate in detecting small liver metastasis or peritoneal lesion. Several studies have demonstrated that MRI with diffusion-weighted imaging increased the sensitivity of detection for liver metastases and could be helpful for characterization of indeterminate liver lesions⁸⁻¹⁰. Results of a French randomized controlled trial have reported that 12% of distant lesion unknown on CT and PET-CT was detected on MRI with diffusion-weighted imaging¹¹. Both CT and MR imaging are equally suited for detecting PDAC and local staging though¹². MRI with diffusion-weighted imaging is currently recommended in the preoperative evaluation of PDAC¹³. The preoperative assessment of lymph node status remains unsatisfactory whatever the imaging modalities as neither the size or morphology can predict nodes involvement¹⁴⁻¹⁶. The accuracy of preoperative imaging for small peritoneal implant is also insufficient.

Despite increasing improvement on imaging modalities, the percentage of patients undergoing surgical exploration in a curative intent is up to 15%¹⁷. One of the explanations might be the time interval between the last MDCT and surgery. Some data suggest that the last MDCT should be at more 4 weeks before any plane surgery to avoid unexpectedly finding such as distant metastases during surgery^{18,19}. Early surgery without a comprehensive preoperative assessment did not confer any benefit survival, meaning that preoperative imaging, nutritional evaluation and early referral to specialist pancreatic unit is the more effective strategy^{20,21}.

Endoscopic ultrasonography (EUS) is the most accurate but invasive preoperative modality to detect pancreatic adenocarcinoma especially for small tumor (<2cm) with reported sensitivities and specificities of over 95% in most studies^{22,23}. EUS can be associated with fine-needle aspiration (FNA) or biopsy for histopathological diagnosis in case of uncertain diagnosis, locally advanced or

metastatic disease before initiation of neoadjuvant/induction therapy or high suspicion of pancreatic adenocarcinoma with inconclusive or negative MDCT and MRI^{24,25}. EUS can be helpful to evaluate lymph node or vascular involvement but is highly operator-dependent regarding these two points. The adverse effects of EUS-FNA needle biopsy are low in the most recent series including mainly pancreatitis (<2%), hemorrhage or infection²⁶. The potential risk of needle track seeding is not supported by recent analysis of large cohort with no impact on survival²⁷. Pathology evidence of malignancy is currently not required for resectable tumor and should not delay curative surgery in case of high suspicion of pancreatic adenocarcinoma on imaging²⁸.

FDG-PET is a positron-emitting radiotracer technique using the 18F-fluorodeoxyglucose (FDG) highly expressed in cancer cells that can be associated with CT. It may have interest in detection of distant metastasis. FDG-PET can detect 97% of liver metastasis greater than 1 cm but fail to detect half of the lesions $\leq 1\text{cm}$ ²⁹. Accuracy of FDG-PET for diagnosis of PDAC and detection of liver and peritoneal metastasis is similar to that of MDCT³⁰. The poor spatial resolution of FDG-PET limits its interest for local staging. Numerous false-positive results linked to inflammatory lesions, liver abscess, pancreatitis or diabetes decrease its accuracy. To date, no available high evidence suggests to perform routinely FDG-PET for diagnosis or preoperative staging of PDAC.

Non-oncological additional information should be analyzed during the preoperative imaging such as anatomic vascular variations (up to 10% of right hepatic artery)^{31,32} or coeliac trunk stenosis related to a median arcuate ligament (up to 5% of patient who undergo pancreaticoduodenectomy) that should be released during the surgery³³.

Serum marker

Carbohydrate antigen 19-9 (CA 19-9) is a sialylated Lewis A blood antigen, that is the most common tumor marker used in pancreatic cancer. In symptomatic patient, CA 19-9 has a sensitivity of 79-81% and a specificity of 80-90% but its low predictive positive value limits its utility as a screening biomarker^{34,35}. However, many studies have demonstrated the negative prognostic value of increased preoperative CA 19-9 in patients undergoing resection and its correlation to the stage of the disease³⁶⁻³⁸. High Preoperative CA 19-9 has been associated with unresectable tumor discovered during staging laparoscopy³⁹⁻⁴¹. The optimal cutoff for its prognostic value is still matter of debate but a preoperative CA 19-9 level <200 UI/ml seems to be associated with a high probability of resectability while a level > 1000 UI/ml is associated with distant metastasis or unresectable locally advanced disease^{37,42}. Patients with early postoperative increased CA 19-9 have also a worse survival compared to that patients with normal postoperative CA 19-9 (5-years OS 0% vs 27%)⁴². Similarly, normalization or decreased CA 19-9 by ≥ 20 -50% following chemotherapy is associated with prolonged survival⁴² and control of the disease.

However, CA 19-9 may have insufficient accuracy in asymptomatic patients⁴³ and has several limitations that should be considered when interpreting serum levels in a clinical setting. First of all, sialylated Lewis antigen-negative patients that have fewer or no secretion of CA19-9⁴⁴ represent approximately 5%–10% of the population. Nonspecific secretion of CA 19-9 has been reported in several non-malignant conditions such as: ovarian cyst, pulmonary disease, rheumatoid arthritis or hashimoto disease^{43,45,46} and the presence of obstructive jaundice increased significantly the serum level of CA 19-9^{47,48}. The serum level is increased in 30-60% of pancreatic patients and could not be recommended as an available screening biomarker in PDAC⁴⁹. Others promising biomarkers are under investigation. Among them circulating DNA seems to be associated with the prognosis and stage of the disease^{50,51}.

Staging Laparoscopy

The goal of staging laparoscopy is to avoid unnecessary laparotomy in patients planned to have surgery with curative-intent⁵². Although systematic staging laparoscopy is controversial, it can be useful in patients with resectable tumor at high risk for disseminated disease with significantly increased CA 19-9 level^{39,53}. Diagnostic laparoscopy could detect about 15 % of locally unresectable tumor or occult metastasis following preoperative imaging⁵⁴. Contemporary studies have shown a decreased yield of staging laparoscopy related to the high-quality imaging improvement but it still exceeds 10% in PDAC^{52,55}. A-selected-staging-laparoscopic approach seems to be the more appropriate and is associated with shorter time to chemotherapy and improved overall survival⁵⁵. Some factors associated with the likelihood of occult metastatic disease have been identified: high preoperative CA 19-9 level (>100- 130 UI/ml) , size of the tumor, no neoadjuvant therapy and body or tail location of the tumor^{52,53}. Consequently, staging laparoscopy could be recommended in case of: i) bulky tumor of the body or tail of the pancreas ii) high level of preoperative CA 19-9 (>130 UI/ml) iii) patients with borderline tumor planned to received preoperative therapy¹³.

II-STAGING PDAC

A well-staged-tumor is a keystone in the management of patients with PDAC. A low-quality preoperative staging may lead to inappropriate therapeutic strategies in up to 50% of patients⁵⁶. These data emphasize the interest of a centralized management of PDAC including expert radiologist and surgeons.

Vascular involvement is the main reason of unresectability for non-metastatic patients and is usually related to the involvement of mesenteric vessels for PDAC of the head of the pancreas. The location pattern is a factor of vascular encasement. Mesenteric vessels involvement has been reported to be significantly increase in case of uncinata adenocarcinoma⁵⁷. The degree of cross-

sectional circumference involvement is used for staging. The radiology report will have to focus on the following vessels: superior mesenteric artery (SMA), common hepatic artery (CHA), coeliac axis (CA), aorta, superior mesenteric vein (SMV), portal vein (PV), first jejunal vein. Indirect signs of venous involvement such as segmental portal hypertension should be analyzed. Using a set of criteria including vascular contact and distant metastasis, patients are divided into 3 groups: resectable/ Borderline/ Unresectable (*i.e.* locally advanced or metastatic disease) (*National comprehensive cancer network-NCCN*)²⁸.

Resectable stage includes tumors with SMV or PV abutment inferior to 180° but no arterial contact (regarding SMA/CA/CHA/Aorta).

Borderline tumor is considered when the SMA abutment is inferior to 180° of the circumference without CA involvement or in case of SMV involvement allowing for safe resection and reconstruction. Borderline tumors have a high likelihood of an incomplete resection (R1) during upfront surgery and should receive preoperative treatment in order to downstage and increase the rate of complete resection⁵⁸⁻⁶¹.

New highly effective chemotherapy such as FOLFIRINOX or Gemcitabine-nab-paclitaxel-based regimen can lead to secondary resection in up to 30% of locally advanced (LA) tumor (SMA involvement >180° of the circumference and/or SMV invasion with no initial technical option⁶²) without tumor progression after induction treatment⁶³⁻⁶⁵.

III-PREOPERATIVE CARE

Biliary drainage

Systematic preoperative biliary drainage has been for a long time a matter of debate. *Van der Gaag et al*⁶⁶ answered to the question with a large multicenter randomized trial including 202 patients with resectable tumor and obstructive jaundice with preoperative bilirubin level of 40-250 micromol/L. They have reported 46% of complications related to the endoscopic pre-operative biliary drainage with plastic stent such as cholangitis (26%), pancreatitis (7%), perforation (2%) or bleeding (2%) while no improvement of surgical outcomes was seen in the biliary drainage patients group⁶⁶. Nevertheless, preoperative relief biliary obstruction in patients with potentially resectable tumor can be necessary in selected patients like those with acute cholangitis, serum bilirubin \geq 250 or 300 micromol/l⁶⁷ or in whom surgery is delayed for neoadjuvant therapies^{68,69}. For these patients, whenever preoperative biliary endoscopic drainage is required, full covered short self-expandable metal stents (FCSEMS) should be used rather than plastic stents as they decreased the rate of complications (51 vs 74%)^{70,71}. The optimal time to surgery should be 4-6 weeks to allow optimal therapeutic benefit with no negative impact on oncological outcomes⁷².

Preoperative nutrition

Up to 80% of the patients undergoing pancreatic resection for malignant tumors have a malnutrition deficiency⁷³. Many studies have reported a higher rate of postoperative complications in undernourished patients^{74,75} such as surgical site infection, hospital acquired infection⁷⁶ or pancreatic fistula^{77,78}. The nutrition status can be evaluated with the following tools: loss of weight ($\geq 5\%$ in the previous month or $\geq 10\%$ within the 6 previous months), albumin and prealbumin level (g/l), Body mass index (BMI). Several nutritional scores such as *The mini nutritional assessment* (MNA) have been evaluated to define the malnutrition risk associated with the postoperative outcomes⁷⁹ but none of these scores seems to be more relevant than to another.

Several studies have reported that preoperative immunonutrition (IN) in gastrointestinal cancer was associated with a lower rate of postoperative infections and a shorter length of hospital stays allowing a shorter functional recovery^{80,81}, even for patients well-nourished⁸². These results have emphasized the interest of preoperative IN for all the patients whatever the nutritional status. A preoperative IN such as Oral Impact© should be at least delivered for ≥ 7 days before surgery to reach a therapeutic benefit. Patients with severe nutritional risk (weight loss $>10\text{-}15\%$ within 6 previous months, BMI $<18.5 \text{ kg/m}^2$, albumin $<30\text{g/l}$) should receive an enteral nutritional support for 10-14 days prior to surgery⁸³.

IV-SURGERY

Surgery is the only chance of cure for PDAC but only 10 to 20% of patients will undergo pancreatic resection^{84,85}. A Japanese multicenter RCT has reported a better survival of patients with resectable locally advanced PDAC undergoing surgical resection than that of treated with radio chemotherapy alone⁸⁴. The median survival of patients with surgical resection ranges from 20.1 to 28 months^{86,87} with a mortality rate that has significantly decreased over the last decade, to fall below 5% in high-volume centers^{13,88}. The goal of the surgery is to achieve a microscopic complete resection (R0). Major prognostic factors have been well-established such as nodes involvement⁸⁹, lymphovascular⁹⁰ and perineural invasion⁹¹, tumor size⁸⁷ or preoperative level of CA 19-9⁹². The prognostic impact of R0 resection has been for a while matter of debate as controversial data have been published⁹³⁻⁹⁶. These conflicting results are highly affected by the definition of R0 resection and the pathology specimen evaluation that are not standardized in most of the studies as highlight the rate of R0 resection ranging from 15% to $> 80\%$ ⁹⁷⁻⁹⁹. Furthermore, several studies have reported that resection status was associated with major prognostic factors such as nodes involvement which may have more relevant impact than that of resection margin status^{89,100}. In a recent prospective French trial, we have reported that R0 resection had a major impact on survival among resected patients without node involvement¹⁰¹.

Pancreaticoduodenectomy

Technical considerations

The nature and extent of the surgery depend on the location and size of the tumor. Tumors located in the head or uncus of the pancreas require a pancreaticoduodenectomy (PD) that remove the pancreatic head, duodenum, gallbladder and common bile duct with removal of the gastric antrum (Whipple procedure) or not. The pylorus-preserving pancreatoduodenectomy (PPPD) was introduced to avoid functional postoperative impairment such as dumping syndrome or bile reflux without compromising the lymph node clearance or oncological outcomes¹⁰². However, PPPD do not improve delayed gastric emptying or overall morbidity¹⁰³. The PPPD is not recommended though for tumors located in the upper part of the head of the pancreas. Three anastomosis are required for reconstruction i) pancreaticojejunostomy (PJ) or pancreaticogastrostomy (PG) ii) hepaticojejunostomy iii) gastrojejunostomy. (Figure 1).

Lymphadenectomy

Lymph node involvement is one of the most powerful prognostic factor in PDAC. Both the number of LN removed in N0 patients and the LN ratio in N1 patients have prognostic value after surgical resection¹⁰⁴. Extended lymphadenectomy including circumferential dissection of the SMA and coeliac axis (CA) had been proposed to increased survival after pancreatic resection. Extended lymphadenectomy has been investigated in 5 RCT trials but failed to find better oncological outcomes compared to standard lymphadenectomy and extended lymphadenectomy increase the rate of postoperative morbidity¹⁰⁵⁻¹⁰⁹(diarrhea, delayed gastric emptying...). While definition of extended lymphadenectomy is still unclear, the standard lymphadenectomy should include the following LN stations: 5 (suprapyloric) ,6 (infrapyloric), 8a (common hepatic artery), 12 b-c (along the bile duct and cystic duct), 13a-b (along the head of the pancreas), 14a-b (along the right lateral side of superior mesenteric artery), 17a-b (along the anterior face of the head of the pancreas) (Figure 2). Retroperitoneal soft-tissue should be removed completely. At least 15 lymph nodes should be harvest to avoid understaging of the tumor disease¹⁰⁴.

Para-aortic lymph node (PALN) dissection is a burden point of the surgical management. PALN involvement is reported in up to 15%^{110,111} of patients undergoing PDAC with curative-intent. Several studies^{110,112} have demonstrated a decreased-overall survival (OS) in patients with PALN metastasis. . Based on these data, some surgical teams do not performed PD in case of positive PALN in frozen-section analysis. However, no international consensual guidelines are available regarding the systematic sampling of PALN and the appropriate therapeutic strategy to decide in case of positive PALN.

First SMA approach

The right side of the SMA is the primary location of incomplete microscopic (R1) resection¹¹³ and is associated with a decreased-OS after resection¹⁰¹. Usually, circumferential involvement of SMA is a contraindication to surgery. For this reason, SMA first approach has been advocated to assess arterial involvement and define the resectability of the tumor early during the surgical procedure. This approach can avoid unnecessary or R1 resection. Besides, it can allow an easier lymphadenectomy dissection and identification of right hepatic artery¹¹⁴. Studies have reported reduction of blood loss¹¹⁵ and a better access to portal vein if vascular resection is needed¹¹⁶ with this technique. Six different approach have been described in the literature. The choice of the best approach depends on the location of the tumor.

Vascular resection

Porto-mesenteric vein involvement is a common clinical finding in PDAC. The rate of venous involvement ranges from 26 to 85% in the literature¹¹⁷⁻¹¹⁹. *En bloc* venous resection (VR) with reconstruction is a way to achieve complete tumor clearance in case of PV-SMV involvement. Portomesenteric-vein resection is a common procedure at high-volume pancreatic centers. Two meta-analysis including more than 1500 patients have reported similar results in postoperative morbidity and mortality (<5%)^{120,121} in patients with VR compared to those without. Nevertheless, VR have been reported as a negative prognostic factor that decrease OS in several studies^{59,98,122}. However, the median OS reported in these studies ranges from 11 to 25 months and is far longer than the median OS observed in these patients when palliative therapies are initiated¹²². In some cohort, patients with VR had more than 67% of node involvement that may also partially explain the worse oncological outcomes among this patients¹²². Patients with venous involvement are good candidates for neoadjuvant therapies. Many studies have reported that FOLFIRINOX based-neoadjuvant chemotherapy increased the rate of R0 resection up to 85% in borderline or locally advanced PDAC and was associated with longer survival^{60,61,123}. Arterial resection is contrariwise not recommended as it is associated with substantial morbidity and poor short and long-term outcomes^{124,125}, even if its remain technically feasible¹²⁶.

Pancreatic anastomosis and abdominal drainage

Postoperative pancreatic fistula (POPF) remains the main factor of postoperative morbidity with a rate of about 15-20% in the literature^{127,128}. Many studies have focused on different aspect to prevent PF. Two type of pancreatic anastomosis are mainly performed for reconstruction: *pancreaticojejunostomy (PJ)* and *pancreaticogastrostomy (PG)*. Retrospectives studies have advocated that PG was associated with decreased clinical POPF. However, Results from several RCT

are conflicting regarding the superiority of PG over PJ and a recent meta-analysis of 1629 patient did not support one procedure to another regarding postoperative morbidity and POPF¹²⁹⁻¹³¹. It appears that one standardized anastomotic technique should be learn and perform within a center to minimize POPF irrespective of the type of anastomosis or texture of the pancreas¹³².

Transanastomotic pancreatic stent duct placement had been proposed to reduce the rate of POPF after pancreatic resection. RCTs have demonstrated that external drainage of pancreatic duct with stent reduced POPF and overall morbidity in high risk patients with soft pancreas texture and non-dilated duct after PD^{51,133,134}.

Inhibition of exocrine secretion by somatostatine analogues including octreotide have been evaluated in many trials with controversial results^{135,136}. To date, no available data suggest to deliver systematic octreotide for prevention of POPF. A French RCT: *Prefips* is currently comparing intravenous somatostatine vs subcutaneous octreotide for prevention of POPF during pancreatectomy.

Abdominal drain is routinely use after pancreatic resection. Selective use of drain and early removal for patients with a low risk of POPF appears to be an appropriate strategy¹³⁷⁻¹³⁹.

Inking of PD specimen

The heterogeneity of incomplete microscopic resection (R1 resection) rate and its association with oncological outcomes remains a central issue. The reported rate of R1 resection ranges from 15 to >80% depending on the definition used to defined R1 status^{98,140}. The Union for International Cancer Control (UICC) define R1 resection as the presence of tumor cells at the surface of the resection margins (0 mm), whereas the UK Royal College of Pathologist define microscopic residual tumor as the presence of tumor cells within 1.0 mm of the margins. The 1 mm cut-off seems to be the more clinically relevant, since it seems to be clearly associated with oncological outcome. The confusion is also maintained as R1 status and microscopic margin involvement are commonly misused to define incomplete resection while the R descriptor stands for residual disease and not for resection margin. The pathology protocol and specimen inking have a major impact on the accurate assessment of incomplete microscopic resection^{100,141}. However, recent survey among pathologist demonstrated a significant inconsistency in the assessment of resection margin involvement as only 58% of pathologists inked the pancreatic specimens¹⁴². A recent prospective study⁸⁹ has clearly highlight the clinical relevance of inking PD specimen to report the appropriate rate of R1 resection that may lead to specific adjuvant strategies. Inking of PD specimen is currently mandatory.

Laparotomy or Laparoscopy?

PD is associated with high rate of morbidity and some surgeons had advocate that minimally invasive procedure (MIP) could reduce the postoperative morbidity and lead to enhanced recovery. Results of study concerning MIP outcome remain controversial. Preliminary results of the *LEOPARD-2 RCT*¹⁴³ (*IHPBA congress, Geneva 2018*) comparing MIP versus open PD for benign, premalignant or malignant disease. The data monitoring board stopped the study after 99 inclusions among the 136 scheduled because of an increased mortality in the MIP group (10% vs 2%). Nevertheless, in high volume centers, postoperative morbidity of MI pancreaticoduodenectomy could be comparable of the one of open PD. However, oncological data are currently not available regarding MIP for PD performed for PDAC. To date, it is very important to underline that minimally invasive approach for PD is not the standard of care.

Distal pancreatectomy

Distal pancreatectomy with splenectomy is usually performed for pancreatic adenocarcinoma located in the body or tail of the pancreas. Standard lymphadenectomy during distal pancreatectomy should include at least LN located in the hilum of the spleen (LN station 10), along the splenic artery (LN station 11) and along the inferior border of the body and tail of the pancreas (LN station 18)¹⁴⁴. Lymph node located around the coeliac axis should be include only in tumors of the body of the pancreas¹⁴⁴ (Figure 3). The minimum number of LN removed during DP remains a central issue. By analogy to PD, the general consensus require 15 LN during distal pancreatectomy but because of different lymphatic spread, it may be not appropriate for body/tail tumor of the pancreas¹⁴⁵. Several studies investigated the minimum number required for appropriate staging after DP. Some of them reported a minimum number of 20 LN necessary to detect at least 1 positive LN^{146,147}. Since the two last decades, the radical antegrade modular pancreatectosplenectomy (RAMPS procedure) advocated by *Strasberg et al*¹⁴⁸ have been matter of interest. During this procedure, the dissection is proceeded from the right to the left side to achieve an early vascular control and parenchymal transection at the neck of the pancreas. The anterior renal fascia is removed to achieve a complete retroperitoneal margin. Coeliac and left-side of SMA node dissection are associated to the standard lymphadenectomy. This surgical technique has demonstrated oncological benefit such as a greater rate of R0 resection and a higher number of LN retrieved¹⁴⁹⁻¹⁵¹.

Section of the remnant pancreatic parenchyma

POPF occur in up to a third of patients after DP. Several techniques have been proposed in an attempt to reduce this rate including hand-sew selective closure of the pancreatic duct, stapler closure, pancreatic anastomosis and stump coverage with glue or patch, but none of them has

demonstrated a significant impact¹⁵². A RCT comparing hand-sew and stapler closure did not report any significant difference in POPF in the two groups¹⁵³. Likewise, transpapillary stent in the remnant pancreas to improve the pancreatic fluid drainage did not decrease the rate or severity of POPF¹⁵⁴.

Laparoscopic DP

Feasibility and safety of laparoscopic DP (LDP) have been widely assessed since few years. A trend toward a reduction in blood loss, delayed gastric emptying and a shorter length of hospital stay have been reported with LDP^{155,156}. The RCT *LEOPARD* have reported similar overall postoperative complications with LDP vs open surgery for benign or malignant left-sided pancreatic tumors with a shorter time to functional recovery (4 days vs 6 days)¹⁵⁷. To date, very few data focus on PDAC and oncological outcomes are available, but there are no strong evidence of decreased survival with LDP¹⁵⁸. The pan-European propensity score matched study *DIPLOMA* including 1212 patients reported a lower LN retrieval with LDP (14 vs 22) without impact on median OS (28 months vs 31 months)¹⁵⁹. RCT with primary endpoint focus on OS and DFS are needed to confirm the oncological safety of LDP. LDP for PDAC should be performed in expert center in pancreatic surgery for selected patients with small tumor without vascular or visceral involvement.

V- POST OPERATIVE MANAGEMENT

Surgical postoperative morbidity is still about 30-40% after pancreatic resection mainly represented by postoperative pancreatic fistula (POPF). The consensual definition of POPF is a drain output fluid (irrespective of the volume) with an amylase content greater than 3 times the serum amylase level¹⁶⁰. International consensus regarding pancreatic surgery-related complications has allow available comparison of studies and development in postoperative care. The management of complications remains the cornerstone of surgical success and safety. Percutaneous or endoscopic drainage of POPF or intra-abdominal abscess and endovascular management of post-operative hemorrhage has improved the postoperative management of surgical complications and decreased perioperative mortality¹⁶¹. Presence of Interventional radiologist service is associated with a lower postoperative mortality that makes sense as 44% of the patients will require interventional radiologic procedure including 12% during the perioperative period¹⁶².

Postoperative Hemorrhage commonly related to the gastroduodenal artery stump in patients with POPF is one of the most demanding complications requiring endovascular procedure to avoid re-intervention and high-mortality hospitals. Sentinel bleeding is usually the first symptoms before hemorrhage that should lead to early angiography associated with embolization or stent placement. Appropriate management of postoperative outcomes and adequate clinical support are the benchmark of expert unit in pancreatic surgery.

The Enhanced recovery after surgery (ERAS program) including early mobilization, early oral feeding, midthoracic epidural analgesia and early removal of abdominal drain have reported shorter length of hospital stay and functional recovery and may reduce postoperative complications without adverse effects on postoperative mortality^{163,164}. The RCT Nutri-DPC failed to demonstrate the superiority of nasojejunal early enteral postoperative nutrition (NJEEN) compared with total parenteral nutrition in terms of postoperative infections, length of hospital stay, delay gastric emptying or hemorrhage while NJEEN was associated with a higher rate of postoperative pancreatic fistula¹⁶⁵.

CONCLUSION

PDAC is still a challenging disease to cure in 2018/2019. Despite major improvement in perioperative management and development of new therapy protocols, its prognosis remains dismal and has poorly evolved over the last 3 decades. Advances in cross-sectional imaging have led to accurate staging of the disease and more appropriate treatment. Multidisciplinary management of PDAC in high and expert centers is mandatory to increase patients' survival. Well-knowledge of postoperative complications and their adequate management is also the cornerstone of expert pancreatic surgical units that decrease postoperative mortality and insure safe surgical procedures. Further studies focus on earlier detection of PDAC are needed to increase the rate of resectable disease at the time of diagnosis and would greatly improve its prognosis.

Table 1: The National Comprehensive Cancer Network classification (version 2017).

Legend: CA: coeliac artery / SMA: superior mesenteric artery / CHA: common hepatic artery/ SMV: superior mesenteric vein / PV: portal vein / IVC: inferior vena cava.

Figure 1: Reconstruction after Whipple procedure.

Legend: 3 anastomosis: 1) Pancreaticojejunostomy 2) Hepaticojejunostomy 3) Gastrojejunostomy.

Figure 2: Lymphadenectomy during pancreaticoduodenectomy.

Legend: Standard lymphadenectomy should include the following Lymph Node stations: 5 (suprapyloric), 6 (infrapyloric), 8a (common hepatic artery), 12b-c (along the bile duct and cystic duct), 13a-b (along the head of the pancreas), 14a-b (along the right lateral side of superior mesenteric artery), 17a-b (along the anterior face of the head of the pancreas).

Figure 3: Lymphadenectomy during pancreatectomy.

Legend : Standard lymphadenectomy during distal pancreatectomy should include at least: LN located in the hilum of the spleen (LN station 10), along the splenic artery (LN station 11) and along the inferior border of the body and tail of the pancreas (LN station 18).

REFERENCES

1. Rahib, L. *et al.* Projecting cancer incidence and deaths to 2030: the unexpected burden of thyroid, liver, and pancreas cancers in the United States. *Cancer Res.* **74**, 2913–2921 (2014).
2. Doi, R. *et al.* Surgery versus radiochemotherapy for resectable locally invasive pancreatic cancer: final results of a randomized multi-institutional trial. *Surg. Today* **38**, 1021–1028 (2008).
3. Hackert, T., Ulrich, A. & Büchler, M. W. Borderline resectable pancreatic cancer. *Cancer Lett.* **375**, 231–237 (2016).
4. Al-Hawary, M. M. *et al.* Pancreatic ductal adenocarcinoma radiology reporting template: consensus statement of the society of abdominal radiology and the american pancreatic association.

Gastroenterology **146**, 291-304.e1 (2014).

5. Tamm, E. P. *et al.* Imaging of pancreatic adenocarcinoma: update on staging/resectability. *Radiol. Clin. North Am.* **50**, 407–428 (2012).
6. Diehl, S. J., Lehmann, K. J., Sadick, M., Lachmann, R. & Georgi, M. Pancreatic cancer: value of dual-phase helical CT in assessing resectability. *Radiology* **206**, 373–378 (1998).
7. Valls, C. *et al.* Dual-phase helical CT of pancreatic adenocarcinoma: assessment of resectability before surgery. *AJR Am. J. Roentgenol.* **178**, 821–826 (2002).
8. Holzapfel, K. *et al.* Comparison of diffusion-weighted MR imaging and multidetector-row CT in the detection of liver metastases in patients operated for pancreatic cancer. *Abdom. Imaging* **36**, 179–184 (2011).
9. Holalkere, N.-S. *et al.* Characterization of small liver lesions: Added role of MR after MDCT. *J. Comput. Assist. Tomogr.* **30**, 591–596 (2006).
10. Bhalla, M. *et al.* Characterizing indeterminate liver lesions in patients with localized pancreatic cancer at the time of diagnosis. *Abdom. Radiol. N. Y.* **43**, 351–363 (2018).
11. Marion-Audibert, A.-M. *et al.* Routine MRI With DWI Sequences to Detect Liver Metastases in Patients With Potentially Resectable Pancreatic Ductal Carcinoma and Normal Liver CT: A Prospective Multicenter Study. *AJR Am. J. Roentgenol.* W1–W9 (2018). doi:10.2214/AJR.18.19640
12. Koelblinger, C. *et al.* Gadobenate dimeglumine-enhanced 3.0-T MR imaging versus multiphasic 64-detector row CT: prospective evaluation in patients suspected of having pancreatic cancer. *Radiology* **259**, 757–766 (2011).
13. Pancreatic cancer: French clinical practice guidelines for diagnosis, treatment and follow-up (SNFGE, FFCD, GERCOR, UNICANCER, SFCD, SFED, SFRO, ACHBT, AFC). Neuzillet C, **Gaujoux S**, Williet N, Bachet JB, Bauguion L, Colson Durand L, Conroy T, Dahan L, Gilibert M, Huguet F, Marthey L, Meilleroux J, de Mestier L, Napoléon B, Portales F, Sa Cunha A, Schwarz L, Taieb J, Chibaudel B, Bouché O, Hammel P; Thésaurus National de Cancérologie Digestive (TNCD); Société Nationale Française de Gastroentérologie (SNFGE); Fédération Francophone de Cancérologie Digestive (FFCD); Groupe Coopérateur multidisciplinaire en Oncologie (GERCOR); Fédération Nationale des Centres de Lutte Contre le Cancer (UNICANCER); Société Française de Chirurgie Digestive (SFCD); Société Française d’Endoscopie Digestive (SFED); Société Française de Radiothérapie Oncologique (SFRO); Association de Chirurgie Hépatobiliaire-Pancréatique et Transplantation (ACHBT); Association Française de Chirurgie (AFC). *Dig Liver Dis.* 2018 Aug 18. pii: S1590-8658(18)30888-0. doi: 10.1016/j.dld.2018.08.008. [Epub ahead of print] Review.
14. al, F. H., *et.* Preoperative staging of biliary carcinoma using 18F-fluorodeoxyglucose PET: prospective comparison with PET+CT, MDCT and histopathology. - PubMed - NCBI. Available at: <https://www.ncbi.nlm.nih.gov/pubmed/?term=Furukawa+H%2C+Ikuma+H%2C+Asakura-Yokoe+K%2C+Uesaka+K.+Preoperative+staging+of+biliary+carcinoma+using+18F->

fluorodeoxyglucose+PET%3A+prospective+comparison+with+PET+%3F+CT%2C+MDCT+and+histopathology.+Eur+Radiol. (Accessed: 30th August 2018)

15. Noji, T. *et al.* Computed tomography evaluation of regional lymph node metastases in patients with biliary cancer. *Br. J. Surg.* **95**, 92–96 (2008).
16. Soriano, A. *et al.* Preoperative staging and tumor resectability assessment of pancreatic cancer: prospective study comparing endoscopic ultrasonography, helical computed tomography, magnetic resonance imaging, and angiography. *Am. J. Gastroenterol.* **99**, 492–501 (2004).
17. Marion-Audibert, A. M., Mabrut, J. Y., Zins, M., Sauvanet, A., Souquet, J. C., Sa Cunha A. *et al.* Intérêt de l'IRM de diffusion dans le bilan préthérapeutique de l'adénocarcinome pancréatique potentiellement r.s.cable. Journées Francophones d'Hépatogastroentérologie et d'Oncologie Digestive, abstr P135 (2014).
18. Raman, S. P. *et al.* Impact of the time interval between MDCT imaging and surgery on the accuracy of identifying metastatic disease in patients with pancreatic cancer. *AJR Am. J. Roentgenol.* **204**, W37-42 (2015).
19. Healy, G. M. *et al.* Preoperative CT in patients with surgically resectable pancreatic adenocarcinoma: does the time interval between CT and surgery affect survival? *Abdom. Radiol. N. Y.* **43**, 620–628 (2018).
20. Mirkin, K. A., Hollenbeak, C. S. & Wong, J. Time to Surgery: a Misguided Quality Metric in Early Stage Pancreatic Cancer. *J. Gastrointest. Surg. Off. J. Soc. Surg. Aliment. Tract* **22**, 1365–1375 (2018).
21. Raptis, D. A., Fessas, C., Belasyse-Smith, P. & Kurzwinski, T. R. Clinical presentation and waiting time targets do not affect prognosis in patients with pancreatic cancer. *Surg. J. R. Coll. Surg. Edinb. Irel.* **8**, 239–246 (2010).
22. DeWitt, J. *et al.* Comparison of endoscopic ultrasonography and multidetector computed tomography for detecting and staging pancreatic cancer. *Ann. Intern. Med.* **141**, 753–763 (2004).
23. Agarwal, B., Abu-Hamda, E., Molke, K. L., Correa, A. M. & Ho, L. Endoscopic ultrasound-guided fine needle aspiration and multidetector spiral CT in the diagnosis of pancreatic cancer. *Am. J. Gastroenterol.* **99**, 844–850 (2004).
24. Deerenberg, E. B. *et al.* Role of endoscopic ultrasonography in patients suspected of pancreatic cancer with negative helical MDCT scan. *Dig. Surg.* **28**, 398–403 (2011).
25. Krishna, S. G. *et al.* Diagnostic performance of endoscopic ultrasound for detection of pancreatic malignancy following an indeterminate multidetector CT scan: a systemic review and meta-analysis. *Surg. Endosc.* **31**, 4558–4567 (2017).
26. Adler, D. G. *et al.* ASGE guideline: complications of EUS. *Gastrointest. Endosc.* **61**, 8–12 (2005).
27. Ngamruengphong, S. *et al.* Risk of gastric or peritoneal recurrence, and long-term outcomes,

- following pancreatic cancer resection with preoperative endosonographically guided fine needle aspiration. *Endoscopy* **45**, 619–626 (2013).
28. Tempero, M. A. *et al.* Pancreatic Adenocarcinoma, Version 2.2017, NCCN Clinical Practice Guidelines in Oncology. *J. Natl. Compr. Cancer Netw. JNCCN* **15**, 1028–1061 (2017).
 29. Fröhlich, A. *et al.* Detection of liver metastases from pancreatic cancer using FDG PET. *J. Nucl. Med. Off. Publ. Soc. Nucl. Med.* **40**, 250–255 (1999).
 30. Lytras, D. *et al.* Positron emission tomography does not add to computed tomography for the diagnosis and staging of pancreatic cancer. *Dig. Surg.* **22**, 55–61; discussion 62 (2005).
 31. Eshuis, W. J., Olde Loohuis, K. M., Busch, O. R. C., van Gulik, T. M. & Gouma, D. J. Influence of aberrant right hepatic artery on perioperative course and longterm survival after pancreatoduodenectomy. *HPB* **13**, 161–167 (2011).
 32. Sulpice, L. *et al.* Does an aberrant right hepatic artery really influence the short- and long-term results of a pancreaticoduodenectomy for malignant disease? A matched case-controlled study. *J. Surg. Res.* **185**, 620–625 (2013).
 33. Gaujoux, S. *et al.* Ischemic complications after pancreaticoduodenectomy: incidence, prevention, and management. *Ann. Surg.* **249**, 111–117 (2009).
 34. Ballehaninna, U. K. & Chamberlain, R. S. The clinical utility of serum CA 19-9 in the diagnosis, prognosis and management of pancreatic adenocarcinoma: An evidence based appraisal. *J. Gastrointest. Oncol.* **3**, 105–119 (2012).
 35. Huang, Z. & Liu, F. Diagnostic value of serum carbohydrate antigen 19-9 in pancreatic cancer: a meta-analysis. *Tumour Biol. J. Int. Soc. Oncodevelopmental Biol. Med.* **35**, 7459–7465 (2014).
 36. Barton, J. G. *et al.* Predictive and prognostic value of CA 19-9 in resected pancreatic adenocarcinoma. *J. Gastrointest. Surg. Off. J. Soc. Surg. Aliment. Tract* **13**, 2050–2058 (2009).
 37. Barugola, G. *et al.* Resectable pancreatic cancer: who really benefits from resection? *Ann. Surg. Oncol.* **16**, 3316–3322 (2009).
 38. Ferrone, C. R. *et al.* Perioperative CA19-9 levels can predict stage and survival in patients with resectable pancreatic adenocarcinoma. *J. Clin. Oncol. Off. J. Am. Soc. Clin. Oncol.* **24**, 2897–2902 (2006).
 39. Maithel, S. K. *et al.* Preoperative CA 19-9 and the yield of staging laparoscopy in patients with radiographically resectable pancreatic adenocarcinoma. *Ann. Surg. Oncol.* **15**, 3512–3520 (2008).
 40. Kondo, N. *et al.* Prognostic impact of perioperative serum CA 19-9 levels in patients with resectable pancreatic cancer. *Ann. Surg. Oncol.* **17**, 2321–2329 (2010).
 41. Halloran, C. M. *et al.* Carbohydrate antigen 19.9 accurately selects patients for laparoscopic assessment to determine resectability of pancreatic malignancy. *Br. J. Surg.* **95**, 453–459 (2008).
 42. Hartwig, W. *et al.* CA19-9 in potentially resectable pancreatic cancer: perspective to adjust surgical and perioperative therapy. *Ann. Surg. Oncol.* **20**, 2188–2196 (2013).

43. Kim, J.-E. *et al.* Clinical usefulness of carbohydrate antigen 19-9 as a screening test for pancreatic cancer in an asymptomatic population. *J. Gastroenterol. Hepatol.* **19**, 182–186 (2004).
44. Hamanaka, Y., Hamanaka, S. & Suzuki, M. Sialyl Lewis(a) ganglioside in pancreatic cancer tissue correlates with the serum CA 19-9 level. *Pancreas* **13**, 160–165 (1996).
45. Kim, H.-R. *et al.* Increased CA 19-9 level in patients without malignant disease. *Clin. Chem. Lab. Med.* **47**, 750–754 (2009).
46. Kim, B. J. *et al.* How do we interpret an elevated carbohydrate antigen 19-9 level in asymptomatic subjects? *Dig. Liver Dis. Off. J. Ital. Soc. Gastroenterol. Ital. Assoc. Study Liver* **41**, 364–369 (2009).
47. Marrelli, D. *et al.* CA19-9 serum levels in obstructive jaundice: clinical value in benign and malignant conditions. *Am. J. Surg.* **198**, 333–339 (2009).
48. Mann, D. V., Edwards, R., Ho, S., Lau, W. Y. & Glazer, G. Elevated tumour marker CA19-9: clinical interpretation and influence of obstructive jaundice. *Eur. J. Surg. Oncol. J. Eur. Soc. Surg. Oncol. Br. Assoc. Surg. Oncol.* **26**, 474–479 (2000).
49. Nazli, O., Bozdog, A. D., Tansug, T., Kir, R. & Kaymak, E. The diagnostic importance of CEA and CA 19-9 for the early diagnosis of pancreatic carcinoma. *Hepatogastroenterology.* **47**, 1750–1752 (2000).
50. Vietsch, E. E., van Eijck, C. H. & Wellstein, A. Circulating DNA and Micro-RNA in Patients with Pancreatic Cancer. *Pancreat. Disord. Ther.* **5**, (2015).
51. Pietrasz, D. *et al.* Plasma Circulating Tumor DNA in Pancreatic Cancer Patients Is a Prognostic Marker. *Clin. Cancer Res. Off. J. Am. Assoc. Cancer Res.* **23**, 116–123 (2017).
52. Allen, V. B., Gurusamy, K. S., Takwoingi, Y., Kalia, A. & Davidson, B. R. Diagnostic accuracy of laparoscopy following computed tomography (CT) scanning for assessing the resectability with curative intent in pancreatic and periampullary cancer. *Cochrane Database Syst. Rev.* **7**, CD009323 (2016).
53. Fong, Z. V. *et al.* Reappraisal of Staging Laparoscopy for Patients with Pancreatic Adenocarcinoma: A Contemporary Analysis of 1001 Patients. *Ann. Surg. Oncol.* **24**, 3203–3211 (2017).
54. Gaujoux, S. & Allen, P. J. Role of staging laparoscopy in peri-pancreatic and hepatobiliary malignancy. *World J. Gastrointest. Surg.* **2**, 283–290 (2010).
55. Sell, N. M. *et al.* Staging Laparoscopy Not Only Saves Patients an Incision, But May Also Help Them Live Longer. *Ann. Surg. Oncol.* **25**, 1009–1016 (2018).
56. Walters, D. M. *et al.* Pancreas-protocol imaging at a high-volume center leads to improved preoperative staging of pancreatic ductal adenocarcinoma. *Ann. Surg. Oncol.* **18**, 2764–2771 (2011).
57. Padilla-Thornton, A. E., Willmann, J. K. & Jeffrey, R. B. Adenocarcinoma of the uncinate process of the pancreas: MDCT patterns of local invasion and clinical features at presentation. *Eur. Radiol.* **22**, 1067–1074 (2012).

58. Bockhorn, M. *et al.* Borderline resectable pancreatic cancer: a consensus statement by the International Study Group of Pancreatic Surgery (ISGPS). *Surgery* **155**, 977–988 (2014).
59. Delpero, J. R. *et al.* Pancreatic adenocarcinoma with venous involvement: is up-front synchronous portal-superior mesenteric vein resection still justified? A survey of the Association Française de Chirurgie. *Ann. Surg. Oncol.* **22**, 1874–1883 (2015).
60. Katz, M. H. G. *et al.* Preoperative Modified FOLFIRINOX Treatment Followed by Capecitabine-Based Chemoradiation for Borderline Resectable Pancreatic Cancer: Alliance for Clinical Trials in Oncology Trial A021101. *JAMA Surg.* **151**, e161137 (2016).
61. Pietrasz, D. *et al.* Pathologic Major Response After FOLFIRINOX is Prognostic for Patients Secondary Resected for Borderline or Locally Advanced Pancreatic Adenocarcinoma: An AGEO-FRENCH, Prospective, Multicentric Cohort. *Ann. Surg. Oncol.* **22 Suppl 3**, S1196-1205 (2015).
62. Varadhachary, G. R. *et al.* Borderline resectable pancreatic cancer: definitions, management, and role of preoperative therapy. *Ann. Surg. Oncol.* **13**, 1035–1046 (2006).
63. Morganti, A. G. *et al.* A systematic review of resectability and survival after concurrent chemoradiation in primarily unresectable pancreatic cancer. *Ann. Surg. Oncol.* **17**, 194–205 (2010).
64. Rombouts, S. J. *et al.* Systematic Review of Resection Rates and Clinical Outcomes After FOLFIRINOX-Based Treatment in Patients with Locally Advanced Pancreatic Cancer. *Ann. Surg. Oncol.* **23**, 4352–4360 (2016).
65. Hackert, T. *et al.* Locally Advanced Pancreatic Cancer: Neoadjuvant Therapy With Folfirinox Results in Resectability in 60% of the Patients. *Ann. Surg.* **264**, 457–463 (2016).
66. van der Gaag, N. A. *et al.* Preoperative biliary drainage for cancer of the head of the pancreas. *N. Engl. J. Med.* **362**, 129–137 (2010).
67. Sauvanet, A. *et al.* Severe Jaundice Increases Early Severe Morbidity and Decreases Long-Term Survival after Pancreaticoduodenectomy for Pancreatic Adenocarcinoma. *J. Am. Coll. Surg.* **221**, 380–389 (2015).
68. Iacono, C. *et al.* Role of preoperative biliary drainage in jaundiced patients who are candidates for pancreatoduodenectomy or hepatic resection: highlights and drawbacks. *Ann. Surg.* **257**, 191–204 (2013).
69. Sun, C., Yan, G., Li, Z. & Tzeng, C.-M. A meta-analysis of the effect of preoperative biliary stenting on patients with obstructive jaundice. *Medicine (Baltimore)* **93**, e189 (2014).
70. Crippa, S. *et al.* Systematic review and meta-analysis of metal versus plastic stents for preoperative biliary drainage in resectable periampullary or pancreatic head tumors. *Eur. J. Surg. Oncol. J. Eur. Soc. Surg. Oncol. Br. Assoc. Surg. Oncol.* **42**, 1278–1285 (2016).
71. Tol, J. a. M. G. *et al.* Metal or plastic stents for preoperative biliary drainage in resectable pancreatic cancer. *Gut* **65**, 1981–1987 (2016).
72. Eshuis, W. J. *et al.* Therapeutic delay and survival after surgery for cancer of the pancreatic head with or without preoperative biliary drainage. *Ann. Surg.* **252**, 840–849 (2010).

73. La Torre, M. *et al.* Malnutrition and pancreatic surgery: prevalence and outcomes. *J. Surg. Oncol.* **107**, 702–708 (2013).
74. Kuzu, M. A. *et al.* Preoperative nutritional risk assessment in predicting postoperative outcome in patients undergoing major surgery. *World J. Surg.* **30**, 378–390 (2006).
75. Shinkawa, H. *et al.* Nutritional risk index as an independent predictive factor for the development of surgical site infection after pancreaticoduodenectomy. *Surg. Today* **43**, 276–283 (2013).
76. Kelley, K. E. *et al.* Impact of a Novel Preoperative Patient-Centered Surgical Wellness Program. *Ann. Surg.* (2018). doi:10.1097/SLA.0000000000002932
77. Kim, E. *et al.* Influence of preoperative nutritional status on clinical outcomes after pancreatoduodenectomy. *HPB* (2018). doi:10.1016/j.hpb.2018.05.004
78. Sierzega, M., Niekowal, B., Kulig, J. & Popiela, T. Nutritional status affects the rate of pancreatic fistula after distal pancreatectomy: a multivariate analysis of 132 patients. *J. Am. Coll. Surg.* **205**, 52–59 (2007).
79. Probst, P. *et al.* Prospective trial to evaluate the prognostic value of different nutritional assessment scores in pancreatic surgery (NURIMAS Pancreas). *Br. J. Surg.* **104**, 1053–1062 (2017).
80. Gianotti, L. *et al.* Nutritional support and therapy in pancreatic surgery: A position paper of the International Study Group on Pancreatic Surgery (ISGPS). *Surgery* (2018). doi:10.1016/j.surg.2018.05.040
81. Bozzetti, F., Gianotti, L., Braga, M., Di Carlo, V. & Mariani, L. Postoperative complications in gastrointestinal cancer patients: the joint role of the nutritional status and the nutritional support. *Clin. Nutr. Edinb. Scotl.* **26**, 698–709 (2007).
82. Silvestri, S. *et al.* Preoperative oral immunonutrition versus standard preoperative oral diet in well nourished patients undergoing pancreaticoduodenectomy. *Int. J. Surg. Lond. Engl.* **31**, 93–99 (2016).
83. Weimann, A. *et al.* ESPEN Guidelines on Enteral Nutrition: Surgery including organ transplantation. *Clin. Nutr. Edinb. Scotl.* **25**, 224–244 (2006).
84. Imamura, M. *et al.* A randomized multicenter trial comparing resection and radiochemotherapy for resectable locally invasive pancreatic cancer. *Surgery* **136**, 1003–1011 (2004).
85. Hartwig, W., Werner, J., Jäger, D., Debus, J. & Büchler, M. W. Improvement of surgical results for pancreatic cancer. *Lancet Oncol.* **14**, e476–e485 (2013).
86. Oettle, H. *et al.* Adjuvant chemotherapy with gemcitabine and long-term outcomes among patients with resected pancreatic cancer: the CONKO-001 randomized trial. *JAMA* **310**, 1473–1481 (2013).
87. Neoptolemos, J. P. *et al.* Comparison of adjuvant gemcitabine and capecitabine with gemcitabine monotherapy in patients with resected pancreatic cancer (ESPAC-4): a multicentre, open-label, randomised, phase 3 trial. *Lancet Lond. Engl.* **389**, 1011–1024 (2017).

88. Krautz, C., Nimptsch, U., Weber, G. F., Mansky, T. & Grützmann, R. Effect of Hospital Volume on In-hospital Morbidity and Mortality Following Pancreatic Surgery in Germany. *Ann. Surg.* **267**, 411–417 (2018).
89. Delpero, J. R. *et al.* Pancreaticoduodenectomy for pancreatic ductal adenocarcinoma: a French multicentre prospective evaluation of resection margins in 150 evaluable specimens. *HPB* **16**, 20–33 (2014).
90. Epstein, J. D. *et al.* Microscopic lymphovascular invasion is an independent predictor of survival in resected pancreatic ductal adenocarcinoma. *J. Surg. Oncol.* **116**, 658–664 (2017).
91. Schorn, S. *et al.* The influence of neural invasion on survival and tumor recurrence in pancreatic ductal adenocarcinoma - A systematic review and meta-analysis. *Surg. Oncol.* **26**, 105–115 (2017).
92. Distler, M. *et al.* Evaluation of survival in patients after pancreatic head resection for ductal adenocarcinoma. *BMC Surg.* **13**, 12 (2013).
93. Rau, B. M. *et al.* R1 resection in pancreatic cancer has significant impact on long-term outcome in standardized pathology modified for routine use. *Surgery* **152**, S103-111 (2012).
94. Westgaard, A. *et al.* Resectable adenocarcinomas in the pancreatic head: the retroperitoneal resection margin is an independent prognostic factor. *BMC Cancer* **8**, 5 (2008).
95. Raut, C. P. *et al.* Impact of resection status on pattern of failure and survival after pancreaticoduodenectomy for pancreatic adenocarcinoma. *Ann. Surg.* **246**, 52–60 (2007).
96. Janot, M. S. *et al.* Can the new RCP R0/R1 classification predict the clinical outcome in ductal adenocarcinoma of the pancreatic head? *Langenbecks Arch. Surg.* **397**, 917–925 (2012).
97. Neoptolemos, J. P. *et al.* Influence of resection margins on survival for patients with pancreatic cancer treated by adjuvant chemoradiation and/or chemotherapy in the ESPAC-1 randomized controlled trial. *Ann. Surg.* **234**, 758–768 (2001).
98. Chandrasegaram, M. D. *et al.* Meta-analysis of radical resection rates and margin assessment in pancreatic cancer. *Br. J. Surg.* **102**, 1459–1472 (2015).
99. Verbeke, C. S. Resection margins in pancreatic cancer. *Surg. Clin. North Am.* **93**, 647–662 (2013).
100. Esposito, I. *et al.* Most pancreatic cancer resections are R1 resections. *Ann. Surg. Oncol.* **15**, 1651–1660 (2008).
101. Delpero, J. R. *et al.* Prognostic Value of Resection Margin Involvement After Pancreaticoduodenectomy for Ductal Adenocarcinoma: Updates From a French Prospective Multicenter Study. *Ann. Surg.* **266**, 787–796 (2017).
102. Tran, K. T. C. *et al.* Pylorus preserving pancreaticoduodenectomy versus standard Whipple procedure: a prospective, randomized, multicenter analysis of 170 patients with pancreatic and periampullary tumors. *Ann. Surg.* **240**, 738–745 (2004).
103. Diener, M. K. *et al.* Pylorus-preserving pancreaticoduodenectomy (pp Whipple) versus

- pancreaticoduodenectomy (classic Whipple) for surgical treatment of periampullary and pancreatic carcinoma. *Cochrane Database Syst. Rev.* CD006053 (2014). doi:10.1002/14651858.CD006053.pub5
104. Slidell, M. B. *et al.* Impact of total lymph node count and lymph node ratio on staging and survival after pancreatectomy for pancreatic adenocarcinoma: a large, population-based analysis. *Ann. Surg. Oncol.* **15**, 165–174 (2008).
105. Jang, J.-Y. *et al.* A prospective randomized controlled study comparing outcomes of standard resection and extended resection, including dissection of the nerve plexus and various lymph nodes, in patients with pancreatic head cancer. *Ann. Surg.* **259**, 656–664 (2014).
106. Farnell, M. B. *et al.* A prospective randomized trial comparing standard pancreatoduodenectomy with pancreatoduodenectomy with extended lymphadenectomy in resectable pancreatic head adenocarcinoma. *Surgery* **138**, 618–628; discussion 628–630 (2005).
107. Pedrazzoli, S. *et al.* Standard versus extended lymphadenectomy associated with pancreatoduodenectomy in the surgical treatment of adenocarcinoma of the head of the pancreas: a multicenter, prospective, randomized study. Lymphadenectomy Study Group. *Ann. Surg.* **228**, 508–517 (1998).
108. Nimura, Y. *et al.* Standard versus extended lymphadenectomy in radical pancreatoduodenectomy for ductal adenocarcinoma of the head of the pancreas: long-term results of a Japanese multicenter randomized controlled trial. *J. Hepato-Biliary-Pancreat. Sci.* **19**, 230–241 (2012).
109. Yeo, C. J. *et al.* Pancreaticoduodenectomy with or without distal gastrectomy and extended retroperitoneal lymphadenectomy for periampullary adenocarcinoma, part 2: randomized controlled trial evaluating survival, morbidity, and mortality. *Ann. Surg.* **236**, 355–366; discussion 366–368 (2002).
110. Komo, T. *et al.* Prognostic Impact of Para-Aortic Lymph Node Micrometastasis in Pancreatic Ductal Adenocarcinoma. *Ann. Surg. Oncol.* **23**, 2019–2027 (2016).
111. Paiella, S. *et al.* The prognostic impact of para-aortic lymph node metastasis in pancreatic cancer: A systematic review and meta-analysis. *Eur. J. Surg. Oncol. J. Eur. Soc. Surg. Oncol. Br. Assoc. Surg. Oncol.* **42**, 616–624 (2016).
112. Schwarz, L. *et al.* Para-aortic lymph node sampling in pancreatic head adenocarcinoma. *Br. J. Surg.* **101**, 530–538 (2014).
113. Gaedcke, J. *et al.* The mesopancreas is the primary site for R1 resection in pancreatic head cancer: relevance for clinical trials. *Langenbecks Arch. Surg.* **395**, 451–458 (2010).
114. Ogiso, S., Conrad, C., Araki, K., Basso, V. & Gayet, B. Posterior approach for laparoscopic pancreaticoduodenectomy to prevent replaced hepatic artery injury. *Ann. Surg. Oncol.* **20**, 3120 (2013).
115. Dumitrascu, T., David, L. & Popescu, I. Posterior versus standard approach in pancreatoduodenectomy: a case-match study. *Langenbecks Arch. Surg.* **395**, 677–684 (2010).

116. Weitz, J., Rahbari, N., Koch, M. & Büchler, M. W. The 'artery first' approach for resection of pancreatic head cancer. *J. Am. Coll. Surg.* **210**, e1-4 (2010).
117. Capussotti, L. *et al.* Extended lymphadenectomy and vein resection for pancreatic head cancer: outcomes and implications for therapy. *Arch. Surg. Chic. Ill 1960* **138**, 1316–1322 (2003).
118. Bachellier, P. *et al.* Is pancreaticoduodenectomy with mesentericoportal venous resection safe and worthwhile? *Am. J. Surg.* **182**, 120–129 (2001).
119. Tseng, J. F. *et al.* Pancreaticoduodenectomy with vascular resection: margin status and survival duration. *J. Gastrointest. Surg. Off. J. Soc. Surg. Aliment. Tract* **8**, 935–949; discussion 949–950 (2004).
120. Zhou, Y., Zhang, Z., Liu, Y., Li, B. & Xu, D. Pancreatectomy combined with superior mesenteric vein-portal vein resection for pancreatic cancer: a meta-analysis. *World J. Surg.* **36**, 884–891 (2012).
121. Chua, T. C. & Saxena, A. Extended pancreaticoduodenectomy with vascular resection for pancreatic cancer: a systematic review. *J. Gastrointest. Surg. Off. J. Soc. Surg. Aliment. Tract* **14**, 1442–1452 (2010).
122. Yekebas, E. F. *et al.* En bloc vascular resection for locally advanced pancreatic malignancies infiltrating major blood vessels: perioperative outcome and long-term survival in 136 patients. *Ann. Surg.* **247**, 300–309 (2008).
123. Bockhorn, M. *et al.* Borderline resectable pancreatic cancer: a consensus statement by the International Study Group of Pancreatic Surgery (ISGPS). *Surgery* **155**, 977–988 (2014).
124. Jegatheeswaran, S., Baltatzis, M., Jamdar, S. & Siriwardena, A. K. Superior mesenteric artery (SMA) resection during pancreatectomy for malignant disease of the pancreas: a systematic review. *HPB* **19**, 483–490 (2017).
125. Mollberg, N. *et al.* Arterial resection during pancreatectomy for pancreatic cancer: a systematic review and meta-analysis. *Ann. Surg.* **254**, 882–893 (2011).
126. Bachellier, P., Addeo, P., Faitot, F., Nappo, G. & Dufour, P. Pancreatectomy With Arterial Resection for Pancreatic Adenocarcinoma: How Can It Be Done Safely and With Which Outcomes?: A Single Institution's Experience With 118 Patients. *Ann. Surg.* (2018).
doi:10.1097/SLA.0000000000003010
127. Bassi, C. *et al.* Reconstruction by pancreaticojejunostomy versus pancreaticogastrostomy following pancreatectomy: results of a comparative study. *Ann. Surg.* **242**, 767–771, discussion 771–773 (2005).
128. Figueras, J. *et al.* Randomized clinical trial of pancreaticogastrostomy versus pancreaticojejunostomy on the rate and severity of pancreatic fistula after pancreaticoduodenectomy. *Br. J. Surg.* **100**, 1597–1605 (2013).
129. Cheng, Y. *et al.* Pancreaticojejunostomy versus pancreaticogastrostomy reconstruction for the prevention of postoperative pancreatic fistula following pancreaticoduodenectomy. *Cochrane*

Database Syst. Rev. **9**, CD012257 (2017).

130. Keck, T. *et al.* Pancreatogastrostomy Versus Pancreatojejunostomy for RECONstruction After PANCreatoduodenectomy (RECOPANC, DRKS 00000767): Perioperative and Long-term Results of a Multicenter Randomized Controlled Trial. *Ann. Surg.* **263**, 440–449 (2016).
131. Topal, B. *et al.* Pancreaticojejunostomy versus pancreaticogastrostomy reconstruction after pancreaticoduodenectomy for pancreatic or periampullary tumours: a multicentre randomised trial. *Lancet Oncol.* **14**, 655–662 (2013).
132. Shrikhande, S. V., Barreto, G. & Shukla, P. J. Pancreatic fistula after pancreaticoduodenectomy: the impact of a standardized technique of pancreaticojejunostomy. *Langenbecks Arch. Surg.* **393**, 87–91 (2008).
133. Motoi, F., Egawa, S., Rikiyama, T., Katayose, Y. & Unno, M. Randomized clinical trial of external stent drainage of the pancreatic duct to reduce postoperative pancreatic fistula after pancreaticojejunostomy. *Br. J. Surg.* **99**, 524–531 (2012).
134. Pessaux, P. *et al.* External pancreatic duct stent decreases pancreatic fistula rate after pancreaticoduodenectomy: prospective multicenter randomized trial. *Ann. Surg.* **253**, 879–885 (2011).
135. Gurusamy, K. S., Koti, R., Fusai, G. & Davidson, B. R. Somatostatin analogues for pancreatic surgery. *Cochrane Database Syst. Rev.* CD008370 (2013). doi:10.1002/14651858.CD008370.pub3
136. Koti, R. S., Gurusamy, K. S., Fusai, G. & Davidson, B. R. Meta-analysis of randomized controlled trials on the effectiveness of somatostatin analogues for pancreatic surgery: a Cochrane review. *HPB* **12**, 155–165 (2010).
137. Van Buren, G. *et al.* A randomized prospective multicenter trial of pancreaticoduodenectomy with and without routine intraperitoneal drainage. *Ann. Surg.* **259**, 605–612 (2014).
138. Villafane-Ferriol, N. *et al.* Evidence-Based Management of Drains Following Pancreatic Resection: A Systematic Review. *Pancreas* **47**, 12–17 (2018).
139. McMillan, M. T. *et al.* Multicenter, Prospective Trial of Selective Drain Management for Pancreatoduodenectomy Using Risk Stratification. *Ann. Surg.* **265**, 1209–1218 (2017).
140. Verbeke, C. S. *et al.* Redefining the R1 resection in pancreatic cancer. *Br. J. Surg.* **93**, 1232–1237 (2006).
141. Strobel, O. *et al.* Pancreatic Cancer Surgery: The New R-status Counts. *Ann. Surg.* **265**, 565–573 (2017).
142. Feakins, R., Campbell, F. & Verbeke, C. S. Survey of UK histopathologists' approach to the reporting of resection specimens for carcinomas of the pancreatic head. *J. Clin. Pathol.* **66**, 715–717 (2013).
143. de Rooij, T. *et al.* Minimally invasive versus open pancreaticoduodenectomy (LEOPARD-2): study protocol for a randomized controlled trial. *Trials* **19**, 1 (2018).
144. Tol, J. A. M. G. *et al.* Definition of a standard lymphadenectomy in surgery for pancreatic ductal adenocarcinoma: a consensus statement by the International Study Group on Pancreatic Surgery

(ISGPS). *Surgery* **156**, 591–600 (2014).

145. Fernández-Cruz, L., Johnson, C. & Dervenis, C. Locoregional dissemination and extended lymphadenectomy in pancreatic cancer. *Dig. Surg.* **16**, 313–319 (1999).

146. Faron, M. *et al.* How to Reliably Assess Nodal Status in Distal Pancreatectomy for Adenocarcinoma. *Pancreas* **47**, 308–313 (2018).

147. Malleo, G. *et al.* Number of Examined Lymph Nodes and Nodal Status Assessment in Distal Pancreatectomy for Body/Tail Ductal Adenocarcinoma. *Ann. Surg.* (2018).

doi:10.1097/SLA.0000000000002781

148. Mitchem, J. B. *et al.* Long-term results of resection of adenocarcinoma of the body and tail of the pancreas using radical antegrade modular pancreatosplenectomy procedure. *J. Am. Coll. Surg.* **214**, 46–52 (2012).

149. Abe, T. *et al.* Comparison of Surgical Outcomes Between Radical Antegrade Modular Pancreatosplenectomy (RAMPS) and Standard Retrograde Pancreatosplenectomy (SPRS) for Left-Sided Pancreatic Cancer. *World J. Surg.* **40**, 2267–2275 (2016).

150. Chang, Y. R. *et al.* Surgical outcome of pancreatic cancer using radical antegrade modular pancreatosplenectomy procedure. *World J. Gastroenterol.* **18**, 5595–5600 (2012).

151. Zhou, Y., Shi, B., Wu, L. & Si, X. A systematic review of radical antegrade modular pancreatosplenectomy for adenocarcinoma of the body and tail of the pancreas. *HPB* **19**, 10–15 (2017).

152. Knaebel, H. P., Diener, M. K., Wente, M. N., Büchler, M. W. & Seiler, C. M. Systematic review and meta-analysis of technique for closure of the pancreatic remnant after distal pancreatectomy. *Br. J. Surg.* **92**, 539–546 (2005).

153. Diener, M. K. *et al.* Efficacy of stapler versus hand-sewn closure after distal pancreatectomy (DISPACT): a randomised, controlled multicentre trial. *Lancet Lond. Engl.* **377**, 1514–1522 (2011).

154. Frozanpor, F., Lundell, L., Segersvärd, R. & Arnelo, U. The effect of prophylactic transpapillary pancreatic stent insertion on clinically significant leak rate following distal pancreatectomy: results of a prospective controlled clinical trial. *Ann. Surg.* **255**, 1032–1036 (2012).

155. Riviere, D. *et al.* Laparoscopic versus open distal pancreatectomy for pancreatic cancer. *Cochrane Database Syst. Rev.* **4**, CD011391 (2016).

156. Røsok, B. I. *et al.* Minimally invasive distal pancreatectomy. *HPB* **19**, 205–214 (2017).

157. de Rooij, T. *et al.* Minimally Invasive Versus Open Distal Pancreatectomy (LEOPARD): A Multicenter Patient-blinded Randomized Controlled Trial. *Ann. Surg.* (2018).

doi:10.1097/SLA.0000000000002979

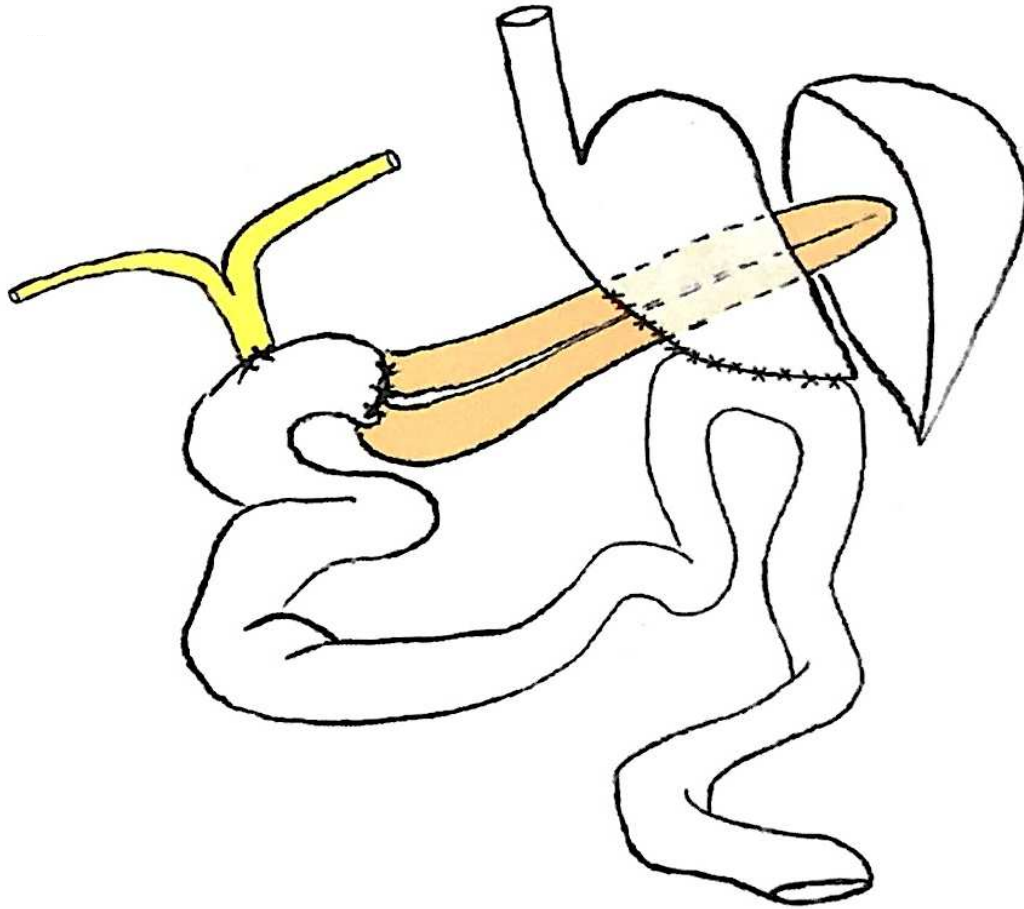
158. Kooby, D. A. *et al.* A multicenter analysis of distal pancreatectomy for adenocarcinoma: is laparoscopic resection appropriate? *J. Am. Coll. Surg.* **210**, 779–785, 786–787 (2010).

159. van Hilst, J. *et al.* Minimally Invasive versus Open Distal Pancreatectomy for Ductal Adenocarcinoma (DIPLOMA): A Pan-European Propensity Score Matched Study. *Ann. Surg.* (2017).

doi:10.1097/SLA.0000000000002561

160. Bassi, C. *et al.* Postoperative pancreatic fistula: an international study group (ISGPF) definition. *Surgery* **138**, 8–13 (2005).
161. Joseph, B. *et al.* Relationship between hospital volume, system clinical resources, and mortality in pancreatic resection. *J. Am. Coll. Surg.* **208**, 520–527 (2009).
162. Sohn, T. A. *et al.* Pancreaticoduodenectomy: role of interventional radiologists in managing patients and complications. *J. Gastrointest. Surg. Off. J. Soc. Surg. Aliment. Tract* **7**, 209–219 (2003).
163. Dai, J., Jiang, Y. & Fu, D. Reducing postoperative complications and improving clinical outcome: Enhanced recovery after surgery in pancreaticoduodenectomy - A retrospective cohort study. *Int. J. Surg. Lond. Engl.* **39**, 176–181 (2017).
164. Perinel, J. & Adham, M. ERAS and pancreatic surgery: a review. *Updat. Surg.* **68**, 253–255 (2016).
165. Perinel, J. *et al.* Early Enteral Versus Total Parenteral Nutrition in Patients Undergoing Pancreaticoduodenectomy: A Randomized Multicenter Controlled Trial (Nutri-DPC). *Ann. Surg.* **264**, 731–737 (2016).

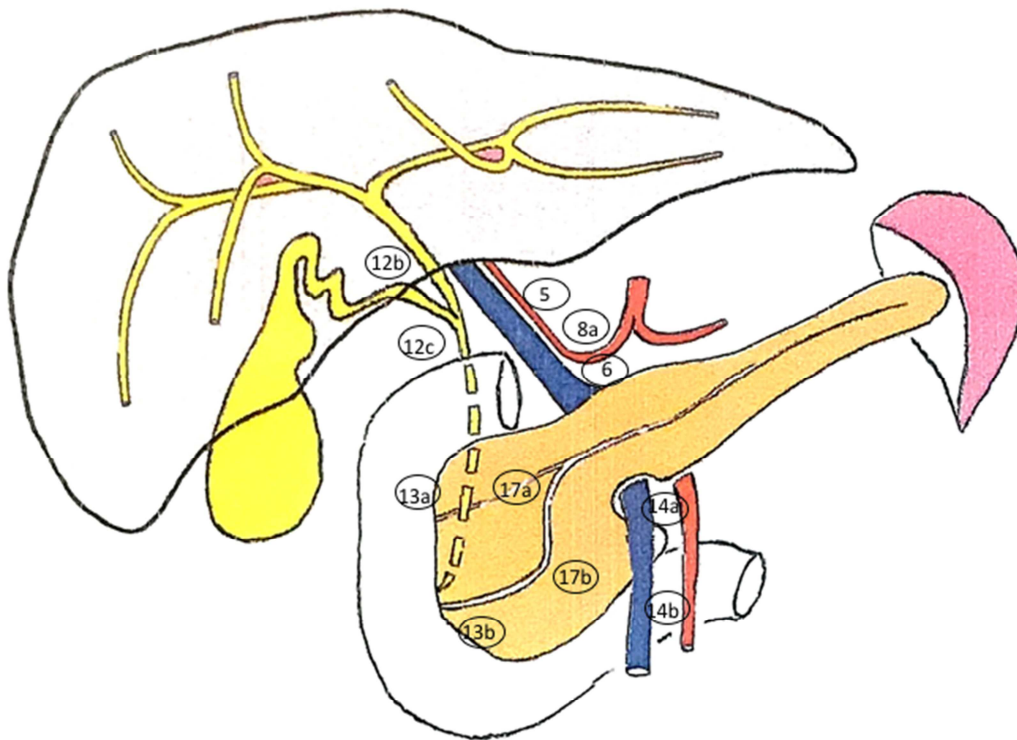
Figure 1: Reconstruction after Whipple procedure.



adapted from Dr Jacques Taboury

3 anastomosis: 1) Pancreaticojejunostomy 2) Hepaticojejunostomy 3) Gastrojejunostomy.

Figure 2 : Lymphadenectomy during pancreaticoduodenectomy.

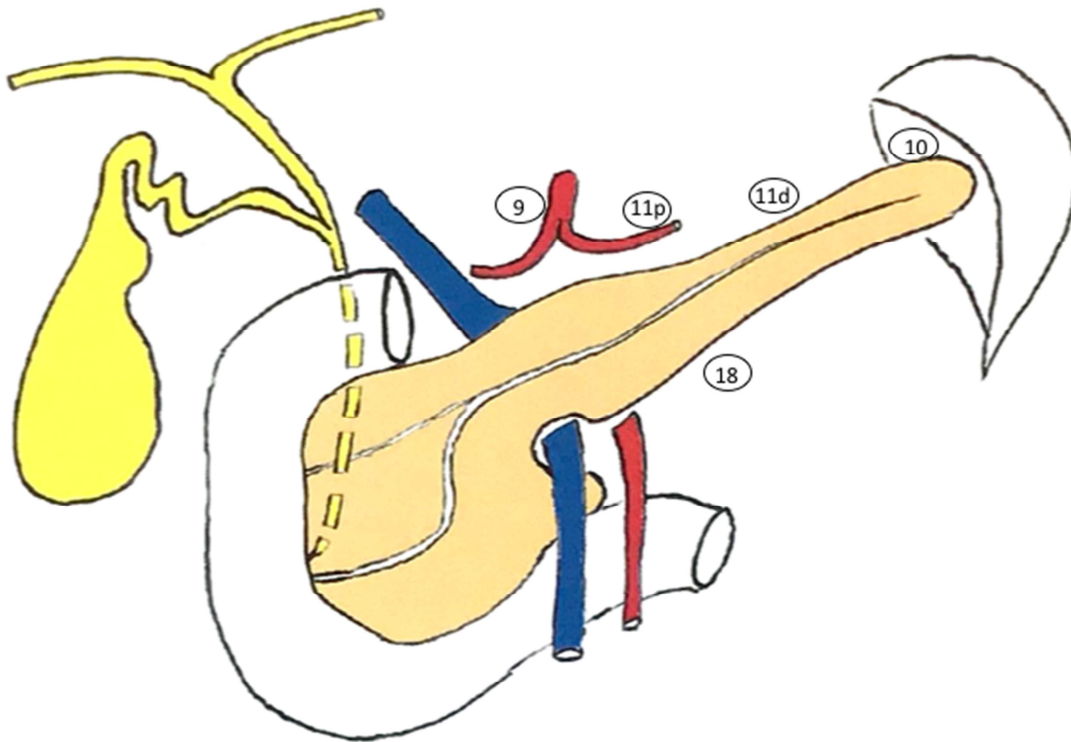


adapted from Dr Jacques Taboury

Standard lymphadenectomy should include the following Lymph Node stations:

5 (suprapyloric) ,6 (infrapyloric), 8a (common hepatic artery), 12b-c (along the bile duct and cystic duct), 13a-b (along the head of the pancreas), 14a-b (along the right lateral side of superior mesenteric artery), 17a-b (along the anterior face of the head of the pancreas).

Figure 3 : Lymphadenectomy during pancreateosplenectomy.



adapted from Dr Jacques Taboury

Standard lymphadenectomy during distal pancreatectomy should include at least:

LN located in the hilum of the spleen (LN station 10), along the splenic artery (LN station 11) and along the inferior border of the body and tail of the pancreas (LN station 18).

Table 1: The National Comprehensive Cancer Network classification (*version 2017*).

Resecability criteria	Arterial contact	Venous contact
Resectable	<ul style="list-style-type: none"> No arterial contact (CA/SMA/CHA) 	<ul style="list-style-type: none"> No tumor contact with SMV or PV $\leq 180^\circ$ without vein contour irregularity
Borderline	<p><u>Pancreatic head/uncinated process:</u></p> <ul style="list-style-type: none"> Contact with CHA without extension to the CA or hepatic artery bifurcation allowing R0 resection Contact with SMA $\leq 180^\circ$ Contact with variant arterial anatomy (right hepatic artery/replaced CHA/...) <p><u>Pancreatic body/Tail:</u></p> <ul style="list-style-type: none"> Contact with the CA $\leq 180^\circ$ Contact with CA $>180^\circ$ without involvement of the aorta, gastroduodenal artery permitting a modified Appleby procedure (resection of the CA after CHA embolization) 	<ul style="list-style-type: none"> Contact with SMV or PV $>180^\circ$ with contour irregularity of the vein or thrombosis permitting safe and R0 resection. Contact with the IVC
Unresectable	<p><u>Head/uncinated process:</u></p> <ul style="list-style-type: none"> Contact with SMA $>180^\circ$ Contact with the CA $>180^\circ$ Contact with the 1st jejunal SMA branch <p><u>Body and tail:</u></p> <ul style="list-style-type: none"> Contact with SMA or CA $>180^\circ$ Aortic involvement <p>Or</p> <ul style="list-style-type: none"> Distant metastasis 	<p><u>Head/uncinated process:</u></p> <ul style="list-style-type: none"> Unreconstructible SMV/PV due to tumor involvement or occlusion Contact with proximal jejunal branch <p><u>Body and tail:</u></p> <ul style="list-style-type: none"> Unreconstructible SMV/PV due to tumor involvement or occlusion

CA: coeliac artery / SMA: superior mesenteric artery / CHA: common hepatic artery/ SMV: superior mesenteric vein / PV: portal vein / IVC: inferior vena cava.