



HAL
open science

Anatomo-functional study of the cerebellum in working memory in children treated for medulloblastoma

Duc Ha Hoang, Anne Pagnier, Emilie Cousin, Karine Guichardet, Isabelle Schiff, Celine Icher, Bixente Dilharreguy, Jacques Grill, Didier Frappaz, Claire Berger, et al.

► To cite this version:

Duc Ha Hoang, Anne Pagnier, Emilie Cousin, Karine Guichardet, Isabelle Schiff, et al.. Anatomo-functional study of the cerebellum in working memory in children treated for medulloblastoma. Journal de Neuroradiologie / Journal of Neuroradiology, 2019, 46, pp.207 - 213. 10.1016/j.neurad.2019.01.093 . hal-03485995

HAL Id: hal-03485995

<https://hal.science/hal-03485995>

Submitted on 20 Dec 2021

HAL is a multi-disciplinary open access archive for the deposit and dissemination of scientific research documents, whether they are published or not. The documents may come from teaching and research institutions in France or abroad, or from public or private research centers.

L'archive ouverte pluridisciplinaire **HAL**, est destinée au dépôt et à la diffusion de documents scientifiques de niveau recherche, publiés ou non, émanant des établissements d'enseignement et de recherche français ou étrangers, des laboratoires publics ou privés.



Distributed under a Creative Commons Attribution - NonCommercial 4.0 International License

Anatomo-functional study of the cerebellum in working memory in children treated for medulloblastoma

Duc Ha Hoang^{1,2,3}, Anne Pagnier⁴, Emilie Cousin^{5,6}, Karine Guichardet⁴, Isabelle Schiff⁴, Celine Icher⁷, Bixente Dilharreguy⁸, Jacques Grill⁹, Didier Frappaz¹⁰, Claire Berger¹¹, Fabien Schneider¹², Fanny Dubois-Teklali⁴, Alexandre Krainik^{1,2,5,7*}

¹Grenoble Institute of Neurosciences, INSERM U836, Grenoble, France

²University Grenoble Alps, Grenoble, France

³Department of Radiology, Viettiep University Hospital, Haiphong, Vietnam

⁴Department of Pediatrics, Grenoble University Hospital, Grenoble, France

⁵UMS IRMaGe, Grenoble, France

⁶Laboratory of Psychology and Neurocognition, University Pierre Mendès, Grenoble, France

⁷Department of Pediatrics, Bordeaux University Hospital, Bordeaux, France

⁸Institute of Neuroscience, UMR 5287, Bordeaux, France

⁹Department of Pediatrics, Gustave Roussy Institute, Villejuif, France

¹⁰Institute of Pediatrics Haematology and Oncology, Lyon, France

¹¹Department of Pediatrics, Saint-Etienne University Hospital, Saint-Etienne, France

¹²Department of Neuroradiology, Saint-Etienne University Hospital, Saint-Etienne, France

¹³Department of Neuroradiology and MRI, Grenoble University Hospital, Grenoble, France

*** Corresponding Author:**

Alexandre Krainik, MD, PhD

Department of Neuroradiology and MRI

University Hospital of Grenoble – CS 10217

38043 Grenoble, France

Email: akrainik@chu-grenoble.fr

Number of words: 3103

Number of tables: 1

Number of figures: 4

Supplemental data: 1

Abstract

Introduction: Medulloblastoma is the most common malignant cerebral tumor during childhood, arising in the posterior fossa. Children treated for medulloblastoma often experience working memory (WM) deficits, affecting their quality of life and school performance. The aim of the present study undertaken to describe the cerebellar involvement in WM deficits observed in these children.

Material and Methods: 23 healthy children and 11 children treated for medulloblastoma were included into study. All subjects performed a detailed neuropsychological examination, an anatomical and functional MRI. Stimuli were presented to the participants with alternating sensory modality and nature of communication in a block design during functional magnetic resonance imaging acquisitions. Non parametric tests were used for analyzing neuropsychological and behavioral data. SPM8 and SUI (Spatially Unbiased Atlas Template) were used for anatomical and functional MRI data analyses.

Results: Patients had cerebellar resections mainly located in the left posterior lobe. Patients had significantly reduced intelligence quotient, central executive and visuospatial WM. In healthy children group, fMRI showed activations for nonverbal and visuospatial WM in the left posterior cerebellar lobe.

Conclusion: this study provides further evidence that left posterior cerebellar lobe plays a critical role in WM. Indeed, lesions of left posterior cerebellar lobe were associated with WM impairment in children treated for cerebellar medulloblastoma. Additionally, fMRI using WM tasks showed activation in the left posterior cerebellar lobe in healthy children. Taken together, these findings may help for improving treatment and rehabilitation of children referred for cerebellar tumor.

Keywords: Working Memory; Children; Functional MRI; Cerebellum; Medulloblastoma.

Abstract word count: 241

INTRODUCTION

The cerebellum has been traditionally considered to play an important role in motor control, physical coordination and balance. Recently, the role of the cerebellum in a wide range of cognitive function such as language, executive functions, and working memory is increasingly evidenced by neuropsychological data, anatomical and functional imaging (Hoang et al., 2014). Evidence for cerebellar involvement in verbal working memory was largely reported (Marvel and Desmond, 2010). However, the role of the cerebellum in visuospatial working memory is not well known. In 1998, Schmahmann and Sherman published for the first time a concept involving the cerebellar cognitive affective syndrome due to lesions of the cerebellar posterior lobe (Schmahmann and Sherman, 1998). This syndrome is clinically characterized by neurological deficits, involving executive function, linguistic processing, regulation of affect, and visuospatial performance. Several recent studies suggested the engagement of the cerebellum in spatial processing, visuospatial memory and a potential lateralization of the left cerebellar side in these functions (O'Halloran et al., 2012) (Tomlinson et al., 2014). Benefiting the advantages of fMRI, we hope to further elucidate the relationship between the cerebellum and visuospatial working memory.

In children treated for a cerebellar medulloblastoma, the survivors frequently present cognitive disorders, including working memory impairment (Knight et al., 2014). Working memory is a cognitive system providing flexible temporary storage of information that is vital for daily cognitive activities such as learning new words, memorizing a phone number or planning actions. The most highly influential working memory model is the tripartite model, which consists in 3 components: the central administrator, the phonological loop, and the visuospatial sketchpad (Baddeley and Hitch, 1974). Recent fMRI studies suggested that the right cerebellar hemisphere seems to be involved into the phonological loop (Thürling et al., 2012) (van den

Bosch et al., 2012), while the left cerebellar hemisphere is suspected to be involved into the visuo-spatial sketchpad (Stoodley, 2012). However, specific contributions of the cerebellum to high cognitive function, especially working memory performance, remain debate. To further identify functional cerebellar areas in verbal and non-verbal working memory and auditory and visual working memory, we conducted a detailed neuropsychological examination and fMRI studies using n-back tasks in healthy children and in children treated for a cerebellar medulloblastoma.

MATERIAL and METHODS

Participant inclusion

A multicenter study was conducted during six years (2008-2014) in the University Hospitals of Grenoble, Lyon, Saint-Etienne, Bordeaux, the Gustave Roussy's and the Curie's Institutes in France. To be compared with patients, healthy age-matched children were recruited via advertisement throughout the medical centers announcements. All participants satisfied the inclusion criteria in Table 1.

(“Table 1 about here”)

All of the children's parents/legal guardians provided informed written consent. The study has been approved by the local ethic committee (number: 2007-A00516-47).

Neuropsychological Assessment

The patients and controls received a detailed neuropsychological testing. It included an assessment of intellectual efficiency and of working memory by tests that had been calibrated in a French population of the same age. The overall assessment consisted of: memory by Wechsler Intelligence Scale for Children (WISC IV), French version (Wechsler, 2005); attention by Trail-Making-Test (Spreeen and Strauss, 1998) and working memory battery by D'Albo working memory procedure, French version (D'albo et al., 1998). These tests had to be performed within two months before the MRI.

Imaging

Experimental fMRI tasks

We conducted two fMRI studies while the participants performed n-back tasks using a 2x2 factorial scheme, to contrast 2 different sensorial cues (visual vs. auditory) and 2 different type

of information (verbal vs. non-verbal) to be memorized. Thus, 4 experimental tasks were conducted including auditory verbal (AUVE), auditory non-verbal (AUNV), visual verbal (VIVE), and visual non-verbal (VINV). Visual tasks were words (verbal) or spatial patterns (nonverbal). Auditory tasks were words (verbal) or sounds (nonverbal). Tasks were randomly presented across subjects.

Participants were required to determine whether the presented cue was identical to the previous one (n-1 back), or to the stimulus before the previous one (n-2 back). These stimuli were displayed using a block-designed paradigm and recorded by using E-prime software (E-prime Psychology Software Tools Inc., Pittsburgh, USA). The answers (accuracy and reaction time) were recorded using MR response grips (NordicNeuroLab, Bergen, Norway).

fMRI Acquisition

The n-1 back experiment was performed on a 1.5T Philips Achieva MRI scanner. The n-2 back experiment was performed on a 3T Philips Achieva TX MRI scanner. Both experiments were conducted using a 8-channels head coil.

fMRI was performed using gradient-echo/T2* echo planar imaging. Image acquisition was repeated every 5 seconds. Images were acquired during the first 3 seconds of each dynamic, leaving 2 silent seconds for auditory and visual cues exposure.

At 1.5 Tesla: 32 adjacent axial slices parallel to the bi-commissural plane were acquired in interleaved mode; TR=5s; TE=50ms; flip angle=90°; number of dynamics=56; voxel size=4×4×4 mm; slice thickness=4 mm; field of view=256 mm.

At 3 Tesla: 52 adjacent axial slices parallel to the bi-commissural plane were acquired in interleaved mode; TR=5s; TE=30ms; flip angle=90°; number of dynamics=50; voxel size=2.5×2.5×2 mm; slice thickness=2.5 mm; field of view=220 mm.

Anatomical Image Acquisition: a T1-weighted high-resolution three-dimensional anatomical volume was acquired using a 3D gradient echo inversion recovery sequence (field of view=256 mm and resolution=1×1×1 mm). These parameters allowed coverage of the whole brain including the entire cerebellum.

Data analysis

Neuropsychological tests and behavioral performances

We used non-parametric Mann-Whitney U tests because of the small number of participants and some variables did not have a Gaussian distribution. Statistical analyses were conducted using SPSS v.20. Statistical significance was set at 0.05.

fMRI

Data analysis was performed using the general linear model (GLM) as implemented in SPM8 ([Welcome Department of Imaging Neuroscience, London, UK, www.fil.ion.ucl.ac.uk/spm](http://www.fil.ion.ucl.ac.uk/spm)) where each event is modeled using a hemodynamic function model and SUIT atlas (spatial unbiased infratentorial and cerebellar template) (Diedrichsen et al., 2009) (http://www.icn.ucl.ac.uk/motorcontrol/imaging/suit_fmri.htm) for fMRI analysis in cerebellar template. Data analysis started with several spatial pre-processing steps such as realignment; slice timing correction; head motion correction; segmentation and spatial normalization of the cerebellum. For each fMRI session, two experimental conditions were defined: Rest (R) and n-back task (T). These conditions were modeled as two regressors and convolved with the canonical form of the hemodynamic response function. Individual statistical analyses were performed for each fMRI task (VIVE, VINV, AUVE and AUNV). Subsequently, [T-R] contrasts were calculated for each task and participant. These contrast data were further smoothed (FWHM=8mm). A group level statistical analysis was conducted using a flexible design. The

contrast [VE(AU+VI) vs. NV(AU+VI)] was calculated in order to explore the cerebellar regions required in working memory processing according to the nature of information and similar calculation for the opposite contrast [NV(AU+VI) vs. VE(AU+VI)]. Activation threshold was set at $p < 0.05$ and a minimal cluster of 4 voxels. The MRICron software was also used to overlay BOLD activations and to segment structural lesions onto SUIIT template.

Anatomical lesion

In patients, cerebellar volumes were isolated from the anatomical images and normalized using SUIIT atlas. The lobular regions of the cerebellum were also described in the SUIIT atlas. The cerebellar resections were segmented and overlaid onto anatomical images using MRICron software (<http://www.cabiatl.com/mricrogl/>).

RESULTS

Participants

11 patients and 23 age-matched healthy children satisfied all inclusion criteria were included. All subjects performed neuropsychological tests. In patients, medulloblastoma treatment consisted in surgical resection (n=11), chemotherapy (n=8), and radiotherapy (n=11). Mean delay between the end of treatment and neuropsychological assessment was 44 ± 15 months (27-73 months). Mean delays between neuropsychological tests and fMRI were 52 ± 52 days in patients, and 51 ± 20 days in controls (p=0.96). However, after fMRI acquisition, 6 controls and 3 patients were subsequently excluded due to excessive movement (n=5), anxiety (n=3), and lack of performance (n=1). Finally, fMRI data analysis was performed for 8 patients (6 boys, 2 girls, mean of age 13.1 ± 1.4 years); 17 controls including 8 controls (4 boys, 4 girls, mean of age 11.1 ± 1.9 years) completed the n-1 back fMRI study, and 9 other controls (7 boys, 2 girls, mean of age 11.6 ± 2.2 years) completed the n-2 back fMRI study. No difference for age (p=0.49) and sex (p=0.91) was detected between controls and patients.

Neuropsychological Results

Weschler Intelligence Scale (IQ)

Results of the neuropsychological tests in comparing the control and patient group showed that patients had significantly lower scores than controls in verbal comprehension index (101.18 ± 13.48 vs 115.04 ± 12.13 , p=0.009), perceptual reasoning index (98.90 ± 9.21 vs 109.47 ± 14.40 , p=0.02) and processing speed index (84.63 ± 14.67 vs 105.43 ± 16.29 , p=0.002).

Working Memory Test

In the tests related to the phonological loop, there was no significant difference in performance score between the control group and the patient group. However, the performance in the compound stimulus visual task information (CSVI) involving the visuospatial sketchpad was significantly lower in patients than in controls (10.97 ± 2.05 vs 12.26 ± 2.61 , $p=0.01$). Patients had also significantly lower scores than controls in transposed span (2.87 ± 0.81 vs 3.89 ± 0.87 , $p=0.003$) and in ordered span (5.05 ± 0.96 vs 5.83 ± 0.96 , $p=0.04$).

Functional MRI Results

Behavioral results

Behavioral results during fMRI tasks are presented in figure 1. For n-1 back, Mann-Whitney U tests showed: no significant differences between patients and controls for accuracy rates, VIVE ($p=0.41$), VINV ($p=0.15$), AUVE ($p=0.28$), and AUNV ($p=0.63$); increased mean reaction times in patients for VINV ($p=0.02$) only, while no difference was detected in VIVE ($p=0.91$), AUVE ($p=0.70$), and AUNV ($p=0.24$). For n-2 back, Mann-Whitney U tests showed: decreased accuracy rates in patients for VIVE ($p=0.01$), AUVE ($p<0.001$), and AUNV ($p=0.01$), while VINV were similar ($p=0.83$); increased mean reaction times in patients for AUNV ($p=0.001$), and trends for VIVE ($p=0.10$) VINV ($p=0.09$), AUVE ($p=0.07$).

(“Figure 1 about here”)

fMRI maps in healthy subjects

Activations related to main effects of each of the four conditions (VIVE VINV, AUVE and AUNV) were mainly found in the posterior cerebellar lobe including lobules HVI, HVIIb, HVIII, H IX, Crus I, Crus II. No age effect was detected. Main activation clusters were detected for VIVE in the right Crus I; VINV in bilateral Crus I, right HVI, right HVIII; AUVE left HIX, right HVI, and right Crus I; AUNV in left HVIII and left HVIIb, and right Crus I (see details in Table 2 of the supplemental data).

fMRI study with n-1 back tasks on 1.5T scanner showed for verbal vs. nonverbal contrast main activation in lobules HIX, HVIII, and HVIIb with a right predominance. Nonverbal vs. verbal contrast showed main activation in lobules HVI, with a left predominance (see details in Table 3 of the supplemental data) (figure 2).

(“Figure 2 about here”)

fMRI study with n-2 back tasks on 3T scanner showed for verbal vs. nonverbal contrast a cluster in the right HVIII. Nonverbal vs. verbal contrast showed main clusters in lobules HVI, with a left predominance (see details in Table 4 of the supplemental data) (figure 3).

(“Figure 3 about here”)

fMRI maps in patients

In the patient group, no significant activation could be detected in the cerebellum for n-1 and n-2 back tasks.

Anatomical Cerebellar Lesions in Patients

Eleven patients completed neuropsychological tests were taken subsequently anatomical MRI. Among them, 2 patients were excluded due to important movement artifacts, leaving 9 patients with structural MRI images. The cerebellar resection of these 9 patients were mainly located in left inferior cerebellar lobe, including the lobule HVIIB, HVIII, HIX, Crus I, II and inferior part of vermis (figure 4).

(“Figure 4 about here”)

DISCUSSION

Children treated for cerebellar medulloblastoma often experience working memory (WM) impairment, affecting their quality of life and school performance. Our combined neuropsychological and MRI results suggest the critical role of the cerebellar lobe in WM. Indeed, patients with structural lesions in the left posterior cerebellar lobe had WM impairment, while patients without left cerebellar hemisphere lesion had no visuospatial or verbal WM deficit. These results are strengthened by fMRI in controls showing that posterior cerebellar lobules are involved in WM tasks with a left predominance.

Our lesional study on anatomical images suggest that the left posterior lobe of the cerebellum is involved in visuospatial working memory, in line with previous neuropsychological and anatomical studies. Indeed, Hokkanen et al. (Hokkanen et al., 2006) found that patients with left cerebellar damage perform visuospatial tasks slower. Gottwald et al. (Gottwald et al., 2004) showed that the right cerebellar hemisphere is engaged in verbal working memory or the phonological loop while left cerebellar hemisphere plays a role in non-verbal or visuospatial working memory. These results are also compatible with those of Scott et al. (Scott et al., 2001), by Wallesch & Horn (Wallesch and Horn, 1990), by Riva & Giorgi (Riva and Giorgi, 2000), and the study of Botez-Marquard et al. (Botez-Marquard et al., 2001). All of these data allow us to strengthen the participation of the cerebellum in cognitive function, including the role of the left cerebellum in visuospatial working memory.

Our fMRI results obtained in the healthy controls only, showed that BOLD activations for nonverbal vs verbal contrast were more present in the left posterior cerebellar lobe, including lobule HVIII, HIX, Crus I and II. The right side of the posterior cerebellar lobe was more

activated for verbal vs nonverbal contrast (Figures 2 and 3). Thus, in right-handed subjects, verbal tasks relate to the right side and nonverbal tasks relate to the left side of the posterior cerebellar lobe. These data are consistent with previous functional neuroimaging studies that emphasize the involvement of the left posterior cerebellar lobe in visuospatial working memory (Richards et al., 2006) (Stoodley and Schmahmann, 2009) (Stoodley et al., 2010) (Stoodley, 2012) (E et al., 2014) (Lv et al., 2014).

Despite the above mentioned cerebellar laterality, we also reported two patients with left posterior cerebellar resection associated with verbal working memory impairment, only. Actually, this finding has also been previously described after damage of the left cerebellar lobule VIII associated with reduced digit span to auditory stimuli and phonological storage (phonological loop component) (Kirschen et al., 2008) while no cerebellar laterality was detected for verbal working memory impairment (Ravizza et al., 2006). Inversely, Ribaupierre et al. reported two patients with right cerebellar side damage and visuospatial deficits (de Ribaupierre et al., 2008).

Taken together, data from neuropsychological tests, anatomical and fMRI studies, and the literature suggest an involvement of the left cerebellum in working memory, especially the left posterior cerebellar lobe in visuospatial working memory. However, it does not exclude a potential role of the left cerebellum verbal working memory.

Our findings also noted that the patients had significant impairment in intelligence performance and central executive. These cognitive impairments were previously showed in children referred for meduloblastoma (Grill et al., 2004) (Palmer et al., 2013). However, no specific location of

cerebellar lesion was detected with these impairments. In several studies, the involvement of the cerebellum in cognitive function might be explained by the anatomical connectivity between the cerebellum and the cerebral cortex. For example using tractography, Salmi et al. (Salmi et al., 2010) found anatomical connectivity between the cerebellar lobules Crus I, II and the lateral prefrontal cortex being involved in cognitive function. Soelva et al. (Soelva et al., 2013) suggest the role of a neural circuitry (fronto-cerebellar fiber tracts) between frontal lobes and the cerebellum involvement in neurocognitive impairment after posterior fossa tumor treatment in children. In another study using diffusion tensor imaging, Law et al. (Law et al., 2011) found that working memory function is related to the integrity of cerebello–thalamo–cerebral connections, structural connections between the cerebellum and dorsolateral prefrontal cortex. A recent resting-state fMRI study also demonstrated a functional connection between the left posterior lobe of the cerebellum and the right parieto-frontal cortex which was engaged in visuospatial working memory (Lv et al., 2014). In our study, post-surgical cerebellar lesions might have disrupted the anatomical connectivity between the posterior cerebellar lobe and cerebral cortex that might also have led to working memory deficits in these patients.

In our study, the effects of cerebellar irradiation were not taken into account. In the literature, some studies on irradiation and chemotherapy effects in patients with brain lesion (acute lymphoblastic leukemia (Ashford et al., 2010) or cerebellar malignant tumors (Khong et al., 2006) have demonstrated a correlation between these effects and working memory deficit. A linear reduction of signal BOLD in the primary visual cortex was also found in patient treated for medulloblastoma compared to the healthy children group (Zou et al., 2005). The patients with posterior fossa malignant tumors, therefore, can sustain damage in the central nervous system from the tumor's growth, per-surgical resection of the tumors, the effects of chemotherapy and

radiotherapy, or from a combination of any of these factors (Cantelmi et al., 2008). Working memory disorders in medulloblastoma survivors may result from a combination of many factors, but here, we showed the importance of cerebellar damage after surgery. Due to ethical constraints, the assessment of working memory disorders caused by each specific factor is difficult to perform. The rehabilitation of these patients needs to take account of all possible risk factors.

Our study has several limitations including: (i) a low statistical power that remains a major concern for fMRI interpretation despite the prolonged duration of this multicenter study; (ii) fMRI limitations to investigate postoperative brain harboring magnetic susceptibility artifacts, anatomical deformations of posterior fossa uncompensated by the anatomical normalization, inter-individual spatial important variability of activations; (iii) heterogeneity of n-back tasks and MRI magnetic field strength caused the difficulties in comparison of the data; (iv) difficulty in distinguishing the surgical effects from those of radiotherapy and chemotherapy as a consequence of lacking a “surgery alone group”. However and despite low statistical thresholds, our fMRI results in controls are emphasized by the evidence given by both anatomical lesion and neuropsychological studies in patients.

CONCLUSION

The present study provides further evidence that the cerebellum plays a major role nonverbal working memory. Indeed, surgical damage to the left posterior cerebellar lobe might lead to nonverbal working memory disorders in children treated for cerebellar medulloblastoma. Additionally, the same region is involved in nonverbal working memory tasks using fMRI in

healthy controls. These findings help to better understand cognitive disorders after cerebellar lesions, and to better plan treatment including rehabilitation for improving the quality of life of children treated for cerebellar medulloblastoma.

Acknowledgement: This work was supported by grants from French Society for Childhood Cancer (SFCE), the Federative Research Structure n°1 (SFR1) and the Hospital Clinical Research Program (PHRC) of France, the Vietnamese ministry of education and training. We acknowledge the support of the MRI facility UMS IRMaGe of Grenoble, and the precious help of Mr. Patrice Jousse† for artwork.

Conflict of interest: None

REFERENCES

- Ashford, J., Schoffstall, C., Reddick, W. E., Leone, C., Laningham, F. H., Glass, J. O., Pei, D., Cheng, C., Pui, C.-H., and Conklin, H. M. (2010). Attention and working memory abilities in children treated for acute lymphoblastic leukemia. *Cancer* 116, 4638–4645. doi:10.1002/cncr.25343.
- Baddeley, A. D., and Hitch, G. J. (1974). “Working memory,” in *The psychology of learning and motivation: Advances in research and theory* (New York: Academic Press), 47–89.
- Van den Bosch, G. E., Marroun, H. E., Schmidt, M. N., Tibboel, D., Manoach, D. S., Calhoun, V. D., and White, T. J. H. (2012). Brain connectivity during verbal working memory in children and adolescents. *Hum. Brain Mapp.* doi:10.1002/hbm.22193.
- Botez-Marquard, T., Bard, C., Léveillé, J., and Botez, M. I. (2001). A severe frontal-parietal lobe syndrome following cerebellar damage. *Eur. J. Neurol. Off. J. Eur. Fed. Neurol. Soc.* 8, 347–353.
- Cantelmi, D., Schweizer, T. A., and Cusimano, M. D. (2008). Role of the cerebellum in the neurocognitive sequelae of treatment of tumours of the posterior fossa: an update. *Lancet Oncol.* 9, 569–576. doi:10.1016/S1470-2045(08)70148-7.
- D'albo, A., Chataing, V., and Revol, F. (1998). Evaluation préalable à la mise en place d'une aide technique à la communication. Available at: <http://cat.inist.fr/?aModele=afficheN&cpsidt=3063841> [Accessed October 30, 2013].
- Diedrichsen, J., Balsters, J. H., Flavell, J., Cussans, E., and Ramnani, N. (2009). A probabilistic MR atlas of the human cerebellum. *NeuroImage* 46, 39–46. doi:10.1016/j.neuroimage.2009.01.045.
- E, K.-H., Chen, S.-H. A., Ho, M.-H. R., and Desmond, J. E. (2014). A meta-analysis of cerebellar contributions to higher cognition from PET and fMRI studies. *Hum. Brain Mapp.* 35, 593–615. doi:10.1002/hbm.22194.
- Gottwald, B., Wilde, B., Mihajlovic, Z., and Mehdorn, H. M. (2004). Evidence for distinct cognitive deficits after focal cerebellar lesions. *J. Neurol. Neurosurg. Psychiatry* 75, 1524–1531. doi:10.1136/jnnp.2003.018093.
- Grill, J., Viguiier, D., Kieffer, V., Bulteau, C., Sainte-Rose, C., Hartmann, O., Kalifa, C., and Dellatolas, G. (2004). Critical risk factors for intellectual impairment in children with posterior fossa tumors: the role of cerebellar damage. *J. Neurosurg.* 101, 152–158. doi:10.3171/ped.2004.101.2.0152.
- Hoang, D. H., Pagnier, A., Guichardet, K., Dubois-Teklali, F., Schiff, I., Lyard, G., Cousin, E., and Krainik, A. (2014). Cognitive disorders in pediatric medulloblastoma: what neuroimaging has to offer. *J. Neurosurg. Pediatr.*, 1–9. doi:10.3171/2014.5.PEDS13571.

- Hokkanen, L. S. K., Kauranen, V., Roine, R. O., Salonen, O., and Kotila, M. (2006). Subtle cognitive deficits after cerebellar infarcts. *Eur. J. Neurol. Off. J. Eur. Fed. Neurol. Soc.* 13, 161–170. doi:10.1111/j.1468-1331.2006.01157.x.
- Khong, P.-L., Leung, L. H. T., Fung, A. S. M., Fong, D. Y. T., Qiu, D., Kwong, D. L. W., Ooi, G.-C., McAlonan, G., McAlanon, G., Cao, G., et al. (2006). White matter anisotropy in post-treatment childhood cancer survivors: preliminary evidence of association with neurocognitive function. *J. Clin. Oncol. Off. J. Am. Soc. Clin. Oncol.* 24, 884–890. doi:10.1200/JCO.2005.02.4505.
- Kirschen, M. P., Davis-Ratner, M. S., Milner, M. W., Chen, S. H. A., Schraedley-Desmond, P., Fisher, P. G., and Desmond, J. E. (2008). Verbal memory impairments in children after cerebellar tumor resection. *Behav. Neurol.* 20, 39–53. doi:10.3233/BEN-2008-0216.
- Knight, S. J., Conklin, H. M., Palmer, S. L., Schreiber, J. E., Armstrong, C. L., Wallace, D., Bonner, M., Swain, M. A., Evankovich, K. D., Mabbott, D. J., et al. (2014). Working Memory Abilities Among Children Treated for Medulloblastoma: Parent Report and Child Performance. *J. Pediatr. Psychol.* doi:10.1093/jpepsy/jsu009.
- Law, N., Bouffet, E., Laughlin, S., Laperriere, N., Brière, M.-E., Strother, D., McConnell, D., Hukin, J., Fryer, C., Rockel, C., et al. (2011). Cerebello-thalamo-cerebral connections in pediatric brain tumor patients: impact on working memory. *NeuroImage* 56, 2238–2248. doi:10.1016/j.neuroimage.2011.03.065.
- Lv, Z., Huang, D.-H., Ye, W., Chen, Z., Huang, W., and Zheng, J. (2014). Alteration of functional connectivity within visuospatial working memory-related brain network in patients with right temporal lobe epilepsy: a resting-state fMRI study. *Epilepsy Behav. EB* 35, 64–71. doi:10.1016/j.yebeh.2014.04.001.
- Marvel, C. L., and Desmond, J. E. (2010). Functional topography of the cerebellum in verbal working memory. *Neuropsychol. Rev.* 20, 271–279. doi:10.1007/s11065-010-9137-7.
- O’Halloran, C. J., Kinsella, G. J., and Storey, E. (2012). The cerebellum and neuropsychological functioning: a critical review. *J. Clin. Exp. Neuropsychol.* 34, 35–56. doi:10.1080/13803395.2011.614599.
- Palmer, S. L., Armstrong, C., Onar-Thomas, A., Wu, S., Wallace, D., Bonner, M. J., Schreiber, J., Swain, M., Chapieski, L., Mabbott, D., et al. (2013). Processing speed, attention, and working memory after treatment for medulloblastoma: an international, prospective, and longitudinal study. *J. Clin. Oncol. Off. J. Am. Soc. Clin. Oncol.* 31, 3494–3500. doi:10.1200/JCO.2012.47.4775.
- Ravizza, S. M., McCormick, C. A., Schlerf, J. E., Justus, T., Ivry, R. B., and Fiez, J. A. (2006). Cerebellar damage produces selective deficits in verbal working memory. *Brain J. Neurol.* 129, 306–320. doi:10.1093/brain/awh685.

- De Ribaupierre, S., Ryser, C., Villemure, J.-G., and Clarke, S. (2008). Cerebellar lesions: is there a lateralisation effect on memory deficits? *Acta Neurochir. (Wien)* 150, 545–550; discussion 550. doi:10.1007/s00701-008-1562-5.
- Richards, T. L., Aylward, E. H., Field, K. M., Grimme, A. C., Raskind, W., Richards, A. L., Nagy, W., Eckert, M., Leonard, C., Abbott, R. D., et al. (2006). Converging evidence for triple word form theory in children with dyslexia. *Dev. Neuropsychol.* 30, 547–589. doi:10.1207/s15326942dn3001_3.
- Riva, D., and Giorgi, C. (2000). The cerebellum contributes to higher functions during development: evidence from a series of children surgically treated for posterior fossa tumours. *Brain J. Neurol.* 123 (Pt 5), 1051–1061.
- Salmi, J., Pallesen, K. J., Neuvonen, T., Brattico, E., Korvenoja, A., Salonen, O., and Carlson, S. (2010). Cognitive and motor loops of the human cerebro-cerebellar system. *J. Cogn. Neurosci.* 22, 2663–2676. doi:10.1162/jocn.2009.21382.
- Schmahmann, J. D., and Sherman, J. C. (1998). The cerebellar cognitive affective syndrome. *Brain J. Neurol.* 121 (Pt 4), 561–579.
- Scott, R. B., Stoodley, C. J., Anslow, P., Paul, C., Stein, J. F., Sugden, E. M., and Mitchell, C. D. (2001). Lateralized cognitive deficits in children following cerebellar lesions. *Dev. Med. Child Neurol.* 43, 685–691.
- Soelva, V., Hernáiz Driever, P., Abbushi, A., Rueckriegel, S., Bruhn, H., Eisner, W., and Thomale, U.-W. (2013). Fronto-cerebellar fiber tractography in pediatric patients following posterior fossa tumor surgery. *Childs Nerv. Syst. ChNS Off. J. Int. Soc. Pediatr. Neurosurg.* 29, 597–607. doi:10.1007/s00381-012-1973-8.
- Spreen, O., and Strauss, E. (1998). *A Compendium of Neuropsychological Tests: Administration, Norms, and Commentary*. Oxford University Press.
- Stoodley, C. J. (2012). The cerebellum and cognition: evidence from functional imaging studies. *Cerebellum Lond. Engl.* 11, 352–365. doi:10.1007/s12311-011-0260-7.
- Stoodley, C. J., and Schmahmann, J. D. (2009). Functional topography in the human cerebellum: a meta-analysis of neuroimaging studies. *NeuroImage* 44, 489–501. doi:10.1016/j.neuroimage.2008.08.039.
- Stoodley, C. J., Valera, E. M., and Schmahmann, J. D. (2010). An fMRI study of intra-individual functional topography in the human cerebellum. *Behav. Neurol.* 23, 65–79. doi:10.3233/BEN-2010-0268.
- Thürling, M., Hautzel, H., Küper, M., Stefanescu, M. R., Maderwald, S., Ladd, M. E., and Timmann, D. (2012). Involvement of the cerebellar cortex and nuclei in verbal and visuospatial working memory: a 7 T fMRI study. *NeuroImage* 62, 1537–1550. doi:10.1016/j.neuroimage.2012.05.037.

- Tomlinson, S. P., Davis, N. J., Morgan, H. M., and Bracewell, R. M. (2014). Cerebellar contributions to spatial memory. *Neurosci. Lett.* 578, 182–186.
doi:10.1016/j.neulet.2014.06.057.
- Wallesch, C. W., and Horn, A. (1990). Long-term effects of cerebellar pathology on cognitive functions. *Brain Cogn.* 14, 19–25.
- Wechsler, D. (2005). *Echelle d'intelligence de Wechsler pour enfants et adolescents*. 4th ed. Paris: ECPA - Editions du Centre de Psychologie Appliquée Available at:
http://www.cra-rhone-alpes.org/cid/opac_css/index.php?lvl=notice_display&id=6852.
- Zou, P., Mulhern, R. K., Butler, R. W., Li, C.-S., Langston, J. W., and Ogg, R. J. (2005). BOLD responses to visual stimulation in survivors of childhood cancer. *NeuroImage* 24, 61–69.
doi:10.1016/j.neuroimage.2004.08.030.

Figure Legends

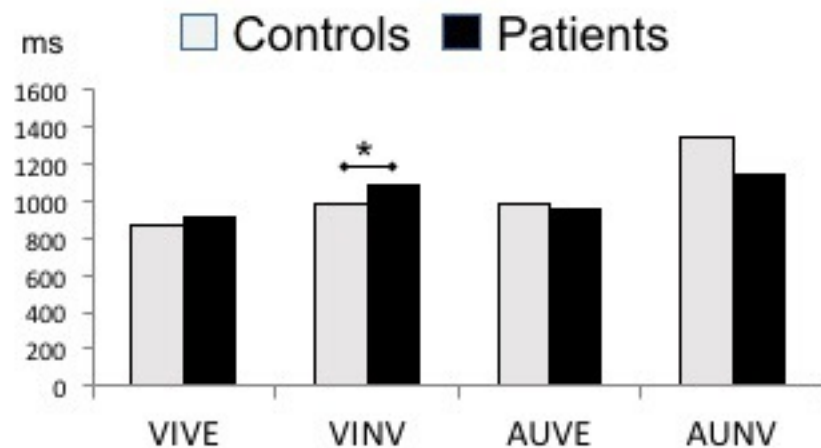
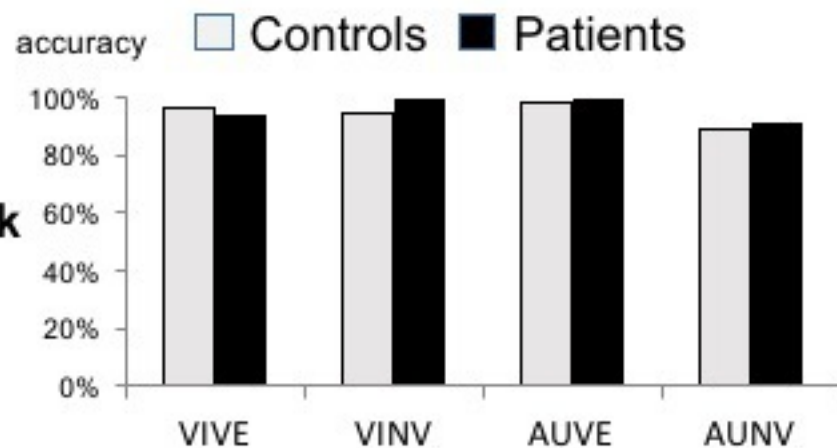
Figure 1: behavioral data during fMRI tasks (VIVE: visual verbal; VINV: visual nonverbal; AUVE: audio verbal; AUNV: audio nonverbal) during n-1 back (upper row) and n-2 back (lower row) with accuracy % (left column) and mean reaction time in ms (right column). *significant difference ($p < 0.05$) across groups.

Figure 2: n-1 back fMRI results in controls displayed onto the SUIT cerebellum template with activation T scores for nonverbal vs. verbal contrast (blue clusters) and for verbal vs. nonverbal contrast (orange clusters). Left posterior cerebellum was more involved in nonverbal tasks.

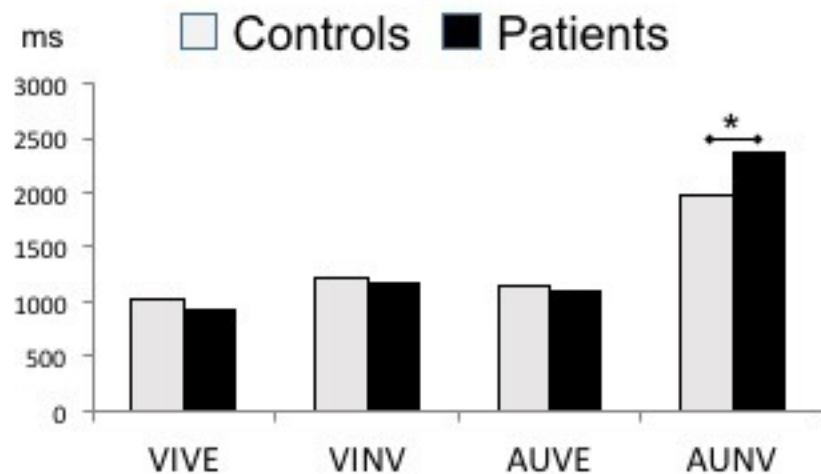
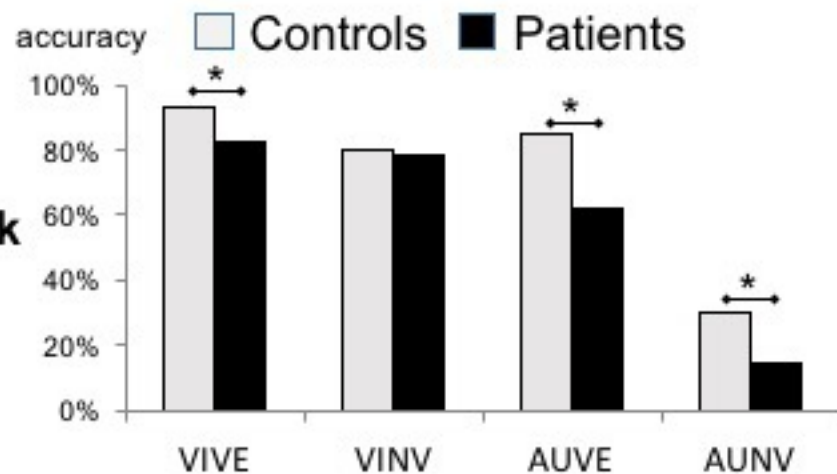
Figure 3: n-2 back fMRI results in controls displayed onto the SUIT cerebellum template with activation T scores for nonverbal vs. verbal contrast (blue clusters) and for verbal vs. nonverbal contrast (orange clusters). Nonverbal tasks were associated with bilateral posterior cerebellar activations with a left predominance, while verbal tasks had a right predominance.

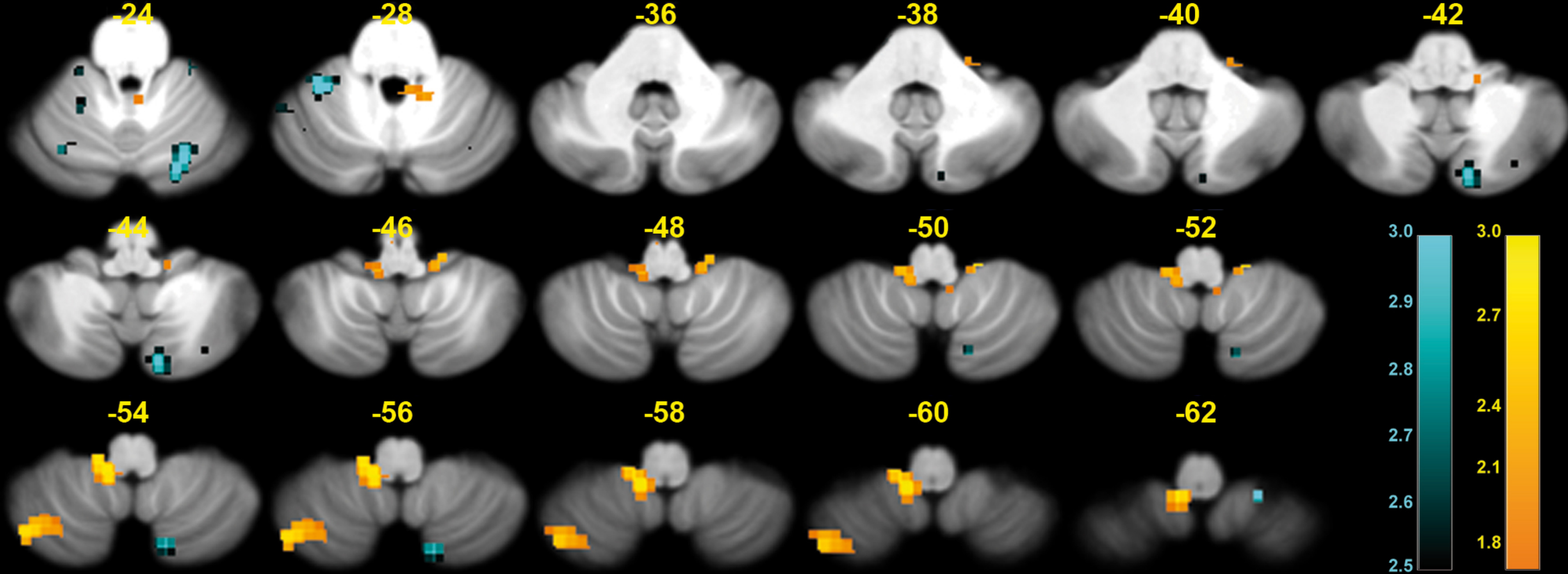
Figure 4: Cerebellar resection in 9 patients treated for medulloblastoma mapping on T1-WI MRI and on the spatially unbiased infratentorial SUIT template.

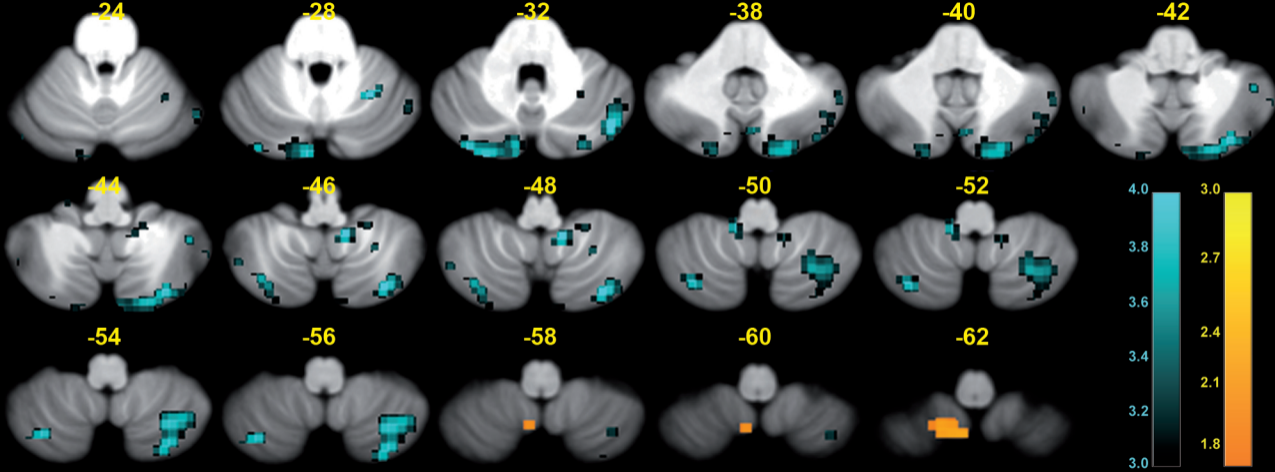
n-1 back



n-2 back







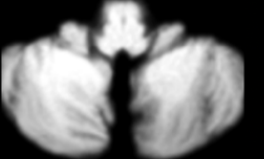
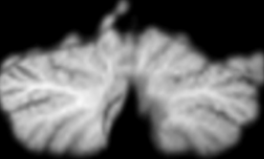














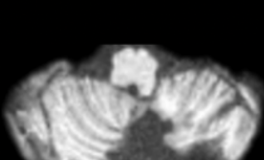




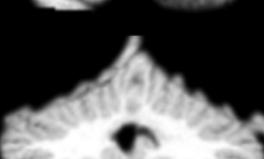


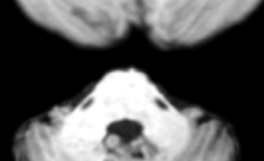
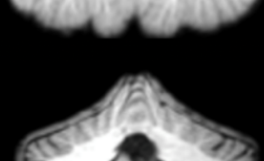


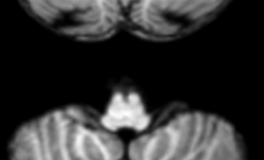







Patients	Cerebellar MRI T1-WI		Macroscopic Lesions on SUIT Model		Lesion Location	WM deficit
	Axial	Coronal	Axial	Coronal		
#1					Left HVIIb, Left Crus II, and vermis	Visuospatial memory and central executive
#2					Bilateral HVIII, HIX, and left HVIIb, Crus I, II, and vermis	Visuospatial memory and central executive
#3					Left HVIII, HIX, and vermis	Central executive
#4					Left HVIIb, HVIII, Crus I G	Visuospatial memory, phonological loop, and central executive
#5					Bilat. HVIIb, and left HVIII, IX, and vermis	Visuospatial memory and central executive
#6					Vermis	No WM impairment
#7					Vermis	No WM impairment
#8					Left HVIIb, HVIII, Crus I and II, and vermis	Phonological loop
#9					Left HVIII, HIX, hemisph. atrophy, and vermis	Central executive

Table 1: inclusion criteria of participants

Criteria	Patients	Healthy subjects
(i) native French speakers	✓	✓
(ii) right-handed	✓	✓
(iii) age of 8 to 14 years 11 months	✓	✓
(iv) overall IQ from 70 to 130	✓	✓
(v) children treated for medulloblastoma after age of 6 years and at least 6 months after the end of all treatments	✓	
(vi) having a good performance in the fMRI training	✓	✓
(vii) no contra-indication for MRI	✓	✓
(viii) not methylphenidate intake within 48 hours before MRI	✓	
(ix) no history of psychiatric, neurological or other major medical disorder		✓