



**HAL**  
open science

## Non-islet-cell tumour hypoglycaemia (NICTH): About a series of 6 cases

Arnaud Jannin, Stéphanie Espiard, Kanza Benomar, Christine Do Cao, Bénédicte Mycinski, Henri Porte, Michèle D'herbomez, Nicolas Penel, Marie-Christine Vantyghem

### ► To cite this version:

Arnaud Jannin, Stéphanie Espiard, Kanza Benomar, Christine Do Cao, Bénédicte Mycinski, et al.. Non-islet-cell tumour hypoglycaemia (NICTH): About a series of 6 cases. *Annales d'Endocrinologie* = *Annals of Endocrinology*, 2019, 80, pp.21 - 25. 10.1016/j.ando.2018.01.005 . hal-03485639

**HAL Id: hal-03485639**

**<https://hal.science/hal-03485639>**

Submitted on 20 Dec 2021

**HAL** is a multi-disciplinary open access archive for the deposit and dissemination of scientific research documents, whether they are published or not. The documents may come from teaching and research institutions in France or abroad, or from public or private research centers.

L'archive ouverte pluridisciplinaire **HAL**, est destinée au dépôt et à la diffusion de documents scientifiques de niveau recherche, publiés ou non, émanant des établissements d'enseignement et de recherche français ou étrangers, des laboratoires publics ou privés.



Distributed under a Creative Commons Attribution - NonCommercial 4.0 International License

**Non-islet-cell tumour hypoglycaemia (NICTH): about a series of 6 cases**

**Non-islet-cell tumour hypoglycaemia (NICTH): à propos de 6 cas.**

**Jannin Arnaud<sup>1</sup> (Resident), Espiard Stéphanie<sup>1</sup> (MD, PhD),  
Benomar Kanza<sup>1</sup> (MD), Do Cao  
Christine<sup>1</sup> (MD), Mycinski Bénédicte<sup>2</sup> (MD), Porte Henri<sup>3</sup> (MD, PhD),  
D'Herbomez Michèle<sup>4</sup> (MCU-PH, PharmaD), Penel Nicolas<sup>5</sup> (MD,  
PhD), Vantyghem Marie-Christine<sup>1, 6,7</sup>(MD, PhD)**

1 Department of Endocrinology and Metabolism, CHRU Lille, 59037 Lille France;

2Department of Medicine and Endocrinology, General Hospital, 62100 Calais, France

3Thoracic Surgery Department, Lille University Hospital,

4 Immunoanalysis Center, Biology and Pathology Center, CHU Lille, F-59000, Lille, France.

5 Medical Oncology Department, Oscar Lambret Cancer Centre, Lille, France 6 UMR 1190 Translational Research in Diabetes INSERM, 59000 Lille, France; 7EGID (European Genomic Institute for Diabetes), Univ Lille, 59000 Lille, France

**Corresponding author:**

Pr MC Vantyghem, Service d'Endocrinologie- Métabolisme, Hôpital C. Huriez,

1, rue Polonovski, Lille University Hospital, 59037 Lille Cedex, France  
mc-vantyghem@chru-lille.fr Tel: + 333 20 44 45 35- fax + 333 20 44 69  
85

## **Non-islet-cell tumour hypoglycaemia (NICTH): about a series of 6 cases**

## **Non-islet-cell tumour hypoglycaemia (NICTH): à propos de 6 cas**

**ABSTRACT :** The purpose of this study was to analyse the characteristics of 6 patients seen in a university hospital between 1996 and 2017 with NICTH, a form of hypoglycaemia due to the paraneoplastic secretion of IGF-2 or its related substances.

**Results:** Three of these 6 patients (50%), aged over 69 years, including 2 with acromegaloid phenotype, presented with a pleural solitary fibrous tumour (SFT), the median diameter of which reached 20 cm (12.5-20.5) with a low median SUV (3.3 (2-7.5) g/mL) on 18F-FDG PET. The 3 other patients presented with a neuroendocrine carcinoma (NEC) of the palate in a 70-year-old woman, a retroperitoneal myxofibrosarcoma in a 66-year-old man and a meningeal hemangiopericytoma in a 36-year-old woman. All three were inoperable and did not respond to any therapy other than glucose solution. Corticosteroid therapy was effective in the 3 SFT and the NEC. One of the SFT recurred 10 years later with asymptomatic hypoglycaemia, which resolved after reintervention. The median (IQR) blood glucose levels of the 6 patients were 0.4 g/L (0.31-0.41), with hypoinsulinemia at 0.7 (0.7-2.0) mIU/L, undetectable GH, low IGF-1, normal IGF-2 levels in 5/6 cases, a high IGF-2:IGF-1 ratio at 26.9 (20.8-37.8), hypokalemia and hypomagnesemia.

**Conclusion:** NICTH is a rare syndrome, which should be considered in the presence of hypoinsulinemic hypoglycaemia with low GH and IGF-1, and a IGF-2:IGF-1 ratio >10. Corticosteroid therapy was effective in elderly subjects, particularly with solitary fibrous tumours, which were generally operable. Hemangiopericytoma and myxofibrosarcoma had a poor prognosis in younger patients.

**Key words:** Hypoglycaemia, hypoinsulinism, paraneoplastic syndrome, NICTH, IGF-2.

## **Résumé:**

**L'objectif** de cette étude est d'analyser les caractéristiques de 6 patients atteints de Non Islet Cell Tumor Hypoglycemia (NICTH), hypoglycémies liées à une sécrétion paranéoplasique d'IGF-2 ou d'apparentés, adressés dans un hôpital universitaire entre 1999 et 2017.

**Résultats:** Parmi les 6 patients, trois (50%) âgés de plus de 69 ans, dont 2 étaient acromégaloïdes, présentaient une tumeur fibreuse solitaire (TFS) pleurale dont le diamètre médian atteignait 20 cm (12,5-20,5) avec un SUV médian bas (3,3 (2,0-7,5) g/ml) en TEP-18FDG. Les 3 autres patients, présentaient 1. un carcinome neuro-endocrine (CNE) du palais chez une femme de 70 ans, 2. un myxofibrosarcome rétropéritonéal chez un homme de 66 ans et 3. un hémangiopéricytome méningé chez une femme de 36 ans. Tous trois étaient inopérables et ne répondaient à aucune thérapeutique hormis le sérum glucosé. La corticothérapie était efficace dans les 3 TFS et la TNE. L'une des TFS a récidivé 10 ans plus tard avec des hypoglycémies asymptomatiques, résolutive après réintervention. La médiane (IQR) glycémique des 6 patients était de 0,4 g/L (0,31-0,41), avec hypoinsulinémie 0,7 (0,7-2,0) mUI/L, GH indétectable, IGF1 basse, IGF-2 moyenne normale à 820 (712-969) ng/mL, rapport IGF-2 / IGF1 élevé à 26,9 (20,8-37,8), hypokaliémie et hypomagnésémie.

**Conclusion:** Les NICTH sont des syndromes rares à évoquer devant une hypoglycémie hypoinsulinémique avec GH et IGF1 basses associée à un rapport IGF2 / IGF1 >10. Dans notre expérience, le pronostic varie selon l'âge et l'étiologie : la corticothérapie était efficace chez les sujets âgés, notamment porteurs de tumeurs fibreuses solitaires en général secondairement opérables. L'hémangiopéricytome et le myxofibrosarcome avaient un pronostic péjoratif chez des patients plus jeunes.

**Mots clés :** Hypoglycémies hypoinsulinique, syndrome paranéoplasique, NICTH, IGF-2.

## INTRODUCTION

Hypoglycaemia secondary to extra-pancreatic tumours, identified in 1929 [1], was at that time thought to be related to an increase in glucose consumption by the tumour, a hypothesis that was not confirmed later [2]. In the 1970's, the observation of low blood insulin levels suggested that such tumours could secrete an "insulin-like" factor. Since the end of the 1990's, the role of a high molecular weight precursor of IGF-2, called Big-IGF-2 [3, 4], was confirmed in these cases of paraneoplastic hypoglycaemia unrelated to an insulinoma, usually referred to the acronym NICTH (non-islet-cell tumour hypoglycaemia). NICTH are invariably characterised by extremely low levels of insulin, C-peptide and GH, paradoxically associated to hypoglycaemia [5-8]. This syndrome, sometimes called IGF-2-oma, may occur with a wide variety of tumours, both benign and malignant, in which the IGF-2 gene is overexpressed, thus explaining the increased production of IGF-2 precursors [9]. It is likely that most neoplastic cells are not able of adequate enzymatic processing. These precursors often present a glycosylation defect, which makes their cleavage incomplete and results in the formation of Big IGF-2 [10]. In NICTH, there is a mix of unprocessed pro-IGF-2 (1-156), pro-IGF-2 (1-104), and heterogeneous O-glycosylated pro-IGF-II (1-87) or "big"-IGF-II [4, 5, 8]. Different isoforms of IGF-2 family compete with mature IGFs for complex formation with IGFBP (Insulin-like growth factor-binding protein), resulting in an increase of free IGFs. The association of big-IGF-2 with IGFBP-3 (or 5) could prevent appropriate Acid-Labile Subunit binding, therefore hampering the formation of the ternary complex [11]. The smaller complexes (binary complexes) and free unbound IGFs permeate the capillary easily, bind to insulin receptors, and activate different mechanisms that contribute to hypoglycaemia. These molecules increase the use of glucose by the skeletal muscles and adipocytes, and inhibit glycogenolysis and neoglucogenesis, thus favoring the occurrence of hypoglycaemia [12-14]. This rare syndrome may be underdiagnosed.

The aim of this retrospective, single-centre study was to review the cases of NICTH over the past two decades in order to identify the characteristics and the main diagnostic pitfalls.

## **PATIENTS AND METHODS**

This study, which was carried out in a university-affiliated endocrinology department, identified 6 cases of NICTH between 1996 and 2016; only one of the cases occurred before 2000, and the 5 others were in the last 10 years, including 2 cases in 2016. The diagnosis of NICTH was made through the association of hypoinsulinemic hypoglycaemia with low GH and IGF-1 in the presence of a tumour.

The data that were compiled included age, gender, comorbidities, body mass index, arterial blood pressure, tumour type, tumour size and location, blood glucose, C-peptide, blood insulin, GH, IGF-1, IGF-2 and the IGF-2:IGF-1 ratio. None of the patients had an assay of Big-IGF-2. The IGF-2 assay was done by radioimmunoassay (normal range: 460 -1125 ng/mL).

## **RESULTS**

The results are presented in Table 1.

### **Characteristics of the population and clinical manifestations**

Five of the 6 patients analysed were women, with a median age of 69.5 years and a median body mass index of 23.4 kg/m<sup>2</sup>. The presenting symptoms of the tumour were the hypoglycaemic manifestations in 3 patients (50%). The hypoglycaemia occurred while fasting, with neuroglucopenic manifestations including confusion, aphasia and coma. In the 3 other cases, the presenting symptoms were a tumoral syndrome, including weight loss, pain or a palpable mass. Two patients presented with non-inaugural acromegaloid syndrome and one patient with seborrheic keratosis.

### **Tumour characteristics**

Three of the 6 patients presented with a pleural solitary fibrous tumour (SFT), with hypoglycaemia as the revealing symptom. The 3 other tumours, became complicated by hypoglycaemia 3 to 8 years after the initial diagnosis. These tumours included a neuroendocrine carcinoma of the soft palate, a meningeal hemangiopericytoma and a retroperitoneal myxofibrosarcoma. Hemangiopericytoma is a term given for meningeal localisation of SFT. This series includes 5 sarcomas and one neuroendocrine tumor. The median tumour size was 17.6 cm, with 5 of the tumours over 15 cm. The median SUV on [<sup>18</sup>F]-fluoro-2-deoxyglucose PET/CT scan of the 6 patients was low at 3.3 mg/mL (2-7.5).

### **Laboratory results**

The median (IQR) blood glucose during the episodes of hypoglycaemia in the 6 patients was 0.4 g/L, with low plasma concentrations of insulin, GH and IGF-1. IGF-2 was normal, with a high IGF-2 / ,IGF-1 ratio and a low IGF-BP3 (Table1). In the cases of hypoinsulinemic hypoglycaemia, the serum glucagon was normal in 3 patients and high in the patient who was most resistant to treatments. Patient #3 with solitary fibrous tumour had a continuous glucose monitoring (CGM) before tumor resection, showing an asymptomatic low mean glucose, especially during the night (Figure 1A), which completely resolved after tumor resection (Figure 1B).

### **Complications**

Electrolytic profile associated to severe hypoglycaemia was mild hypokalemia with normal urine potassium and hypomagnesemia. Iron-deficiency anemia and low prealbumin levels were also evidenced. Three of the 6 patients presented with euthyroid goiter.

The two patients with hemangiopericytoma and myxofibrosarcoma died, respectively 1 year 2 months and 8 months after the occurrence of hypoglycaemia.

## **DISCUSSION**

The prevalence of NICTH is low, but such condition may be under-diagnosed. Indeed, this retrospective study reporting only 6 cases from a university department in an area of 4 million inhabitants might reflect a lack of identification, with only one diagnosis made before 2000, and five since then, including two during the last year. It is therefore important to be aware of the circumstances and early signs associated to this curable disorder when hypoglycaemia is the presenting symptom.

The diagnosis of NICTH in our patients was made either with hypoglycaemia as the presenting symptom of a tumour, or following a tumoral syndrome, in which the hypoglycaemia was identified several years after the initial diagnosis, often with tumor recurrence. The cases of NICTH in which a tumoral syndrome was the presenting symptom had a poor prognosis (2 out of the 3 patients died in the 14 months following the occurrence of hypoglycaemia). They also had more severe hypoglycaemia, resisting to all treatments other than glucose infusion.

As described by Bodnar et al. [7], hypoglycaemia occurred in our patients while fasting and hypoglycaemia unawareness may be frequent as illustrated by the CGMS performed systematically before surgery of a recurrent tumour in a clinically symptomless 73-year-old woman. Hypoglycemia can be discovered during nocturnal confusion or a fall in elderly individuals without a known tumour. Neuroglycopenic symptoms prevailed at diagnosis. The earliest sign is the loss of judgement ability, before the confusion and amnesia. Severe hypoglycaemia may result in seizures, coma and sometimes death [15]. The patient may present with focalised neurological signs, such as aphasia in one of our patients, mimicking a stroke or a brain metastasis [16]. As a result, any behavioural or mental status changes in a patient should prompt a blood glucose measurement, whether or not there is a known tumour. In addition, besides its role in carbohydrate metabolism, IGF-2 can lead to tissue overgrowth and skin changes, resulting in acromegaloid features, as seen in two of our patients [17] and goiter in 3



of them. Seborrheic keratosis, which was present in two of our patients, has also been described in literature [18].

The diagnostic procedure and the differential diagnoses can be achieved using the algorithm defined in the consensus of the French Society of Endocrinology [19] and the Endocrine Society [20]. In the presence of seemingly organic hypoglycaemia, laboratory explorations can rule out iatrogenic causes, cortico-somatotropic insufficiencies and metabolic causes.

The occurrence of hypoinsulinemic hypoglycaemia with low GH and IGF-1 should prompt consideration of the secretion of a hypoglycaemic substance impeding the secretion of insulin and GH, such as IGF-2 or one of its related substances. The confirmation of the diagnosis is not often given by a high level of IGF-2 (only one out of the 6 patients) but by a high IGF-2:IGF-1 ratio (26.9 in our study). The normal ratio is around 3:1; a ratio greater than 10:1 is highly suggestive of IGF-2 precursor secretion [5-8]. In their series, Fukuda et al. [5] showed a mean ratio of 64:1. Therefore, a normal IGF-2 level in the presence of hypoinsulinemic hypoglycaemia should not rule out this diagnosis. Currently, the assay for Big IGF-2 and high molecular weight precursors of IGF-2 is only performed in some research laboratories. These assays are radioimmunoassays, using antibodies against the E-domain (105–108). A more rapid technique for separating pro-IGF-II from mature IGF that employs thin layer chromatography (Tricine-SDS-PAGE followed by IGF-II immunoblot analysis) was recently developed, which could enable NICTH to be diagnosed more easily [6]. The decrease in IGF-BP3, as in our patients, is an indirect evidence supporting the diagnosis of NICTH. Unexpectedly, the serum glucagon was normal or high in our patients, while it should be decreased by the excess of related IGF-2 substances [5]. This is probably related to the stimulating effect of hypoglycemia on the secretion of this hyperglycemic hormone.

IGF-2 and its related substances can be secreted by a broad spectrum of benign and malignant tumours [7, 8, 21, 22]. In our study, SFT was the most frequent. Mesenchymatous and hepatic tumours are more common in the literature [8]. Hypoglycaemia occurs with bulky tumours, easily reaching 20 cm for pleural SFT [23]. In our series, hypoglycemia was less severe with SFT and in the patient with neuroendocrine carcinoma, and it was more sensitive to corticosteroid therapy (median prednisone-equivalent dose of 40 mg/day) than hypoglycaemia secondary to hemangiopericytoma and myxofibrosarcoma, which only responded to glucose solution. The most effective treatment for NICTH is surgical resection of the tumour [24]. New episodes of hypoglycemia following the tumour resection mark the recurrence.

Several of our cases of hypoglycaemia were accompanied by hypokalemia and normal urine potassium, as described in the literature [5, 7, 8]. They were probably induced by the insulin-like effects of IGF-2, since insulin has the property to facilitate the intracellular transfer of glucose, potassium and magnesium, thus also explaining the hypomagnesemia. All of our patients also presented with iron deficiency anemia and low prealbumin, possibly due to the tumour or malnutrition.

Despite our small sample size, the results of our study therefore match those in the literature.

## **CONCLUSION**

NICTH due to the paraneoplastic secretion of IGF-2-related substances is a rare syndrome, which may be overlooked. NICTH should be considered in the context of organic hypoglycemia associated with very low levels of insulin, peptide C and IGF-1. Hypoglycemia can be the presenting symptom particularly in pleural fibrous tumour. Focused diagnostic work-up is needed from the outset in individuals, often the youngest, with a tumoral syndrome and

organic hypoglycaemia. The diagnosis is confirmed with an IGF-2:IGF-1 ratio greater than 10, much more useful than the measurement of Big-IGF-2, which is not marketed. In our experience, the prognosis varies according to age and etiology. Corticosteroid therapy was effective, particularly in fibrous tumours, which were generally operable. Resection of the responsible tumour resolves the hypoglycemia. Hemangiopericytoma and myxofibrosarcoma had a poor prognosis in younger patients. New anti-IGF-2 therapies are undergoing evaluation and could be a therapeutic option in these patients [9].

**Table 1 : Characteristics of the patients (SFT: Solitary fibrous tumor; NEC : Neuroendocrine carcinoma)**

*Tableau 1: Caractéristiques des patients (SFT: Tumeur fibreuse solitaire; NEC: carcinome neuroendocrine)*

**Figure 1. Continuous glucose monitoring night profiles before (A) and after (B) tumor resection (the green zone corresponds to the blood glucose normal range)**

*Figure 1: Monitoring continu du glucose nocturne avant (A) et après (B) resection tumorale (la zone verte correspond aux valeurs normales de glycémie)*

**The authors report no conflicts of interest. The authors alone are responsible for the content and writing of this article**

**Les auteurs déclarent ne pas avoir de liens d'intérêt.**

## **REFERENCES**

[1] Nadler WH, Wolfer JA. Hepatogenic hypoglycemia associated with primary liver cell carcinoma.

Arch

Intern

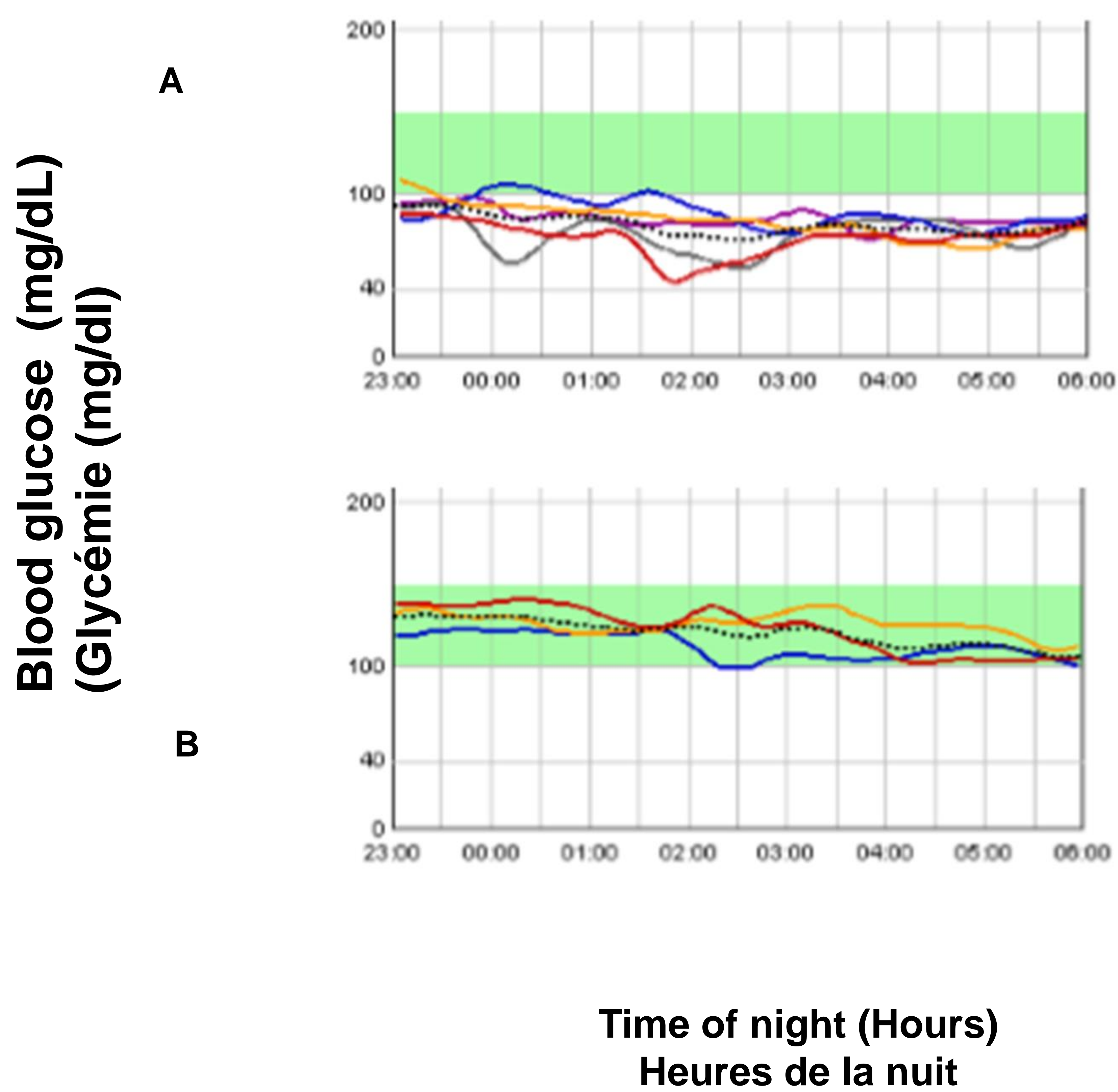
Med.1929;44:700–10.

- [2] Gogvadze V, Orrenius S, Zhivotovsky B. Mitochondriain cancer cells : what is so special about them? Trends Cell Biol. 2008;18:165–73.
- [3] Kahn, CR. The riddle of tumor hypoglycemia revisited. Clin. Endocrinol. Metab. 1980;9:335-60.
- [4] Daughaday WH, Emanuele MA, Brooks MH, Barbato AL, Kapadia M, Rotwein P. Insulin-like growth factor II synthesis and secretion by a leiomyosarcoma with associated hypoglycemia. N. Engl. J. Med. 1988;319:1434-40.
- [5] Fukuda I, Hizuka N, Ishikawa Y, Yasumoto K, Murakami Y, Sata A et al . Clinical features of insulin-like growth factor-II producing non-islet-cell tumor hypoglycemia. Growth Horm IGF Res.2006;16:211–6.
- [6] Miraki-Moud F, Grossman AB, Besser M, Monson JP, Camacho-Hübner C. A rapid method for analyzing serum pro-insulin-like growthfactor-II in patients with non-islet cell tumor hypoglycemia. J Clin Endocrinol Metab. 2005;90:3819–23.
- [7] Bodnar TW, Acevedo MJ, Pietropaolo M. Management of non-islet-cell tumor hypoglycemia: a clinical review. J Clin Endocrinol Metab.2013 ;99:713–22.
- [8] Dynkevich Y, Rother KI, Whitford I, Qureshi S, Galiveeti S, Szulc AL et al. Tumors, IGF-2 and hypoglycemia: insights from the clinic, the laboratory and the historical archive. Endocr Rev. 2013;34:798–826.
- [9] Belfiore A, Malaguarnera R. Insulin receptor and cancer. Endocr Relat Cancer 2011;18 :R125-47.
- [10] Widmer U, Zapf J, Froesch ER. Is extrapancreatic tumor hypoglycemia associated with elevated levels of insulinlike growth factor II? J Clin Endocrinol Metab. 1982;55: 833–9.
- [11] Zapf J, Futo E, Peter M, Froesch ER. Can “big” insulin-like growth factor II in serum of tumor patients account for the development of extrapancreatic tumor hypoglycemia? J Clin Invest. 1992;90:2574–84.
- [12] Alexandrides T, Moses AC, Smith RJ. Developmental expression of receptors for insulin, insulin-like growth factor I(IGF-I) and IGF-II in rat skeletal muscle.Endocrinology. 1989;124:1064–76.
- [13] Froesch ER, Zapf J. Insulin-like growth factors and insulin: comparative aspects. Diabetologia. 1985;28:485–93.
- [14] Shapiro ET, Bell GI, Polonsky KS, Rubenstein AH, Kew MC, Tager HS. Tumor hypoglycemia :

- relationship to high molecular weight insulin-like growth factor-II. *J Clin Invest.* 1990;85:1672–79.
- [15] Deary IJ. Symptoms of hypoglycaemia and effects on mental performance and emotions. Frier BM, Fisher M, eds. *Hypoglycaemia in Clinical Diabetes.* New York, NY: Wiley; 2007:25–48.
- [16] Malouf R, Brust J. Hypoglycemia: causes, neurological manifestations, and outcome. *Ann Neurol.* 1985;17:421–30.
- [17] Trivedi N, Mithal A, Sharma AK, Mishra SK, Pandey R, B Trivedi et al. Non-islet cell tumour induced hypoglycemia with acromegaloïd facial and acral swelling. *Clin Endocrinol (Oxf).* 1995;42:433–5.
- [18] Mayou SC, Benn JJ, Sonksen PH, Black MM. Paraneoplastic rhinophyma and the Leser-Tre'lat sign. *Clin Exp Dermatol.* 1989;14:253–5.
- [19] Consensus of the French Endocrine Society : « Hypoglycaemia in non-diabetic adult patients ». *Ann Endocrinol* 2013;14:166-206.
- [20] Cryer PE, Axelrod L, Grossman AB, Heller SR, Montori VM, Seaquist ER et al. Evaluation and management of adult hypoglycemic disorders : an Endocrine Society Clinical Practice Guideline. *J Clin Endocrinol Metab.* 2009;94:709–28.
- [21] Baker J, Liu JP, Robertson EJ, Efstratiadis A. Role of insulin-like growth factors in embryonic and postnatal growth. *Cell.* 1993;75:73–82.
- [22] Teale JD, Marks V. Glucocorticoid therapy suppresses abnormal secretion of big IGF-II by non-islet cell tumours inducing hypoglycaemia (NICTH). *Clin Endocrinol (Oxf).* 1998;49:491–8.
- [23] Kalebi AY, Hale MJ, Wong ML, Hoffman T, Murray J. Surgically cured hypoglycemia secondary to pleural solitary fibrous tumour: case report and up date review on the Doege-Potter syndrome. *J Cardiothorac Surg.* 2009;4:45.
- [24] Teale JD, Wark G. The effectiveness of different treatment options for non-islet cell tumour hypoglycemia. *Clin Endocrinol (Oxf).* 2004;60:457–60.

**Figure 1. Continuous glucose monitoring (CGM) night profiles before (A) and after (B) tumor resection.**

**Figure 1. Profil glycémique nocturne avant et après résection tumorale.**



Characteristics	Patients	# 1	# 2	# 3	# 4	# 5	# 6	Median (IQR)
General	Age at diagnosis	69	77	70	70	36	66	69.5 (66.7-70)
	Female (F) / Male (M)	F	F	F	F	F	M	5F/1M
	Body Mass Index (kg/m <sup>2</sup> )	19.8	23	24.9	20.4	23.7	30.1	23.4 (21.1-24.6)
Hypoglycaemia	Revealing the tumor	Yes	Yes	Yes	No	No	No	3/6
	Blood glucose (g/L)	0.52	0.47	0.29	0.42	0.24	0.39	0.4 (0.31-0.41)
	HbA1c (%)	4.8	5.3	5.2	4.8	4.6	4.7	4.8 (4.7-5.1)
	Blood C-peptide (N: 0.5-2 ng/mL)	0.08	0.08	0.08	0.1	0.09	0.08	0.08 (0.08-0.09)
	Blood Insulin (N : 2.5-10.4) mU/L	2	2	0.7	0.7	0.5	0.6	0.7 (0.6-1.7)
	GH (N : 0-10 ng/mL)	0.1	0.1	0.1	0.3	0.2	0.2	0.15 (0.2-0.2)
	IGF-1 (N : 117-388 ng/mL)	30	61	22	25	19	46	27.5 (22.7-42)
	IGF-2 (N : 460-1125 ng/mL)	613	750	700	995	5632	1015	872 (712-1010)
	IGF-2/ IGF-1 (N < 3)	20.4	12.3	31.8	39.8	288	22.6	31.8 (20.8-37.8)
	IGF BP3 (N : 2.7-6.7 mg/L)	2.7	1.8	1.6	1.5	1	1.2	1.8 (1.3-1.7)
Glucagon (N <180 pg/mL)			81	124	412	68	102.5 (77.7-196)	
Tumor	Type	SFT	SFT	SFT	NEC	Hemangiopericytoma	Myxofibrosarcoma	3 SFT/ 6
	Localisation	Pleural	Pleural	Pleural	Velum	Meningeal	Retro-péritoneal	3 pleural/ 6
	Diameter (cm)	17.5	20	21	5	17.6	15.3	17.6 (12.7-20.2)
	TFDG-TEP SUV (g/mL)	2.5	2.7	5.4	2.9	5.6	3.8	3.3 (2.7-5)
Complications	Acromegaly	Yes	No	Yes	No	No	No	2/6
	Thyroid goiter	Yes	Yes	Yes	No	No	No	3/6
	TSH (N: 0.4-3.6) $\mu$ UI/ml	0.1	4.5	3.6	3.1	5.2	0.5	3.65 (1.2-4.3)
	Blood Potassium (N: 3.5-5 mmol/L)	3.9	3.3	2.8	3.8	2.75	4.75	3.3 (2.9-3.9)
	Kaliuresis (mmol/24h)	52	18	56	109	84	68	62 (53-80)
	Magneemia (18-24 mg/L)	17	15	14	20	15.5	16	15.7 (15.1-16.7)
	Pre-albumin (g/L)	0.11	0.9	0.12	0.23	0.18	0.19	0.12 (0.11-0.18)
Hemoglobin (g/dl)	13.1	9.4	10.1	11.2	9.1	12.2	10.6 (9.5-11.9)	
Treatment	Dietary measures	Yes	Yes	Yes	Yes	Yes	Yes	6/6
	G30	Yes	Yes	Yes	Yes	Yes	Yes	6/6
	Surgery	Yes	No	Yes	No	Yes	No	2/6
	Prednisone dose (mg/day)	40	40	40	30	60	60	40 (40-55)
	Sirolimus	No	No	No	No	Yes	No	1/6
	Glucagon	Yes	No	No	Yes	Yes	Yes	4/6
	Somatostatin analog	No	No	No	No	Yes	Yes	2/6
Outcome	Cured post surgery	Yes	-	Yes	-	Yes	-	3/6
	Recurrence of hypoglycemia Post surgery	No	-	Yes	-	Yes	-	2/6
	Intractable hypoglycemia	-	-	-	-	Yes	-	1/6
	Length between diagnosis and cure, stabilization or death (months)	10	8	36	48	14 Death	8 Death	12 (8.5-30.5)

Table 1 : Characteristics of the patients (SFT: Solitary fibrous tumor; NEC : Neuroendocrine carcinoma)