



## Dual mobility cups in total hip arthroplasty after failed internal fixation of proximal femoral fractures

Sandrine Boulat, Thomas Neri, Bertrand Boyer, Rémi Philippot, Frédéric Farizon

### ► To cite this version:

Sandrine Boulat, Thomas Neri, Bertrand Boyer, Rémi Philippot, Frédéric Farizon. Dual mobility cups in total hip arthroplasty after failed internal fixation of proximal femoral fractures. *Orthopaedics & Traumatology: Surgery & Research*, 2019, 105, pp.491 - 495. 10.1016/j.otsr.2019.01.014 . hal-03484990

**HAL Id: hal-03484990**

**<https://hal.science/hal-03484990>**

Submitted on 20 Dec 2021

**HAL** is a multi-disciplinary open access archive for the deposit and dissemination of scientific research documents, whether they are published or not. The documents may come from teaching and research institutions in France or abroad, or from public or private research centers.

L'archive ouverte pluridisciplinaire **HAL**, est destinée au dépôt et à la diffusion de documents scientifiques de niveau recherche, publiés ou non, émanant des établissements d'enseignement et de recherche français ou étrangers, des laboratoires publics ou privés.



Distributed under a Creative Commons Attribution - NonCommercial 4.0 International License

**Original article**

**Dual mobility cups in total hip arthroplasty after failed internal fixation of proximal femoral fractures**

Sandrine **BOULAT**\*<sup>1</sup>, Thomas **NERI**<sup>1,2</sup>, Bertrand **BOYER**<sup>1,3</sup>, Rémi **PHILIPPOT**<sup>1,2</sup>, Frédéric **FARIZON**<sup>1,3</sup>

<sup>1</sup> Department of Orthopaedic Surgery, University hospital of Saint Etienne, France

<sup>2</sup> EA 7424 - Inter-university Laboratory of Human Movement Science, University Lyon - University Jean Monnet Saint Etienne, FRANCE

<sup>3</sup> INSERM, U1059,F-42055, Saint Etienne, France

\*corresponding author: sandrine.boulat@yahoo.fr

## **ABSTRACT**

**Introduction:** Performing total hip arthroplasty (THA) following failed internal fixation of proximal femur fractures is associated with an elevated risk of implant dislocation. We hypothesized that using a dual mobility (DM) cup will help to reduce the risk of postoperative instability in this specific context.

**Material and methods:** This was a retrospective study of 33 consecutive patients who underwent DM THA following failed internal fixation of a proximal femur fracture. The clinical assessment consisted of the Postel-Merle d'Aubigné and HHS scores along with an analysis of preoperative and follow-up radiographs. The primary outcome was the occurrence of implant dislocation.

**Results:** At the last follow-up ( $44 \pm 24$  months), 7 patients had died and 0 were lost to follow-up. Only one dislocation had occurred (3%). The mean PMA and HSS scores of 14.8 and 80 respectively were significantly better than the preoperative scores. There were no cases of aseptic loosening.

**Conclusion:** The use of DM cups in the context of THA following failed internal fixation of proximal femur fractures helps to reduce the risk of dislocation. Thus DM cups are recommended in this indication with high risk of postoperative instability.

**Keywords:** femoral neck fracture, bone fixation, dual mobility hip arthroplasty, dislocation

## INTRODUCTION

The failure rate of internal fixation for proximal femur fractures is 20% to 30% [1]. In this context, recourse to total hip arthroplasty (THA) is often the case. However, there are technical difficulties inherent to this procedure, especially in cases of extracapsular fractures. The need to remove the fixation hardware, the potential presence of malunion and the modified anatomical landmarks can lead to errors in implant positioning. Periprosthetic muscular weakness related to repeat procedures increases the risk of postoperative complications and especially that of implant dislocation [2–4]. In this indication, the postoperative instability rate of about 10% is significantly higher than following primary THA [5–7].

By reusing the McKee concept, dual mobility (DM) cups help to increase the jump distance and thereby reduce the risk of implant dislocation [8,9]. For 30 years, the design has been shown to be effective at preventing postoperative instability following primary THA and revision THA procedures [4,10–14]. Recent comparative studies have confirmed DM cups are better than standard cups at preventing implant dislocation [15,16]. Nevertheless, there are few studies on the outcomes of DM cups during revision for failed internal fixation of the proximal femur. Only Muller et al. have reported results of THA with a DM cup in this indication [17]. However, DM cups were used in only 6% of their cases.

We hypothesized that using DM cups in this specific context would reduce the risk of postoperative instability. The objective was to evaluate the implant dislocation rate after DM THA following failed internal fixation of a proximal femur fracture.

## MATERIALS AND METHODS

### *Study population*

This was a continuous, single center, retrospective study. All patients who underwent THA with a DM cup following failed internal fixation of a proximal femur fracture between May 2010 and December 2014 were included. Patients were excluded if they had suffered an infection after the initial fracture fixation procedure. Surgical revision by THA following failed internal fixation of a proximal femur fracture was indicated for symptomatic nonunion, avascular necrosis, poorly tolerated malunion or secondary migration of the fixation hardware (Table 1).

In all, 33 patients (4 men, 29 women) were included. Their mean age at time of surgery was 74 years  $\pm$  15 [27–96]. Their mean BMI was  $25 \pm 4.8$  [18.78–38.09]. The initial indication was a pertrochanteric fracture (n=22, 67%), femoral neck fracture (n=8, 24%) or base of femoral neck fracture (n=3, 9%). The initial internal fixation procedure consisted of the implantation of a dynamic nail (n=23, 70%), screw plate (n=4, 12%) or cannulated screw (n=6, 18%) (Table 1).

### *Surgical technique and implants used*

Single-stage surgery, combining hardware removal and DM THA implantation by the posterolateral approach was completed. The DM cups were from the NOVAE® product line (SERF®<sup>1</sup>). These are third-generation cups, forged in 316L stainless steel with a bilayer coating of plasma-sprayed titanium and hydroxyapatite. Depending on the bone quality and size of bone defect observed intraoperatively, two types of cups were used. The cases with satisfactory bone stock received a cup

---

<sup>1</sup>SERF®, Décines-Charpieu, France.

with press-fit fixation (NOVAE®SUNFIT TH) (Figure 1). In the cases where the bone defect did not allow for adequate primary stability, a tripod cup (press-fit fixation with 2 pegs and 1 proximal flange) was used (NOVAE® E TH).

The femoral stems used (TSF®<sup>2</sup>, Corail®<sup>3</sup>, Louxor®<sup>4</sup>) were either cementless or cemented, depending on the quality and quantity of femoral bone stock after removal of the fixation hardware.

The femoral heads were made of 316L stainless steel or cobalt-chrome alloy and were 22.2 mm or 28 mm in diameter. The 28-mm diameter heads were only implanted with cups sized 53 or larger, to ensure the polyethylene liner was at least 10 mm thick, in accordance with the manufacturer's recommendations.

### *Clinical and radiological assessments*

The clinical and radiological follow-ups were carried out at 45 days, 3 months, 6 months, 1 year, then every 2 years until the final follow-up. The patients' general condition was evaluated using the Charlson score and the American Society of Anesthesiologists (ASA) score [18–20]. The clinical outcomes were determined using the Postel Merle d'Aubigné (PMA) score and the Harris Hip Score (HHS) [21,22]. The duration of the surgical procedure was recorded. The radiological analysis was done with OSIRIX® software<sup>5</sup> to look for periprosthetic osteolysis, to determine the change in cup inclination between the immediate postoperative period and last follow-up, and to calculate the ARA score [23] and Brooker score [24]. All of the complications, such as dislocation, infection, loosening, and periprosthetic fractures were recorded.

### *Statistical analysis*

The primary outcome was the occurrence of a dislocation. Student's t-test, the Chi-square test and analysis of variance were used to analyze the distribution of quantitative variables, qualitative variables and variability factors. The statistical analysis was done using R®<sup>6</sup> software. The significance threshold was set at  $P < 0.05$ .

## **RESULTS**

### *Population and implants*

The mean postoperative follow-up was  $44 \pm 24$  months [2–83 months]. At the latest follow-up, 7 patients (21%) had died for reasons unrelated to the surgery and 0 patients were lost to follow-up. Preoperatively, the mean Charlson score was  $2.28 \pm 2.5$  [0–11], with 9 patients ASA 1, 11 patients ASA 2 and 13 patients ASA 3. The mean time between internal fracture fixation and the surgical revision was  $5 \pm 6$  months [0–22]. The mean operative time was  $100 \pm 34$  min [60–209]. The press-fit NOVAE SUNFIT® TH cup was used in 18 patients (55%), while the NOVAE E® TH tripod cup was used in 15 patients (45%). The 22.2-mm diameter head was used in most cases ( $n=31$ , 94%). On the femur side, 28 cementless stems (84%) and 5 cemented stems (15%) were used.

---

<sup>2</sup>SERF®, Décines-Charpieu, France

<sup>3</sup>DePuy-Synthes, Warsaw, IN, USA

<sup>4</sup>SEM, Créteil, France

<sup>5</sup>Pixmeo SARL, 266 Rue de Bernex, CH-1233 Bernex, Switzerland

<sup>6</sup>R Core Team

### *Clinical and radiological assessments*

The PMA and HHS scores significantly improved between the preoperative period and the latest follow-up visit, going from  $6.3 \pm 2.8$  [3–15] to  $14.8 \pm 2.6$  [9–18] ( $p < 0.001$ ) and from  $30.27 \pm 15.7$  [5–7] to  $80 \pm 13.8$  [50–100] ( $p < 0.001$ ) (Table 2), respectively. There were no significant differences between the preoperative scores of the three fixation method subgroups (Table 2).

At the latest follow-up, the mean ARA score was  $5.4 \pm 0.8$  [4–6] and the mean Brooker score was  $2 \pm 1$  [1–4]. Two patients had acetabular osteolysis in Gruen zone I while two patients had acetabular osteolysis in Gruen zone II. There were no cases of septic or aseptic loosening. There was no significant change in cup inclination, which went from  $47 \pm 8^\circ$  [32–60] in the immediate postoperative period to  $47 \pm 8^\circ$  [33–61] at the latest follow-up ( $p = 0.2$ ).

### *Complications*

Unfortunately, there were 6 intraoperative femur fractures: one metaphysis and diaphysis junction fracture require plate fixation and 5 greater trochanter fractures required wire cerclage.

Two early postoperative complications required surgical revision: one dislocation and one infection. The dislocation occurred early on after a fall and was considered post-traumatic. Open reduction was needed because closed reduction maneuvers failed. Thus as the last follow-up, the overall dislocation rate was 3%. The infection was deep and occurred early on. This patient was treated with a DAIR (debridement, antibiotics and implant retention) procedure; the infection healed and there was no recurrence at the last follow-up.

All of the intraoperative and postoperative complications occurred in patients who had initially been treated with a Gamma® Locking Nail (Stryker) for their femur fracture.

### **Discussion**

Our hypothesis is confirmed. Use of a DM cup in THA surgical revision of failed internal fixation of proximal femur fracture results in a low implant dislocation rate.

The first important finding is the high complication rate associated with THA procedures in this specific indication. With an overall complication rate of 21% ( $n=7$ ), our study falls at the upper end of published rates. In a meta-analysis, Mahmoud et al. reported a mean complication rate of 12% [7]. Only the studies by Müller et al. [17] (21% rate) and Dehaan et al. [25] (26% rate) found higher complication rates than in our study. The complication rate of revision THA after failed fracture fixation is significantly higher than following primary THA. Nilsson et al. [26] along with Oztürkmen et al. [27] found a 17% complication rate for revision THA versus 13% for primary THA in cases of proximal femur fracture. This higher rate can be explained by the technical difficulties encountered during revision surgery. Removal of the fixation hardware, muscle atrophy, reduced bone stock, leg length difference, or presence of malunion can modify the skeletal architecture and make it more difficult to position the implant. These factors contribute to the technical difficulty of THA revision with risk of intraoperative and postoperative complications.

The second important finding is that only patients with pertrochanteric fractures who underwent intramedullary nailing initially suffered a complication after revision THA. No complications were found in the patients who had a femoral neck fracture or base of femoral neck fracture. Thus there is a legitimate difference between intracapsular and extracapsular fractures. This observation is

consistent with published results. The Tetsunaga et al. [28] study of 50 patients also found complications only in the subset of patients with pertrochanteric fractures. Mehloff et al. [29] reported three cases of implant dislocation in the subgroup who had suffered a pertrochanteric fracture (n=13) but no complications in the subgroup who had suffered a femoral neck fracture (n=14). In our study, the large proportion of patients with a pertrochanteric fracture (66.6%) may explain our high complication rate.

One aspect that may explain these differences between fracture types is the greater complexity of the revision surgery procedure for pertrochanteric fractures. Revision of extracapsular fractures are more difficult technically and have a higher risk of complications. In these fractures, due to the appearance of malunion or even nonunion, all of the anatomical landmarks are modified, which complicates implant positioning. In addition, nail removal is an invasive surgical procedure that can lead to heterotopic ossification and lesions of the gluteus medius, which are known to contribute to instability.

Given these challenges, the use of DM cups seems relevant. Even if they do not eliminate all the complications inherent to this type of surgery, they reduce the risk of dislocation relative to THA studies using standard cups (Table 3). An analysis of the literature shows the dislocation rate with standard (non-DM) cups ranges from 0% to 20%: 3.1% for Hammad et al. [35], 4.9 % for Archibeck et al. [30], 6.4% for Shi et al. [36] and 19.6% for McKinley et al. [2]. With a 3% dislocation rate, our study of revision THA with DM cups falls in the lower end of this range. It has been shown that DM cups are effective at reducing the dislocation risk even in patients with major deficits in their hip abductors [37,38]. With a majority of cases in our study involving an extracapsular fracture, this insufficiency of the gluteus medius is likely largely present in our study. Nevertheless, we only found one case of dislocation. By reducing the risk of postoperative instability, DM cups appear to be a relevant treatment options when performing THA after failed proximal femur fracture fixation.

Our study has several limitations. The moderate size of the cohort contributed to reducing the statistical power of our analysis. Nevertheless, given the low incidence of this surgical indication, our study is comparable in terms of sample size to other published studies on this topic [33,34]. The lack of homogeneity of the various groups also makes the sub-group analysis difficult to interpret. Lastly, while the mean follow-up was relatively short, it was comparable to that of other published studies (between 1 and 7 years) [7,14,32].

## CONCLUSION

Use of DM cups in the context of THA after failed internal fixation of proximal femur fractures helps to reduce the risk of implant dislocation. Thus its use can be recommended in this indication with high risk of postoperative instability.

**Conflict of interest:** none

**Funding:** none

**Contributions:** Sandrine Boulat helped to collect data and write the manuscript; Thomas Neri helped to collect data and write the manuscript; Bertrand Boyer provided critical review of the manuscript; Rémi Philippot supervised the study and provided critical review of the manuscript; Frédéric Farizon supervised the study and provided critical review of the manuscript.



## REFERENCES

- [1] Lu-Yao GL, Keller RB, Littenberg B, Wennberg JE. Outcomes after displaced fractures of the femoral neck. A meta-analysis of one hundred and six published reports. *J Bone Joint Surg Am* 1994;76:15–25.
- [2] McKinley JC, Robinson CM. Treatment of displaced intracapsular hip fractures with total hip arthroplasty: comparison of primary arthroplasty with early salvage arthroplasty after failed internal fixation. *J Bone Joint Surg Am* 2002;84-A:2010–5.
- [3] Mehlhoff T, Landon GC, Tullos HS. Total hip arthroplasty following failed internal fixation of hip fractures. *Clin Orthop* 1991:32–7.
- [4] Darrith B, Courtney PM, Della Valle CJ. Outcomes of dual mobility components in total hip arthroplasty: a systematic review of the literature. *Bone Jt J* 2018;100-B:11–9.
- [5] Blomfeldt R, Törnkvist H, Ponzer S, Söderqvist A, Tidermark J. Displaced femoral neck fracture: comparison of primary total hip replacement with secondary replacement after failed internal fixation: a 2-year follow-up of 84 patients. *Acta Orthop* 2006;77:638–43.
- [6] Franzén H, Nilsson LT, Strömquist B, Johnsson R, Herrlin K. Secondary total hip replacement after fractures of the femoral neck. *J Bone Joint Surg Br* 1990;72:784–7.
- [7] Mahmoud SSS, Pearse EO, Smith TO, Hing CB. Outcomes of total hip arthroplasty, as a salvage procedure, following failed internal fixation of intracapsular fractures of the femoral neck: a systematic review and meta-analysis. *Bone Jt J* 2016;98-B:452–60.
- [8] McKee GK, Chen SC. The statistics of the McKee-Farrar method of total hip replacement. *Clin Orthop* 1973:26–33.
- [9] Bousquet G, Argenson C, Godeneche JL, Cisterne JP, Gazielly DF, Girardin P, et al. [Recovery after aseptic loosening of cemented total hip arthroplasties with Bousquet's cementless prosthesis. Apropos of 136 cases]. *Rev Chir Orthop Reparatrice Appar Mot* 1986;72 Suppl 2:70–4.
- [10] Philippot R, Camilleri JP, Boyer B, Adam P, Farizon F. The use of a dual-articulation acetabular cup system to prevent dislocation after primary total hip arthroplasty: analysis of 384 cases at a mean follow-up of 15 years. *Int Orthop* 2009;33:927–32.
- [11] Neri T, Philippot R, Farizon F, Boyer B. Results of primary total hip replacement with first generation Bousquet dual mobility socket with more than twenty five years follow up. About a series of two hundred and twelve hips. *Int Orthop* 2017;41:557–61.
- [12] Dangin A, Boulat S, Farizon F, Philippot R. Prevention of Dislocation Risk During Hip Revision Surgery with the Dual Mobility Concept; Study of a New Generation of Dual Mobility Cups. *Surg Technol Int* 2016;29:314–9.
- [13] Viste A, Desmarchelier R, Fessy M-H. Dual mobility cups in revision total hip arthroplasty. *Int Orthop* 2017;41:535–42.
- [14] Hamadouche M, Ropars M, Rodaix C, Musset T, Gaucher F, Biau D, et al. Five to thirteen year results of a cemented dual mobility socket to treat recurrent dislocation. *Int Orthop* 2017;41:513–9.
- [15] Prudhon J-L, Desmarchelier R, Hamadouche M, Delaunay C, Verdier R, SoFCOT T. Causes for revision of dual-mobility and standard primary total hip arthroplasty. *Int Orthop* 2017;41:455–9.
- [16] Caton JH, Prudhon JL, Ferreira A, Aslanian T, Verdier R. A comparative and retrospective study of three hundred and twenty primary Charnley type hip replacements with a minimum follow up of ten years to assess whether a dual mobility cup has a decreased dislocation risk. *Int Orthop* 2014;38:1125–9.
- [17] Müller F, Galler M, Zellner M, Bäuml C, Füchtmeier B. Total hip arthroplasty after failed osteosynthesis of proximal femoral fractures: Revision and mortality of 80 patients. *J Orthop Surg Hong Kong* 2017;25:2309499017717869.
- [18] Charlson ME, Pompei P, Ales KL, MacKenzie CR. A new method of classifying prognostic comorbidity in longitudinal studies: development and validation. *J Chronic Dis* 1987;40:373–83.
- [19] DRIPPS R. New classification of physical status. *Anesthesiology* 1963;24:111.

- [20] Saklad M. Grading of patients for surgical procedures. *Anesthesiol J Am Soc Anesthesiol* 1941;2:281–4.
- [21] Harris WH. Traumatic arthritis of the hip after dislocation and acetabular fractures: treatment by mold arthroplasty. An end-result study using a new method of result evaluation. *J Bone Joint Surg Am* 1969;51:737–55.
- [22] d'Aubigné RM, Postel M. The classic: functional results of hip arthroplasty with acrylic prosthesis. 1954. *Clin Orthop* 2009;467:7–27.
- [23] Massin P, Schmidt L, Engh CA. Evaluation of cementless acetabular component migration. An experimental study. *J Arthroplasty* 1989;4:245–51.
- [24] Brooker AF, Bowerman JW, Robinson RA, Riley LH. Ectopic ossification following total hip replacement. Incidence and a method of classification. *J Bone Joint Surg Am* 1973;55:1629–32.
- [25] DeHaan AM, Groat T, Priddy M, Ellis TJ, Duwelius PJ, Friess DM, et al. Salvage Hip Arthroplasty After Failed Fixation of Proximal Femur Fractures. *J Arthroplasty* 2013;28:855–9.
- [26] Nilsson LT, Stromqvist B, Thorngren KG. Secondary arthroplasty for complications of femoral neck fracture. *Bone Jt J* 1989;71-B:777–81.
- [27] Oztürkmen Y, Karamehmetoğlu M, Azboy I, Açıkgöz I, Caniklioğlu M. [Comparison of primary arthroplasty with early salvage arthroplasty after failed internal fixation for displaced femoral neck fractures in elderly patients]. *Acta Orthop Traumatol Turc* 2006;40:291–300.
- [28] Tetsunaga T, Fujiwara K, Endo H, Noda T, Tetsunaga T, Sato T, et al. Total hip arthroplasty after failed treatment of proximal femur fracture. *Arch Orthop Trauma Surg* 2017;137:417–24.
- [29] Mehlhoff T, Landon GC, Tullos HS. Total hip arthroplasty following failed internal fixation of hip fractures. *Clin Orthop* 1991:32–7.
- [30] Archibeck MJ, Carothers JT, Tripuraneni KR, White RE. Total hip arthroplasty after failed internal fixation of proximal femoral fractures. *J Arthroplasty* 2013;28:168–71. doi:10.1016/j.arth.2012.04.003.
- [31] Mortazavi SMJ, R Greenky M, Bican O, Kane P, Parvizi J, Hozack WJ. Total hip arthroplasty after prior surgical treatment of hip fracture is it always challenging? *J Arthroplasty* 2012;27:31–6.
- [32] Enocson A, Mattisson L, Ottosson C, Lapidus LJ. Hip arthroplasty after failed fixation of trochanteric and subtrochanteric fractures. *Acta Orthop* 2012;83:493–8.
- [33] Haidukewych GJ, Berry DJ. Hip arthroplasty for salvage of failed treatment of intertrochanteric hip fractures. *J Bone Joint Surg Am* 2003;85-A:899–904.
- [34] Winemaker M, Gamble P, Petrucci D, Kaspar S, de Beer J. Short-term outcomes of total hip arthroplasty after complications of open reduction internal fixation for hip fracture. *J Arthroplasty* 2006;21:682–8.
- [35] Hammad A, Abdel-Aal A, Said HG, Bakr H. Total hip arthroplasty following failure of dynamic hip screw fixation of fractures of the proximal femur. *Acta Orthop Belg* 2008;74:788–92.
- [36] Shi X, Zhou Z, Yang J, Shen B, Kang P, Pei F. Total Hip Arthroplasty Using Non-Modular Cementless Long-Stem Distal Fixation for Salvage of Failed Internal Fixation of Intertrochanteric Fracture. *J Arthroplasty* 2015;30:1999–2003.
- [37] . Schneider L, Philpott R, Boyer B, Farizon F. Revision total hip arthroplasty using a reconstruction cage device and a cemented dual mobility cup. *Orthop Traumatol Surg Res OTSR* 2011;97:807–13.
- [38] Philippeau J-M, Durand J-M, Carret J-P, Leclercq S, Waast D, Gouin F. Dual mobility design use in preventing total hip replacement dislocation following tumor resection. *Orthop Traumatol Surg Res OTSR* 2010;96:2–8.

## FIGURES AND TABLES

**Figure 1:**

**1a:** Failure of internal fixation of a right femoral neck fracture

**1b:** X-rays at 4 years' after the surgical revision by THA with DM cup (right leg)

**Table 1: Characteristics of study population**

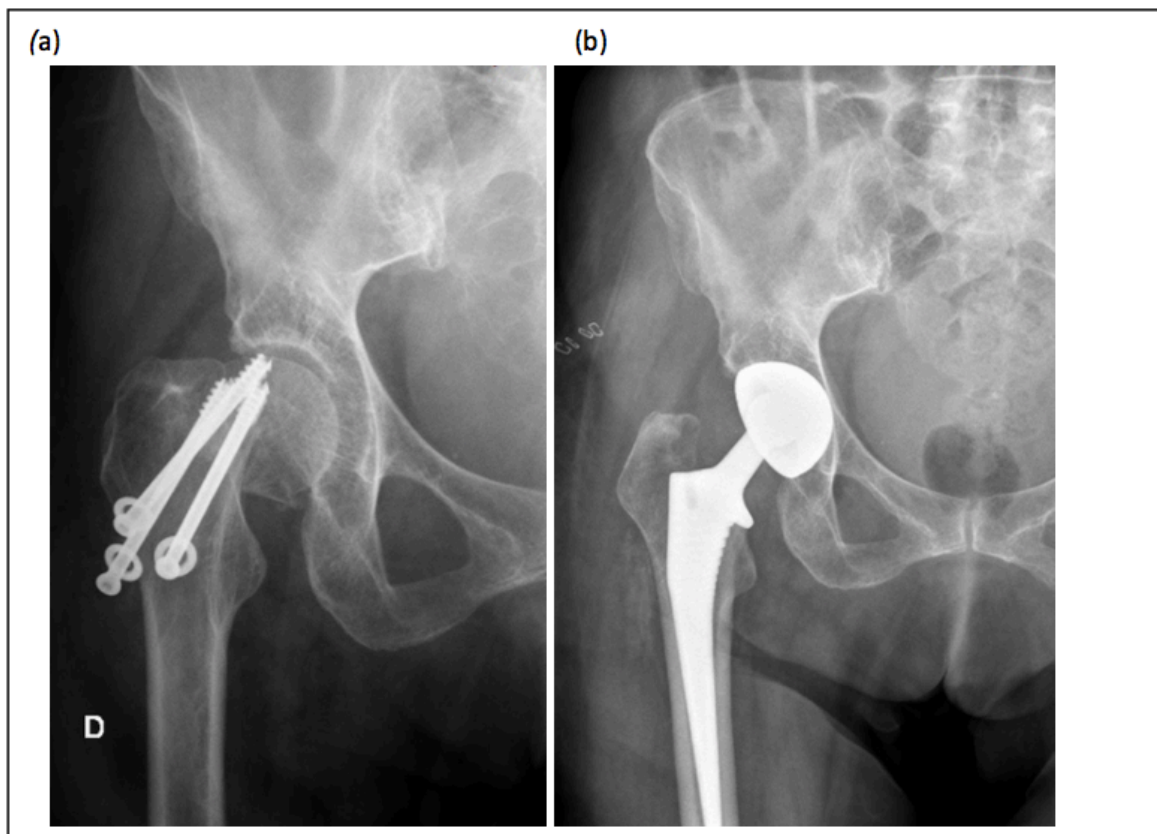
	Number (%)
Mean age	74
Sex	
Female	29 (87.7%)
Male	4 (12.2%)
Initial fracture	
Trochanteric	22 (66.6%)
Femoral neck	8 (24.2%)
Base of femoral neck	3 (9%)
Initial fixation	
Gamma nail	23 (69.6%)
Cannulated screw	6 (18.2%)
DHS	4 (12.1%)
Indication for reoperation	
Hardware migration	16 (48.5%)
Osteonecrosis	9 (27.3%)
Nonunion	6 (18.2%)
Malunion	2 (6%)

**Table 2: Characteristics of the various internal fixation subgroups**

	Nail (n=23)	Screw fixation (n=6)	DHS (n=4)	P value
Mean age	74	72	70	0.73
Gender:				
Female	21	5	3	
Male	2	1	1	
Mean Charlson score	2	3	3	0.82
Preoperative Harris Hip Score (mean)	28.3 ± 15.6	35.5 ± 20	33.25 ± 9	0.58
Preoperative PMA score (mean)	6.2 ± 2.7	7 ± 4	5.5 ± 1	0.71
Mortality (%)	17.3	16.6	50	0.34

**Table 3: Summary of relevant published studies**

Study	Nb. of patients	Initial fixation	Mortality rate (%)	Implants Standard cup: STD Dual mobility: DM	Approach	Dislocation rate
Mahmoud et al. (2016) [7]	168	–	–	–	–	7%
McKinley et al. (2002) [2]	107	Screw	23	STD (Charnley prosthesis)	Posterior	19.6%
Archibeck et al. (2013) [30]	102	Nail 3 Screw 42 Screw/plate 57	44.1	STD (Zimmer®)	–	4.9%
Mortazavi et al. (2012) [31]	154	DHS 61 Nail 10 Screw 83	4.5	STD (Stryker®, Biomet®)	Lateral	0%
Enocson et al. (2012) [32]	88	Nail 55 DHS 30 Screw/plate 3	16	STD (Stryker®, Zimmer®, DePuy®)	Hardinge 53 Moore 35	3.4%
Franzén et al. (1990) [6]	84	–	50	STD (Link®)	Posterior	4.7%
Muller et al. (2017) [17]	80	DHS 50 Nail 26 Screw 4	28	STD 93.7% DM 6.3% (Zimmer®)	Lateral	1.2%
Tetsunaga et al. (2017) [28]	50	Screw 15 Nail 17 DHS 9	–	STD (DePuy®, Zimmer®, Kyocera®)	Hardinge 38 Posterolateral 11 Watson-Jones 1	4%
Dehaan et al. (2013) [25]	46	Nail 16 Screw/plate 30	–	STD	–	6.5%
Haidukewych et al. (2003) [33]	32	Screw/plate	31.25	–	–	3.1%
Winemaker et al. (2006) [34]	36	Screw/plate 22	0	STD	–	0%
Hammad et al. (2008) [35]	32	–	18.7	STD	–	3.1%
Shi et al. (2015) [36]	31	DHS 17 Nail 8 Plate 6	9.6	STD	Posterolateral	6.4%
Our study	33	Nail 23 DHS 4 Screw 6	21	DM (Serf®)	Moore	3%



**Figure 1 :**