



HAL
open science

Pisiformectomy in advanced pisotriquetral joint arthritis: A retrospective study of 12 wrists with a mean follow-up of 7.5 years

Y.-K. de Almeida, C. Piessat, L. Athlani, F. Dap, G. Dautel

► **To cite this version:**

Y.-K. de Almeida, C. Piessat, L. Athlani, F. Dap, G. Dautel. Pisiformectomy in advanced pisotriquetral joint arthritis: A retrospective study of 12 wrists with a mean follow-up of 7.5 years. *Hand Surgery and Rehabilitation*, 2019, 38, pp.165 - 168. <10.1016/j.hansur.2019.01.005>. <hal-03484977>

HAL Id: hal-03484977

<https://hal.science/hal-03484977v1>

Submitted on 20 Dec 2021

HAL is a multi-disciplinary open access archive for the deposit and dissemination of scientific research documents, whether they are published or not. The documents may come from teaching and research institutions in France or abroad, or from public or private research centers.

L'archive ouverte pluridisciplinaire HAL, est destinée au dépôt et à la diffusion de documents scientifiques de niveau recherche, publiés ou non, émanant des établissements d'enseignement et de recherche français ou étrangers, des laboratoires publics ou privés.



Distributed under a Creative Commons CC BY-NC 4.0 - Attribution - Non-commercial use - International License

1 **Pisiformectomy in advanced pisotriquetral joint arthritis: a retrospective study of 12**
2 **wrists with a mean follow-up of 7.5 years**

3

4 **La pisiformectomie dans l'arthrose avancée de l'articulation piso-triquétrale : une**
5 **étude rétrospective au recul moyen de 7,5 ans**

6

7 **Abstract**

8 Pisiformectomy is the gold standard treatment for pisotriquetral arthritis resistant to
9 conservative treatment. We evaluated the long-term clinical and functional outcomes after
10 pisiformectomy in resistant pisotriquetral arthritis cases.

11 We retrospectively evaluated 11 patients (12 wrists), mean age of 59 years (49–69)
12 treated by pisiformectomy using a standardized surgical technique. Pisiformectomy was
13 performed for primary osteoarthritis in 10 cases, for post-traumatic osteoarthritis in 1 case
14 and for pisotriquetral instability in 1 case. The clinical and functional evaluation was carried
15 out by an independent examiner.

16 Mean time to review was 90 months (63–151). Pain on a visual analog scale (/10)
17 decreased significantly to 1.1 from 6.8 preoperatively. Mean range of motion was 79° in
18 flexion, 61.5° in extension, 18° in ulnar deviation and 36° in radial deviation. Mean grip
19 strength of the operated wrist was 86% of the non-operated wrist. Functional scores
20 significantly improved with a gain of 40 points for the QuickDASH and 53 points for the
21 PRWE.

22 Based on this long-term follow-up study, pisiformectomy seems to alleviate wrist pain
23 and improve the quality of life in a low-demand population with pisotriquetral osteoarthritis
24 resistant to conservative treatment. When compared to the pisotriquetral arthrodesis,
25 pisiformectomy is easier to perform, allows quicker mobilization of the wrist and leads to
26 good functional outcomes.

27

28 **Résumé**

29 La pisiformectomie représente la solution chirurgicale la plus utilisée en cas d'échec
30 d'un traitement médical bien conduit dans l'arthrose piso-triquétrale. L'objectif de cette étude
31 était d'évaluer les résultats cliniques et fonctionnels à long terme de cette technique.

32 Il s'agit d'une étude rétrospective monocentrique portant sur 11 patients (12
33 poignets), d'âge moyen 59 ans (49-69), opérés d'une pisiformectomie selon la même
34 technique chirurgicale. Dans 10 cas, l'étiologie était l'arthrose piso-triquétrale essentielle. Il y
35 avait un cas d'arthrose post-traumatique et une instabilité de l'articulation piso-triquétrale.
36 Une évaluation clinique et fonctionnelle a été réalisée par un examinateur indépendant.

37 Le recul moyen à la révision était de 90 mois (63-151). On retrouvait une amélioration
38 significative de la douleur avec une EVA moyenne évaluée à 1.1/10 (versus 6.8/10 en
39 préopératoire). Les mobilités moyennes du poignet étaient de 79°, 61,5°, 18° et 36° en
40 flexion, en extension, en inclinaison ulnaire et en inclinaison radiale respectivement. La force
41 de poigne était de 86% par rapport au côté controlatéral. Les scores fonctionnels étaient
42 également améliorés significativement avec un gain de 40 points pour le QuickDASH et 53
43 points pour le PRWE.

44 Au vu de cette étude au recul important, la pisiformectomie semble apporter
45 l'indolence et améliorer le confort de vie chez les patients porteurs d'une arthrose piso-
46 triquétrale avancée. En comparaison à l'arthrodèse piso-triquétrale, principale alternative
47 chirurgicale, la pisiformectomie a l'avantage de la simplicité de réalisation, mais également
48 des suites opératoires rapides permettant de maintenir les mobilités articulaires du poignet.

49

50 *Key words:* Arthritis; Pisiformectomy; Pisotriquetral joint

51

52 *Mots-clés :* Arthrose ; Pisiformectomie ; Articulation piso-triquétrale

53

54

55 **1. Introduction**

56 The pisotriquetral joint (PTJ) is a rare and an often-overlooked cause of ulnar-sided
57 wrist pain. Causes of pisotriquetral dysfunction are primary osteoarthritis (Fig. 1), post-
58 traumatic osteoarthritis (Fig. 2) and PTJ instability after carpal tunnel release [1]. Surgical
59 management is indicated in resistant cases after well-conducted conservative treatment. The
60 most used surgical options for PTJ osteoarthritis are pisiformectomy and pisotriquetral fusion
61 [2-8].

62 Functional and clinical results after pisiformectomy are rarely reported in the literature.
63 Almost all authors describe generally favorable outcomes with pain relief and no loss of wrist
64 motion. However, results for grip strength are contradictory [2-7]. In a recent biomechanics
65 study, O'Keefe et al. [9] demonstrated that greater flexor carpi radialis (FCU) force was
66 required to flex the wrist after pisiformectomy in cadaver model. They concluded that FCU
67 force decreased by 20% in the extreme range of motion and during fast movements.

68 The objective of our retrospective study was to report the long-term clinical and
69 functional outcomes after pisiformectomy.

70

71 **2. Patients and methods**

72 2.1. Population

73 From 2005 to 2012, 14 patients (15 wrists) with a mean age of 59 years (48–69) were
74 operated at our hospital. Pisiformectomy was performed for primary osteoarthritis in 83% and
75 post-traumatic osteoarthritis in 17%. All patients were included retrospectively.

76

77 2.2. Surgical technique

78 Pisiformectomy was performed by five senior hand surgeons. The surgical technique
79 was standardized and consisted in a V-shaped approach of the pisiform. The FCU sheath
80 was incised longitudinally to avoid damaging the ulnar neurovascular bundle. The next step
81 was to confirm PTJ arthritis before pisiform excision. The longitudinal tenotomy of the FCU
82 was closed with a slow resorbing running suture. The skin was closed with absorbable

83 sutures without the use of a drain. X-rays were taken systematically, and the patients wore a
84 cast with the wrist in neutral position for 15 days.

85

86 2.3. Clinical evaluation

87 Patients were contacted for a clinical and functional evaluation of the operated wrist.

88 A questionnaire was mailed to patients who could not easily return for the review visit.

89 Clinical evaluation criteria were pain at rest on a visual analog scale (VAS, /10), grip
90 strength (Kg.F) with the Jamar® hydraulic gauge (Arex™, Palaiseau, France), and wrist
91 motion in flexion, extension, radial and ulnar deviation. These data were compared to the
92 contralateral wrist. FCU instability was evaluated by moving the wrist passively in
93 flexion/extension and ulnar deviation. Sensation was evaluated with the Weber two-point
94 discrimination test (millimeter) of the fifth finger.

95 Functional results were determined using the standardized QuickDASH (Disabilities of
96 the Arm, Shoulder and Hand Score, /100) and PRWE (Patient-Rated Wrist Evaluation, /100)
97 [10-11] scores. Ulnar neuritis was evaluated with the DN4 questionnaire [12]. A score of 4/10
98 or higher was considered positive. Scar pain was evaluated by palpating the ulnar side of the
99 hand. The activity level after pisiformectomy was compared with the presurgery level (less,
100 equal, more). Finally, patients were asked to rate their satisfaction (“poor”, “moderate”,
101 “good” or “excellent”). Clinical and functional evaluations was carried by an independent
102 examiner.

103

104 2.4 Statistical analysis

105 Data were compared using the paired Student’s *t* test at a significance level of *p*
106 < 0.05.

107

108 **3. Results**

109 Three patients were excluded because they had a four-corner fusion (one case) or a
110 total wrist fusion (two cases) before the pisiformectomy procedure. Total wrist fusion was
111 performed after failure of proximal row carpectomy and pisiformectomy was performed
112 because of piso-ulnar impingement. Four-corner fusion was indicated for a SLAC
113 (ScaphoLunate Advanced Collapse) wrist. Finally, 11 patients (12 wrists) were included in
114 our analysis, of which two patients answered via a questionnaire only. The dominant hand
115 was involved in 67%. Eight patients (67%) were retired. Four patients (33%) had a carpal
116 tunnel release before the pisiformectomy. Mean time to final review was 90 months (63–151)
117 (Table 1).

118 At the final review, pain on VAS was significantly reduced ($p < 0.001$) from 6.8/10
119 preoperatively to 1.1/10. Grip strength was 23kg.F, which was 80% of the contralateral wrist
120 grip ($p = 0.07$). Mean range of motion was 79°, 61.5°, 36° and 18° or 97%, 86%, 97% and
121 92% compared to the contralateral side in flexion, extension, ulnar deviation and radial
122 deviation, respectively. All but extension ($p = 0.006$) were not significantly decreased
123 compared to the contralateral side. One patient reported having FCU instability. The mean
124 Weber two-point discrimination test was 3.5 mm and ranged from 2 to 6 mm at the fifth
125 fingertip.

126 The QuickDASH and PRWE improved significantly at the final review visit with a gain
127 of 40 points and 53 points, respectively ($p < 0.005$).

128 The DN4 score was positive in three cases (25%). However, all these patients had
129 preoperative symptoms of neuritis of the ulnar nerve according to the surgeon's pre-
130 operative findings (DN4 not done before surgery). Two patients (7%) complained of ulnar
131 pain at the wrist with scar tenderness. The level of activity was improved in 10 patients (83%)
132 and similar in two patients (17%). The overall outcome was rated as "good" or "excellent" in
133 all cases (Table 2).

134

135 **4. Discussion**

136 Pisiformectomy is a reliable option in advanced PTJ osteoarthritis resistant to
137 conservative treatment. Our study seems to confirm the good long-term results of
138 pisiformectomy on pain and functional outcomes. Our results are similar to those reported in
139 the literature. In 1978, Helal [2] reported on four racket-sport players complaining of ulnar-
140 sided pain of the wrist due to chondromalacia. A painless wrist was obtained after
141 pisiformectomy in all cases and all returned to their prior sports level. Other authors also
142 concluded that pisiformectomy was effective at providing pain relief [3-7].

143 Van Eijzeren et al. [6] and Lam et al. [7] reported no difference in grip strength
144 compared to the non-operated wrist in their case series of 11 patients (mean age of 47
145 years) and 19 patients (mean age of 45 years) respectively. Trail et al. [4], in a case series of
146 12 patients (mean age of 31 years), reported significantly decreased grip strength (86% of
147 the contralateral wrist).

148 O'Keefe et al [9], in a biomechanical study, found greater FCU excursion in extreme
149 range of motion after pisiformectomy and while carrying heavy loads because the pisiform
150 acts as a pulley. Increasing the FCU excursion leads to decreased FCU force during these
151 tasks.

152 Our results are similar to these studies with significant pain reduction and better
153 functional scores with a loss of grip strength. However, patients did not complain about this
154 loss of strength and the painless wrist was stable over the long term. We found no cases of
155 iatrogenic ulnar neuritis. The DN4 score was negative except in patients complaining of ulnar
156 neuritis before the pisiformectomy. The Weber two-point discrimination test found no
157 evidence of fingertip hypoesthesia.

158 PTJ arthritis can be primary, post-traumatic (fracture or ligament injury) or the result of
159 pisiform instability after flexor retinaculum release [1]. Interestingly, four patients (33%)
160 presented with PTJ pain a few months after carpal tunnel release. We hypothesize that
161 sectioning this strong stabilizer (flexor retinaculum) could trigger PJT instability that might
162 reveal underlying PTJ arthritis or accelerate the development of PTJ arthritis. Nevertheless,

163 Legré et al. [13], in a retrospective study of 55 patients undergoing minimally invasive carpal
164 tunnel release, did not find PTJ instability.

165 PTJ arthrodesis is an alternative to pisiformectomy. This procedure is preferred by
166 some authors [8,14] for young patients to prevent loss of grip strength. Nevertheless, this
167 technique requires extensive experience, a small surface area for bone healing and long-
168 term casting. Abrams et al. reported on a 14-year-old female gymnast complaining of PTJ
169 instability [8]. PTJ fusion was performed and painless wrist was obtained but she complained
170 of her wrist freezing in maximum flexion. Singer et al. performed PTJ fusion in a 22-year-old
171 male cyclist with painful PTJ instability [14]; a painless wrist was obtained with full range of
172 motion. Unfortunately, grip strength was not mentioned in both of these case reports.

173 Recently, Bellemère et al. [15] reported good results with pyrocarbon implant
174 interposition (Pyrocardan®, Tornier™, Grenoble, France) in eight patients with a
175 symptomatic primary PTJ osteoarthritis. Painless wrist was obtained in all patients with a
176 95% range of motion in flexion–extension compared to the contralateral wrist and no loss of
177 grip strength. One implant dislocated and was successfully treated surgically by repositioning
178 the implant with a Gore-Tex suture. Outcomes were favorable with early return to work.

179

180 **5. Conclusion**

181 Given the results of this study, pisiformectomy appears to yield good clinical and
182 functional outcomes over many years. Grip strength was not significantly decreased but only
183 12 cases were available for evaluation. The simplicity of pisiformectomy and early
184 mobilization make this operation a valuable option for advanced, recalcitrant PTJ
185 osteoarthritis regardless of its etiology.

186

187 **Conflict of interest:**

188 The authors declared no potential conflicts of interest with respect to the research,
189 authorship, and/or publication of this article.

190

191 **Informed consent:** The participants had given informed consent for the study.

192

193 **References**

194 1. Le Nen D, Saraux A, Dubrana F, Lefèvre C. Pathologie de l'articulation piso-
195 triquétrale, Démembrement à propos de 26 cas. *Ann Orthop Ouest* 2000;32:129-34.

196 2. Helal B. Racquet player's pisiform. *Hand* 1978;10:87-90.

197 3. Carroll RE, Coyle MP Jr. Dysfunction of the pisotriquetral joint: treatment by excision
198 of the pisiform. *J Hand Surg Am* 1985;10:703-7.

199 4. Trail IA, Linscheid RL. Pisiformectomy in young patients. *J Hand Surg Br*
200 1992;17:346-8.

201 5. Pierre A, Le Nen D, Hu W, Dubrana F, Saraux A, Chaise F. Traitement des douleurs
202 piso-triquétrales par exérèse du pisiforme : à propos de 15 cas. *Chir Main.* 2003;22:37-42.

203 6. Lam KS, Woodbridge S, Burke FD. Wrist function after excision of the pisiform. *J*
204 *Hand Surg Br* 2003;28:69-72.

205 7. Van Eijzeren J, Karthaus RP. The effect of pisiform excision on wrist function. *J Hand*
206 *Surg Am* 2014;39:1258-63.

207 8. Abrams R, Tontz W. Pisotriquetral arthrodesis as an alternative to excision for
208 pisotriquetral instability in high demand patients: a case report in a gymnast. *J Hand Surg*
209 *Am* 2006;31:611-4.

210 9. O'Keefe KD, Werner FW, Boyette M, Palmer AK, Garcia-Elias M, Harley BJ. Effect of
211 pisiform excision or pisotriquetral arthrodesis as a treatment for pisotriquetral arthritis: a
212 biomechanical study. *J Hand Surg Am* 2013;38:1913-18.

213 10. Hudak PL, Amadio PC, Bombardier C. Development of an upper extremity outcome
214 measure: the DASH (disabilities of the arm, shoulder and hand). The Upper Extremity
215 Collaborative Group (UECG). *Am J Ind Med* 1996;29:602-8.

216 11. MacDermid JC, Turgeon T, Richards RS, Beadle M, Roth JH. Patient rating of wrist
217 pain and disabilities: a reliable and valid measurement tool. *J Orthop Trauma* 1998;12:577-
218 86.

- 219 12. Bouhassira D, Attal N, Alchaar H, Boureau F, Bruxelle J, Cunin G, et al. Comparison
220 of pain syndromes associated with nervous or somatic lesions and development of a new
221 neuropathic pain diagnostic questionnaire (DN4). *Pain* 2005;114:29-36.
- 222 13. Caubère A, Butin C, Guilhem K, Levadoux M, Légré R, Nguyen MK. Is there
223 pisotriquetral instability after carpal tunnel release? Retrospective study of 55 cases. *Chir*
224 *Main* 2014;33:286-90.
- 225 14. Singer G, Eberl R, Hoellwarth ME. Pisotriquetral arthrodesis for pisotriquetral
226 instability: case report. *J Hand Surg Am* 2011;36:299-303.
- 227 15. Bellemère P, Aribert M, Choughri H, Leroy M, Gaisne E. Treatment of pisotriquetral
228 arthritis by pyrocarbon interposition arthroplasty. *J Wrist Surg* 2018;7:2-20.
- 229

230 **Figure captions**

231 **Fig. 1.** X-rays of primary pisotriquetral joint (PTJ) osteoarthritis (wrist in 30° supination)

232 **Fig. 2.** T2-weighted magnetic resonance imaging of a case of post-traumatic PTJ

233 osteoarthritis due to PTJ instability with rupture of the pisohamate ligament (ulnar deviation
234 of the pisiform)

235

236 **Table titles**

237 Table 1. Characteristics of the study population (both wrists were operated in patient 1).

238 *POA*: primary OA

239 Table 2. Clinical and functional outcomes after pisiformectomy (two patients were contacted
240 by mail). *VAS*: visual analog scale

FIGURES

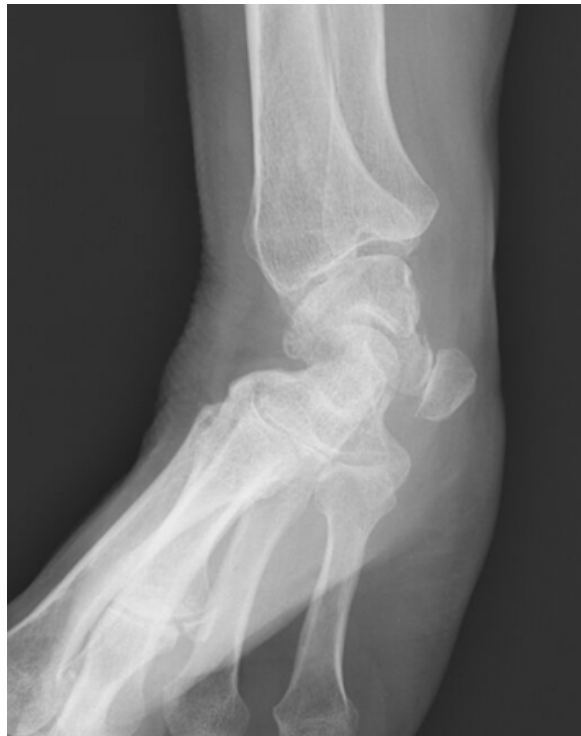

Fig. 1. X-rays of primary pisotriquetral joint (PTJ) osteoarthritis (wrist in 30° supination)

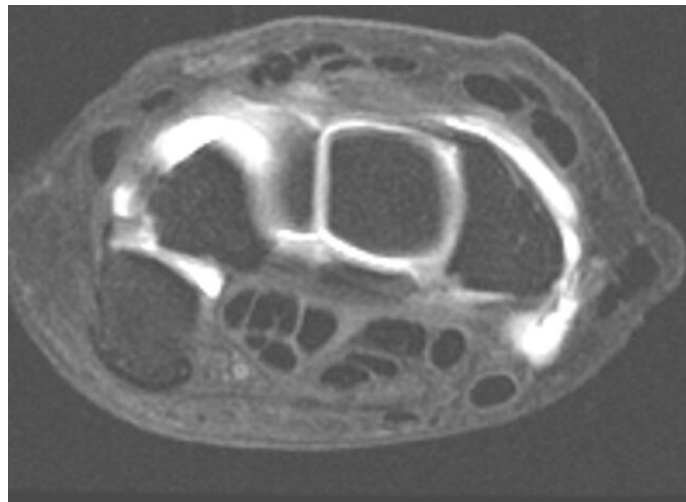


Fig. 2. T2-weighted magnetic resonance imaging of a case of post-traumatic PTJ osteoarthritis due to PTJ instability with rupture of the pisohamate ligament (ulnar deviation of the pisiform)

TABLES

Table 1. Characteristics of the study population (both wrists were operated in patient 1). *POA* : primary osteoarthritis

Patient	1	2	3	4	5	6	7	8	9	10	11
Age	66	64	52	69	48	55	53	64	62	57	52
Etiology	POA	POA	Traumatic	POA	Traumatic	POA	POA	POA	POA	POA	POA
Affected wrist	Bilateral	Right	Right	Right	Right	Left	Right	Left	Right	Right	Right
Dominant hand	Right	Left	Right	Right	Right	Right	Right	Right	Right	Right	Right
Ulnar nerve neuritis	-	-	+	-	+ (severe cubital tunnel syndrome)	+	-	-	+	-	-
Occupation	Retired	Retired	Manual labor	Retired	Retired	Retired	Retired	Office worker	Office worker	Retired	Office worker
Anterior carpal tunnel release (delay in months)	Yes (15 and 23)	No	No	No	No	No	Yes (wrist pain before carpal tunnel release)	No	Yes (24)	Yes (4)	No

Table 2. Clinical and functional outcomes after pisiformectomy (two patients were contacted by mail). VAS: visual analog scale

	Preoperative status	Postoperative status	p value
Pain at rest (VAS, /10) (n=11)	6.8	1.1	< 0.005
QuickDASH score /100 (n=11)	68.4	27.6	< 0.005
PRWE score /100 (n=11)	75.4	22.1	< 0.005
DN4 score /10 (n=11)	/	1.7	
Flexor carpi ulnaris instability (n=9)	/	1	
Weber two-point discrimination test (mm) (n=9)	/	3.5	
	Operated wrist (n=9)	Contralateral wrist (n=7 because one patient was operated on both side)	
Flexion (°)	79.5	82.5	0.05
Extension (°)	61.5	71.5	0.006
Ulnar deviation (°)	18	19.5	0.19
Radial deviation (°)	36	37	0.17
Wrist grip strength (kg.F)	22.9	28.9	0.07

