



**HAL**  
open science

## **Cricoarytenoid Joint Ankylosis: Classification and Transoral Laser Microsurgical Treatment**

Ihab Atallah, Manjunath Mk, Ahmad Al Omari, Christian Adrien Righini, Paul F. Castellanos

► **To cite this version:**

Ihab Atallah, Manjunath Mk, Ahmad Al Omari, Christian Adrien Righini, Paul F. Castellanos. Cricoarytenoid Joint Ankylosis: Classification and Transoral Laser Microsurgical Treatment. *Journal of Voice*, 2019, 33, pp.375 - 380. <10.1016/j.jvoice.2017.11.020>. <hal-03484375>

**HAL Id: hal-03484375**

**<https://hal.science/hal-03484375v1>**

Submitted on 20 Dec 2021

**HAL** is a multi-disciplinary open access archive for the deposit and dissemination of scientific research documents, whether they are published or not. The documents may come from teaching and research institutions in France or abroad, or from public or private research centers.

L'archive ouverte pluridisciplinaire **HAL**, est destinée au dépôt et à la diffusion de documents scientifiques de niveau recherche, publiés ou non, émanant des établissements d'enseignement et de recherche français ou étrangers, des laboratoires publics ou privés.



Distributed under a Creative Commons CC BY-NC 4.0 - Attribution - Non-commercial use - International License

# **Cricothyroid joint ankylosis: classification and transoral laser microsurgical treatment**

Ihab Atallah, MD-PhD<sup>1,2</sup>; Manjunath MK, MD<sup>1,3</sup>; Ahmad Al Omari, MD<sup>1,4</sup>;

Christian Adrien Righini, MD-PhD<sup>2</sup>; Paul F. Castellanos, MD, FCCP<sup>1</sup>

## **Affiliation of authors:**

1. Division of Otolaryngology, Department of Surgery, University of Alabama at Birmingham, Boshell Building 563, Birmingham, AL 35233, USA
2. Otolaryngology-Head & Neck Surgery Department, Grenoble University Hospital, BP 217, 38043 Grenoble Cedex 09, France
3. Colombia Asia Referral Hospital, Yeshwanthpur, Bangalore, India
4. Division of Otolaryngology, Department of Special Surgery, Faculty of Medicine. Jordan University of Science and Technology, Irbid, Jordan

This work was presented in the meeting of the American Laryngological Association (San Diego, CA, 2017)

**Conflict of interest:** none

## **Abstract**

**Objective:** To describe a graduated approach for effective transoral mobilization of cricoarytenoid joint ankylosis (CJA) in the context of the Bogdasarian system of classifying posterior glottic web-based stenosis (PGWS).

**Study Design:** Retrospective cohort study through data from medical records and operative notes. A consecutive series of 23 patients who underwent reconstructive transoral laser microsurgery for PGWS with a significant degree of CJA (Bogdasarian Grade III-IV), were included in the study.

**Methods:** Techniques necessary to remobilize their cricoarytenoid joints were reviewed in the context of the extent of scar tissue found.

**Results:** Arytenoids with CJA were successfully mobilized by resection of the fused portion of the cricoid and arytenoid cartilages achieving respiratory improvements as well as decannulation of tracheostomy dependent patients. The majority (83%) of patient's voices improved. All patients tolerated a full diet after the procedures. Cases with Bogdasarian Grade III PGWS with minor unilateral fixation should be classified as IIIa. If the fixation is severe, the case should be classified as a Grade IIIb. Grade IVa would indicate both sides were mildly to moderately ankylosed and Grade IVb involves ankylosis of both joints with subtotal or complete fusion of at least one; it presents the greatest surgical challenge.

**Conclusion:** We provided effective trans-oral techniques for the re-mobilization of cricoarytenoid joint, along with a classification of CJA that aims to standardize the severity of disease in the context of the existing and widely accepted Bogdasarian scale.

**Keywords:** Cricoarytenoid joint ankylosis; Posterior glottic stenosis; Reconstructive transoral laser microsurgery; Airway reconstruction; Arytenoid remobilization; Arytenoid fixation

## **1. Introduction**

Cricoarytenoid joint arthritis and subsequent ankylosis were first described by Montgomery in 1955<sup>1</sup>. Arthritis of the cricoarytenoid joints can be the result of traumatic or prolonged endotracheal intubation, arytenoid cartilage dislocation during intubation, tumorous infiltration in laryngeal and hypopharyngeal carcinoma, radiation therapy, rheumatoid arthritis, external trauma, and caustic inhalation and ingestion<sup>1-5</sup>. Cricoarytenoid joint ankylosis (CJA) is frequently associated with posterior glottic web-based stenosis (PGWS), which is a narrowing of the airway at the posterior aspect of the larynx due to the development of a scar tissue in the interarytenoid space. Bogdasarian and Olson provided a scheme for classifying PGWS into four groups<sup>6</sup>. Grade III involves a posterior commissure scar or web with fixation of one cricoarytenoid joint. Grade IV, the most difficult to treat, involves fixation of both cricoarytenoid joints.

For Grade III and IV PGWS, complex laryngoplasty procedures are needed, including arytenoidectomy, or as proposed in this work, cricoarytenoid joint remobilization<sup>7-9</sup>. The removal of arytenoid tissue is needed for two purposes: 1. To improve laminar airflow through the supraglottis and glottis; 2. To enable the return of functional movement of the cricoarytenoid joint complex after healing. The aim of this study is to describe a series of graduated techniques that effectively remobilize or address ankylosed cricoarytenoid joints and a proposed addition to the Bogdasarian system of classifying PGWS to include a taxonomy of the severity of CJA.

## **2. Material and Methods**

### **2.1. Patient selection and preoperative evaluation**

A consecutive cohort of adult patients undergoing reconstructive transoral laser microsurgery (R-TLM) for posterior glottic web-based stenosis (PGWS) diagnosed preoperatively by flexible

scope examination and confirmed during peroperative examination, was reviewed (2011-2015). This study was approved by the Human Studies Institutional Review Board of University of Alabama at Birmingham. All procedures performed in the study were in accordance with the ethical standards of the institution and with the 1964 Helsinki declaration and its later amendments. 23 cases were found to have a significant degree of cricoarytenoid joint ankyloses (Bogdasarian Grade III-IV) with outcome information sufficient to know the mobility of the cricoarytenoid joint's preoperatively and post treatment outcomes.

All patients underwent trans-nasal flexible laryngotracheoscopy under local anesthesia with a flexible endoscope (KayPENTAX, New Jersey, USA) to confirm the diagnosis and to assess the mobility of the vocal folds and the arytenoids. All tracheostomy patients underwent trans-stomal retrograde endoscopy of the vocal folds and the subglottis. All patients without a tracheostomy filled out a Dyspnea Index questionnaire (score range: 0 to 40) preoperatively and 12 weeks postoperatively<sup>10</sup>. Voice and swallowing were assessed preoperatively and postoperatively.

## **2.2. Surgical techniques**

The procedure is performed under general anesthesia. All patients are treated with a dose of preoperative systemic steroids (commonly 125 mg IVP of methylprednisolone, Solu-medrol®, Sandoz, Basel, Switzerland) and broad spectrum IV antibiotics (commonly, piperacillin-tazobactam 3.75 gm IV, Zosyn®, Pfizer, Inc. NYC, NY, USA). An oral endotracheal tube of an appropriate size is placed when intubation is possible. When per-oral intubation is not possible because of a too narrow respiratory aperture, the case is started with jet ventilation alone. A Lindholm laryngoscope (8587 A, KARL STORZ, Germany) is used for the suspension micro-laryngoscopy, which provides a wide aperture for bimanual manipulation of instruments.

The endotracheal tube is removed and jet ventilation is used through the laryngoscope for the rest of the surgery. For patients with a tracheostomy, ventilation is maintained through the trans-stomal placement of a cuffed endotracheal tube.

The larynx is then examined with a 30°HOPKINS® Telescope (49046 BA, KARL STORZ, Germany). At the start of the endoscopy, the active mobility of the arytenoids is tested through direct mechanical stimulation of the larynx with careful observation, since neuromuscular blockade is commonly not fully effective. Afterwards, passive mobility of the cricoarytenoid joints is tested using a laryngeal spatula. CJA can then be confirmed or ruled out. These factors are used to quantify the nature of the PGWS by the Bogdasarian scale as Grade II-IV<sup>5</sup>.

A Leica F-40 operating microscope (Leica® Model M-525, Germany) with an Encore II Ultrapulse® scanning CO<sub>2</sub> laser and a digital AcuBlade® robotic joystick controller (Lumenis, Israel) is used. A 0.9-1.2 mm circle scanning laser figure is used to excavate and remove the inter-arytenoid mucosa with the underlying scar tissue. Additionally, a curved 2.0 mm line is used to cut the web from the contour of the arytenoid bodies. If the arytenoids spring apart, then the fixation was purely a tethering and not CJA, proving that this is a Grade II fixation.

If one or both arytenoids are still the fixed in the midline, mobilization may be obtained through laryngeal balloon dilatation using an 18 mm balloon (M00550310, Boston Scientific, Natick, MA, USA). If one or both became mobile, this was likely a lower grade PGWS (Grade II) or a mild form of a Grade III or even IV.

For the cases where no meaningful mobility returns, attention is then turned to the cricoarytenoid joints. The postero-medial aspect of the joint is exposed after removal of any

fibrous tissue at this level. A 1.0 to 2.0 mm line scanning laser is used in an oblique fashion to cut through the joint line. The joint space can be entered postero-laterally with alligator forceps and bluntly explored to free it up. Any residual bony callus is removed using a Kleinsasser cutting forceps (8591MK, KARL STORZ, Germany) in order to achieve a full mobilization of the arytenoid. A detailed taxonomy of arytenoidectomy and remobilization follows.

### **2.2.1. Graduated endoscopic arytenoidectomy taxonomy**

There is no way to describe all of the possible disease combinations that could be encountered. Therefore, a listing of the general types of “arytenoidectomy” options is worthwhile, emphasizing that any given patient may require more than one of these serially or during the same case.

The graduated approach to arytenoid surgery used in these procedures is as follows (Figure 1):

Type I: the removal of protruding arytenoid cartilage to improve laminar air flow through the injured posterior commissure without specific joint work. The mucosa over the cartilage is commonly vaporized in the process of removing the obstructing cartilage. Then the remaining cartilage is made concave (Laser settings: 1.0 mm circle with 0.1 second delay) to allow the mucosa to close over it and protect it during healing.

Type II: The lysis of the ankylosis with or without removal of minor medial or posteromedial arytenoid. This requires the exposure of the posterior arytenoid from the top of the body down to the cricoarytenoid joint. The perichondrium is separated from the cartilage maintaining its attachments to the interarytenoid muscle fibers to improve movement once it heals. Alligator forceps are then insinuated into the space posterior to the arytenoid until the joint is reached. Blunt dissection is performed to see if only minor disruption is needed. If successful, cup forceps can be passed into the same location and the involved tissues can be removed. If not

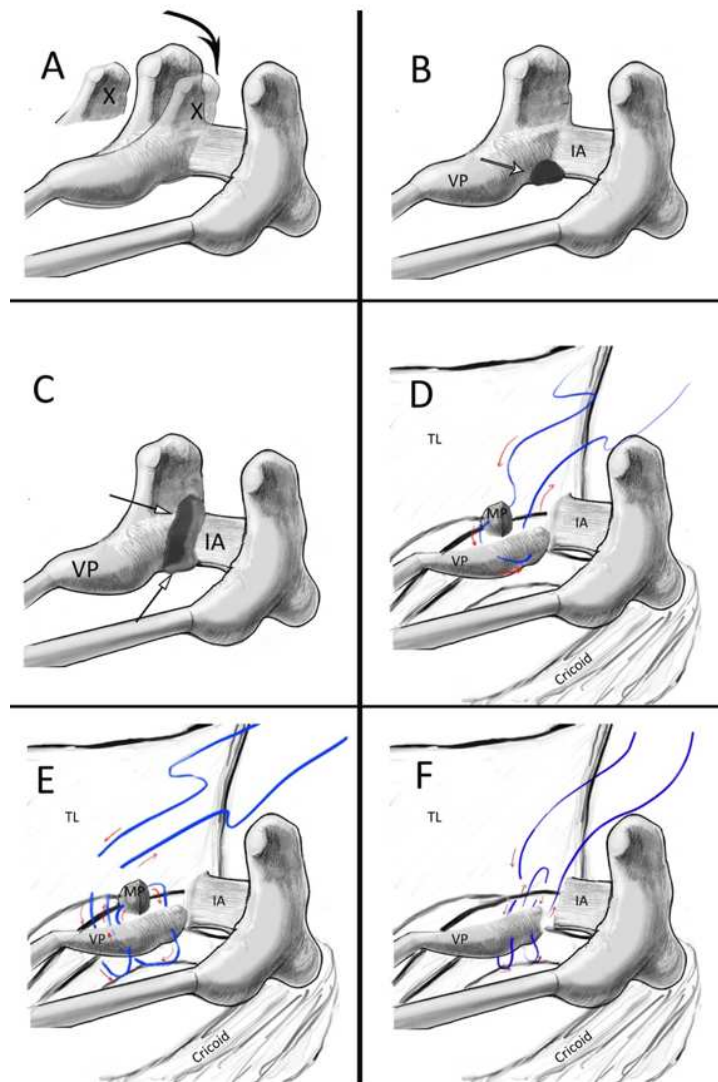
successful, cup forceps (described above) can be used to remove enough cartilage to enable movement of the remaining arytenoid. This may be a small amount or a large amount as in a Type III resection below.

Type III: Removal of a large portion of the posteromedial arytenoid body with the fused articular surface. As in a Type II above but with much more tissue removed. Bleeding is common during this scale of resection but still responds to topical epinephrine on cottonoid pledgets. If not, careful suction cautery can be performed, mindful of the posterolateral location of the recurrent laryngeal nerve trunk or even a divided posterior branch and taking care to avoid an electrical neurotomy, which would may prevent abduction.

Type IV: A central arytenoidectomy is a parasagittal resection of the center of the arytenoid, from its top down to the cricoarytenoid joint capsule. This makes room for a wider airway without impairing the return of the movement of the arytenoid. This is predicated on the separation of the medial face of the arytenoid attached to the vocal process and the vocal ligament. Some portion of the central arytenoid is then separated from the muscular process/lateral arytenoid to both encompass the ankylosed portion and enable the movement of the arytenoid. The arytenoid is then reconstituted alone or as part of a lateralization procedure to open the airway widely and enable the healing of a mobile cricoarytenoid complex. Even a firmly lateralized arytenoid/vocal fold complex will break free from its mooring if it heals and movement is physiologically and neurologically possible.

Type V: A near total arytenoidectomy involves the removal of the residual arytenoid and the surrounding soft tissues that may still be encumbering the airway, preserving only the medial face of the arytenoid attached to the vocal process and ligament. This is done only after less

radical maneuvers have not worked and an inadequate airway is still present. Some of the thyroarytenoid muscle may need to be removed to allow for a straight surface of the vocal fold, post lateralization. This improves the airway but more importantly, it enables a much better voice.



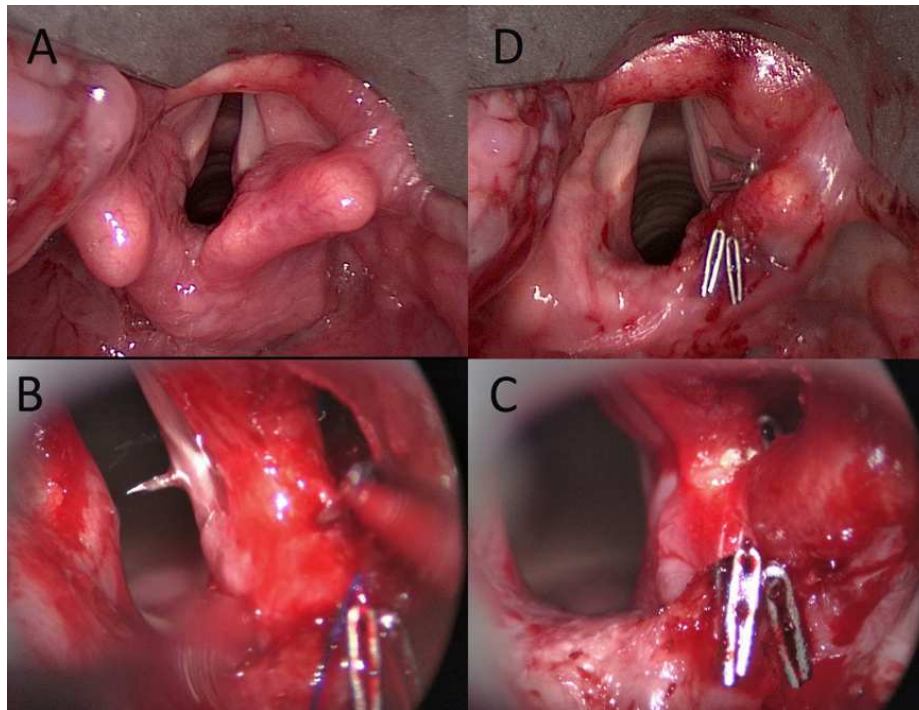
**Figure 1:** Various types of arytenoidectomy. (A) Minimal resection of the arytenoid body that is deformed or distorted by scar and that may be impeding air flow and is considered a “Type I” resection. (B) Depicts the “Type II” posteromedial removal of a small amount of cartilage from the adhesion of the cricoarytenoid joint in a Grade IIIa or IVa fibrosis. (C) The greater degree of fibrosis can be addressed by the process depicted in this panel with a deep excavation of the posteromedial aspect of the damaged cartilage that is going as deeply lateral as the resection is going superiorly in the image. (D) Depicts a “Type IV” (central arytenoidectomy) without lateralization and (E) is the same surgery with lateralization. (F) depicts a “near total” or “Type V” arytenoidectomy with the remains of the medial arytenoid being hoisted as far back and laterally as possible to produce a straight cord with a large airway. TL = Thyroid Lamina; VP = Vocal Process; IA = Interarytenoid.

In addition to cricoarytenoid joint remobilization in the setting of PGWS treatment, a post-cricoid mucosal flap is performed to separate and cover the tissue left raw after the removal of the posterior glottic web. This is performed during the same surgery and has been described in our previous work<sup>9</sup>. Other laryngologic and tracheal procedures may be performed during the same or subsequent surgeries as indicated. A brief description of two adjunctive techniques, trans-oral “supraglottic laryngotomy” and a trans-oral suture lateralization follows (Figure 2).

The supraglottic laryngotomy is an approach to the peri-arytenoid area through the supraglottic larynx involving a sigmoid laser incision through the aryepiglottic fold (AEF) starting at the interarytenoid mucosa (for this application) and extending to the anterolateral AEF. Laser and blunt dissection will expose the arytenoid and allow the work that includes the Type IV central arytenoidectomy and the suture lateralization. Suction cautery is frequently needed to control branches of the inferior and superior laryngeal arteries. Clips, like those used for suture fixation, are also sometimes needed.

Transoral suture lateralization is a technique through which the remobilized arytenoid, regardless of the procedure used, can be laterally displaced. We use a 4-0 polypropylene suture on a cutting needle (Prolene 4-0 on P-3 needle; Ethicon, Johnson and Johnson, Indiana, USA). Briefly, the needle is placed into the soft tissue overlying the thyroid lamina and picked up in the laryngotomy wound below the level of the vocal process of the arytenoid. It is then passed into the lumen of the airway and back through to the wound through the cartilage of the arytenoid. In these cases, the medial face of the arytenoid may be separated from the rest of the arytenoid cartilage and some (or most of it) may have been removed. Then the suture is passed posteriorly to encompass the residual arytenoid to “reconstitute” it. In the case of a Type V near total arytenoidectomy, the suture is used to bring the medial face of the arytenoid as

posteriorly and laterally as possible. It is usually anchored to the soft tissue overlying the posterior inside of the thyroid lamina and the cricoid cartilage giving a firm purchase to hoist this tissue postero-laterally. There is no need to do a supraglottic laryngotomy in this last case since the entire area is open and no additional opening of the supraglottis is needed for access.



**Figure 2:** Lateralization suture in a case with a medially displaced fibrosed cord with airway obstruction. (A) Depicts the position of the right arytenoid post onset of neuromuscular blockage. Palpation demonstrated a hard to move arytenoid with the top of the arytenoid being somewhat tipped in and the vocal process being medially oriented. (B) Depicts the supraglottic laryngotomy and the prolene suture being passed from within it to draw the vocal process and body of the arytenoid laterally. (C) Depicts the same view after the lateralization suture is drawn and clipped into a lateralized position. (D) Depicts the finished product. The additional sutures seen at the posterior aspect of the right aryepiglottic fold are of the “Type I” partial arytenoidectomy used to trim the top of the medially displaced arytenoid. This example was used instead of a CJA associated with a webbing process because it makes the arytenoid work and displacement clearer than a more complex image of the posterior commissure being opened widely.

### 2.3. Postoperative care

Patients are admitted and managed postoperatively in an ICU or an intermediate care unit for the first 1-2 days until they their airway is deemed stable. They also get respiratory care including nebulized 3% sodium chloride (4 cc BID and PRN). Broad spectrum antibiotics, commonly, piperacillin-tazobactam 3.75 gm every 6 hours, is administered to protect the

laryngeal cartilage. After discharge, they are followed-up in the outpatient clinic at 2, 6, and 12 weeks postoperatively.

**3. Results**

All arytenoids with cricoarytenoid joint ankyloses were successfully mobilized by the resection of the ankylosed portion of the cricoid and arytenoid cartilages achieving respiratory improvements as well as decannulation of all tracheostomy dependent patients (n=11). The only exceptions were patients who needed a “near total” arytenoidectomy (Type V) where no movement is expected after this permanent lateralization (n=6). All patients without a tracheostomy were complaining preoperatively of dyspnea (n=12) and showed significant improvement of their symptoms on the Dyspnea Index with a mean postoperative improvement of 16.17 (p< 0.001) (Table I).

**Table I:** Change in the Dyspnea Index (maximum score=40) in patients with cricoarytenoid joint ankylosis (CJA) who underwent endoscopic remobilization of their fixed arytenoids

	Dyspnea Index
Mean preoperative value	30.5
Mean postoperative value	14.33
Postoperative difference (P <0.0001)	16.17

Table II shows the distribution of grades of CJA among our cohort. Only one patient who did not have a tracheostomy in this series got a tracheostomy as part of their care. This was also the only patient who did not receive preoperative IV methylprednisolone. The number of surgeries each type of patient required for definitive improvement is described in Table III.

**Table II:** Cricoarytenoid joint ankylosis (CJA) classification in patients with grade III and IV posterior glottic web-based stenosis (PGWS) who underwent reconstructive transoral laser microsurgeries (R-TLM) in this study.

Bogdasarian Classification of PGWS	Grade of PGWS				Total (n)
	III (n)		IV (n)		
Proposed classification	IIIa	IIIb	IVa	IVb	
Patients with tracheostomy	0	1	2	8	11
Patients without tracheostomy	1	1	2	8	12
<b>Total</b>	3		20		23

Grade IIIa: minor unilateral fixation, Grade IIIb: severe unilateral fixation, Grade IVa: mild bilateral fixation of the arytenoids, Grade IVb: bilateral fixation of the arytenoids with severe to complete fusion within at least 1 joint

**Table III:** Average number of surgeries required based on the modified Bogdasarian Scale

Modified Bogdasarian Grade	IIIa	IIIb	IVa	IVb
<b>Without Tracheostomy</b>	1-1 n=1	3-3 n=1*	1-1 n=2	1.3-1.8 n=8
<b>With Tracheostomy</b>	none	2-3 n=1	1-3 n=2	2-3.5 n=8

The first number is the number of surgeries which involved arytenoid procedures. The second number is the total number of surgeries which patients required until they reached the endpoint of achieving decannulation or significant improvement in dyspnea in non-tracheotomized patients. The second number includes surgeries which

involved other laryngeal and tracheal procedures; it also includes one final evaluation and debridement of the trachea in preparation for decannulation during that hospitalization.

\*This patient was not given preoperative steroids and subsequently developed excessive swelling and required a tracheostomy during the first hospitalization. It was removed 4 months later.

The majority of patients were hoarse before the surgery and most voices were improved after their surgery, likely because of the increased mobility of their arytenoids. Improved voices were noted in 19 of the 23 patients (83%); seven improved to normal (VHI-10 < 10) and twelve felt significant improvement (mean postoperative improvement of 12 on VHI-10) ( $p < 0.001$ ), but still with some degree of breathiness or hoarseness. Three patients (13%) reported no change in their voice, and one patient (4%) reported occasional raspiness.

#### **4. Discussion**

In our experience, cricoarytenoid joint movement limitation associated with PGWS may range from reduced range of motion to complete fixation of the joint. In the Bogdasarian classification as it is commonly used, there is no differentiation between these two points. Bogdasarian and Olson, in their original description of ten patients with PGWS, did point out that there could be varying degrees of fixation. A preoperative assessment of the Bogdasarian classification for a patient is limited by that fact that it does not necessarily distinguish between paralysis, web-based motion restriction, and ankylosis of the cricoarytenoid joint. In the context of the Bogdasarian scale, we provide a classification of CJA that aims to standardize the severity of disease in grades III and IV of PGWS, thus dividing each grade to two subcategories: “a” and “b” according to the severity of CJA. Cases with Bogdasarian Grade III PGWS with minor unilateral fixation should be classified as IIIa. We had one case which fits that criteria; it was not confirmed until during surgery when the degree of fixation was appreciated to be only minor. If the fixation is severe, it should be classified as a Grade IIIb. Grade IVa would denote mild

bilateral joint fixation. We propose Grade IVb as involving bilateral joint restriction with subtotal or complete fusion within at least one joint. These cases require extensive dissection to remobilize at least one of the two joints. These needed more surgeries when both joints were completely fixed. Table III shows the distribution of grades of CJA among our cohort and the number of arytenoid procedure and total surgeries needed for completion of care. As in the original series presented by Bogdasarian and Olson, patients with grade IV posterior glottic web-based stenosis were more likely to require extensive arytenoid resections initially or additional procedures to achieve satisfactory results. In reviewing the data of the current study, we noted that the number of surgeries required decreased as the study progressed. This is presumed to be secondary to more aggressive dissection of the arytenoids when indicated.

Arytenoidectomy is well known to produce dysphagia. This was recognized by Bogdasarian and others<sup>6, 11, 12</sup>. We have found that if the medial face of the arytenoid is maintained and the sensory nerve supply to the mucosa about the distal aryepiglottic fold is uninjured, swallowing function will be preserved, assuming there is sufficient height to the level of the posterior larynx relative to the depth of the pyriform sinus. Non-conservative procedures, including complete arytenoidectomy and posterior cordectomy, inherently increase the risk of aspiration and impaired voice quality<sup>11, 12</sup>.

Most of the arytenoid remobilization techniques described in the literature are done through an open approach, such as laryngofissure, and commonly require a tracheostomy. More importantly, tracheostomy impacts the voice and secondary stenosis, acute airway obstruction, and even great vessel injury<sup>13, 14</sup>. With our approach, patients with CJA without a tracheostomy on presentation did not require one to secure their airway postoperatively because trans-oral approaches cause less tissue edema. Another commonly used technique is the use of stents to

hold the remobilized arytenoids apart during healing; but this can cause granulation tissue formation, ulceration, and laryngeal re-stenosis. In our procedure, a flap is used to separate the healing arytenoids without the need of a stent.

Endoscopic techniques of arytenoid surgery have also been described. Ejnell, Cummings, and Rovo have reported different, valuable techniques which use a combination open/closed approach and special tools<sup>15</sup>. Our techniques for arytenoid mobilization can be performed by one surgeon without any assistance or specific instrumentation, but he has to be trained in techniques of reconstructive transoral laser microsurgery described above and in our previous works<sup>9</sup>.

This study describes successful arytenoid remobilization techniques in 23 cases. With more laryngologists actually being trained in reconstructive transoral laser microsurgery, further multicentric studies with larger cohorts will be performed to confirm our results.

## **5. Conclusion**

We provide a classification of cricoarytenoid joint ankyloses that aims to standardize the severity of disease in the context of the Bogdasarian scale for posterior glottic web-based stenosis. We also describe a taxonomy of endoscopic techniques to address ankylosed arytenoids that are safe, effective, and well tolerated choices to treat CJA in patients with grade III and IV PGWS. The use of an endoscopic approach rather than a laryngofissure for arytenoid remobilization reduces iatrogenic harm to the larynx and trachea. Additionally, it can be performed by laryngologists familiar with laryngeal microsurgery with commonly available laryngeal instruments and a scanning CO2 laser.



## References

1. Montgomery WW, Perone PM, Schall LA. Arthritis of the cricoarytenoid joint. *Ann Otol Rhinol Laryngol*. 1955;64:1025-1033.
2. Hoasjoe DK, Franklin SW, Aarstad RF, Day TA, Stucker FJ. Posterior glottic stenosis mechanism and surgical management. *Laryngoscope*. 1997;107:675-679.
3. Whited RE. Posterior commissure stenosis post long-term intubation. *Laryngoscope*. 1983;93:1314-1318.
4. Montgomery WW. Pathology of cricoarytenoid arthritis. *Trans Am Acad Ophthalmol Otolaryngol*. 1959;63:650-656.
5. Montgomery WW, Goodman ML. Rheumatoid cricoarytenoid arthritis complicated by upper esophageal ulcerations. *Ann Otol Rhinol Laryngol*. 1980;89:6-8.
6. Bogdasarian RS, Olson NR. Posterior glottic laryngeal stenosis. *Otolaryngol Head Neck Surg (1979)*. 1980;88:765-772.
7. Wolf M, Primov-Fever A, Talmi YP, Kronenberg J. Posterior glottic stenosis in adults. *Isr Med Assoc J*. 2007;9:597-599.
8. Gardner GM. Posterior glottic stenosis and bilateral vocal fold immobility: diagnosis and treatment. *Otolaryngol Clin North Am*. 2000;33:855-878.
9. Atallah I, Manjunath MK, Omari AA, Righini CA, Castellanos PF. Reconstructive transoral laser microsurgery for posterior glottic web with stenosis. *Laryngoscope*. 2016.
10. Gartner-Schmidt JL, Shembel AC, Zullo TG, Rosen CA. Development and validation of the Dyspnea Index (DI): a severity index for upper airway-related dyspnea. *J Voice*. 2014;28:775-782.
11. Kashima HK. Bilateral vocal fold motion impairment: pathophysiology and management by transverse cordotomy. *Ann Otol Rhinol Laryngol*. 1991;100:717-721.
12. Ossoff RH, Sisson GA, Duncavage JA, Moselle HI, Andrews PE, McMillan WG. Endoscopic laser arytenoidectomy for the treatment of bilateral vocal cord paralysis. *Laryngoscope*. 1984;94:1293-1297.
13. Bennett JD. High tracheostomy and other errors--revisited. *The Journal of laryngology and otology*. 1996;110:1003-1007.
14. Gilony D, Gilboa D, Blumstein T, et al. Effects of tracheostomy on well-being and body-image perceptions. *Otolaryngol Head Neck Surg*. 2005;133:366-371.
15. Ejnell H, Bake B, Mansson I, et al. New mobilization and laterofixation procedure for cricoarytenoid joint ankylosis in rheumatoid arthritis. *Ann Otol Rhinol Laryngol*. 1985;94:442-444.

## **6. Vitae**

### **Ihab Atallah, MD-PhD**

Dr. Atallah is a specialist of laryngology and bronchoesophagology at Grenoble University Hospital (France). After earning his medical degree, he completed an otolaryngology-head and neck surgery residency at Strasbourg University Hospital (France). He worked as an attending physician at Lyon University Hospital in 2010. He joined Grenoble University Hospital in 2011. He received advanced fellowship training in laryngology and bronchoesophagology at University of Alabama at Birmingham (USA). In addition to patient care, Dr. Atallah is actively engaged in clinical and translational research. Dr. Atallah is author and coauthor of many published reviewed scientific manuscripts and book chapters.

### **Manjunath MK, MD**

Dr. Manjunath M.K. is a specialist in Otolaryngology and serves as a consultant at Columbia Asia Hospital in Yeshwanthpur. He is well adept in performing voice, airway and swallowing surgeries. He has completed his MBBS as well as MS Otolaryngology from Sree Siddhartha Medical College, Tumkur, Karnataka. He further obtained Voice and Airway Fellowship from Deenanath Mangeshkar Hospital, and Research Centre and Mini Fellowship in Laryngology from Emory University hospital, Atlanta, both in 2012. He has also acquired Fellowship in Laryngology Bronchoesophagology from University of Alabama at Birmingham, AL, USA in 2015.

### **Ahmad Al Omari, MD**

Dr. Al Omari is an assistant professor and consultant of laryngology at Jordan university of science and technology. He is specialist in voice and swallowing disorders, airway reconstructive surgery and transoral laser microsurgery. After earning his medical degree and completing his otolaryngology residency at Jordan University of Science and Technology, he underwent advanced laryngology training at University of Alabama at Birmingham and Stanford university hospital in USA.

### **Christian Adrien Righini, MD-PhD**

Dr. Righini is the chairman of the otolaryngology-head and neck surgery department at Grenoble Alpes University Hospital, France. He is actively engaged in fundamental and translational researches on head and neck cancers. He has multiple publications and book chapters.

### **Paul F. Castellanos, MD, FCCP**

Dr. Castellanos is an associate professor and the director of the Voice and AeroDigestive Center at University of Alabama at Birmingham, USA. He is specialist in voice and swallowing disorders, airway stenosis, and esophageal disorders. He developed multiple novel techniques for reconstructive transoral laser microsurgery. He is engaged in active training of national and international laryngologists to master these novel techniques that will represent in the near future the modern laryngology.