



HAL
open science

Quantitative analysis of choriocapillaris alterations in swept-source optical coherence tomography angiography in diabetic patients

Olivier Loria, Laurent Kodjikian, Philippe Denis, Christine Vartin, Sarra Dimassi, Lucas Gervolino, Antoine Maignan, Ronan Kermarrec, Claudine Chambard, Pierre Pradat, et al.

► To cite this version:

Olivier Loria, Laurent Kodjikian, Philippe Denis, Christine Vartin, Sarra Dimassi, et al.. Quantitative analysis of choriocapillaris alterations in swept-source optical coherence tomography angiography in diabetic patients. *RETINA. The Journal of Retinal and Vitreous Diseases*, 2021, 41 (9), pp.1809-1818. 10.1097/IAE.0000000000003102 . hal-03483720

HAL Id: hal-03483720

<https://hal.science/hal-03483720>

Submitted on 18 May 2023

HAL is a multi-disciplinary open access archive for the deposit and dissemination of scientific research documents, whether they are published or not. The documents may come from teaching and research institutions in France or abroad, or from public or private research centers.

L'archive ouverte pluridisciplinaire **HAL**, est destinée au dépôt et à la diffusion de documents scientifiques de niveau recherche, publiés ou non, émanant des établissements d'enseignement et de recherche français ou étrangers, des laboratoires publics ou privés.

QUANTITATIVE ANALYSIS OF CHORIOCAPILLARIS ALTERATIONS IN SWEEP-SOURCE OPTICAL COHERENCE TOMOGRAPHY ANGIOGRAPHY IN DIABETIC PATIENTS

Loria, Olivier MD*; Kodjikian, Laurent MD, PhD*,†; Denis, Philippe MD, PhD*; Vartin, Christine MD*; Dimassi, Sarra MD‡; Gervolino, Lucas§; Maignan, Antoine§; Kermarrec, Ronan§; Chambard, Claudine*,§; Pradat, Pierre PhD¶; Mathis, Thibaud MD, PhD*,†

Purpose: To evaluate quantitative alterations of the choriocapillaris in swept-source optical coherence tomography angiography in diabetic patients. **Methods:** We included normal patients and diabetic patients with and without diabetic retinopathy (DR), excluding patients with macular edema. Angiograms in 3 · 3 mm were acquired with Plexelite 9000 swept-source optical coherence tomography angiography. Choroidal flow voids were analyzed after removal of projection artifacts. The main evaluation was the correlation between choroidal flow voids area (FVA-CC) and DR stage. **Results:** A total of 120 eyes of 72 patients were analyzed. There were 17 eyes from healthy subjects, 30 eyes without DR, 22 eyes with minimal nonproliferative DR, 30 eyes with moderate nonproliferative DR, 16 eyes with severe nonproliferative DR, and 5 eyes with proliferative DR (PDR). The percentage of FVA-CC for each group was, respectively, $10.9 \pm 3.4\%$, $14.6 \pm 4.8\%$, $17.6 \pm 3.5\%$, $20.7 \pm 5.9\%$, $19.9 \pm 2.9\%$, and $26.6 \pm 4.4\%$. FVACC and DR stage significantly correlated ($P = 0.0001$). FVA-CC was significantly increased in diabetic patients without DR compared with healthy subjects ($P = 0.008$). **Conclusion:** Diabetes is associated with quantifiable choriocapillaris alterations in swept-source optical coherence tomography angiography. These alterations precede clinical signs of DR and are correlated with DR stage.

Diabetic retinopathy (DR) is the first cause of blindness in patients younger than 75 years in industrialized countries.¹ Visual acuity loss is mainly

From the *Service d'Ophtalmologie, Hôpital universitaire de la Croix-Rousse, Hospices Civils de Lyon, France; †Laboratoire UMR-CNRS 5510 Matéis, Villeurbanne, France; ‡Service d'Ophtalmologie, Groupe Hospitalier Public Sud de l'Oise, Creil, France; §Institut des Sciences et Techniques de la Réadaptation—Orthoptie, Lyon, France; and ¶Centre de Recherche Clinique, Hôpital universitaire de la Croix-Rousse, Hospices Civils de Lyon, France.

T. Mathis is a consultant for Allergan, Bayer, and Novartis; L. Kodjikian is a consultant for Alcon, Alimera, Allergan, Bayer, Novartis, and Théa; P. Denis is a consultant for Alcon, Allergan, Novartis, Santen, Théa, and Istar. The remaining authors do not have any financial/conflicting interests to disclose.

Reprint requests: Thibaud Mathis, MD, Service d'Ophtalmologie, Hôpital Universitaire de la Croix-Rousse—Hospices Civils de Lyon, 103, Grande Rue de la Croix-Rousse, 69317 Lyon Cedex 04, France; e-mail: mathisthibaud@hotmail.fr

attributed to retinal lesions,² but choroidal lesions could have their own role in the alteration of visual function. The term “diabetic choroidopathy” was introduced by Hidayat and Fine³ to describe histological lesions found in the choroids of diabetic patients. Typical lesions include degeneration of the capillary endothelium, thinning and rarefaction of choroidal capillaries, laminar deposits, tortuous and beaded vessels, and even choroidal neovessels.^{4,5} In more advanced stages, some have described choroidal microaneurysms and dilated choroidal vessels.³

In vivo, decreased choriocapillaris perfusion was measured by Laser Doppler Flowmetry.^{6,7} Spectral-domain optical coherence tomography angiography (OCT-A) allows noninvasive imaging of retinal capillary plexus and choriocapillaris.^{8,9} In diabetic patients,

it shows nonperfusion areas and irregular capillaries and microaneurysms in the superficial and deep retinal plexus.^{10,11} At the choroidal level, there is a decrease in the choriocapillaris density^{12,13} and an increase in the number of non-flow areas, commonly referred to as « *flow voids* ». ^{12,14} Some studies show a correlation between choriocapillary alterations and the stage of DR.^{13,14} However, they tend to regroup stages of retinopathy or include patients with diabetic macular edema (DME), which can hinder the interpretation of flow at the choriocapillaris level.

Swept-source (SS) OCT uses a longer wavelength and faster A-scan rate, allowing better penetration in the choroid and increased signal-to-noise ratio.¹⁵ Choroidal alterations have been described in SS-OCT-A in diabetic patients, both qualitatively¹⁶ and quantitatively,¹⁷ even in the absence of DR.^{16,18,19} Further quantitative studies, using standardized and reproducible artifact removal and flow void quantification methods, are needed to correlate SS-OCT-A alterations of the choriocapillaris and DR stage.

The main objective of our study is to quantify microvascular changes in the choriocapillaris of diabetic patients using SS-OCT-A and to correlate them to the stage of DR as defined by the international classification.²⁰ Secondary objectives are to evaluate the correlation between choriocapillaris changes and other retinal microvascular changes, glycemic control, duration of diabetes, and renal disease.

Materials and Methods

Study Population

We performed a prospective study including consecutive diabetic patients and healthy subjects, consulting in our department of ophthalmology at the Croix Rousse University Hospital between July 2018 and July 2019 in Lyon, France. Two patient groups were defined: diabetic patients and healthy subjects. The protocol was approved by an international review board (Ethics Committee of the French Society of Ophthalmology, IRB 00008855 Société Française d'Ophthalmologie IRB#1). Informed consent to participate in the study was obtained from all patients.

Diabetic subjects were classified according to DR stage: no DR, minimal, moderate or severe non-proliferative DR (NPDR), or proliferative DR (PDR) in the eye studied. Healthy subjects were defined as patients with no history of ophthalmologic abnormality in the eye studied and comparable in age to the diabetic patients recruited in the study.

Eyes presenting other ophthalmologic conditions that could alter retinal vascularization or alter the OCT-A

signal were excluded: eyes with DME, dry exudates at the posterior pole, a history of panretinal photocoagulation, macular grid or focal laser, or complications of DR (retinal detachment, neovascular glaucoma, vitreous hemorrhage). We also excluded eyes treated by intravitreal injections of anti-vascular endothelial growth factor, dexamethasone, or subconjunctival triamcinolone. Eyes with epiretinal membrane, disorganized retinal internal layers, retinal pigmentary epithelium (RPE) atrophy, or retinal vitrectomy surgery were also excluded because of possible artifacts in the layer segmentation or window effects that could hinder OCT-A signal analysis. Eyes with a refractive error greater than 6 spherical diopters or 3 cylindrical diopters, with a crystalline lens opalescence or coloration superior to Grade 3 or patients with an OCT-A signal strength inferior to 8/10 were excluded. Whenever possible, both eyes were included in the study. When the contralateral eye had exclusion criteria, only one eye was included.

Data Collection

Demographic data obtained from medical records and questionnaires included: history of hypertension, renal disease and its stage, the level of glycosylated hemoglobin, and the duration of diabetes. The Snellen best-corrected visual acuity was measured and converted to logarithm of the minimum angle of resolution.

Diabetic retinopathy stage was determined by double reading according to the Diabetic Retinopathy Disease Severity Scale²⁰ on confocal color fundus photographs covering at least the 7 ETDRS fields (Centervue Eidon, Centervue, Padova, Italy). In case of disagreement between the two readers, the photographs were evaluated by a third retinal specialist.

Optical Coherence Tomography Angiography Image Acquisition

Optical coherence tomography-A images were obtained using the swept-source OCT Plexelite 9000 (Carl Zeiss Meditech AG, Germany). Each patient had a 3 mm × 3 mm angiogram centered on the fovea, composed of 300 A-scans at 300 positions, with 4 scans per position, using the eye tracking system (FastTrac, Carl Zeiss Meditech, Inc.). This scan size has the best sensitivity for microvascular changes in diabetes.²¹ All acquisitions were performed by the same operator. Decorrelation signal was analyzed using the native Plexelite 9000 algorithm (Optical MicroAngiography). Eyes presenting DME, exudates, epiretinal membrane, RPE atrophy, or disorganized retinal internal layers on the OCT B-scan or motion or blinking artifacts on the angiogram were excluded. En-face angiograms were segmented

automatically using the Plexelite software, with manual correction of segmentation to isolate the superficial capillary plexus, located between the internal limiting membrane and the internal plexiform layer; the deep capillary plexus, located between the internal plexiform layer and the outer plexiform layer; and the choriocapillaris, located between the outer part of the Bruch membrane and a parallel line 20- μm deeper (Figure 1D).

Outcome Measures

Choroidal nonperfusion analysis. Choriocapillaris angiograms were imported into ImageJ in 8-bit format (256 gray levels) (Figure 1A). To reduce projection artifacts from retinal capillary plexus, we used a previously described algorithm,²² and choroidal pixels directly under areas of retinal plexus flow signal were excluded from the analysis (Figure 1B).

The local thresholding algorithm was applied by selecting *Image>Adjust>Auto Local Threshold*. We chose the Phansalkar method,²³ with a radius set to 6 pixels, as most appropriate for 3 mm \times 3 mm angiograms and based on an estimated intercapillary distance of 25 μm as described by Chu et al²⁴ and by selecting « *white objects on black background* ». The colors were then inverted to quantify the flow voids (Figure 1C) using *Analyze>Analyze Particles*.

The flow voids area at the choriocapillaris level (FVA-CC) was calculated as a percentage according to the following formula:

We also studied the choriocapillaris perfusion using the method described by Nesper et al¹³ by measuring

$$\text{Flow voids area} = \frac{\text{Total area of flow voids} - \text{Masked flow voids}}{\text{Total area of angiogram} - \text{All masked pixels}}$$

the percentage area of nonperfusion (PAN) at the choriocapillaris level (PAN-CC), after choosing a threshold in the foveal avascular zone of the superficial capillary plexus (Figure 1, E and H).

Reproducibility of the Measure at the Choriocapillaris Level. Reproducibility of the two methods described above was evaluated by comparing the FVA-CC and the PAN-CC of the left and right eyes with the same stage of DR, when both eyes were imaged, using a Pearson correlation coefficient.

Analysis of Retinal Capillary Plexus Nonperfusion. Superficial and deep retinal capillary plexus angio-

grams were imported into ImageJ. A threshold was defined for each angiogram, as previously described,¹³ as the mean signal of the FAZ, taken on three different circles of 30- μm radius. Pixels with a flow signal above threshold were considered as flow, and pixels with a signal below threshold were considered as having no flow. The percent area of nonperfusion for each level of segmentation was defined as the percentage of pixels with a signal below threshold (Figure 1, F–H).


Geometric Properties of the Foveal Avascular Zone. The FAZ was manually delimited by two independent and masked retinal specialists for each angiogram at the superficial capillary plexus level using ImageJ. Its perimeter was measured in pixels, and the surface area was converted to square millimeter. The regularity of the perifoveal anastomosis was quantified using the index of circularity ($IC = 4\pi A/P^2$).²⁵

Statistical Analysis

Normal distribution of initial patient characteristics was verified using a Shapiro–Wilk test. Group comparability was analyzed using Student T-test and analysis of variance test for continuous variables, and Pearson chi-squared or Kruskal–Wallis test depending on the distribution. The association between OCT-A parameters and the stage of retinopathy was tested using a linear mixed-effects model taking into account dependence of measurements within subjects. Results are expressed as estimate with its 95% confidence interval and *P* value. The estimate gives the increase or decrease in the OCT-A parameter per each additional retinopathy stage. Correlation between flow voids and clinical or other quantitative parameters

was analyzed using Pearson correlation coefficient. The significance threshold was defined as a *P* value less than 0.05. The interobserver agreement for FAZ area, FAZ perimeter, and FAZ index of circularity was assessed by calculating the intraclass correlation coefficients. To get rid of the possible eye effect (introduced by having sometimes both eyes of a same subject), we performed a simulation study by randomly choosing one of both eyes (when both were present). This analysis was thus conducted on all 72 patients (not on all eyes) and was repeated 1,000 times. For each run that included only one eye per

Fig. 1. Measure of choroidal flow voids area (FVA-CC) and PAN in a 65-year-old patient with moderate NPDR. **A.** Choriocapillaris angiogram. **B.** Projection mask (red pixels) derived from the superficial and deep angiograms superimposed on the choriocapillaris angiogram. **C.** Binarization of the whole retina angiogram using Phansalkar algorithm, after excluding the projection mask in **(B)** (red pixels) from the analysis projection mask in **(B)**. **D.** Optical coherence tomography B-scan from the same patient showing absence of macular edema. **E.** Measure of flow threshold on the foveal avascular zone at the superficial retinal capillary plexus level **F.** Measure of the PAN at the superficial retinal capillary level (PAN-Sup). **G.** Measure of the PAN at the deep retinal capillary plexus level (PAN-deep). **H.** Measure of the PAN at the choriocapillaris level (PAN-CC).



patient, the intraclass correlation coefficient was calculated using a 2-way mixed model measuring absolute agreement between raters (Package “irr” of the R software). The mean intraclass correlation coefficient summarizing all runs was then calculated and is now presented together with Min and Max values. Statistical analysis was performed in GraphPad Prism Version 8.2.1 for Mac OS (GraphPad Software, La Jolla, CA, www.graphpad.com).

Results

A total of 162 eyes from 81 patients were screened. Both eyes were excluded for 9 patients (18 eyes) and 1 eye was excluded for 24 patients (24 eyes) because of exclusion criteria, insufficient image quality, or presence of artifacts. Of the remaining 120 eyes of 72 patients, there were 17 eyes from healthy subjects, 30 eyes from diabetic patients without DR, 22 eyes with minimal NPDR, 30 eyes with moderate NPDR, 16 eyes with severe NPDR, and 5 eyes with PDR. Initial patient characteristics are summarized in Table 1. The only significant differences between groups concerned the duration of diabetes, the level of glycated hemoglobin, and the lens status.

Correlation Between Quantitative Optical Coherence Tomography Angiography Parameters and Retinal Changes

The FVA-CC, the PAN of the superficial plexus (PAN-Sup), deep plexus (PAN-deep), and PAN-CC, as well as the FAZ area, FAZ perimeter, and FAZ index of circularity are presented in Table 2. The inter-observer agreement for FAZ area, FAZ perimeter, and

FAZ index of circularity gave intraclass correlation coefficient values (Min–Max) of 0.993 (0.989–0.997), 0.984 (0.976–0.990), and 0.940 (0.909–0.957), respectively. At the choriocapillaris level, in the mixed-effects model, the increase in FVA-CC (Figure 2) and PAN significantly correlated with the stage of DR ($P < 0.0001$ and $P = 0.0001$, respectively). At the retinal level, the perimeter ($P = 0.0003$) and area of the FAZ ($P = 0.029$), its index of circularity ($P < 0.0001$), the PAN of the superficial plexus ($P < 0.0001$), and the deep plexus ($P < 0.0001$) all significantly correlated with the stage of DR. Superficial retinal plexus and choriocapillaris angiograms with corresponding PAN-Sup and FVA-CC of representative patients are shown in Figure 3.

Correlation Between FVA-CC, Clinical Parameters, and Other Optical Coherence Tomography Angiography Parameters

The FVA-CC significantly correlated with the duration of diabetes ($P = 0.01$), but not to age, level of glycated hemoglobin, stage of renal disease, or sex. In the group of healthy patients, the FVA-CC significantly correlated with age ($P = 0.03$). Concerning other quantitative parameters, the FVA-CC significantly correlated with the index of circularity of the ZAC ($P = 0.04$), the PAN of the superficial plexus ($P < 0.0001$), the PAN of the deep plexus ($P < 0.0001$), and the PAN of the choriocapillaris ($P < 0.0001$). However, it was not correlated to the FAZ perimeter or FAZ surface. The strongest correlation was found for the FVA-CC and the PAN of the choriocapillaris ($R^2 = 0.37$) (Figure 4).

Table 1. Patient Characteristics

	Controls	Diab w/o DR	min NPDR	mod NPDR	Sev NPDR	PDR	<i>P</i>
Eyes/patients	17/13	30/18	22/13	30/19	16/11	5/3	
Gender, M/F	7/6	4/14	8/5	10/9	5/6	3/0	0.1
Age, years \pm SD	56.1 \pm 15.5	58.9 \pm 10.1	67.4 \pm 7.4	64 \pm 11.3	60.1 \pm 10.2	56.6 \pm 7.7	0.9
Type of DM, n (%)							
Type 1		0 (0%)	0 (0%)	1 (5.3%)	1 (9.1%)	0 (0%)	
Type 2		18 (100%)	13 (100%)	18 (94.7%)	10 (90.9%)	3 (100%)	
Duration of DM, years \pm SD	10.13 \pm 3	10.3 \pm 1.7	15.36 \pm 5.5	12.13 \pm 2.9	17 \pm 5	<0.01	
HbA1c, % \pm SD		7.3 \pm 3	7.5 \pm 0.9	7.6 \pm 0.8	8.3 \pm 1.3	8.45 \pm 0.6	0.01
HBP (Yes/no/unknown)	3/10/0	10/8/0	10/3/0	11/7/1	8/3/0	2/1/0	0.23
Renal disease, n (%)							0.8
Stage 1	13 (100%)	7 (38%)	5 (38%)	8 (42%)	3 (27%)	1 (33%)	
Stage 2	0 (0%)	2 (11%)	2 (15%)	2 (10%)	1 (9%)	1 (33%)	
Stage 3	0 (0%)	0 (0%)	0 (0%)	1 (5%)	1 (9%)	0 (0%)	
Stage 4	0 (0%)	0 (0%)	0 (0%)	0 (0%)	0 (0%)	0 (0%)	
Unknown	0 (0%)	9 (50%)	5 (38%)	8 (42%)	6 (54%)	1 (33%)	
BCVA							
mean \pm SD (LogMAR)	0 \pm 0	0.05 \pm 0.10	0.05 \pm 0.1	0.17 \pm 0.27	0.05 \pm 0.09	0 \pm 0	0.17
mean (Snellen)	20/20	20/16	20/16	20/32	20/16	20/20	
Lens status, n (%)							0.0158
Clear	15 (88%)	18 (60%)	13 (59%)	14 (47%)	11 (68%)	5 (100%)	
Grade 1 or 2 cataract	2 (12%)	10 (33%)	7 (32%)	7 (23%)	1 (6%)	0 (0%)	
Pseudophakia	0 (0%)	2 (7%)	2 (9%)	9 (30%)	4 (25%)	0 (0%)	

DM, diabetes melitus; min, minimal; mod, moderate; sev, severe; prolif, proliferative; M, Male; F, female; HBP, high blood pressure; LogMAR, logarithm of the minimum angle of resolution; BCVA, best-corrected visual acuity.

Retinal and Choroidal Changes in Diabetic Patients without Diabetic Retinopathy

There was a significant difference in FAZ area ($P < 0.001$), FAZ perimeter ($P < 0.001$), PAN-CC ($P = 0.01$), and FVA-CC ($P = 0.01$) between healthy subjects and diabetic patients without DR (Figure 5). However, the difference was not significant for the PAN-Sup, PAN-Deep, and FAZ circularity.

Reproducibility of Optical Coherence Tomography Angiography Quantitative Measures

The FVA-CC and the PAN-CC for contralateral eyes with the same DR stage are represented in Figure 6. The correlation between both eyes was significant only for the FVA-CC.

Discussion

Our study shows quantifiable choriocapillaris alterations on SS-OCT-A that significantly correlated with the stage of DR. The strongest association is found for the FVA-CC. In addition, this OCT-A parameter shows that early choriocapillaris alterations are significantly increased in diabetic patients without DR. Those results are in agreement with previous studies showing the importance of early choriocapillaris alterations in spectral-domain OCT-A in diabetic

patients.^{13,14,19} We also show a correlation between the FVA-CC and the duration of diabetes, reinforcing the hypothesis of a pathophysiological link between choroidal and retinal alterations in diabetes. We have also quantified changes using the PAN of the choriocapillaris, and this OCT-A parameter also correlated with the stage of DR. A previous study found a significant and positive, albeit weak, correlation between PAN of the choriocapillaris and DR stage.¹³ However, this study included patients with DME, which may hinder choriocapillaris OCT-A analysis. In fact, patients with more advanced DR stages are more likely to have DME, which would increase the measured PAN by masking effect.²⁶ Nonetheless, the PAN of the choriocapillaris seems to be sensitive to early changes because it is significantly increased in diabetic patients without DR. For stages higher than minimal DR, however, there is little increase in the PAN of the choriocapillaris. It seems therefore as a sensitive marker of diabetic alterations, but not specific to the stage of DR. Conversely, FVA-CC seems to reflect changes at more advanced stages of DR because it keeps increasing up to the PDR stage. This shows the interest of combining those two measures in evaluating choriocapillaris anomalies.

The reproducibility of the two methods, assessed by comparing the values of the left and right eyes with the same stage of DR, found a much better correlation with the FVA-CC than with the PAN of the

Table 2. Optical coherence tomography-A Parameters Measured at the Retinal and Choroidal Level Depending on the Stage of Retinopathy

	Control	DM w/o DR	min NPDR	mod NPDR	Sev NPDR	PDR	Estimate (95% CI)	P
Eyes, n	n = 17	n = 30	n = 22	n = 30	n = 16	n = 5		
Average FAZ area, mm ² ± SD, Sup	0.23 ± 0.11	0.40 ± 0.10	0.26 ± 0.14	0.34 ± 0.20	0.44 ± 0.13	0.40 ± 0.06	0.027 (0.003 to 0.050)	0.029
Average FAZ perimeter, pixels ± SD, Sup	633 ± 163	844 ± 111	693 ± 206	823 ± 262	1,047 ± 213	985 ± 37	62.1 (30.6 to 93.6)	0.0003
Average FAZ IC ± SD, Sup	0.77 ± 0.05	0.77 ± 0.07	0.7 ± 0.13	0.67 ± 0.12	0.59 ± 0.10	0.62 ± 0.12	-0.04 (-0.05 to -0.03)	<0.0001
Average PAN, % ± SD, Sup	18.5 ± 4.46	19.3 ± 4.06	20.5 ± 3.67	25.4 ± 4.12	27.2 ± 5.8	28.7 ± 3.6	2.26 (1.62 to 2.90)	<0.0001
Deep	16.9 ± 4.8	19.1 ± 4.12	22.2 ± 3.5	24.5 ± 3.8	28.9 ± 6.8	25.8 ± 3.7	2.51 (1.83 to 3.18)	<0.0001
CC	0.17 ± 0.18	1.37 ± 1.8	3.46 ± 2.59	3.35 ± 1.99	2.97 ± 2.11	3.67 ± 2.52	0.67 (0.36 to 0.98)	0.0001
Total FVA, % ± SD, CC	10.9 ± 3.4	14.6 ± 4.8	17.6 ± 3.5	20.7 ± 5.9	19.9 ± 2.9	26.6 ± 4.4	2.55 (1.86 to 3.24)	<0.0001

CC, choriocapillaris; CI, confidence interval; DM, diabetes mellitus; Deep, deep plexus; FVA, flow voids area; FAZ, foveal avascular zone; IC, index of circularity; min, minimal; mod, moderate; sev, severe; Sup, superficial plexus.

choriocapillaris. Percentage area of nonperfusion values were much smaller than FVA-CC, leaving out a lot of areas that seemed nonperfused. This is probably because of the choice of threshold, which is taken at the superficial capillary plexus and may not be adapted to analysis of the choriocapillaris layer, which has a higher average decorrelation signal. The use of an internal control would be ideal, but unfortunately, there is no avascular zone in the choriocapillaris. This is why the use of a local thresholding algorithm seems more appropriate. Spaide²⁷ proposed using the Phansalkar algorithm, allowing the analysis of dark areas in low-contrasted images, such as choriocapillaris angiograms, and which we used in this study.

To this day, there are few SS-OCT-A studies that quantitatively evaluate diabetic choroidopathy.^{17,28} Using similar methods, Mastropasqua et al were able to show a decrease in flow density at the choriocapillaris level but only in patients with PDR. They were not able to show alteration in diabetic patients without DR. This study presents limits in the analysis of the choriocapillaris: The inclusion of patients with DME (50% of patients in the PDR group) may introduce a measuring bias as explained above. Wide-field acquisition of 15 mm × 9 mm angiograms divides the number of A scan per location by two, which causes a

decrease in the lateral resolution and the signal-to-noise ratio.¹⁵ This can be responsible for decreased sensitivity to microvascular alterations at the choriocapillaris level and may explain why differences were not significant for patients without DR. Finally, some DR stages in that study regroup moderate and severe DR. The risk of progression between those two groups

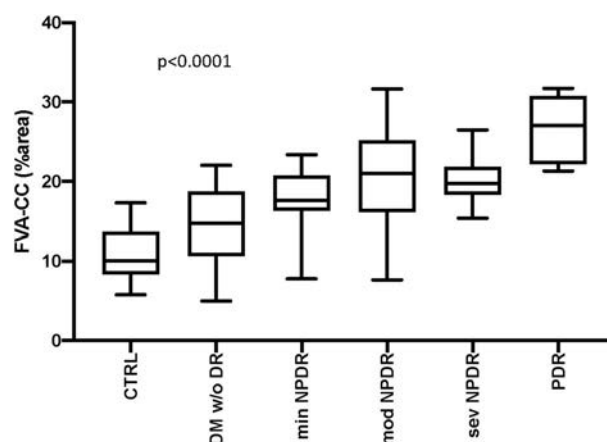


Fig. 2. Choroidal flow voids area (FVA-CC) according to the stage of retinopathy. Spearman correlation test was used by considering retinopathy stage as a discontinuous variable. Estimate and 95% confidence interval for mixed model correlation: 2.55 [1.86–3.24]. CTRL, non diabetic patients; DM, Diabetes mellitus; min, minimal; mod, moderate; sev, severe.

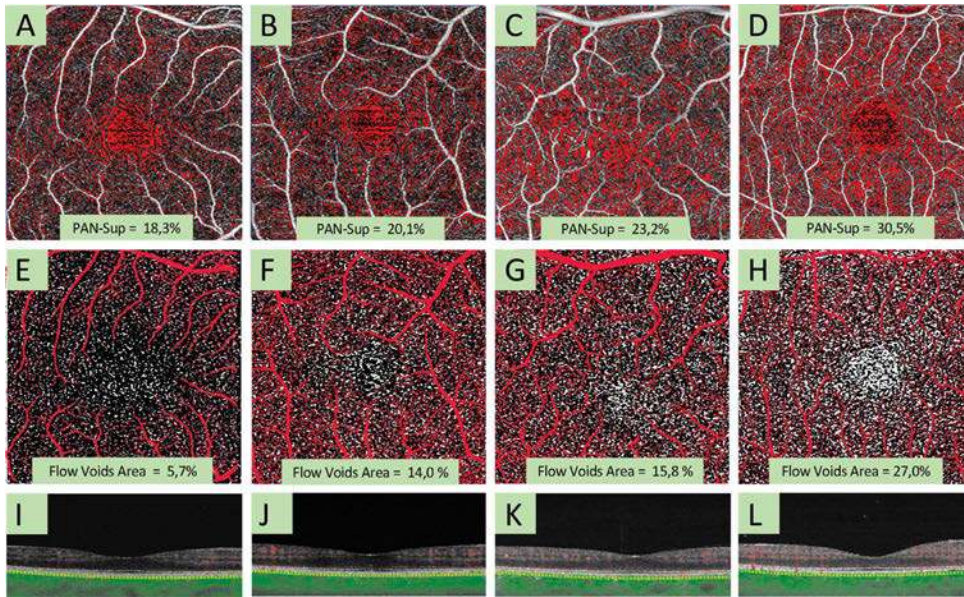


Fig. 3. Percentage area of non-perfusion in superficial plexus (PAN-Sup, A–D), choroidal flow voids area (E–H), and corresponding OCT B-scans (I–L) in representative patients. A, E, I, healthy subjects, (B and F) diabetic patient without DR, (C and G) moderate DR. D and H, Proliferative DR. Red pixels have a signal below threshold (A–D). White pixels represent flow voids (E–H). Red pixels on choriocapillaris angiogram in (E–H) represent retinal flow projection mask and were excluded from the analysis. Optical coherence tomography B-scans show absence of macular edema (I–L).

is quite different, and common DR classifications make a clear distinction between those stages.^{20,29} Gendelman et al showed that quantitative choriocapillaris alterations correlated with DR stage but did not include healthy patients to show alterations in diabetic patients without DR. They also included patients with DME and anti-vascular endothelial growth factor injections. Regarding the angiogram analysis method, they used a global threshold that can be sensitive to varying contrast across the angiogram^{27,30} and did not describe their artifact removal method.

In our study, the analysis of other OCT-A parameters found a significant correlation between DR stage and FAZ area, perimeter and index of circularity, PAN of the superficial plexus, deep plexus, and choriocapillaris.

Those results agree with several studies on OCT-A retinal changes during diabetes.^{13,14,19,31} Additionally, we have found a significant correlation between FVA-CC and some retinal parameters, namely, FAZ index of circularity, PAN of superficial plexus, and PAN of the deep plexus. This suggests that the pathophysiological mechanisms implied in the early retinal changes also have early consequences on the choroid.

In our study, we have taken special care to reduce potential OCT-A artifacts that could introduce a bias in the measure of parameters. Motion artifacts were reduced by including only exams with the EyeTracker, and after careful review of the angiograms we excluded eyes who still exhibited artifacts. The masking effects that could arise from DME, hard

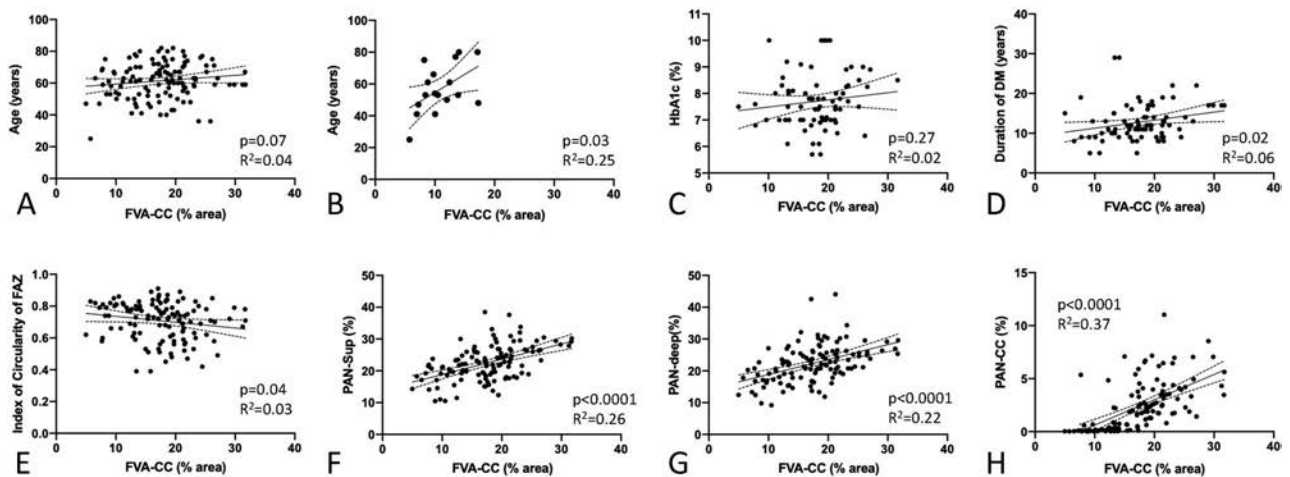
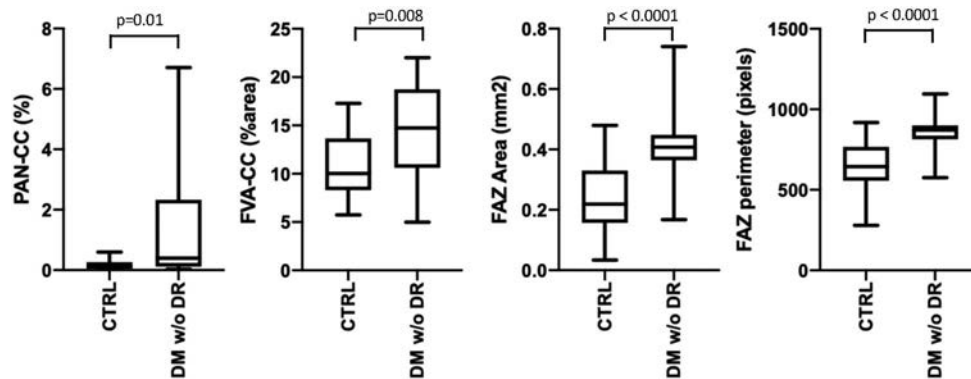


Fig. 4. Correlation between choroidal flow voids area and other clinical (A–D) and angiographic (E–H) parameters. The solid line represents the linear regression, the dotted line represents the 95% confidence interval of the regression. The correlation was considered significant for a $P < 0.05$. The correlation between age and choroidal flow voids is shown for all patients (A) and for healthy patients (B).

Fig. 5. Comparison of retinal and choroidal OCT-A parameters in nondiabetic subjects and diabetic patients without retinopathy. Student *t* test on non-paired values was used with a significance threshold set to $P < 0.05$.



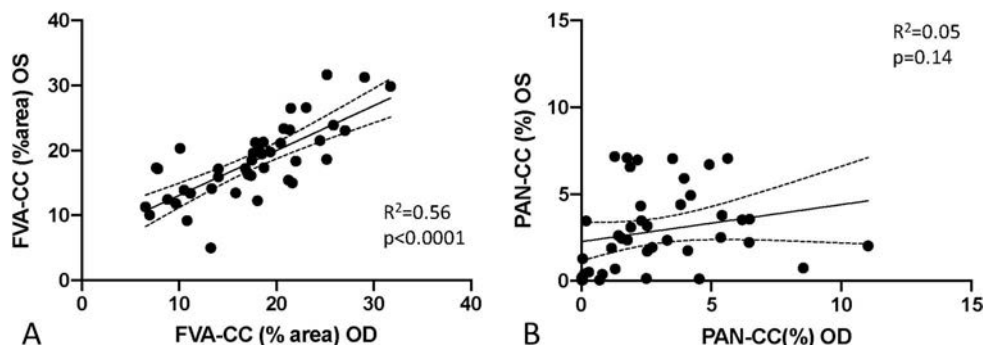
exudates or drusen were also avoided by excluding patients with such alterations. Projection artifacts, mainly because of the retinal plexus were reduced by an exclusion algorithm. The integrated Plexelite software can correct those artifacts using a compensation method, by decreasing the decorrelation signal that is projected from the retinal plexus onto the choriocapillaris. The problem with this method is that it implies extrapolation. The decorrelation signal given by the algorithm at the choriocapillaris level may be higher or lower than the actual flow would give. This is why we decided to exclude the zones subject to projection artifact altogether. Some authors even propose to exclude more zones using the C-scan at the level of the RPE from the *en face* OCT.³² This scan level is a good reflection of masking effects from the whole retina,²⁶ particularly from drusen or exudates. Because we excluded eyes presenting such masking elements, this correction had little interest in our study.

On a pathophysiological level, the probable reasons for a decrease in choriocapillaris flow are still under investigation. Systemic factors, hypertension, and hyperglycemia probably play a role in the alterations of choroidal capillaries. Vascular endothelial growth factor originating from the retina or RPE³³ may also play a role on the choroid. There are probably consequences of choriocapillaris hypoperfusion on photoreceptors, which are mainly vascularized by the choroid.

One study has shown that flow voids found in OCT-A were colocalized with alterations in the ellipsoid zone.¹⁴

The main limit of our study is its observational nature, which implies that a number of missing data among which glycemic control, duration of diabetes, and stage of renal disease are not always known by the patient. We were not able to show a significant correlation between choroidal flow voids area and stage of renal disease, probably by lack of statistical power but also because there was no association, in our study population, between DR stage and renal disease stage. There was significant correlation between choroidal flow voids and age only when looking at the healthy patients. When looking at the whole population, the influence of DR stage may explain why this correlation is lost. Patient number is relatively low especially in the PDR group, whereas DR is a frequent abnormality, and many patients with PDR are followed in our department. This is certainly because of the exclusion of patients with DME, which is frequent in this subgroup. In addition, patients with PDR are often referred because of a complication limiting OCT-A imaging (intravitreal hemorrhage, retinal detachment) or have already had pan retinal photocoagulation or anti-vascular endothelial growth factor injection, which excludes them from our study. Another limitation of our study is the choriocapillaris slab used for the flow voids quantification. We used

Fig. 6. Correlation between right and left eye measures of flow voids area (FVA-CC) and percent area of nonperfusion at the level of the choriocapillaris (PAN-CC) for patients with the same DR stage in both eyes. There is a significant correlation for flow voids area (A) but not for the percentage area of nonperfusion in choriocapillaris level (PAN-CC) (B). OS, Left eye; OD, right eye; R, Pearson correlation coefficient.



the automated choriocapillaris slab selection algorithm in the Plexelite 9000 software, which corresponds to a 20- μm -thick slab at a depth of 29 μm below the RPE. This slab is deeper and thicker than the slab used by Chu et al²⁴ in their flow void quantification study (15- μm -thick slab at 16- μm depth). Although slab depth changes greater than 6- μm can significantly increase the number of flow deficits, thickness changes less than 8 μm have no significant effect on flow deficits.³⁴ Moreover, although this certainly limits interstudy comparison of flow deficit values, it should still allow for intrastudy comparison between patients.

There are also limits in the method used to evaluate the reproducibility of FVA-CC and PAN-CC measurement. It was assessed by comparing both eyes of the same subject when DR stages were identical. Ideally, the reproducibility should be assessed on replicated images of the same eye, but such images were not obtained at inclusion.

The results we obtained show a strong association between DR and choroidopathy. This encourages us to study the potential influence of the choriocapillaris alterations on DR and visual function. This would require integrating OCT-A in the routine examination of diabetic patients and eventually to design follow-up studies showing the evolution of these alterations in time and to compare them to the evolution of retinal changes.

Key words: diabetes mellitus, OCT angiography, choriocapillaris, flow voids, diabetic retinopathy.

Acknowledgments

The authors thank Amélie Bouilloux, Christelle Szatanek, and Monia Benhaddou for their help in the study design and regulatory affairs.

References

- Cheung N, Mitchell P, Wong TY. Diabetic retinopathy. *Lancet* 2010;376:124–136.
- Zong H, Ward M, Stitt AW. AGEs, RAGE, and diabetic retinopathy. *Curr Diab Rep* 2011;11:244–252.
- Hidayat AA, Fine BS. Diabetic choroidopathy. Light and electron microscopic observations of seven cases. *Ophthalmology* 1985;92:512–522.
- McLeod DS, Luttly GA. High-resolution histologic analysis of the human choroidal vasculature. *Invest Ophthalmol Vis Sci* 1994;35:3799–3811.
- Cao J, McLeod S, Merges CA, Luttly GA. Choriocapillaris degeneration and related pathologic changes in human diabetic eyes. *Arch Ophthalmol* 1998;116:589–597.
- Nagaoka T, Kitaya N, Sugawara R, et al. Alteration of choroidal circulation in the foveal region in patients with type 2 diabetes. *Br J Ophthalmol* 2004;88:1060–1063.
- Schocket LS, Brucker AJ, Niknam RM, et al. Foveolar choroidal hemodynamics in proliferative diabetic retinopathy. *Int Ophthalmol* 2004;25:89–94.
- Braaf B, Vienola KV, Sheehy CK, et al. Real-time eye motion correction in phase-resolved OCT angiography with tracking SLO. *Biomed Opt Express* 2012;4:51–65.
- Choi W, Mohler KJ, Potsaid B, et al. Choriocapillaris and choroidal microvasculature imaging with ultrahigh speed OCT angiography. *PLoS One* 2013;8:e81499.
- Matsunaga DR, Yi JJ, De Koo LO, et al. Optical coherence tomography angiography of diabetic retinopathy in human subjects. *Ophthalmic Surg Lasers Imaging Retina* 2015;46:796–805.
- Bandello F, Corbelli E, Carnevali A, et al. Optical coherence tomography angiography of diabetic retinopathy. *Dev Ophthalmol* 2016;56:107–112.
- Dimitrova G, Chihara E, Takahashi H, et al. Quantitative retinal optical coherence tomography angiography in patients with diabetes without diabetic retinopathy. *Invest Ophthalmol Vis Sci* 2017;58:190–196.
- Nesper PL, Roberts PK, Onishi AC, et al. Quantifying microvascular abnormalities with increasing severity of diabetic retinopathy using optical coherence tomography angiography. *Invest Ophthalmol Vis Sci* 2017;58:BIO307–BIO315.
- Dodo Y, Suzuma K, Ishihara K, et al. Clinical relevance of reduced decorrelation signals in the diabetic inner choroid on optical coherence tomography angiography. *Sci Rep* 2017;7:5227.
- Spaide RF, Fujimoto JG, Waheed NK, et al. Optical coherence tomography angiography. *Prog Retin Eye Res* 2018;64:1–55.
- Choi W, Waheed NK, Moulton EM, et al. Ultrahigh speed swept source optical coherence tomography angiography of retinal and choriocapillaris alterations in diabetic patients with and without retinopathy. *Retina* 2017;37:11–21.
- Gendelman I, Alibhai AY, Moulton EM, et al. Topographic analysis of macular choriocapillaris flow deficits in diabetic retinopathy using swept-source optical coherence tomography angiography. *Int J Retina Vitreous* 2020;6:6.
- Vujosevic S, Toma C, Villani E, et al. Early detection of microvascular changes in patients with diabetes mellitus with and without diabetic retinopathy: comparison between different swept-source OCT-A instruments. *J Diabetes Res* 2019;2019:2547216.
- Forte R, Haulani H, Jürgens I. Quantitative and qualitative analysis of the three capillary plexuses and choriocapillaris in patients with type 1 and type 2 diabetes mellitus without clinical signs of diabetic retinopathy: a prospective pilot study. *Retina* 2020;40:333–344.
- Wilkinson CP, Ferris FL, Klein RE, et al. Proposed international clinical diabetic retinopathy and diabetic macular edema disease severity scales. *Ophthalmology* 2003;110:1677–1682.
- Hirano T, Kitahara J, Toriyama Y, et al. Quantifying vascular density and morphology using different swept-source optical coherence tomography angiographic scan patterns in diabetic retinopathy. *Br J Ophthalmol* 2019;103:216–221.
- Zhang A, Zhang Q, Wang RK. Minimizing projection artifacts for accurate presentation of choroidal neovascularization in OCT micro-angiography. *Biomed Opt Express* 2015;6:4130–4143.
- Phansalkar N, More S, Sabale A, Joshi M. Adaptive local thresholding for detection of nuclei in diversity stained cytology images. In: 2011 International Conference on Communications and Signal Processing. Kerala, India IEEE; 2011:218–220. doi:10.1109/ICCSP.2011.5739305.
- Chu Z, Zhou H, Cheng Y, et al. Improving visualization and quantitative assessment of choriocapillaris with swept source

- OCTA through registration and averaging applicable to clinical systems. *Sci Rep* 2018;8:16826.
25. Kim K, Kim ES, Yu SY. Optical coherence tomography angiography analysis of foveal microvascular changes and inner retinal layer thinning in patients with diabetes. *Br J Ophthalmol* 2018;102:1226–1231.
 26. Spaide RF, Fujimoto JG, Waheed NK. Image artifacts in optical coherence angiography. *Retina* 2015;35:2163–2180.
 27. Spaide RF. Choriocapillaris flow features follow a power law distribution: implications for characterization and mechanisms of disease progression. *Am J Ophthalmol* 2016;170:58–67.
 28. Mastropasqua R, D'Aloisio R, Di Antonio L, et al. Widefield optical coherence tomography angiography in diabetic retinopathy. *Acta Diabetol* 2019;56:1293–1303.
 29. Fundus photographic risk factors for progression of diabetic retinopathy. ETDRS report number 12. Early Treatment Diabetic Retinopathy Study Research Group. *Ophthalmology* 1991;98:823–833.
 30. Chu Z, Zhang Q, Zhou H, et al. Quantifying choriocapillaris flow deficits using global and localized thresholding methods: a correlation study. *Quant Imag Med Surg* 2018;8:1102–1112.
 31. de Carlo TE, Chin AT, Bonini Filho MA, et al. Detection of microvascular changes in eyes of patients with diabetes but not clinical diabetic retinopathy using optical coherence tomography angiography. *Retina* 2015;35:2364–2370.
 32. Nesper PL, Soetikno BT, Fawzi AA. Choriocapillaris nonperfusion is associated with poor visual acuity in eyes with reticular pseudodrusen. *Am J Ophthalmol* 2017;174:42–55.
 33. Blaauwgeers HG, Holtkamp GM, Rutten H, et al. Polarized vascular endothelial growth factor secretion by human retinal pigment epithelium and localization of vascular endothelial growth factor receptors on the inner choriocapillaris. Evidence for a trophic paracrine relation. *Am J Pathol* 1999;155:421–428.
 34. Byon I, Nassisi M, Borrelli E, Sadda S. Impact of slab selection on quantification of choriocapillaris flow deficits by optical coherence tomography angiography. *Am J Ophthalmol* 2019;208. doi:10.1016/j.ajo.2019.08.026.