



HAL
open science

Tyrosine kinase inhibitors and immune checkpoint inhibitors-induced thyroid disorders

Arnaud Jannin, Nicolas Penel, Miriam Ladsous, Marie Christine Vantyghem,
Christine Do Cao

► **To cite this version:**

Arnaud Jannin, Nicolas Penel, Miriam Ladsous, Marie Christine Vantyghem, Christine Do Cao. Tyrosine kinase inhibitors and immune checkpoint inhibitors-induced thyroid disorders. *Critical Reviews in Oncology/Hematology*, 2019, 141, pp.23 - 35. 10.1016/j.critrevonc.2019.05.015 . hal-03480676

HAL Id: hal-03480676

<https://hal.science/hal-03480676v1>

Submitted on 20 Dec 2021

HAL is a multi-disciplinary open access archive for the deposit and dissemination of scientific research documents, whether they are published or not. The documents may come from teaching and research institutions in France or abroad, or from public or private research centers.

L'archive ouverte pluridisciplinaire **HAL**, est destinée au dépôt et à la diffusion de documents scientifiques de niveau recherche, publiés ou non, émanant des établissements d'enseignement et de recherche français ou étrangers, des laboratoires publics ou privés.



Distributed under a Creative Commons Attribution - NonCommercial 4.0 International License

Tyrosine Kinase Inhibitors and Immune Checkpoint inhibitors-induced thyroid disorders

Arnaud Jannin (Resident)¹, Nicolas Penel (MD-PhD)^{2,3}, Miriam Ladsous (MD)¹, Marie Christine Vantghem (MD-PhD)^{1,4}, Christine Do Cao (MD)¹.

¹ Department of Endocrinology and Metabolism, CHU Lille, 59037 Lille France

² Medical Oncology Department, Oscar Lambret Cancer Centre, Lille, France

³ Medical Oncology Department, CHU Lille, 59037, Lille France

⁴UMR 1190 Translational Research in Diabetes INSERM, 59000 Lille, France

Running title: New anticancer therapies and thyroid disorders

Keywords: Thyroiditis, Tyrosine kinase inhibitors, Immunotherapy, Immune checkpoint inhibitors, toxicity, thyrotoxicosis, hypothyroidism

Table or figure: 3 tables and 3 figures

Author Disclosure Statement

The authors have no competing interests and nothing to disclose.

The authors thank Elsevier for the proofreading of the English version.

Names and address of corresponding authors

Jannin Arnaud and Do Cao Christine

Department of Endocrinology, Diabetology and Metabolism

arnaud.jannin.aj@gmail.com

christine.docao@chru-lille.fr

CHU Lille

1, Rue Polonovski, 59037 Lille, FRANCE

Phone: +33 (0)3 2 0444 535

Fax: +33 (0)3 2 0446 985

| Author's name | Affiliation and contact |
|--------------------------|---|
| Arnaud Jannin | Department of Endocrinology and Metabolism, CHU Lille, 59037 Lille France. arnaud.jannin.aj@gmail.com |
| Nicolas Penel | Medical Oncology Department, Oscar Lambret Cancer Centre, Lille, France Medical Oncology Department, CHU Lille 59037 Lille, France. n-penel@o-lambret.fr |
| Miriam Ladsous | Department of Endocrinology and Metabolism, CHU Lille, 59037 Lille France miriam.ladsous@chru-lille.fr |
| Marie-Christine Vantghem | Department of Endocrinology and Metabolism, CHU Lille, 59037 Lille France UMR 1190 Translational Research in Diabetes INSERM, 59000 Lille, France Mariechristine.VANTYGHM@chru-lille.fr |
| Christine Do Cao | Department of Endocrinology and Metabolism, CHU Lille, 59037 Lille France christine.docao@chru-lille.fr |

Tyrosine Kinase Inhibitors and Immune Checkpoint inhibitors-induced thyroid disorders

Key-words: Thyroiditis, Tyrosine kinase inhibitors, Immunotherapy, Immune checkpoint inhibitors, toxicity, thyrotoxicosis, hypothyroidism

Abstract

Recently, tyrosine kinase inhibitors (TKI) and immune checkpoint inhibitors (ICPIs) have emerged as new classes of anticancer therapies. Although generally considered less toxic than cytotoxic chemotherapy, these new drugs can cause significant unanticipated side effects including thyroid dysfunction. This review provides a literature assessment of thyroid dysfunctions induced by TKI and ICPIs. We intend to define for these two classes the frequency of thyroid involvement, the potential mechanisms that result in this toxicity, the clinical-biological impact and the therapeutic management. Detection of thyroid dysfunction requires monitoring of TSH, in combination with free T4 if needed and, depending on the clinical impact and the kinetics of biological abnormalities, starting symptomatic treatment of hyperthyroidism and/or correcting hypothyroidism.

I. Introduction:

The development of molecular biology and cancer immunology has brought drastic changes in anticancer therapies in recent years (DiMasi and Grabowski, 2007). In addition to conventional cytotoxic chemotherapy, new therapeutic approaches are now available, based 1/ on the molecular profile of the tumor - such as tyrosine kinase inhibitors (TKIs) which, according to their action profile, block certain self-induced signals from the tumor cell (this is the concept of personalized medicine); and 2/ on the lifting of the immune-tolerance barriers to cancer by means of immune checkpoint inhibitors (ICPIs).

TKIs are classified as targeted therapies because of their mode of action. They bind competitively to the ATP binding sites of tyrosine kinases, whether they are membrane receptor tyrosine kinases or cytosolic protein tyrosine kinases. The kinome defines the set of tyrosine kinase proteins in a cell. TKIs thus block some of these proteins that play a key role in cell signaling and whose activity is deregulated in cancers. As deregulated pathways tend to promote energy metabolism and cancer cell survival, thus TKIs can restore control of cell proliferation. The spectrum of activity of these TKIs is extremely variable from one molecule to another (inhibition of one to several tyrosine kinases). Some TKIs have also been designed to preferentially inhibit angiogenesis and to limit the metastatic spread of cancer cells (Arora and Scholar, 2005; Krause and Van Etten, 2005) (Figure 1). These compounds might hence exhibit toxicity against highly vascularized organs like thyroid gland. TKIs are now used in metastatic kidney cancers, gastrointestinal stromal tumors (GIST), chronic myeloid leukemias, acute lymphoblastic leukemias, some sarcomas, hepatocellular carcinomas, certain bronchial cancers, medullary thyroid cancer and differentiated thyroid cancer refractory to iodine-131.

The principle of immunotherapy against solid cancer is to amplify the adaptive cytotoxic T-cell-mediated antitumor immune reaction (Figure 1). One effective strategy currently used is blocking some immune inhibitory “checkpoints” like PD1 (Programmed Cell Death 1), PDL1 (Programmed Cell Death Ligand 1) or CTLA4 (Cytotoxic T lymphocyte antigen-4) preventing them to blunt T-cell proliferation and activation against tumor cells (Brahmer et al., 2012; Topalian et al., 2012). Three families of ICPIs are currently marketed: anti-CTLA4 (ipilimumab, tremelimumab), anti-PD1 (nivolumab, pembrolizumab) and anti-PDL1 (avelumab, atezolizumab, durvalumab). These molecules have improved the survival of cancer patients but are accompanied by autoimmune side effects, manifested by various tissue inflammatory reactions, especially in the thyroid (Arora and Scholar, 2005; Brahmer et al., 2012; Eggermont et al., 2016; Gharwan and Groninger, 2016; Krause and Van Etten, 2005; Topalian et al., 2012).

The thyroiditis induced by these therapies occurs at varying frequencies and can be manifested by biological hyper- or hypothyroidism depending on when the thyroid disorder is recognized or both successively. Cooperation between endocrinologist and oncologist generally enables the continuation of anti-cancer therapy and the supervision of symptomatic treatment of dysthyroidism.

This article provides a comprehensive assessment of the literature relating to the thyroid side effects of TKIs and ICPIs.

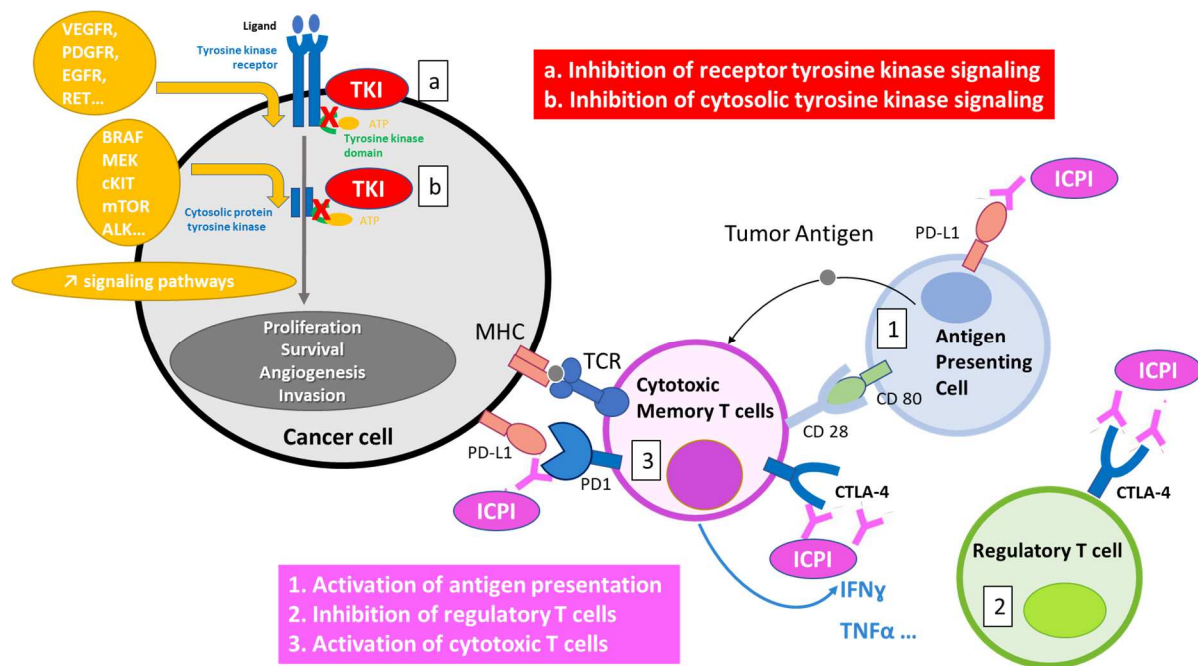


Figure 1: Mechanisms of action of TKIs and ICPIs. Adapted from (Orlov et al., 2015).

TKIs block the activation of proteins involved in the signaling pathways of cell survival and angiogenesis (a,b). ICPIs block the action of immune tolerance effectors (1, 2) and induce the recruitment of cytotoxic T lymphocytes (3).

TKI: Tyrosine Kinase Inhibitor, symbolized by

ICPI: Immune Checkpoint Inhibitor (Anti-PD-1, Anti-PDL1, Anti-CTLA-4), symbolized by

ALK: Anaplastic lymphoma kinase, ATP: Adenosine triphosphate, B-RAF: B-Rapidly Accelerated Fibrosarcom, CD: Cluster of differentiation, CKIT: C-kit receptor, CTLA-4: Cytotoxic T Lymphocyte-Associated Antigen-4, EFGFR: Endothelial Growth Factor Receptor, INF γ : Interferon gamma, MEK: Mitogen-activated Extracellular signal regulated Kinase, MHC: Major Histocompatibility Complex, mTOR: mechanistic target of rapamycin, PDGFR: Platelet Derived Growth Factor Receptor, PD1: Programmed cell Death-1, PDL1: Programmed Death-Ligand 1, RET: Rearranged during Transfection, TCR: T Cell Receptor, TNF α : Tumor Necrosis Factor-alpha, VEGFR: Vascular Endothelial Growth Factor Receptor

II. Thyroid dysfunction associated with TKIs and ICPIs is common and benign (Table 1)

The prevalence of thyroid dysfunction (hypo- or hyperthyroidism) related to a TKI or ICPI varies considerably from about 3.1% to 100% depending on the type of molecule, the dose administered, the types of thyroid monitoring and the recording accuracy of these events (see Table 1 and Table 2) (Abdel-Rahman and Fouad, 2014; Barroso-Sousa et al., 2018b, 2018a; Boutros et al., 2016; de Filette et al., 2016; Delivanis et al., 2017; Fallahi et al., 2014; Gharwan and Groninger, 2016; Kim et al., 2010; Morganstein et al., 2017; Orlov et al., 2015; Pani et al., 2017; Sznol et al., 2017; Torino et al., 2009). Given the frequency of this iatrogenic dysthyroidism, it should be noted that the prevalence of clinical hypothyroidism in the general population is between 0.2% and 5.3% in Europe and between 0.3% and 3.7% in the United States, while the prevalence of clinical hyperthyroidism is similar in Europe and the United States (0.7% versus 0.5%) (Taylor et al., 2018). These figures depend of course on the definition used and the population studied (iodine-deficient or not) but illustrate the causality of these treatments in the thyroid dysfunctions identified.

The quality of report of thyroid toxicity induced by TKIs or ICPIs depends on the rigor of clinical trials that were not designed to evaluate the frequency of thyroid side effects. Indeed, these studies list sometimes established or incipient hypothyroidism, sometimes variations of thyroid stimulating

hormone (TSH) or increase in thyroid hormone therapy, sometimes global endocrine effects. In addition, the pattern of monitoring the thyroid biological parameters differed from one trial to another. Finally, the studies rarely detail previous or concomitant treatments, such as interferon, amiodarone, radiation therapy to the neck and brain, corticosteroid therapy and repeated iodine contrast injection for CT scan, which can also modify the thyroid function or thyrotropic hormone regulation. Moreover, the gradation of thyroid toxicities according to the Common Terminology Criteria for Adverse Events (CTCAE) scale used in oncology describes the outcome of the thyroid disorder but does not make it possible to decide on the treatment to be initiated. This specific management will depend on the amplitude of variations in the TSH/free T4 levels, the clinical impact, and the transient or permanent nature of dysthyroidism. In general, hospitalization is not required (grade 3) and the indication of symptomatic treatment of thyrotoxicosis or correction of hypothyroidism (grade 2) is not in itself a criterion of severity.

The probability of developing TKI-induced dysthyroidism depends on the patient's background (risk is higher in female and older patient groups), the existence of associated thyroid disorder, the duration of TKI exposure and the molecule (Beukhof et al., 2017; Funakoshi and Shimada, 2013; Illouz et al., 2009; Lechner et al., 2018). On the other hand, the type of cancer treated does not seem to be a factor modifying the risk of thyroid side effects.

Thus, TKI-induced thyroid toxicity involves mainly compounds targeting VEGFR1-3 (Vascular Endothelial Growth Factor Receptor) or PDGFR (Platelet Derived Growth Factor Receptor) such as sunitinib, sorafenib, axitinib and vandetanib unlike other TKI such as nilotinib, imatinib and dasatinib that do not target angiogenic receptors (Table 1) (Abdel-Rahman and Fouad, 2014; Kim et al., 2010). But this observation requires a cautious interpretation given the small number of subjects in some studies using TKIs. By contrast, thyroid dysfunction has not been reported *in vivo*, with treatments such as monoclonal antibodies directing against VEGF (bevacizumab and aflibercept) though reduction of thyroid perfusion may occur (van der Veldt et al., 2013) nor with TKIs targeting EGFR (Epidermal Growth Factor Receptor) (cetuximab and panitumumab), ALK (Anaplastic Lymphoma Kinase) and MEK (Mitogen-activated Protein Kinase Kinase).

Iatrogenic thyroid disorder related to TKIs is mainly caused by destructive thyroiditis, probably due to vascular damage. A thyrotoxic phase is often reported first after a median treatment duration of 6 weeks (1-70 weeks), then hypothyroidism occurs after a median duration of 22 weeks (1-135) (Abdel-Rahman and Fouad, 2014; Kim et al., 2010). Most cases of hyperthyroidism are brief (nearly 80%) and almost always of grade 1 or 2 (98 to 100% of patients) (Bianchi et al., 2013; Kim et al., 2010). Hyperthyroidism affects an average of 15.8% of patients undergoing TKI therapy (Abdel-Rahman and Fouad, 2014; Fallahi et al., 2014; Illouz et al., 2009; Kim et al., 2010; Ohba et al., 2013; Torino et al., 2009) and corresponds rather to a state of transient thyrotoxicosis, most often subclinical (Table 1). The occurrence of hypothyroidism is late and prolonged (Table 1), easy to recognize and therefore reported more frequently (18% of cases). In a recent meta-analysis, the relative risk of hypothyroidism was 3.59 [95% CI: 2.40-5.38; $p < 0.0001$] (Abdel-Rahman and Fouad, 2014). TKI-induced hypothyroidism may persist when treatment is discontinued (Beukhof et al., 2017; Illouz et al., 2009; Wolter et al., 2008).

Table 1: Frequency and presentation of dysthyroidism during TKI therapy (number of patients with thyroid dysfunction/number of patients in the study).

CCRCC: Clear Cell Renal Cell Carcinoma, CML: Chronic Myeloid Leukemia, FGFR: Fibroblast Growth Factor Receptors, GIST: Gastro-Intestinal Stromal Tumor, HCC: Hepatocellular carcinoma, HL: Hodgkin's Lymphoma, HNSCC: Head and Neck Squamous Cell Carcinoma, ND: Non determined, NET: Neuroendocrine Tumor, NSCLC: Non-Small Cell Lung Cancer, PDGFR: Platelet Derived Growth Factor Receptor, TKI:

*Tyrosine Kinase Inhibitor, UC: Urothelial Carcinoma, VEGFR: Vascular Endothelial Growth Factor Receptors,
: Increased doses of levothyroxine after total thyroidectomy.

| Name of TKI Targeted tyrosine kinases Indications | References | Thyrotoxicosis | Transient Hypothyroidism | Definitive Hypothyroidism | Thyrotoxicosis then hypothyroidism | Dysthyroidism (within each study) minimum/maximum frequency | Dysthyroidism (all studies) main frequency |
|---|---------------------------|----------------|-----------------------------|------------------------------|--|--|--|
| <i>Axitinib</i> (VEGFR 1-3, PDGFR, C-Kit) CCRCC | (Ohba et al., 2013) | 5/6 (83%) | 5/6 (83%) | ND | 4/6 (66.6%) | 6/6 (100%) | 137-157/580 (15.5-23.6%) |
| | (Ueda et al., 2013) | ND | 69/355 (19.4%) | ND | ND | 69/355 (19.4%) | |
| | (Hutson et al., 2013) | ND | 39/189 (20.6%) | ND | ND | 39/189 (20.6%) | |
| | (Karam et al., 2014) | ND | 17/24 (70.8%) | ND | ND | 17/24 (70.8%) | |
| | (Daimon et al., 2012) | 0/6 | 6/6 (100%) | ND | ND | 6/6 (100%) | |
| | (Mukohara et al., 2010) | 5/12 (41.7%) | 7/12 (58.3%) | ND | 3/12 (25%) | 9/12 (75%) | |
| | (Tomita et al., 2011) | 20/64 (31.3%) | 31/64 (48.4%) | ND | ND | 31-51/64 (48.4-79.7%) | |
| (Motzer et al., 2013a) | ND | 72/359 | ND | ND | 72/359 (20%) (19.4-100%) | | |
| <i>Dasatinib</i> (BCR-ABL, Src, C-Kit, EphR) Acute lymphoblastic leukemia | (Kim et al., 2010) | 2/10 (20%) | 4/ 10 (40%) | 1/10 (10%) | 1/10 (10%) | 6/10 (60%) | 6/10 (60%) |
| <i>Imatinib</i> (BCR-ABL, RET, PDGFR, C-Kit) CML, GIST, Dermatofibrosarcoma protuberans | (Kim et al., 2010) | 1/8 (12.5%) | 1/8 (12.5%) | 0/8 | 0/8 | 2/8 (25%) | 18/31 (58.1%) |
| | (de Groot et al., 2007) | ND | ND | 9/15 (60%) | ND | 9/15 (60%) | |
| | (de Groot et al., 2005) | ND | 7/8* (87.5%) | ND | ND | 7/8 (87.5%) 25-87.5% | |
| <i>Nilotinib</i> (BCR-ABL, C-Kit, LCK, EPHA3,8, DDR1, DDR2, PDGFR, MAPK11, ZAK) CML | (Kim et al., 2010) | 18/55 (32.7%) | 6/55 (10.9%) | ND | 5/55 (9.09%) | 25/55 (45.4%) | 25/55 (45.4%) |
| <i>Pazopanib</i> (VEGFR-1-3, PDGFR, C-Kit) CCRCC, Sarcoma | (Motzer et al., 2013b) | ND | 67/554 (12.1%) | ND | ND | 67/554 (12.1%) | 84/666 (12.6%) |
| | (Matrana et al., 2013) | ND | 17/112 (15.2%) | ND | ND | 17/112 (15.2%) (12.1-15.2%) | |
| <i>Regorafenib</i> (VEGFR 1-3, PDGFR, KIT, RET, FGFR 1-2, TIE2, DDR2, Trk2A, Eph2A, RAF-1, BRAF, SAPK2, PTK5) CCRCC, GIST, HCC | (Pani et al., 2017) | 1/25 (4%) | ND | 11/25 (44%) | 1/25 (4%) | 11/25 (44%) | 26/61 (42%) |
| | (Bruix et al., 2013) | ND | 15/36 (41.7%) | ND | ND | 15/36 (41.7%) (41.7-44%) | |
| <i>Sorafenib</i> (VEGFR 1-2, RET, PDGFR, C-KIT, RAF) CCRCC, HCC, Follicular thyroid Carcinoma refractory to | (Tamaskar et al., 2008) | 1/39 (2.6%) | 7/39 (17.9%) | ND | ND | 8/39 (20.5%) | 149-160/1455 (10.2-11%) |
| | (Clement P et al., 2008) | 1/23 (4.3%) | 7/23 (30.4%) | ND | ND | 8/23 (34.8%) | |
| | (Riesenbeck et al., 2011) | ND | 8/31 (25.8%) | ND | ND | 8/31 (25.8%) | |
| | (Ueda et al., 2013) | ND | 29/355 (8.2%) | ND | ND | 29/355(8.2%) | |
| | (Hutson et al., 2013) | ND | 7/96 (7.3%) | ND | ND | 7/96 (7.3%) | |

| | | | | | | | |
|--|-----------------------------|---------------|------------------|---------------|--------------|-----------------------|-----------------------|
| Radioactive iodine | (Miyake et al., 2010) | 11/69 (15.9%) | 46/69 (66.7) | ND | ND | 46-57/69 (66.7-82.6%) | |
| | (Daimon et al., 2012) | 0/12 | 6/12 (50%) | ND | ND | 6/12 (50%) | |
| | (Kudo et al., 2018) | ND | 8/475 (16.8%) | ND | ND | 8/475 (16.8%) | |
| | (Motzer et al., 2013a) | ND | 29/355 (8.2%) | ND | ND | 29/355 (8.2%) | |
| | | | | | | (7.3-82.6%) | |
| <i>Sunitinib</i> | (Desai et al., 2006) | 10/42 (23.8%) | 7/42 (16.7%) | 15/42 (35.7%) | 6/42 (14.3%) | 26/42 (61.9%) | |
| (VEGFR-2, PDGFR, c-KIT, RET, CSF-1R, FLT3) CCRCC, GIST, pancreatic NET | (Rini et al., 2007) | 10/66 (15.1%) | 46/66 (69.7%) | ND | ND | 46-56/66 (69.7-84.8%) | 1318-1349/7532 |
| | (Schoeffski et al., 2006) | 6/33 (18.2%) | 15/33 (45.4%) | ND | ND | 15-21/33 (45.4-63.6%) | (17.5-17.9%) |
| | (Wong et al., 2007) | 3/40(7.5%) | 21/40 (52.5%) | ND | ND | 21-24/40 (52.5-60%) | |
| | (Mannavola et al., 2007) | ND | 17/24 (70.8%) | ND | ND | 17/24 (70.8%) | |
| | (Wolter et al., 2008) | 3/59 (5.1%) | 16/59 (27.1%) | ND | ND | 16-19/59 (27.1-32.2%) | |
| | (Shinohara et al., 2011) | 4/17 (23.5%) | 9/17 (52.9%) | ND | 4/17 | 9-13/17 (52.9-76.4%) | |
| | (Riesenbeck et al., 2011) | ND | 8/52 (15.4%) | ND | ND | 8/52 (15.4%) | |
| | (Daimon et al., 2012) | 4/15 (26.7%) | 7/15 (46.7%) | ND | 2/15 (13.3%) | 9/15 (60%) | |
| | (Fallahi et al., 2014) | 5/24 (20.8%) | 8/24 (33.3%) | 3/24 (12.5%) | ND | 12/24 (50%) | |
| | (Rini et al., 2008) | ND | 18/61 (29.5%) | ND | ND | 18/61 (29.5%) | |
| | (Motzer et al., 2013b) | ND | 133/548 (24.3%) | ND | ND | 133/548 (24.3%) | |
| | (Motzer et al., 2012) | ND | 30/292 (10.3%) | ND | ND | 30/292 (10.3%) | |
| | (Akaza et al., 2015) | ND | 593/1671 (35.5%) | ND | ND | 593/1671 (35.5%) | |
| | (Coelho et al., 2016) | ND | 25/58 (43.1%) | ND | ND | 25/58 (43.1%) | |
| | (Gore et al., 2009) | ND | 261/4371 (6%) | ND | ND | 261/4371 (6%) | |
| | (Kappers et al., 2011) | 5/83 (6%) | 35/83 (42.2%) | ND | ND | 35-40/83 (42.2%) | |
| | (Sabatier et al., 2012) | 3/102 (29.4%) | 51/102 (50%) | ND | ND | 51-54/102 (50-53%) | |
| | | | | | | (6-84.8%) | |
| <i>Vandetanib</i> | (Robinson et al., 2010) | ND | 2/17* (11.8%) | ND | ND | 2/17* (11.8%) | 126/259 |
| (VEGFR-2-3, RET, BRK, TIE2, Ephr & Src) Medullary thyroid cancer * | (Wells et al., 2012) | ND | 114/231* (49.3%) | ND | ND | 114/231* (49.3%) | (48.6%) |
| | (Lodish et al., 2015) | ND | 10/11* (91%) | ND | ND | 10/11* (91%) | |
| | | | | | | (11.8-91%) | |
| <i>Cabozantinib</i> | (Yavuz et al., 2014) | 5/29 (17.2%) | 21/29 (72.4%) | 11/29 (37.9%) | 3/29 (10.3%) | 27/29 (93.1%) | |
| (VEGFR1-3, RET, MET, KIT, TRKB, FLT-3, AXL, ROS1, TYRO3, MER & TIE-2) CCRCC, Medullary thyroid cancer* | (Prisciandaro et al., 2018) | ND | 4/17 (13.8%) | ND | ND | 4/17 (23.5%) | |
| | (Rabinowits et al., 2018) | ND | 4/8 (50%) | ND | ND | 4/8 (50%) | 146/677 |
| | (Choueiri et al., 2015) | ND | 67/331 (20.2%) | ND | ND | 67/331 (20.2%) | |
| | (Schlumberger et al., 2017) | ND | 26/214 (12.1%) | ND | ND | 26/214 (12.1%) | |
| | (Choueiri et al., 2018) | ND | 18/78 (23.1%) | ND | ND | 18/78 (23.1%) | |
| | | | | | | (12.1-93.1%) | |
| <i>Lenvatinib</i> | (Koyama et al., 2018) | 0/5 | 4/5 (80%) | ND | ND | 4/5 (80%) | 126/665 |
| (VEGFR1-3, FGFR1- 4, PDGFR α , KIT & RET) Follicular thyroid Carcinoma refractory to Radioactive iodine *, CCRCC (in association with everolimus) | (Kudo et al., 2018) | ND | 78/476 (16.4%) | ND | ND | 78/476 (16.4%) | (18.9%) |
| | (Motzer et al., 2015) | ND | 19/52 (36.5%) | ND | ND | 19/52 (36.5%) | |
| | (Yamada et al., 2011) | ND | 7/27* (25.9%) | ND | ND | 7/27 (25.9%) | |
| | (Schlumberger et al., 2016) | ND | 12/59* (20.3%) | ND | ND | 12/59 (20.3%) | |
| | (Ikeda et al., 2017) | ND | 10/46 (21.7%) | ND | ND | 10/46 (21.7%) | |
| | | | | | | (16.4-80%) | |

Thyroid dysfunction is also a major side effect of ICPIs. It occurs in 3.1 to 25% of patients treated with ICPI as monotherapy, affecting an average 20% of patients receiving multiple ICPI combinations (Table 2). The risk of hyperthyroidism and hypothyroidism is higher in patients treated with anti-PD1 versus anti-PD-L1 and anti-CTLA-4 (Barroso-Sousa et al., 2018a)(Table 2). When a combination of immunotherapy is prescribed, the risk of thyroid toxicity is roughly double than in monotherapy. Schematically, the dysthyroidism under ICPI occurs between the 2nd and the 4th cycle, but there have been cases of dysthyroidism reported up to 3 years after the initiation of treatment (de Filette et al., 2016) (Table 3). When a combination of ICPI is prescribed, dysthyroidism usually appears in the first cycle (de Filette et al., 2016). The risk of developing thyroid disorder depends, as for TKIs, on the patient's background (female predominance and in the elderly), the existence of associated thyroid disorder, the exposure time and the combination with another ICPI (Porta et al., 2016). It is not formally established that a high titer of anti-thyroperoxidase (TPO-Abs) or anti-thyroglobulin (Tg-Abs) antibodies, or that TSH levels at the high end of the normal range before the prescription of immunotherapy are associated with an increased risk of thyroid toxicity.

Some studies have shown a statistical correlation between the occurrence of thyroid dysfunction when prescribing TKIs or ICPIs and a better prognosis in progression-free survival and overall survival. (Beukhof et al., 2017; Osorio et al., 2017; Pani et al., 2017; Riesenbeck et al., 2011; Schmidinger et al., 2011). This can be explained by the anti-angiogenic effect of TKIs or the immune-mediated effects of immunotherapy involving both cancer and thyroid. Therefore, the thyroid function could serve as an indirect "sensor" for the effect of TKIs or ICPIs (Makita and Iiri, 2013). However, there is an analytical bias because surviving patients will have more time to develop treatment-related toxicity than those who die early.

Table 2: Thyroid effects of different types of immunotherapy (number of patients with thyroid dysfunction/number of patients in the study).

CCRCC: Clear Cell Renal Cell Carcinoma, HL: Hodgkin Lymphoma, HNSCC: Head and Neck Squamous Cell Carcinoma, ICPI: Immune Checkpoint Inhibitor, MSI+: Microsatellite instability, ND: Non determined. NSCLC: Non-Small Cell Lung Cancer, P.I: Prescribing Information, UC: Urothelial Carcinoma.

| Class of ICPI Name of ICPI Indications | References | Thyrototoxicosis | Transient Hypothyroidism | Definitive Hypothyroidism | Thyrototoxicosis then Hypothyroidism | Dysthyroidism (within each study) | Dysthyroidism (all studies) | | |
|---|--|-----------------------|-----------------------------|------------------------------|--|--------------------------------------|--|-----------------------|---|
| Anti-CTLA4 <i>Ipilimumab</i> Melanoma/NSCLC | (Eggermont et al., 2016) | ND | ND | 48/471 (10.2%) | ND | 48/471 (10.2%) | 127/1698 (7.4%) | | |
| | (Robert et al., 2015) | 6/256 (2.3%) | ND | 2/256 (0.8%) | ND | 8/256 (3.1%) | | | |
| | (Larkin et al., 2015) | 3/311 (2.7%) | ND | 13/311 (11.7%) | ND | 13/311 (11.7%) | | | |
| | (Wolchok et al., 2017) | 3/311 (2.7%) | ND | 14/311 (12.6%) | ND | 14/311 (12.6%) | | | |
| | (Hodi et al., 2016) | 0/46 | ND | 6/46 (13%) | ND | 6/46 (13%) | | | |
| | (McDermott et al., 2013) | ND | ND | 2/131 (15.3%) | ND | 2/131 (15.3%) | | | |
| | (Postow et al., 2015) | 0/46 | ND | 7/46 (15.2%) | ND | 7/46 (15.2%) | | | |
| | (Morganstein et al., 2017) | 20/126 (15.8%) | ND | 9/126 (7.1%) | ND | 29/126 (23%) | | | |
| (3.1-23%) | | | | | | | | | |
| Anti-PD-1 <i>Nivolumab</i> Melanoma/NSCLC/ CCRCC/HL/HNSC C/ UC | (Borghaei et al., 2015) | 4/287 (1.4%) | ND | 17/287 (5.9%) | ND | 17-21/287 (5.9-7.3%) | 133-158/1656 (8-9.5%) | | |
| | (Larkin et al., 2015) | 13/313 (4.1%) | ND | 27/313 (8.6%) | 2/313 (0.6%) | 40/313 (12.8%) | | | |
| | (Weber et al., 2015) | 5/268 (1.9%) | ND | 16/268 (6%) | ND | 16-21/268 (6-7.8%) | | | |
| | (Ferris et al., 2016) | 2/236 (0.8%) | ND | 9/236 (3.8%) | ND | 9-11/236 (3.8-4.7%) | | | |
| | (Wolchok et al., 2017) | 14/313 (4.5%) | ND | 33/313 (10.5%) | ND | 33-47/313 (10.5-15%) | | | |
| | (Brahmer et al., 2015) | ND | ND | 5/131 (3.8%) | ND | 5/131 (3.8%) | | | |
| | (Antonia et al., 2016) | 2/98 (2%) | ND | 3/98 (3.1%) | ND | 3/98 (3.1%) | | | |
| | (3.1-12.8%) | | | | | | | | |
| | <i>Pembrolizumab</i> Melanoma/NSCLC/ CRCC/HL/HNSCC /UC/MSI+ Cancers | (Robert et al., 2015) | 17/278 (6.1%) | ND | 25/278 (9%) | ND | | 42/278 (15.1%) | 230-283/2415 (9.5-11.7%) |
| | | (Ribas et al., 2016) | 15/655 (2.3%) | ND | 49/655 (7.5%) | ND | | 49- 64/655 (7.5-9.8%) | |
| (Reck et al., 2016) | | 12/154 (7.8%) | ND | 14/154 (9.1%) | ND | 14-26/124 (9.1-21%) | | | |
| (Bellmunt et al., 2017) | | 10/266 (3.8%) | ND | 17/266 (6.4%) | ND | 17-27/266 (6.4-10.2%) | | | |
| (Garon et al., 2015) | | 9/495 (1.8%) | ND | 34/495 (6.9%) | ND | 34-43/495 (6.9-8.7%) | | | |
| (Robert et al., 2015) | | ND | ND | 32/357 (9%) | ND | 32/357 (9%) | | | |
| (de Filette et al., 2016) | | 12/99 (12.1%) | 0/99 | 15/99 (15.2%) | 9/99 (9.1%) | 17/99 (17.2%) | | | |
| (Delivanis et al., 2017) | | 7/93 (7.5%) | 1/93 (1.1%) | 8/93(8.6%) | 3/93 (3.2%) | 13/93(14%) | | | |
| (Osorio et al., 2017) | 8/48 (16.7%) | 0/48 | 10/48 (20.8%) | 6/48 (12.5%) | 12/48 (25%) | | | | |
| (7.5-25%) | | | | | | | | | |
| Anti-PDL1 <i>Atezolizumab</i> UC | (Fehrenbacher et al., 2016) | ND | ND | 9/142 (6.3%) | ND | 9/142 (6.3%) | 170-212/3536 (4.8-6%) | | |
| | (Peters et al., 2017) | ND | ND | 33/659 (5%) | ND | 33/659 (5%) | | | |
| | (Balar et al., 2017) | ND | ND | 8/119 (6.7%) | ND | 8/119 (6.7%) | | | |
| | (Atezolizumab), p.i) | 42/2616 (1.6%) | ND | 120/2616 (4.6%) | ND | 120-162/2616 (4.6-6.2%) | | | |
| (4.6-6.7%) | | | | | | | | | |
| <i>Avelumab</i> Merkel Carcinoma | (Gulley et al., 2017) | ND | ND | 11/184 (6%) | ND | 11/184 (6%) | 119/2024 (5.9%) | | |
| | (Avelumab), p.i.,2017) | 8/1738 (0.5%) | ND | 90/1738 (5.2%) | ND | 98/1738 (5.6%) | | | |
| (5.6-6%) | | | | | | | | | |
| | | | | | ND | | 156-167/1608 | | |

| | | | | | | | |
|-----------------------------------|----------------------------|----------------|----|-----------------|---------------|------------------------|-------------------------------------|
| <u>Durvalumab</u> | (Antonia et al., 2016) | ND | ND | 10/102 (9.8%) | ND | 10/102 (9.8%) | (9.1-9.7%) |
| UC ADDIN | (Powles et al., 2017) | 10/191 (5.2%) | ND | 10/191 (5.2%) | ND | 10-20/191 (5.2-10.5%) | |
| | (Durvalumab), p.i, 2017) | 1/1417 (0.07%) | ND | 136/1417 (9.6%) | | 136-137/1417 (9.6%) | |
| | | | | | | (5.2-10.5%) | |
| Immunotherapy combinations | (Larkin et al., 2015) | 31/313 (10%) | ND | 47/313 (15%) | 12/313 (3.8%) | 66/313 (21.1%) | 173-226/947 (18.3-23.9%) |
| | (Wolchok et al., 2017) | 35/313 (11.1%) | ND | 53/313 (16.9%) | ND | 53-88/313 (16.9-28.1%) | |
| <u>Nivolumab+</u> | (Hodi et al., 2016) | 4/94 (4.3%) | ND | 16/94 (17%) | ND | 16-20/94 (17-21.3%) | |
| <u>Ipilimumab</u> | (Antonia et al., 2016) | 10/115 (8.7%) | ND | 14/115 (12.2%) | ND | 14-24/115 (12.2-20.9%) | |
| Melanoma | (Postow et al., 2015) | 4/94 (4.3%) | ND | 15/94 (16%) | ND | 15-19/94 (20.2%) | |
| | (Morganstein et al., 2017) | 4/18 (22.2%) | ND | 5/18 (27.7%) | 3/18 (16.7%) | 9/18 (50%) | (12.2-50%) |

Table 3: Median time in months to occurrence of hyperthyroidism as well as hypothyroidism according to the immunotherapy molecule (Eggermont et al., 2016; Jaafar et al., 2018; Morganstein et al., 2017)

ICPI: Immune Checkpoint Inhibitor, NSCLC: Non-Small Cell Lung Cancer, UC: Urothelial Carcinoma.

| Class of ICPI | Anti-CTLA4 | | Anti-PD1 | | Anti-PDL1 | |
|------------------------|------------------|-----------------------|---------------|---|---------------|------------------|
| | Ipilimumab | Nivolumab | Pembrolizumab | Atezolizumab | Avelumab | Durvalumab |
| Hyperthyroidism | 1.64 (1.18-3.64) | 0.76-1.48 (0.03-14.2) | 1.4 (0.03-22) | 3.2 (1.4-5.8) in UC 4.9 (0.69-31) in NSCLC | 2.8 (0.49-13) | 1.41 (0.46-2.33) |
| Hypothyroidism | 2.13 (0.85-2.96) | 2-3 (0.03-22) | 3.5 (0.03-19) | 5.4 (0.69-11.3) in UC 4.8 (0.49-31) in NSCLC | | 1.38 (0.49-7.85) |

III. Pathophysiology of thyroid side effects induced by TKIs and ICPIs (Figure 2)

The cumulative clinical experience of recent years and the basic studies have led to a better understanding of the mechanisms of thyroid dysfunction. Schematically, we may consider that the iatrogenic thyroiditis of TKIs is linked to vascular damage and the iatrogenic thyroiditis of ICPIs is based on an inflammatory mechanism by autoimmune reaction. Additional pathophysiological hypotheses have been put forward to explain the worsening hypothyroidism of the thyroidectomized subject, involving alteration of the transport and metabolism of thyroid hormones with certain TKIs.

Sunitinib-induced thyroid toxicity has been the most studied clinical model for 10 years. Desai et al, have conducted a prospective study with 42 patients treated by sunitinib. Persistent primary hypothyroidism occurred in 15 (36%) patients. Six of 15 (40%) hypothyroid patients had suppressed TSH concentrations before developing hypothyroidism suggesting induced thyroiditis through a destructive mechanism (Desai et al., 2006). Such biphasic thyroiditis pattern was reported from 13,3 to 87,5% of cases (Table 1). First, thyrotoxicosis is reported, accompanied by a transient increase in thyroglobulin associated with TKI-induced cell lysis, and then hypothyroidism develops secondarily. This sequence is repeated at each cycle when an intermittent on/off pattern is prescribed. When several cycles of treatment are performed, a decreased vascularization of the thyroid parenchyma is reported with thyroid hypotrophy which will eventually be responsible for permanent hypothyroidism if the treatment is prolonged. (Desai et al., 2006; Kappers et al., 2011; Makita and Iiri, 2013; Sato et al., 2010). The thyroiditis reported with anti-angiogenic TKIs is therefore the consequence of devascularization of the thyroid vesicles, which represent the functional units of the thyroid. The vascularization abnormalities and the resulting cellular hypoxia are related to capillary regression mediated by the anti-VEGFR effect (Cao, 2014; Kamba et al., 2006; Kappers et al., 2011; Makita et al., 2010; Yang et al., 2013). There is both functional and structural damage. Indeed, VEGF-A/VEGFR2 signaling is directly involved in all fenestrated capillaries (which allows the introduction of iodine and the secretion of thyroid hormones through the endothelial cells) and in the trophic development of the thyroid tissue, according to the work conducted in murine models (Jang et al., 2017). Therefore blocking this signaling pathway also leads to a decreased synthesis of thyroid hormones (Cao, 2014; Kamba et al., 2006; Kitajima et al., 2012; Makita et al., 2010; Mannavola et al., 2007; Yang et al., 2013). Other intra-thyroid mechanisms have been suspected in the occurrence of hypothyroidism under TKI, such as the inhibition of iodine uptake by thyrocytes and the inactivation of thyroperoxidase (Liwanpo et al., 2014; Mannavola et al., 2007; Salem et al., 2008; Simonides et al., 2008; Wong et al., 2007). These hypotheses were subsequently invalidated because this functional impairment was a logical consequence of the ischemia and tissue damage induced by TKI. Regarding the central nervous system, it is also assumed that some TKIs, by decreasing the production of nitric oxide, could decrease the secretion of TRH by the paraventricular nucleus of the hypothalamus and thus decrease the secretion of TSH by the thyrotrophic pituitary cells (Ohba et al., 2013). TKIs also have effects on the peripheral metabolism of thyroid hormones regardless of their own thyroid toxicity. In thyroidectomized patients treated with TKIs, there is an increased demand for thyroid hormone. Indeed, TKIs such as sunitinib or sorafenib increase the activity of type 3 deiodinase (as evidenced by the decrease in T3/T4 and T3/rT3 ratios) resulting in hypothyroidism because of lower tissue availability of the active hormone T3, locally inactivated in T2 or rT3 (Abdulrahman et al., 2010; Beukhof et al., 2017; Kappers et al., 2011). Finally, other TKIs such as imatinib, bosutinib and dasatinib, but also sunitinib, can inhibit the transporter of MCT8 thyroid hormones (monocarboxylate transporter) across the plasma membrane, reducing the supply of T3 to peripheral tissues but also centrally, in the thyrotrophic cell (Braun et al., 2012). Thyroid hormones exert their action by binding to specific nuclear receptors that are heterodimerized with a retinoic acid receptor. Sunitinib, by binding

to retinoic acid receptors, could prevent this heterodimerization and thus inhibit the expression of target genes (Shu et al., 2016). Sunitinib also has immunostimulatory properties by inhibiting the expression of CTLA4 and PD1 on CD4+ and CD8+ T cells. If this cytotoxic lymphocyte activation is beneficial for tumor control, it can be exercised against healthy tissues, affecting organs such as the thyroid, on the ICPI toxicity model detailed below (Oza-Choy et al., 2009).

The pathophysiological conception of dysthyroidism linked to immunotherapy is still likely to evolve with the emergence of new research (Angell et al., 2018; Delivanis et al., 2017). A mechanism of silent lymphocytic thyroiditis that in its clinical presentation is similar to the postpartum thyroiditis, at the time of physiological reactivation of the immune system, is currently assumed (Iwatani et al., 1988). Similarly, in the patient under ICPI therapy, following the amplification of the adaptive immune response, a cell-mediated cytotoxic immune reaction occurs linked to mature NK (Natural killers) cells, T helper CD4+ cells and cytotoxic CD8+ T cells (Delivanis et al., 2017). Unlike the typical autoimmune diseases for example, ICPI-related iatrogenic autoimmune disorders are accompanied by a decrease in some immunosuppressive cells and an increase in HLA-DR expression on the surface of CD14+CD16+ monocytes (Delivanis et al., 2017). Some researchers have suggested that thyroiditis induced by pembrolizumab may be related to monocytic activation induced by this overexpression of HLA-DR. These monocytes would infiltrate the thyroid tissue after recognition of antigens similar to the tumor antigens and exert their cytotoxic action, explaining why the first phase of thyrotoxicosis is contemporaneous with an increase in thyroid volume, before returning to normal or before a possible evolution towards hypothyroidism. The analysis of a thyroid fine needle aspiration cytology carried out in a patient with thyroiditis receiving combined treatment with nivolumab and ipilimumab, had in fact numerous necrotic cells and plenty of CD163 histiocytes and lymphocytes (Angell et al., 2018). Other arguments support the hypothesis of a cytotoxic cell-mediated response rather than the induction of humoral immunity: 1/ pembrolizumab - which gives thyroid toxicities - is an IgG4 antibody, an immunoglobulin subclass that is not associated with antibody or complement-mediated cytotoxicity (Davies and Sutton, 2015); 2/ TPO-Abs do not seem to have a pathogenic role for the ICPI-induced dysthyroidism (Delivanis et al., 2017); 3/ in classical autoimmune thyroiditis (Graves' disease, Hashimoto's thyroiditis), the circulating anti-TPO and Tg-Abs levels correlate with T-cell infiltration into the thyroid gland (Huber et al., 2002; Yoshida et al., 1978), which does not seem the case for the thyroiditis induced by ICPIs.

For the issue of thyroid disorder 2 to 5 times more common with anti-PD1/PDL1 compared to anti-CTLA4, two explanations are proposed. This difference could be related to the strong expression of PDL1 and PDL2 in healthy thyroid tissue, making it a preferred target for cytotoxic T cells and, in addition, to the weak CTLA4 expression in circulating lymphocytes and intra-thyroid lymphocytes (Delivanis et al., 2017; Yamauchi et al., 2017). On the other hand, particular genetic backgrounds could increase the susceptibility to autoimmune toxicities related to ICPI. An HLA typing predisposing to autoimmune thyroid disorders also seems to promote the occurrence of thyroiditis under ICPI therapy (Jacobson et al., 2008; Menconi et al., 2008; Nada and Hammouda, 2014). The role of certain polymorphisms of CTLA4 and PD1 has also been mentioned, but this hypothesis is not confirmed (Han et al., 2006; Orlov et al., 2015; Tomer, 2010).

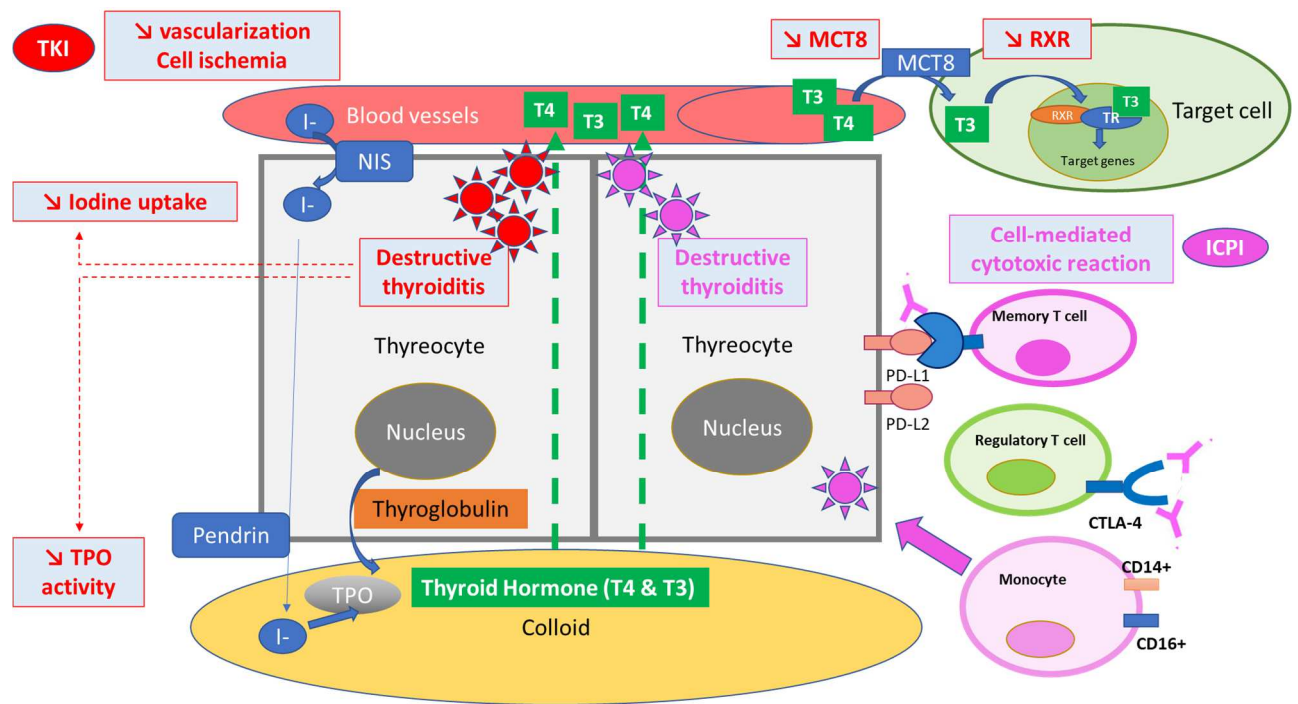


Figure 2 The pathophysiological mechanisms of dysthyroidism under TKIs and ICPI therapy.

Tyrosine Kinase Inhibitor  Immune Checkpoint Inhibitor 

CD: Cluster of differentiation, CTLA-4: Cytotoxic T Lymphocyte-Associated Antigen-4, I-: Iodine, NIS: Sodium-iodide symporter, MCT8: Monocarboxylate transporter 8, PDL1-2: Programmed death-ligand 1-2, TPO: Thyroperoxidase, RAR: Retinoic acid receptor, TR: Thyroid hormone receptor.

IV. Description of thyroid disorders

A. Clinical presentation

The clinical presentation of the thyroid disorder is varied. Two situations are encountered. Indeed, these disorders can occur in a healthy thyroid (strictly normal thyroid function and morphology) or in a patient with a preexisting known or unknown thyroid disease: nodular thyroid disease, nodular goiter, autoimmune thyroiditis with or without thyroid dysfunction. It will be necessary to discern the toxicity inherent to the anti-cancer treatment from the potential baseline thyroid condition. The classic presentation of dysthyroidism associated with TKIs or ICPIs is silent thyroiditis. This thyroiditis begins with a phase of thyrotoxicosis secondary to thyroid vesicles destruction releasing the stock of available thyroid hormones and thyroglobulin into the bloodstream. Clinical manifestations may be absent or minor and go unnoticed, or may cause palpitations, tachycardia, heat intolerance, weight loss, irritability, sleep disorders, or asthenia. Thyrotoxicosis may also be reported in hypothyroid patients prior to the initiation of ICPIs or TKIs (Villa et al., 2018). Genuine thyrotoxicosis storms have rarely been described; they are often secondary to a combination between several ICPIs (McMillen et al., 2016). In the phase of thyrotoxicosis, there is a return to euthyroidism preceded or not by a transition to hypothyroidism that is sometimes not reversible. As for conventional thyroiditis, it is considered that 50% of these patients will progress to permanent hypothyroidism secondary to the destruction of thyroid follicles. In the hypothyroid phase, patients also have few symptoms, inconsistently complaining of weight gain, chills, constipation, and fatigability or reporting these

symptoms to their neoplastic disease. The transition between the thyrotoxicosis and hypothyroidism phases seems much faster and earlier with ICPIs (shorter form of thyrotoxicosis) than with TKIs.

In patients treated with sunitinib using a discontinuous schedule, TSH increases at the end of the 4 weeks of the ON phase (treatment intake) and returns to normal at the end of the 2 weeks of the OFF phase (treatment discontinuation). After several treatment cycles, the rate of TSH increases in stages at the end of the OFF phase: the initially intermittent hypothyroidism becomes permanent (Illouz et al., 2009). Sometimes hypothyroidism is the initial mode of revelation without previous thyrotoxicosis. Hypothyroidism can sometimes be severe if diagnosed late as reported under treatment with nivolumab (Khan et al., 2017). The risk of permanent hypothyroidism seems greater under TKI therapy especially as accompanied by thyroid atrophy.

Finally, rare cases of Graves' disease without expression of anti-RTSH antibodies (TRAbs) or orbitopathies without hyperthyroidism have been described (imatinib, sorafenib, ipilimumab, tremelimumab and pembrolizumab) (Azmat et al., 2016; Borodic et al., 2011; de Filette et al., 2016; Eroukhmanoff et al., 2016; Gan et al., 2017; Konca Degertekin et al., 2012).

B. What biological and morphological assessments should be made?

The symptoms and physical signs of dysthyroidism under TKI and ICPI therapy are often discrete. Paraclinical evaluation is essential to establish the diagnosis of iatrogenic thyroiditis and eliminate a differential diagnosis by listing the patient's co-morbidities and confounding factors (nutritional status, treatments, injections of iodinated contrast agents). During the thyrotoxicosis phase, TSH is low and free T4 increased (or normal in cases of subclinical hyperthyroidism). During this phase, TRAbs are often absent - they are measured only when there is diagnostic doubt with Graves' disease. During the hypothyroid phase, TSH is high and free T4 is low (or normal in cases of subclinical hypothyroidism). The measurement of TPO-Abs will only be performed if the TSH level rises moderately, between 5 and 10 mIU/L to argue the benefit of a levothyroxine supplementation from the outset. During this phase, TPO-Abs and/or Tg-Abs are present, but generally low (25% of patients under TKI therapy and in 50 to 67% of cases under immunotherapy). They usually occur after the prescription of these anti-cancer drugs and their presence is associated with thyroid dysfunction in 80% of cases (de Filette et al., 2016; Kobayashi et al., 2018; Osorio et al., 2017). As a reminder, in the case of lowered TSH associated with a low or normal free T4 in a patient treated with immunotherapy and especially with anti-CTLA4, a complete assessment of the pituitary function is recommended to rule out hypophysitis with corticotropin deficiency (measure the cortisol levels every 8 hours and ACTH if cortisol levels are low) or combined thyrotropic deficiency.

The thyroid gland has a different ultrasound appearance in thyroiditis under TKI and ICPI therapy. Indeed, under ICPI therapy we can see first a transient hyperechoic thyroid hypertrophy and sometimes hypervascular hypertrophy, and then a hypoechoic appearance (Angell et al., 2018; Kobayashi et al., 2018). Under TKI therapy, a hypoechoic, heterogeneous appearance and decreased vascularization are initially observed by Doppler, then a progression to thyroid atrophy (this is the case for 89% of patients treated with sunitinib with hypothyroidism) (Pani et al., 2015).

In the phase of biological hyperthyroidism, in case of diagnostic doubt with Graves' disease or functional nodular dystrophy, a thyroid scintigraphy may be performed on endocrinology recommendations (checking for the absence of recent injection of iodinated contrast products which would give false negative results). This examination does not show a tracer uptake in the case of iatrogenic thyroiditis at the stage of lesion damage.

If an ¹⁸F-FDG PET/CT scan is performed for cancer monitoring, patients developing thyroiditis under immunotherapy will show an increased thyroid uptake of 18 FDG, in a diffuse manner, as described in common autoimmune thyroiditis (Hashimoto's thyroiditis, Graves' disease) (de Filette et al., 2016; Delivanis et al., 2017; Karantanis et al., 2007).

V. Therapeutic aspect (Figure 3)

No predictor of the occurrence of dysthyroidism has been clearly identified to date for TKIs and for ICPIs. Thus, in order to better detect the occurrence of thyroid dysfunction, it is essential to teach the patient to recognize the symptoms of hypothyroidism and thyrotoxicosis, to provide this case history routinely during the oncology consultations. However, given the paucisymptomatic nature of these thyroid dysfunctions and their early onset after the initiation of TKIs or ICPIs, we suggest, as recently recommended by the French Society of Endocrinology, to measure the TSH/free T4 levels before starting treatment, and every 3 to 4 weeks during the first 6 months as changes in free T4 levels precede the changes in TSH by 3 to 6 weeks (Drui et al., 2018; Illouz et al., 2018). After this period, the laboratory tests may be conducted every 2-3 months, and simplified by the TSH measurement alone.

Screening for anti-thyroid autoimmunity (TPO-Abs, Tg-Abs, TRAbs) before initiation of TKIs or ICPIs is not recommended. A history of thyroid disorder does not contraindicate initiation of TKI or ICPI therapy. In hypothyroid patients in these classes of anti-cancer drugs, adjustment of the replacement therapy may be necessary; it will be performed in connection with the patient's endocrinologist.

The occurrence of thyroid dysfunction, usually grade 1 or 2, does not contraindicate the continuation of TKI or ICPI therapy.

During the thyrotoxicosis phase, a symptomatic treatment will be initiated including low-dose non-cardioselective β -blockers such as propranolol, in the absence of contraindication, in order to control cardiothyrosis and tremors (Drui et al., 2018; Illouz et al., 2018). Severe thyrotoxicosis may justify the addition of cholestyramine treatment for its chelation effect of thyroid hormones in the enterohepatic circulation. Based on current literature data, there is no evidence to support routine use of corticosteroids except in the case of Graves' orbitopathy (Bartalena et al., 2016). Treatment with synthetic antithyroid drugs will be initiated only in cases of Graves' disease, toxic nodular goiter or solitary toxic nodules detected during this monitoring.

Given the risk of progression to hypothyroidism in the weeks following thyrotoxicosis, regular monitoring of TSH and free T4 is required. Hyperthyroidism is almost always resolving, followed or not by a hypothyroidism phase. In the hypothyroid phase, the β -blocker treatment is of course discontinued and a supportive treatment with levothyroxine may be started. This treatment will only be prescribed if the TSH is greater than 10 mIU/L or between 5 and 10 mIU/L in symptomatic patients or those with elevated TPO-Abs (Drui et al., 2018; Illouz et al., 2018). In asymptomatic patients with TSH between 5 and 10 mIU/L, a second TSH+free T4 test may be performed every 2-4 weeks in order to avoid treating transient hypothyroidism or conversely, not to overlook worsening hypothyroidism that may deserve further hormone replacement. Classically, levothyroxine may be initiated at a dose of 1 to 1.6 μ g/kg/day, except in elderly patients or patients with cardiovascular co-morbidities who will start with lower intakes (25-50 μ g/day) to be increased by levels of 12.5 μ g. A follow-up TSH test will be performed 6 weeks after the prescription of Levothyroxine.

Patients with already substituted hypothyroidism should have the TSH levels carefully monitored in order to adjust the levothyroxine doses if necessary.

VI. Conclusion

In patients treated with TKIs or ICPIs, the thyroid toxicities are common and pauci-symptomatic at the beginning of their evolution but can lead to prolonged hypothyroidism that should not be ignored. Endocrinologists and oncologists must systematize the laboratory follow-up of the thyroid based on the logistical or monitoring constraints already imposed on the patient. At least the TSH+free T4 measurement should be proposed monthly for 6 months, and then have this monitoring expanded and simplified if there is no event or following the episode of thyroiditis, after the euthyroidism is restored with or without treatment. In both cases, even if the pathophysiological mechanisms involved are singular, giving in particular a clinical expression of different chronology depending on the nature of the immune or vascular damage, the resultant is destructive thyroiditis. It is typically manifested by a thyrotoxicosis phase (by definition insensitive to synthetic antithyroid drugs) whose transient symptoms can be treated with non-cardioselective β -blockers or even with cholestyramine. Then the patient may develop hypothyroidism, which is reversible in half of the cases, to be supplemented by Levothyroxine, depending on the intensity of the signs of hypometabolism and the elevation of TSH levels. The occurrence of thyroid dysfunction does not contraindicate the continuation of TKI or ICPI therapy.

Collaboration between oncologists and endocrinologists for diagnosis, treatment and therapeutic education will be essential to good management of these thyroid side effects.

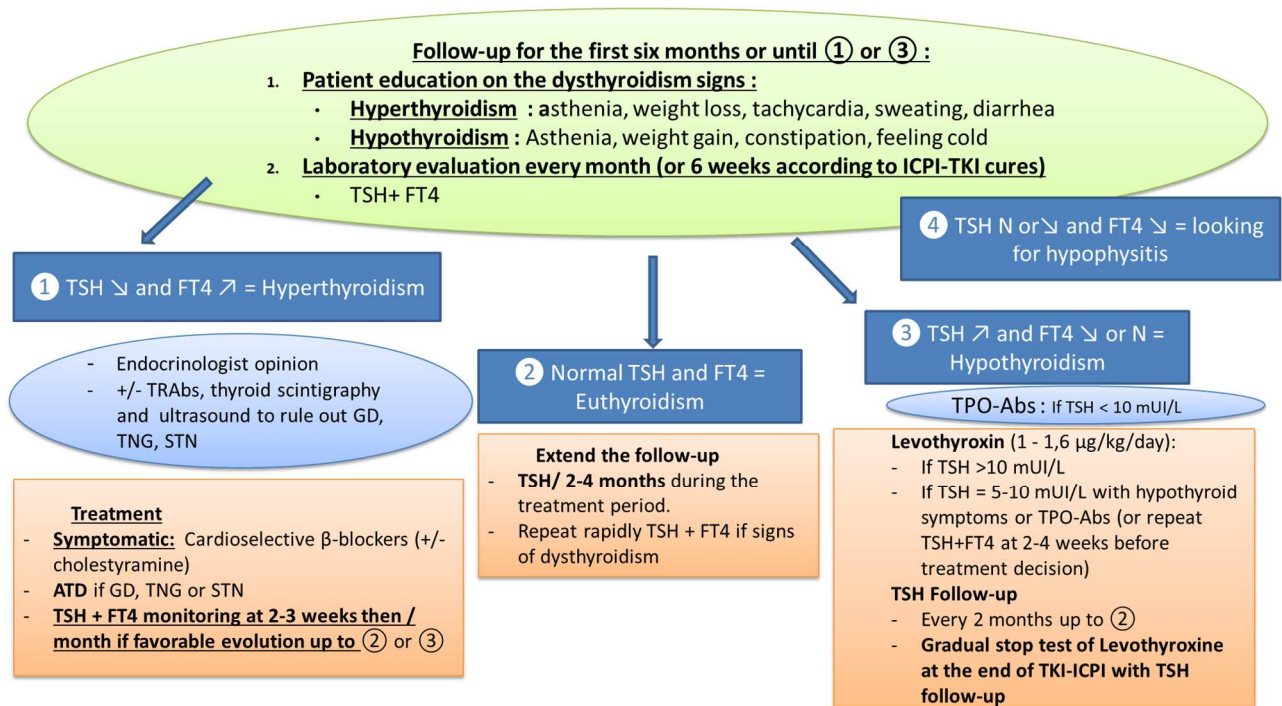


Figure 3 : Treatment of dysthyroidism.

ATD: Synthetic antithyroid drug, GD: Grave's disease, ICPI: Immune checkpoint inhibitor STN: Solitary Toxic Nodule, TKI: Tyrosine Kinase Inhibitor, TNG: Toxic Nodular Goiter, TPO-Abs: anti-thyroid peroxidase antibodies, TRAbs: anti-thyrotropin receptor antibodies, we: weeks.

References :

- Abdel-Rahman, O., Fouad, M., 2014. Risk of thyroid dysfunction in patients with solid tumors treated with VEGF receptor tyrosine kinase inhibitors: a critical literature review and meta analysis. *Expert Rev. Anticancer Ther.* 14, 1063–1073. <https://doi.org/10.1586/14737140.2014.929501>
- Abdulrahman, R.M., Verloop, H., Hoftijzer, H., Verburg, E., Hovens, G.C., Corssmit, E.P., Reiners, C., Gelderblom, H., Pereira, A.M., Kapiteijn, E., Romijn, J.A., Visser, T.J., Smit, J.W., 2010. Sorafenib-induced hypothyroidism is associated with increased type 3 deiodination. *J. Clin. Endocrinol. Metab.* 95, 3758–3762. <https://doi.org/10.1210/jc.2009-2507>
- Akaza, H., Naito, S., Ueno, N., Aoki, K., Houzawa, H., Pitman Lowenthal, S., Lee, S.-Y., 2015. Real-world use of sunitinib in Japanese patients with advanced renal cell carcinoma: efficacy, safety and biomarker analyses in 1689 consecutive patients. *Jpn. J. Clin. Oncol.* 45, 576–583. <https://doi.org/10.1093/jjco/hyv045>
- Angell, T.E., Min, L., Wieczorek, T.J., Hodi, F.S., 2018. Unique Cytologic Features of Thyroiditis Caused by Immune Checkpoint Inhibitor Therapy for Malignant Melanoma. *Genes Dis.* 5, 46–48. <https://doi.org/10.1016/j.gendis.2017.11.002>
- Antonia, S., Goldberg, S.B., Balmanoukian, A., Chaft, J.E., Sanborn, R.E., Gupta, A., Narwal, R., Steele, K., Gu, Y., Karakunnel, J.J., Rizvi, N.A., 2016. Safety and antitumour activity of durvalumab plus tremelimumab in non-small cell lung cancer: a multicentre, phase 1b study. *Lancet Oncol.* 17, 299–308. [https://doi.org/10.1016/S1470-2045\(15\)00544-6](https://doi.org/10.1016/S1470-2045(15)00544-6)
- Antonia, S.J., López-Martin, J.A., Bendell, J., Ott, P.A., Taylor, M., Eder, J.P., Jäger, D., Pietanza, M.C., Le, D.T., de Braud, F., Morse, M.A., Ascierto, P.A., Horn, L., Amin, A., Pillai, R.N., Evans, J., Chau, I., Bono, P., Atmaca, A., Sharma, P., Harbison, C.T., Lin, C.-S., Christensen, O., Calvo, E., 2016. Nivolumab alone and nivolumab plus ipilimumab in recurrent small-cell lung cancer (CheckMate 032): a multicentre, open-label, phase 1/2 trial. *Lancet Oncol.* 17, 883–895. [https://doi.org/10.1016/S1470-2045\(16\)30098-5](https://doi.org/10.1016/S1470-2045(16)30098-5)
- Arora, A., Scholar, E.M., 2005. Role of tyrosine kinase inhibitors in cancer therapy. *J. Pharmacol. Exp. Ther.* 315, 971–979. <https://doi.org/10.1124/jpet.105.084145>
- Azmat, U., Liebner, D., Joehlin-Price, A., Agrawal, A., Nabhan, F., 2016. Treatment of Ipilimumab Induced Graves' Disease in a Patient with Metastatic Melanoma. *Case Rep. Endocrinol.* 2016, 2087525. <https://doi.org/10.1155/2016/2087525>
- Balar, A.V., Galsky, M.D., Rosenberg, J.E., Powles, T., Petrylak, D.P., Bellmunt, J., Loriot, Y., Necchi, A., Hoffman-Censits, J., Perez-Gracia, J.L., Dawson, N.A., van der Heijden, M.S., Dreicer, R., Srinivas, S., Retz, M.M., Joseph, R.W., Drakaki, A., Vaishampayan, U.N., Sridhar, S.S., Quinn, D.I., Durán, I., Shaffer, D.R., Eigel, B.J., Grivas, P.D., Yu, E.Y., Li, S., Kadel, E.E., Boyd, Z., Bourgon, R., Hegde, P.S., Mariathasan, S., Thåström, A., Abidoye, O.O., Fine, G.D., Bajorin, D.F., IMvigor210 Study Group, 2017. Atezolizumab as first-line treatment in cisplatin-ineligible patients with locally advanced and metastatic urothelial carcinoma: a single-arm, multicentre, phase 2 trial. *Lancet Lond. Engl.* 389, 67–76. [https://doi.org/10.1016/S0140-6736\(16\)32455-2](https://doi.org/10.1016/S0140-6736(16)32455-2)
- Barroso-Sousa, R., Barry, W.T., Garrido-Castro, A.C., Hodi, F.S., Min, L., Krop, I.E., Tolane, S.M., 2018a. Incidence of Endocrine Dysfunction Following the Use of Different Immune Checkpoint Inhibitor Regimens: A Systematic Review and Meta-analysis. *JAMA Oncol.* 4, 173–182. <https://doi.org/10.1001/jamaoncol.2017.3064>

- Barroso-Sousa, R., Ott, P.A., Hodi, F.S., Kaiser, U.B., Tolaney, S.M., Min, L., 2018b. Endocrine dysfunction induced by immune checkpoint inhibitors: Practical recommendations for diagnosis and clinical management. *Cancer* 124, 1111–1121. <https://doi.org/10.1002/cncr.31200>
- Bartalena, L., Baldeschi, L., Boboridis, K., Eckstein, A., Kahaly, G.J., Marcocci, C., Perros, P., Salvi, M., Wiersinga, W.M., 2016. The 2016 European Thyroid Association/European Group on Graves' Orbitopathy Guidelines for the Management of Graves' Orbitopathy. *Eur. Thyroid J.* 5, 9–26. <https://doi.org/10.1159/000443828>
- BAVENCIO® (avelumab), prescribing information., 2017.
- Bellmunt, J., de Wit, R., Vaughn, D.J., Fradet, Y., Lee, J.-L., Fong, L., Vogelzang, N.J., Climent, M.A., Petrylak, D.P., Choueiri, T.K., Necchi, A., Gerritsen, W., Gurney, H., Quinn, D.I., Culine, S., Sternberg, C.N., Mai, Y., Poehlein, C.H., Perini, R.F., Bajorin, D.F., KEYNOTE-045 Investigators, 2017. Pembrolizumab as Second-Line Therapy for Advanced Urothelial Carcinoma. *N. Engl. J. Med.* 376, 1015–1026. <https://doi.org/10.1056/NEJMoa1613683>
- Beukhof, C.M., van Doorn, L., Visser, T.J., Bins, S., Visser, W.E., van Heerebeek, R., van Kemenade, F.J., de Rijke, Y.B., de Herder, W.W., Chaker, L., Mathijssen, R.H., Peeters, R.P., 2017. Sorafenib-Induced Changes in Thyroid Hormone Levels in Patients Treated for Hepatocellular Carcinoma. *J. Clin. Endocrinol. Metab.* 102, 2922–2929. <https://doi.org/10.1210/jc.2016-4025>
- Bianchi, L., Rossi, L., Tomao, F., Papa, A., Zoratto, F., Tomao, S., 2013. Thyroid dysfunction and tyrosine kinase inhibitors in renal cell carcinoma. *Endocr. Relat. Cancer* 20, R233-245. <https://doi.org/10.1530/ERC-13-0201>
- Borghaei, H., Paz-Ares, L., Horn, L., Spigel, D.R., Steins, M., Ready, N.E., Chow, L.Q., Vokes, E.E., Felip, E., Holgado, E., Barlesi, F., Kohlhäufel, M., Arrieta, O., Burgio, M.A., Fayette, J., Lena, H., Poddubskaya, E., Gerber, D.E., Gettinger, S.N., Rudin, C.M., Rizvi, N., Crinò, L., Blumenschein, G.R., Antonia, S.J., Dorange, C., Harbison, C.T., Graf Finckenstein, F., Brahmer, J.R., 2015. Nivolumab versus Docetaxel in Advanced Nonsquamous Non-Small-Cell Lung Cancer. *N. Engl. J. Med.* 373, 1627–1639. <https://doi.org/10.1056/NEJMoa1507643>
- Borodic, G., Hinkle, D.M., Cia, Y., 2011. Drug-induced graves disease from CTLA-4 receptor suppression. *Ophthalm. Plast. Reconstr. Surg.* 27, e87-88. <https://doi.org/10.1097/IOP.0b013e3181ef72a1>
- Boutros, C., Tarhini, A., Routier, E., Lambotte, O., Ladurie, F.L., Carbonnel, F., Izzeddine, H., Marabelle, A., Champiat, S., Berdelou, A., Lanoy, E., Texier, M., Libenciuc, C., Eggermont, A.M.M., Soria, J.-C., Mateus, C., Robert, C., 2016. Safety profiles of anti-CTLA-4 and anti-PD-1 antibodies alone and in combination. *Nat. Rev. Clin. Oncol.* 13, 473–486. <https://doi.org/10.1038/nrclinonc.2016.58>
- Brahmer, J., Reckamp, K.L., Baas, P., Crinò, L., Eberhardt, W.E.E., Poddubskaya, E., Antonia, S., Pluzanski, A., Vokes, E.E., Holgado, E., Waterhouse, D., Ready, N., Gainor, J., Arén Frontera, O., Havel, L., Steins, M., Garassino, M.C., Aerts, J.G., Domine, M., Paz-Ares, L., Reck, M., Baudelet, C., Harbison, C.T., Lestini, B., Spigel, D.R., 2015. Nivolumab versus Docetaxel in Advanced Squamous-Cell Non-Small-Cell Lung Cancer. *N. Engl. J. Med.* 373, 123–135. <https://doi.org/10.1056/NEJMoa1504627>
- Brahmer, J.R., Tykodi, S.S., Chow, L.Q.M., Hwu, W.-J., Topalian, S.L., Hwu, P., Drake, C.G., Camacho, L.H., Kauh, J., Odunsi, K., Pitot, H.C., Hamid, O., Bhatia, S., Martins, R., Eaton, K., Chen, S., Salay, T.M., Alaparthi, S., Grosso, J.F., Korman, A.J., Parker, S.M., Agrawal, S., Goldberg, S.M., Pardoll, D.M., Gupta, A., Wigginton, J.M., 2012. Safety and activity of anti-PD-L1 antibody in patients with advanced cancer. *N. Engl. J. Med.* 366, 2455–2465. <https://doi.org/10.1056/NEJMoa1200694>
- Braun, D., Kim, T.D., le Coutre, P., Köhrle, J., Hershman, J.M., Schweizer, U., 2012. Tyrosine kinase inhibitors noncompetitively inhibit MCT8-mediated iodothyronine transport. *J. Clin. Endocrinol. Metab.* 97, E100-105. <https://doi.org/10.1210/jc.2011-1837>

- Bruix, J., Tak, W.-Y., Gasbarrini, A., Santoro, A., Colombo, M., Lim, H.-Y., Mazzaferro, V., Wiest, R., Reig, M., Wagner, A., Bolondi, L., 2013. Regorafenib as second-line therapy for intermediate or advanced hepatocellular carcinoma: multicentre, open-label, phase II safety study. *Eur. J. Cancer Oxf. Engl.* 1990 49, 3412–3419. <https://doi.org/10.1016/j.ejca.2013.05.028>
- Cao, Y., 2014. VEGF-targeted cancer therapeutics-paradoxical effects in endocrine organs. *Nat. Rev. Endocrinol.* 10, 530–539. <https://doi.org/10.1038/nrendo.2014.114>
- Choueiri, T.K., Escudier, B., Powles, T., Mainwaring, P.N., Rini, B.I., Donskov, F., Hammers, H., Hutson, T.E., Lee, J.-L., Peltola, K., Roth, B.J., Bjarnason, G.A., Géczi, L., Keam, B., Maroto, P., Heng, D.Y.C., Schmidinger, M., Kantoff, P.W., Borgman-Hagey, A., Hessel, C., Scheffold, C., Schwab, G.M., Tannir, N.M., Motzer, R.J., METEOR Investigators, 2015. Cabozantinib versus Everolimus in Advanced Renal-Cell Carcinoma. *N. Engl. J. Med.* 373, 1814–1823. <https://doi.org/10.1056/NEJMoa1510016>
- Choueiri, T.K., Hessel, C., Halabi, S., Sanford, B., Michaelson, M.D., Hahn, O., Walsh, M., Olencki, T., Picus, J., Small, E.J., Dakhil, S., Feldman, D.R., Mangeshkar, M., Scheffold, C., George, D., Morris, M.J., 2018. Cabozantinib versus sunitinib as initial therapy for metastatic renal cell carcinoma of intermediate or poor risk (Alliance A031203 CABOSUN randomised trial): Progression-free survival by independent review and overall survival update. *Eur. J. Cancer Oxf. Engl.* 1990 94, 115–125. <https://doi.org/10.1016/j.ejca.2018.02.012>
- Clement P, Stefan C, Decallonne P, et al., 2008. Thyroid dysfunction in patients (pts) with metastatic renal cell cancer (RCC) treated with sorafenib [abstract 16145]. American Society of Clinical Oncology 44th Annual Meeting (ASCO); 30 May-- 3 June 2008;Chicago, USA.
- Coelho, R.C., Reinert, T., Campos, F., Peixoto, F.A., de Andrade, C.A., Castro, T., Herchenhorn, D., 2016. Sunitinib treatment in patients with advanced renal cell cancer: the Brazilian National Cancer Institute (INCA) experience. *Int. Braz J Urol Off. J. Braz. Soc. Urol.* 42, 694–703.
- Daimon, M., Kato, Tomoyuki, Kaino, W., Takase, K., Karasawa, S., Wada, K., Kameda, W., Susa, S., Oizumi, T., Tomita, Y., Kato, Takeo, 2012. Thyroid dysfunction in patients treated with tyrosine kinase inhibitors, sunitinib, sorafenib and axitinib, for metastatic renal cell carcinoma. *Jpn. J. Clin. Oncol.* 42, 742–747. <https://doi.org/10.1093/jjco/hys076>
- Davies, A.M., Sutton, B.J., 2015. Human IgG4: a structural perspective. *Immunol. Rev.* 268, 139–159. <https://doi.org/10.1111/imr.12349>
- de Filette, J., Jansen, Y., Schreuer, M., Everaert, H., Velkeniers, B., Neyns, B., Bravenboer, B., 2016. Incidence of Thyroid-Related Adverse Events in Melanoma Patients Treated With Pembrolizumab. *J. Clin. Endocrinol. Metab.* 101, 4431–4439. <https://doi.org/10.1210/jc.2016-2300>
- de Groot, J.W.B., Zonnenberg, B.A., Plukker, J.T.M., van Der Graaf, W.T.A., Links, T.P., 2005. Imatinib induces hypothyroidism in patients receiving levothyroxine. *Clin. Pharmacol. Ther.* 78, 433–438. <https://doi.org/10.1016/j.clpt.2005.06.010>
- de Groot, J.W.B., Zonnenberg, B.A., van Ufford-Mannesse, P.Q., de Vries, M.M., Links, T.P., Lips, C.J.M., Voest, E.E., 2007. A phase II trial of imatinib therapy for metastatic medullary thyroid carcinoma. *J. Clin. Endocrinol. Metab.* 92, 3466–3469. <https://doi.org/10.1210/jc.2007-0649>
- Delivanis, D.A., Gustafson, M.P., Bornschlegl, S., Merten, M.M., Kottschade, L., Withers, S., Dietz, A.B., Ryder, M., 2017. Pembrolizumab-Induced Thyroiditis: Comprehensive Clinical Review and Insights Into Underlying Involved Mechanisms. *J. Clin. Endocrinol. Metab.* 102, 2770–2780. <https://doi.org/10.1210/jc.2017-00448>
- Desai, J., Yassa, L., Marqusee, E., George, S., Frates, M.C., Chen, M.H., Morgan, J.A., Dychter, S.S., Larsen, P.R., Demetri, G.D., Alexander, E.K., 2006. Hypothyroidism after sunitinib treatment for patients with gastrointestinal stromal tumors. *Ann. Intern. Med.* 145, 660–664.
- DiMasi, J.A., Grabowski, H.G., 2007. Economics of new oncology drug development. *J. Clin. Oncol. Off. J. Am. Soc. Clin. Oncol.* 25, 209–216. <https://doi.org/10.1200/JCO.2006.09.0803>
- Drui, D., Illouz, F., Do Cao, C., Caron, P., 2018. Expert opinion on thyroid complications of new anti-cancer therapies: Tyrosine kinase inhibitors. *Ann. Endocrinol.* <https://doi.org/10.1016/j.ando.2018.07.003>

- Eggermont, A.M.M., Chiarion-Sileni, V., Grob, J.-J., Dummer, R., Wolchok, J.D., Schmidt, H., Hamid, O., Robert, C., Ascierto, P.A., Richards, J.M., Lebbé, C., Ferraresi, V., Smylie, M., Weber, J.S., Maio, M., Bastholt, L., Mortier, L., Thomas, L., Tahir, S., Hauschild, A., Hassel, J.C., Hodi, F.S., Taitt, C., de Pril, V., de Schaetzen, G., Suci, S., Testori, A., 2016. Prolonged Survival in Stage III Melanoma with Ipilimumab Adjuvant Therapy. *N. Engl. J. Med.* 375, 1845–1855. <https://doi.org/10.1056/NEJMoa1611299>
- Eroukhmanoff, J., Castinetti, F., Penel, N., Salas, S., 2016. Auto-immune thyroid dysfunction induced by tyrosine kinase inhibitors in a patient with recurrent chordoma. *BMC Cancer* 16. <https://doi.org/10.1186/s12885-016-2705-3>
- Evaluation of thyroid dysfunction as a candidate surrogate marker for efficacy of sunitinib in patients (pts) with advanced renal cell cancer (RCC): *Journal of Clinical Oncology: Vol 26, No 15_suppl [WWW Document]*, n.d. URL http://ascopubs.org/doi/abs/10.1200/jco.2008.26.15_suppl.5126 (accessed 5.11.18).
- Fallahi, P., Ferrari, S.M., Vita, R., Di Domenicantonio, A., Corrado, A., Benvenega, S., Antonelli, A., 2014. Thyroid dysfunctions induced by tyrosine kinase inhibitors. *Expert Opin. Drug Saf.* 13, 723–733. <https://doi.org/10.1517/14740338.2014.913021>
- Fehrenbacher, L., Spira, A., Ballinger, M., Kowanzet, M., Vansteenkiste, J., Mazieres, J., Park, K., Smith, D., Artal-Cortes, A., Lewanski, C., Braiteh, F., Waterkamp, D., He, P., Zou, W., Chen, D.S., Yi, J., Sandler, A., Rittmeyer, A., POPLAR Study Group, 2016. Atezolizumab versus docetaxel for patients with previously treated non-small-cell lung cancer (POPLAR): a multicentre, open-label, phase 2 randomised controlled trial. *Lancet Lond. Engl.* 387, 1837–1846. [https://doi.org/10.1016/S0140-6736\(16\)00587-0](https://doi.org/10.1016/S0140-6736(16)00587-0)
- Ferris, R.L., Blumenschein, G., Fayette, J., Guigay, J., Colevas, A.D., Licitra, L., Harrington, K., Kasper, S., Vokes, E.E., Even, C., Worden, F., Saba, N.F., Iglesias Docampo, L.C., Haddad, R., Rordorf, T., Kiyota, N., Tahara, M., Monga, M., Lynch, M., Geese, W.J., Kopit, J., Shaw, J.W., Gillison, M.L., 2016. Nivolumab for Recurrent Squamous-Cell Carcinoma of the Head and Neck. *N. Engl. J. Med.* 375, 1856–1867. <https://doi.org/10.1056/NEJMoa1602252>
- Funakoshi, T., Shimada, Y.J., 2013. Risk of hypothyroidism in patients with cancer treated with sunitinib: a systematic review and meta-analysis. *Acta Oncol. Stockh. Swed.* 52, 691–702. <https://doi.org/10.3109/0284186X.2012.752579>
- Gan, E.H., Mitchell, A.L., Plummer, R., Pearce, S., Perros, P., 2017. Tremelimumab-Induced Graves Hyperthyroidism. *Eur. Thyroid J.* 6, 167–170. <https://doi.org/10.1159/000464285>
- Garon, E.B., Rizvi, N.A., Hui, R., Leighl, N., Balmanoukian, A.S., Eder, J.P., Patnaik, A., Aggarwal, C., Gubens, M., Horn, L., Carcereny, E., Ahn, M.-J., Felip, E., Lee, J.-S., Hellmann, M.D., Hamid, O., Goldman, J.W., Soria, J.-C., Dolled-Filhart, M., Rutledge, R.Z., Zhang, J., Luceford, J.K., Rangwala, R., Lubiniecki, G.M., Roach, C., Emancipator, K., Gandhi, L., KEYNOTE-001 Investigators, 2015. Pembrolizumab for the treatment of non-small-cell lung cancer. *N. Engl. J. Med.* 372, 2018–2028. <https://doi.org/10.1056/NEJMoa1501824>
- Gharwan, H., Groninger, H., 2016. Kinase inhibitors and monoclonal antibodies in oncology: clinical implications. *Nat. Rev. Clin. Oncol.* 13, 209–227. <https://doi.org/10.1038/nrclinonc.2015.213>
- Gore, M.E., Szczylik, C., Porta, C., Bracarda, S., Bjarnason, G.A., Oudard, S., Hariharan, S., Lee, S.-H., Haanen, J., Castellano, D., Vrdoljak, E., Schöffski, P., Mainwaring, P., Nieto, A., Yuan, J., Bukowski, R., 2009. Safety and efficacy of sunitinib for metastatic renal-cell carcinoma: an expanded-access trial. *Lancet Oncol.* 10, 757–763. [https://doi.org/10.1016/S1470-2045\(09\)70162-7](https://doi.org/10.1016/S1470-2045(09)70162-7)
- Gulley, J.L., Rajan, A., Spigel, D.R., Iannotti, N., Chandler, J., Wong, D.J.L., Leach, J., Edenfield, W.J., Wang, D., Grote, H.J., Heydebreck, A. von, Chin, K., Cuillerot, J.-M., Kelly, K., 2017. Avelumab for patients with previously treated metastatic or recurrent non-small-cell lung cancer (JAVELIN Solid Tumor): dose-expansion cohort of a multicentre, open-label, phase 1b trial. *Lancet Oncol.* 18, 599–610. [https://doi.org/10.1016/S1470-2045\(17\)30240-1](https://doi.org/10.1016/S1470-2045(17)30240-1)

- Han, S., Zhang, S., Zhang, W., Li, R., Li, Y., Wang, Z., Xie, Y., Mao, Y., 2006. CTLA4 Polymorphisms and Ophthalmopathy in Graves' Disease Patients: Association Study and Meta-Analysis. *Hum. Immunol.* 67, 618–626. <https://doi.org/10.1016/j.humimm.2006.05.003>
- Hodi, F.S., Chesney, J., Pavlick, A.C., Robert, C., Grossmann, K.F., McDermott, D.F., Linette, G.P., Meyer, N., Giguere, J.K., Agarwala, S.S., Shaheen, M., Ernstoff, M.S., Minor, D.R., Salama, A.K., Taylor, M.H., Ott, P.A., Horak, C., Gagnier, P., Jiang, J., Wolchok, J.D., Postow, M.A., 2016. Combined nivolumab and ipilimumab versus ipilimumab alone in patients with advanced melanoma: 2-year overall survival outcomes in a multicentre, randomised, controlled, phase 2 trial. *Lancet Oncol.* 17, 1558–1568. [https://doi.org/10.1016/S1470-2045\(16\)30366-7](https://doi.org/10.1016/S1470-2045(16)30366-7)
- Huber, G., Staub, J.-J., Meier, C., Mitrache, C., Guglielmetti, M., Huber, P., Braverman, L.E., 2002. Prospective study of the spontaneous course of subclinical hypothyroidism: prognostic value of thyrotropin, thyroid reserve, and thyroid antibodies. *J. Clin. Endocrinol. Metab.* 87, 3221–3226. <https://doi.org/10.1210/jcem.87.7.8678>
- Hutson, T.E., Lesovoy, V., Al-Shukri, S., Stus, V.P., Lipatov, O.N., Bair, A.H., Rosbrook, B., Chen, C., Kim, S., Vogelzang, N.J., 2013. Axitinib versus sorafenib as first-line therapy in patients with metastatic renal-cell carcinoma: a randomised open-label phase 3 trial. *Lancet Oncol.* 14, 1287–1294. [https://doi.org/10.1016/S1470-2045\(13\)70465-0](https://doi.org/10.1016/S1470-2045(13)70465-0)
- Ikeda, K., Kudo, M., Kawazoe, S., Osaki, Y., Ikeda, M., Okusaka, T., Tamai, T., Suzuki, T., Hisai, T., Hayato, S., Okita, K., Kumada, H., 2017. Phase 2 study of lenvatinib in patients with advanced hepatocellular carcinoma. *J. Gastroenterol.* 52, 512–519. <https://doi.org/10.1007/s00535-016-1263-4>
- Illouz, F., Drui, D., Caron, P., Do Cao, C., 2018. Expert opinion on thyroid complications in immunotherapy. *Ann. Endocrinol.* <https://doi.org/10.1016/j.ando.2018.07.007>
- Illouz, F., Laboureaux-Soares, S., Dubois, S., Rohmer, V., Rodien, P., 2009. Tyrosine kinase inhibitors and modifications of thyroid function tests: a review. *Eur. J. Endocrinol.* 160, 331–336. <https://doi.org/10.1530/EJE-08-0648>
- IMFINZI™ (durvalumab), prescribing information, 2017.
- Iwatani, Y., Amino, N., Tamaki, H., Aozasa, M., Kabutomori, O., Mori, M., Tanizawa, O., Miyai, K., 1988. Increase in peripheral large granular lymphocytes in postpartum autoimmune thyroiditis. *Endocrinol. Jpn.* 35, 447–453.
- Jaafar, J., Fernandez, E., Alwan, H., Philippe, J., 2018. Programmed cell death-1 and programmed cell death ligand-1 antibodies-induced dysthyroidism. *Endocr. Connect.* 7, R196–R211. <https://doi.org/10.1530/EC-18-0079>
- Jacobson, E.M., Huber, A., Tomer, Y., 2008. THE HLA GENE COMPLEX IN THYROID AUTOIMMUNITY: FROM EPIDEMIOLOGY TO ETIOLOGY. *J. Autoimmun.* 30, 58–62. <https://doi.org/10.1016/j.jaut.2007.11.010>
- Jang, J.Y., Choi, S.Y., Park, I., Park, D.Y., Choe, K., Kim, P., Kim, Y.K., Lee, B.-J., Hirashima, M., Kubota, Y., Park, J.-W., Cheng, S.-Y., Nagy, A., Park, Y.J., Alitalo, K., Shong, M., Koh, G.Y., 2017. VEGFR2 but not VEGFR3 governs integrity and remodeling of thyroid angiofollicular unit in normal state and during goitrogenesis. *EMBO Mol. Med.* 9, 750–769. <https://doi.org/10.15252/emmm.201607341>
- Kamba, T., Tam, B.Y.Y., Hashizume, H., Haskell, A., Sennino, B., Mancuso, M.R., Norberg, S.M., O'Brien, S.M., Davis, R.B., Gowen, L.C., Anderson, K.D., Thurston, G., Joho, S., Springer, M.L., Kuo, C.J., McDonald, D.M., 2006. VEGF-dependent plasticity of fenestrated capillaries in the normal adult microvasculature. *Am. J. Physiol. Heart Circ. Physiol.* 290, H560-576. <https://doi.org/10.1152/ajpheart.00133.2005>
- Kappers, M.H.W., van Esch, J.H.M., Smedts, F.M.M., de Krijger, R.R., Eechoute, K., Mathijssen, R.H.J., Sleijfer, S., Leijten, F., Danser, A.H.J., van den Meiracker, A.H., Visser, T.J., 2011. Sunitinib-induced hypothyroidism is due to induction of type 3 deiodinase activity and thyroidal capillary regression. *J. Clin. Endocrinol. Metab.* 96, 3087–3094. <https://doi.org/10.1210/jc.2011-1172>

- Karam, J.A., Devine, C.E., Urbauer, D.L., Lozano, M., Maity, T., Ahrar, K., Tamboli, P., Tannir, N.M., Wood, C.G., 2014. Phase II Trial Of Neoadjuvant Axitinib In Patients With Locally Advanced Non-Metastatic Clear Cell Renal Cell Carcinoma. *Eur. Urol.* 66, 874–880. <https://doi.org/10.1016/j.eururo.2014.01.035>
- Karantanis, D., Bogsrud, T.V., Wiseman, G.A., Mullan, B.P., Subramaniam, R.M., Nathan, M.A., Peller, P.J., Bahn, R.S., Lowe, V.J., 2007. Clinical significance of diffusely increased 18F-FDG uptake in the thyroid gland. *J. Nucl. Med. Off. Publ. Soc. Nucl. Med.* 48, 896–901. <https://doi.org/10.2967/jnumed.106.039024>
- Khan, U., Rizvi, H., Sano, D., Chiu, J., Hadid, T., 2017. Nivolumab induced myxedema crisis. *J. Immunother. Cancer* 5, 13. <https://doi.org/10.1186/s40425-017-0213-x>
- Kim, T.D., Schwarz, M., Nogai, H., Grille, P., Westermann, J., Plöckinger, U., Braun, D., Schweizer, U., Arnold, R., Dörken, B., le Coutre, P., 2010. Thyroid dysfunction caused by second-generation tyrosine kinase inhibitors in Philadelphia chromosome-positive chronic myeloid leukemia. *Thyroid Off. J. Am. Thyroid Assoc.* 20, 1209–1214. <https://doi.org/10.1089/thy.2010.0251>
- Kitajima, K., Takahashi, S., Maeda, T., Yoshikawa, T., Ohno, Y., Fujii, M., Miyake, H., Fujisawa, M., Sugimura, K., 2012. Thyroid size change by CT monitoring after sorafenib or sunitinib treatment in patients with renal cell carcinoma: comparison with thyroid function. *Eur. J. Radiol.* 81, 2060–2065. <https://doi.org/10.1016/j.ejrad.2011.06.035>
- Kobayashi, T., Iwama, S., Yasuda, Y., Okada, N., Tsunekawa, T., Onoue, T., Takagi, H., Hagiwara, D., Ito, Y., Morishita, Y., Goto, M., Suga, H., Banno, R., Yokota, K., Hase, T., Morise, M., Hashimoto, N., Ando, M., Kiyoi, H., Gotoh, M., Ando, Y., Akiyama, M., Hasegawa, Y., Arima, H., 2018. Patients With Antithyroid Antibodies Are Prone To Develop Destructive Thyroiditis by Nivolumab: A Prospective Study. *J. Endocr. Soc.* 2, 241–251. <https://doi.org/10.1210/js.2017-00432>
- Konca Degertekin, C., Coşkun, U., Baloş Törüner, F., Aktürk, M., Demirci, U., 2012. Hyperthyroidism and thyroid autoimmunity induced by sorafenib in metastatic renal cell cancer. *Endocrine* 42, 756–757. <https://doi.org/10.1007/s12020-012-9683-2>
- Koyama, S., Miyake, N., Fujiwara, K., Morisaki, T., Fukuhara, T., Kitano, H., Takeuchi, H., 2018. Lenvatinib for Anaplastic Thyroid Cancer and Lenvatinib-Induced Thyroid Dysfunction. *Eur. Thyroid J.* 7, 139–144. <https://doi.org/10.1159/000485972>
- Krause, D.S., Van Etten, R.A., 2005. Tyrosine kinases as targets for cancer therapy. *N. Engl. J. Med.* 353, 172–187. <https://doi.org/10.1056/NEJMra044389>
- Kudo, M., Finn, R.S., Qin, S., Han, K.-H., Ikeda, K., Piscaglia, F., Baron, A., Park, J.-W., Han, G., Jassem, J., Blanc, J.F., Vogel, A., Komov, D., Evans, T.R.J., Lopez, C., Dutcus, C., Guo, M., Saito, K., Kraljevic, S., Tamai, T., Ren, M., Cheng, A.-L., 2018. Lenvatinib versus sorafenib in first-line treatment of patients with unresectable hepatocellular carcinoma: a randomised phase 3 non-inferiority trial. *Lancet Lond. Engl.* 391, 1163–1173. [https://doi.org/10.1016/S0140-6736\(18\)30207-1](https://doi.org/10.1016/S0140-6736(18)30207-1)
- Larkin, J., Chiarion-Sileni, V., Gonzalez, R., Grob, J.J., Cowey, C.L., Lao, C.D., Schadendorf, D., Dummer, R., Smylie, M., Rutkowski, P., Ferrucci, P.F., Hill, A., Wagstaff, J., Carlino, M.S., Haanen, J.B., Maio, M., Marquez-Rodas, I., McArthur, G.A., Ascierto, P.A., Long, G.V., Callahan, M.K., Postow, M.A., Grossmann, K., Sznol, M., Dreno, B., Bastholt, L., Yang, A., Rollin, L.M., Horak, C., Hodi, F.S., Wolchok, J.D., 2015. Combined Nivolumab and Ipilimumab or Monotherapy in Untreated Melanoma. *N. Engl. J. Med.* 373, 23–34. <https://doi.org/10.1056/NEJMoa1504030>
- Lechner, M.G., Vyas, C.M., Hamnvik, O.-P.R., Alexander, E.K., Larsen, P.R., Choueiri, T.K., Angell, T.E., 2018. Risk Factors for New Hypothyroidism During Tyrosine Kinase Inhibitor Therapy in Advanced Nonthyroidal Cancer Patients. *Thyroid* 28, 437–444. <https://doi.org/10.1089/thy.2017.0579>
- Liwanpo, L., Ro, C., Haq, S., Hershman, J.M., 2014. Sunitinib does not block thyroid peroxidase in patients. *Thyroid Off. J. Am. Thyroid Assoc.* 24, 1325–1326. <https://doi.org/10.1089/thy.2014.0006>

- Lodish, M., Gkourogianni, A., Bornstein, E., Sinaii, N., Fox, E., Chuk, M., Marcus, L., Akshintala, S., Balis, F., Widemann, B., Stratakis, C.A., 2015. Patterns of thyroid hormone levels in pediatric medullary thyroid carcinoma patients on vandetanib therapy. *Int. J. Pediatr. Endocrinol.* 2015, 3. <https://doi.org/10.1186/1687-9856-2015-3>
- Makita, N., Iiri, T., 2013. Tyrosine kinase inhibitor-induced thyroid disorders: a review and hypothesis. *Thyroid Off. J. Am. Thyroid Assoc.* 23, 151–159. <https://doi.org/10.1089/thy.2012.0456>
- Makita, N., Miyakawa, M., Fujita, T., Iiri, T., 2010. Sunitinib induces hypothyroidism with a markedly reduced vascularity. *Thyroid Off. J. Am. Thyroid Assoc.* 20, 323–326. <https://doi.org/10.1089/thy.2009.0414>
- Mannavola, D., Coco, P., Vannucchi, G., Bertuelli, R., Carletto, M., Casali, P.G., Beck-Peccoz, P., Fugazzola, L., 2007. A novel tyrosine-kinase selective inhibitor, sunitinib, induces transient hypothyroidism by blocking iodine uptake. *J. Clin. Endocrinol. Metab.* 92, 3531–3534. <https://doi.org/10.1210/jc.2007-0586>
- Matrana, M.R., Duran, C., Shetty, A., Xiao, L., Atkinson, B.J., Corn, P., Pagliaro, L.C., Millikan, R.E., Charnsangave, C., Jonasch, E., Tannir, N.M., 2013. Outcomes of patients with metastatic clear-cell renal cell carcinoma treated with pazopanib after disease progression with other targeted therapies. *Eur. J. Cancer Oxf. Engl.* 1990 49, 3169–3175. <https://doi.org/10.1016/j.ejca.2013.06.003>
- McDermott, D., Haanen, J., Chen, T.-T., Lorigan, P., O’Day, S., MDX010-20 Investigators, 2013. Efficacy and safety of ipilimumab in metastatic melanoma patients surviving more than 2 years following treatment in a phase III trial (MDX010-20). *Ann. Oncol. Off. J. Eur. Soc. Med. Oncol.* 24, 2694–2698. <https://doi.org/10.1093/annonc/mdt291>
- McMillen, B., Dhillon, M.S., Yong-Yow, S., 2016. A rare case of thyroid storm. *BMJ Case Rep.* 2016, 10.1136/bcr-2016–214603. <https://doi.org/10.1136/bcr-2016-214603>
- Meeting Library | Correlation between dysthyroidism and efficacy in patients treated with anti PD-1 or anti PDL-1 agents. [WWW Document], n.d. URL <https://meetinglibrary.asco.org/record/140833/abstract> (accessed 5.11.18).
- Menconi, F., Monti, M.C., Greenberg, D.A., Oashi, T., Osman, R., Davies, T.F., Ban, Y., Jacobson, E.M., Concepcion, E.S., Li, C.W., Tomer, Y., 2008. Molecular amino acid signatures in the MHC class II peptide-binding pocket predispose to autoimmune thyroiditis in humans and in mice. *Proc. Natl. Acad. Sci. U. S. A.* 105, 14034–14039. <https://doi.org/10.1073/pnas.0806584105>
- Miyake, H., Kurahashi, T., Yamanaka, K., Kondo, Y., Muramaki, M., Takenaka, A., Inoue, T.-A., Fujisawa, M., 2010. Abnormalities of thyroid function in Japanese patients with metastatic renal cell carcinoma treated with sorafenib: a prospective evaluation. *Urol. Oncol.* 28, 515–519. <https://doi.org/10.1016/j.urolonc.2009.08.011>
- Morganstein, D.L., Lai, Z., Spain, L., Diem, S., Levine, D., Mace, C., Gore, M., Larkin, J., 2017. Thyroid abnormalities following the use of cytotoxic T-lymphocyte antigen-4 and programmed death receptor protein-1 inhibitors in the treatment of melanoma. *Clin. Endocrinol. (Oxf.)* 86, 614–620. <https://doi.org/10.1111/cen.13297>
- Motzer, R.J., Escudier, B., Tomczak, P., Hutson, T.E., Michaelson, M.D., Negrier, S., Oudard, S., Gore, M.E., Tarazi, J., Hariharan, S., Chen, C., Rosbrook, B., Kim, S., Rini, B.I., 2013a. Axitinib versus sorafenib as second-line treatment for advanced renal cell carcinoma: overall survival analysis and updated results from a randomised phase 3 trial. *Lancet Oncol.* 14, 552–562. [https://doi.org/10.1016/S1470-2045\(13\)70093-7](https://doi.org/10.1016/S1470-2045(13)70093-7)
- Motzer, R.J., Hutson, T.E., Cella, D., Reeves, J., Hawkins, R., Guo, J., Nathan, P., Staehler, M., de Souza, P., Merchan, J.R., Boleti, E., Fife, K., Jin, J., Jones, R., Uemura, H., De Giorgi, U., Harmenberg, U., Wang, J., Sternberg, C.N., Deen, K., McCann, L., Hackshaw, M.D., Crescenzo, R., Pandite, L.N., Choueiri, T.K., 2013b. Pazopanib versus sunitinib in metastatic renal-cell carcinoma. *N. Engl. J. Med.* 369, 722–731. <https://doi.org/10.1056/NEJMoa1303989>
- Motzer, R.J., Hutson, T.E., Glen, H., Michaelson, M.D., Molina, A., Eisen, T., Jassem, J., Zolnierak, J., Maroto, J.P., Mellado, B., Melichar, B., Tomasek, J., Kremer, A., Kim, H.-J., Wood, K., Dutcus, C., Larkin, J., 2015. Lenvatinib, everolimus, and the combination in patients with metastatic

- renal cell carcinoma: a randomised, phase 2, open-label, multicentre trial. *Lancet Oncol.* 16, 1473–1482. [https://doi.org/10.1016/S1470-2045\(15\)00290-9](https://doi.org/10.1016/S1470-2045(15)00290-9)
- Motzer, R.J., Hutson, T.E., Olsen, M.R., Hudes, G.R., Burke, J.M., Edenfield, W.J., Wilding, G., Agarwal, N., Thompson, J.A., Cella, D., Bello, A., Korytowsky, B., Yuan, J., Valota, O., Martell, B., Hariharan, S., Figlin, R.A., 2012. Randomized phase II trial of sunitinib on an intermittent versus continuous dosing schedule as first-line therapy for advanced renal cell carcinoma. *J. Clin. Oncol. Off. J. Am. Soc. Clin. Oncol.* 30, 1371–1377. <https://doi.org/10.1200/JCO.2011.36.4133>
- Mukohara, T., Nakajima, H., Mukai, H., Nagai, S., Itoh, K., Umeyama, Y., Hashimoto, J., Minami, H., 2010. Effect of axitinib (AG-013736) on fatigue, thyroid-stimulating hormone, and biomarkers: a phase I study in Japanese patients. *Cancer Sci.* 101, 963–968. <https://doi.org/10.1111/j.1349-7006.2009.01465.x>
- Nada, A.M., Hammouda, M., 2014. Immunoregulatory T cells, LFA-3 and HLA-DR in autoimmune thyroid diseases. *Indian J. Endocrinol. Metab.* 18, 574–581. <https://doi.org/10.4103/2230-8210.137524>
- Ohba, K., Takayama, T., Matsunaga, H., Matsushita, A., Sasaki, S., Oki, Y., Ozono, S., Nakamura, H., 2013. Inappropriate elevation of serum thyrotropin levels in patients treated with axitinib. *Thyroid Off. J. Am. Thyroid Assoc.* 23, 443–448. <https://doi.org/10.1089/thy.2012.0378>
- Orlov, S., Salari, F., Kashat, L., Walfish, P.G., 2015. Induction of painless thyroiditis in patients receiving programmed death 1 receptor immunotherapy for metastatic malignancies. *J. Clin. Endocrinol. Metab.* 100, 1738–1741. <https://doi.org/10.1210/jc.2014-4560>
- Osorio, J.C., Ni, A., Chaft, J.E., Pollina, R., Kasler, M.K., Stephens, D., Rodriguez, C., Cambridge, L., Rizvi, H., Wolchok, J.D., Merghoub, T., Rudin, C.M., Fish, S., Hellmann, M.D., 2017. Antibody-mediated thyroid dysfunction during T-cell checkpoint blockade in patients with non-small-cell lung cancer. *Ann. Oncol. Off. J. Eur. Soc. Med. Oncol.* 28, 583–589. <https://doi.org/10.1093/annonc/mdw640>
- Ozao-Choy, J., Ma, G., Kao, J., Wang, G.X., Meseck, M., Sung, M., Schwartz, M., Divino, C.M., Pan, P.-Y., Chen, S.-H., 2009. The novel role of tyrosine kinase inhibitor in the reversal of immune suppression and modulation of tumor microenvironment for immune-based cancer therapies. *Cancer Res.* 69, 2514–2522. <https://doi.org/10.1158/0008-5472.CAN-08-4709>
- Pani, F., Atzori, F., Baghino, G., Boi, F., Tanca, L., Ionta, M.T., Mariotti, S., 2015. Thyroid Dysfunction in Patients with Metastatic Carcinoma Treated with Sunitinib: Is Thyroid Autoimmunity Involved? *Thyroid Off. J. Am. Thyroid Assoc.* 25, 1255–1261. <https://doi.org/10.1089/thy.2015.0170>
- Pani, F., Massidda, M., Pusceddu, V., Puzzone, M., Massa, E., Madeddu, C., Scartozzi, M., Mariotti, S., 2017. Regorafenib-induced hypothyroidism and cancer-related fatigue: is there a potential link? *Eur. J. Endocrinol.* 177, 85–92. <https://doi.org/10.1530/EJE-17-0231>
- Peters, S., Gettinger, S., Johnson, M.L., Jänne, P.A., Garassino, M.C., Christoph, D., Toh, C.K., Rizvi, N.A., Chaft, J.E., Carcereny Costa, E., Patel, J.D., Chow, L.Q.M., Koczywas, M., Ho, C., Früh, M., van den Heuvel, M., Rothenstein, J., Reck, M., Paz-Ares, L., Shepherd, F.A., Kurata, T., Li, Z., Qiu, J., Kowanetz, M., Mocchi, S., Shankar, G., Sandler, A., Felip, E., 2017. Phase II Trial of Atezolizumab As First-Line or Subsequent Therapy for Patients With Programmed Death-Ligand 1-Selected Advanced Non-Small-Cell Lung Cancer (BIRCH). *J. Clin. Oncol. Off. J. Am. Soc. Clin. Oncol.* 35, 2781–2789. <https://doi.org/10.1200/JCO.2016.71.9476>
- Porta, C., Gore, M.E., Rini, B.I., Escudier, B., Hariharan, S., Charles, L.P., Yang, L., DeAnnuntis, L., Motzer, R.J., 2016. Long-term Safety of Sunitinib in Metastatic Renal Cell Carcinoma. *Eur. Urol.* 69, 345–351. <https://doi.org/10.1016/j.eururo.2015.07.006>
- Postow, M.A., Chesney, J., Pavlick, A.C., Robert, C., Grossmann, K., McDermott, D., Linette, G.P., Meyer, N., Giguere, J.K., Agarwala, S.S., Shaheen, M., Ernstoff, M.S., Minor, D., Salama, A.K., Taylor, M., Ott, P.A., Rollin, L.M., Horak, C., Gagnier, P., Wolchok, J.D., Hodi, F.S., 2015. Nivolumab and ipilimumab versus ipilimumab in untreated melanoma. *N. Engl. J. Med.* 372, 2006–2017. <https://doi.org/10.1056/NEJMoa1414428>

- Powles, T., O'Donnell, P.H., Massard, C., Arkenau, H.-T., Friedlander, T.W., Hoimes, C.J., Lee, J.L., Ong, M., Sridhar, S.S., Vogelzang, N.J., Fishman, M.N., Zhang, J., Srinivas, S., Parikh, J., Antal, J., Jin, X., Gupta, A.K., Ben, Y., Hahn, N.M., 2017. Efficacy and Safety of Durvalumab in Locally Advanced or Metastatic Urothelial Carcinoma: Updated Results From a Phase 1/2 Open-label Study. *JAMA Oncol.* 3, e172411. <https://doi.org/10.1001/jamaoncol.2017.2411>
- Prisciandaro, M., Ratta, R., Massari, F., Fornarini, G., Caponnetto, S., Iacovelli, R., De Giorgi, U., Facchini, G., Scagliarini, S., Sabbatini, R., Caserta, C., Peverelli, G., Mennitto, A., Verzoni, E., Procopio, G., 2018. Safety and Efficacy of Cabozantinib for Metastatic Nonclear Renal Cell Carcinoma: Real-world Data From an Italian Managed Access Program. *Am. J. Clin. Oncol.* <https://doi.org/10.1097/COC.0000000000000478>
- Rabinowits, G., Lezcano, C., Catalano, P.J., McHugh, P., Becker, H., Reilly, M.M., Huang, J., Tyagi, A., Thakuria, M., Bresler, S.C., Sholl, L.M., Shapiro, G.I., Haddad, R., DeCaprio, J.A., 2018. Cabozantinib in Patients with Advanced Merkel Cell Carcinoma. *The Oncologist* 23, 814–821. <https://doi.org/10.1634/theoncologist.2017-0552>
- Reck, M., Rodríguez-Abreu, D., Robinson, A.G., Hui, R., Csőszi, T., Fülöp, A., Gottfried, M., Peled, N., Tafreshi, A., Cuffe, S., O'Brien, M., Rao, S., Hotta, K., Leiby, M.A., Lubiniecki, G.M., Shentu, Y., Rangwala, R., Brahmer, J.R., KEYNOTE-024 Investigators, 2016. Pembrolizumab versus Chemotherapy for PD-L1-Positive Non-Small-Cell Lung Cancer. *N. Engl. J. Med.* 375, 1823–1833. <https://doi.org/10.1056/NEJMoa1606774>
- Ribas, A., Hamid, O., Daud, A., Hodi, F.S., Wolchok, J.D., Kefford, R., Joshua, A.M., Patnaik, A., Hwu, W.-J., Weber, J.S., Gangadhar, T.C., Hersey, P., Dronca, R., Joseph, R.W., Zarour, H., Chmielowski, B., Lawrence, D.P., Algazi, A., Rizvi, N.A., Hoffner, B., Mateus, C., Gergich, K., Lindia, J.A., Giannotti, M., Li, X.N., Ebbinghaus, S., Kang, S.P., Robert, C., 2016. Association of Pembrolizumab With Tumor Response and Survival Among Patients With Advanced Melanoma. *JAMA* 315, 1600–1609. <https://doi.org/10.1001/jama.2016.4059>
- Riesenbeck, L.M., Bierer, S., Hoffmeister, I., Köpke, T., Papavassilis, P., Hertle, L., Thielen, B., Herrmann, E., 2011. Hypothyroidism correlates with a better prognosis in metastatic renal cancer patients treated with sorafenib or sunitinib. *World J. Urol.* 29, 807–813. <https://doi.org/10.1007/s00345-010-0627-2>
- Rini, B.I., Michaelson, M.D., Rosenberg, J.E., Bukowski, R.M., Sosman, J.A., Stadler, W.M., Hutson, T.E., Margolin, K., Harmon, C.S., DePrimo, S.E., Kim, S.T., Chen, I., George, D.J., 2008. Antitumor activity and biomarker analysis of sunitinib in patients with bevacizumab-refractory metastatic renal cell carcinoma. *J. Clin. Oncol. Off. J. Am. Soc. Clin. Oncol.* 26, 3743–3748. <https://doi.org/10.1200/JCO.2007.15.5416>
- Rini, B.I., Tamaskar, I., Shaheen, P., Salas, R., Garcia, J., Wood, L., Reddy, S., Dreicer, R., Bukowski, R.M., 2007. Hypothyroidism in patients with metastatic renal cell carcinoma treated with sunitinib. *J. Natl. Cancer Inst.* 99, 81–83. <https://doi.org/10.1093/jnci/djk008>
- Robert, C., Schachter, J., Long, G.V., Arance, A., Grob, J.J., Mortier, L., Daud, A., Carlino, M.S., McNeil, C., Lotem, M., Larkin, J., Lorigan, P., Neyns, B., Blank, C.U., Hamid, O., Mateus, C., Shapira-Frommer, R., Kosh, M., Zhou, H., Ibrahim, N., Ebbinghaus, S., Ribas, A., 2015. Pembrolizumab versus Ipilimumab in Advanced Melanoma. *N. Engl. J. Med.* 372, 2521–2532. <https://doi.org/10.1056/NEJMoa1503093>
- Robinson, B.G., Paz-Ares, L., Krebs, A., Vasselli, J., Haddad, R., 2010. Vandetanib (100 mg) in patients with locally advanced or metastatic hereditary medullary thyroid cancer. *J. Clin. Endocrinol. Metab.* 95, 2664–2671. <https://doi.org/10.1210/jc.2009-2461>
- Sabatier, R., Eymard, J.C., Walz, J., Deville, J.L., Narbonne, H., Boher, J.M., Salem, N., Marcy, M., Brunelle, S., Viens, P., Bladou, F., Gravis, G., 2012. Could thyroid dysfunction influence outcome in sunitinib-treated metastatic renal cell carcinoma? *Ann. Oncol. Off. J. Eur. Soc. Med. Oncol.* 23, 714–721. <https://doi.org/10.1093/annonc/mdr275>
- Salem, A.K., Fenton, M.S., Marion, K.M., Hershman, J.M., 2008. Effect of sunitinib on growth and function of FRTL-5 thyroid cells. *Thyroid Off. J. Am. Thyroid Assoc.* 18, 631–635. <https://doi.org/10.1089/thy.2007.0336>

- Sato, S., Muraishi, K., Tani, J., Sasaki, Y., Tokubuchi, I., Tajiri, Y., Yamada, K., Suekane, S., Miyajima, J., Matsuoka, K., Hiromatsu, Y., 2010. Clinical characteristics of thyroid abnormalities induced by sunitinib treatment in Japanese patients with renal cell carcinoma. *Endocr. J.* 57, 873–880.
- Schlumberger, M., Elisei, R., Müller, S., Schöffski, P., Brose, M., Shah, M., Licitra, L., Krajewska, J., Kreissl, M.C., Niederle, B., Cohen, E.E.W., Wirth, L., Ali, H., Clary, D.O., Yaron, Y., Mangeshkar, M., Ball, D., Nelkin, B., Sherman, S., 2017. Overall survival analysis of EXAM, a phase III trial of cabozantinib in patients with radiographically progressive medullary thyroid carcinoma. *Ann. Oncol. Off. J. Eur. Soc. Med. Oncol.* 28, 2813–2819. <https://doi.org/10.1093/annonc/mdx479>
- Schlumberger, M., Jarzab, B., Cabanillas, M.E., Robinson, B., Pacini, F., Ball, D.W., McCaffrey, J., Newbold, K., Allison, R., Martins, R.G., Licitra, L.F., Shah, M.H., Bodenner, D., Elisei, R., Burmeister, L., Funahashi, Y., Ren, M., O'Brien, J.P., Sherman, S.I., 2016. A Phase II Trial of the Multitargeted Tyrosine Kinase Inhibitor Lenvatinib (E7080) in Advanced Medullary Thyroid Cancer. *Clin. Cancer Res.* 22, 44–53. <https://doi.org/10.1158/1078-0432.CCR-15-1127>
- Schmidinger, M., Vogl, U.M., Bojic, M., Lamm, W., Heinzl, H., Haitel, A., Clodi, M., Kramer, G., Zielinski, C.C., 2011. Hypothyroidism in patients with renal cell carcinoma: blessing or curse? *Cancer* 117, 534–544. <https://doi.org/10.1002/cncr.25422>
- Schoeffski P., Wolter P., Himpe U et al., 3092. Sunitinib-related thyroid dysfunction: A single-center retrospective and prospective evaluation [WWW Document]. URL http://ascopubs.org/action/showCitFormats?doi=10.1200/jco.2006.24.18_suppl.3092 (accessed 9.18.18).
- Shinohara, N., Takahashi, M., Kamishima, T., Ikushima, H., Otsuka, N., Ishizu, A., Shimizu, C., Kanayama, H., Nonomura, K., 2011. The incidence and mechanism of sunitinib-induced thyroid atrophy in patients with metastatic renal cell carcinoma. *Br. J. Cancer* 104, 241–247. <https://doi.org/10.1038/sj.bjc.6606029>
- Shu, M., Zai, X., Zhang, B., Wang, R., Lin, Z., 2016. Hypothyroidism Side Effect in Patients Treated with Sunitinib or Sorafenib: Clinical and Structural Analyses. *PloS One* 11, e0147048. <https://doi.org/10.1371/journal.pone.0147048>
- Simonides, W.S., Mulcahey, M.A., Redout, E.M., Muller, A., Zuidwijk, M.J., Visser, T.J., Wassen, F.W.J.S., Crescenzi, A., da-Silva, W.S., Harney, J., Engel, F.B., Obregon, M.-J., Larsen, P.R., Bianco, A.C., Huang, S.A., 2008. Hypoxia-inducible factor induces local thyroid hormone inactivation during hypoxic-ischemic disease in rats. *J. Clin. Invest.* 118, 975–983. <https://doi.org/10.1172/JCI32824>
- Sznol, M., Postow, M.A., Davies, M.J., Pavlick, A.C., Plimack, E.R., Shaheen, M., Veloski, C., Robert, C., 2017. Endocrine-related adverse events associated with immune checkpoint blockade and expert insights on their management. *Cancer Treat. Rev.* 58, 70–76. <https://doi.org/10.1016/j.ctrv.2017.06.002>
- Tamaskar, I., Bukowski, R., Elson, P., Ioachimescu, A.G., Wood, L., Dreicer, R., Mekhail, T., Garcia, J., Rini, B.I., 2008. Thyroid function test abnormalities in patients with metastatic renal cell carcinoma treated with sorafenib. *Ann. Oncol. Off. J. Eur. Soc. Med. Oncol.* 19, 265–268. <https://doi.org/10.1093/annonc/mdm483>
- Taylor, P.N., Albrecht, D., Scholz, A., Gutierrez-Buey, G., Lazarus, J.H., Dayan, C.M., Okosieme, O.E., 2018. Global epidemiology of hyperthyroidism and hypothyroidism. *Nat. Rev. Endocrinol.* 14, 301–316. <https://doi.org/10.1038/nrendo.2018.18>
- TECENTRIQ®(atezolizumab), prescribing information., n.d.
- Tomer, Y., 2010. Genetic Susceptibility to Autoimmune Thyroid Disease: Past, Present, and Future. *Thyroid* 20, 715–725. <https://doi.org/10.1089/thy.2010.1644>
- Tomita, Y., Uemura, H., Fujimoto, H., Kanayama, H., Shinohara, N., Nakazawa, H., Imai, K., Umeyama, Y., Ozono, S., Naito, S., Akaza, H., Japan Axitinib Phase II Study Group, 2011. Key predictive factors of axitinib (AG-013736)-induced proteinuria and efficacy: a phase II study in Japanese patients with cytokine-refractory metastatic renal cell Carcinoma. *Eur. J. Cancer Oxf. Engl.* 1990 47, 2592–2602. <https://doi.org/10.1016/j.ejca.2011.07.014>

- Topalian, S.L., Hodi, F.S., Brahmer, J.R., Gettinger, S.N., Smith, D.C., McDermott, D.F., Powderly, J.D., Carvajal, R.D., Sosman, J.A., Atkins, M.B., Leming, P.D., Spigel, D.R., Antonia, S.J., Horn, L., Drake, C.G., Pardoll, D.M., Chen, L., Sharfman, W.H., Anders, R.A., Taube, J.M., McMiller, T.L., Xu, H., Korman, A.J., Jure-Kunkel, M., Agrawal, S., McDonald, D., Kollia, G.D., Gupta, A., Wigginton, J.M., Sznol, M., 2012. Safety, activity, and immune correlates of anti-PD-1 antibody in cancer. *N. Engl. J. Med.* 366, 2443–2454. <https://doi.org/10.1056/NEJMoa1200690>
- Torino, F., Corsello, S.M., Longo, R., Barnabei, A., Gasparini, G., 2009. Hypothyroidism related to tyrosine kinase inhibitors: an emerging toxic effect of targeted therapy. *Nat. Rev. Clin. Oncol.* 6, 219–228. <https://doi.org/10.1038/nrclinonc.2009.4>
- Ueda, T., Uemura, H., Tomita, Y., Tsukamoto, T., Kanayama, H., Shinohara, N., Tarazi, J., Chen, C., Kim, S., Ozono, S., Naito, S., Akaza, H., 2013. Efficacy and safety of axitinib versus sorafenib in metastatic renal cell carcinoma: subgroup analysis of Japanese patients from the global randomized Phase 3 AXIS trial. *Jpn. J. Clin. Oncol.* 43, 616–628. <https://doi.org/10.1093/jjco/hyt054>
- van der Veldt, A.A.M., Lammertsma, A.A., Smit, E.F., 2013. Reduction in thyroid perfusion after bevacizumab treatment. *Thyroid Off. J. Am. Thyroid Assoc.* 23, 1329–1330. <https://doi.org/10.1089/thy.2013.0147>
- Villa, N.M., Farahmand, A., Du, L., Yeh, M.W., Smooke-Praw, S., Ribas, A., Chmielowski, B., Cherry, G., Leung, A.M., 2018. Endocrinopathies with use of cancer immunotherapies. *Clin. Endocrinol. (Oxf.)* 88, 327–332. <https://doi.org/10.1111/cen.13483>
- Weber, J.S., D’Angelo, S.P., Minor, D., Hodi, F.S., Gutzmer, R., Neyns, B., Hoeller, C., Khushalani, N.I., Miller, W.H., Lao, C.D., Linette, G.P., Thomas, L., Lorigan, P., Grossmann, K.F., Hassel, J.C., Maio, M., Sznol, M., Ascierto, P.A., Mohr, P., Chmielowski, B., Bryce, A., Svane, I.M., Grob, J.-J., Krackhardt, A.M., Horak, C., Lambert, A., Yang, A.S., Larkin, J., 2015. Nivolumab versus chemotherapy in patients with advanced melanoma who progressed after anti-CTLA-4 treatment (CheckMate 037): a randomised, controlled, open-label, phase 3 trial. *Lancet Oncol.* 16, 375–384. [https://doi.org/10.1016/S1470-2045\(15\)70076-8](https://doi.org/10.1016/S1470-2045(15)70076-8)
- Wells, S.A., Robinson, B.G., Gagel, R.F., Dralle, H., Fagin, J.A., Santoro, M., Baudin, E., Elisei, R., Jarzab, B., Vasselli, J.R., Read, J., Langmuir, P., Ryan, A.J., Schlumberger, M.J., 2012. Vandetanib in patients with locally advanced or metastatic medullary thyroid cancer: a randomized, double-blind phase III trial. *J. Clin. Oncol. Off. J. Am. Soc. Clin. Oncol.* 30, 134–141. <https://doi.org/10.1200/JCO.2011.35.5040>
- Wolchok, J.D., Chiarion-Sileni, V., Gonzalez, R., Rutkowski, P., Grob, J.-J., Cowey, C.L., Lao, C.D., Wagstaff, J., Schadendorf, D., Ferrucci, P.F., Smylie, M., Dummer, R., Hill, A., Hogg, D., Haanen, J., Carlino, M.S., Bechter, O., Maio, M., Marquez-Rodas, I., Guidoboni, M., McArthur, G., Lebbé, C., Ascierto, P.A., Long, G.V., Cebon, J., Sosman, J., Postow, M.A., Callahan, M.K., Walker, D., Rollin, L., Bhore, R., Hodi, F.S., Larkin, J., 2017. Overall Survival with Combined Nivolumab and Ipilimumab in Advanced Melanoma. *N. Engl. J. Med.* 377, 1345–1356. <https://doi.org/10.1056/NEJMoa1709684>
- Wolter, P., Stefan, C., Decallonne, B., Dumez, H., Bex, M., Carmeliet, P., Schöffski, P., 2008. The clinical implications of sunitinib-induced hypothyroidism: a prospective evaluation. *Br. J. Cancer* 99, 448–454. <https://doi.org/10.1038/sj.bjc.6604497>
- Wong, E., Rosen, L.S., Mulay, M., Vanvugt, A., Dinolfo, M., Tomoda, C., Sugawara, M., Hershman, J.M., 2007. Sunitinib induces hypothyroidism in advanced cancer patients and may inhibit thyroid peroxidase activity. *Thyroid Off. J. Am. Thyroid Assoc.* 17, 351–355. <https://doi.org/10.1089/thy.2006.0308>
- Yamada, K., Yamamoto, N., Yamada, Y., Nokihara, H., Fujiwara, Y., Hirata, T., Koizumi, F., Nishio, K., Koyama, N., Tamura, T., 2011. Phase I dose-escalation study and biomarker analysis of E7080 in patients with advanced solid tumors. *Clin. Cancer Res. Off. J. Am. Assoc. Cancer Res.* 17, 2528–2537. <https://doi.org/10.1158/1078-0432.CCR-10-2638>

- Yamauchi, I., Sakane, Y., Fukuda, Y., Fujii, T., Taura, D., Hirata, M., Hirota, K., Ueda, Y., Kanai, Y., Yamashita, Y., Kondo, E., Sone, M., Yasoda, A., Inagaki, N., 2017. Clinical Features of Nivolumab-Induced Thyroiditis: A Case Series Study. *Thyroid Off. J. Am. Thyroid Assoc.* 27, 894–901. <https://doi.org/10.1089/thy.2016.0562>
- Yang, Y., Zhang, Y., Cao, Z., Ji, H., Yang, X., Iwamoto, H., Wahlberg, E., Länne, T., Sun, B., Cao, Y., 2013. Anti-VEGF- and anti-VEGF receptor-induced vascular alteration in mouse healthy tissues. *Proc. Natl. Acad. Sci. U. S. A.* 110, 12018–12023. <https://doi.org/10.1073/pnas.1301331110>
- Yavuz, S., Apolo, A.B., Kummar, S., del Rivero, J., Madan, R.A., Shawker, T., Reynolds, J., Celi, F.S., 2014. Cabozantinib-induced thyroid dysfunction: a review of two ongoing trials for metastatic bladder cancer and sarcoma. *Thyroid Off. J. Am. Thyroid Assoc.* 24, 1223–1231. <https://doi.org/10.1089/thy.2013.0621>
- Yoshida, H., Amino, N., Yagawa, K., Uemura, K., Satoh, M., Miyai, K., Kumahara, Y., 1978. Association of serum antithyroid antibodies with lymphocytic infiltration of the thyroid gland: studies of seventy autopsied cases. *J. Clin. Endocrinol. Metab.* 46, 859–862. <https://doi.org/10.1210/jcem-46-6-859>