



**HAL**  
open science

## Contribution of shear wave elastography in evaluation of the deltoid in reverse shoulder arthroplasty: reproducibility study and preliminary results

Ruben Dukan, Claudio Vergari, Patrick Boyer, Wafa Skalli

### ► To cite this version:

Ruben Dukan, Claudio Vergari, Patrick Boyer, Wafa Skalli. Contribution of shear wave elastography in evaluation of the deltoid in reverse shoulder arthroplasty: reproducibility study and preliminary results. *Medical Ultrasonography*, In press, 10.11152/mu-3249 . hal-03470648

**HAL Id: hal-03470648**

**<https://hal.science/hal-03470648v1>**

Submitted on 13 Dec 2021

**HAL** is a multi-disciplinary open access archive for the deposit and dissemination of scientific research documents, whether they are published or not. The documents may come from teaching and research institutions in France or abroad, or from public or private research centers.

L'archive ouverte pluridisciplinaire **HAL**, est destinée au dépôt et à la diffusion de documents scientifiques de niveau recherche, publiés ou non, émanant des établissements d'enseignement et de recherche français ou étrangers, des laboratoires publics ou privés.

# Contribution of shear wave elastography in evaluation of the deltoid in reverse shoulder arthroplasty: reproducibility study and preliminary results

Ruben Dukan<sup>1,2</sup>, Claudio Vergari<sup>2</sup>, Patrick Boyer<sup>1,2</sup>, Wafa Skalli<sup>2</sup>

<sup>1</sup>Université Paris Diderot, Bichat Hospital, Service d'Orthopédie, <sup>2</sup>Institut de Biomécanique Humaine Georges Charpak, Arts et Métiers Paristech, Paris, France

## Abstract

**Aims:** The current difficulty of reverse shoulder arthroplasty (RSA) is soft tissue management, and adequate deltoid tension and at present there is no consensus and available tools (X-ray, MRI, EMG) remain difficult to apply in clinical follow-up. The objective of this study was (1) to determine reliability and feasibility of deltoid elasticity assessment using ultrasound elastography and (2) to assess the change of deltoid stiffness after RSA by comparing shear wave speed (SWS) between healthy and RSA shoulders. **Material and methods:** Twenty-six healthy (native shoulder, painless and complete range of motion) subjects and twelve patients with RSA were included. Two independent investigators performed 3 measurements on each segment. Measurements were bilateral. Anterior segment was also evaluated at 45° and 60° of passive abduction. Reliability and feasibility have been assessed (ISO5725-standard). **Results:** Coefficient of measurements variation was less than 6.1% and 0.13 m/s. In the healthy group, SWS was not significantly different between anterior and middle segments; however, the SWS of the posterior segment was significantly lower than others ( $p < 0.0001$ ). In abduction position, compared to the rest position, SWS of the anterior segment decreased at 45° abduction ( $p = 0.0003$ ) and increased at 60° abduction ( $p < 0.0001$ ). Variability of measurement was higher in the RSA group. No significant difference was found between the SWS measurement of the operated and non-operated side. SWS measurements of the operated side of the anterior and middle segment were significantly higher compared to the healthy group. In abduction position, compared to rest position, no difference in SWS of the anterior segment was found at 45° abduction ( $p = 0.71$ ) and nor at 60° abduction ( $p = 0.75$ ). **Conclusion:** This study demonstrated feasibility and reliability of shoulder assessment with shear wave elastography. Reference values for asymptomatic patients can already be used in future studies on shoulder pathology and surgery.

**Keywords:** shear wave elastography; deltoid; reverse shoulder arthroplasty; elastography

## Introduction

Reverse shoulder arthroplasty (RSA) was created in 1987 by Grammont [1]. This implant modifies the joint biomechanics by lateralizing and lowering the joint rotation center. Except in acute context (fracture, traumatic rotator cuff tear), this implant is designed to compensate the deficiency of the rotator cuff in elderly subjects suffering from chronic rotator cuff tear with significant

fatty degeneration, for which repair is not possible. In this case, the deltoid (composed of 3 segments: anterior, middle and posterior) became the only motor for anterior elevation and abduction of the shoulder [1].

However, deltoid moment arm change has an implication on the tension applied on this muscle. Over-tension will result in increased pain, decreased range of motion and potentially an increased incidence of acromial fractures. In contrast, tension default is associated with an increased rate of shoulder dislocation. Several parameters influence this tension: extrinsic parameters represented by implant design and intra-operative implant positioning, as well as intrinsic parameters such as the deltoid's biomechanical properties. By determining pre-operative deltoid elasticity, the surgeon can adapt the design and

positioning of implants. In post-operative care, physiotherapy can be adapted according to the evolution of muscle elasticity [2].

The importance of the deltoid in achieving satisfactory outcomes after RSA has been reported through biomechanical studies using cadaveric shoulders [3], finite element analysis [4] and three-dimensional motion analysis using virtual shoulder models [5,6]. However, only the changes of deltoid moment arm or its required force for shoulder motions have been evaluated. Although deltoid evaluation techniques exist such as X-rays, CT-scan and MRI [7,8], they remain difficult to apply in clinical follow-up practice and they are not informative on muscle mechanical properties.

Shear wave elastography (SWE) is a quantitative, non-invasive and relatively low-cost tool to evaluate the biomechanical properties of the deltoid. The method is based on the measurement of shear wave speed (SWS) in the tissue; this parameter is directly related to the shear modulus, an inherent parameter related to tissue stiffness [9]. While the reliability of SWE has been proved in a large number of studies, the shoulder presents specific difficulties and, in particular, the standardization of the arm position and the determination of the different anatomical regions of the deltoid. Currently, there is no baseline data to evaluate pathologic shoulder measures. Furthermore, adjacent bony structures to shoulder muscles, including the acromion, scapular spine and clavicle have been shown to interfere with a uniform compression of the soft tissue [10], as well as sparse overlying subcutaneous tissue.

The aim of this study was (1) to determine reliability and feasibility of deltoid elasticity assessment using SWE and (2) to assess the changes of deltoid stiffness after RSA by comparing SWS between healthy and RSA shoulders.

## **Material and methods**

### ***Patients***

A total of 38 subjects were included in this study from October 2019 to June 2020. Healthy subjects were selected from the hospital and university staff. RSA patients were selected from the orthopedic surgery department of Bichat Hospital (Paris, France). Two groups were formed: healthy group (n=26, native shoulder, painless and complete range of motion) and RSA group (n=12). Indication for RSA was eccentric omarthrosis. All subjects were adults. Exclusion criteria were: (1) neuromuscular pathology, (2) previous fracture of the humeral head or glen, (3) previous shoulder surgery. Professional athletes were not included in the study.

The study was approved by the Ethical Committee (CPP Ile de France VI) and all patients provided written informed consent before data and collection.

### ***Surgery protocol***

All patients were operated on by the same surgeon with same supero-lateral approach. This approach required passage between the anterior and middle portion of the deltoid. The distal part of the deltoid was preserved to avoid any injury to the axillary nerve. At first, an anatomic section of the humerus at the bone-cartilage junction was performed. An asymmetric reamer was used for increasing the height of the central portion to improve osteointegration and it preserved the peripheral rim to optimize the stability of the baseplate. Then, the humeral implant was retroverted by 20° and was uncemented. Care was taken to not cause any damage to the deltoid muscle. Repair was performed for any existing deltoid muscle lesion, especially the anterior deltoid.

Short humeral stem RSA (Ascend, Wright, US) was used with a 145° cervico-diaphyseal angle. The same physiotherapist managed all patients after surgery.

### ***Clinical assessment***

After surgery, at a minimum of 24 months follow-up, patients underwent clinical assessment to perform deltoid clinical palpation and determine Constant score [11], followed by the ultrasound procedure described below. The surgeon performing the clinical evaluation was blinded from the ultrasound measurements and vice-versa.

### ***SWE***

Measurements were performed with an Aixplorer (SuperSonic Imagine, Aix en Provence, France) and a linear SL-10 probe (10 MHz central frequency). Training sessions on manipulation and interpretation of elastography sequences were performed before the beginning of this study by the 2 investigators (P.B and R.D). Intra- and inter-observer agreements in reproducibility of the measurements were evaluated. Subjects avoided sport sessions within 24 hours before ultrasound measurements.

First, B-mode imaging was used to identify each deltoid segment, to evaluate the structure of the muscle and to exclude a pathological process in the healthy subject (tumor, fibrosis, bursitis, etc).

Investigators adjusted the imaging parameters (depth, brightness, SWS range, etc.) to optimize the acquisition for each patient. The adjustment of the image should make it possible to obtain an image in the long axis of the deltoid muscle allowed for the simultaneous visualization of the tendon insertion/ footprint at the greater tuberosity, non-insertional (proximal) tendon and adjacent peribursal tissues/deltoid muscle. The probe was placed parallel to the deltoid fibers to acquire elastography and

only the slightest pressure was applied to avoid compressing the tissue.

Investigator performed bilateral measurements of each deltoid segment in relaxed position (palms on his thighs), in each group.

A specific measurement of the anterior segment of the deltoid in abducted position (45° and 60°) was performed, for the dominant side in the healthy group and for the operated side in the RSA group.

Each acquisition corresponded to a 10-seconds video (about 10 frames). Previously validated custom post-processing software by Vergari et al [12,13] was used to define a region of interest (ROI) in the first video frame and semi-automatically tracked in following frames. Average shear modulus was calculated in each frame ROI and then averaged to obtain one value per acquisition. This allowed the continual measuring of the same ROI and avoiding zones where the signal was unreliable. ROI was placed manually by the investigator, avoiding fascia and bone structure [14] (fig 1).

### Statistical analyses

Statistical analysis was performed using SAS 9.1 software (SAS Institute, Cary, IN, USA). ANOVA test was used to analyze SWS between each segment of the deltoid and after between each shoulder. The post hoc test was used if the ANOVA test was significant. Correlation was analyzed with the Pearson test. P values equal to 0.05 were considered to indicate statistical significance. ISO 5725 standard was used to calculate intra-investigator repeatability and inter-investigator reproducibility in terms of standard deviation (SD, in m/s units) and coefficient of variation (percentage). Results are reported as mean ± SD.

## Results

### Healthy group

Mean age was 33.7±14.6 years. Sex ratio was 1.9 female to male.

The inter-investigator reproducibility of the measurements in the resting position was less than 0.12 m/s for each deltoid segment, corresponding to a coefficient of variation of less than 6%. Coefficient of measurements variation was less than 6.1% and 0.13 m/s. Bland and Altman plot of the whole data is reported in figure 2.

SWS measurements are reported in table I. In the dominant side, no difference was found between the anterior and middle segment (p=0.14). These segments were significantly higher than the posterior one (p<0.0001). In the non-dominant side, no difference was found between the anterior and middle segment (p=0.21). These segments were significantly higher than the posterior one (p<0.0001).

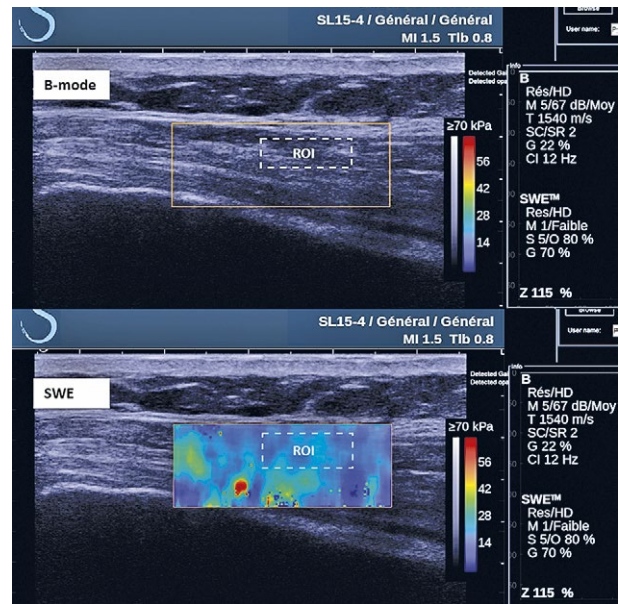


Fig 1. ROI measurement.

In the abduction position, compared to the rest position, SWS of the anterior segment decreased at 45° abduction (2.4±0.1 vs 2.2±0.1, p=0.0003) and increased at 60° abduction (2.4±0.1 vs 2.6±0.1, p<0.0001).

### RSA group

Mean age of the patients was 67.2±8.3 years. Sex ratio was 0.7 female to male. Mean follow-up since surgery was 27.1±5.3 months. Operated shoulder corresponded to the dominant side in 8 cases (67%). Mean Constant score was 74±13 and mean VAS was 2±2. Range of motion in forward flexion was 133±31°, abduction was 113±23° and external rotation was 35±13°.

Data variability was higher in the RSA+ group. The surgical scar between the anterior and middle deltoid segment was avoided for SWS measurement. No significant difference was found between the SWS measurement of the operated and non-operated side. SWS measurements of the operated side of the anterior and middle segment were significantly higher compared to the healthy group. Results are reported in table II and table III.

Table I. Shear Wave Speed assessment in the healthy group

Deltoid segment	SWS dominant side (m/s)	SWS non-dominant side (m/s)	p-value
Anterior	2.4±0.11	2.3±0.14	0.22
Middle	2.3±0.11	2.3±0.13	0.26
Posterior	2.2±0.12	2.1±0.11	0.18

The results are expressed as mean±standard deviation. SWS: Shear Wave Speed

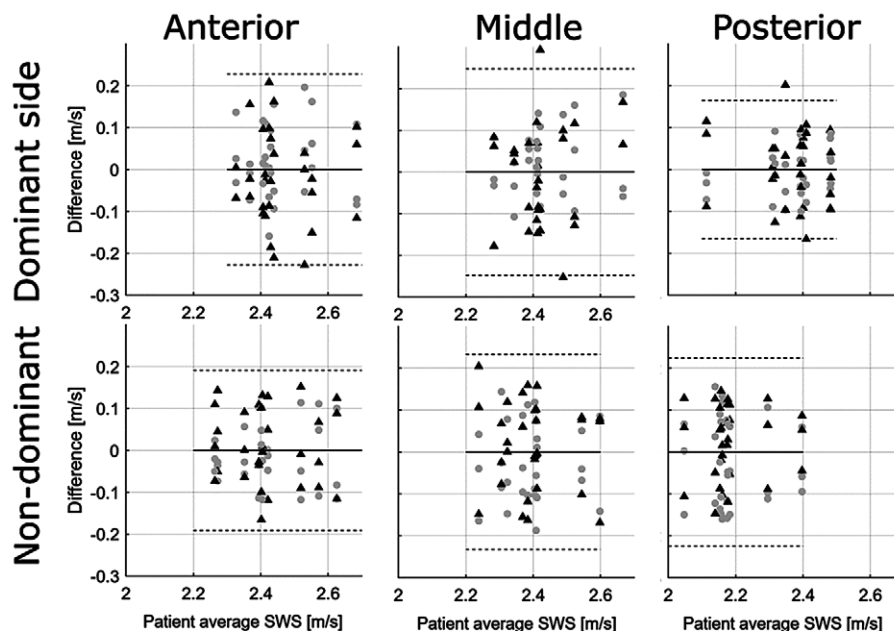


Fig 2. Bland and Altman plots of the reproducibility study in healthy subjects (investigator 1 and 2 represented by circles and triangles respectively)

In the abduction position, compared to the rest position, no difference in SWS of the anterior segment was found at 45° abduction ( $2.7 \pm 0.6$  vs  $2.7 \pm 0.7$ ,  $p=0.71$ ) and nor at 60° abduction ( $2.7 \pm 0.6$  vs  $2.8 \pm 0.6$ ,  $p=0.75$ ).

No correlation was found between the SWS values and the Constant score.

### Discussion

This study confirmed reliability and feasibility of SWE in the assessment of the shear modulus of the three deltoid segments (anterior, middle, posterior) in different postures: palms on the thighs and at three abduction positions: 0°, 45° and 60°.

Results reported in the healthy group could give an insight into deltoid muscle function. For each side, no significant difference was found between SWS of the anterior and middle segment. Often ignored in the evaluation of the deltoid function, ultrasound assessment of this muscle segment will permit the reassessment of its role in abduction and correlate the evolution of its mechanical properties with clinical outcomes.

In the healthy group, SWS decreased at 45° abduction and increased at 60° abduction in comparison to the rest position. This observation was surprising because deltoid is shortened in abduction and therefore a progressive decrease of SWS was expected. However, two factors can explain this phenomenon. First, the position of the sling was not perfectly orthogonal to the body. Thus, at 45° abduction the sling induced a component of forward flexion

and therefore a shortening of the deltoid. At 60°, the arm was in a slight retroflexion, thus causing an elongation of the deltoid which could have caused an increase in SWS. Such increase was previously demonstrated *in vivo* using ultrasound elastography for evaluating upper limb muscles or lower limb muscles [15]. This is consistent with the increase of muscle stiffness according to elongation which was observed by Hatta et al [16] on 8 cadaveric

Table II. Shear Wave Speed assessment in the RSA group

Deltoid segment	SWS operated side (m/s)	SWS non-operated side (m/s)	p-value
Anterior	$2.7 \pm 0.63$	$2.4 \pm 0.09$	0.08
Middle	$2.5 \pm 0.16$	$2.4 \pm 0.10$	0.06
Posterior	$2.2 \pm 0.14$	$2.12 \pm 0.12$	0.80

The results are expressed as mean±standard deviation; SWS: Shear Wave Speed

Table III. Shear Wave Speed comparison between the RSA and the healthy group

Deltoid segment	SWS RSA operated side (m/s)	SWS healthy group (m/s) *	p-value
Anterior	$2.7 \pm 0.63$	$2.4 \pm 0.13$	0.017
Middle	$2.5 \pm 0.16$	$2.3 \pm 0.12$	0.004
Posterior	$2.2 \pm 0.14$	$2.2 \pm 0.13$	0.31

The results are expressed as mean±standard deviation SWS: Shear Wave Speed

\* No difference was made between dominant and non-dominant side

shoulders. The second factor could have been a modification of involuntary contraction of the deltoid at elevated abduction positions, described by Kok et al [17], which can also increase SWS [18].

Kim et al [19] evaluated deltoid SWS at different abduction positions. SWS measurement at 45° abduction were ranged approximatively between 17 kPa and 21 kPa corresponded to 2.3 m/s and 2.5 m/s. These values were similar to our measurements in the healthy group (range 1.9 m/s to 2.3 m/s). Thus, in our study, we can consider that the forward flexion component of the sling was negligible and the muscle was well relaxed and shortened.

In clinical practice, deltoid elongation can be observed after RSA. The clinical consequences of hyperelongation, also called over-tension, of the deltoid have already been described: increased pain, reduction of mobility, increased risk of acromial fracture [20]. These findings were also reported by Pegreffì et al [7] with the use of EMG. There is a deterioration of the deltoid fibers at 2 years postoperatively.

The use of ultrasound to assess deltoid after RSA was evaluated in 2016 by Fischer et al [21]. Sixty-four patients were included and the evaluation was bilateral. Acoustic radiation force impulse imaging and Doppler were used to evaluate the SWS of the different deltoid segments. Those authors found a significantly stronger perfusion and larger caliber of the deltoid muscle in patients with an above-average outcome after RSA compared with patients with a below-average outcome. Functional and ultrasound evaluations showed impaired function and diminished deltoid perfusion of the operated-on shoulder compared with the contralateral side. Reduced perfusion kinetics of the operated-on shoulder should be a sign of muscle tissue atrophy and can be associated with the ultrasound elastography to assess the atrophy. However, those authors compared the operated side with the contralateral one. They found asymmetry in patient outcomes in both short- and long-term follow-up. Degradation of the deltoid muscle over time was observed in an earlier study [22]. Therefore, comparison to a contralateral side could lead to overestimate or underestimate the results according to the dominance of the operated side.

In the present study, the RSA group was compared to a cohort of subjects with healthy shoulders. At an average follow-up of 27.1 months, no differences in SWS were found between the different deltoid segments in the rest position. SWS values were not correlated to the Constant score. However, SWS increased at 45° and 60° abduction. This is probably due to a post-operative modification of the biomechanical properties of the anterior deltoid. The superolateral approach crosses between the

anterior and middle deltoid, hence the anterior deltoid can be injured intraoperatively. It is interesting to note that the highest SWS were reported and correlated to the 3 cases of clinical sclerotic rope palpation in the anterior deltoid. We developed this idea (sclerotic muscle modification) in our previous study [23].

Postoperative sclerosis may be the cause of an increase in SWS. This hypothesis is supported by the fact that when we removed these 3 outliers-sclerotic muscles, the pattern becomes the same as in the asymptomatic group. Thus, this stiffer muscle either stretches more than a healthy muscle at 45°, or it prevents forward movement of the arm.

This study has some limitations. The main limitation was the relatively small number of subjects. There is an age and sex difference between the two groups. However, we performed statistical analyses to search for a significant difference between the dominant sides of the asymptomatic group and the dominant non-operated sides of the RSA group and the non-dominant sides of the asymptomatic group with the non-dominant non-operated sides of the RSA group. We did not find any significant difference and this suggested that the age and sex ratio represented an acceptable bias.

This preliminary feasibility study reported that the measurement is feasible and reliable in all three deltoid segments, and it demonstrated potential application in clinical practice. We think that elastography should allow improvement of RSA surgical strategy [24] (choice of implant, orientation of bone cuts), by optimizing tension of the deltoid according to the elasticity measured in the pre-operative period. The type of glenosphere (diameter and lateral offset) [5], humeral component (offset and rotation) [25], and their positioning (tilt and rotation) [6, 26] have demonstrated that this affect the mechanical properties of the deltoid muscle.

In **conclusion**, this study demonstrated feasibility and reliability of shoulder assessment with SWE. Reference values for healthy patients can already be used in future studies on shoulder pathology and surgery.

**Conflict of interest:** none

## References

1. Grammont PM, Trouilloud P, Laffey JP, Deries X. Etude et réalisation d'une nouvelle prothèse d'épaule. *Rhumatologie* 1987;39:17–22.
2. Minafra P, Alvitì F, Giovagnorio R, Cantisani V, Mazzoni G. Shear Wave Elastographic Study of the Myotendinous Junction of the Medial Gastrocnemius: Normal Patterns and Dynamic Evaluation. *J Ultrasound Med* 2020;39:2195–2200.

3. Nolte PC, Miles JW, Tanghe KK, et al. The effect of glenosphere lateralization and inferiorization on deltoid force in reverse total shoulder arthroplasty. *J Shoulder Elbow Surg* 2021;30:1817-1826.
4. Hettrich CM, Permeswaran VN, Goetz JE, Anderson DD. Mechanical tradeoffs associated with glenosphere lateralization in reverse shoulder arthroplasty. *J Shoulder Elbow Surg* 2015;24:1774-1781.
5. Costantini O, Choi DS, Kontaxis A, Gulotta LV. The effects of progressive lateralization of the joint center of rotation of reverse total shoulder implants. *J Shoulder Elbow Surg* 2015;24:1120-1128.
6. Berhouet J, Kontaxis A, Gulotta LV, et al. Effects of the humeral tray component positioning for onlay reverse shoulder arthroplasty design: a biomechanical analysis. *J Shoulder Elbow Surg* 2015;24:569-577.
7. Pegreff F, Pellegrini A, Paladini P, et al. Deltoid muscle activity in patients with reverse shoulder prosthesis at 2-year follow-up. *Musculoskelet Surg* 2017;101(Suppl 2):129-135.
8. Yoon JP, Seo A, Kim JJ, et al. Deltoid muscle volume affects clinical outcome of reverse total shoulder arthroplasty in patients with cuff tear arthropathy or irreparable cuff tears. *PloS One* 2017;12:e0174361.
9. Ferraioli G, Barr RG, Farrokh A, et al. How to perform shear wave elastography. Part I. *Med Ultrason* 2021 May 4. doi:10.11152/mu-3217.
10. Shimoyama D, Shitara H, Hamano N, et al. Reliability of shoulder muscle stiffness measurement using strain ultrasound elastography and an acoustic coupler. *J Med Ultrason (2001)* 2021;48:91-96.
11. Sabesan VJ, Lombardo DJ, Khan J, Wiater JM. Assessment of the optimal shoulder outcome score for reverse shoulder arthroplasty. *J Shoulder Elbow Surg* 2015;24:1653-1659.
12. Vergari C, Rouch P, Dubois G, et al. Non-invasive biomechanical characterization of intervertebral discs by shear wave ultrasound elastography: a feasibility study. *Eur Radiol* 2014;24:3210-3216.
13. Vergari C, Rouch P, Dubois G, Tanter M, Gennisson JL, Skalli W. Intervertebral disc characterisation by elastography: a preliminary study. *Comput Methods Biomech Biomed Engin* 2013;16 Suppl 1:275-277.
14. Schmalzl J, Fenwick A, Boehm D, Gilbert F. The application of ultrasound elastography in the shoulder. *J Shoulder Elbow Surg* 2017;26:2236-2246.
15. Dubois G, Kheireddine W, Vergari C, et al. Reliable protocol for shear wave elastography of lower limb muscles at rest and during passive stretching. *Ultrasound Med Biol* 2015;41:2284-2291.
16. Hatta T, Giambini H, Sukegawa K, et al. Quantified Mechanical Properties of the Deltoid Muscle Using the Shear Wave Elastography: Potential Implications for Reverse Shoulder Arthroplasty. *PloS One* 2016;11:e0155102.
17. Kok LM, Schrijvers J, Fiocco M, van Royen B, Harlaar J. Use of a Shoulder Rest for Playing the Violin Revisited: An Analysis of the Effect of Shoulder Rest Height on Muscle Activity, Violin Fixation Force, and Player Comfort. *Med Probl Perform Art* 2019;34:39-46.
18. Ateş F, Hug F, Bouillard K, et al. Muscle shear elastic modulus is linearly related to muscle torque over the entire range of isometric contraction intensity. *J Electromyogr Kinesiol* 2015;25:703-708.
19. Kim K, Hwang HJ, Kim SG, Lee JH, Jeong WK. Can Shoulder Muscle Activity Be Evaluated With Ultrasound Shear Wave Elastography? *Clin Orthop Relat Res* 2018;476:1276-1283.
20. Henninger HB, Barg A, Anderson AE, Bachus KN, Tashjian RZ, Burks RT. Effect of deltoid tension and humeral version in reverse total shoulder arthroplasty: a biomechanical study. *J Shoulder Elbow Surg* 2012;21:483-490.
21. Fischer C, Krammer D, Hug A, et al. Dynamic contrast-enhanced ultrasound and elastography assess deltoid muscle integrity after reverse shoulder arthroplasty. *J Shoulder Elbow Surg* 2017;26:108-117.
22. Greiner SH, Back DA, Herrmann S, Perka C, Asbach P. Degenerative changes of the deltoid muscle have impact on clinical outcome after reversed total shoulder arthroplasty. *Arch Orthop Trauma Surg* 2010;130:177-183.
23. Dukan R, Bahman M, Rousseau MA, Boyer P. Outcomes of reverse shoulder arthroplasty using a short stem through a superolateral approach. *J Shoulder Elbow Surg* 2020;29:1197-1205.
24. Elwell J, Athwal G, Willing R. Maximizing range of motion of reverse total shoulder arthroplasty using design optimization techniques. *J Biomech* 2021;125:110602.
25. Giles JW, Langohr GDG, Johnson JA, Athwal GS. Implant Design Variations in Reverse Total Shoulder Arthroplasty Influence the Required Deltoid Force and Resultant Joint Load. *Clin Orthop Relat Res* 2015;473:3615-3626.
26. Läderrmann A, Denard PJ, Boileau P, et al. Effect of humeral stem design on humeral position and range of motion in reverse shoulder arthroplasty. *Int Orthop* 2015;39:2205-2213.