



**HAL**  
open science

## Transesophageal HIFU cardiac fibrillation therapy guidance by two perpendicular US images

Bathoul Dahman, Jean-Louis Dillenseger

► **To cite this version:**

Bathoul Dahman, Jean-Louis Dillenseger. Transesophageal HIFU cardiac fibrillation therapy guidance by two perpendicular US images. *Surgetica* 2019, Jun 2019, Rennes, France. hal-03469752

**HAL Id: hal-03469752**

**<https://hal.science/hal-03469752>**

Submitted on 7 Dec 2021

**HAL** is a multi-disciplinary open access archive for the deposit and dissemination of scientific research documents, whether they are published or not. The documents may come from teaching and research institutions in France or abroad, or from public or private research centers.

L'archive ouverte pluridisciplinaire **HAL**, est destinée au dépôt et à la diffusion de documents scientifiques de niveau recherche, publiés ou non, émanant des établissements d'enseignement et de recherche français ou étrangers, des laboratoires publics ou privés.

# Transesophageal HIFU cardiac fibrillation therapy guidance by two perpendicular US images

**Bathoul DAHMAN and Jean-Louis DILLESEGER**

Univ Rennes, Inserm, LTSI - UMR 1099, F-35000 Rennes, France

Tel : +33 (0)2 23 23 62 20

Contact: batoul.dahman@univ-rennes1.fr

In this paper, we will present a registration technique to localize the pose of two perpendicular ultrasound image in the preoperative CT volume for the guidance of a transesophageal HIFU cardiac fibrillation therapy.

## 1 Introduction

During the last years, cardiac patients with arrhythmia (or irregular heart beat) have been treated using ablation therapies such as Radio Frequency (RF). High-intensity focused ultrasound (HIFU) energy can be used to create thermal lesions in deep tissues without damaging the tissues in the propagation path. Transesophageal HIFU cardiac fibrillation therapy is a mini-invasive treatment that places the HIFU transducer close to the ablation zone by navigating inside the esophagus, the probe navigation and transducer positioning is carry out using an embedded ultrasound (US) imaging system [1].

As any mini-invasive procedure, first a therapy planning (the ablation path) is defined on high-resolution anatomical preoperative 3D imaging (CT/MRI). The goal of this work is to propose a therapy guidance system by the registration of the intraoperative 2D-US images to the preoperative volume.

In a previous study, the registration of one 2D US image perpendicular to the esophagus axis to the preoperative 3D-CT was proposed with the hypothesis of some strong anatomical constraints [2].

A new HIFU probe with 2 perpendicular 2D US imaging planes is now under study. We propose to integrate the information of these new imaging planes in the registration scheme to relieve the anatomical constraints and gain localization accuracy.

## 2 Two 2D-US/3D-CT image-based Registration

As input we have a 3D-CT and two perpendicular US images acquired on the HIFU probe. Because the US imaging tool is ECG gated, we consider only the US images at the same cardiac phase as the CT and so only a 3D rigid transform with six degrees of freedom has to be estimated. We have also an initial rough estimation of the pose of the probe inside the 3D-CT (e.g. estimated by the method described in [2]). From this initial pose, we performed the following two 2D/3D (two perpendicular slices/volume) image-based registration approach to refine the estimation of the transesophageal probe pose. This approach is characterized by:

### 1) Slice extraction :

For a specific probe pose, the 3D transform allows us to define the US imaging referential system  $(O_1, x_i, y_i, z_1)$ , in which the 2 perpendicular planes,  $x_i-y_i$  and  $y_i-z_i$  represent the US perpendicular slices. The CT volume is then sampled along these 2 planes to provide the information in the same spatial context (same size and spatial location) as the US images;

### 2) similarity metric :

We used Mutual Information to compare the information of the US images and the corresponding information extracted from the CT data. The global similarity will be the sum of the similarity measures between the two sets of slices;

### 3) Optimizer :

We used gradient descent to estimate the pose which maximize the global similarity.

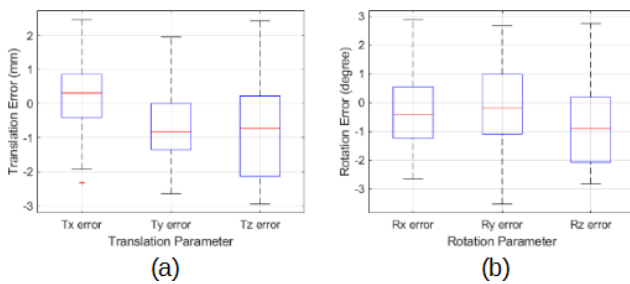
## 3 Results

A feasibility study has been conducted on a patient with fibrillation CT dataset, obtained from Louis Pradel Uni-

versity Hospital in Lyon, France. Because the HIFU probe with the 2 perpendicular US imaging planes is still under development. We validate our method on simulated US data. For this, we defined an initial pose (the ground truth-GT) inside the CT volume. From this pose we extracted two perpendicular slices from the CT and simulated the corresponding US slices with the method described in [3]. Then, we randomly produced 55 initial poses in a range of  $\pm 5$  mm on translation and  $\pm 5^\circ$  in rotation around the GT pose and performed the registration. The accuracy of the registration is estimated through (1) transformation parameter estimation errors; and, (2) Target Registration Error (TRE).

### 3.1 Transformation estimation error

The transformation parameter errors are the differences for each 6 parameters of the transformation between the estimated pose of each trial and GT. Figure 1 shows the boxplot of these errors in (a) translation expressed in mm, and (b) rotation expressed in degree. We can see the median errors are less than 0.7 mm for translation and 0.9 degree for rotation.



**Figure 1:** Boxplot corresponding to the estimation error. (a) in terms of translation parameters. (b) in terms of rotation parameters.

### 3.2 Target Registration Error (TRE)

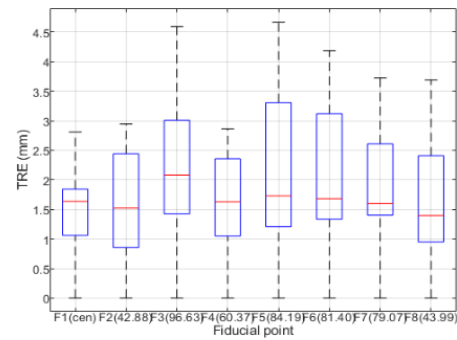
The validation can be done by estimating the registration errors on some specific feature points. To quantify the error, we defined eight specific feature points (or landmarks)  $P_j$  in the two 2D-US fixed images, and we used the two transformations matrices  $T_{Est}$  and  $T_{GT}$  to project these points in the 3D-CT volume.

$$TRE(P_j) = \|T_{GT}P_j - T_{Est}P_j\|$$

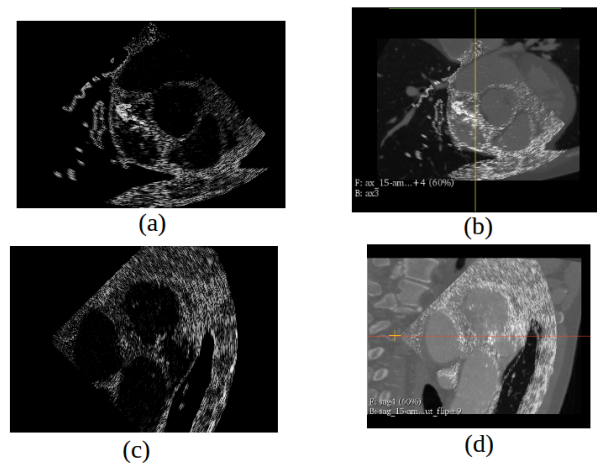
Figure 2 shows the boxplot of the TREs for all the 8 fiducial points. Quantitative results show a mean TRE of 1.76 mm for the overall set of fiducial points.

### 3.3 Visual validation

Figure 3 shows the simulated US images (a and c) and their superimposition to the estimated corresponding reformed CT slice (b and d). The visual examination of these two figures shows a good alignment.



**Figure 2:** Box plots of the Target Registration Error (TRE). The boxplots are ordered from left to right according to the distance of the fiducial points to  $O_i$ .



**Figure 3:** Visualization result (a) image US 1, (b) resulted CT slice 1, (c) image US 2, (d) resulted CT slice 2.

## 4 Conclusion

We performed rigid registration of two 2D planar echocardiography images with a cardiac CT volume. Results indicate promising accuracy of the proposed technique. Our future work aims at include phantom and real-patients data to evaluate the contribution of the registration scheme for the therapy guidance.

## Acknowledgments

This work was part of the CHORUS (ANR-17-CE19-0017) project which have been supported by the French National Research Agency (ANR).

## References

- [1] F. Bessi re et al. (2016), Ultrasound-Guided Transesophageal High-Intensity Focused Ultrasound Cardiac Ablation in a Beating Heart: A Pilot Feasibility Study in Pigs, *Ultrasound Med. Biol.*, 42(8), pp. 1848–1861.

- [2] Z. Sandoval et al. (2018), Transesophageal 2D Ultrasound to 3D Computed Tomography registration for the guidance of a cardiac arrhythmia therapy, *Phys. Med. Biol.*, 463(15), p. 155007.
- [3] J.-L. Dillenseger et al. (2009), Fast simulation of ultrasound images from a CT volume, *Comput. Biol. Med.*, 39(2), pp. 180–186.