

IRSNINSTITUT
DE RADIOPROTECTION
ET DE SÛRETÉ NUCLÉAIRE*Faire avancer la sûreté nucléaire*

Preclinical study of Chronic radiation cystitis and cell therapy treatment

Clément Brossard* ^{1,2}, Anne-Charlotte Lefranc^{1,2}, Morgane Dos Santos ^{1,3},
Mohamedamine Benadjaoud¹, Christelle Demarquay^{1,2}, Valérie Buard^{1,2}, Georges
Tarlet^{1,2}, Claire Squiban^{1,2}, Christine Linard^{1,2}, Noëlle Mathieu^{1,2}, Romain Granger⁴,
Amandine Sache⁴, Delphine Denais Lalieue⁴, Jean-Marc Simon⁵, Marc Benderitter¹, Fabien
Milliat^{1,2}, Alain Chapel^{1,2}

¹Service de recherche en radiobiologie et en médecine régénérative (SERAMED),

²Laboratoire de Radiobiologie des expositions médicales (LRMED), ³Laboratoire de radiobiologie des expositions accidentelles (LRAcc), ⁴Service de recherche sur les effets biologiques et sanitaires des rayonnements ionisants (SESANE), Groupe de support à la recherche et à l'éthique animale (GSEA), Institut de Radioprotection et de Sûreté Nucléaire, Fontenay-aux-roses, ⁵Département de radio-oncologie, Hôpital universitaire de la Pitié-Salpêtrière, Paris, France

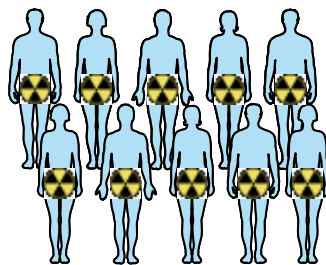
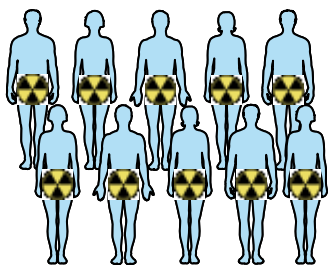
W W W . S F R O 2 0 2 0 . C O M
SFRO 2020
7-10 OCTOBRE
ESPACE GRANDE ARCHE • PARIS LA DÉFENSE

Address of the author:

Clement.brossard@irsn.fr

Acute and chronic radiation cystitis

Population concerned



**Pelvic
Radiotherapy**



Days- months



6 months - 20 years

Acute complications
40% of patients

Acute radiation cystitis

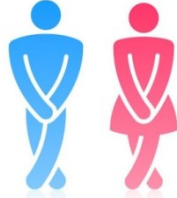Chronic complications
5 - 10 % of patients

Chronic radiation cystitis

Mithal et al., 1993
Rigaud et al., 2004

Symptoms and treatment of chronic radiation cystitis

Incontinence



Pain



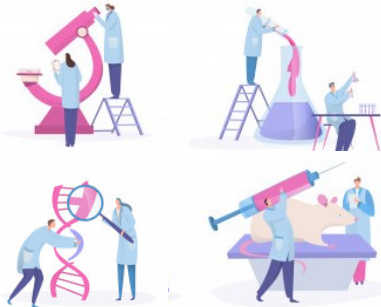
Hematuria



Decrease the quality of life

No curative treatment
Only symptomatic treatments (hyperbaric oxygen therapy, oral and intra-vesical agents)

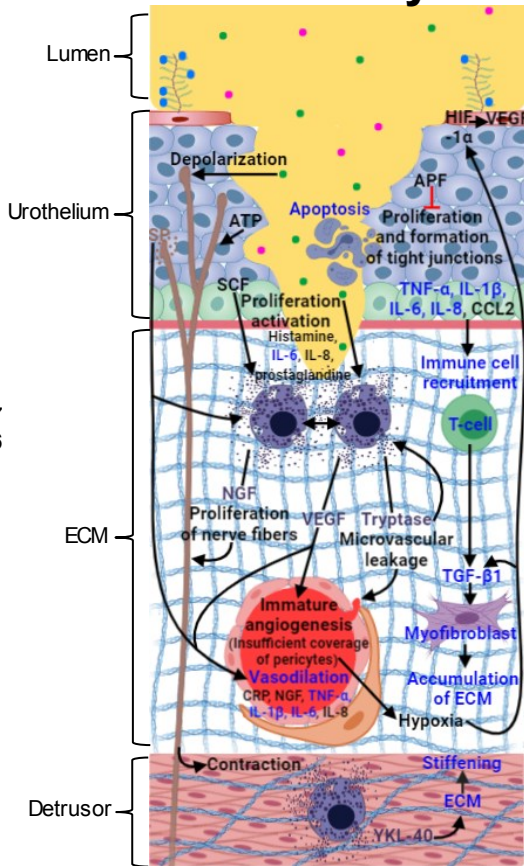
Transient effects that may induce serious complications



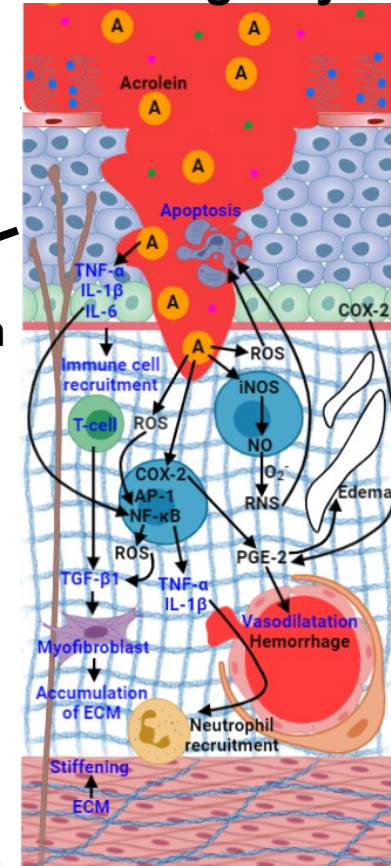
Few studies on chronic radiation cystitis
Little known molecular mechanisms
Preclinical research to develop innovative treatments

Similar pathology

Interstitial cystitis



Hemorrhagic cystitis



Urothelium dysfunction
Inflammation
Fibrosis
Ad-Mesenchymal Stem Cells (MSCs)

↑ Tissue regeneration

↓ Inflammation

↓ Fibrosis

Hypothesis: MSCs reduced inflammation, fibrosis and increase tissue regeneration in CRC?

Choi et al., 2018
Fry et al., 2018
He and Walls, 1997
Homma et al., 2016
Jiang et al., 2013;
Kim et al., 2016
Sant et al., 2007
Song et al., 2015
Tyagi et al., 2018

Baygan et al., 2007
Dantas et al., 2010
De Vries and Freiha, 1990
Hu et al., 2003
Korkmaz et al., 2007
Lee et al., 2003

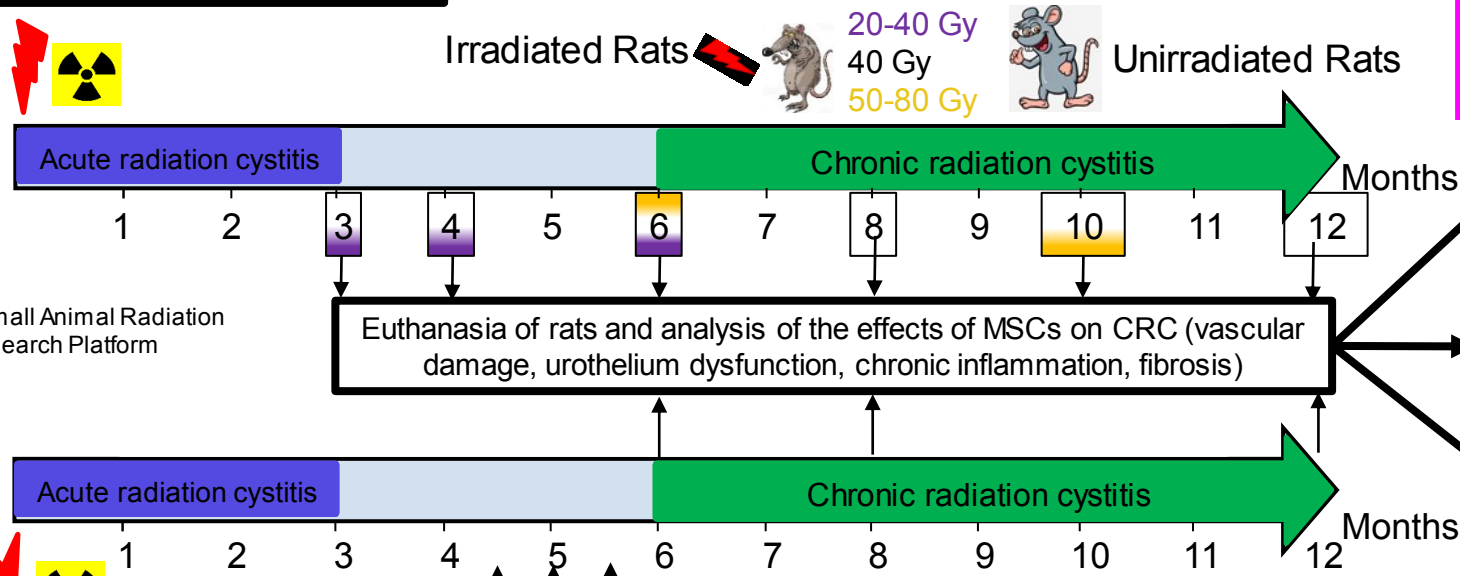
Pre clinical Study:
Song et al., 2015 (IC)
Kim et al., 2016 (IC)

Clinical study:
Cesaro et al., 2003 (HC)
Hassan et al., 2011 (HC)
Ringdén et al., 2007 (HC)

age: 12 w weeks
 protocol ethics committee: P17-09

Local bladder irradiation in rats with SARRP*

Experimental conditions: 5 rats for each condition and for each euthanasia time.



* Small Animal Radiation Research Platform

HES
Red Sirius
immunolabelling

Tissue

Physiological:
Metabolic cage once a month for 24 hours

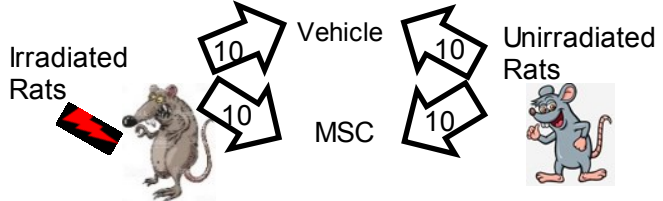
Transcriptomics

RT-qPCR
(TLDA: Taqman low density array)

Local bladder irradiation in rats with SARRP*

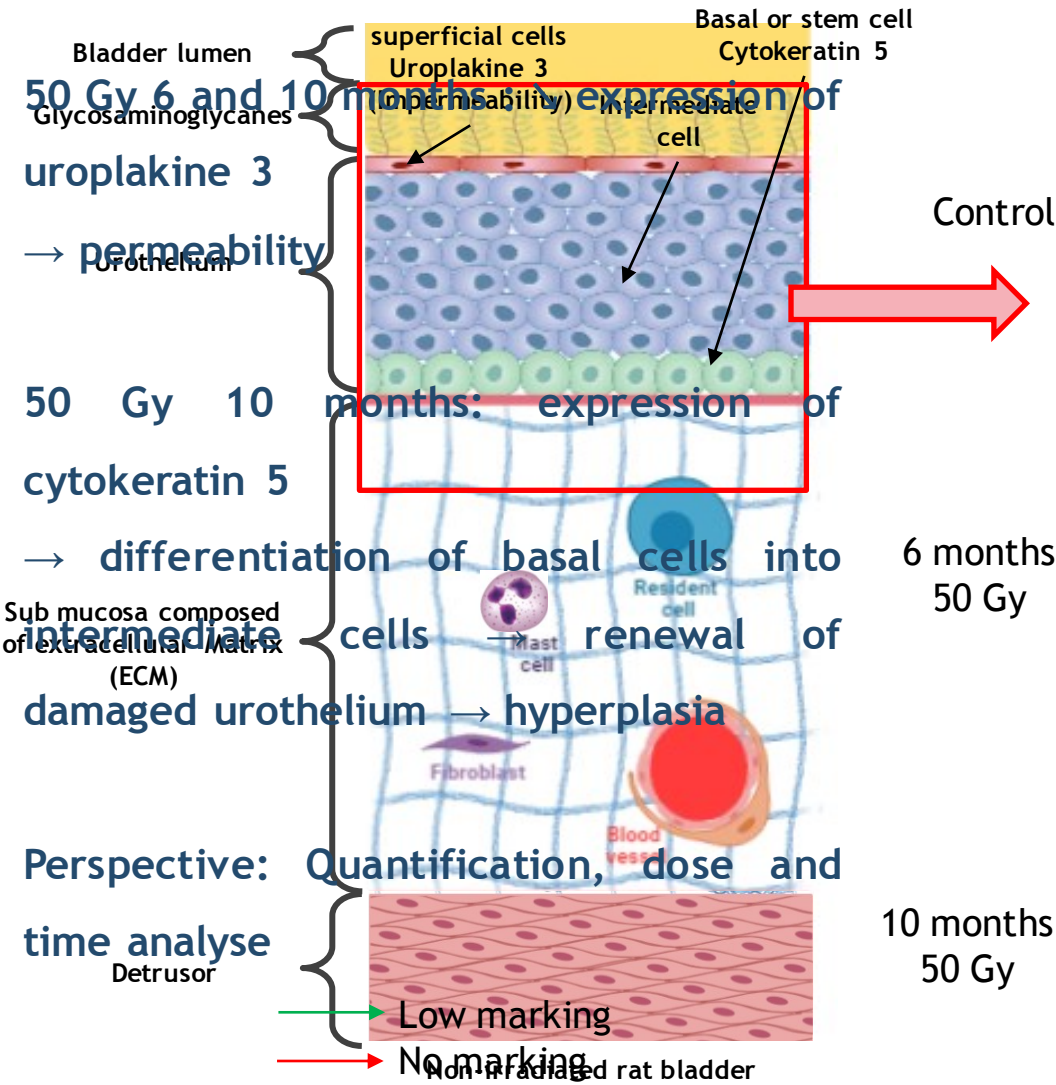
3 Injections of 5 million MSCs intravenously

Experimental conditions: 10 rats for each condition and for each euthanasia time.
Experimental conditions for each time of euthanasia

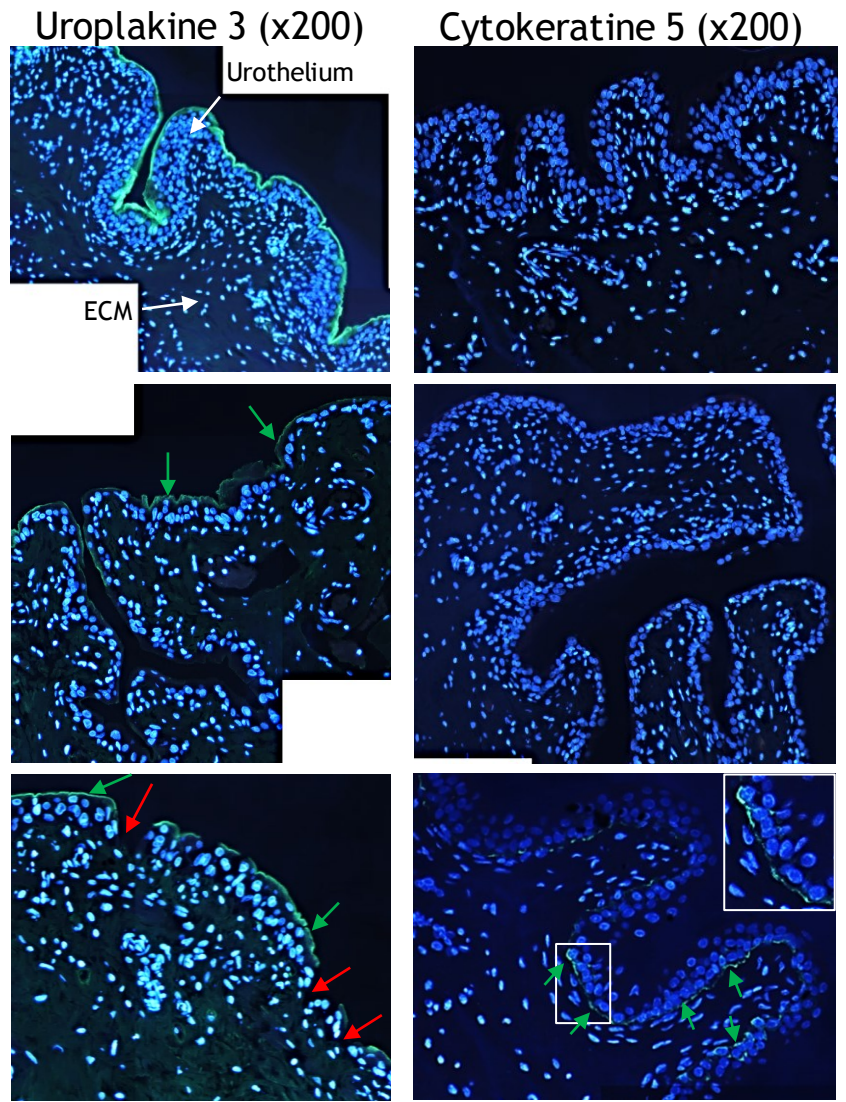


age: 12 w weeks
 protocol ethics committee: P19-09

Urothelium dysfunction

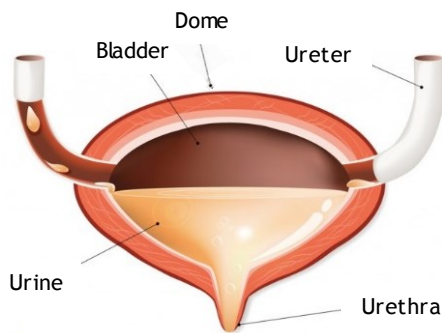
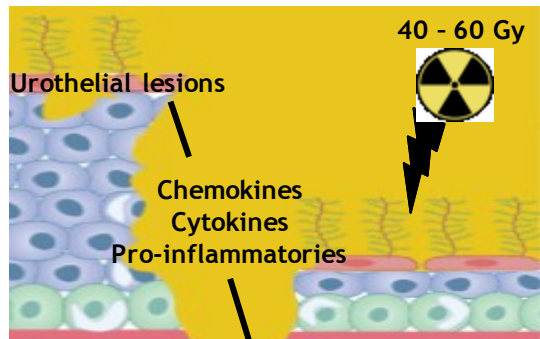


Urothelial differentiation markers





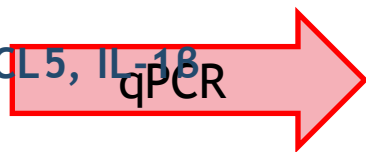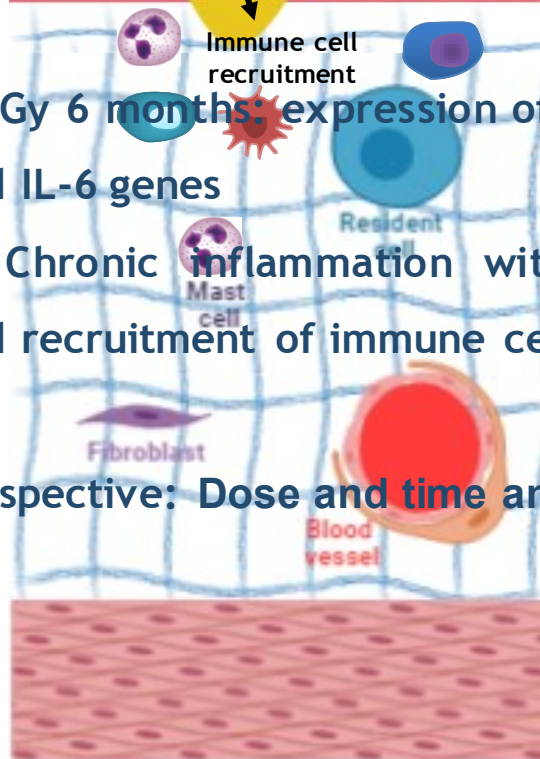Inflammation at 6 months post-irradiation



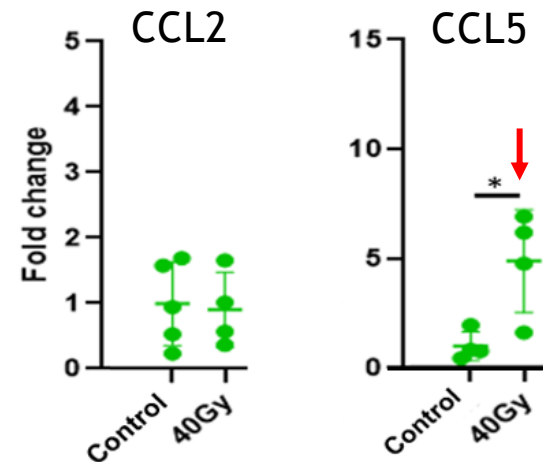
40 Gy 6 months: expression of CCL5, IL-18 and IL-6 genes

→ Chronic inflammation with activation and recruitment of immune cells

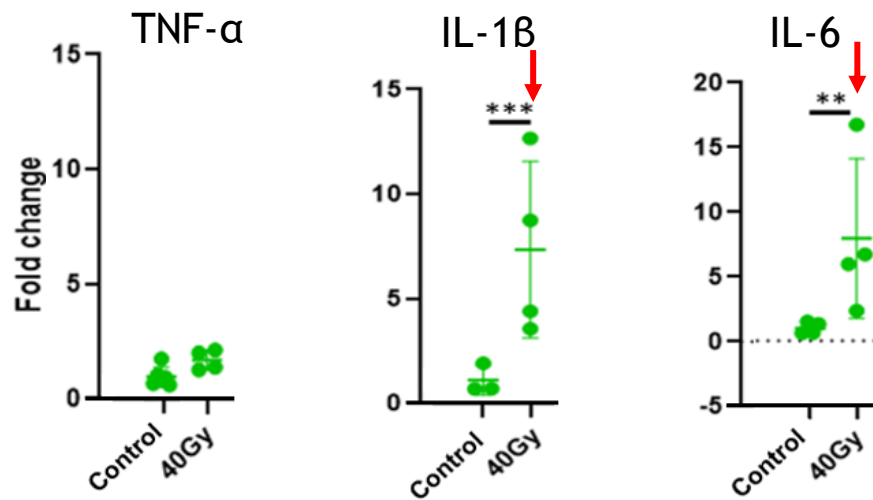
Perspective: Dose and time analyse



Chimiokines



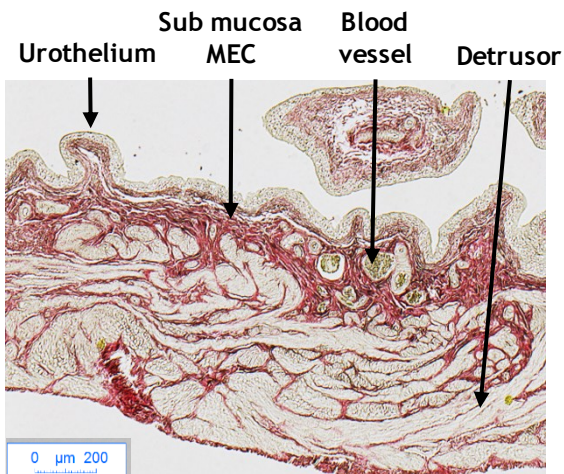
Pro-inflammatory cytokines



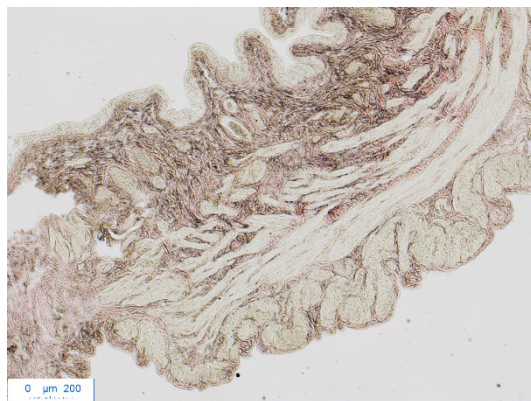


Fibrosis at 6 months post-irradiation

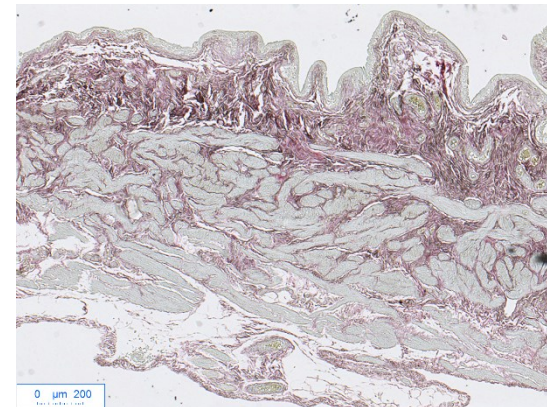
Red sirius (X50)



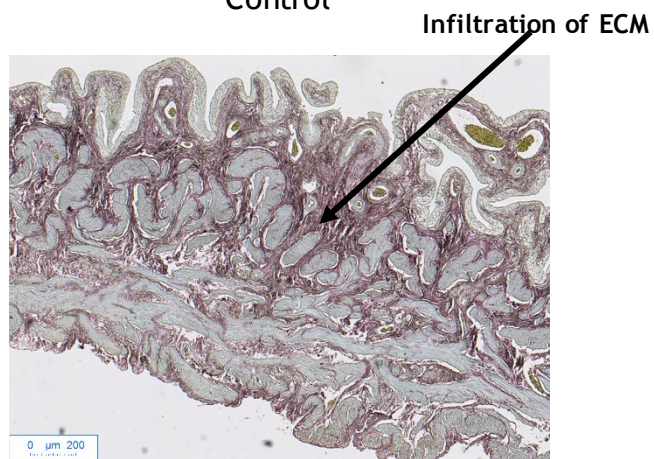
Control



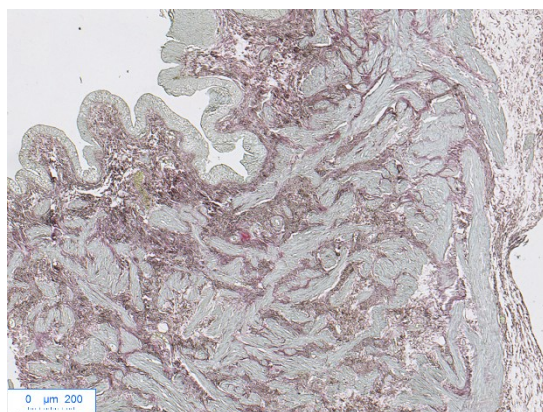
40 Gy



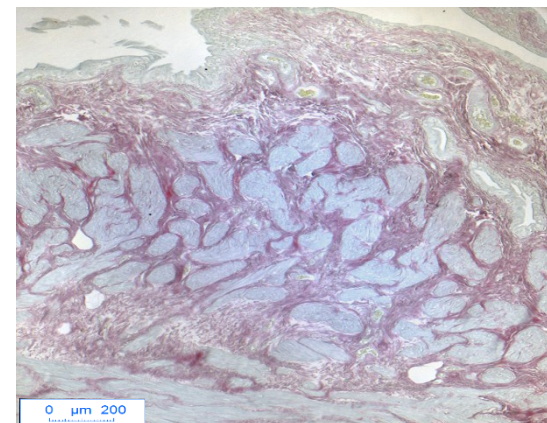
50 Gy



60 Gy



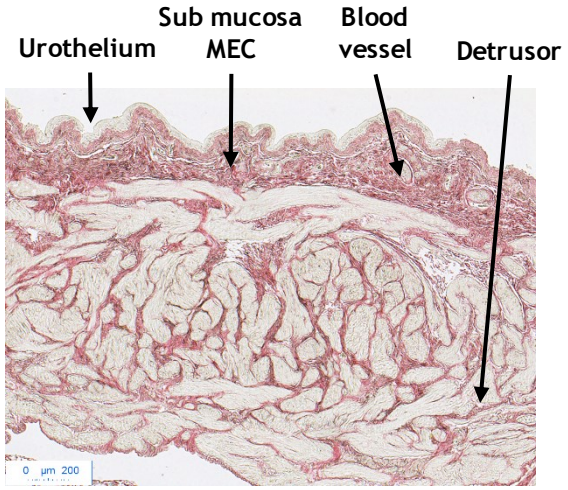
70 Gy



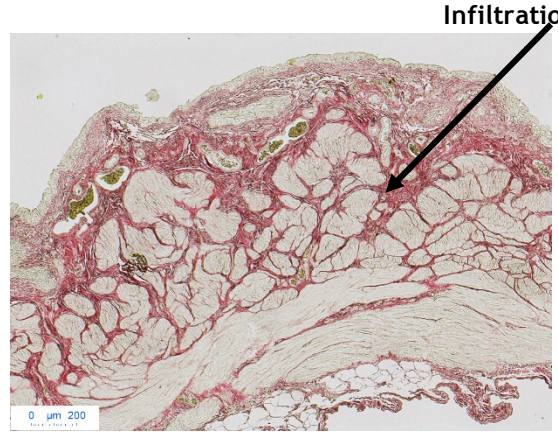
80 Gy

Fibrosis at 10 months post-irradiation

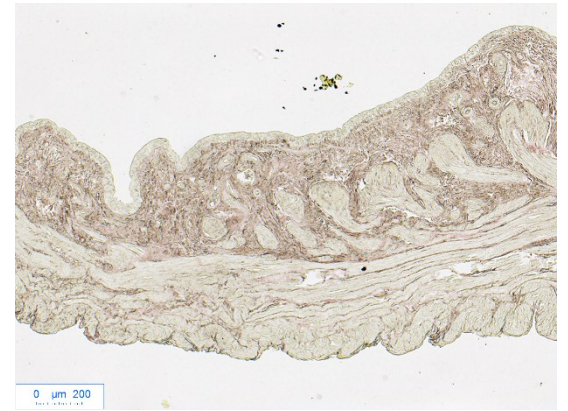
Red sirius (X50)



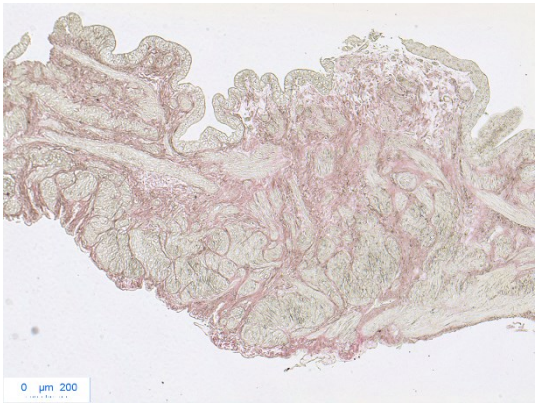
Control



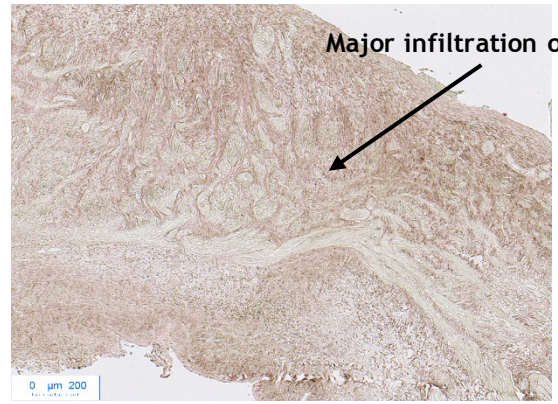
40 Gy



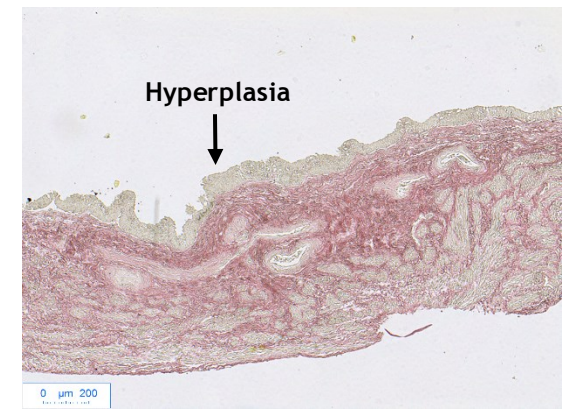
50 Gy



60 Gy



70 Gy

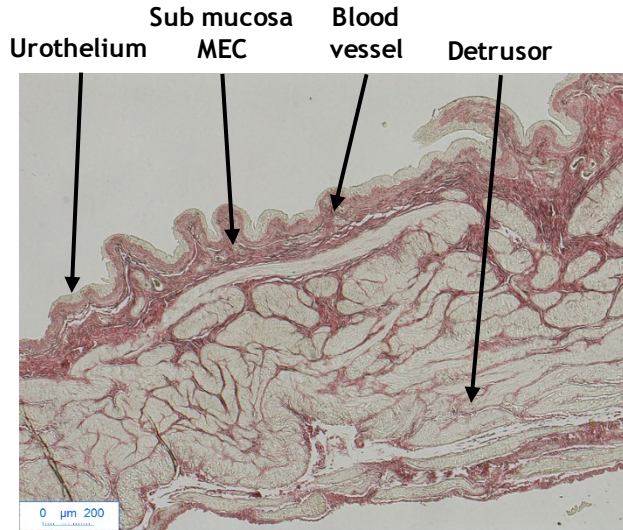


80 Gy

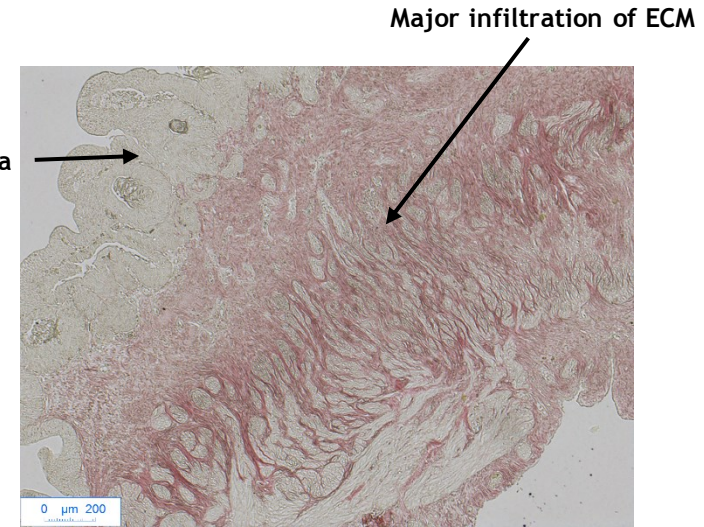


Fibrosis at 12 and 15 months post-irradiation for 40 Gy

Red sirius (X50)



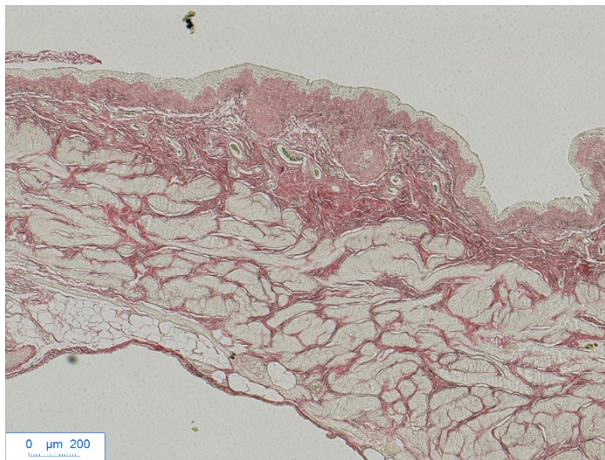
Control



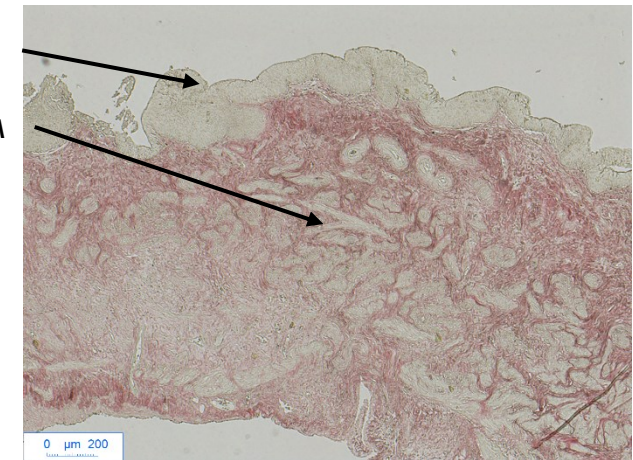
40 Gy

12 months

Increase fibrosis with dose and time



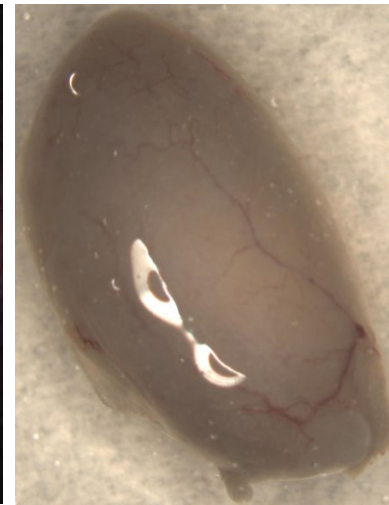
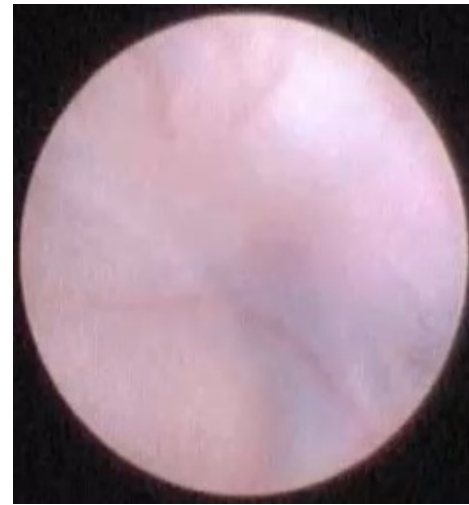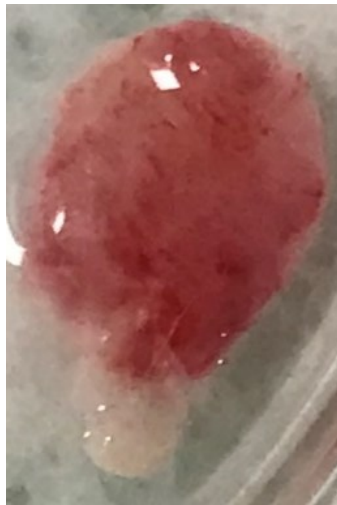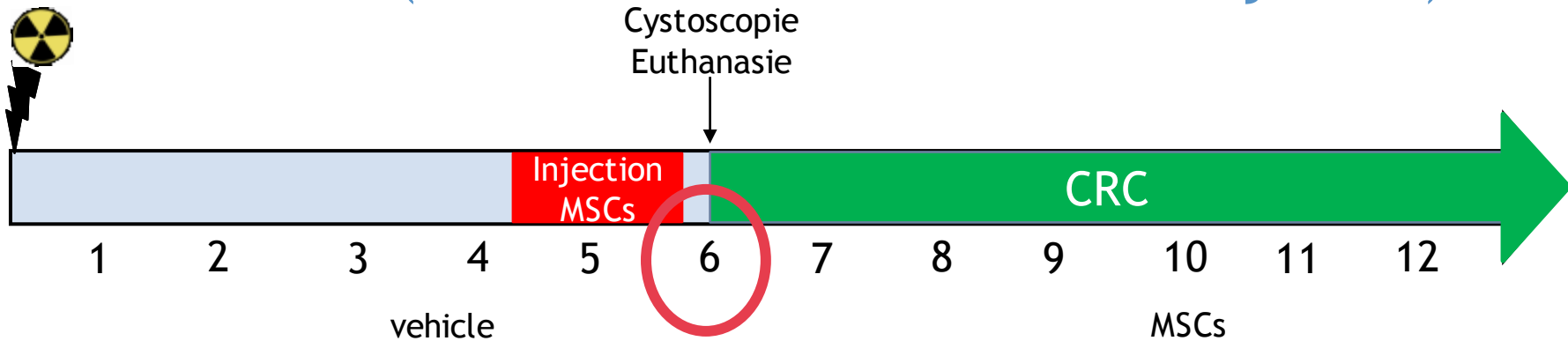
Control



40 Gy

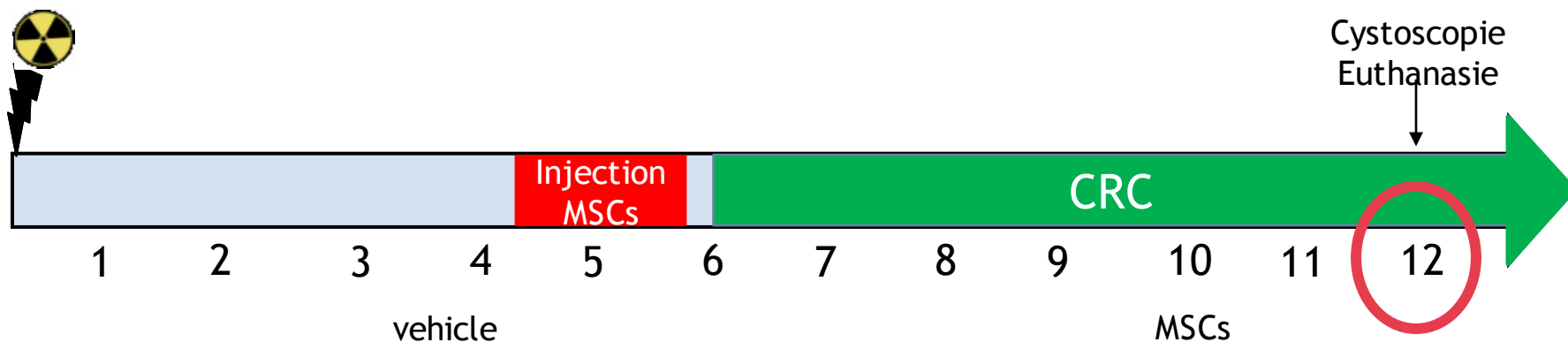
15 months

Visualization of the bladder wall by cystoscopy at 6 months post-irradiation (1.5 months after the first MSC injection)

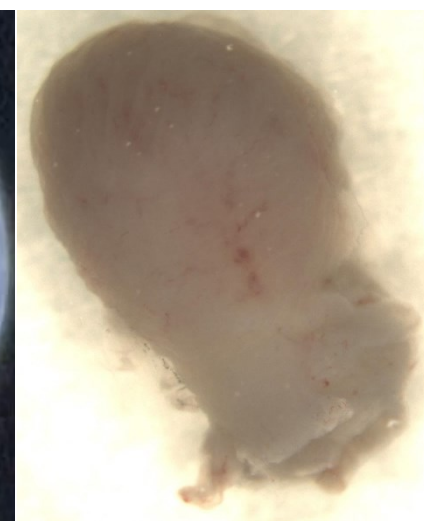
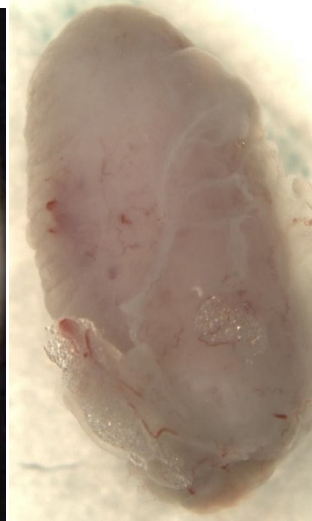
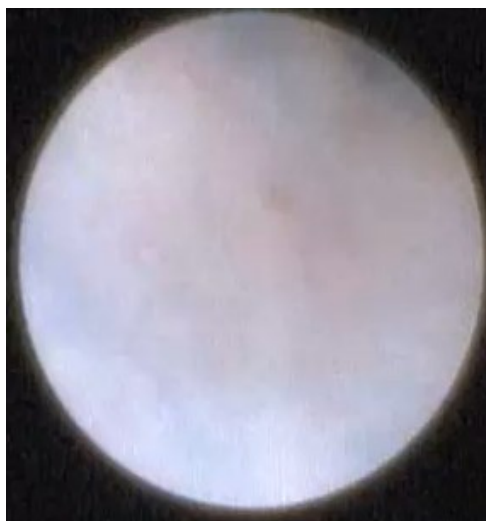

MSCs: ∨ vascular damage caused by irradiation

Visualization of the bladder wall by cystoscopy at 12 months post-irradiation (7.5 months after the first MSC injection)



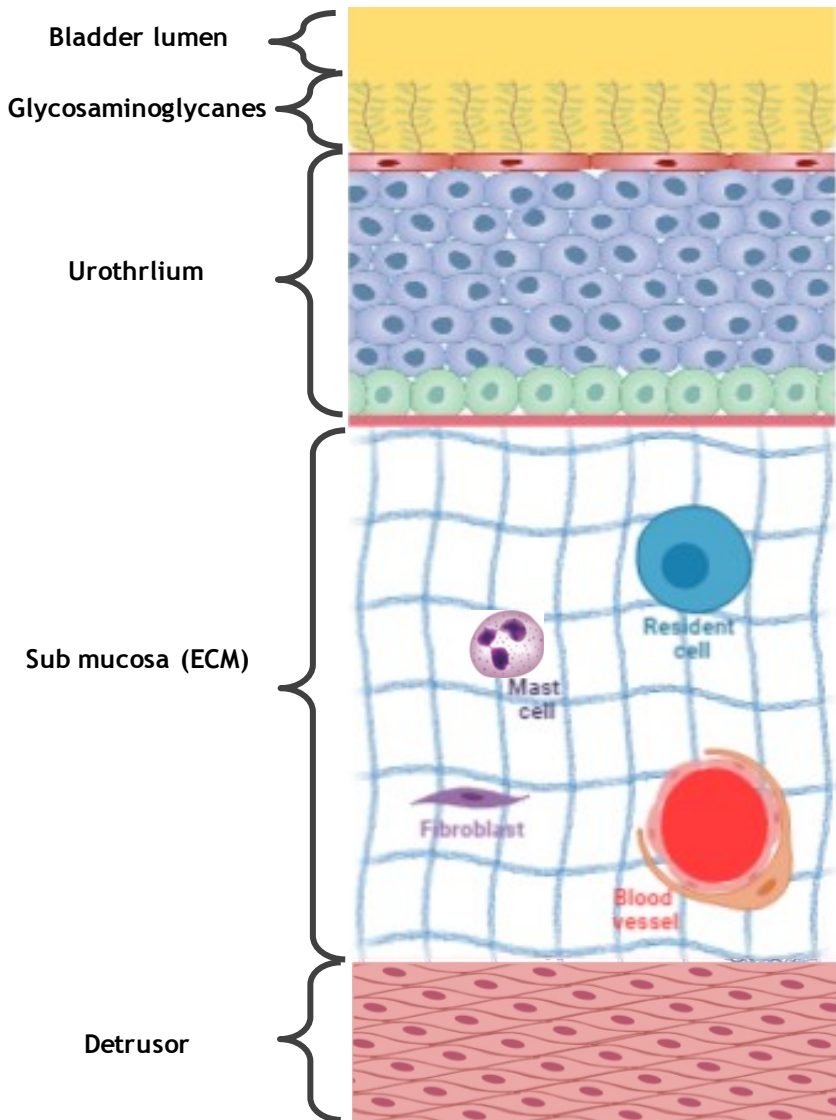
Irradiated at 40 Gy



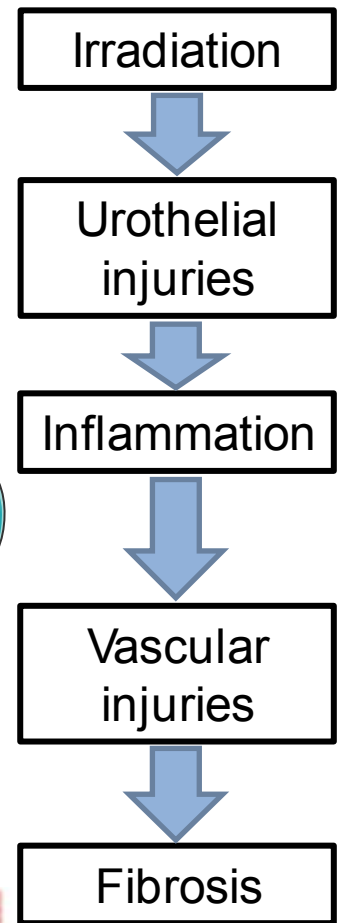
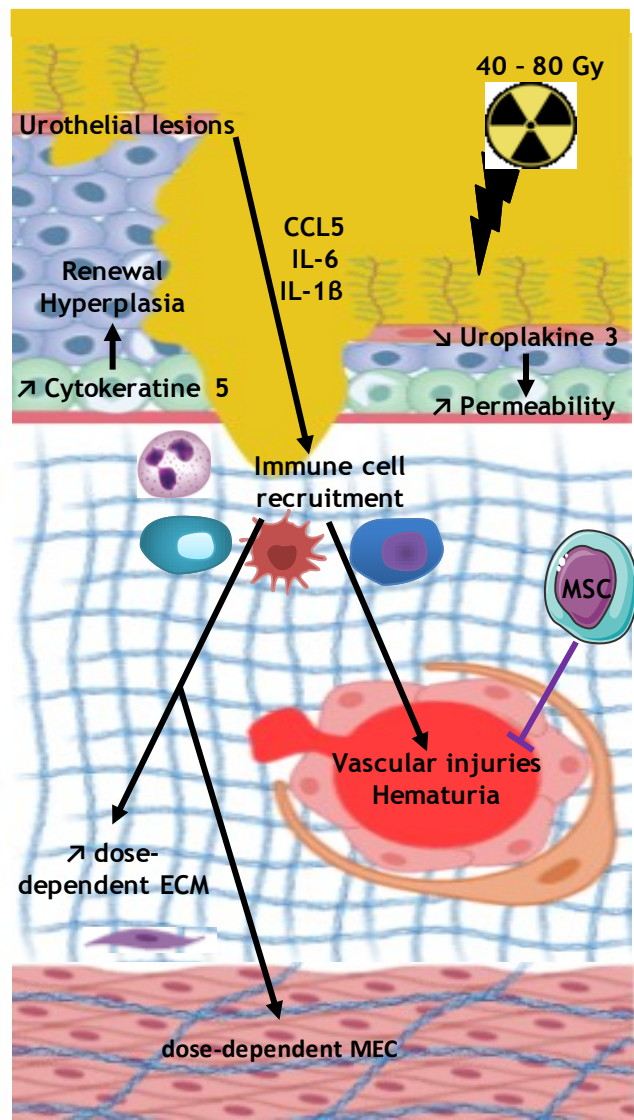
MSCs: ↘ over time in vascular damage caused by irradiation

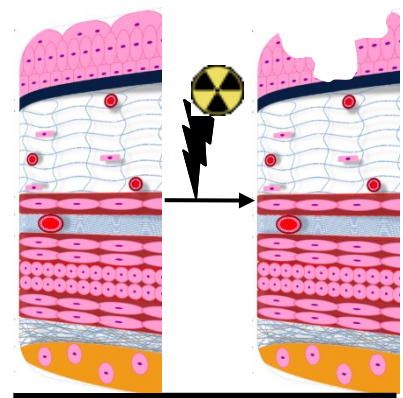


Non-irradiated rat bladder



Chronic radiation cystitis in rats at 6-12 months post-irradiation

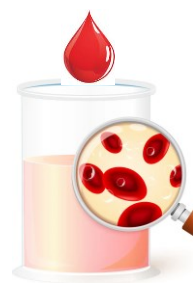



Urothelium dysfunction

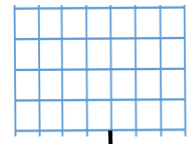


Chronic inflammation




Vascular injuries

ECM without fibrosis



ECM with fibrosis



Fibrosis

Model Characterization :

- Quantification
- Analyze different doses
- Analyze longer time

Effect of MSC treatment:

- Transcriptomics studies: Inflammation
- Tissue studies: Urothelium dysfunction, fibrosis
- Physiological studies: Vascular injuries

Merci pour votre attention

9 Doctors
2 post-doc
4 technicians
6 PhD students

Member-of the GSEA: Animal monitoring and assistance in experimentation
A. Benadjaoud: Biostatistics
Mr. Dos Santos: Radiation to rats

C. Demarquay
MSC Culture

V. Buard
Microscopy and
immunolabeling

F. Milliat
Head of laboratory

G. Tarlet
PCR

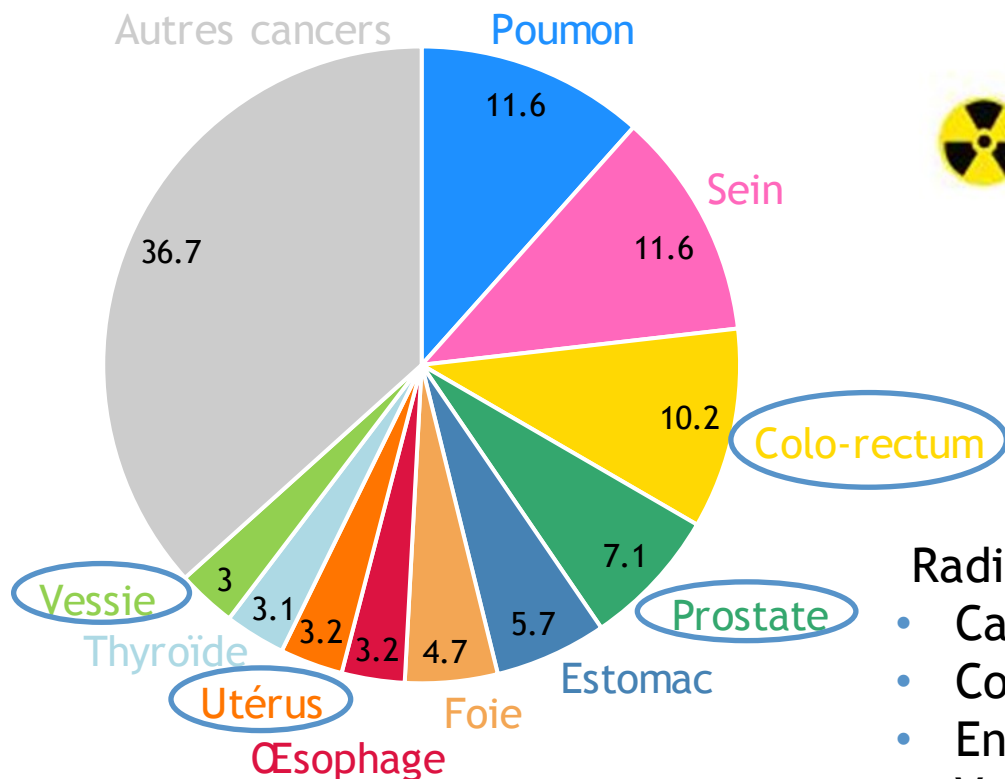
C. Brossard

N. Mathieu
Cytogenetics

C. Linard
Immunohistological
and inflammation
studies

Cancers et radiothérapie

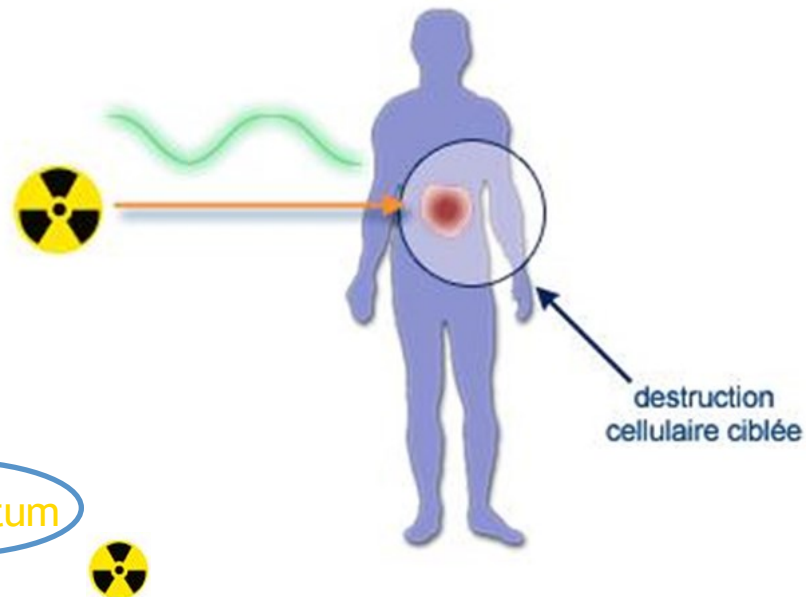
Fréquence des nouveaux cas de cancer estimé en 2018



Total : 18 078 957 personnes

WHO Global Cancer Observatory

Principe de la radiothérapie



Radiothérapie :

- Canal anal
- Col de l'utérus
- Endomètre
- Vulve
- Prostate

Organe à risque :
Vessie

Thérapie cellulaire par les cellules souches mésenchymateuses (CSM) des cystites et maladies pelviennes radio-induites

Maladies pelviennes radio-induites

Usunier et al., 2014
Linard et al., 2013

CSM

↓ Inflammation

↓ Fibrose

↑ Régénération tissulaire

Cystite interstitielle

Kim et al., 2016
Song et al., 2015

CSM

↓ Inflammation

↓ Fibrose

↑ Régénération tissulaire

Cystite hémorragique

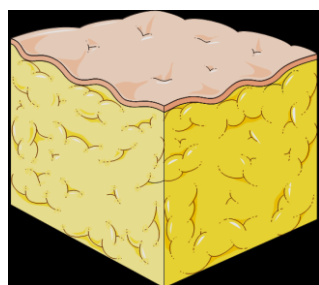
Lee et al., 2003
Baygan et al., 2017

CSM

↓ Hémorragie

↑ Régénération tissulaire

Injection des cellules souches mésenchymateuses

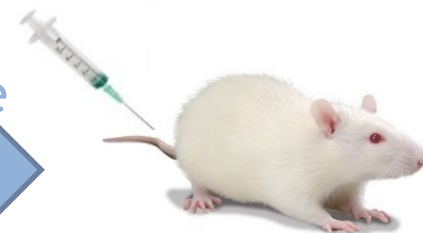

Tissu
adipeux

Isolement
Purification
Culture



Injection par
intraveineuse



3 injections espacées de 2
semaines
5 millions de CSMs par injection

Grade de la cystite radique

Tableau II. Cystite radique : critères tardifs de toxicité génito-urinaire RTOG/EORTC.

Grade 0 asymptomatique

Grade 1

Dysurie : légère

Hématurie : microscopique

Fréquence : / 2 h

Grade 2

Dysurie : modérée

Hématurie : intermittente

Fréquence : / 1 h

Grade 3

Dysurie : sévère

Hématurie : fréquente

chirurgie mineure e.g. coagulation

Fréquence : / 0,5 h

Capacité vésicale : réduction, 150 cc

Grade 4

Hématurie : cystite hémorragique sévère

Capacité vésicale : vessie rétractée (< 100 cc)

Grade of hemorrhagic cystitis

Table 1 | RTOG/EORTC grading of hematuria events

Hematuria morbidity	Grade 1	Grade 2	Grade 3	Grade 4	Grade 5
Acute hemorrhagic radiation cystitis (RTOG scale)	NA	NA	Gross hematuria with or without clot passage	Hematuria requiring transfusion	Death from uncontrolled hematuria
Late hemorrhagic radiation cystitis (RTOG/EORTC scale)	Minor telangiectasia (microscopic hematuria)	Generalized telangiectasia (macroscopic hematuria)	Severe generalized telangiectasia (macroscopic hematuria)	Severe hemorrhagic cystitis	Death from uncontrolled hematuria

Abbreviations: EORTC, European Organisation for Research and Treatment of Cancer; RTOG, Radiation Therapy Oncology Group.

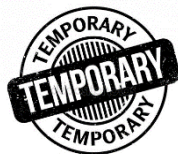Traitement:

Intravesical instillation :

- Aluminium
- Formalin
- Alun
- Pentosan polysulfate

Traitement hyper bar

Smit SG, Heyns CF. [Management of radiation cystitis](#). Nat Rev Urol. 2010 Apr;7(4):206-14. doi: 10.1038/nrurol.2010.23. Epub 2010 Mar 9. Review. PubMed PMID: 20212517.




Treatments :


Oral or parental agents



- Sodium pentosan polysulfate
- Tetrachlorodecaoxide
- Pentoxifylline



 Hematuria

 Low and very short-term effects


Cystoscopy



- Fulguration
- Botulinum toxin



 Hematuria

 Low and very short-term effects

Intravesical installation



- Aluminum salts
- Silver nitrate
- Formalin



 Hematuria

  Pain

No effect after stopping treatment

Treatment :

Hyperbaric oxygen therapy (HBOT)

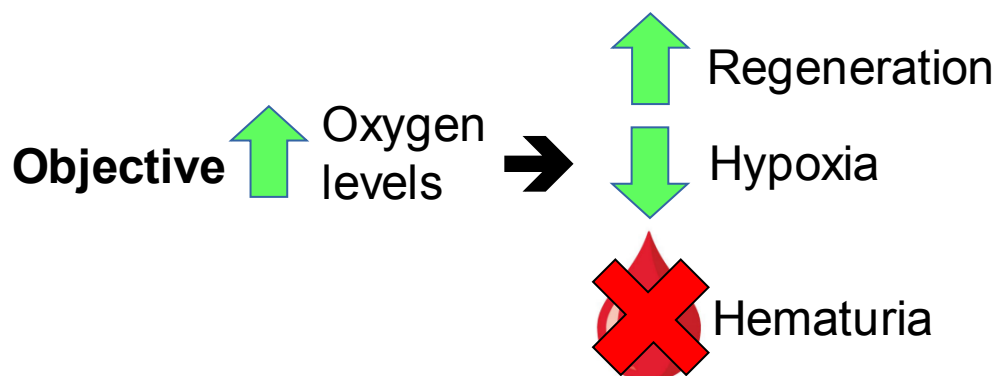






Figure 1 Hyperbaric oxygen chambers
a | Newly delivered hyperbaric chamber prior to installation. b | Hyperbaric oxygen chamber with control panel.

Smit and Heyns, 2010

Disadvantage

-  Long, adequate and rare equipment, patient monitoring
-  Not very effective, effects over a few months, year


30–40 sessions, 100% oxygen,
for 80–90 min, 2 months


75% improvement within 6 months

Need for a relevant model and curative treatments

Rigaud et al., 2010
Orcasson et al., 2019

Objective:

- Creation of a model of chronic radiation cystitis in rats
 - New method of irradiation using SARRP
- ➔ Irradiator for small animals (similar characteristic to clinical models)

SARRP

- Small Animal Radiation Research Platform (SARRP, Xstrahl)
- Single or multi beam(s)
- Combined with scanner imaging and treatment plan software (MuriPlan) => stereotaxy
- 4 available field sizes: **10x10 mm²**, 7x7 mm², 3x3 mm² and Ø 1 mm



Picture of SARRP
Dr M. Dos Santos, LRAcc

Method of irradiation: Local bladder irradiation

muriplan
by **strahl**

Verify (Step 5 of 7)

A) Isodoses

Prescribed dose: 2000 cGy (IsoC)

Show isodose surfaces (3D):

Show isodose lines (2D):

Relative Dose
0 10%
1 20%
2 60%
3 80%
4 95%

Compute Isodoses

B) Compute Dose Volume Histogram Statistics

Current: SARRPDose

Label	Volume (cc)	Mean (cGy)	Min (cGy)	Max (cGy)
1 New	0.206823	2022.79	1792.4	2247.59

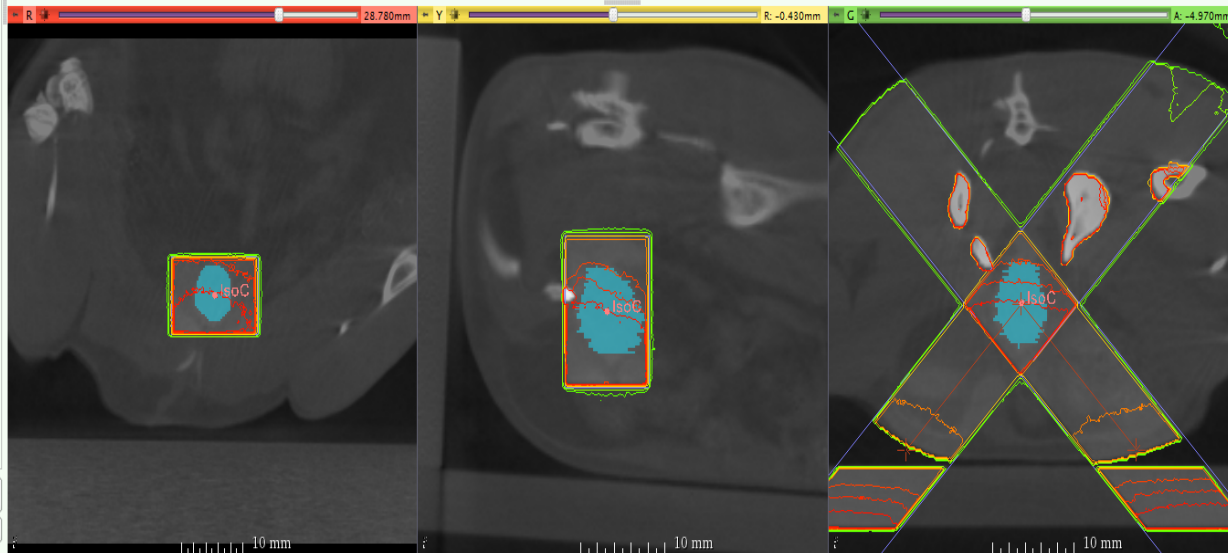
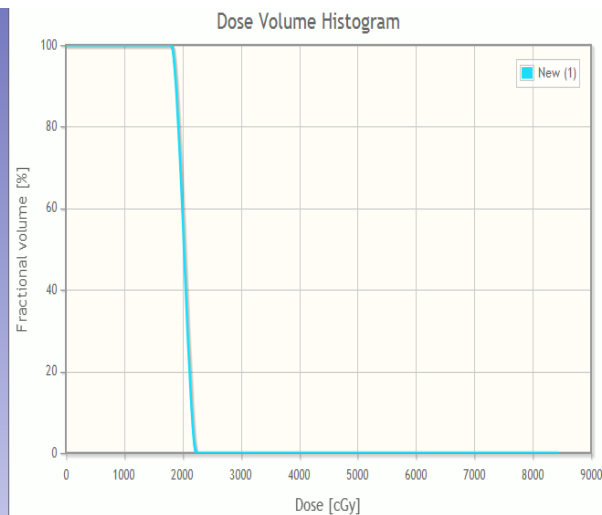
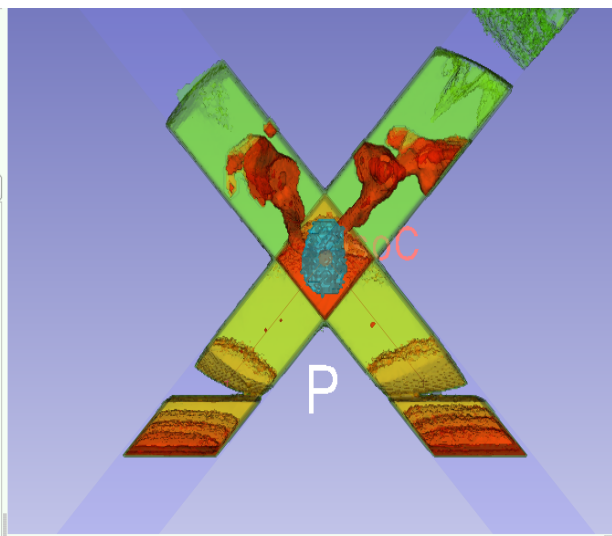
Compute DVH

C) Plan

TPS_2017-09-04_10_17_20

Treatment Planning Execute

Data Probe



- 2 irradiation beams

- Maximized the dose on the bladder and minimized the dose on surrounding tissues

Pre-clinical model of CRC

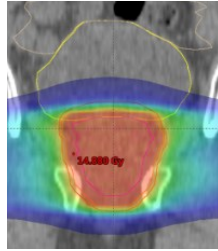
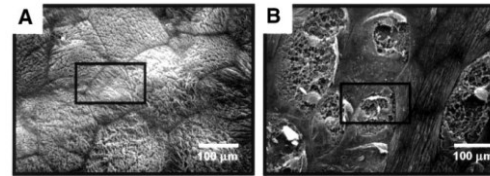


In Rats receiving (irradiation totale vessie)

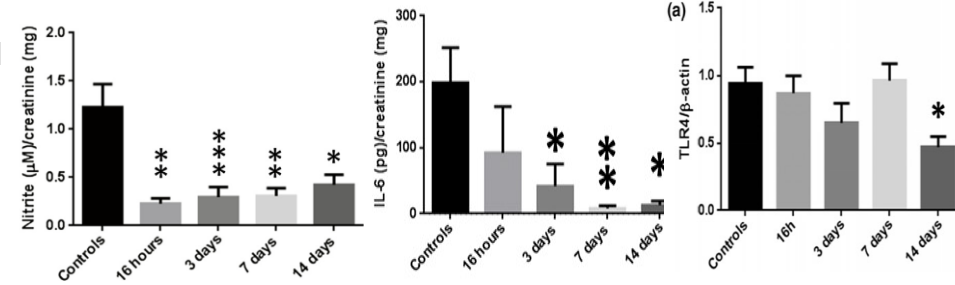
✓ 35 Gy, Urothelium damage 48h (Kanai et Eperly 2002)

✓ 20 Gy killed 16 h to 14 days later (Giglio et al. 2012)

- Bladder irradiation increased the expression of IL-1 and collagen in the bladder, while TLR4 and IL-6 expressions were decreased in the urothelium concomitantly with a decrease in mast cells in the submucosa and urine levels of IL-6 and nitrite.



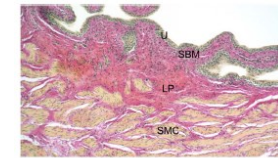
Jurado-Bruggeman et al.; 2017



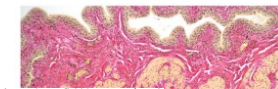
✓ 20 Gy all 29 days (Oscarsson 2017)

- Bladder irradiation increased the expression of 8-OHdG, SOD2, HO-1, NRFα, IL-10, TNF and tended to increase TGF-β

29 days Urothelium, SBM=Submucosa, LP=Lamina Propria, SMC=Smooth Muscle Cell layer

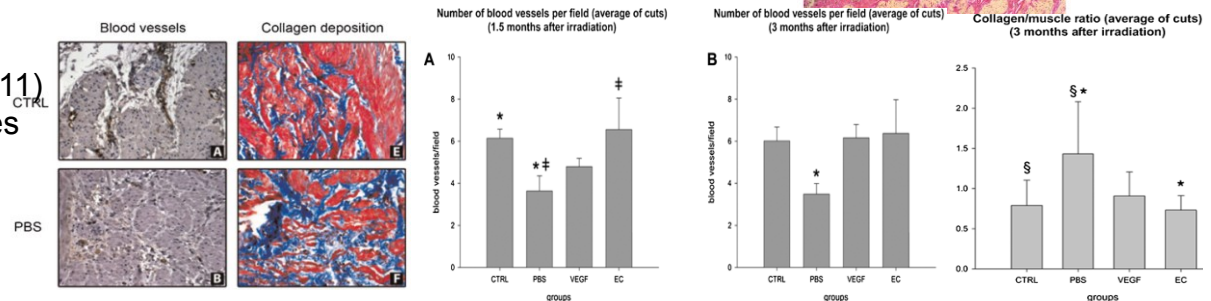


No significant macro or microscopically changes in the urinary bladder could be observed by bladder irradiation



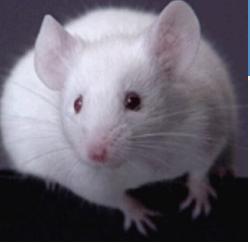✓ 20Gy killed 1,5 and 3 months (Soler 2011)

- 1,5 month vascular abnormalities
- 3 months collagen deposition



✓ 20 Gy all exhibited small and contracted bladders 6 months after treatment (Vale JA 1993)

Pre-clinical model of CRC



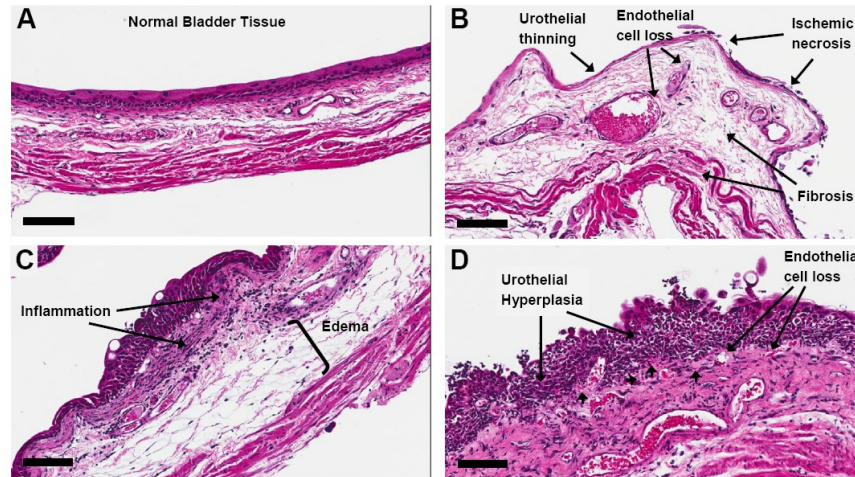
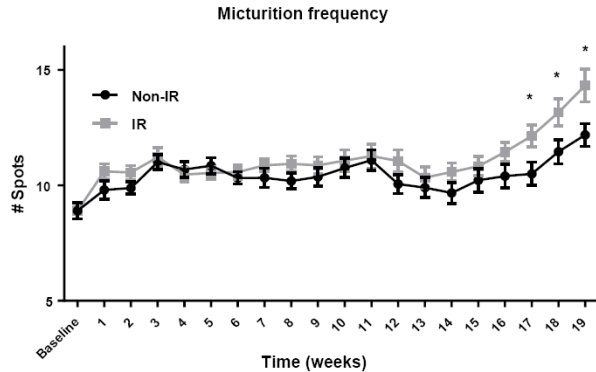
In mice receiving

✓ 15 Gy , 20% developed fibrotic bladders,

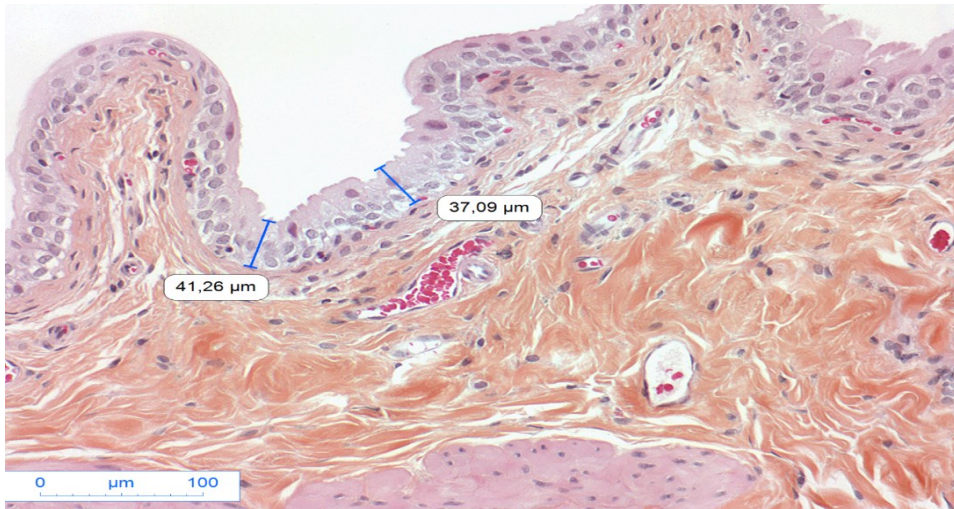✓ 15–20 Gy exhibited increased frequency and decreased bladder volume (Stewart 1991).

✓ 20 Gy SARP 2 faisceaux ((Zwaans et al. 2016)

- Starting at 17 weeks after treatment, micturition frequency was significantly higher
- Pathological changes include fibrosis, inflammation, urothelial thinning, and necrosis.
- At a site of severe insult, we observed telangiectasia, absence of uroplakin-3 and E-cadherin relocalization

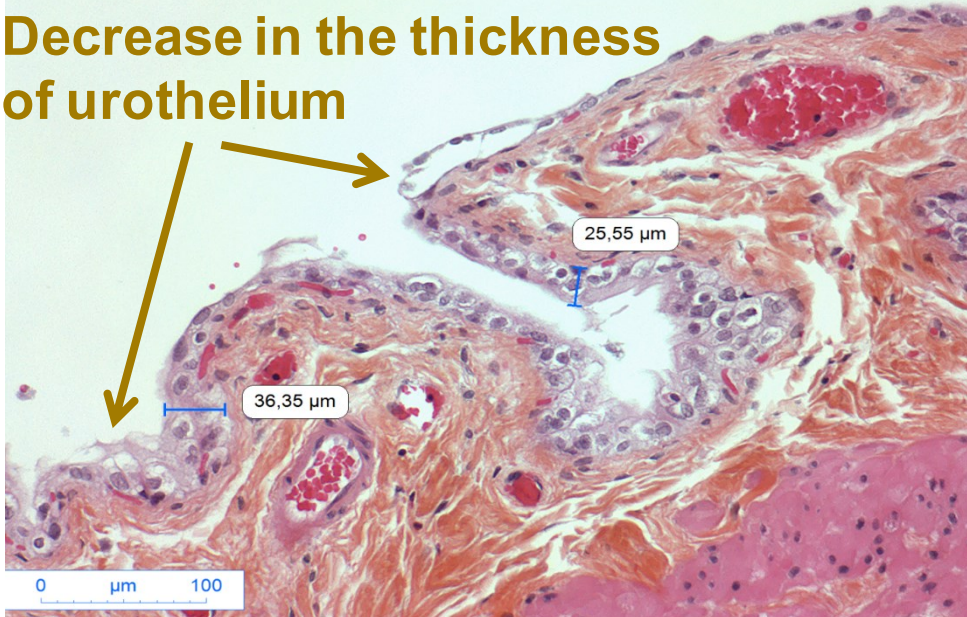


Tissue study: urothelium damages (HES)

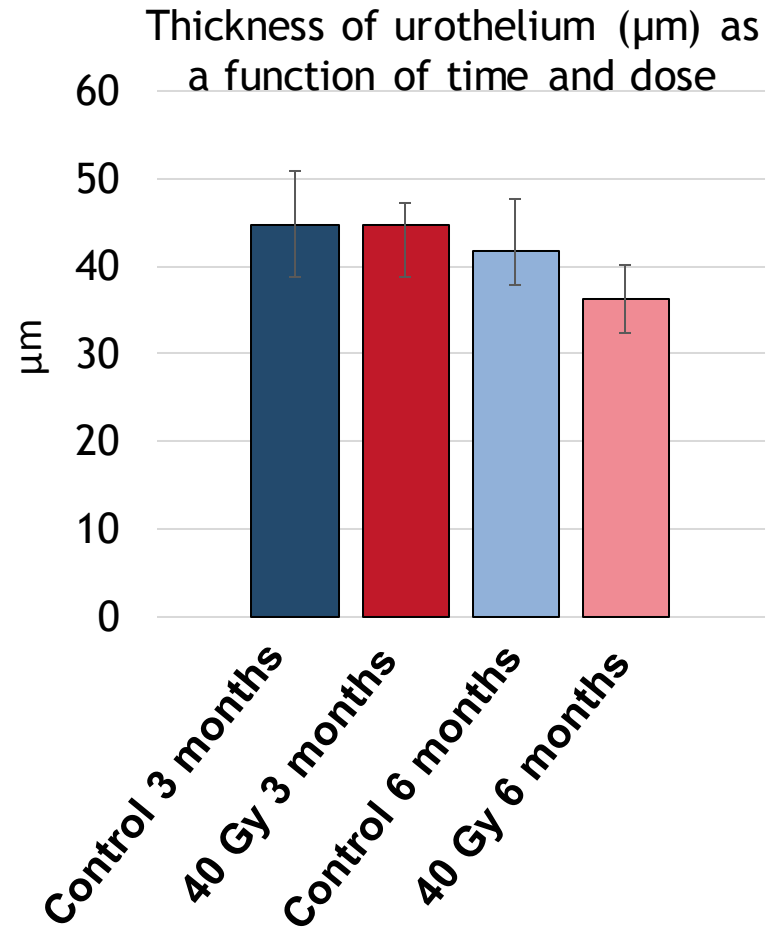


Unirradiated bladder, 6 months, X 200

Decrease in the thickness of urothelium



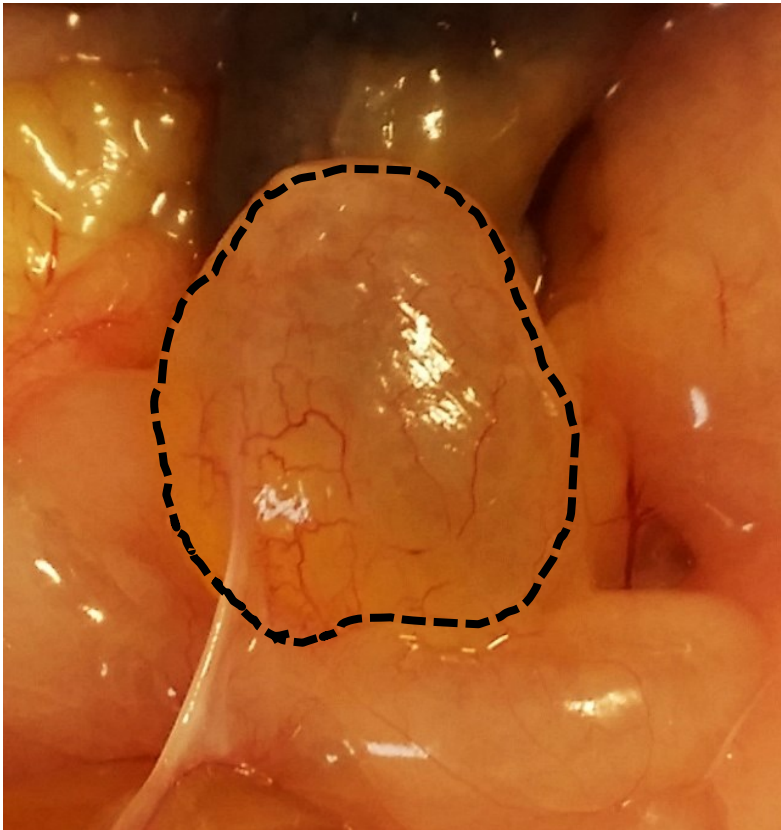
Bladder irradiated at 40 Gy, 6 months, X 200



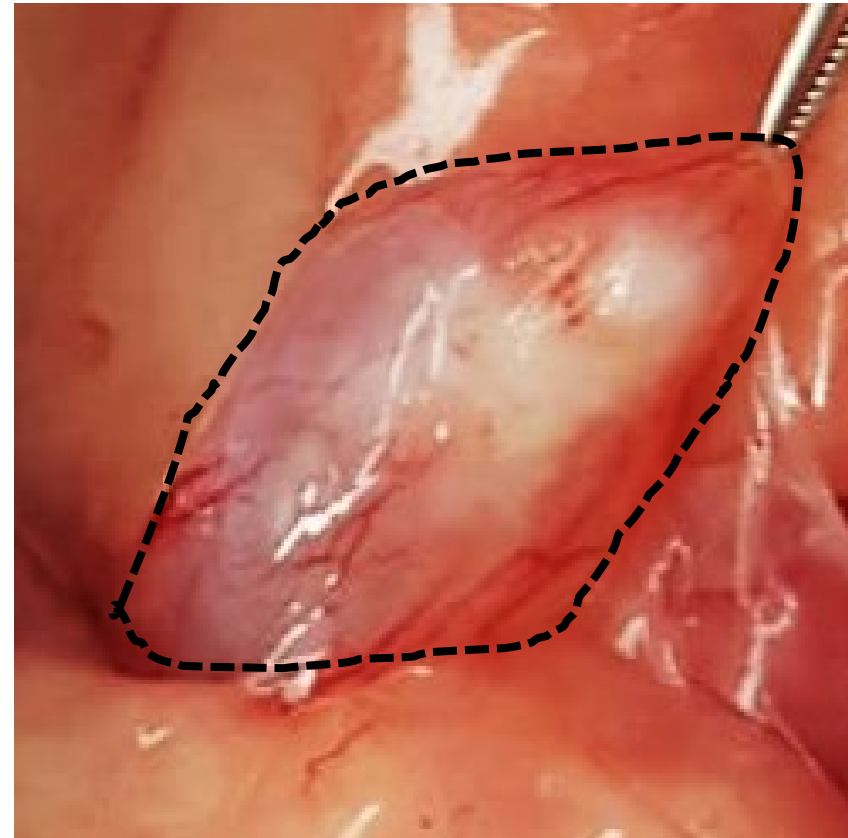
Degradation of the urothelium structure

HES: Hematoxyline, Eosin, Safran

Conclusions:



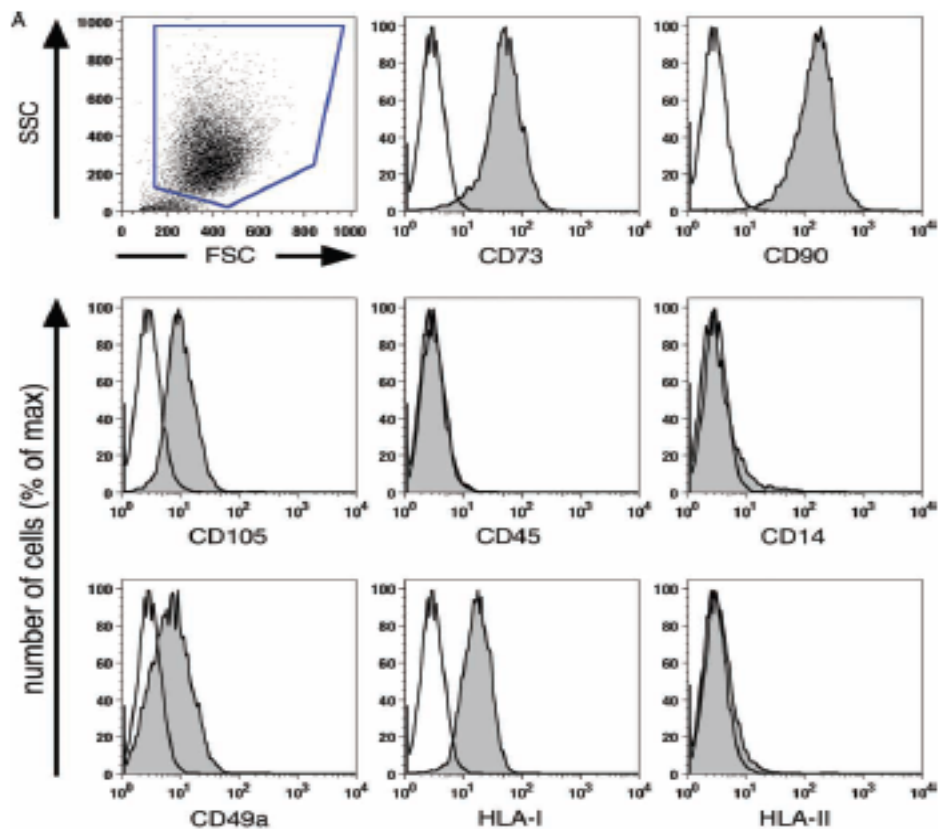
Unirradiated bladder, 10 months



Irradiated bladder, 40Gy 10 months

At 10 months, onset of apparent fibrosis in a few rats 40 Gy

Protocol injection: Characterization of MSCs



International Society for Cellular Therapy
ISCT

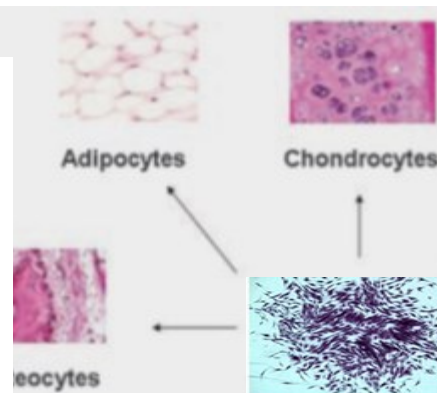
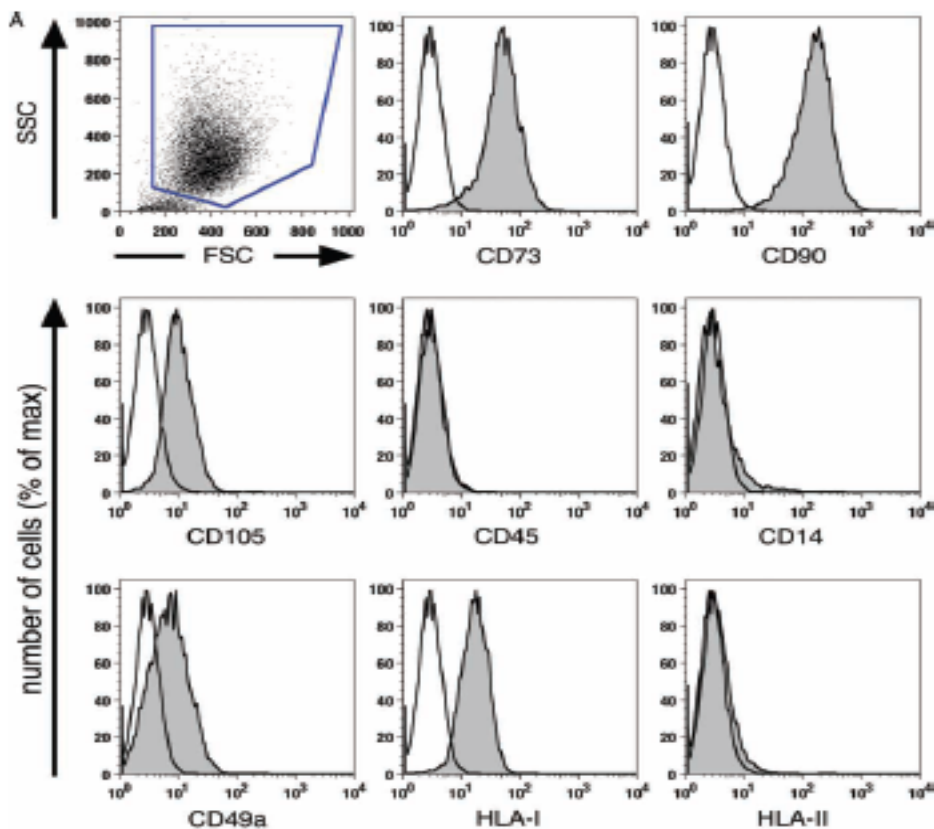
Cytotherapy (2009) Vol. 11, No. 2, 114-128

informa
healthcare

Characterization of bone marrow-derived mesenchymal stromal cells (MSC) based on gene expression profiling of functionally defined MSC subsets

Ariane Tormin¹, Jan C. Brune¹, Eleonor Olsson^{1,2}, Jeanette Valcich^{1,2}, Ulf Neuman³, Tor Olofsson⁴, Sten-Eirik Jacobsen^{1,5} and Stefan Scheduling^{1,6}

Protocol injection: Characterization of MSCs



MSCs

Liu 2009

International Society for Cellular Therapy
ISCT

Cytotherapy (2009) Vol. 11, No. 2, 114-128

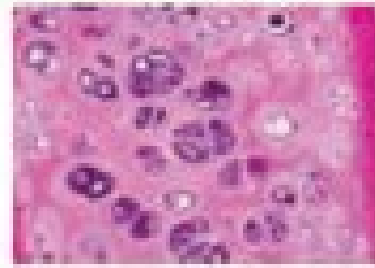
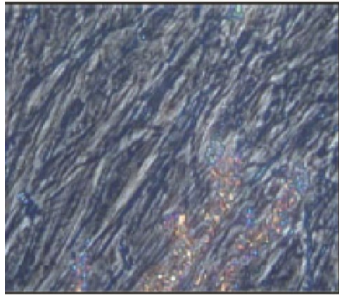
informa
healthcare

Characterization of bone marrow-derived mesenchymal stromal cells (MSC) based on gene expression profiling of functionally defined MSC subsets

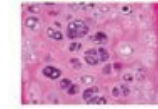
Ariane Tormin¹, Jan C. Brune¹, Eleonor Olsson^{1,2}, Jeanette Valcich^{1,2}, Ulf Neuman³, Tor Olofsson⁴, Sten-Eirik Jacobsen^{1,5} and Stefan Scheduling^{1,6}

Protocol of injection: Characterization of MSCs

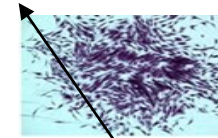
Chondrogenic differentiation
(Bleu Alcian)



Chondrocytes
Osteocytes




Chondrocytes



MSCs

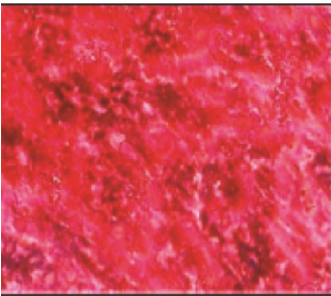
Adipogenic differentiation
(Noir Soudan IV)



Adipocytes

Liu 2009

Osteogenic differentiation
(Von Kossa et Alizarin)



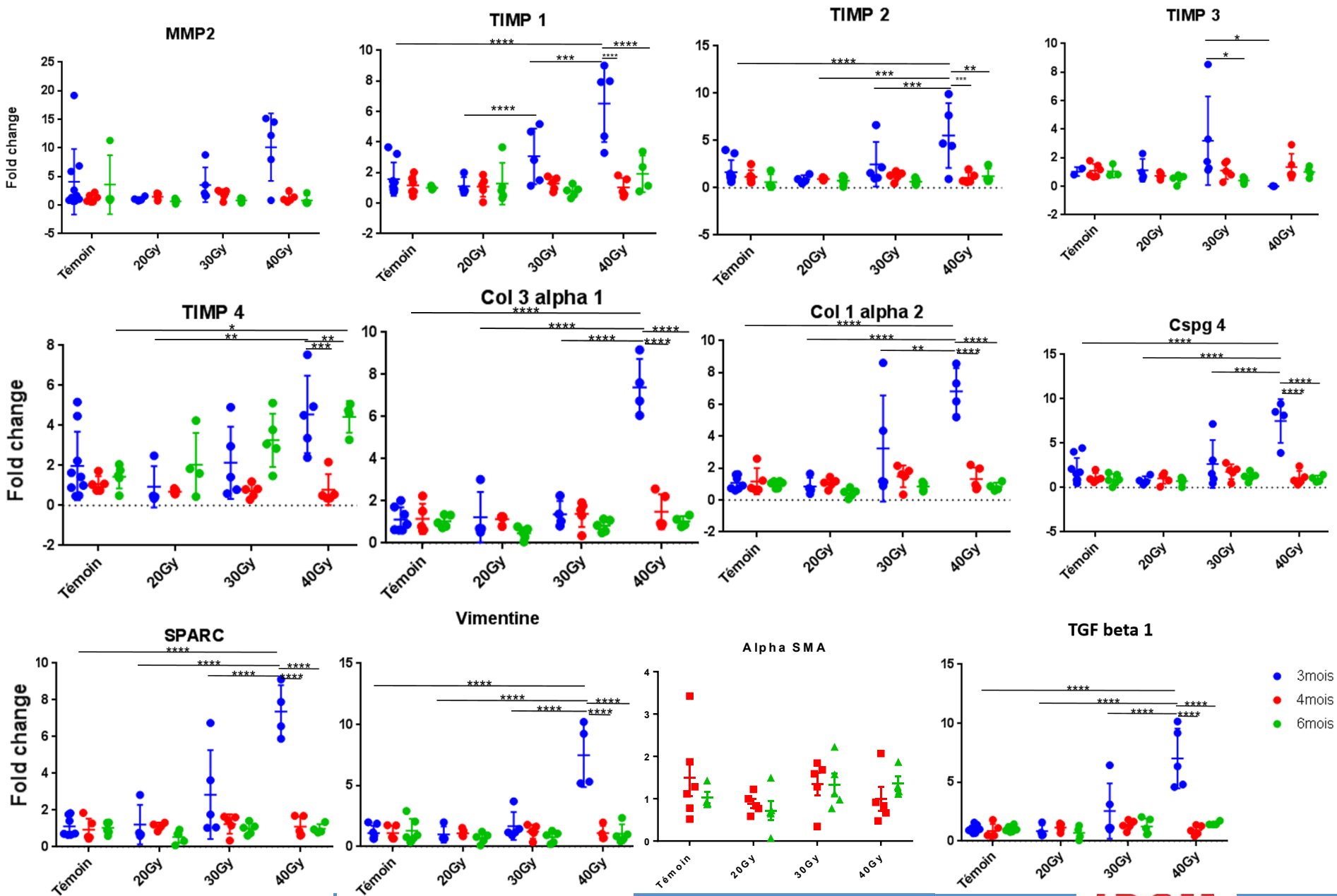
Osteocytes

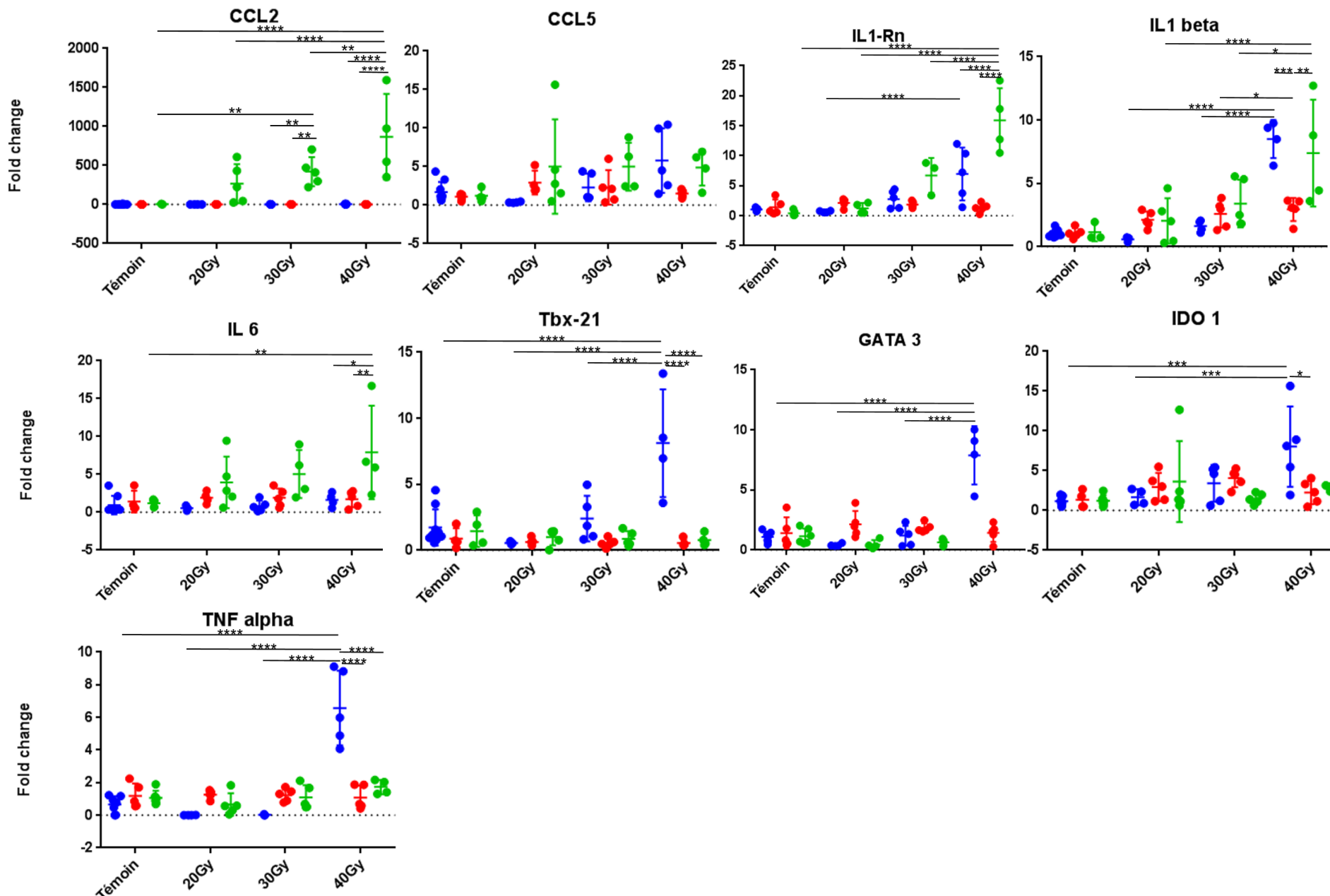
Mouiseddine et al., 2006

MSCs pathways of action on preclinical fibrosis models

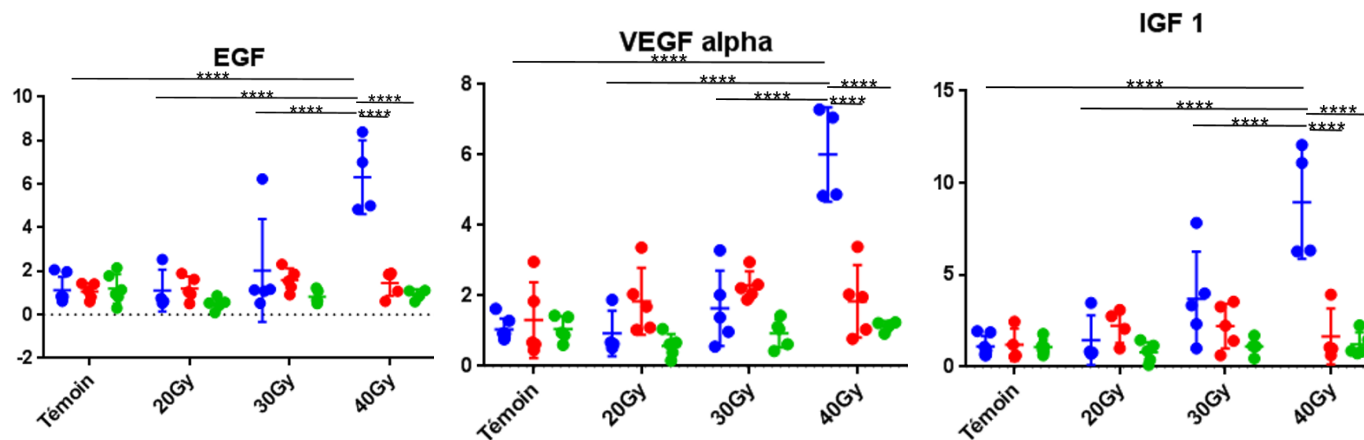
Mode of action	Mechanism	References
Immunomodulation	<p>Decrease in inflammatory infiltration</p> <p>Polarity change of macrophages: M1 -> M2</p> <p>Decrease in the expression and secretion of pro-inflammatory cytokines (TNF-α, IL-1, IL-6...)</p> <p>Decrease in apoptosis</p>	<p>Linard et coll., 2013</p> <p>Zhou et coll., 2013</p> <p>Semedo et coll., 2009</p> <p>Horton et coll., 2013</p>
Inhibition of the TGF pathway- β 1	<p>Decreased expression and secretion of TGF-β1</p> <p>Decrease in the activation of the Smad channel</p> <p>Decrease in the number of myofibroblasts</p>	<p>Ueno et coll., 2013</p> <p>Wu et coll., 2014</p> <p>Jang et coll., 2014</p> <p>Li et coll., 2013</p>
Pro-angiogenic/anti-oxidant	<p>Increase in the expression and secretion of antioxidant enzymes (NQO1, HO-1, SOD...)</p> <p>Pro-angiogenic effect: increase in VEGF and FGF-2</p> <p>Augmentation de la prolifération des cellules endothéliales</p>	<p>Chen et coll., 2011</p> <p>Kinnaird et coll., 2004</p> <p>Niu et coll., 2008</p> <p>Kinnaird et coll., 2004</p>
Remodelage matriciel	<p>Decrease in the expression and production of MEC components</p> <p>Rebalancing the MMP/TIMP balance</p>	<p>Moodley et coll., 2009</p> <p>Mias et coll., 2009</p> <p>Ebrahimi et coll., 2013</p>

Usunier et al., 2013

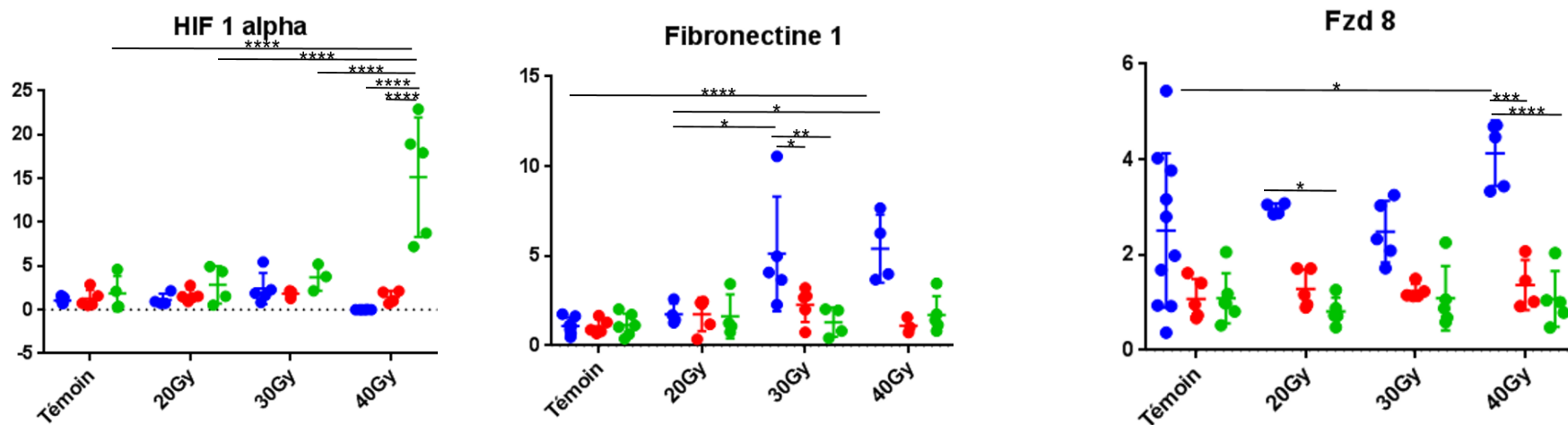




Fold change



Fold change



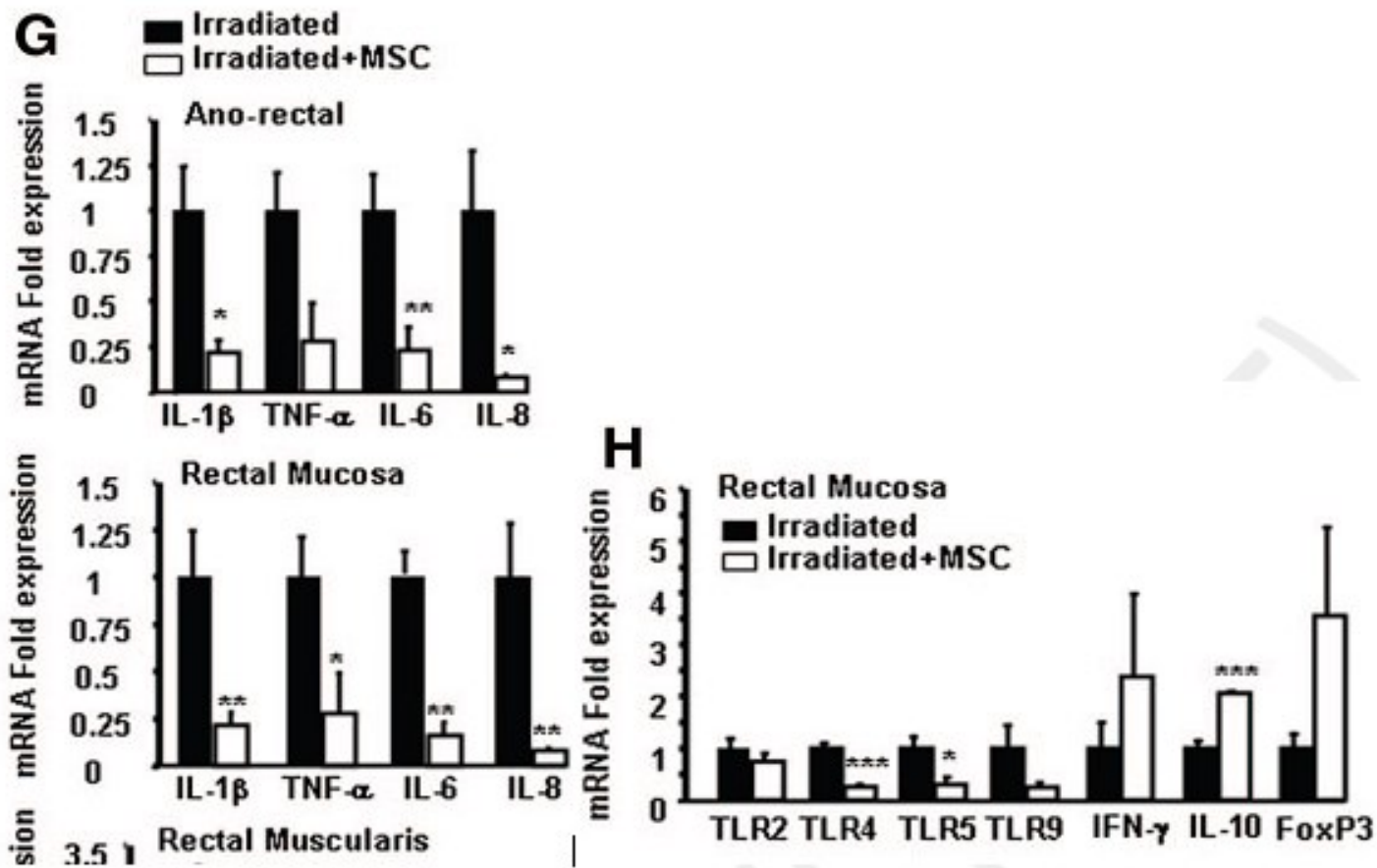
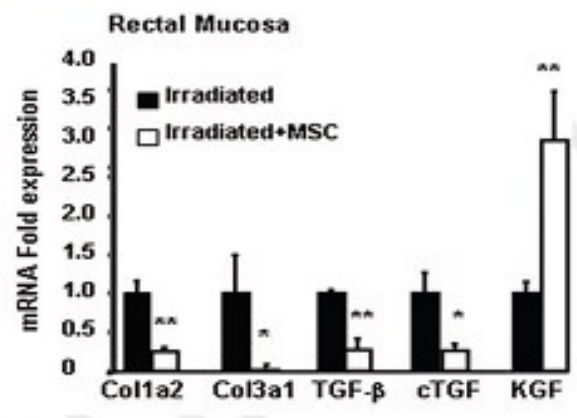
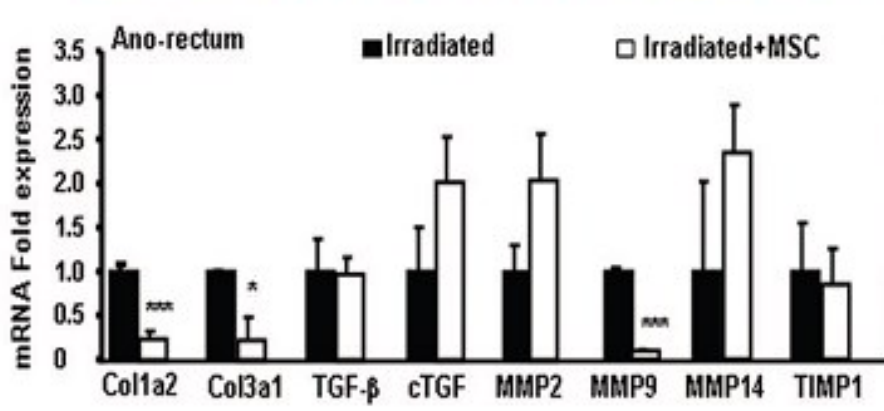
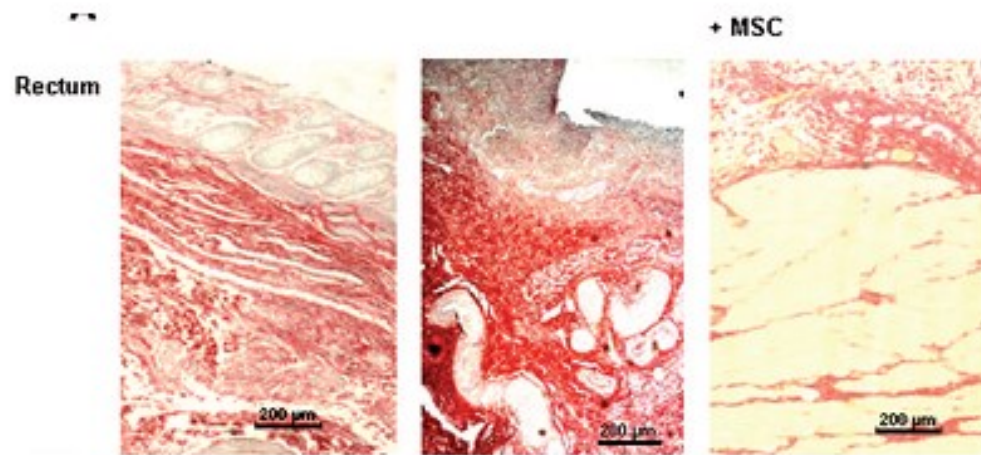


Figure 24. Experimental efficacy and anti-inflammatory effect of MSC injections.

Linard et al., 2013



Linard et al., 2013

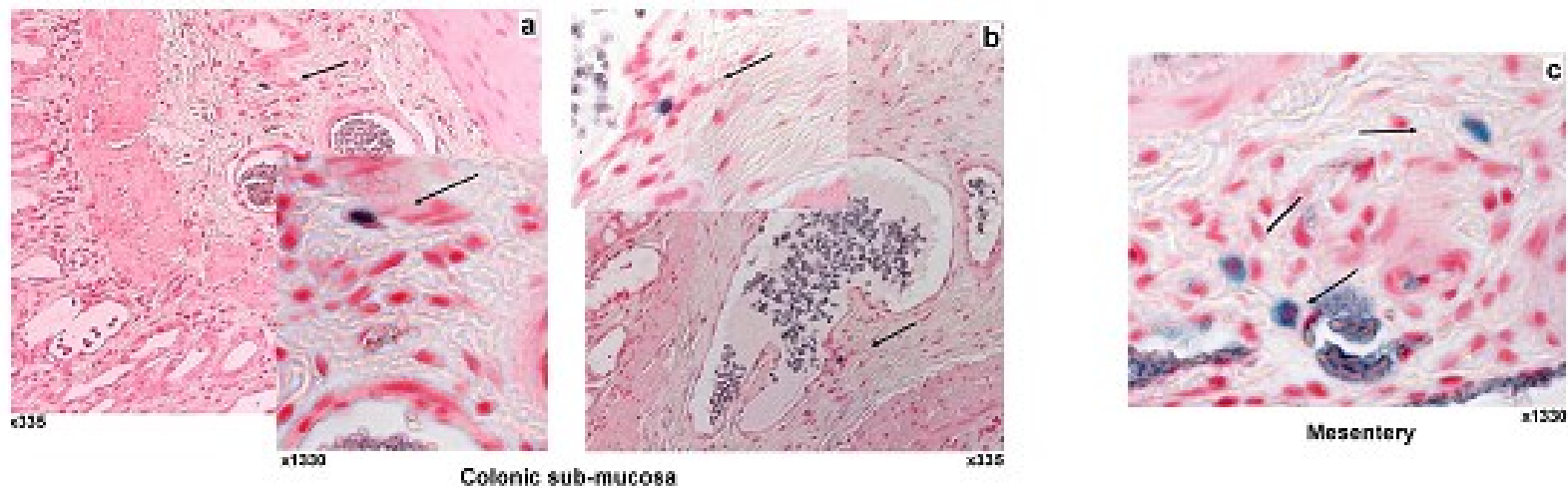


Figure 33: MSC engraft in colonic mucosa one week after injection and disappeared at 2 weeks
 Intravenous injected MSC-GFP engraft in the colon. Detection of GFP-MSC (black arrow) in irradiated (a, b) colonic sub-mucosa or (c) mesentery, 1 week after injection using GFP-specific antibodies. Magnification, x335 and x1330.

Sémont et al., 2010

Matériel :

- Milieu MSCs : MEM α , SVF 20%, PS, Glut
- Milieu PBS, SVF 10%
- Collagénase type I (Sigma C0130-1g)
- 6 tubes 50ml avec collagénase à 0.1% dans du milieu de digestion : MEM α , PS, Glut
- Boite de pétri en verre

● Prélèvement de la graisse

La graisse est prélevée au-dessus de la patte entre la peau et le péritoine, mise dans 5mL de PBS 1X.

● Digestion (x3)

On coupe la graisse en petits morceaux, que l'on met dans du MEM α + collagénase à 0,1% (x2 tubes/digestion). Incubation **pdt 30 min à 37°C** avec agitation.

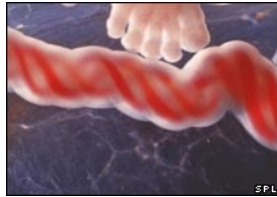
On récupère les cellules avec une filtration 100 μ m, la graisse non digérée est remise en MEM α + collagénase à 0,1%. Sur les cellules filtrées, on ajoute du milieu contenant du SVF pour diluer la collagénase.

On effectue une centrifugation pour rassembler toutes les cellules, filtration sur 40 μ m et ensuite numération. (4ml au 5^e en bleu acétique)

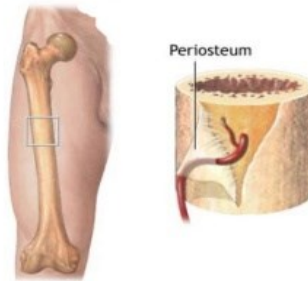
● Culture

PO 1000 ζ /cm² soit 0,150.10⁶ ζ /150cm² en milieu MSCs

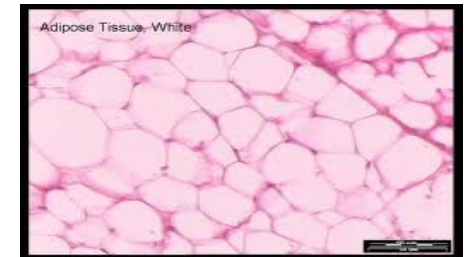
CFU-F 1000 ζ /F25cm² en triplicat



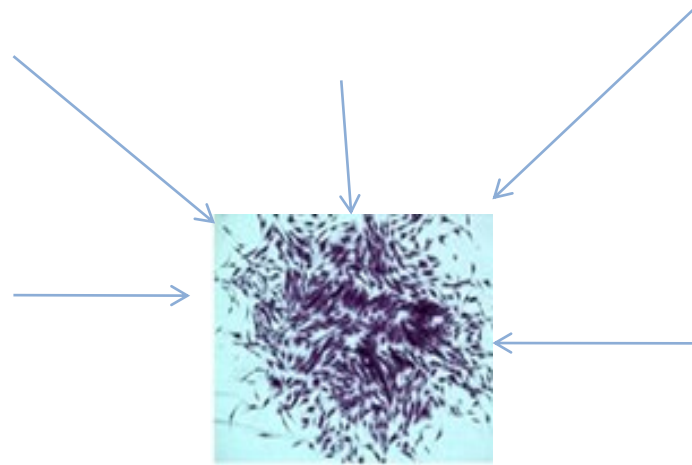
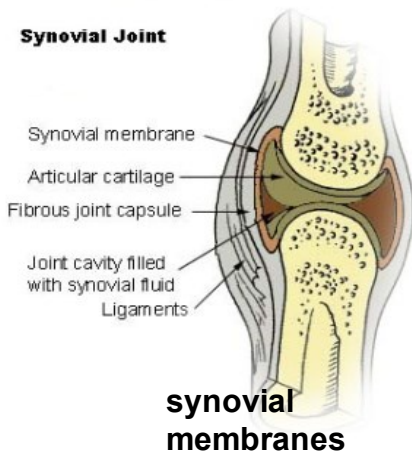
**Umbilical cord
Wharton's jelly**



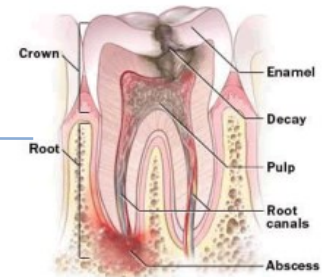
**Bone marrow
periosteum**



Adipose tissue



**Sources of
MSCs**



Dental pulp

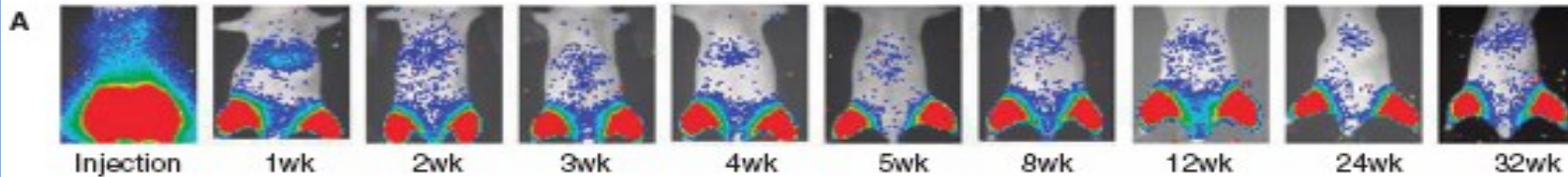
MSC homing after intramuscular injection (0.5×10^6 CSM) (Vilata 2008)

STEM CELLS AND DEVELOPMENT 17:993–1004 (2008)
© Mary Ann Liebert, Inc.
DOI: 10.1089/scd.2007.0201

Biodistribution, Long-term Survival, and Safety of Human Adipose Tissue-derived Mesenchymal Stem Cells Transplanted in Nude Mice by High Sensitivity Non-invasive Bioluminescence Imaging

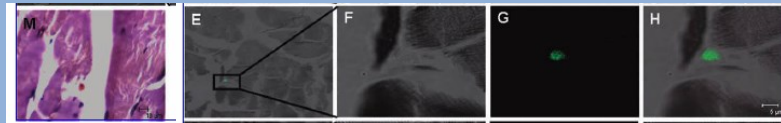
Marta Vilalta,¹ Irene R. Dégano,¹ Juli Bagó,¹ David Gould,² Mónica Santos,³ Mariano García-Arriaza,⁴ Ramon Ayala,⁵ Carme Fuster,⁶ Yuli Chernajovsky,⁷ Damián García-Olmo,⁸ Nerea Rubio,¹ and Jeronimo Blanco¹

Intramuscularly (IM) inoculated MSC.



75 % of MSC lost the first week

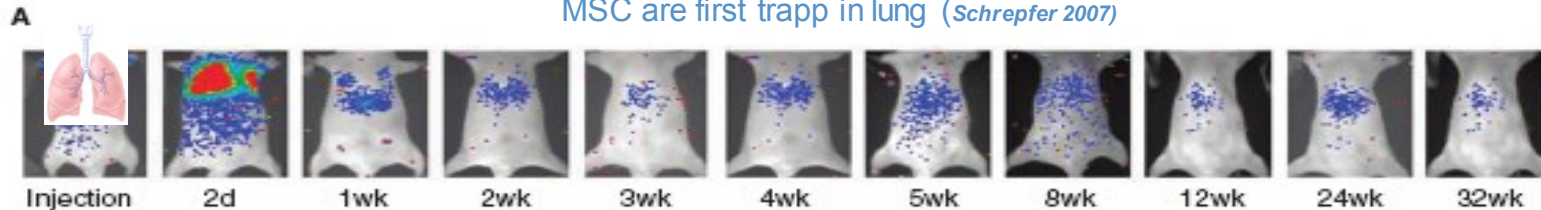
Number surviving cells remains stable over 32 weeks



Histological localization of MSC

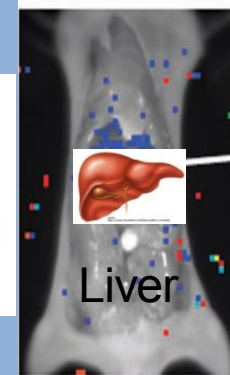
Tail vein (IV) inoculated MSC

MSC are first trapped in lung (Schrepfer 2007)



MSC first retained in lung
Cleared after one week

1.5% of cells detected in abdomen (persisted 32 weeks)



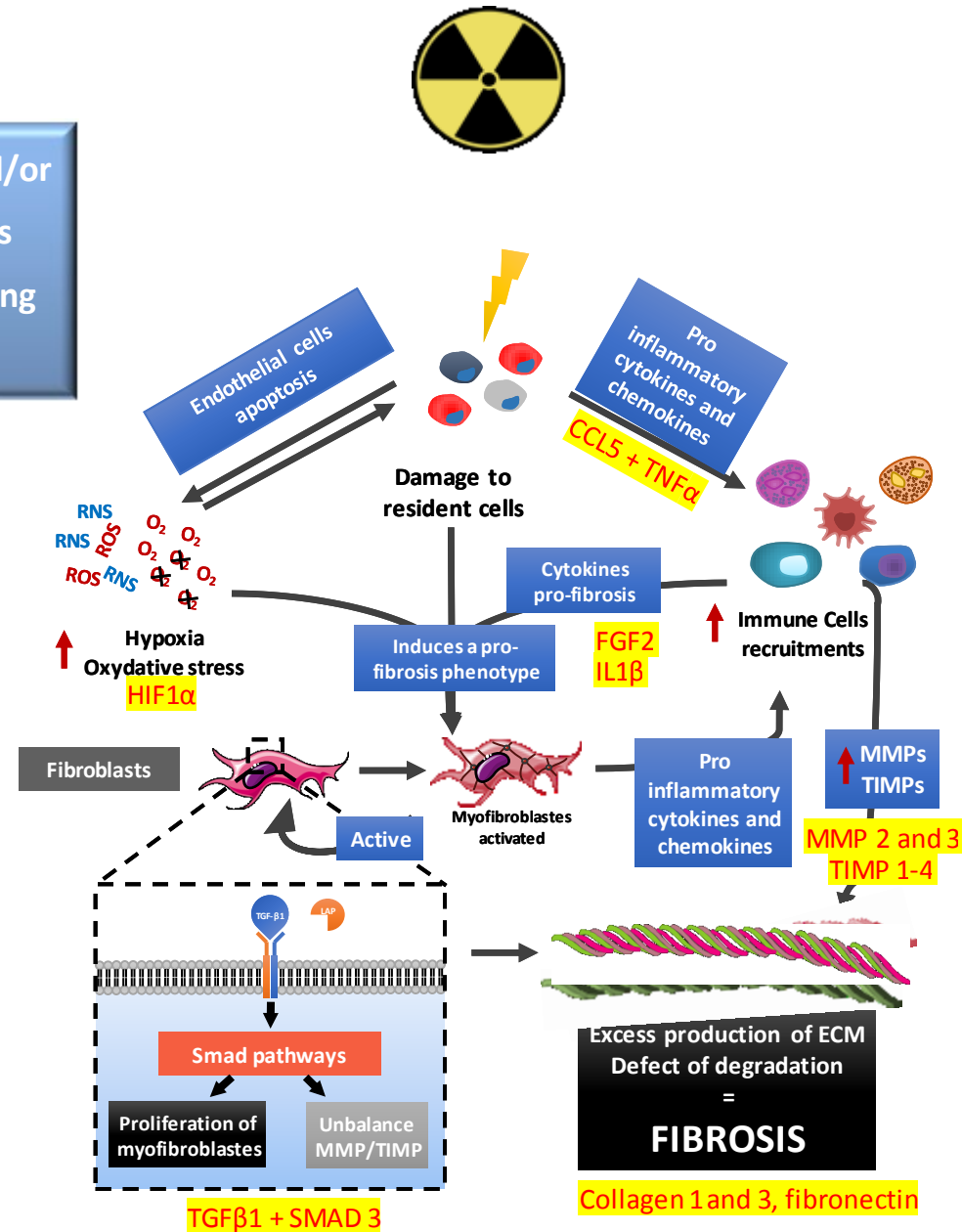
IV and IM Liver preferred target organ for colonization

“Fibrosis is defined by the overgrowth, hardening, and/or scarring of various tissues and is attributed to excess deposition of extracellular matrix components including collagen” (Wynn TA, 2008)

Cytokine pro fibrosis secreted following irradiation

Activation of extracellular matrix secreting cells

Imbalance of the accumulation/degradation of the ECM

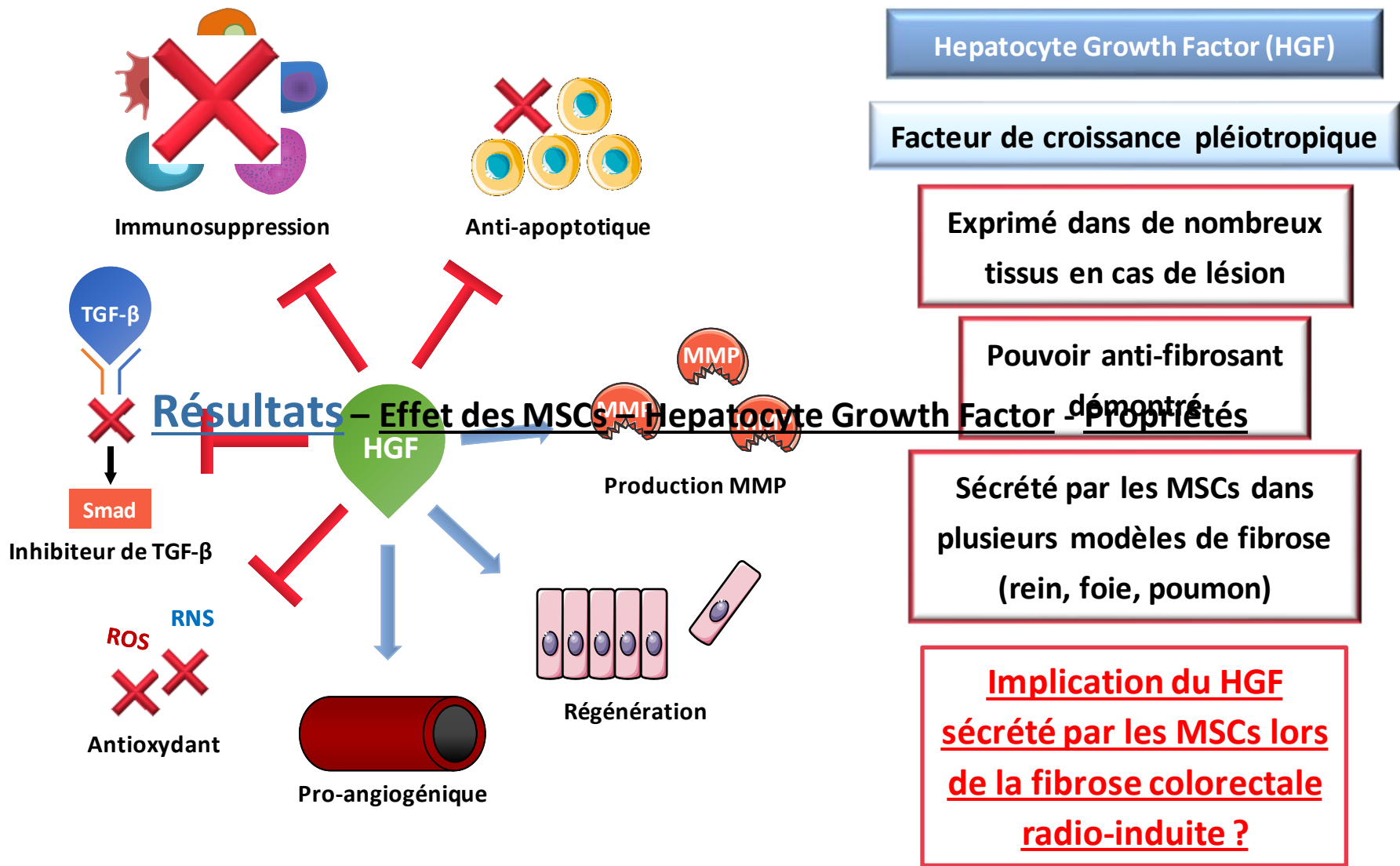


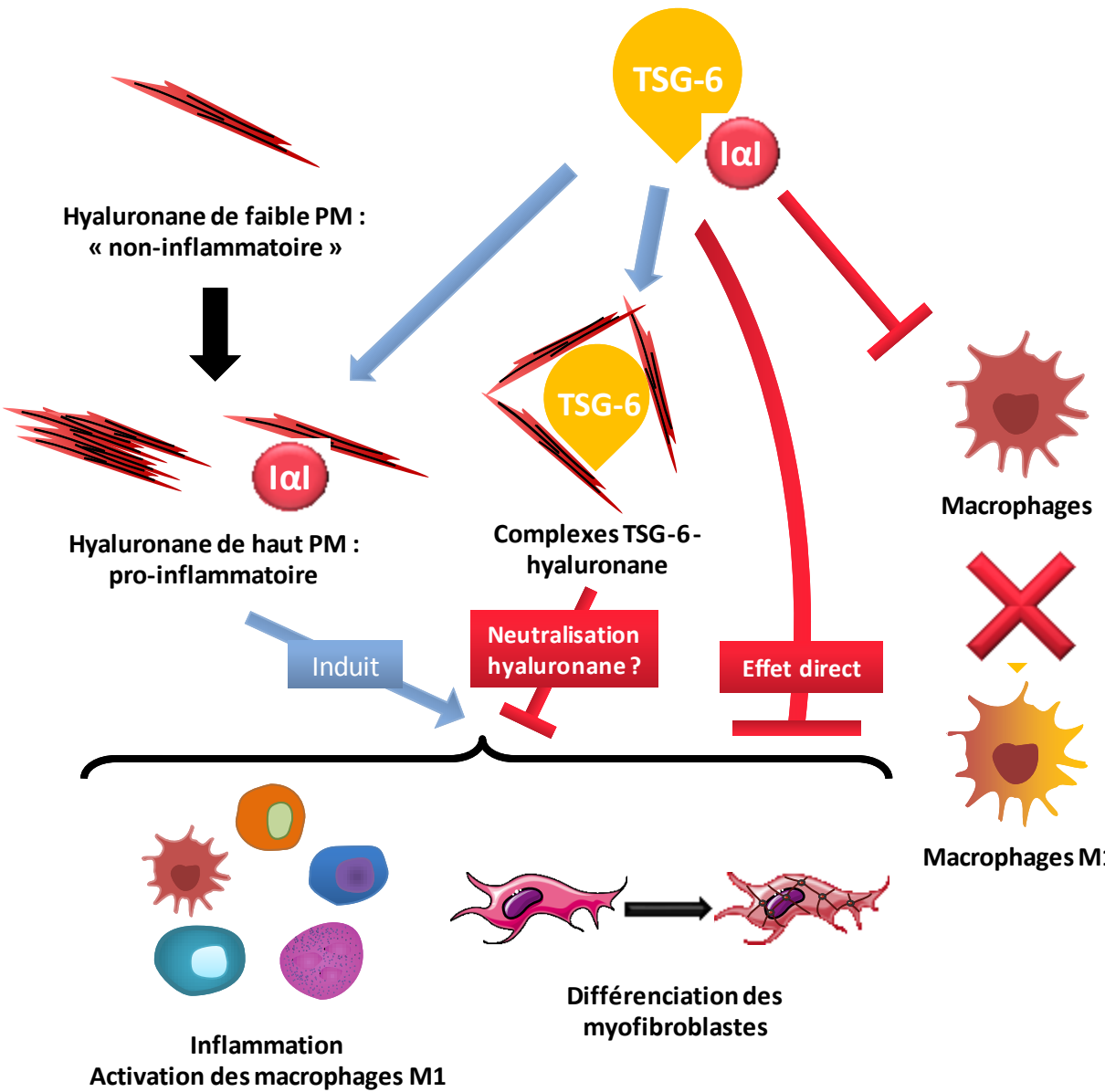
HIF1α = results of M2

ECM: ExtraCellular Matrix

TGFβ1 + SMAD 3

Collagen 1 and 3, fibronectin





TNF-stimulated Gene-6 (TSG-6)

Protéine immunomodulatrice

Exprimé lors de l'inflammation (induit par TNF-α)

Stimule/réduit l'inflammation

Sécrété par les MSCs dans plusieurs modèles de fibrose (rein, peau) : effet anti-fibrosant

Implication du TSG-6 sécrété par les MSCs lors de la fibrose colorectale radio-induite ?

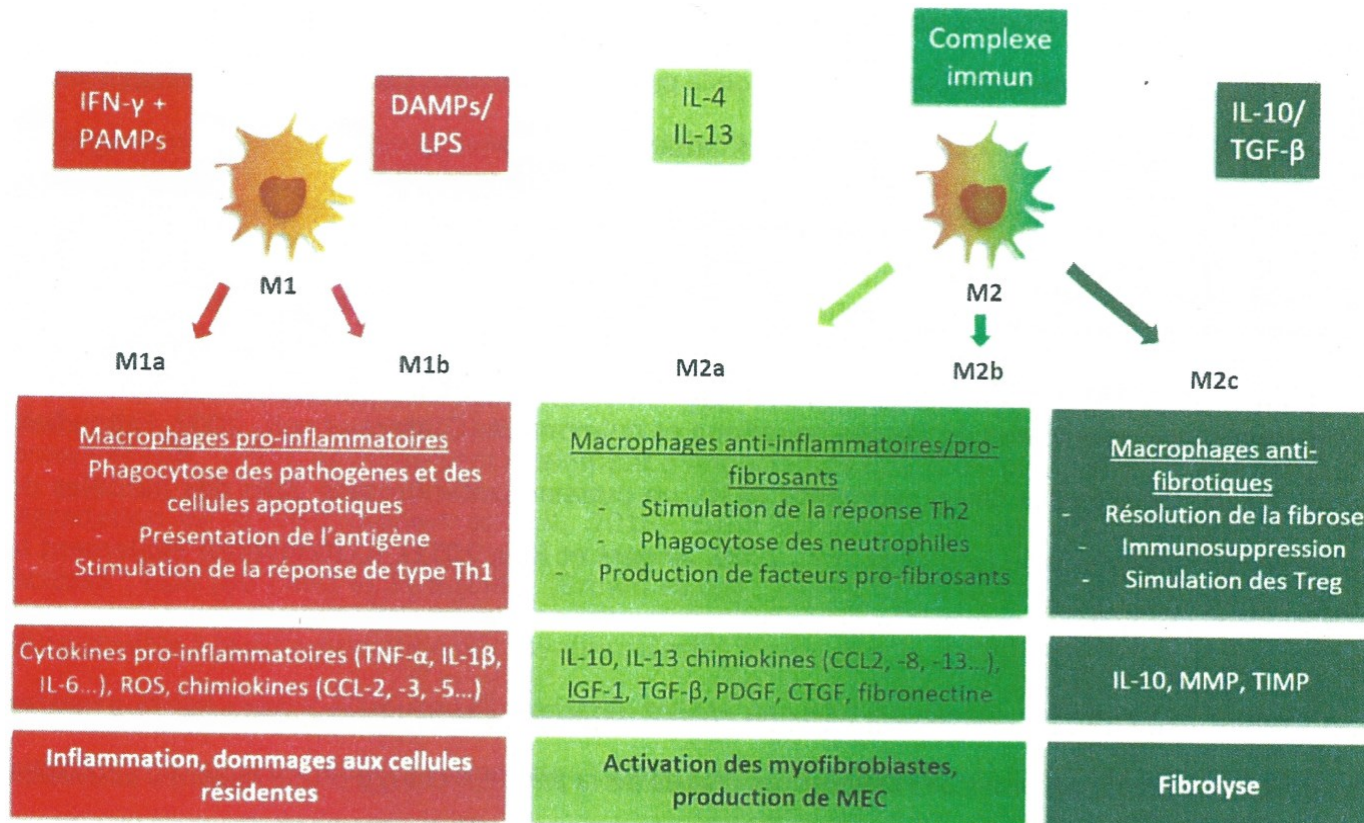


Figure 8 : Caractéristique des différents états de polarisation des macrophages.

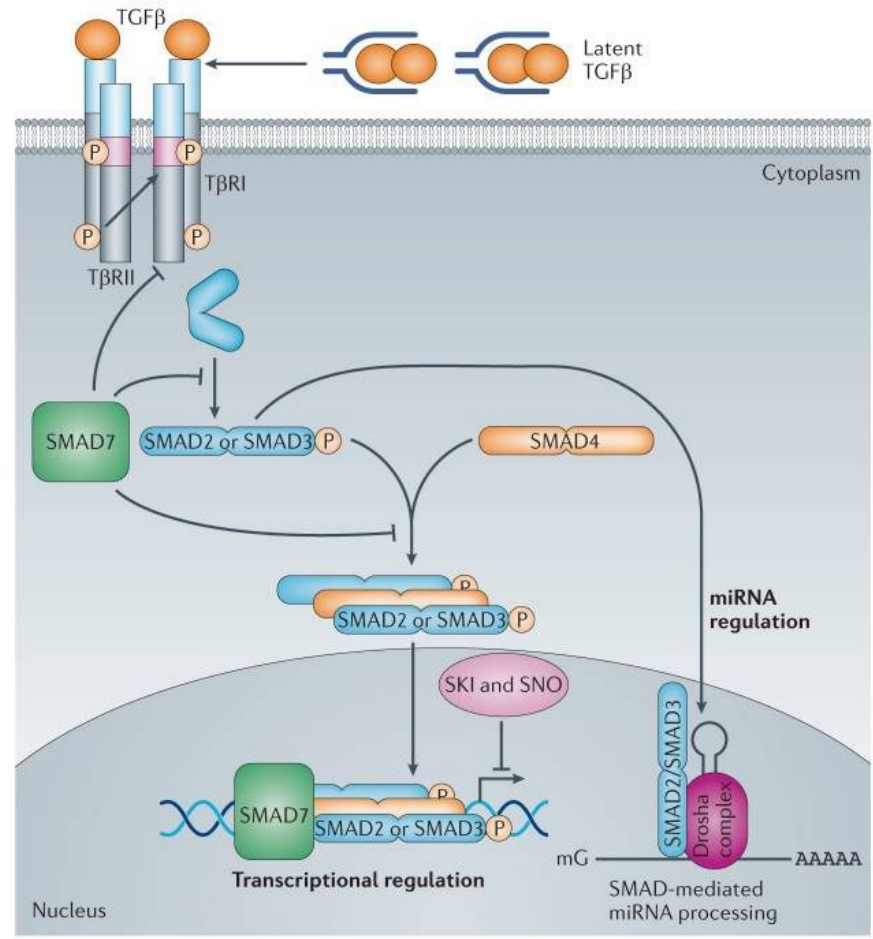
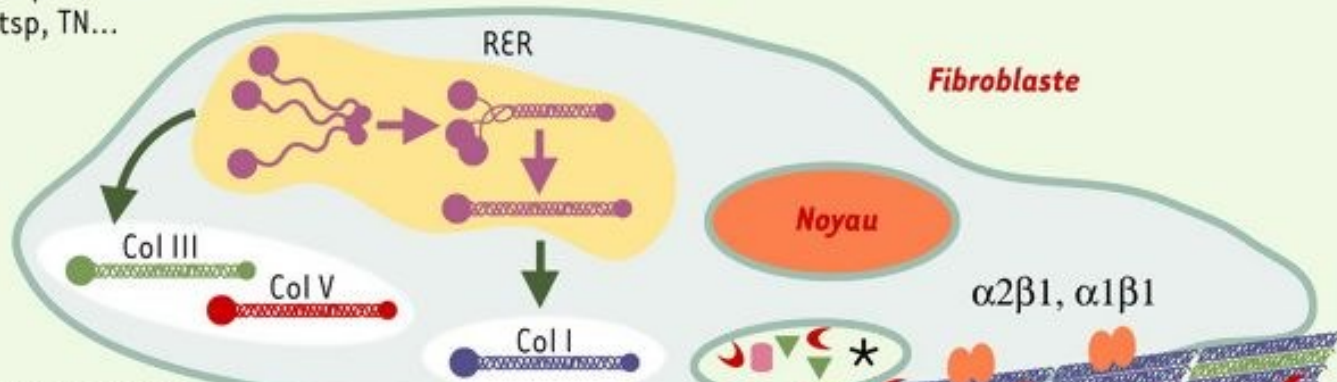
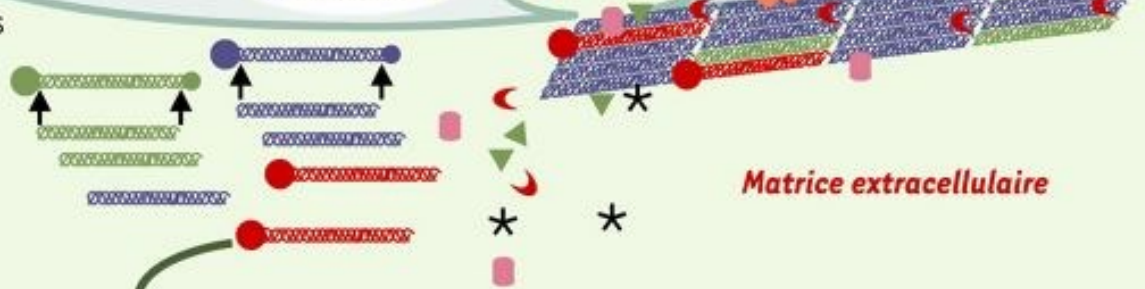

Figure: mécanismes d'activation et d'inhibition de la voie Smad (D'après Akhurst, 2012) (Akhurst and Hata, 2012)

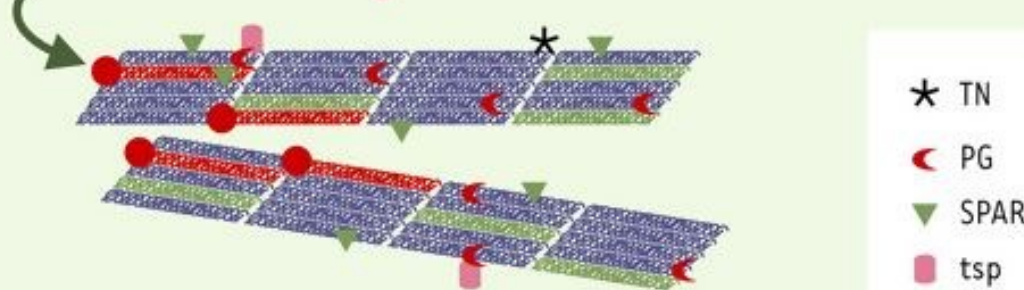
1. Synthèse des collagènes et autres composés matriciels : PG, SPARC, tsp, TN...



2. Sécrétion des protéines matricielles, maturation des collagènes



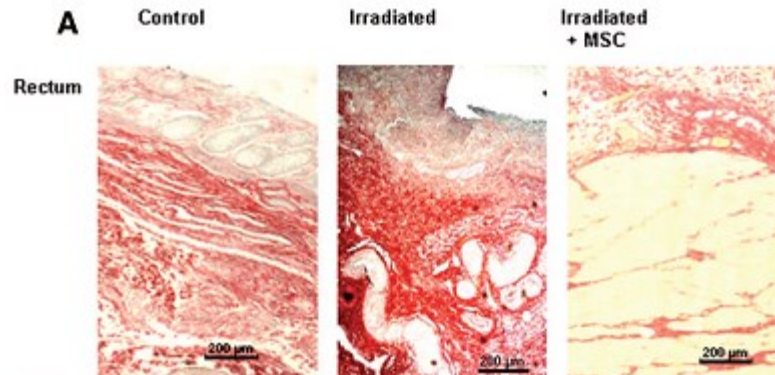
3. Association en fibres et interaction avec d'autres composants matriciels



- * TN
- ◀ PG
- ▼ SPARC
- tsp

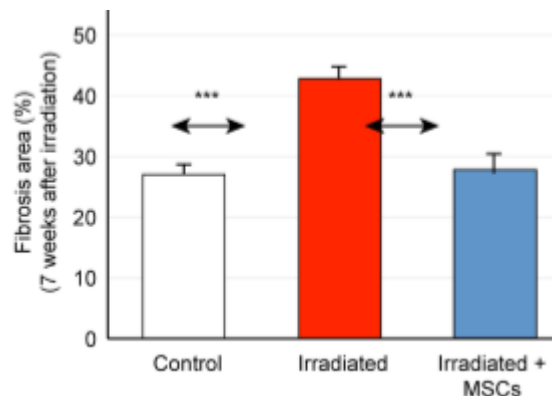
Protocol of intravenous injection:

- 5 millions of MSCs significantly improve the epithelial injury score
- Iterative injections in established radiation-induced lesions restore mucosal damages.



Linard et al., 2013; Bessout et al., 2014

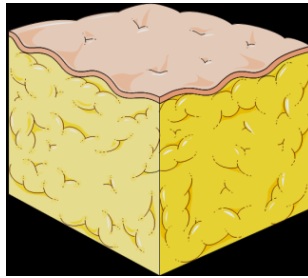
- Injection frequency \geq 1 week
- MSCs injections are more effective during the initiation phase of fibrosis



Usunier et al. 2014
Colorectal fibrosis

Protocol injection: Chronic Radiation Cystitis

Adipose tissue



Isolation
Purification
Expansion

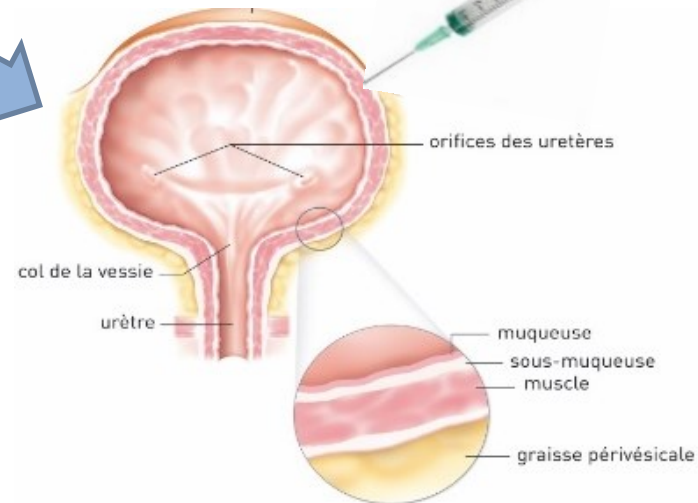
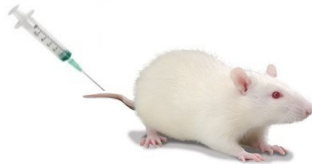

Local injection

1 millions cells^{2,3,4}

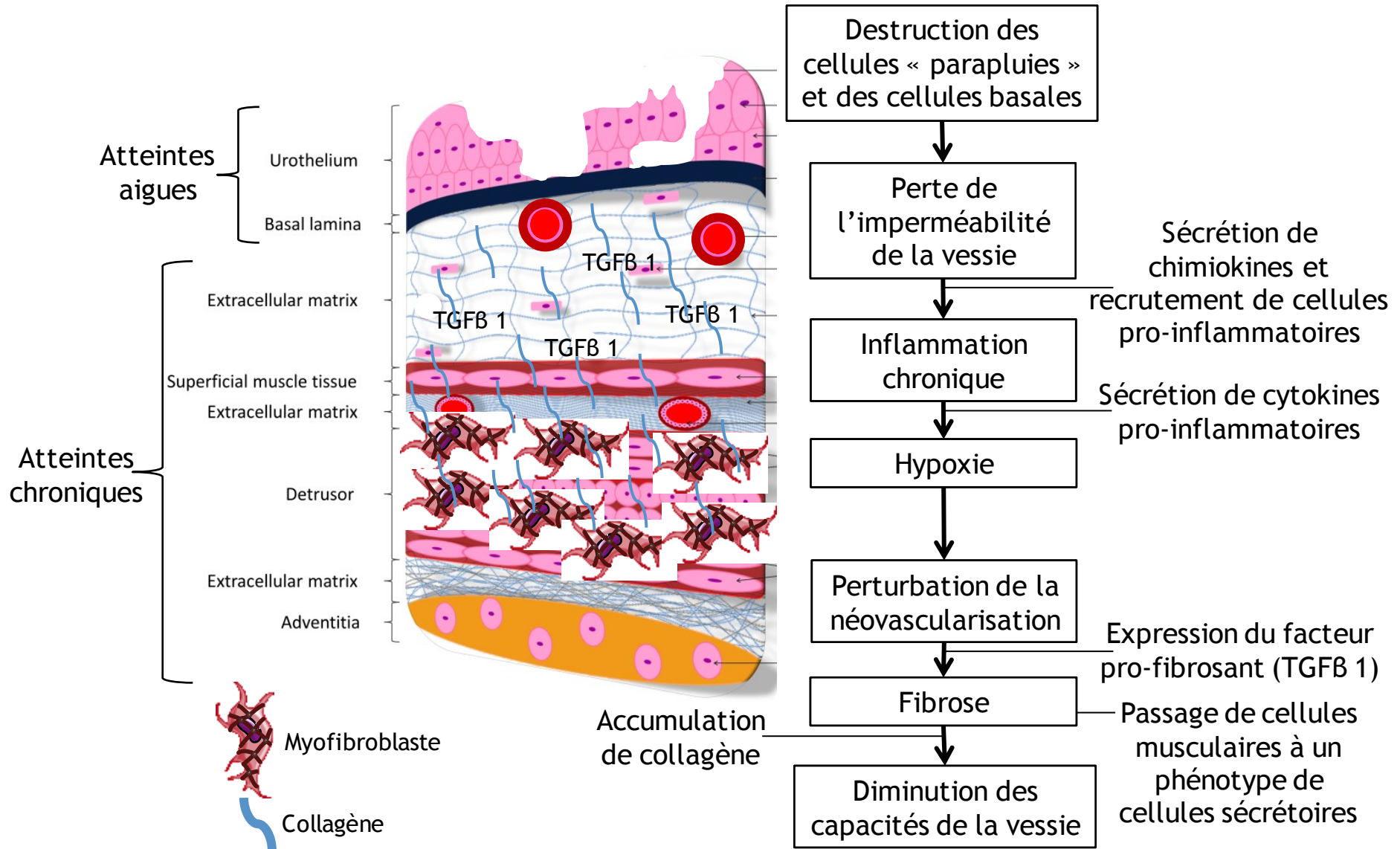
Intravenous injection

5 millions cells¹

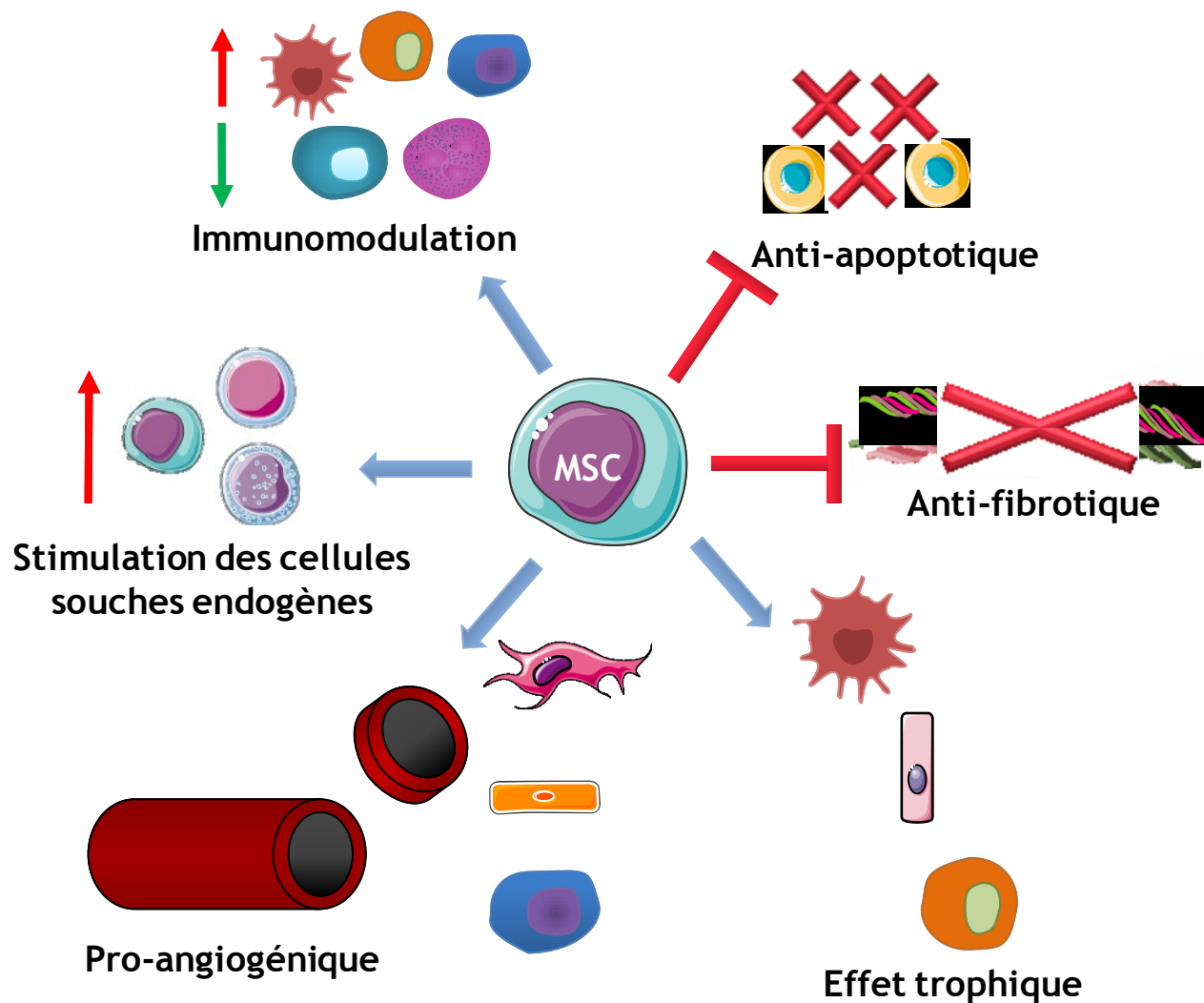


- 1: Kanno et al.; 2014
- 2: Kim et al.; 2016
- 3: Lee S.W et al.; 2018
- 4: Salehi-pourmehr H. et al.; 2019

Mécanisme de la cystite radique chronique



Fonctions des cellules souches mésenchymateuses



Principaux récepteurs de chimiokines exprimés sur les différents types de cellules immunitaires

Cellules	Récepteurs
Lymphocyte B	CXCR4, CXCR5
Basophile, éosinophile	CCR3
Neutrophile	CXCR1, CXCR2
Lymphocyte TCD8	CCR5, CX3CR1, CXCR1, CXCR3, CXCR6
Cellule dendritique immature	CCR1, CCR6
Cellule dendritique mature	CCR7
Macrophage	CCR1, CCR2, CCR5
Cellule Th1	CCR1, CCR5, CXCR3, CXCR6
Mastocyte	CXCR1, CXCR2
Monocyte	CCR5, CX3CR1, CCR1, CCR2
Cellule Th2	CCR3, CCR4, CCR8, CXCR4
Cellule NK	CX3CR1, CXCR1, CXCR3, CXCR4, XCR1