

IRSN

INSTITUT
DE RADIOPROTECTION
ET DE SÛRETÉ NUCLÉAIRE

Cellular therapy treatment of chronic radiation cystitis in rats

Brossard C.¹

(clement.brossard@irsn.fr)

Dos Santos M.², Benadjaoud MA, Demarquay C.¹,
Buard V.¹, Tarlet G.¹, Squiban C.¹, Linard C.¹,
Mathieu N.¹, Granger R.³, Sache A.³, Denais Lalieue
D.³, Milliat F.¹, Chapel A.¹

¹Radiobiology of Medical Exposure Laboratory
(LRMed), ²Radiobiology of Accidental Exposure
Laboratory (LRAcc), ³Support Group for Research
and Animal Ethics (GSEA)

MEMBRE DE

ETSON

EUROPEAN
TECHNICAL SAFETY
ORGANISATIONS
NETWORK



IFATS

International Federation for
Adipose Therapeutics and Science

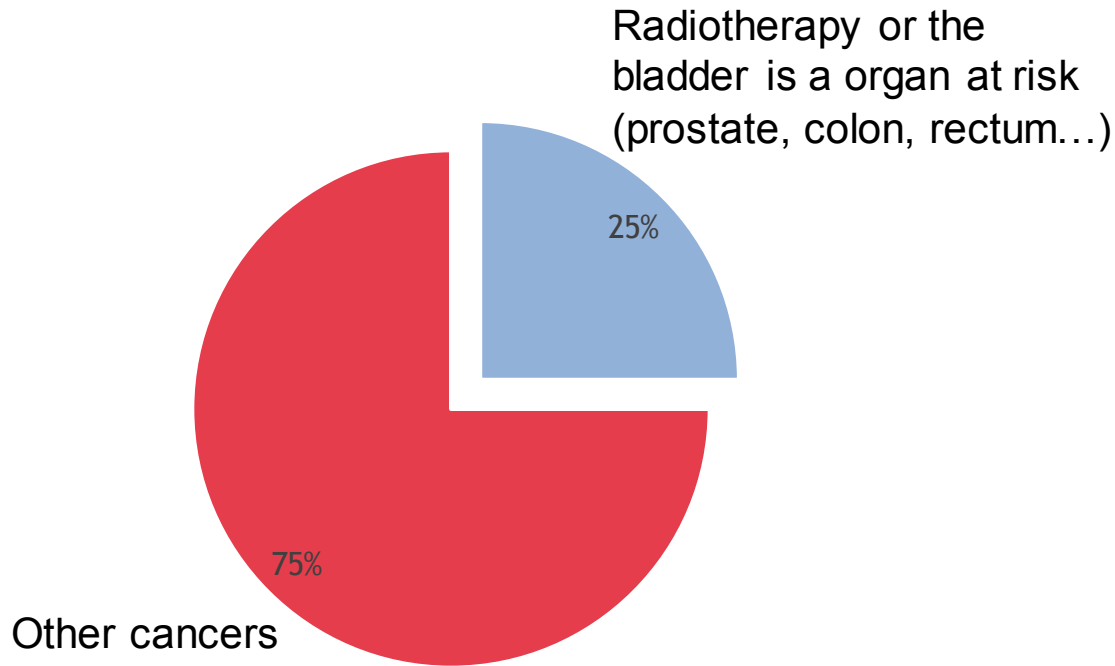


IFATS 2019 . MARSEILLE, FRANCE . DECEMBER 4-7

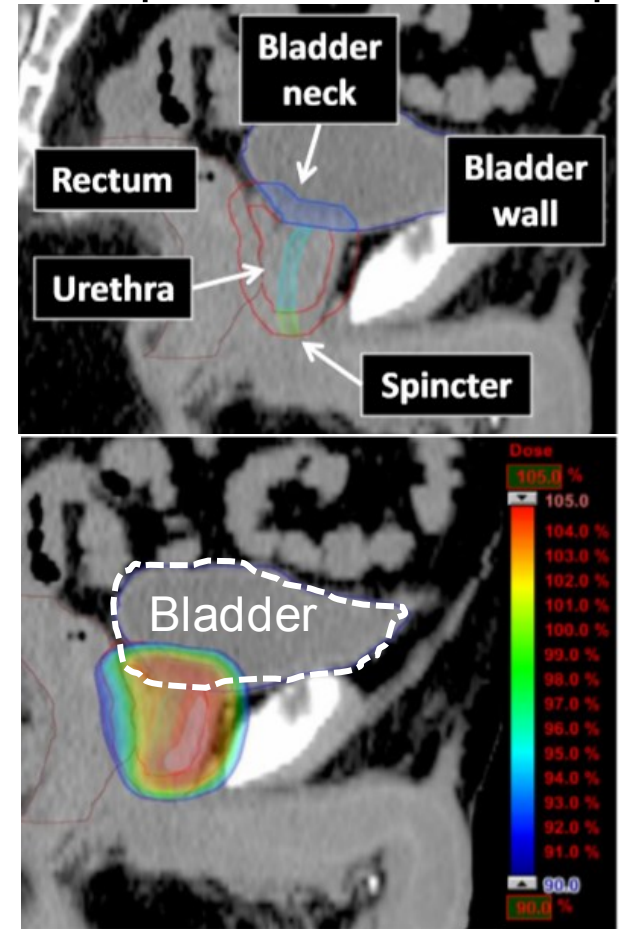
PRESIDENT - GUY MAGALON

Introduction: Pelvic cancers

Global estimation of the number of new cases of cancer, 2018



Example of a treatment plan for external prostate radiotherapy



The Global Cancer Observatory - May, 2019.

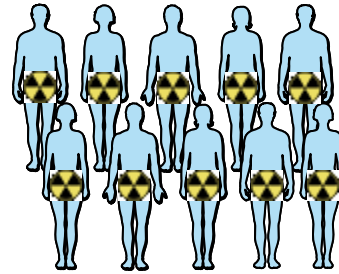
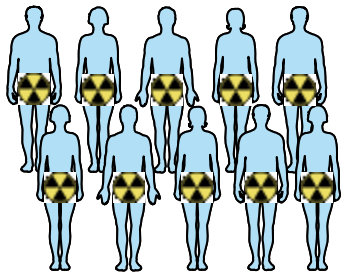
Inokuchiet et al.; 2017

Abdominal-pelvic sphere = 25% of cancers

The bladder is an organ at risk for pelvic radiotherapy

Introduction: Complication radiotherapy

Population concerned



Radiotherapy



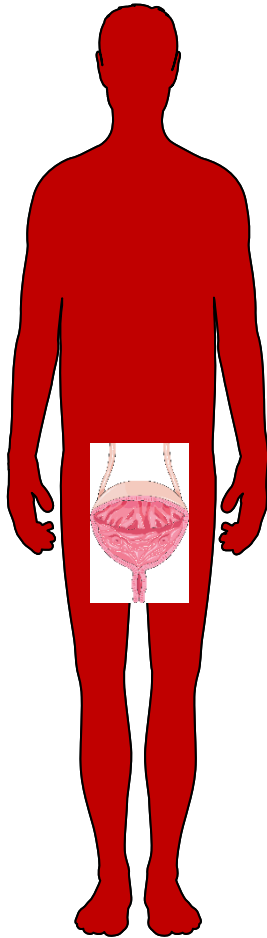
Days - weeks

Acute effects
40% of patients

Month - years

Late effects (Chronic Radiation Cystitis or CRC)
5 to 10% of patients (6 month at 20 years)
9000 to 18 000 patients per years in France

Levenback et al., 1994; Manikandan et al., 2006



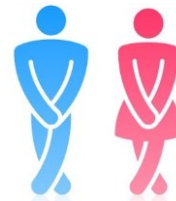Chronic effects :



Pain



Hematuria



Incontinence




Significant decrease
in quality of life

No curative treatment is available

Ad-Mesenchymal Stem Cells (MSCs) Effects




Other pelvic radio-induced diseases

Usunier et al., 2014
Linard et al., 2013

 Inflammation
 Fibrosis
 Tissue regeneration



Interstitial cystitis

Kim et al., 2016
Song et al., 2015

 Inflammation
 Fibrosis
 Tissue regeneration

Hemorrhagic cystitis

Lee et al., 2003
Baygan et al., 2007

 Tissue regeneration
 Hemorrhage

MSCs

- Significant effect on diseases similar to CRC.
- Not tested on CRC.

Hypothesis:

MSCs reduced inflammation, fibrosis and increase tissue regeneration in CRC?

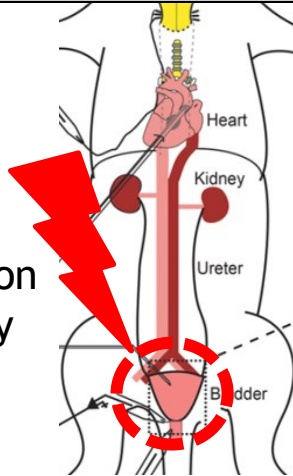
Study design

Local bladder irradiation

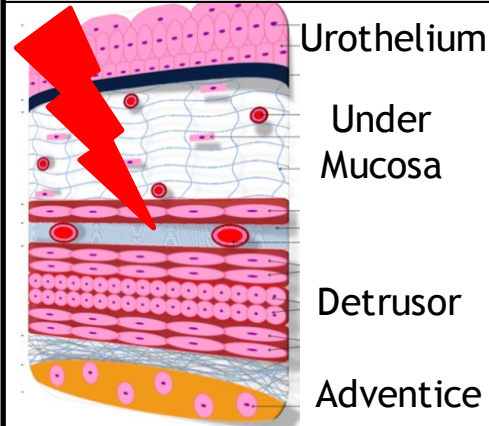


Irradiation
20-80Gy

Bladder

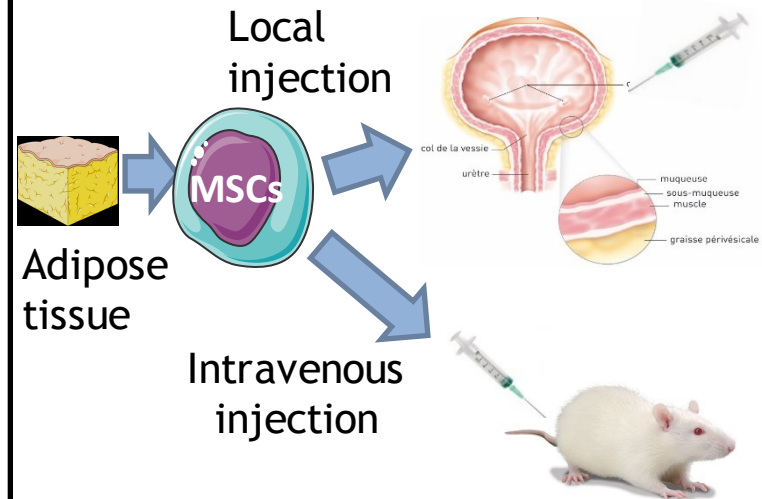


CRC



1. Inflammation
2. Vascular damage
3. Fibrosis
4. Ulcer

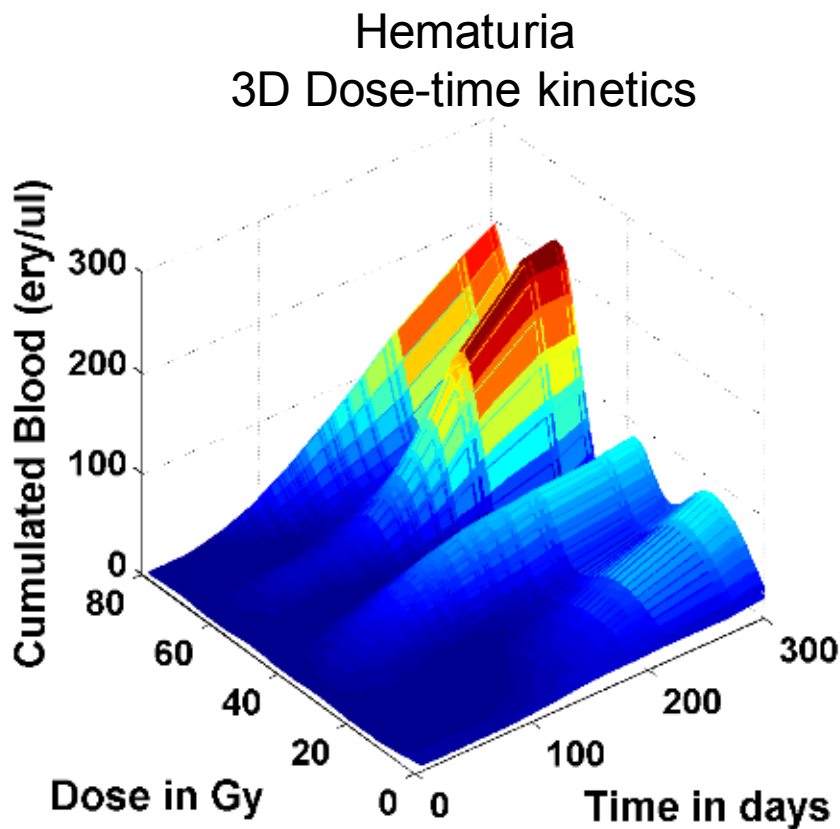
Treatment



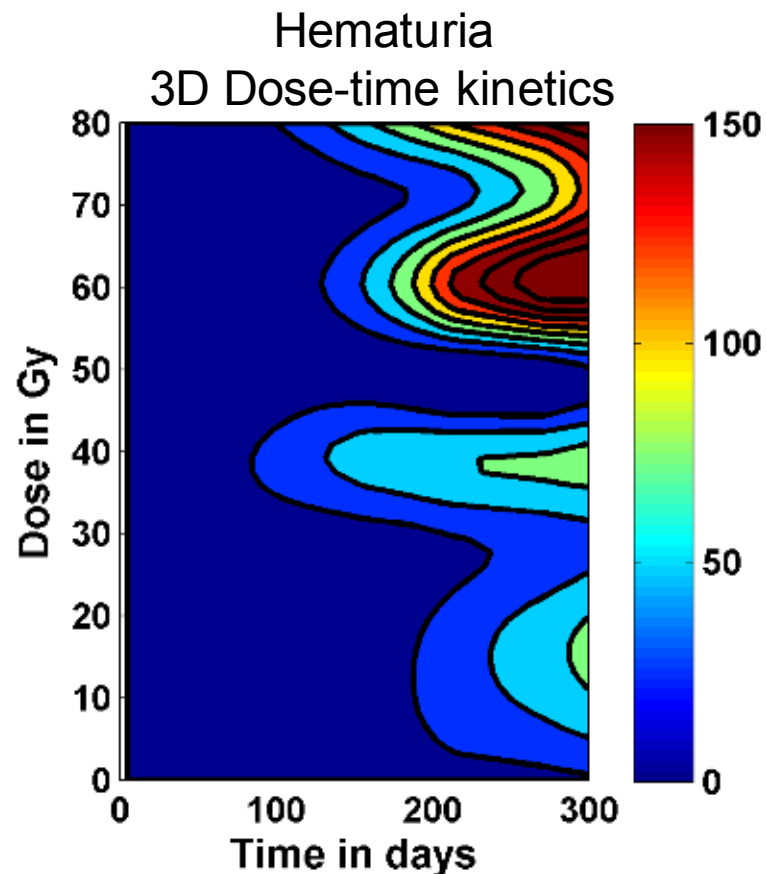
- Total irradiation of the bladder to reproduce CRC
- Study of the mechanisms of the CRC
- Treatment of CRC by Injection of MSCs
- Studies of the effectiveness of treatment on CRC (fibrosis, inflammation, hematuria...)

Urinary analysis over time post irradiation

Cumulated blood concentration in urine with dose and time (24h in metabolic cage)

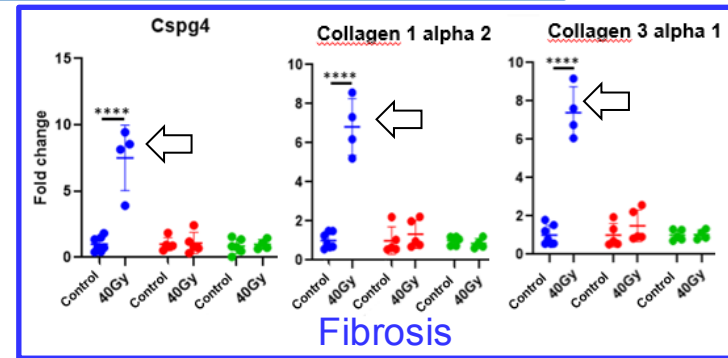
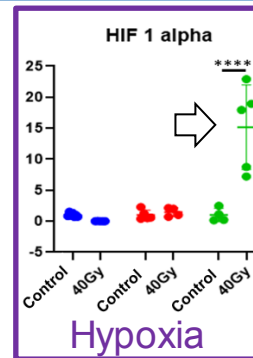
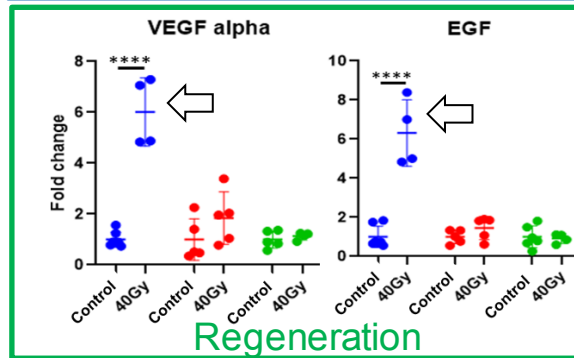
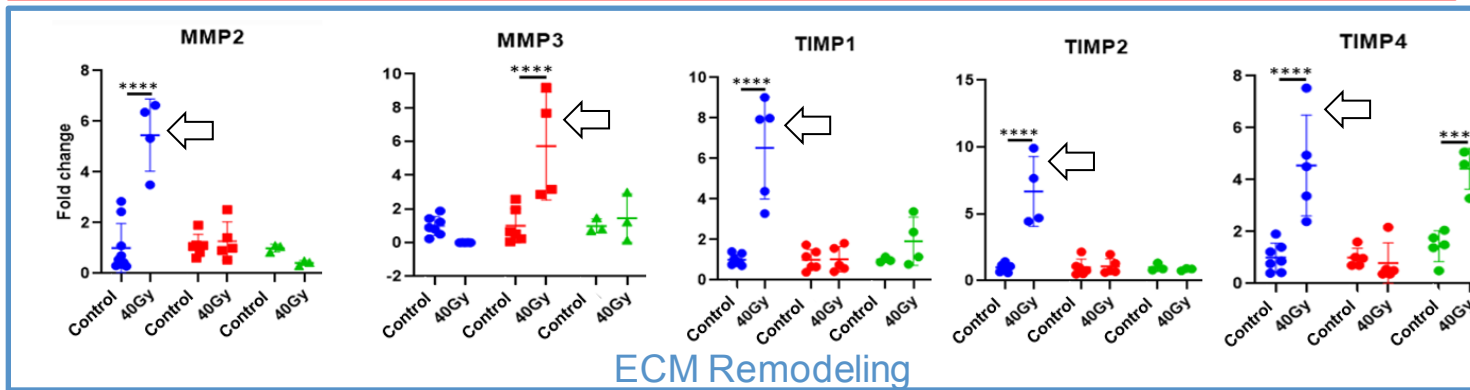
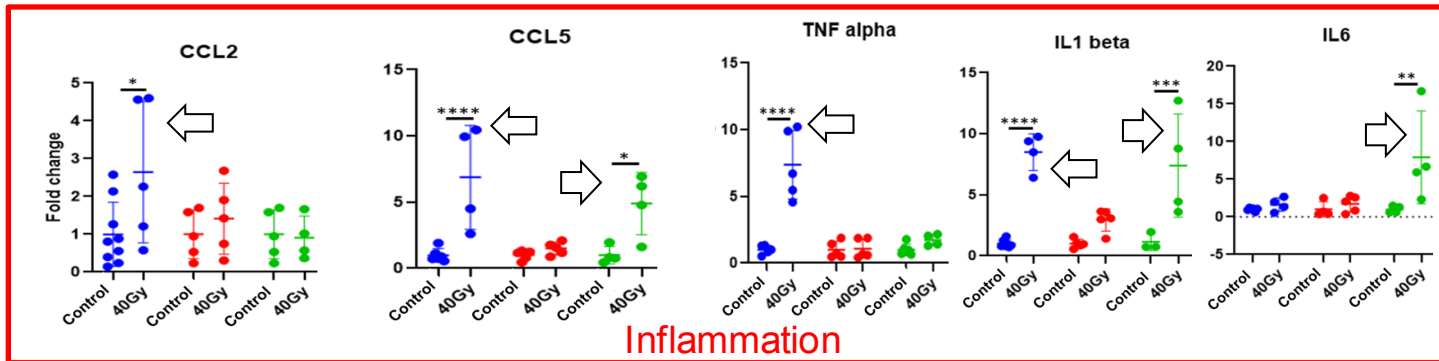


Higher hematuria as a function of dose from 40Gy



Earlier hematuria from 40 Gy

Transcriptomics studies: inflammation

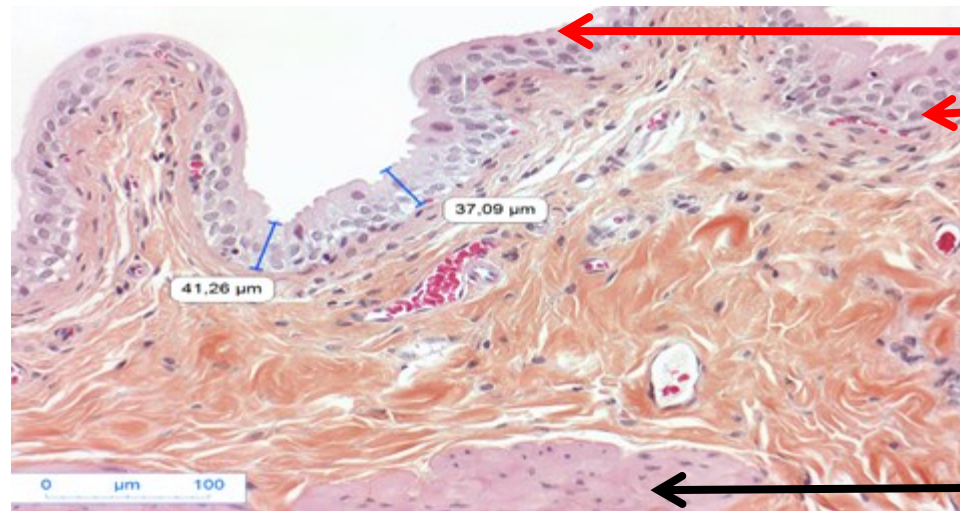


● 3 mois
● 4 mois
● 6 mois

*: p-value < 0,05
**: p-value < 0,01
***: p-value < 0,001
****: p-value < 0,0001

At 3 months increase in the expression of genes associated to inflammation, regeneration, ECM remodeling and fibrosis
At 6 months increase in the expression of genes associated to inflammation, hypoxia but not ECM remodeling and fibrosis

Tissue study: urothelium damages (HES)



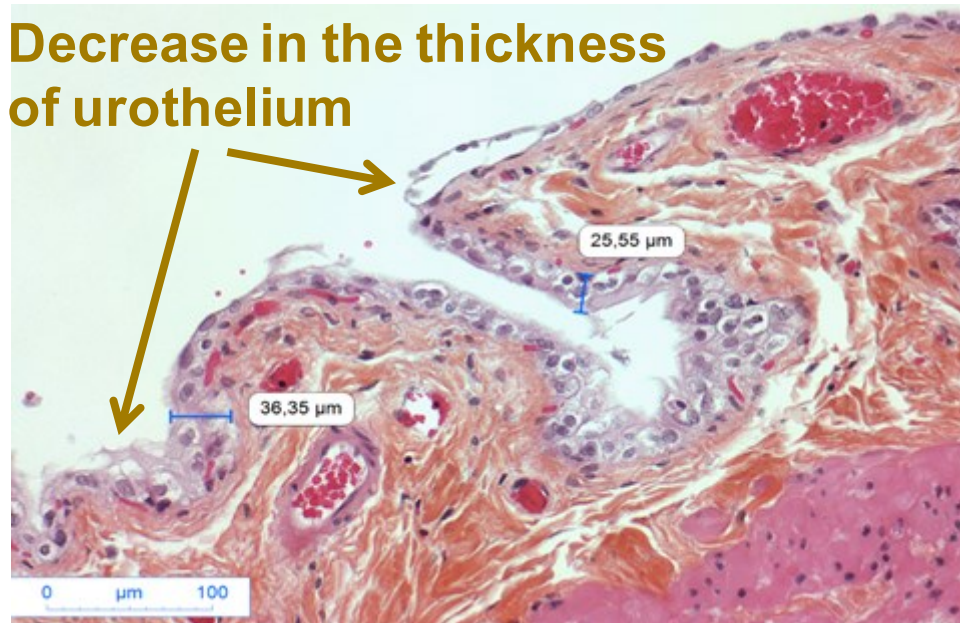
Superficial cells
Basal cells
Urothelium

Extra cellular matrix

Detrusor

Unirradiated bladder, 6 months, X 200

Decrease in the thickness of urothelium



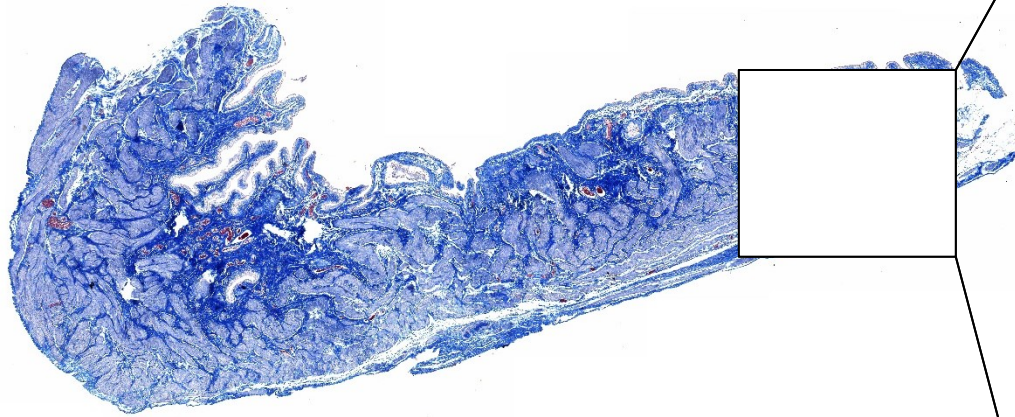
Loss of superficial cells

Degradation of the urothelium structure

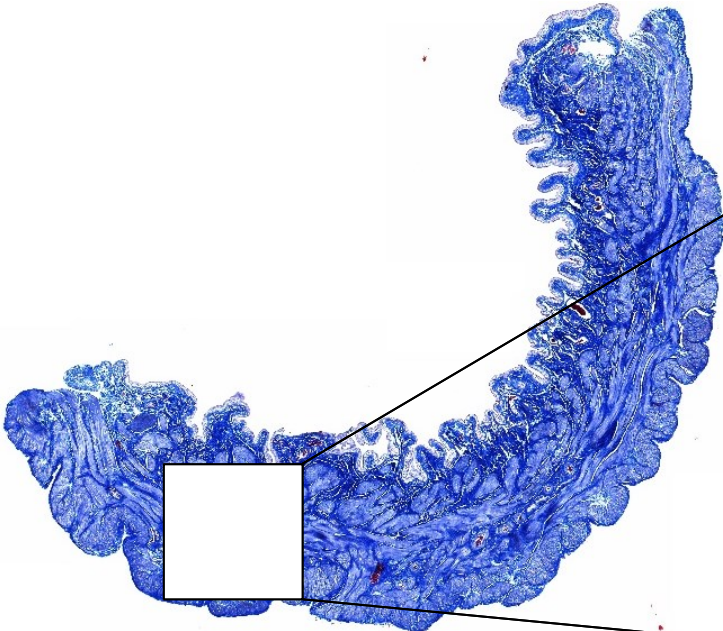
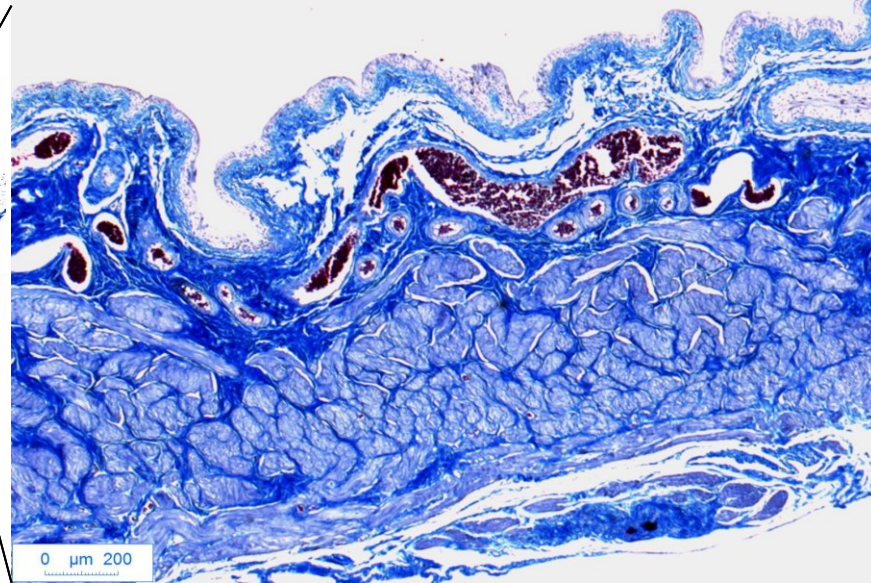
Bladder irradiated at 40 Gy, 6 months, X 200

HES: Hematoxyline, Eosin, Safran

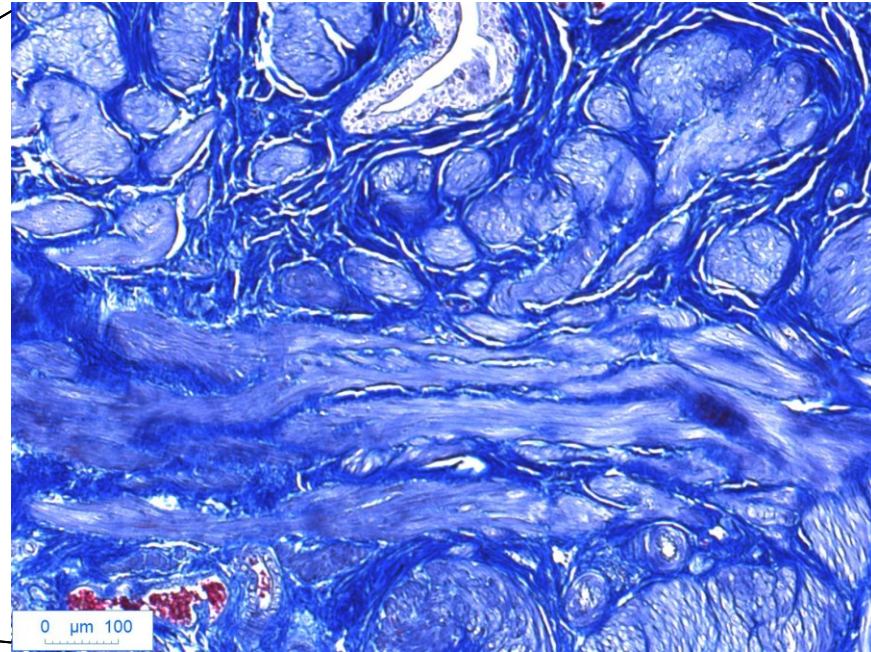
Tissue study: Fibrosis (Trichrome of Masson)



Unirradiated bladder, 6 months, X 100



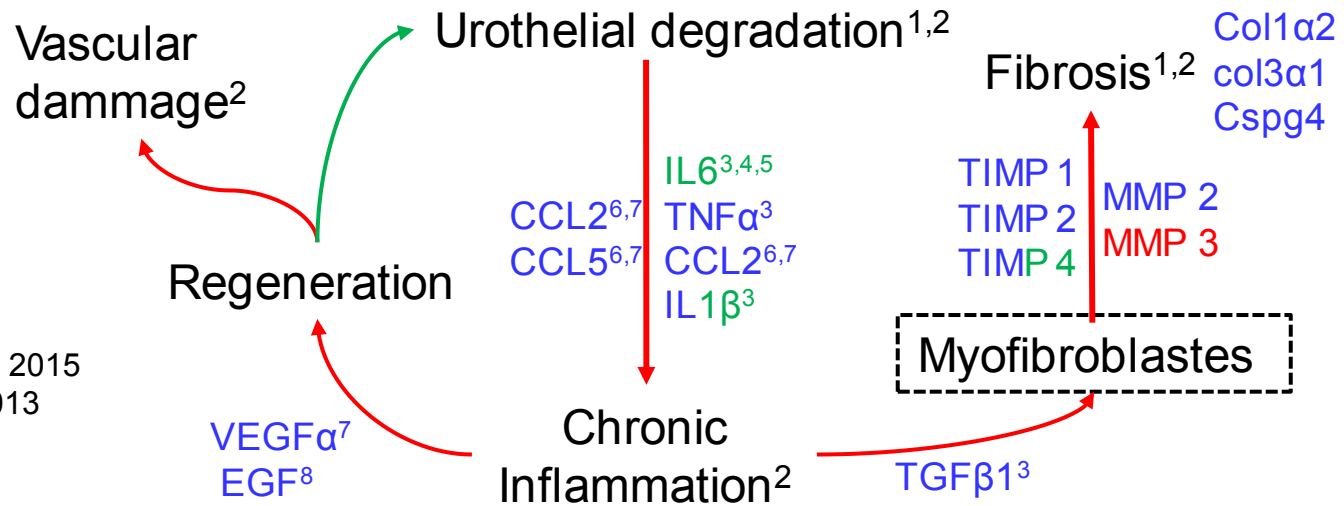
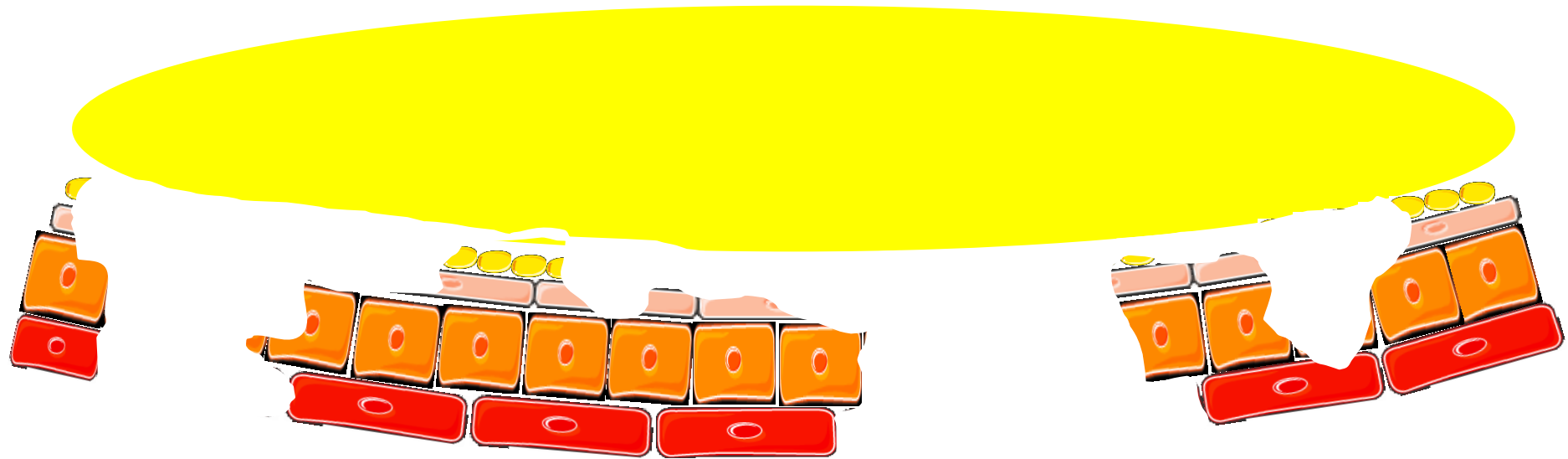
Bladder irradiated at 40 Gy, 6 months, X 100



Tissue study: Fibrosis (Trichrome of Masson)

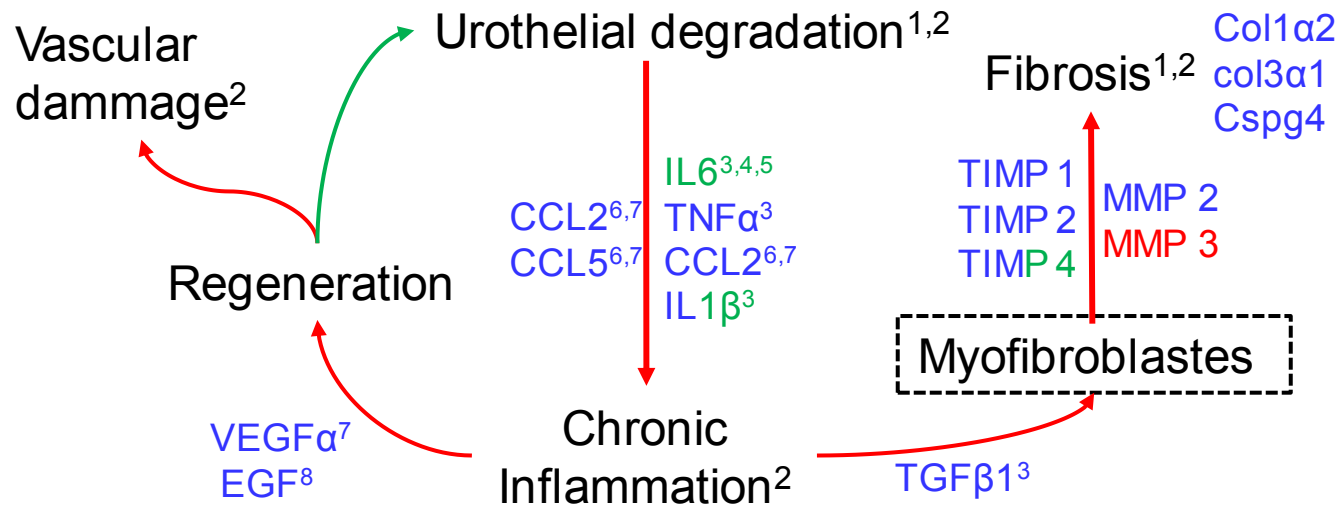
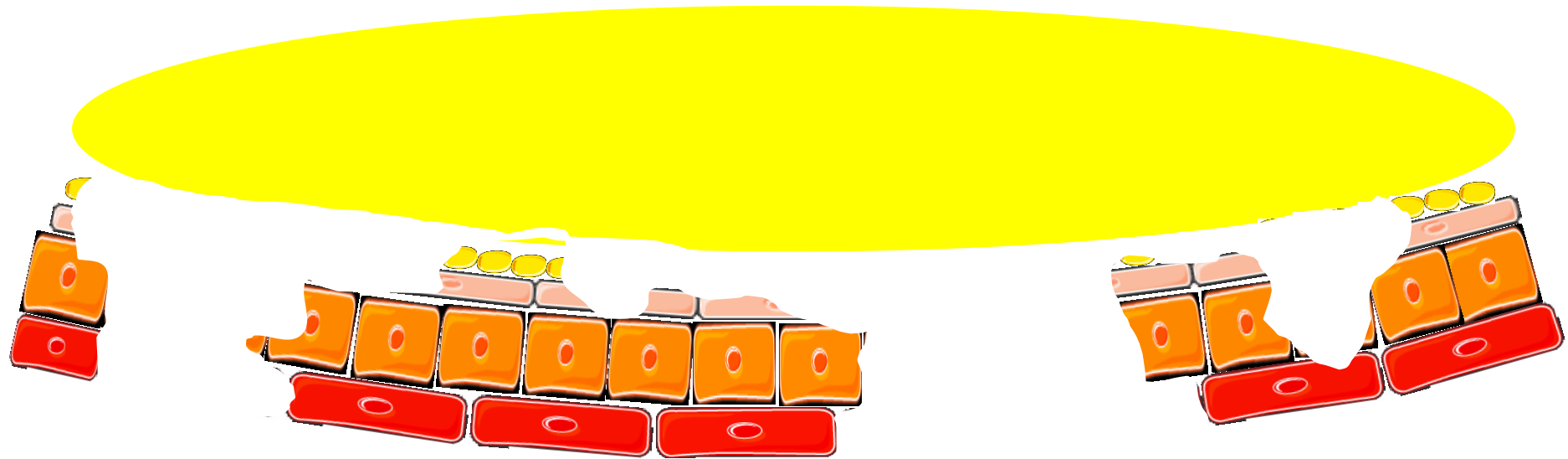
initiation of fibrosis at 6 months after 40Gy irradiation

Conclusions: Global mechanism

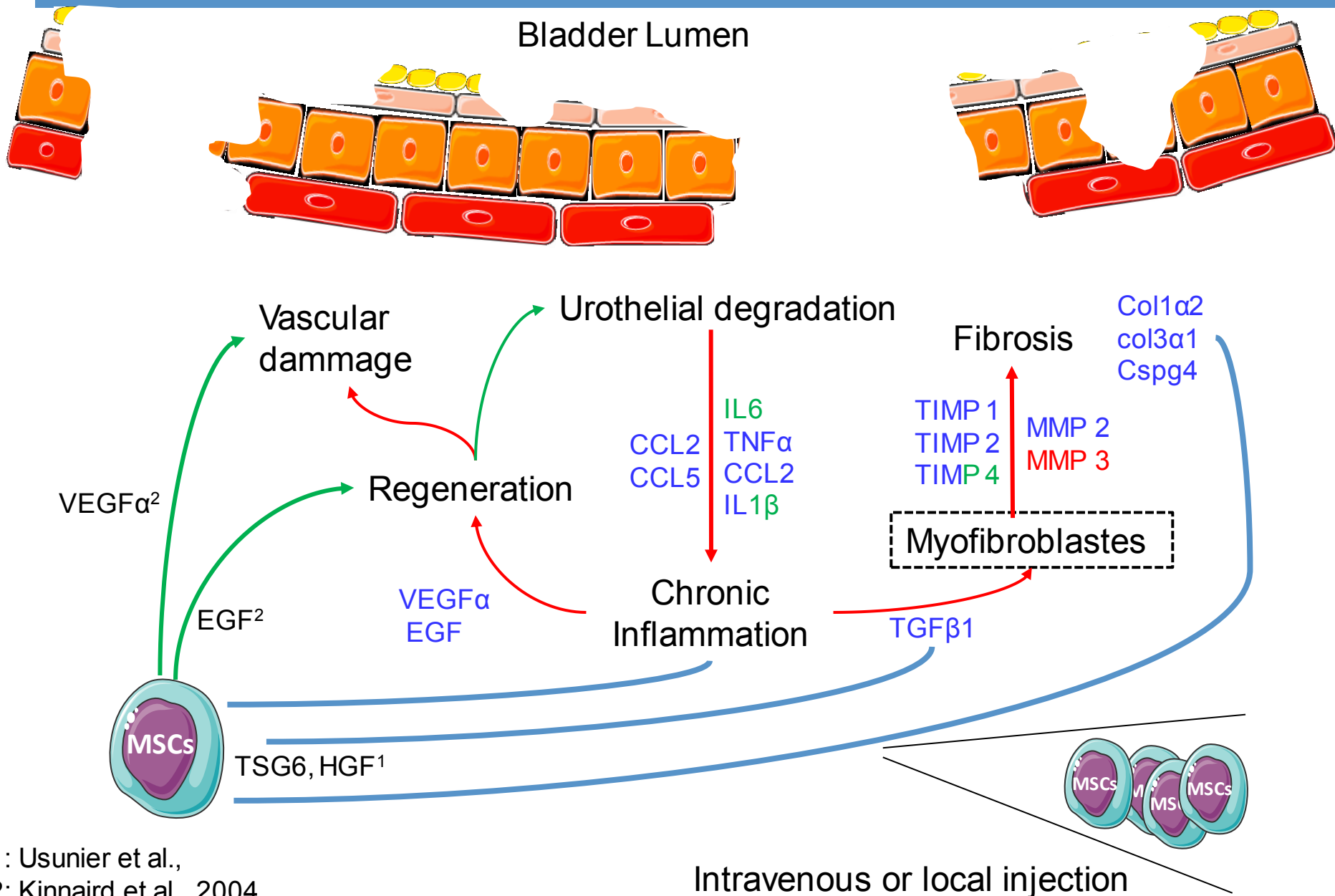


- 1: Zwaans et al., 2016
- 2: Rajaganapathy et al., 2015
- 3: Abdo-Salem et al., 2013
- 4: Chen et al., 2018
- 5: Erickson, 2001
- 6: Soehnlein et Lindbom, 2010
- 7: Furuta et al., 2017
- 8: Song et al., 2015

Conclusions: Global mechanism



Study of MSCs action : principal hypothesis



- 1: Usunier et al.,
- 2: Kinnaird et al., 2004

Thank you for your attention

Director thesis: Chapel A.

Acknowledgement:

Buard V.
Demarquay C.
François A.
Linard C.

Mathieu N.
Milliat F.
Squiban C.
Tarlet G.



Denais Lalieve D.
Granger R.
Sache A.

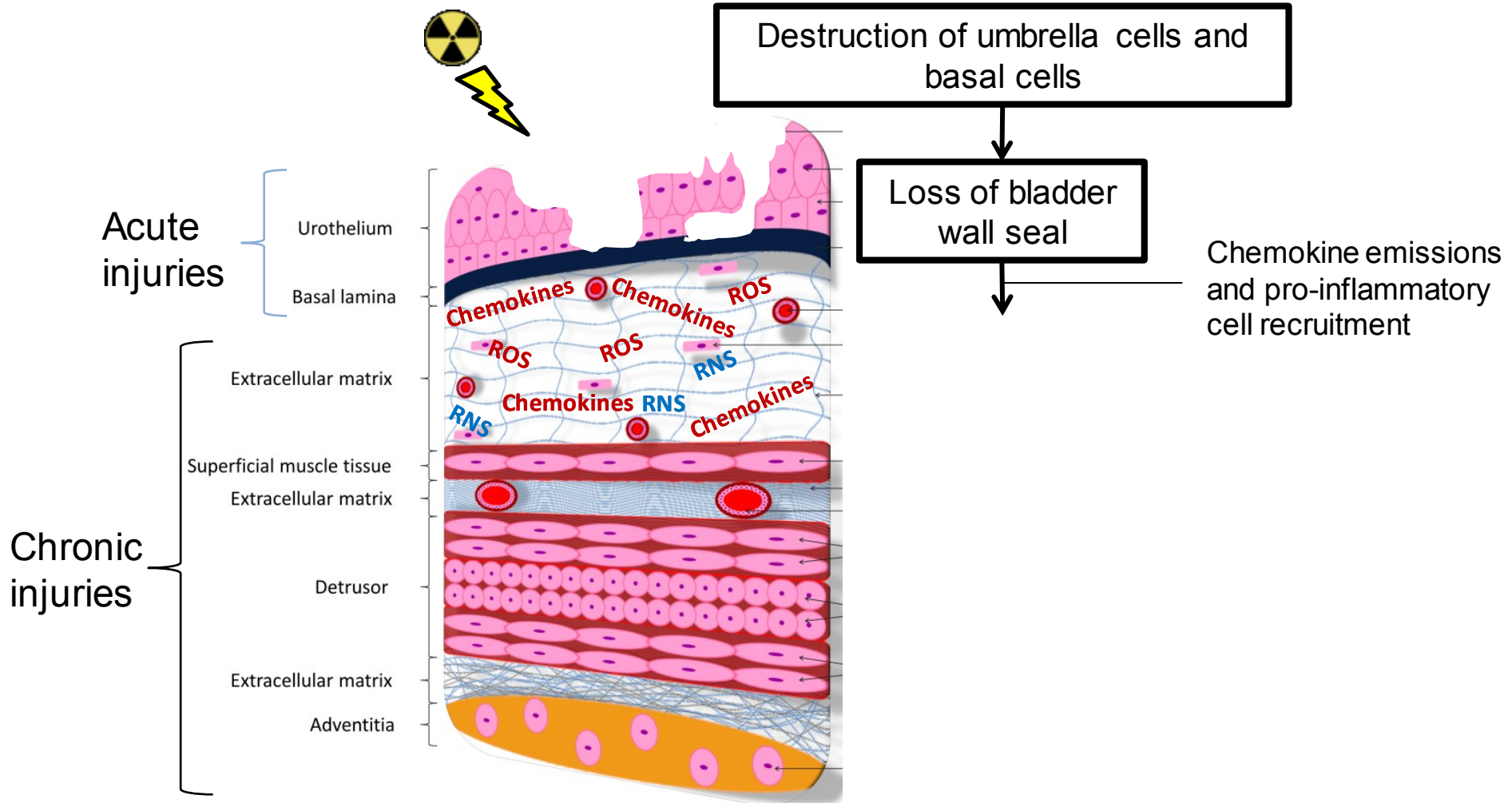
**Radiobiology of Medical
Exposure Laboratory
(LRMed)**

**Support Group for Research
and Animal Ethics
(GSEA)**

Dos Santos M.
Soudi M.
Gaouaoui H.

**Radiobiology of Accidental Exposure Laboratory
(LRAcc)**

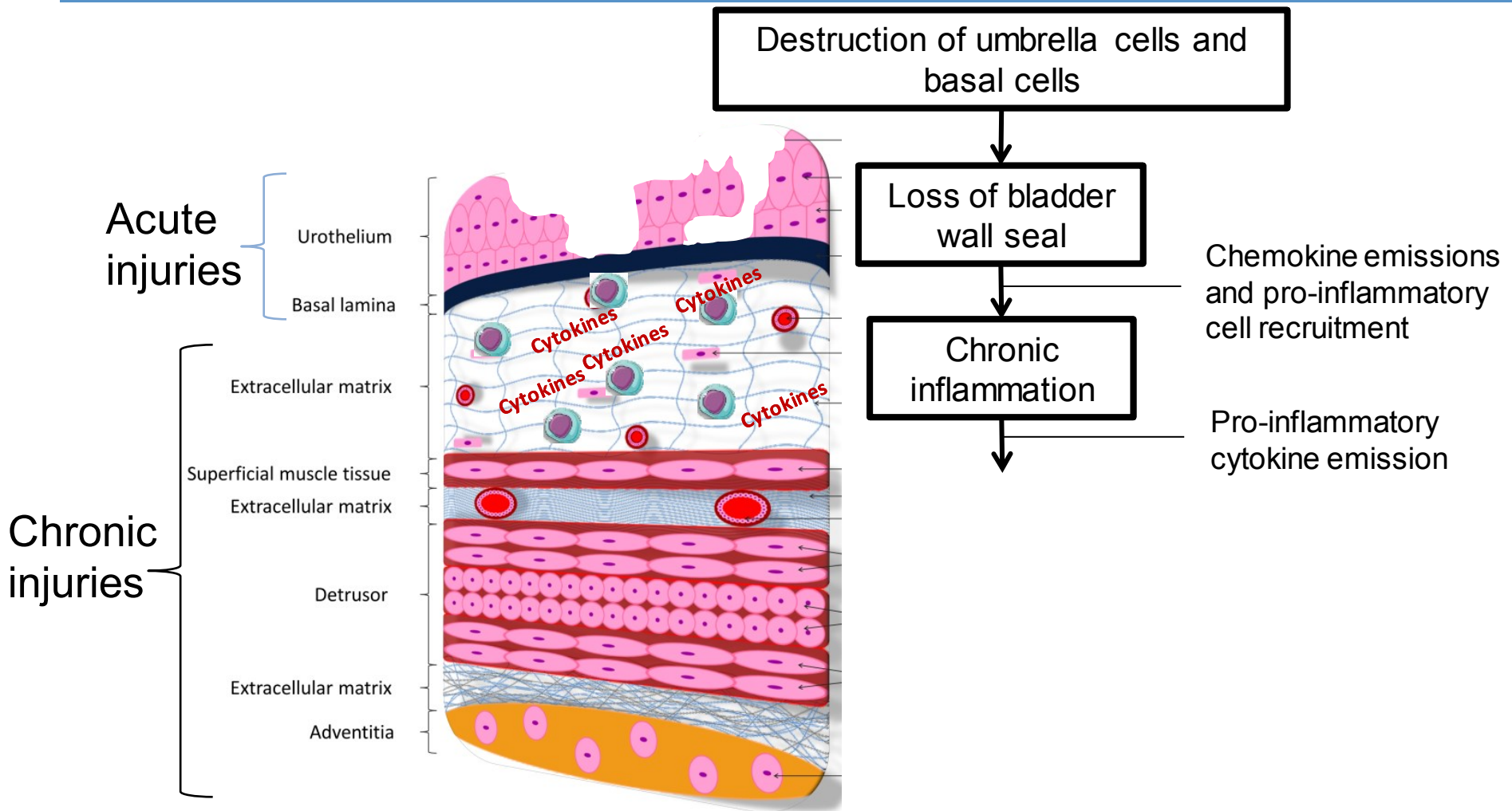
Introduction: Mechanism of Chronic Radiation Cystitis (CRC)



ROS= reactive oxygen species

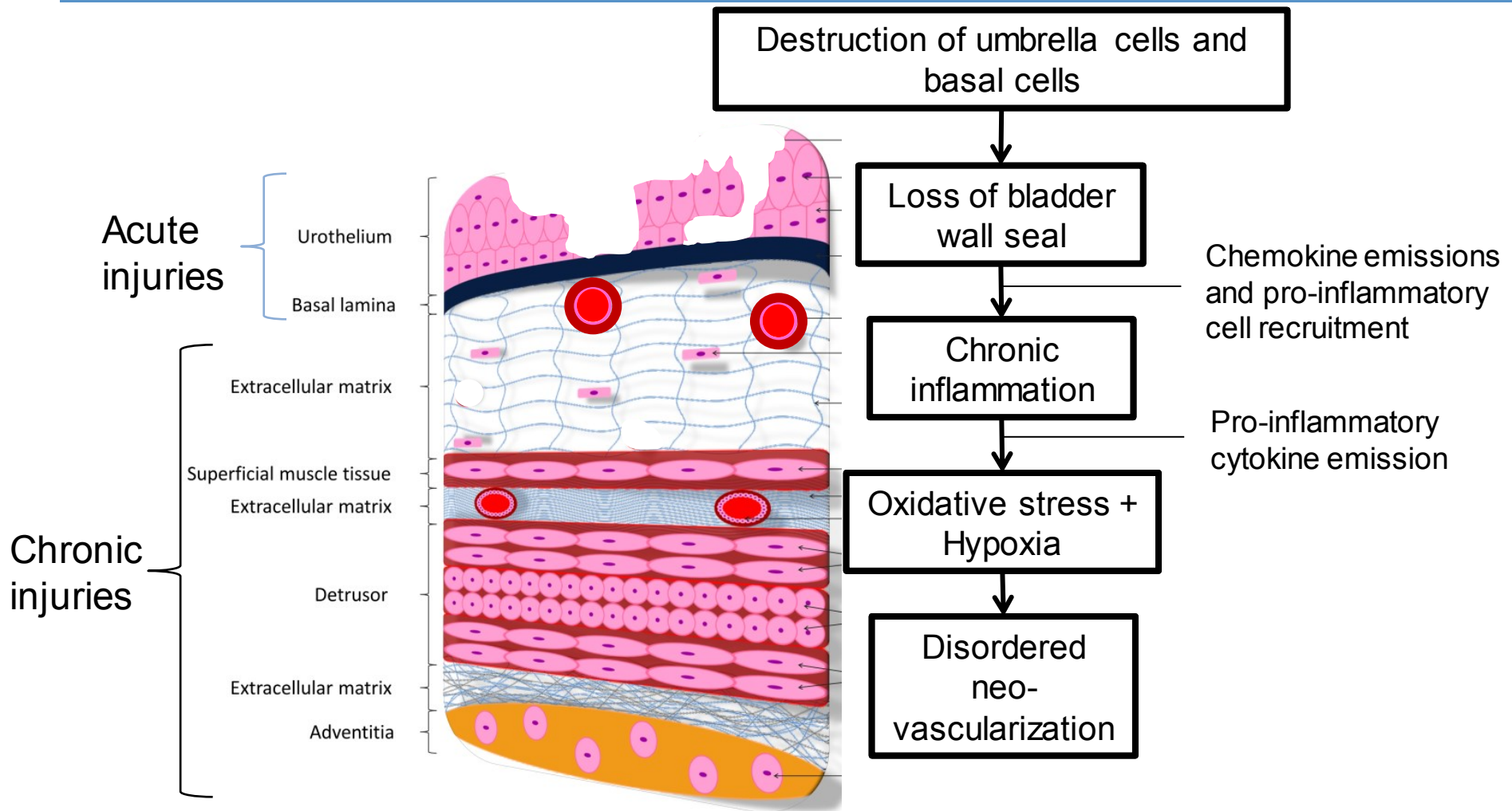
RNS= reactive nitrogen species

Introduction: Mechanism of CRC

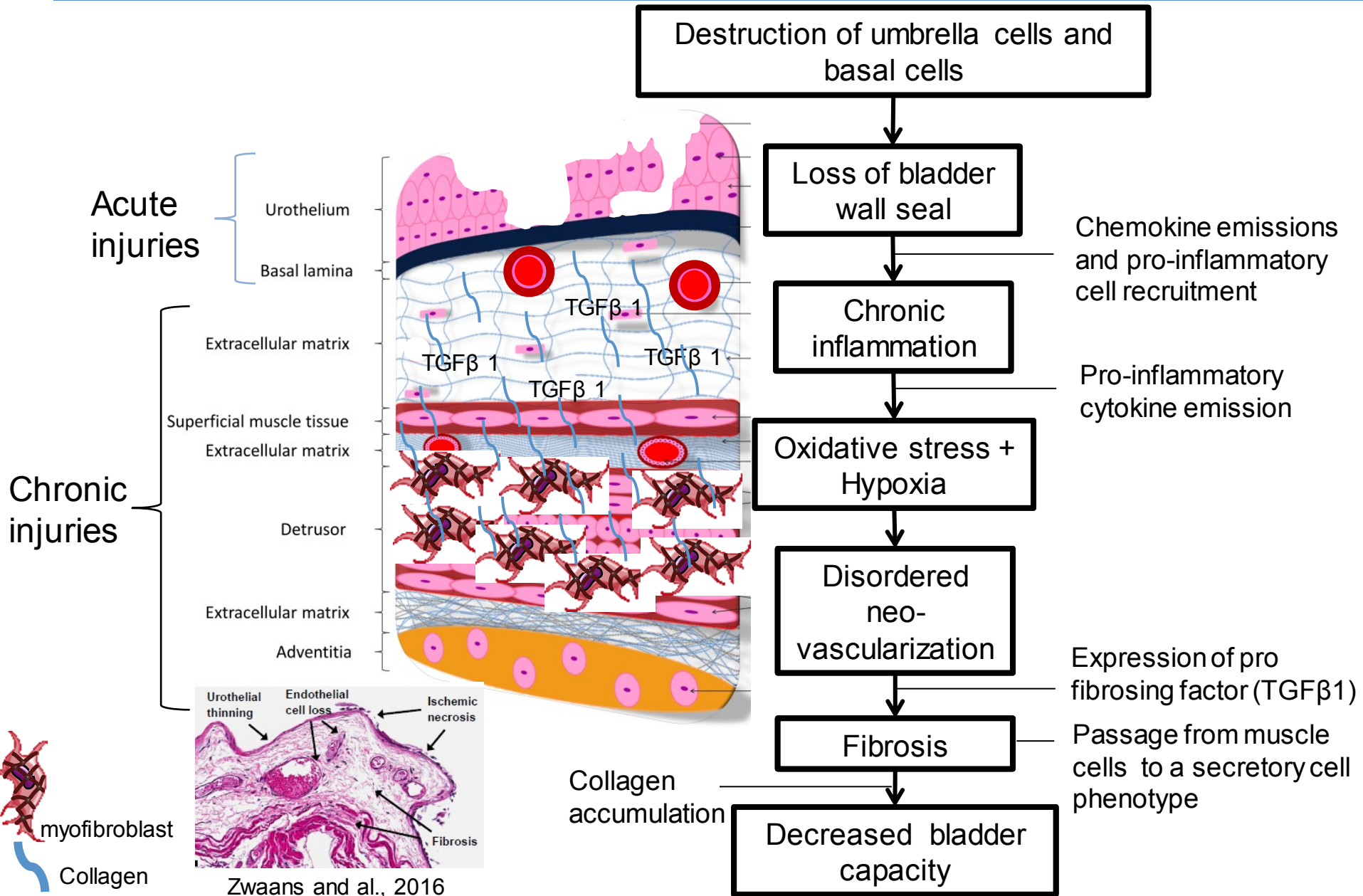


Lymphocyte

Introduction: Mechanism of CRC



Introduction: Mechanism of CRC



Zwaans and al., 2016

Grade of hemorrhagic cystitis

Table 1 | RTOG/EORTC grading of hematuria events

Hematuria morbidity	Grade 1	Grade 2	Grade 3	Grade 4	Grade 5
Acute hemorrhagic radiation cystitis (RTOG scale)	NA	NA	Gross hematuria with or without clot passage	Hematuria requiring transfusion	Death from uncontrolled hematuria
Late hemorrhagic radiation cystitis (RTOG/EORTC scale)	Minor telangiectasia (microscopic hematuria)	Generalized telangiectasia (macroscopic hematuria)	Severe generalized telangiectasia (macroscopic hematuria)	Severe hemorrhagic cystitis	Death from uncontrolled hematuria

Abbreviations: EORTC, European Organisation for Research and Treatment of Cancer; RTOG, Radiation Therapy Oncology Group.

Traitement:

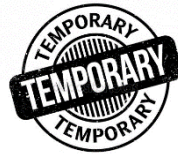Intravesical instillation :

- Aluminium
- Formalin
- Alun
- Pentosan polysulfate

Traitement hyper bar

Smit SG, Heyns CF. [Management of radiation cystitis](#). Nat Rev Urol. 2010 Apr;7(4):206-14. doi: 10.1038/nrurol.2010.23. Epub 2010 Mar 9. Review. PubMed PMID: 20212517.

Introduction: Side effects and treatment



Treatments :


Oral or parental agents



- Sodium pentosan polysulfate
- Tetrachlorodecaoxide
- Pentoxifylline



 Hematuria

 Low and very short-term effects


Cystoscopy



- Fulguration
- Botulinum toxin



 Hematuria

 Low and very short-term effects

Intravesical installation



- Aluminum salts
- Silver nitrate
- Formalin



 Hematuria

  Pain

No effect after stopping treatment

Treatment :

Hyperbaric oxygen therapy (HBOT)


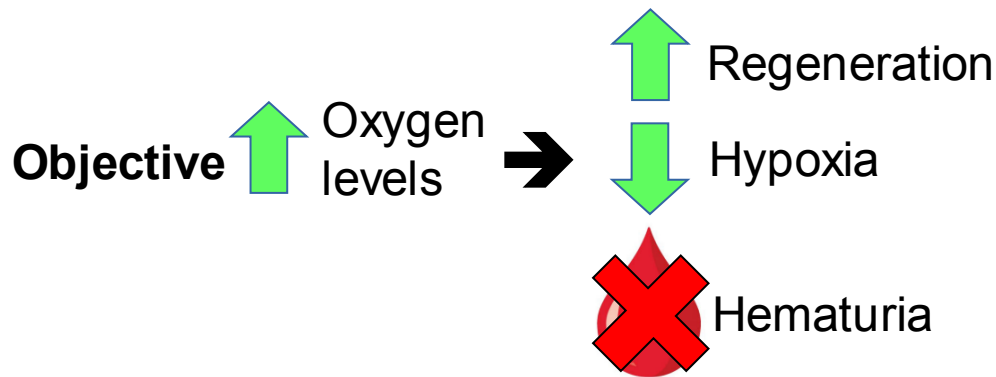


Figure 1 Hyperbaric oxygen chambers

a | Newly delivered hyperbaric chamber prior to installation. b | Hyperbaric oxygen chamber with control panel.

Smit and Heyns, 2010

Disadvantage

- Long, adequate and rare equipment, patient monitoring
- Not very effective, effects over a few months, year

↓
30–40 sessions, 100% oxygen,
for 80–90 min, 2 months

↓
75% improvement within 6 months

Need for a relevant model and curative treatments

Rigaud et al., 2010
Orcasson et al., 2019

Method of irradiation: Local bladder irradiation

Objective:

- Creation of a model of chronic radiation cystitis in rats
 - New method of irradiation using SARRP
- ➔ Irradiator for small animals (similar characteristic to clinical models)

SARRP

- Small Animal Radiation Research Platform (SARRP, Xstrahl)
- Single or multi beam(s)
- Combined with scanner imaging and treatment plan software (MuriPlan) => stereotaxy
- 4 available field sizes: **10x10 mm²**, 7x7 mm², 3x3 mm² and Ø 1 mm



Picture of SARRP
Dr M. Dos Santos, LRAcc

Method of irradiation: Local bladder irradiation

Method of irradiation: Local bladder irradiation



Verify (Step 5 of 7)

A) Isodoses

Prescribed dose: 2000 cGy (IsoC)

Show isodose surfaces (3D):

Show isodose lines (2D):

Relative Dose

Relative Dose
0 10%
1 20%
2 60%
3 80%
4 95%

Compute Isodoses

B) Compute Dose Volume Histogram Statistics

Current: SARRPDose

Label	Volume (cc)	Mean (cGy)	Min (cGy)	Max (cGy)
1 New	0.206823	2022.79	1792.4	2247.59

Compute DVH

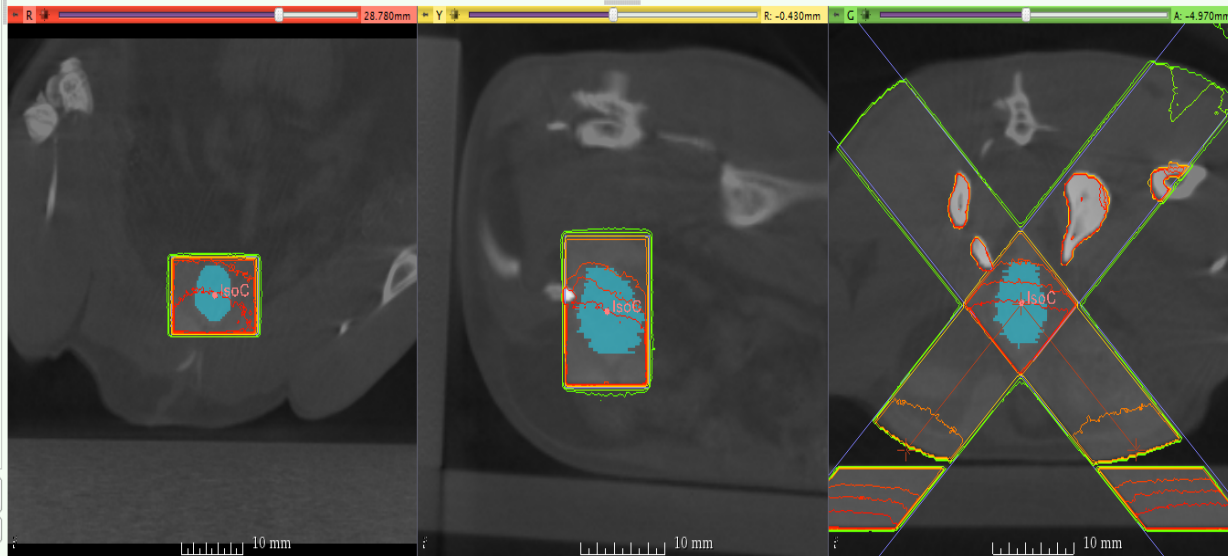
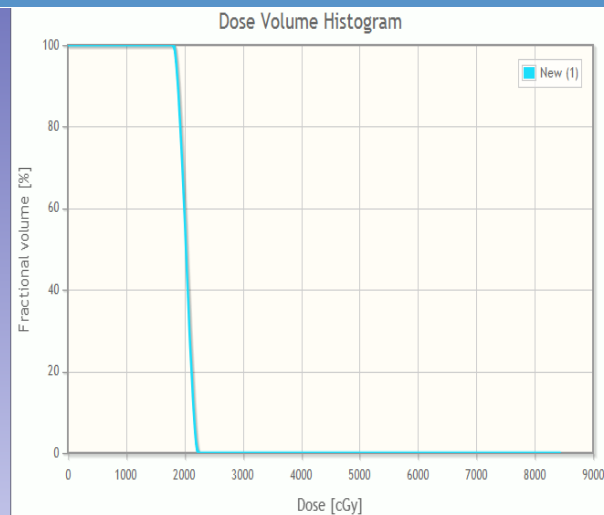
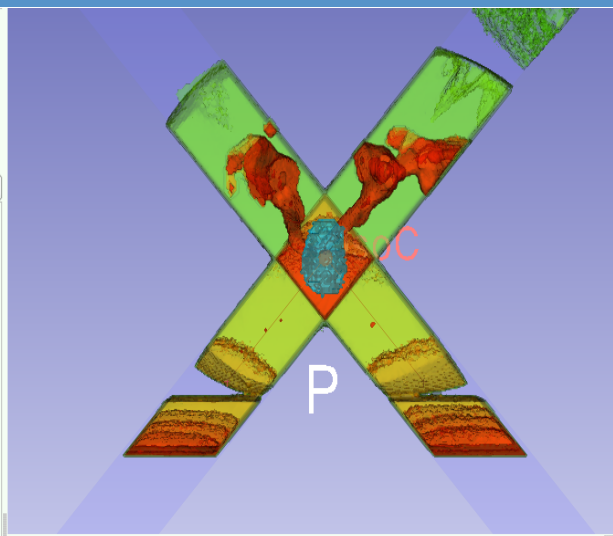
C) Plan

TPS_2017-09-04_10_17_20

Treatment Planning

Execute

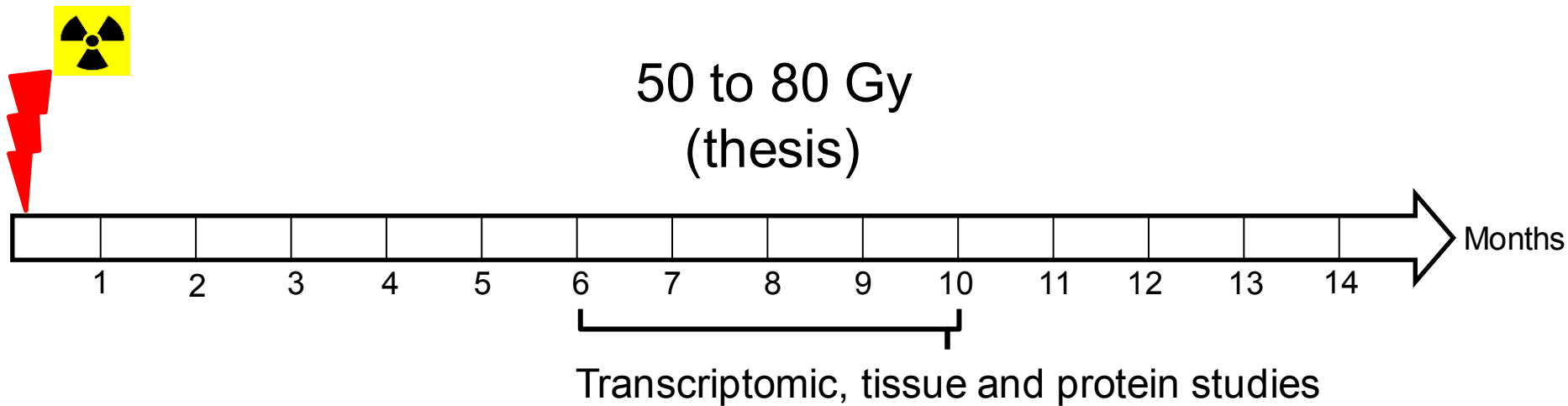
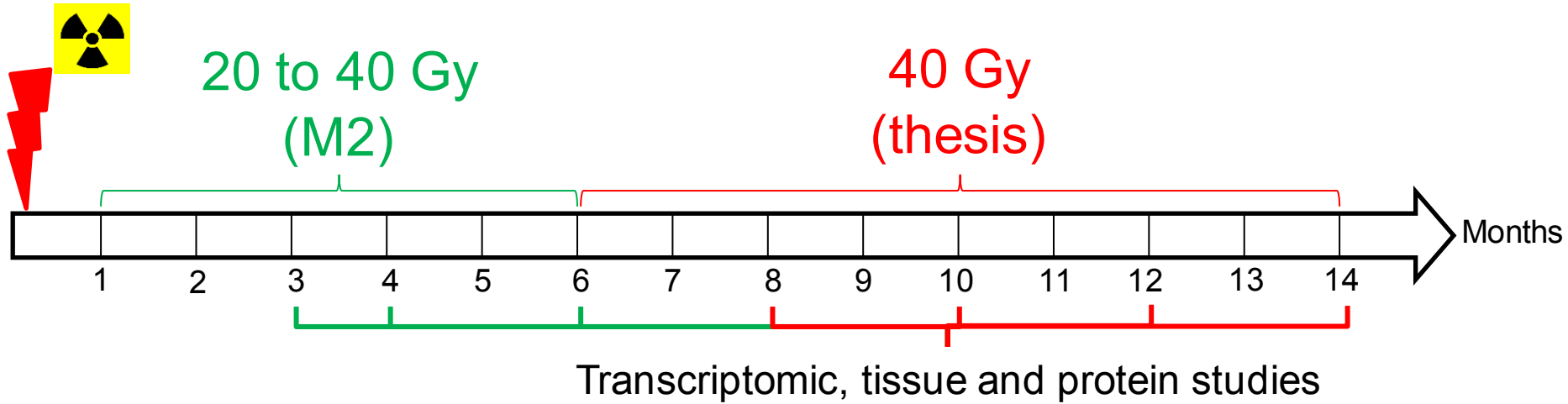
Data Probe



- 2 irradiation beams

- Maximized the dose on the bladder and minimized the dose on surrounding tissues

Protocol: Animal groups



Pre-clinical model of CRC



In Rats receiving (irradiation totale vessie)

✓ 35 Gy, Urothelium damage 48h (Kanai et Eperly 2002)

✓ 20 Gy killed 16 h to 14 days later (Giglio et al. 2012)

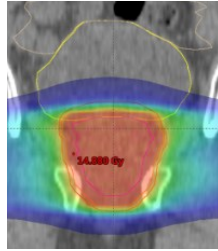
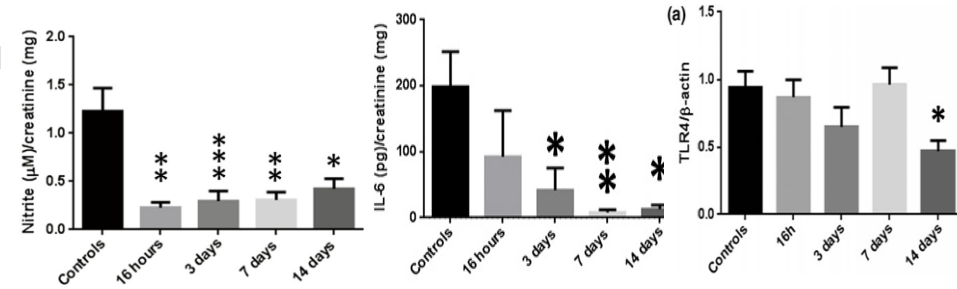
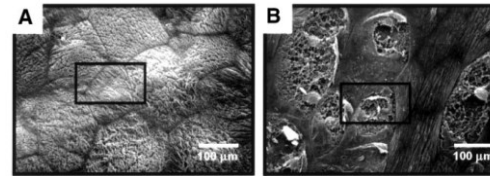
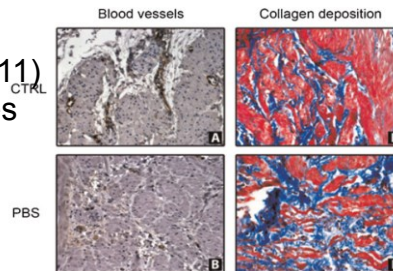
- Bladder irradiation increased the expression of IL-1 and collagen in the bladder, while TLR4 and IL-6 expressions were decreased in the urothelium concomitantly with a decrease in mast cells in the submucosa and urine levels of IL-6 and nitrite.

✓ 20 Gy all 29 days (Oscarsson 2017)

- Bladder irradiation increased the expression of 8-OHdG, SOD2, HO-1, NRF α , IL-10, TNF and tended to increase TGF- β

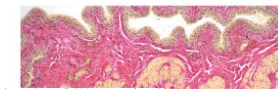
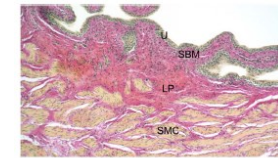
✓ 20Gy killed 1,5 and 3 months (Soler 2011)

- 1,5 month vascular abnormalities
- 3 months collagen deposition

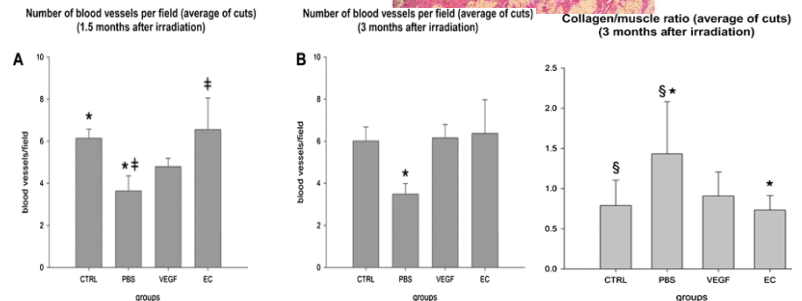


Jurado-Bruggeman et al.; 2017

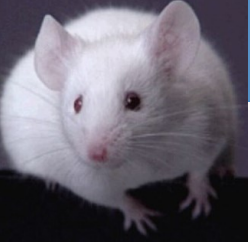29 days Urothelium, SBM=Submucosa, LP=Lamina Propria, SMC=Smooth Muscle Cell layer



No significant macro or microscopically changes in the urinary bladder could be observed by bladder irradiation



✓ 20 Gy all exhibited small and contracted bladders 6 months after treatment (Vale JA 1993)



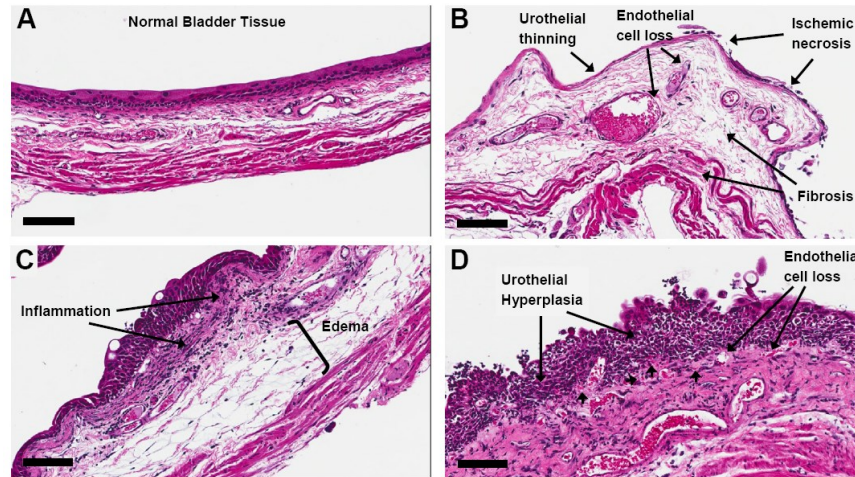
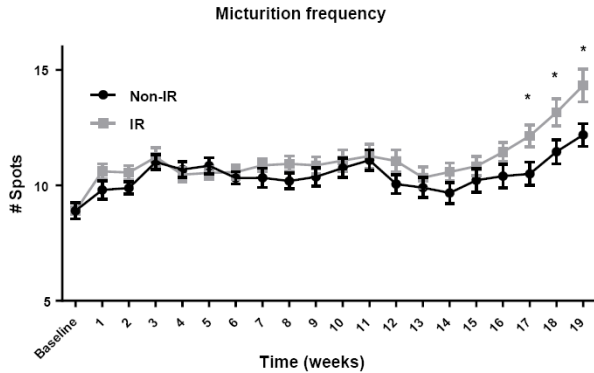
In mice receiving

✓ 15 Gy , 20% developed fibrotic bladders,

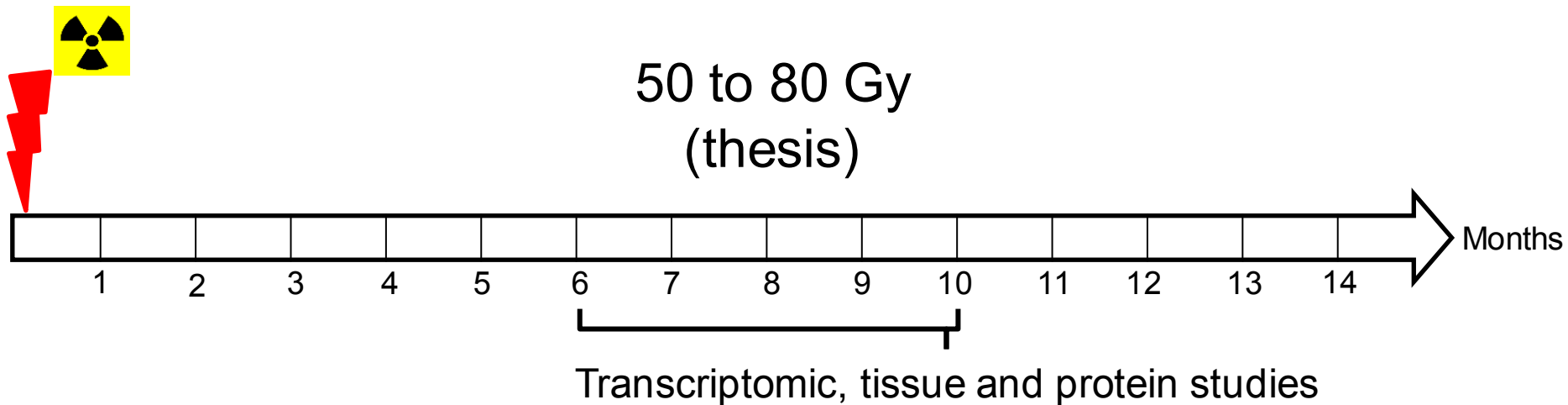
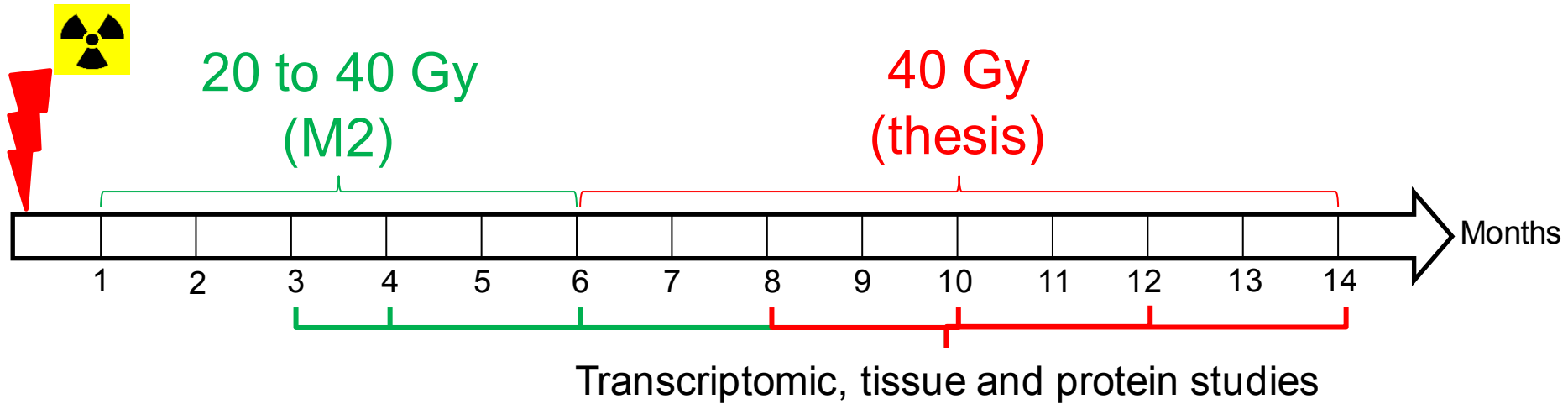
✓ 15–20 Gy exhibited increased frequency and decreased bladder volume (Stewart 1991).

✓ 20 Gy SARP 2 faisceaux ((Zwaans et al. 2016)

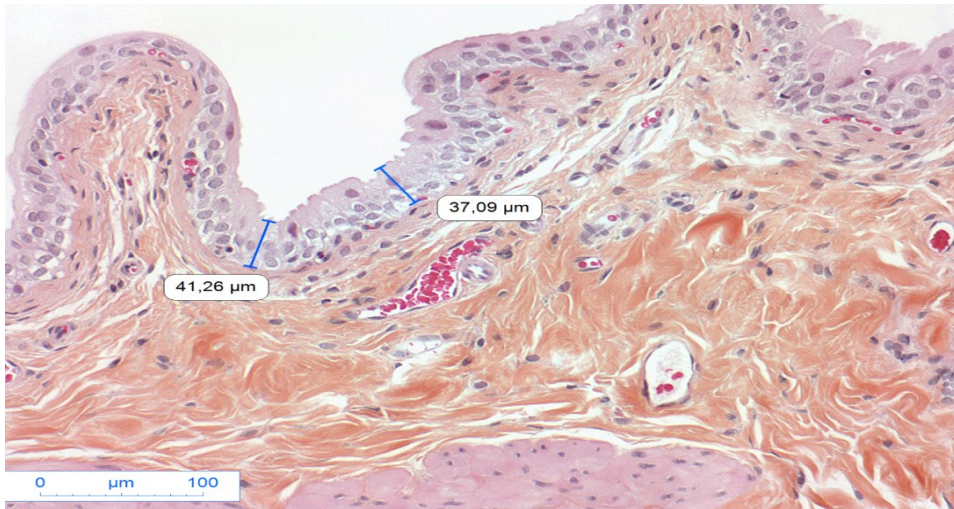
- Starting at 17 weeks after treatment, micturition frequency was significantly higher
- Pathological changes include fibrosis, inflammation, urothelial thinning, and necrosis.
- At a site of severe insult, we observed telangiectasia, absence of uroplakin-3 and E-cadherin relocalization



Protocol: Animal groups

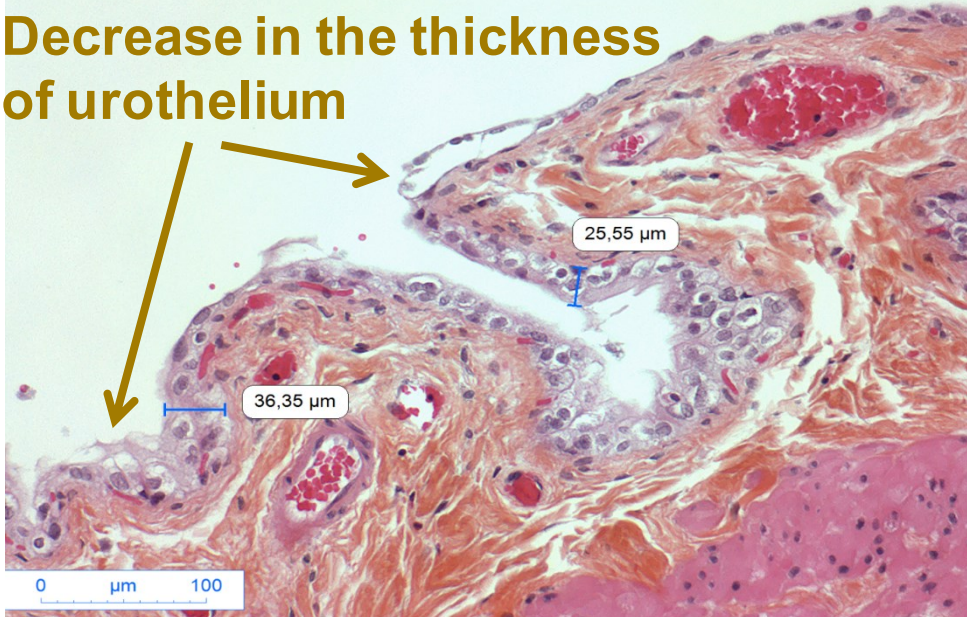


Tissue study: urothelium damages (HES)

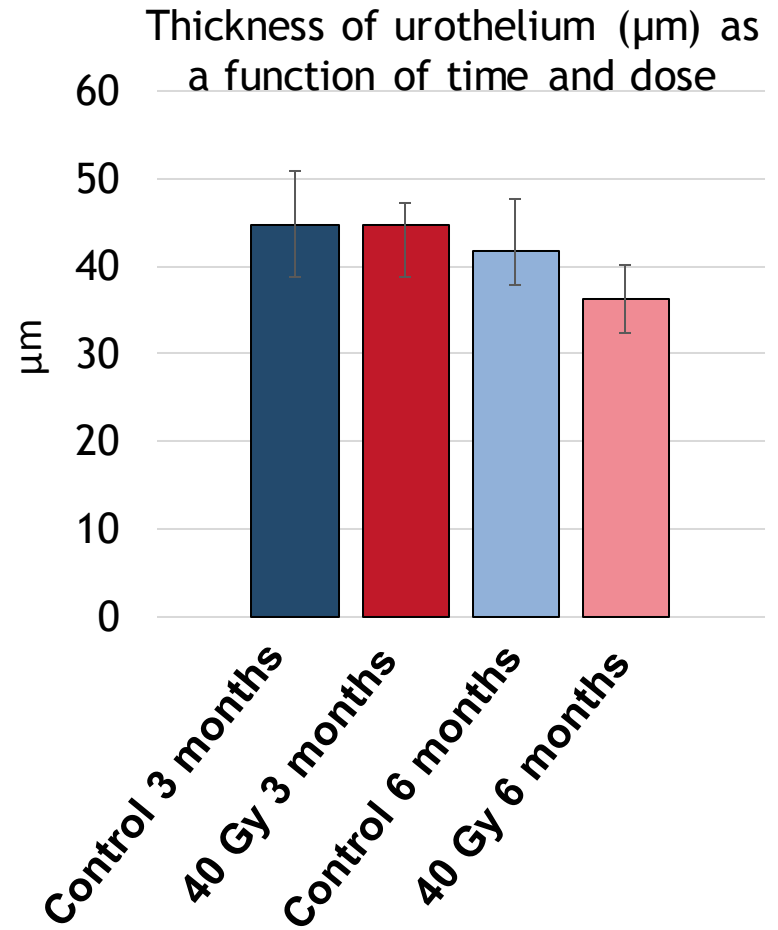


Unirradiated bladder, 6 months, X 200

Decrease in the thickness of urothelium



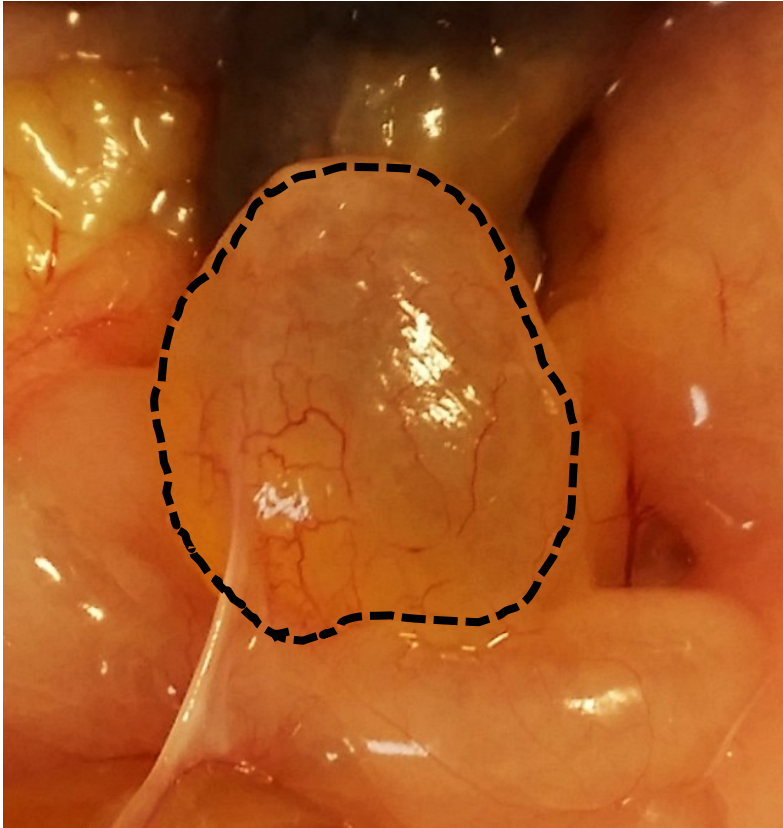
Bladder irradiated at 40 Gy, 6 months, X 200



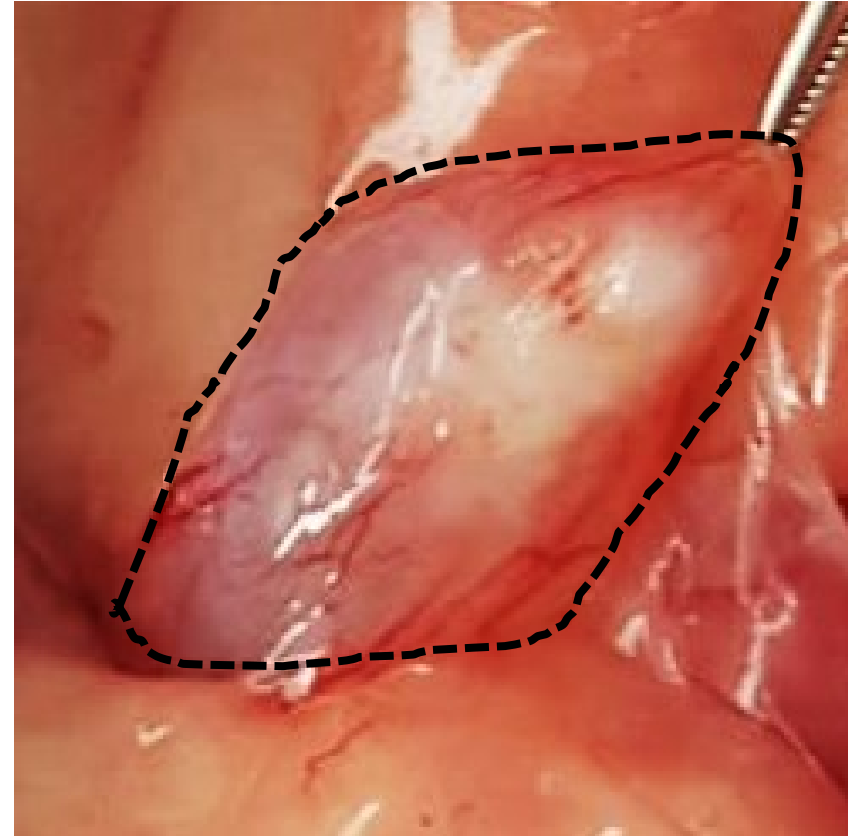
Degradation of the urothelium structure

HES: Hematoxyline, Eosin, Safran

Conclusions:



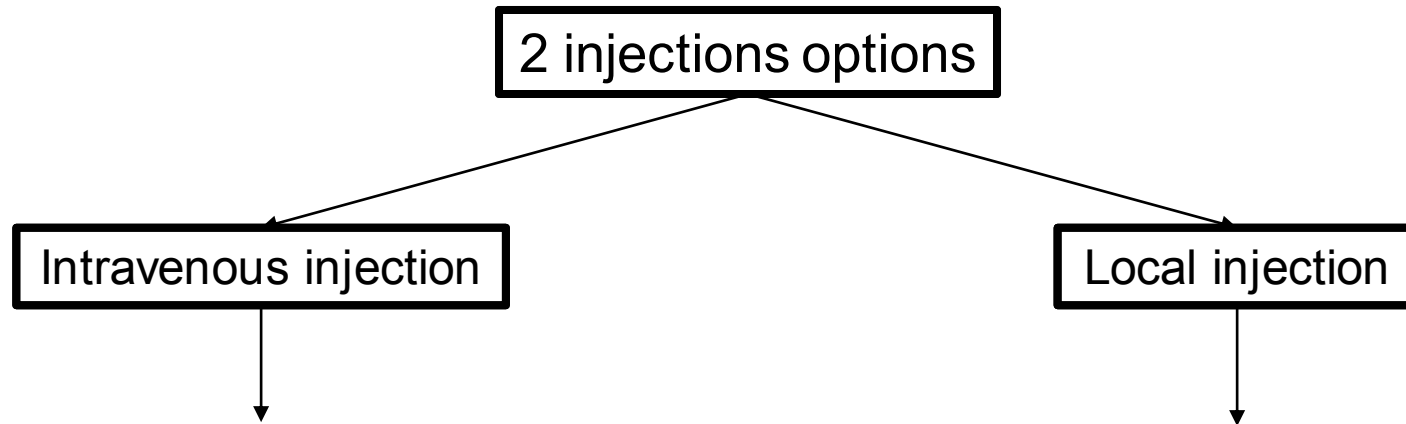
Unirradiated bladder, 10 months



Irradiated bladder, 40Gy 10 months

At 10 months, onset of apparent fibrosis in a few rats 40 Gy

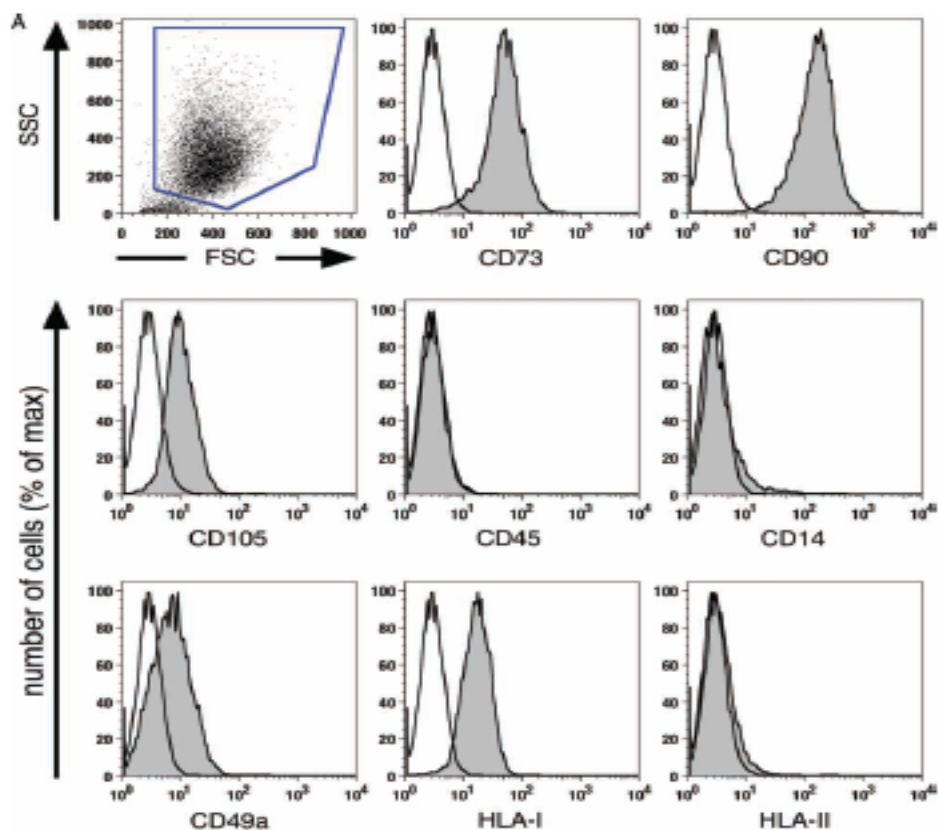
Protocol injection: Chronic Radiation Cystitis



Advantages	Disadvantages
No surgery	Dispersion of cells in body
Use in clinic (Consequences of radiotherapy → PRISME)	Large quantity of MSCs
No damage to bladder	Potentiale toxicity

Advantages	Disadvantages
Potentialize effects of MSCs	Require surgery
Reduce quantity of MSCs	Possible damage to bladder
Reduce toxicity	Not use in clinic

Protocol injection: Characterization of MSCs



International Society for Cellular Therapy
ISCT

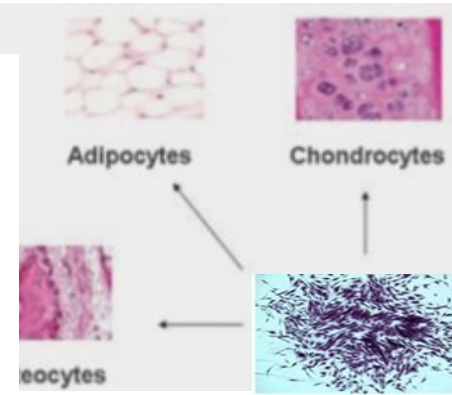
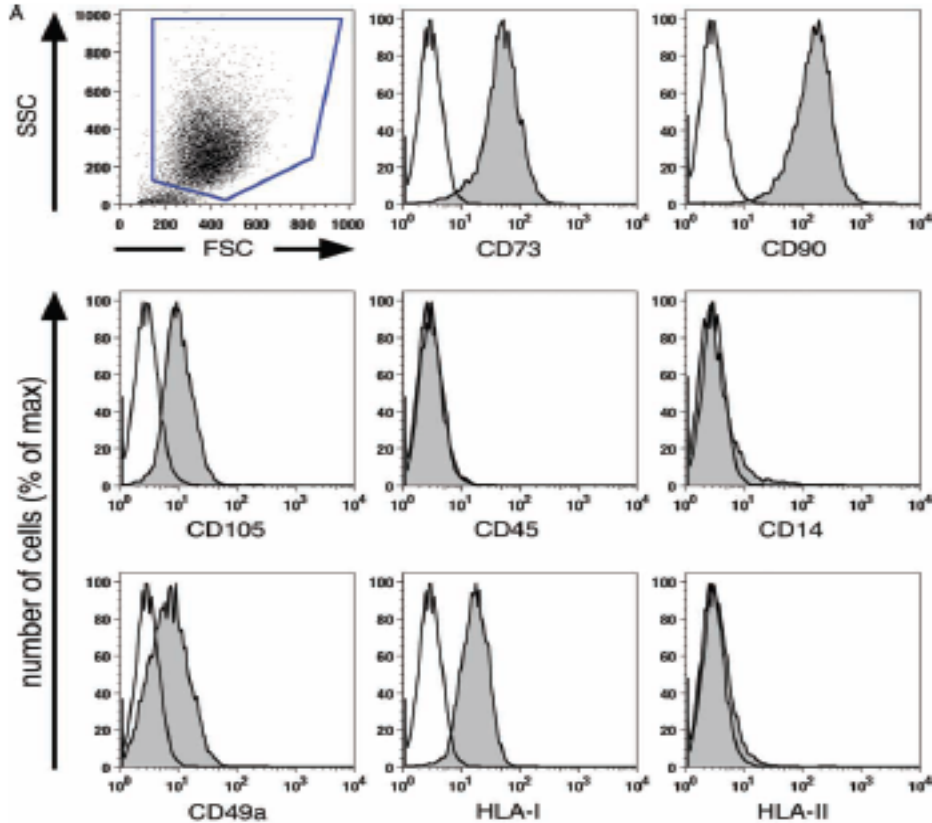
Cytotherapy (2009) Vol. 11, No. 2, 114-128

informa
healthcare

Characterization of bone marrow-derived mesenchymal stromal cells (MSC) based on gene expression profiling of functionally defined MSC subsets

Ariane Tormin¹, Jan C. Brune¹, Eleonor Olsson^{1,2}, Jeanette Valcich^{1,2}, Ulf Neuman³, Tor Olofsson⁴, Sten-Eirik Jacobsen^{1,5} and Stefan Scheduling^{1,6}

Protocol injection: Characterization of MSCs



MSCs

Liu 2009

International Society for Cellular Therapy
ISCT

Cytotherapy (2009) Vol. 11, No. 2, 114-128

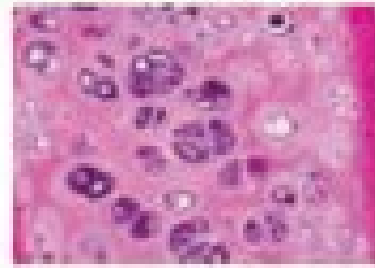

informa
healthcare

Characterization of bone marrow-derived mesenchymal stromal cells (MSC) based on gene expression profiling of functionally defined MSC subsets

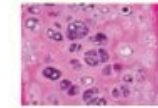
Ariane Tormin¹, Jan C. Brune¹, Eleonor Olsson^{1,2}, Jeanette Valcich^{1,2}, Ulf Neuman³, Tor Olofsson⁴, Sten-Eirik Jacobsen^{1,5} and Stefan Scheduling^{1,6}

Protocol of injection: Characterization of MSCs

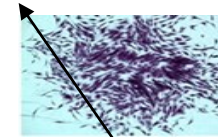
Chondrogenic differentiation
(Bleu Alcian)



Chondrocytes
Osteocytes




Chondrocytes



MSCs


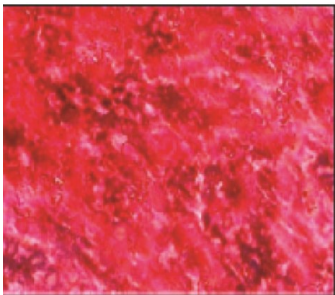
Adipogenic differentiation
(Noir Soudan IV)




Adipocytes

Liu 2009

Osteogenic differentiation
(Von Kossa et Alizarin)



Osteocytes



Intestin grêle	Dose maximale de 50 Gy Dose maximale de 40 Gy sur un grand volume
Estomac, duodénum	Dose maximale de 45 Gy Dose maximale de 54 Gy dans un petit volume
Vessie	$V_{60} \leq 50\%$ $V_{70} \leq 25\%$
Cols, têtes fémorales, grand trochanter	$V_{50} \leq 10\%$
Rectum (paroi rectale)	$V_{60} \leq 50\%$ $V_{70} \leq 25\%$ $V_{74} \leq 5\%$

INCa: Dose de tolérance des principaux organes à risque et des tissus sains

Collection [Outils pour la pratique des médecins généralistes - Du diagnostic au suivi](#)

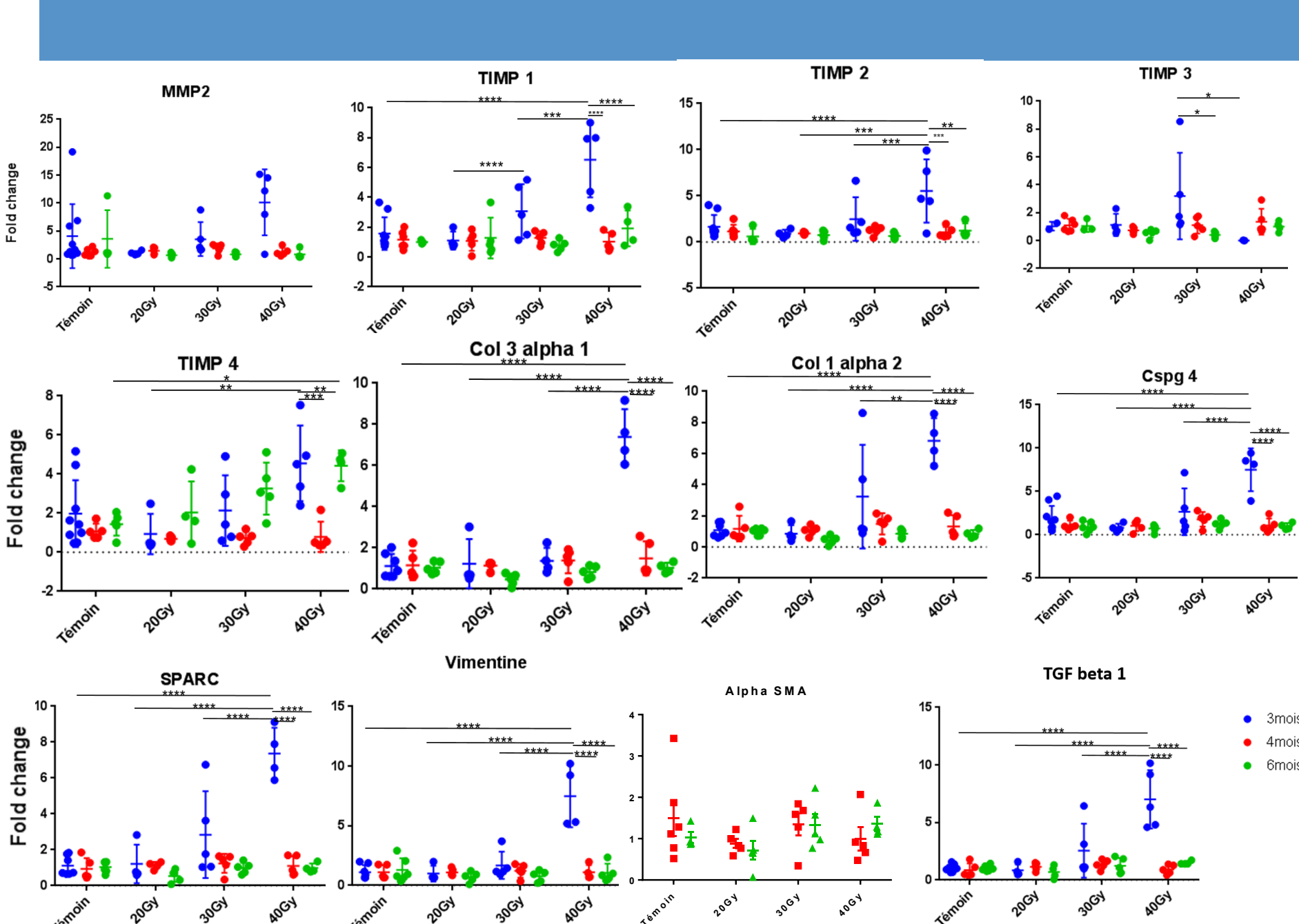
Référence : BRORADPRO08F4

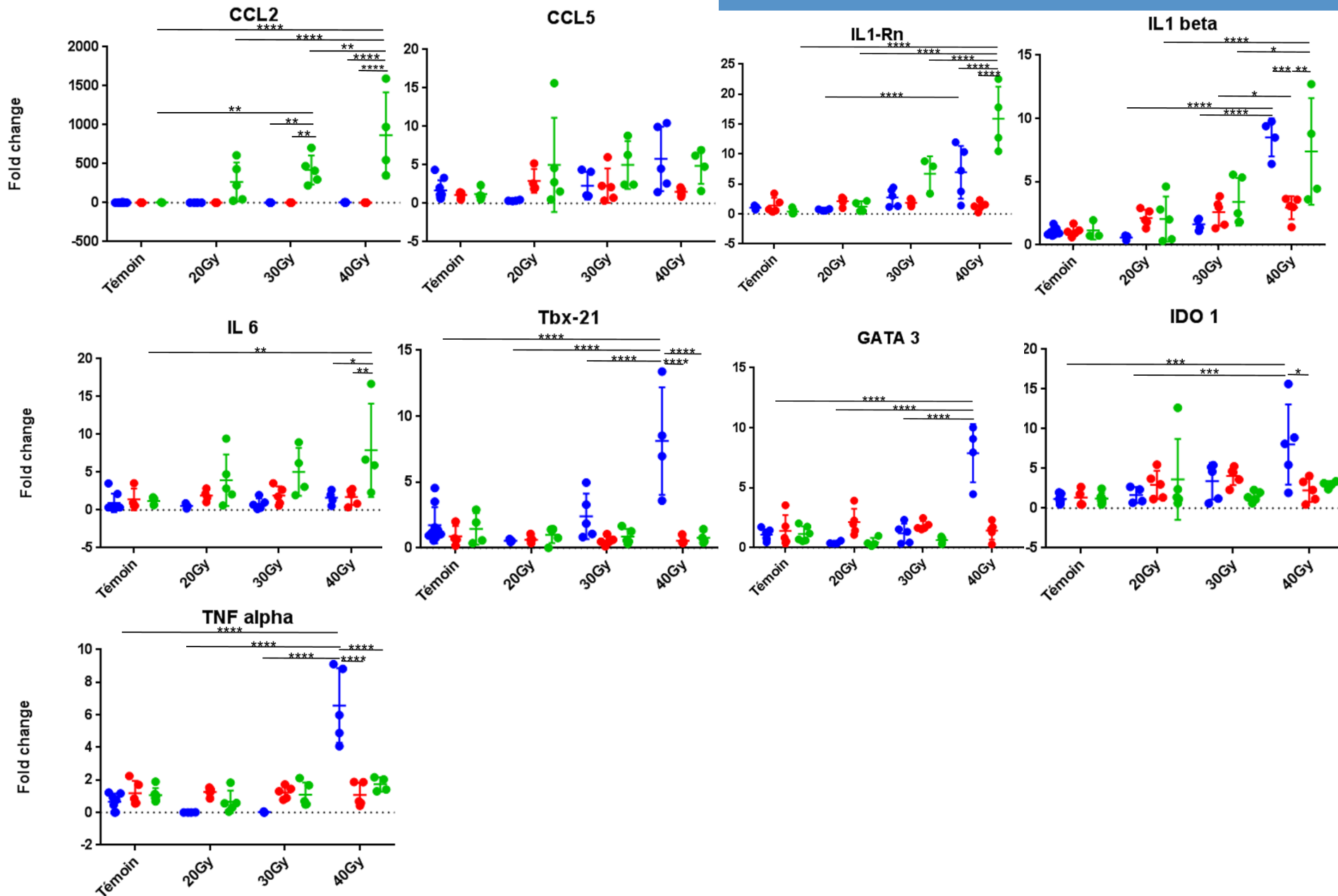
Page 3

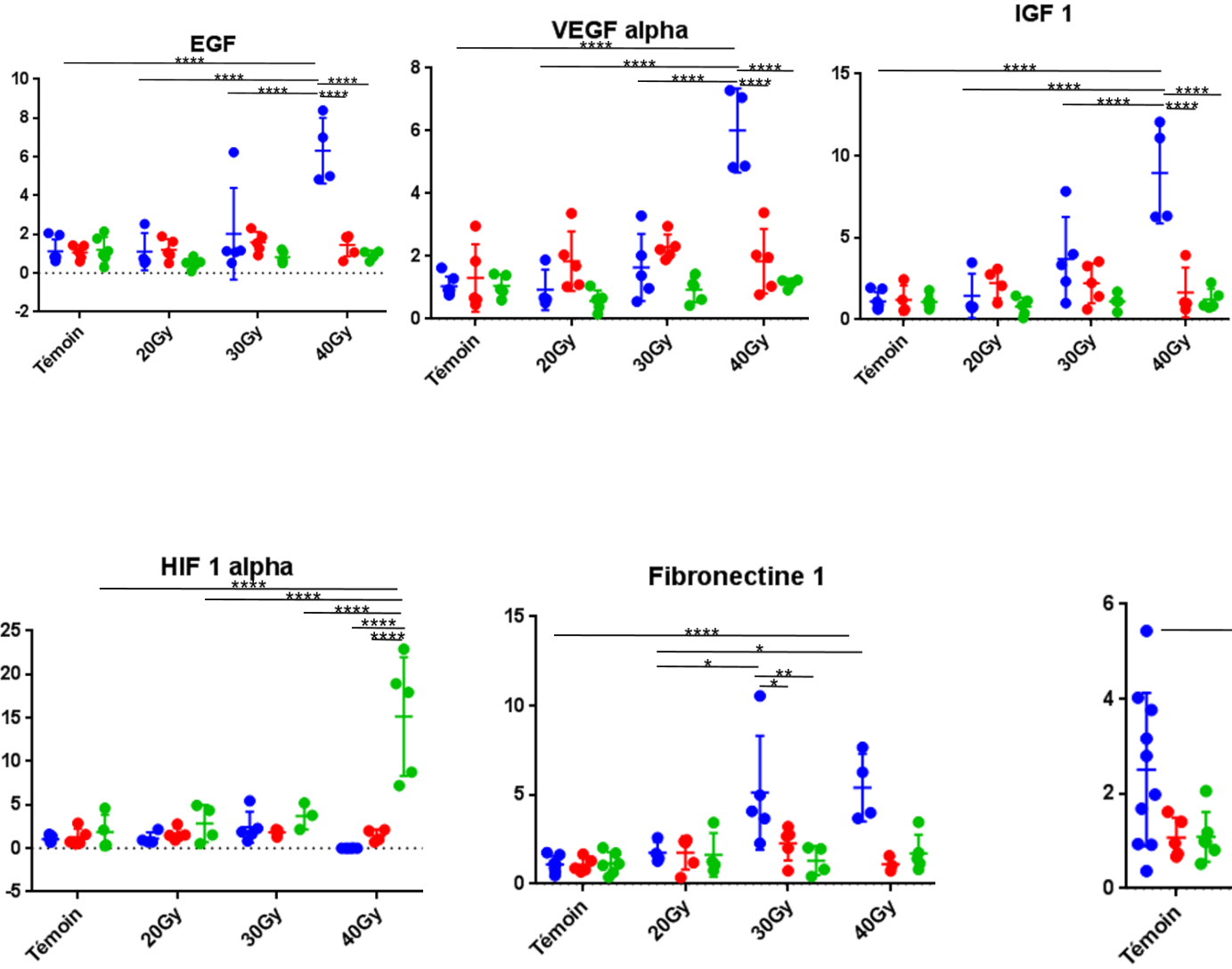
MSCs pathways of action on preclinical fibrosis models

Mode of action	Mechanism	References
Immunomodulation	<p>Decrease in inflammatory infiltration</p> <p>Polarity change of macrophages: M1 -> M2</p> <p>Decrease in the expression and secretion of pro-inflammatory cytokines (TNF-α, IL-1, IL-6...)</p> <p>Decrease in apoptosis</p>	<p>Linard et coll., 2013</p> <p>Zhou et coll., 2013</p> <p>Semedo et coll., 2009</p> <p>Horton et coll., 2013</p>
Inhibition of the TGF pathway- β 1	<p>Decreased expression and secretion of TGF-β1</p> <p>Decrease in the activation of the Smad channel</p> <p>Decrease in the number of myofibroblasts</p>	<p>Ueno et coll., 2013</p> <p>Wu et coll., 2014</p> <p>Jang et coll., 2014</p> <p>Li et coll., 2013</p>
Pro-angiogenic/anti-oxidant	<p>Increase in the expression and secretion of antioxidant enzymes (NQO1, HO-1, SOD...)</p> <p>Pro-angiogenic effect: increase in VEGF and FGF-2</p> <p>Augmentation de la prolifération des cellules endothéliales</p>	<p>Chen et coll., 2011</p> <p>Kinnaird et coll., 2004</p> <p>Niu et coll., 2008</p> <p>Kinnaird et coll., 2004</p>
Remodelage matriciel	<p>Decrease in the expression and production of MEC components</p> <p>Rebalancing the MMP/TIMP balance</p>	<p>Moodley et coll., 2009</p> <p>Mias et coll., 2009</p> <p>Ebrahimi et coll., 2013</p>

Usunier et al., 2013







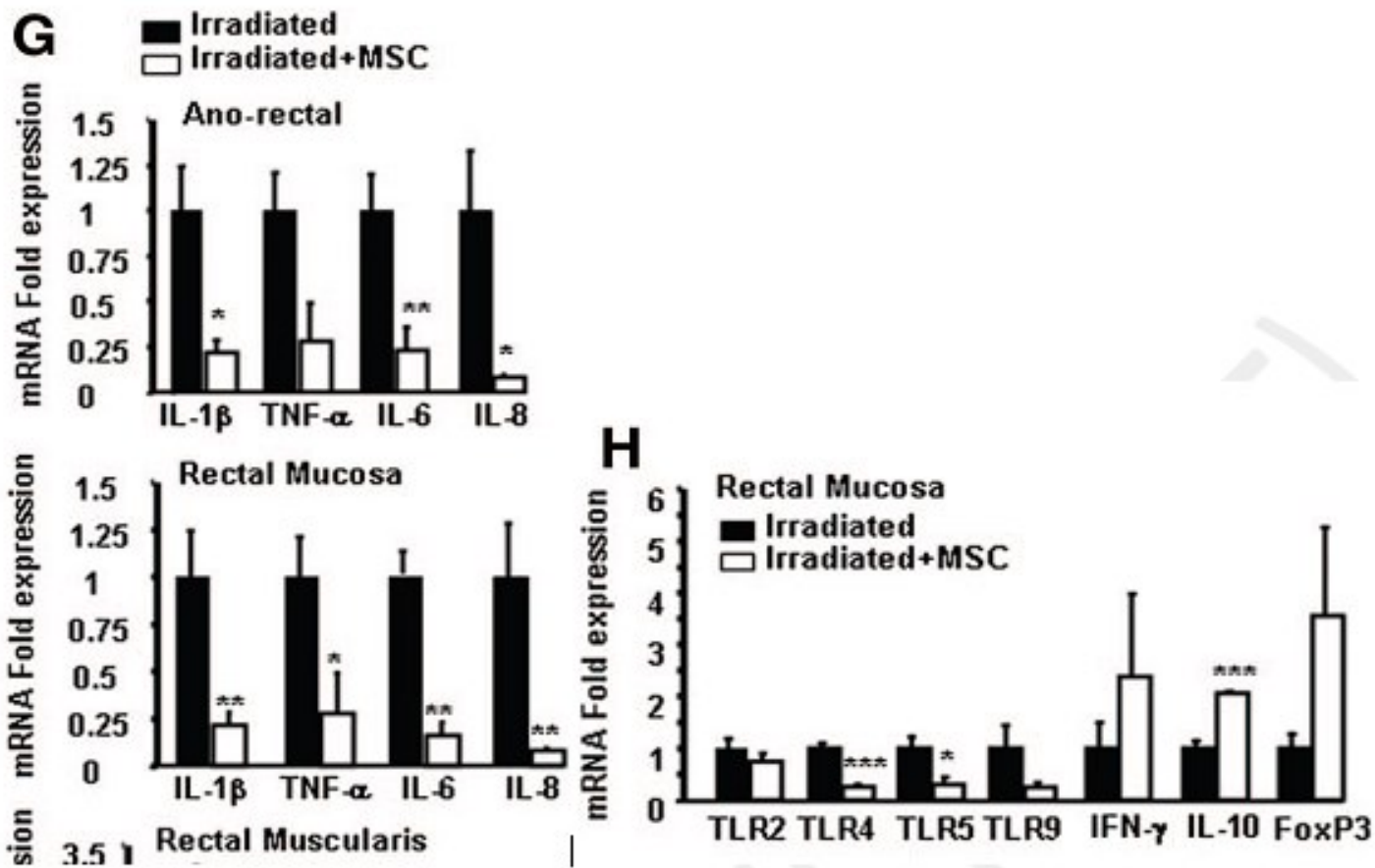
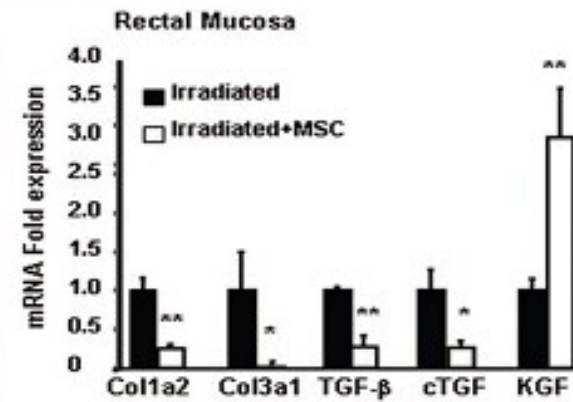
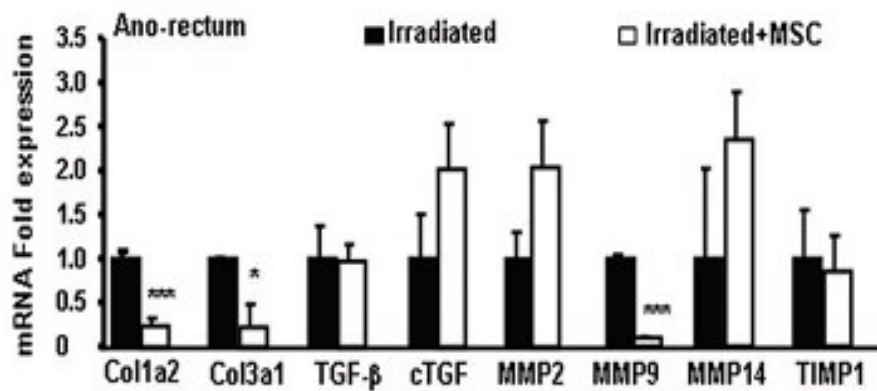
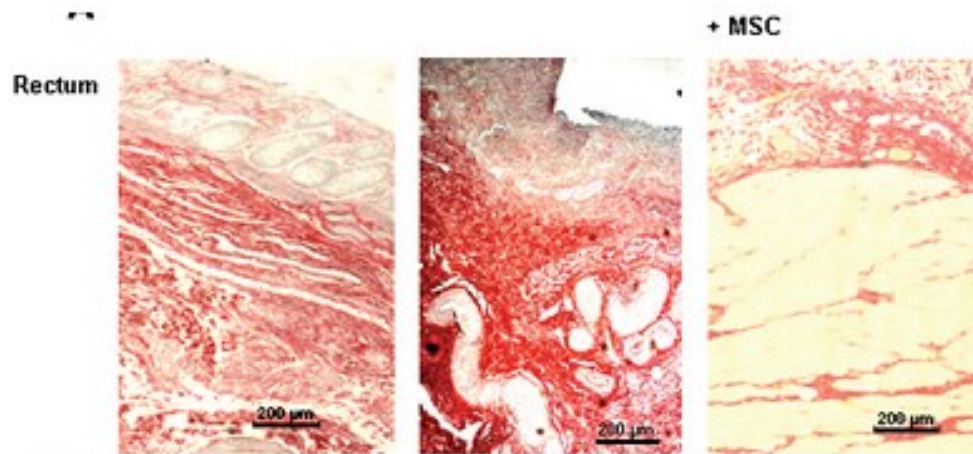


Figure 24. Experimental efficacy and anti-inflammatory effect of MSC injections.

Linard et al., 2013



Linard et al., 2013

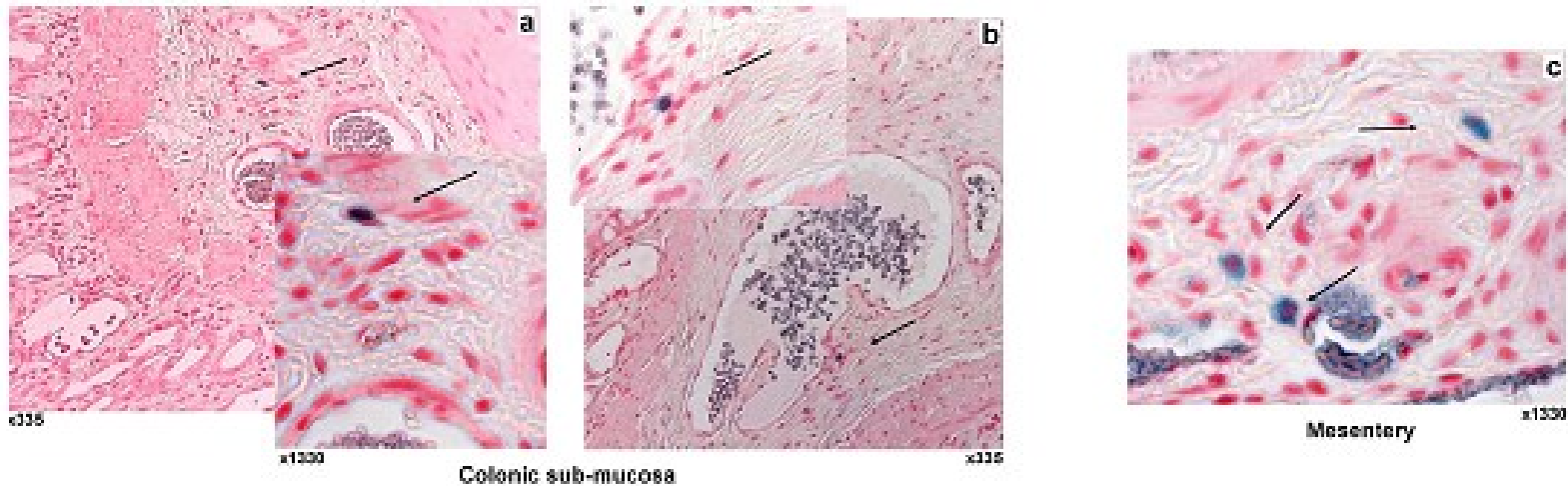


Figure 33: MSC engraft in colonic mucosa one week after injection and disappeared at 2 weeks
 Intravenous injected MSC-GFP engraft in the colon. Detection of GFP-MSC (black arrow) in irradiated (a, b) colonic sub-mucosa or (c) mesentery, 1 week after injection using GFP-specific antibodies. Magnification, x335 and x1330.

Sémont et al., 2010

Matériel :

- Milieu MSCs : MEM α , SVF 20%, PS, Glut
- Milieu PBS, SVF 10%
- Collagénase type I (Sigma C0130-1g)
- 6 tubes 50ml avec collagénase à 0.1% dans du milieu de digestion : MEM α , PS, Glut
- Boite de pétri en verre

● Prélèvement de la graisse

La graisse est prélevée au-dessus de la patte entre la peau et le péritoine, mise dans 5mL de PBS 1X.

● Digestion (x3)

On coupe la graisse en petits morceaux, que l'on met dans du MEM α + collagénase à 0,1% (x2 tubes/digestion). Incubation **pdt 30 min à 37°C** avec agitation.

On récupère les cellules avec une filtration 100 μ m, la graisse non digérée est remise en MEM α + collagénase à 0,1%.

Sur les cellules filtrées, on ajoute du milieu contenant du SVF pour diluer la collagénase.

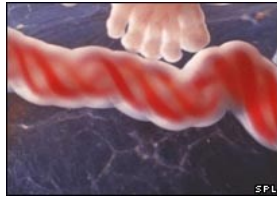
On effectue une centrifugation pour rassembler toutes les cellules, filtration sur 40 μ m et ensuite numération.

(4ml au 5^e en bleu acétique)

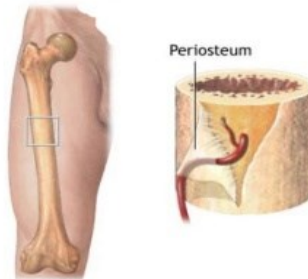
● Culture

PO 1000 ζ /cm² soit 0,150.10⁶ ζ /150cm² en milieu MSCs

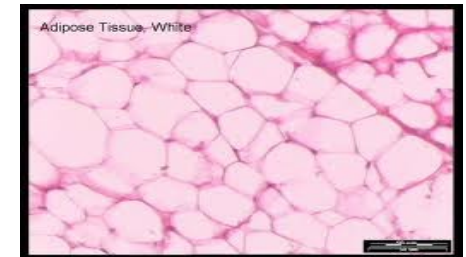
CFU-F 1000 ζ /F25cm² en triplicat



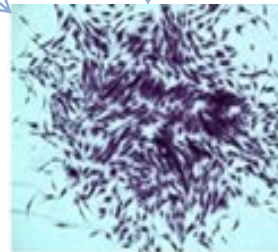
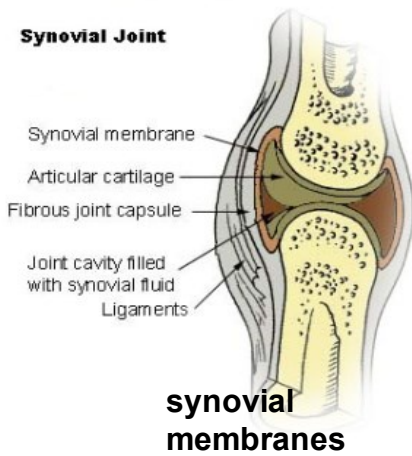
**Umbilical cord
Wharton's jelly**



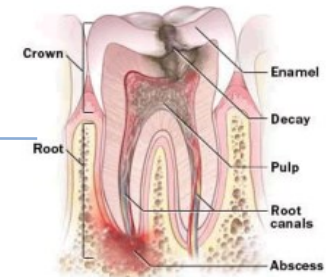
**Bone marrow
periosteum**



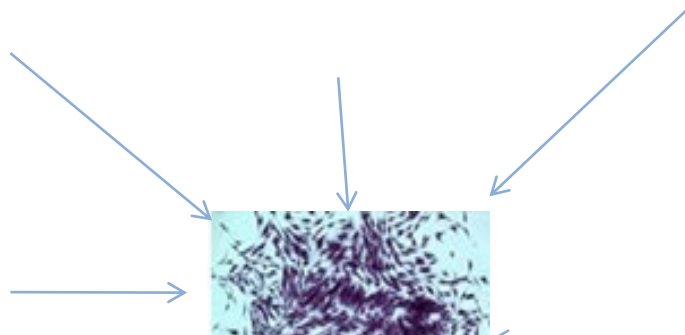
Adipose tissue



**Sources of
MSCs**



Dental pulp



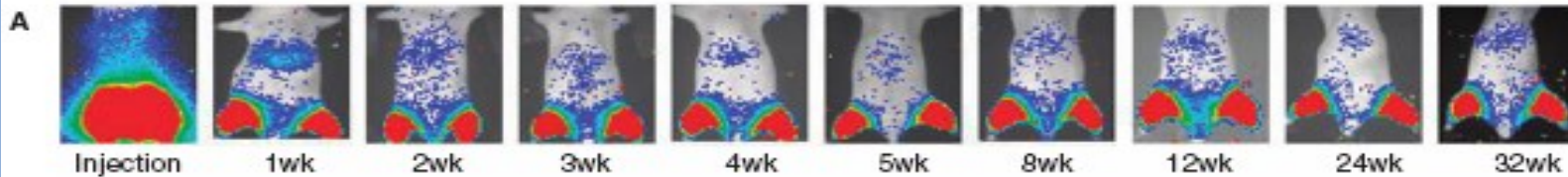
MSC homing after intramuscular injection (0.5×10^6 CSM) (Vilata 2008)

STEM CELLS AND DEVELOPMENT 17:993-1004 (2008)
© Mary Ann Liebert, Inc.
DOI: 10.1089/scd.2007.0201

Biodistribution, Long-term Survival, and Safety of Human Adipose Tissue-derived Mesenchymal Stem Cells Transplanted in Nude Mice by High Sensitivity Non-invasive Bioluminescence Imaging

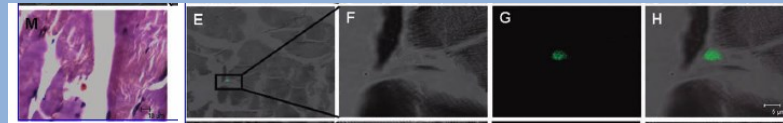
Marta Vilalta,¹ Irene R. Dégano,¹ Juli Bagó,¹ David Gould,² Mónica Santos,³ Mariano García-Arriaza,⁴ Ramon Ayala,⁵ Carme Fuster,⁶ Yuli Chernajovsky,⁷ Damián García-Olmo,⁸ Nura Rubio,¹ and Jeronimo Blanco¹

Intramuscularly (IM) inoculated MSC.



75 % of MSC lost the first week

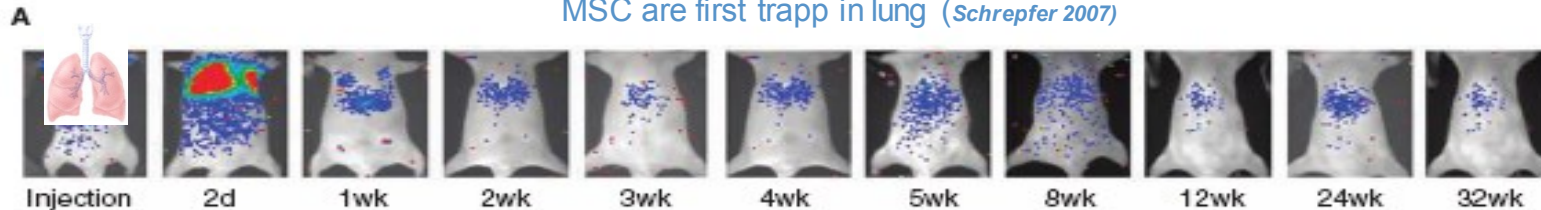
Number surviving cells remains stable over 32 weeks



Histological localization of MSC

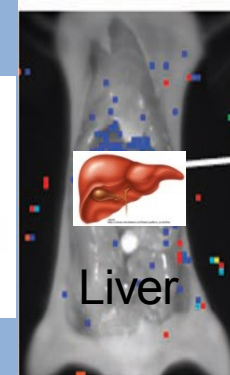
Tail vein (IV) inoculated MSC

MSC are first trapped in lung (Schrepfer 2007)



MSC first retained in lung
Cleared after one week

1.5% of cells detected in abdomen (persisted 32 weeks)



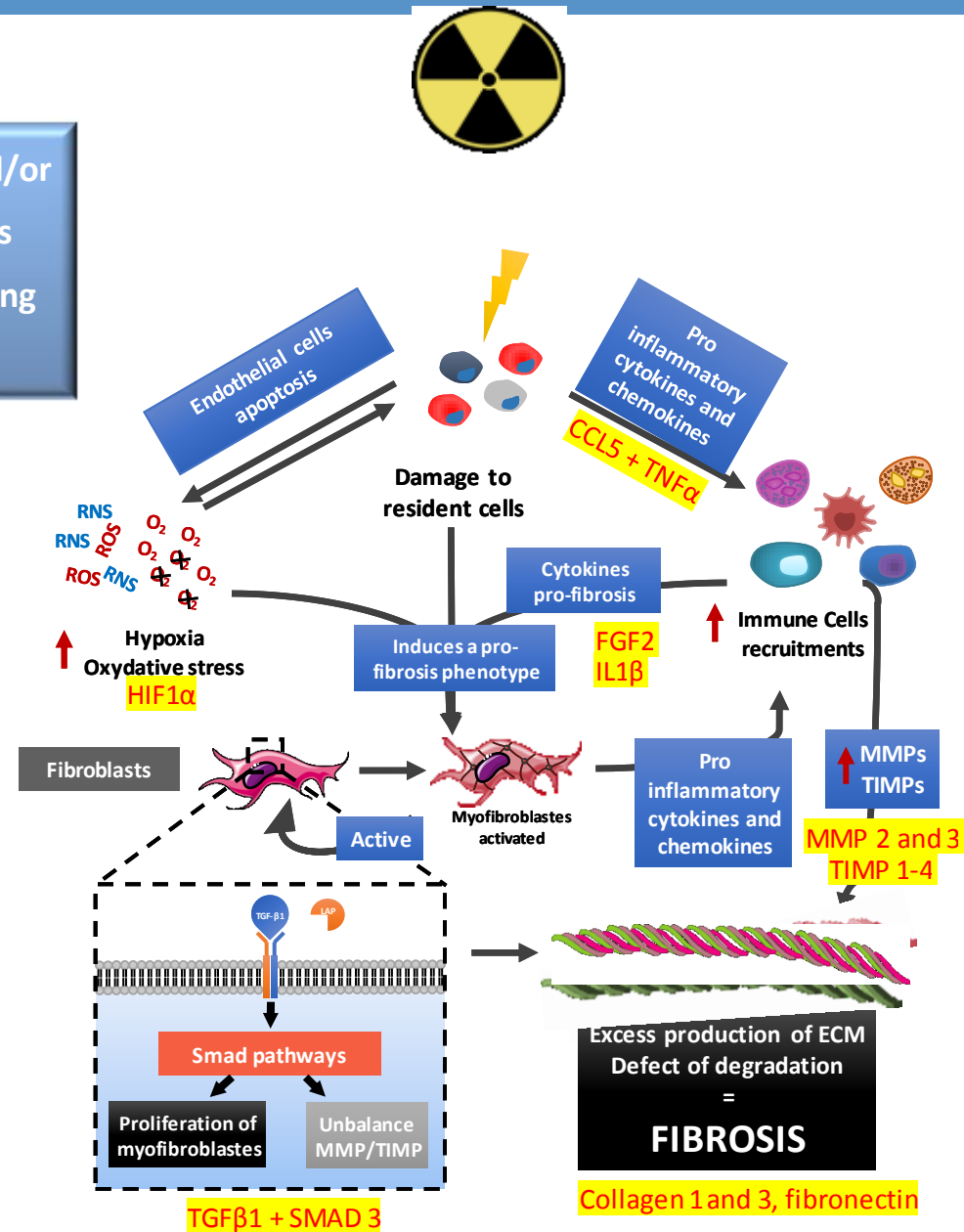
IV and IM Liver preferred target organ for colonization

“Fibrosis is defined by the overgrowth, hardening, and/or scarring of various tissues and is attributed to excess deposition of extracellular matrix components including collagen” (Wynn TA, 2008)

Cytokine pro fibrosis secreted following irradiation

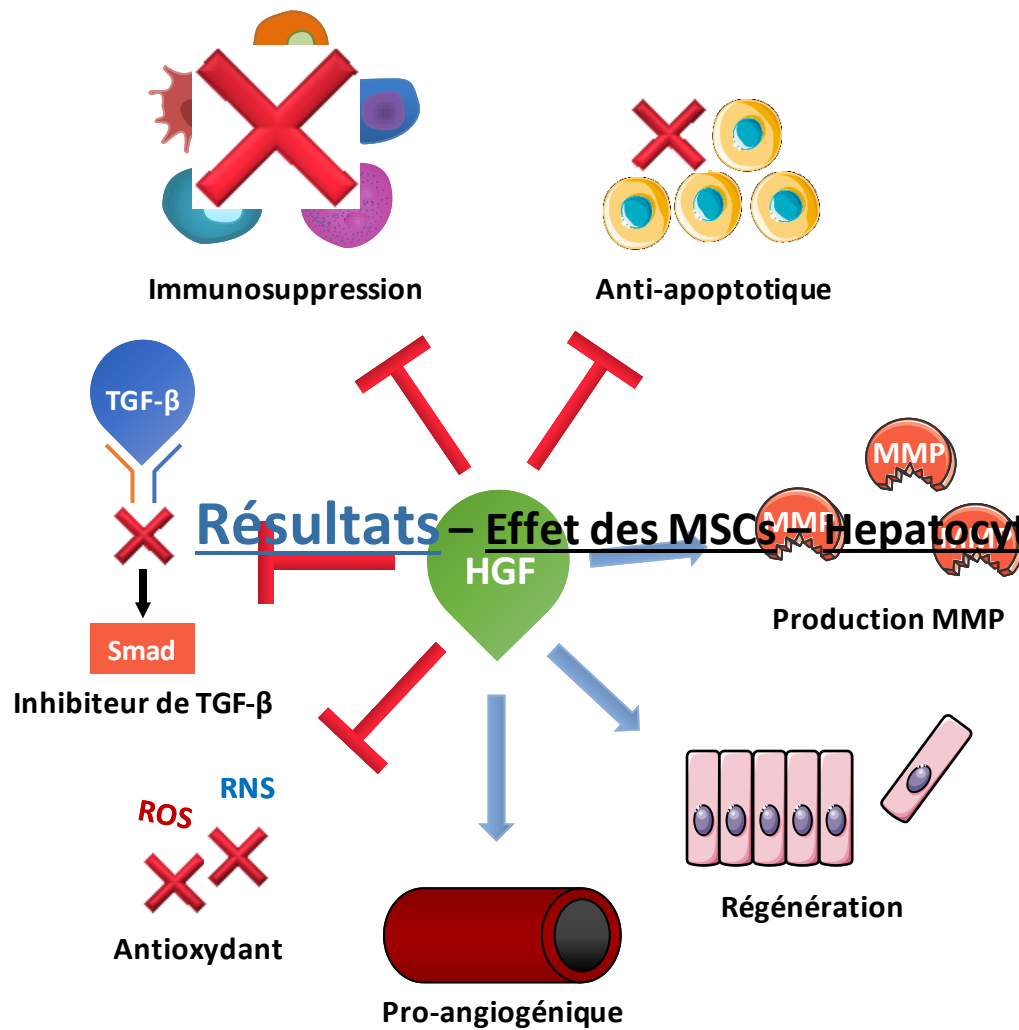
Activation of extracellular matrix secreting cells

Imbalance of the accumulation/degradation of the ECM



HIF1α = results of M2

ECM: ExtraCellular Matrix



Hepatocyte Growth Factor (HGF)

Facteur de croissance pléiotropique

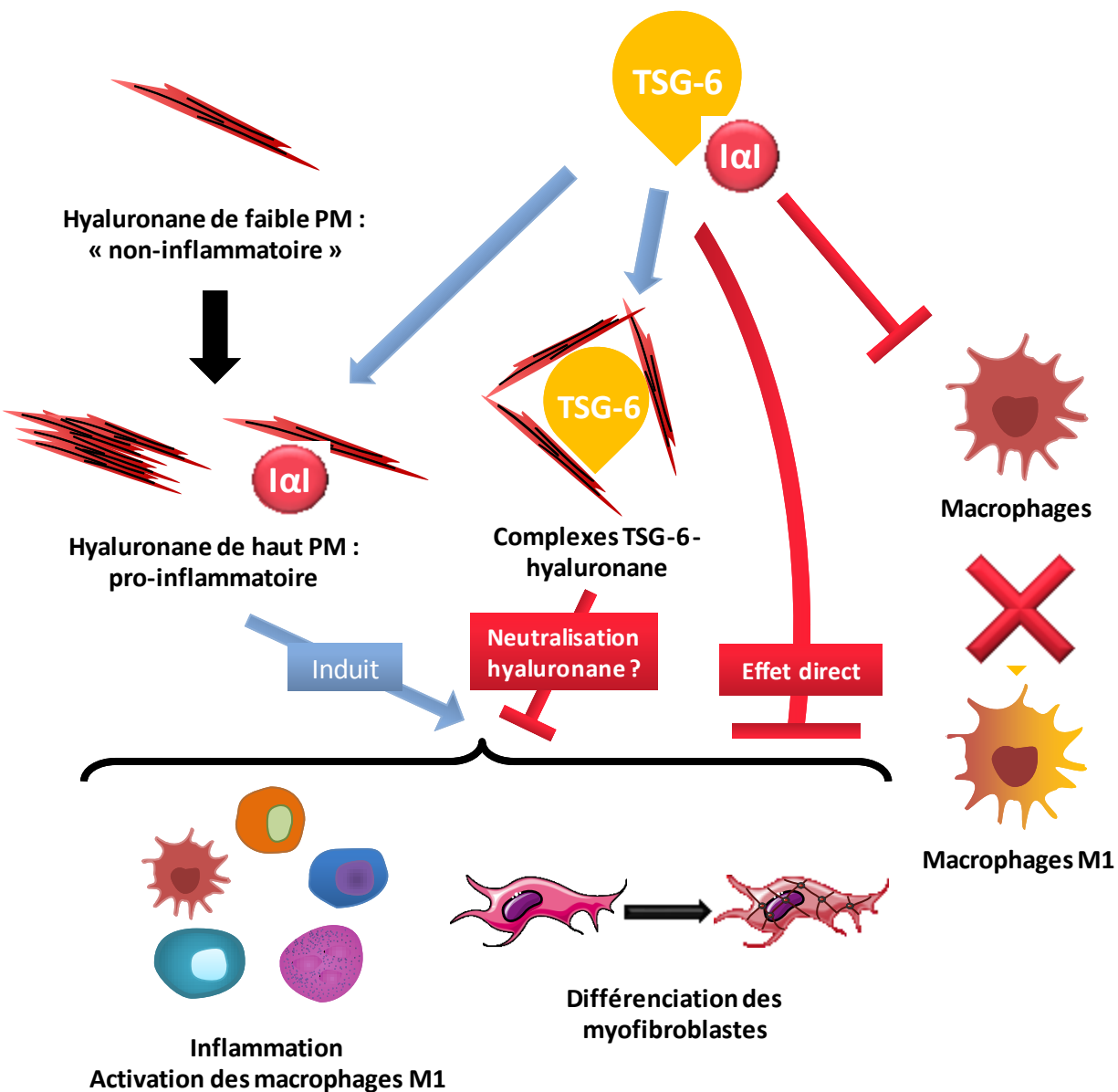
Exprimé dans de nombreux tissus en cas de lésion

Pouvoir anti-fibrosant démontré

Sécrété par les MSCs dans plusieurs modèles de fibrose (rein, foie, poumon)

Implication du HGF sécrété par les MSCs lors de la fibrose colorectale radio-induite ?

Résultats – Effet des MSCs – Hepatocyte Growth Factor – Propriétés démontrées



TNF-stimulated Gene-6 (TSG-6)

Protéine immunomodulatrice

Exprimé lors de l'inflammation (induit par TNF-α)

Stimule/réduit l'inflammation

Sécrété par les MSCs dans plusieurs modèles de fibrose (rein, peau) : effet anti-fibrosant

Implication du TSG-6 sécrété par les MSCs lors de la fibrose colorectale radio-induite ?

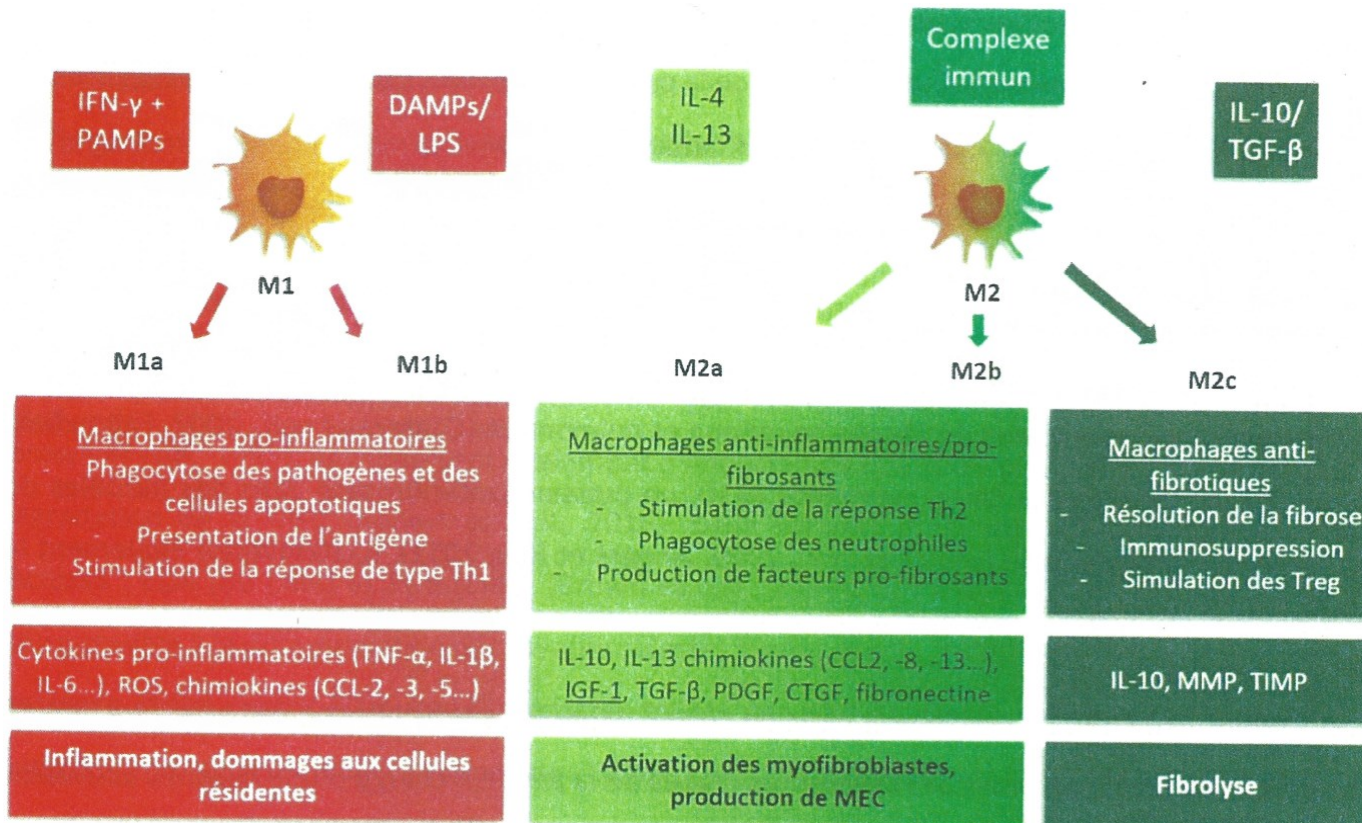


Figure 8 : Caractéristique des différents états de polarisation des macrophages.

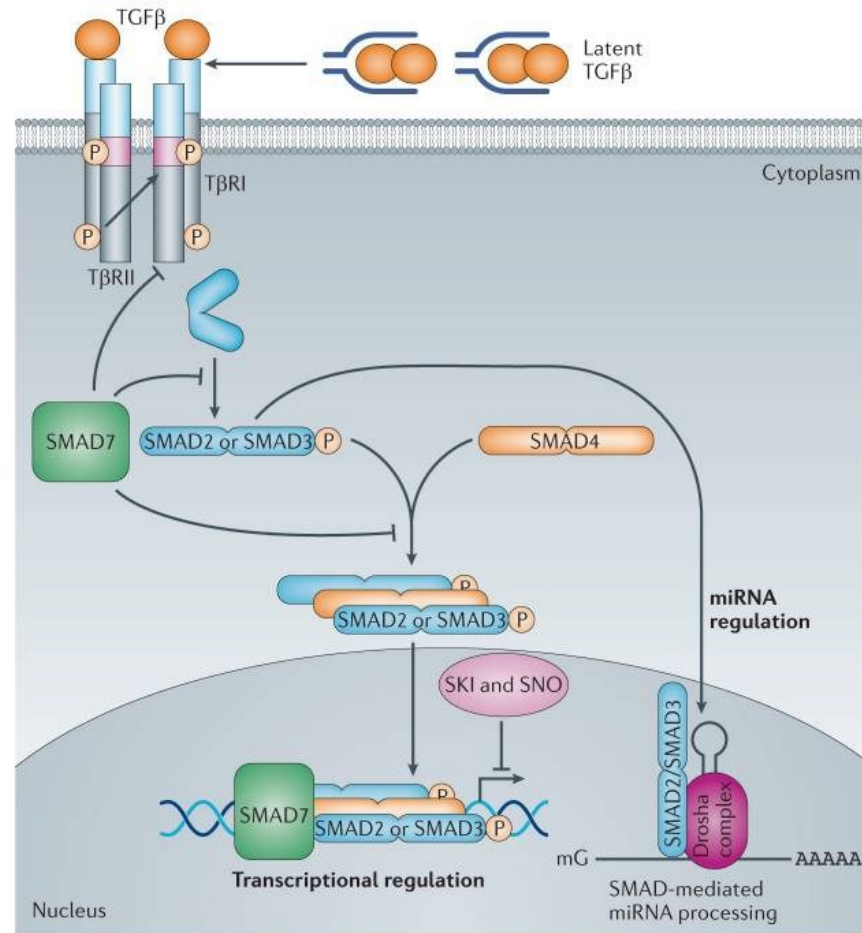
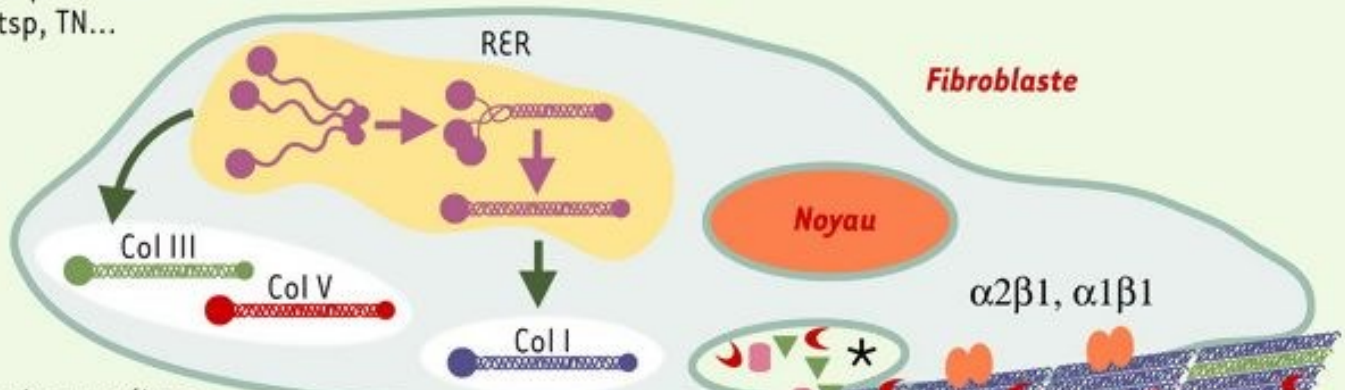
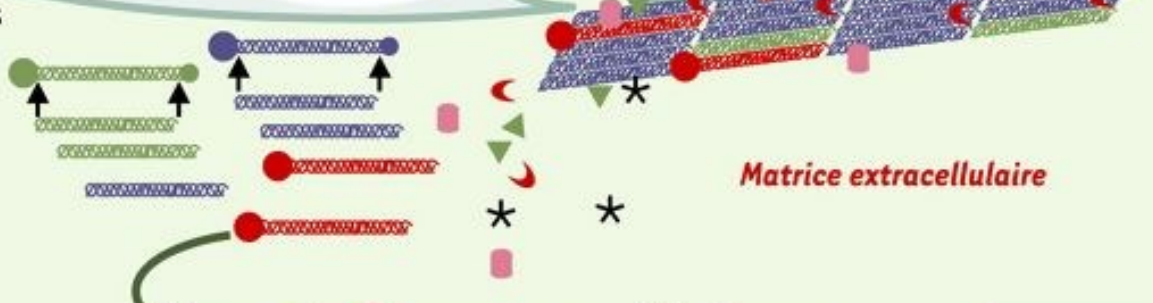


Figure: mécanismes d'activation et d'inhibition de la voie Smad (D'après Akhurst, 2012) (Akhurst and Hata, 2012)

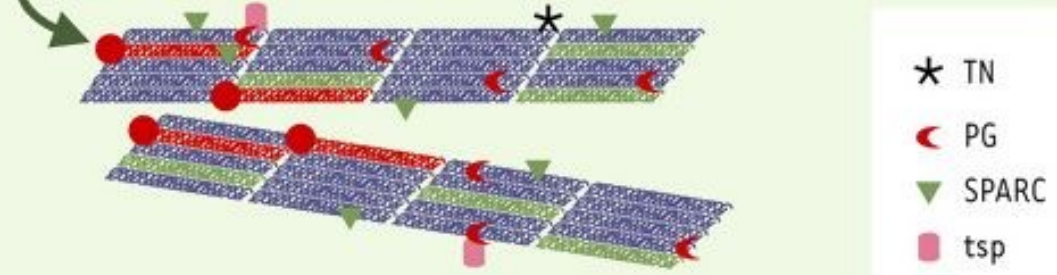
1. Synthèse des collagènes et autres composés matriciels : PG, SPARC, tsp, TN...



2. Sécrétion des protéines matricielles, maturation des collagènes



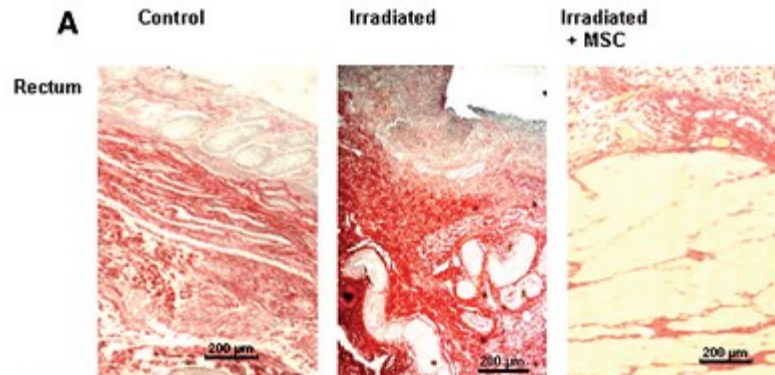
3. Association en fibres et interaction avec d'autres composants matriciels



- * TN
- ◀ PG
- ▼ SPARC
- tsp

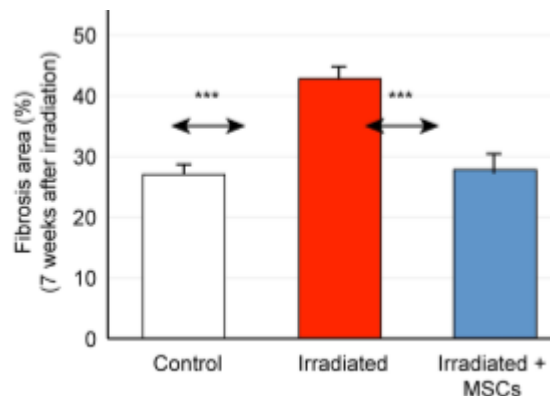
Protocol of intravenous injection:

- 5 millions of MSCs significantly improve the epithelial injury score
- Iterative injections in established radiation-induced lesions restore mucosal damages.



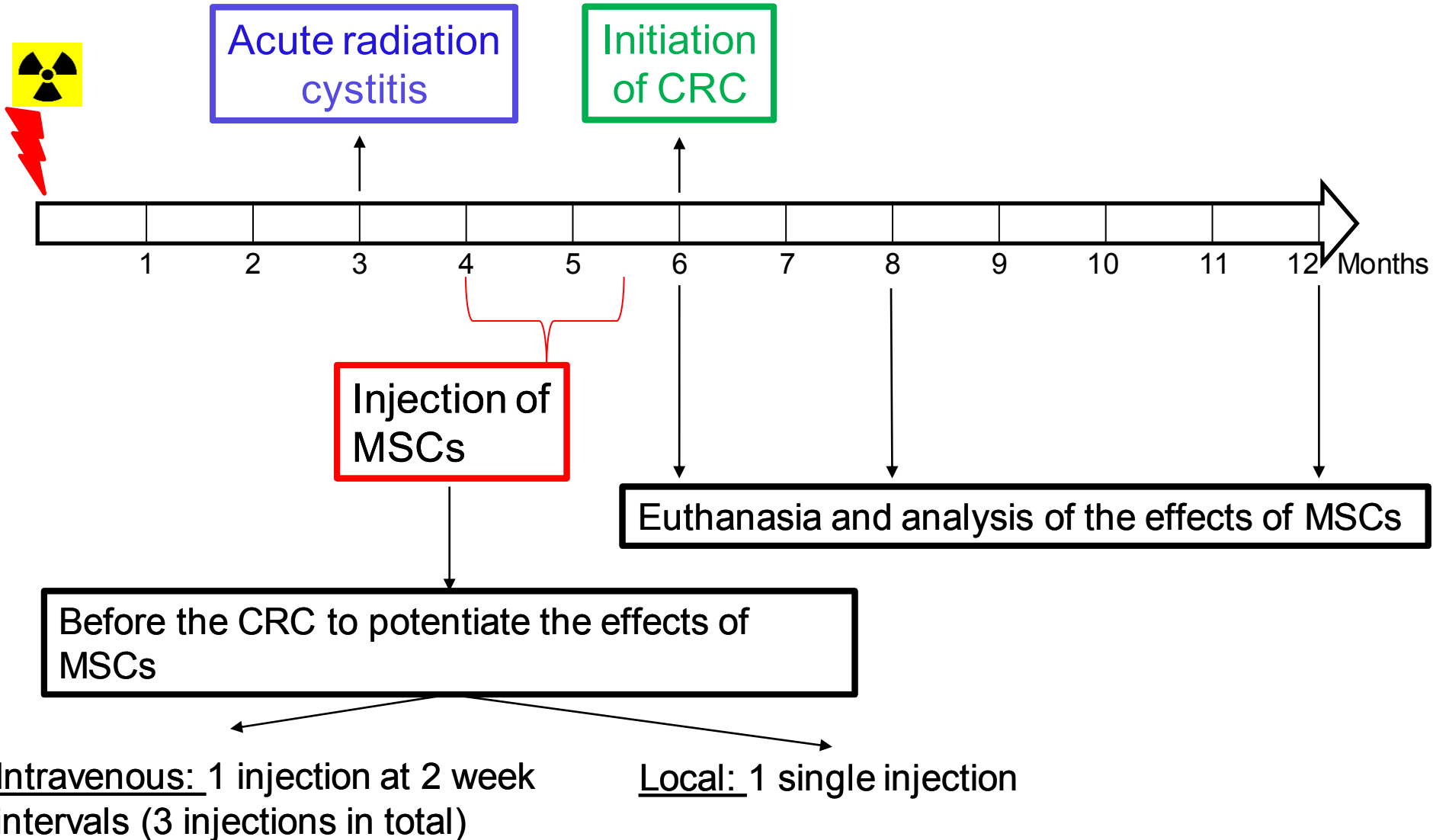
Linard et al., 2013; Bessout et al., 2014

- Injection frequency \geq 1 week
- MSCs injections are more effective during the initiation phase of fibrosis



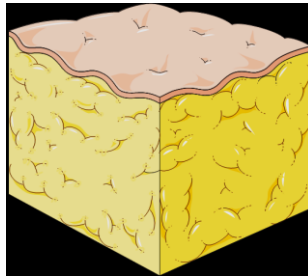
Usunier et al. 2014
Colorectal fibrosis

Protocol of injection:



Protocol injection: Chronic Radiation Cystitis

Adipose tissue



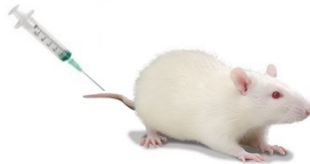Isolation
Purification
Expansion



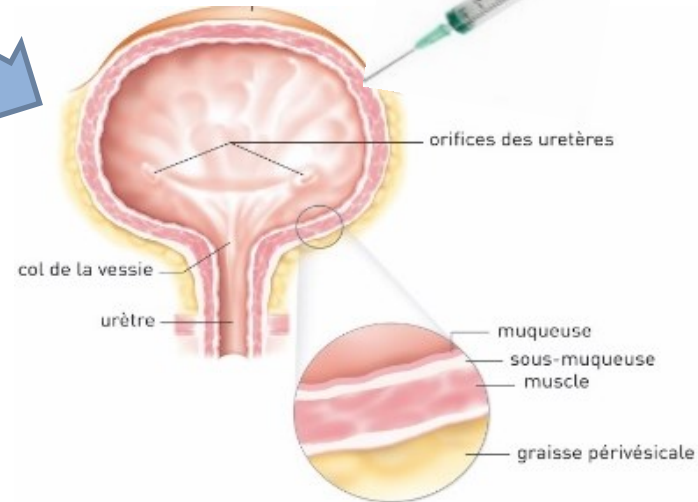
Intravenous injection

Local injection

5 millions cells¹



1 millions cells^{2,3,4}



1:Kanno et al.; 2014

2: Kim et al.; 2016

3: Lee S.W et al.; 2018

4: Salehi-pourmehr H. et al.; 2019