



HAL
open science

Disentangling Cro-Magnon: The dental and alveolar remains

Erik Trinkaus, Sarah A Lacy, Adrien Thibeault, Sébastien Villotte

► **To cite this version:**

Erik Trinkaus, Sarah A Lacy, Adrien Thibeault, Sébastien Villotte. Disentangling Cro-Magnon: The dental and alveolar remains. *Journal of Archaeological Science: Reports*, 2021, 37, 10.1016/j.jasrep.2021.102911 . hal-03441696

HAL Id: hal-03441696

<https://hal.science/hal-03441696>

Submitted on 22 Nov 2021

HAL is a multi-disciplinary open access archive for the deposit and dissemination of scientific research documents, whether they are published or not. The documents may come from teaching and research institutions in France or abroad, or from public or private research centers.

L'archive ouverte pluridisciplinaire **HAL**, est destinée au dépôt et à la diffusion de documents scientifiques de niveau recherche, publiés ou non, émanant des établissements d'enseignement et de recherche français ou étrangers, des laboratoires publics ou privés.

1 **Disentangling Cro-Magnon: The Dental and Alveolar Remains**

2
3 **Erik Trinkaus,^{a,b,*} Sarah A. Lacy,^c Adrien Thibeault^d and Sébastien Villotte^d**

4
5 ^a Department of Anthropology, Washington University, Saint Louis, MO 63130, USA;
6 trinkaus@wustl.edu

7 ^b 32 Cliff Street, Burlington VT 05401, USA

8 ^c Department of Anthropology, California State University Dominguez Hills, Carson, CA 90747,
9 USA; slacy@scudh.edu

10 ^d Université de Bordeaux, CNRS, PACEA, UMR 5199, F-33615 Pessac, France;
11 adrien.thibeault@u-bordeaux.fr; sebastien.villotte@u-bordeaux.fr

12 * Corresponding author

13
14
15 The authors declare no conflicts of interest.

16
17 ***Author contributions:***

18 **Erik Trinkaus:** Conceptualization, Data curation, Investigation, Methodology, Visualization,
19 Writing - original draft. **Sarah A. Lacy:** Funding acquisition, Data curation, Investigation,
20 Methodology, Writing-review & editing. **Adrien Thibeault:** Methodology, Visualization,
21 Writing-review & editing. **Sébastien Villotte:** Conceptualization, Funding acquisition,
22 Investigation, Project administration, Resources, Writing-review & editing.

23
24
25 ***Corresponding author:*** Erik Trinkaus

26 trinkaus@wustl.edu

27 32 Cliff Street, Burlington VT 05401, USA

30 **Highlights**

- 31 □ The Cro-Magnon human remains include the dentoalveolar remains of four individuals
- 32 □ Cro-Magnon 1 (4253) exhibits advanced periodontal resorption and 3 granulomata
- 33 □ Cro-Magnon 4257/58 has exceptionally large molars, for an Upper Paleolithic human
- 34 □ Cro-Magnon 4253, 4256 and 4257 exhibit rotated premolars
- 35 □ Cro-Magnon teeth and alveoli are otherwise unexceptional for the Upper Paleolithic

36

37 **Abstract**

38 The dental and alveolar remains of the Upper Paleolithic early modern humans from the Abri de
39 Cro-Magnon (Dordogne, France) are described and reassessed, building on descriptions since
40 their discovery in 1868. There are four individuals represented; two (Cro-Magnon (CM) 4253
41 and 4254) are portions of numbered skulls (Cro-Magnon 1 and 2) and two (Cro-Magnon 4256
42 and 4257/58) are unassociated but likely deriving from Cro-Magnon 3 and 4. CM 4253 exhibits
43 advanced periodontal lesions, likely secondary to tooth wear, CM 4256 has moderate alveolar
44 resorption, but the others show little alveolar pathology. CM 4253, 4256 and 4257 have premolar
45 rotation, and CM 4257/58 had impacted M3s. The CM 4254 molars are average in size for the
46 Late Pleistocene, but those of CM 4257/58 are at or beyond the upper limits of known ranges of
47 Upper Paleolithic variation. Only the dental dimensions of the CM 4257/58 molars are
48 exceptional for earlier Upper Paleolithic humans.

49

50 **Key Words:** Paleoanthropology, Upper Paleolithic, Gravettian, Dentition, Paleopathology,
51 Granulomata, Caries

52

53 **1. Introduction**

54 The Cro-Magnon rock shelter (Les Eyzies-de-Tayac-Sireuil, Dordogne, France) is one of
55 the premier Upper Paleolithic sites, best known for establishing the contemporaneity of early
56 modern humans with Upper Paleolithic assemblages and Pleistocene fauna (Broca, 1868; Lartet,
57 1868). Although described in relative detail by Broca (1868) and Pruner-Bey (1865-75) shortly
58 after their discovery, and reassessed 100 years later by Vallois and Billy (1965), the human
59 skeletal assemblage from Cro-Magnon has remained poorly known despite the incorporation of
60 various elements into Late Pleistocene comparative analyses. In this context, and in the

61 framework of a broader refocus on western Eurasian Upper Paleolithic human paleobiology, we
62 have undertaken the reassessment of the Cro-Magnon human remains (Thibeault and Villotte,
63 2018; Villotte and Balzeau, 2018; Partiot et al., 2020; Villotte et al., 2020); in this contribution,
64 we provide a description and reassessment of the dental and alveolar remains of the adults.

65 The human remains from Cro-Magnon were formerly attributed generally to the
66 “Aurignacian,” but they are currently dated to the Mid Upper Paleolithic (MUP), to an early
67 phase of the Gravettian technocomplex (33–31,000 cal BP) based on radiocarbon dating of
68 associated archeological remains (Henry-Gambier, 2002; Henry-Gambier et al., 2013). The
69 relatively abundant human remains represent all portions of the skeleton. However, they became
70 commingled, whether in situ or subsequently, resulting in various attempts to reassociate them
71 by individual (e.g., Broca, 1868; Pruner-Bey, 1865-75; Vallois and Billy, 1965; Henry-Gambier
72 et al., 2013; Thibeault and Villotte, 2018; Villotte and Balzeau, 2018; Villotte et al., 2020).
73 Based on the cranial remains, four adults are present (Broca, 1868; Lartet, 1868; Pruner-Bey,
74 1965-75; Vallois and Billy, 1965). Gambier et al. (2006) also identified four adults from pelvic
75 remains, but reassessment indicates that only three are pelvically represented (Thibeault and
76 Villotte, 2018; see also Pruner-Bey, 1865-75). Most recently, Villotte et al. (2020) determined
77 that there is a fourth adult represented by the ulnae.

78 In this contribution to the reassessment of the Cro-Magnon assemblage, we focus on the
79 adult dental and alveolar remains. These remains were a primary focus of the original Cro-
80 Magnon description by Broca (1868), in that he used the dental remains to assess the ages-at-
81 death of three individuals. He assessed the associated maxillae and mandible of Cro-Magnon 1
82 and the maxillae of Cro-Magnon 2, plus the isolated maxilla (Cro-Magnon (CM) 4257) which he
83 assigned to Cro-Magnon 3 (Table 1). He did not consider the two separate mandibles, CM 4256
84 and 4258. These remains were described in more detail with respect to age-at-death,
85 morphology, pathology and dental attrition by Pruner-Bey (1865-75), who assigned them to the
86 four cranially identified individuals. A century later, Vallois and Billy (1965) reassessed the
87 sample with a more inclusive discussion of the full dental and alveolar sample; they attributed
88 the isolated CM 4256 mandible to Cro-Magnon 3, but did not assign the isolated CM 4257 and
89 4258 elements.

90 None of these papers provided detailed descriptions of the dental and especially alveolar
91 remains, although Broca (1868) commented in particular on patterns of dental wear and both

92 Pruner-Bey (1865-75) and Vallois and Billy (1965) provided broader assessments of
 93 morphological and paleopathological aspects. The considerations here are intended to both
 94 reassess previously noted aspects of these alveolar and dental remains and fill out the
 95 descriptions of them.

96
 97 **Table 1.** Previous assignments of the Cro-Magnon craniomandibular remains with dentoalveolar
 98 portions by individual.

	Broca 1868	Pruner-Bey 1865-75	Vallois & Billy 1965
CM 4253 cranium	Cro-Magnon 1	Cro-Magnon 1	Cro-Magnon 1
CM 4253 mandible	Cro-Magnon 1	Cro-Magnon 1	Cro-Magnon 1
CM 4254 cranium	Cro-Magnon 2	Cro-Magnon 2 (“3”) ¹	Cro-Magnon 2
CM 4256 mandible	no mention	Cro-Magnon 3 (“2”) ¹	Cro-Magnon 3
CM 4257 maxilla	Cro-Magnon 3	Cro-Magnon 4	unassigned
CM 4258 mandible	no mention	Cro-Magnon 4	unassigned

99 ¹ Pruner-Bey (1865-75) referred to Cro-Magnon 2 (CM 4254) as number 3, and Cro-Magnon 3
 100 (CM 4255) as number 2.

101

102 **2. Materials**

103 ***2.1 The Cro-Magnon Dentoalveolar Remains***

104 The human remains from the Abri de Cro-Magnon are curated in the Musée de l’Homme,
 105 Muséum national d’Histoire naturelle (MNHN), Paris. The specimens of consideration here
 106 consist of the maxillae of two crania (CM 4253 [Cro-Magnon 1]) and (CM 4254 (Cro-Magnon
 107 2)), the mandible with the first cranium (CM 4253), an isolated partial maxilla (CM 4257), and
 108 two isolated partial mandibles (CM 4256 and 4258).

109 The Cro-Magnon 4253 maxillae and mandible (Fig. 1) retain their full dental arcades
 110 (each M3 to M3), although both have sustained extensive postmortem abrasion and the maxillae
 111 in particular retain a coating of irregular carbonate. The carbonate cannot be removed from the
 112 fragile bone, and attempts to “clean” the cranium virtually have failed given the thinness of the
 113 layer and similar radiodensity to the underlying bone (Fig. S1). Only one partial tooth, the right
 114 M², and partial roots of two others, the right M₁ and M₃, remain in situ (Fig. 1).

115 The Cro-Magnon 4254 maxillary alveoli are largely present from the mesial right M³
 116 alveolus to the mesiodistal middle of the left M¹ alveolus (Fig. 2). There is erosion especially to

117 the labial anterior alveoli and the buccal postcanine alveoli. The right M¹ and M² are in situ, and
118 a root fragment of the left M¹ is present.

119 Cro-Magnon 4256 (Fig. 3) is a complete mandibular corpus, from incomplete M₃
120 alveolus to incomplete M₃ alveolus. It is largely without teeth, but the alveolar processes
121 sustained only minor damage, primarily to those of the buccal M₁s. Although all dental crowns
122 are absent, root portions remains for the left I₁ and both P₃s.

123 The Cro-Magnon 4257 left maxilla (Fig. 4) retains the lingual alveoli from the I¹ to distal
124 of the M². There are three teeth remaining, a P⁴ and the left M¹ and M². The two molars are
125 securely in situ. However, the P⁴ does not fit the left maxilla (see SI S5). It would be appropriate
126 as a right P⁴ for the same individual, and it is so considered here.

127 The Cro-Magnon 4258 right posterior mandibular corpus and ramus (Fig. 4) retains the
128 damaged M₁ and M₂ and the complete M₃, the last impacted in its crypt. The buccal alveoli from
129 the mid-M₁ to the ramus are intact, but there is damage to the lingual M₁ alveolus and the lingual
130 M₂ alveolus was lost. Most of the alveolar margins of the M₃ crypt are intact.

131

132 *2.2 Comparative Samples*

133 The principal comparative sample, and the primary context for the Cro-Magnon sample,
134 is the human remains from the earlier Upper Paleolithic of Europe, the Early (EUP) and Mid
135 (MUP) Upper Paleolithic combined and referred to as E/MUP. The majority of these remains
136 derive from the MUP. Additional data for dental crown diameters are provided for European
137 Late Upper Paleolithic (LUP) humans, and reference as appropriate is made to Middle
138 Paleolithic late archaic (Neandertal) and early modern human remains.

139

140 **3. Methods**

141 The reassessment of these oral remains is based on visual observation of the original
142 remains in the Musée de l'Homme in 2012 (SAL) and 2018 (ET and SV), combined with images
143 taken in 1978 and 1985. Microtomodensitometric (μCT) data for these bones were acquired at
144 the AST-RX platform in the MNHN. They were obtained with the microfocus tube of the μCT
145 scanner “v|tome|xL 240” (GE Sensing and Inspection Technologies Phoenix X ray). Each final
146 volume was then reconstructed with isotropic voxels ranging from 30 to 115 μm (Table S4) and

147 using NRecon v2.0 (Bruker microCT) in 16-bit format. Surface rendering (STL format) of these
148 3D models was obtained with Avizo v.9 (Visualization Sciences Group Inc.).

149 Osteometrics are limited to standard dental crown diameters (Bräuer, 1988), discrete
150 occlusal traits follow the ASUDAS system (Turner et al., 1991; Scott and Turner, 1997), and
151 occlusal wear is scored following Smith (1984). Comparative dental crown diameters are
152 provided [as mean \pm standard deviation (N)]. Mesiodistal diameters of the crowns with
153 interproximal wear were estimated by continuing the rounded crown contour in occlusal view,
154 following Wood and Abbott (1983). Data are from the published literature and personal
155 measurement, and available on request. Right and left diameters, if available for an individual,
156 were averaged prior to graphing and statistical calculations.

157

158 **4. Results and Comparisons**

159 **4.1 *Morphology and Dental Dimensions***

160 The postmortem loss of most of the Cro-Magnon 4253, 4254 and 4256 teeth for which
161 alveoli are preserved, crown breakage to their few remaining teeth, and extensive occlusal wear
162 to the Cro-Magnon 4257 and 4258 molars have resulted in little available morphological data on
163 their dentitions.

164 As noted by Pruner-Bey (1865-75) and Vallois and Billy (1965), both CM 4254 and 4257
165 have two rooted P³s, bilaterally where preserved in the former (Figs. 2 and 4). CM 4253 appears
166 to have had single rooted P³s (Fig. S1). With the possible exception of the CM 4256 M₂s (Fig. 3),
167 all of the molars or the molar alveoli exhibit clearly separated molar roots, indicating a general
168 absence of taurodontism. Among the maxillary molars, the CM 4254 and 4257 M¹s appear to
169 have been 4-cusped, or have had well developed hypocones (ASUDAS stage \approx 4) (Figs. 2 and 4).
170 The CM 4257 M² appears to have had some hypocone reduction (Fig. 4), probably ASUDAS
171 stage 3. None of these molars retain sufficient occlusal morphology for further scoring given
172 wear.

173 The one tooth providing a complete, if partially observable, occlusal surface is the CM
174 4258 impacted M₃. The tooth has a simple Y-5 cusp pattern without a mid-trigonid crest or other
175 distinct features (Fig. 4). As such, it is relatively simple, especially compared to other Upper
176 Paleolithic M₃s (see Bailey (2006) and Martín-Torres et al. (2012) for mixed early modern
177 human comparative data).

178 The only reliable crown morphometrics, given wear and damage, are mesiodistal and
179 buccolingual diameters for the CM 4254 and 4257 M¹s and M²s, the same diameters for the CM
180 4257 P⁴ and the CM 4258 M₂, and the mesiodistal diameter of the CM 4258 M₃ (Table S2). Even
181 so, several of those dimensions have required estimation given interproximal wear and
182 postmortem breakage (Table S2). The dimensions of the CM 4254 molars are unexceptional for
183 an E/MUP (or Upper Paleolithic) human, even if the dimensions of its M² may be modestly
184 underestimated given postmortem damage (Fig. 5).

185 At the same time, the dimensions of CM 4257 are unusually large for the Upper
186 Paleolithic. The “area” (length x breadth) of the P⁴ is exceeded only by that of the E/MUP
187 Baouso da Torre 2. The M¹ “area” is above the known Upper Paleolithic range, and the M²
188 “area” is exceeded only by that of the E/MUP Oase 2 (Fig. 5). The same pattern holds if the
189 comparative sample is Late Pleistocene, thereby including Middle Paleolithic archaic and
190 modern humans. Only the Oase 2 M² and the Baouso da Torre 2 and Neandertal Obi-Rakhmat 1
191 P⁴s are larger than the Cro-Magnon 4257 teeth.

192 The dimensions of the CM 4258 molar crowns are more difficult to assess, given wear
193 and postmortem damage (Fig. 4). The more complete crown, the M₂, as preserved, has
194 mesiodistal and buccolingual diameters of 12.5 and ≈12.0 mm. Correcting for interproximal and
195 occlusal wear, they were likely ≈13.0 and ≈12.5 mm respectively. When the respective “areas”
196 (≈150 mm² and ≈162.5 mm²) are placed in an Upper Paleolithic context (Fig. 5), the latter one is
197 beyond the comparative ranges and may well be modestly too high. But the preserved
198 (minimum) values are exceeded only by the E/MUP Předmostí 9 and Oase 1.

199 Therefore, both CM 4257 and CM 4258 have unusually large teeth. Contra Vallois and
200 Billy (1965), these dimensions are exceptional. They fall in the size range especially of the Oase
201 1 and 2 molars, dentitions which have been highlighted for having very large molars for early
202 modern humans (Trinkaus et al., 2013; Trinkaus, 2018). The only Late Pleistocene M¹ and M₂
203 teeth with larger crowns are archaic human ones from the Middle/Late Pleistocene site of
204 Krapina (Wolpoff, 1979) and the Aterian sites of Dar-es-Soltane, El Haroura and Témara
205 (Hublin et al., 2012).

206

207 **4.2 Variations in Number and Position**

208 None of the Cro-Magnon alveoli or dental remains indicate dental agenesis or
209 supernumerary teeth. In particular, both sides of CM 4253 and 4256 and one side each of CM
210 4254, 4257 and 4258 indicate the presence of third molars, the most common tooth to exhibit
211 agenesis and the only one documented among E/MUP humans (Lacy, 2021). Among E/MUP
212 humans, M_3 agenesis is documented for Dolní Věstonice 16 and may have been present in
213 Předmosti 3 (Matiegka, 1934; Hillson, 2006), and supernumerary teeth occurred in Dolní
214 Věstonice 15, Pataud 1 and Sunghir 2 (Hillson, 2006; Trinkaus et al., 2014; Villotte et al., 2018).

215 At the same time, the CM 4253, 4256 and 4257 alveoli indicate several orthodontic
216 alterations. The right P_3 of CM 4253 is rotated, such that the buccal side is displaced distally, and
217 the right C_1 may have been as well (Figs. 1 and S4). Both P_3 s of CM 4256 exhibit the same
218 rotation. In addition, the I_2 s of CM 4256 were slightly rotated with the labial portion mesially
219 displaced (Figs. 3 and S7), and its right M_2 was mesially sloping, with its mesial occlusal surface
220 against the M_1 . These mandibular dental rotations (Table S3) are accompanied by a possible
221 rotation of the CM 4253 left P^3 and the rotated left P^3 of CM 4257. The two root sockets of the
222 latter tooth are aligned along the mesiodistal axis of the dental arcade (Figs. 4 and S8), indicating
223 a crown rotated $\approx 90^\circ$.

224 Rotated mandibular premolars in particular are evident in other E/MUP humans, being
225 present in Dolní Věstonice 13, 14 and 15, Muierii 1 and Pataud 1 (Hillson, 2006; Doboş et al.,
226 2010; Villotte et al., 2018). The first four are unilateral, the last is bilateral, and all involve P_4 s.
227 All of them except Muierii 1 have the buccal side displaced mesially. Rotated P_3 s are also well
228 known in both archaic and modern Middle Paleolithic humans (Rougier et al., 2006; Hillson,
229 2006; Willman et al., 2012). The etiology of rotated premolars is poorly known (Stefan, 2006),
230 but it appears to have a genetic basis (Rougier et al., 2006; McMullan and Kvam, 1990). The
231 presence of premolar rotations in three Cro-Magnon specimens, all from separate individuals
232 (see below), therefore reinforces the population coherence of the sample.

233 The CM 4258 mandible exhibits a completely impacted M_3 , such that its mesial occlusal
234 margin is in contact with the vertical middle of the distal M_2 root below the alveolar plane (Fig.
235 4). There is a bony opening into the gingival area above the M_3 occlusal surface, but even the
236 raised distal occlusal margin did not rise above the alveolar plane. As the M_3 roots are
237 completely closed, the tooth was mature and hence fully impacted. The M^3 of the CM 4257
238 maxilla is not preserved. However, the distal M^2 lacks an interproximal facet, there is a section

239 of retromolar alveolar bone distal of the M², and there is a crypt above the M² roots of an
240 appropriate size for an M³ crown (Figs. 4, S8 and S10). As noted by Vallois and Billy (1965),
241 this cavity represents the position of an impacted M³ in this maxilla. Among E/MUP humans,
242 impacted M₃s are known for Dolní Věstonice 3, 15 and 16 (Hillson, 2006; Lacy, 2014), and
243 Pataud 1 presents an impacted M³ (Villotte et al., 2018).

244

245 **4.3 Occlusal Wear**

246 The extent of dental occlusal wear was first noted by Broca (1868) with reference to
247 ages-at-death. In particular, he emphasized the marked wear (to or below the cervix) of CM 4253
248 and started the reference to the individual as a “veillard” (or old man). Indeed, the preserved
249 mesial root of the right M₁ appears to have been occlusally worn, suggesting tooth wear below
250 the root bifurcation, root separation, and continued functioning of the mesial root. Yet, the right
251 M² retained at least some of its crown enamel (see SI S1 and Fig. S2), indicating that a number
252 of the CM 4253 teeth retained crowns (see antemortem tooth loss below). It remains unclear to
253 what extent the periodontal changes of CM 4253 (see below) may have affected his rates of
254 dental wear (or vice versa).

255 The two preserved CM 4254 molars exhibit moderately pronounced wear, but
256 unexceptional for a late third or fourth decade E/MUP individual. The CM 4257 and 4258 teeth,
257 however, are markedly more worn, to similar degrees. In particular the M₁s retain little of their
258 occlusal enamel, with the CM 4258 M₁ having worn away the crown enamel on a portion of its
259 circumference. Modestly more crown is present on the M₂s.

260 There is nothing unusual in the patterns of occlusal (or interproximal) wear on these Cro-
261 Magnon teeth. Nonetheless, they permit a general seriation of these individuals by degrees of
262 wear, and assuming similar rates of wear, by ages-at-death. CM 4254 would be the youngest,
263 followed by CM 4257 and probably CM 4258, and then CM 4253 the oldest. In comparison with
264 other E/MUP individuals with dentitions and age-at-death assessments based on skeletal (non-
265 dental) aspects (e.g., Hillson et al., 2006; Trinkaus et al., 2014; de Lumley, 2016), these degrees
266 of occlusal wear suggest a range of ages-at-death for these Cro-Magnon individuals spanning the
267 fourth to the sixth decades. This implied age range is recognized to be approximate, given
268 expected variation within and between samples in rates of occlusal wear. Yet, it is sufficient to
269 provide a contrast with previous age assessments based on the auricular metamorphosis of two

270 Cro-Magnon pelvis (Gambier et al., 2006) and considerations of the degenerations of a third
271 individual (Thibeault and Villotte, 2018). Those age assessments suggest that all of the Cro-
272 Magnon individuals were at the older end of this range, in agreement with CM 4253, 4257 and
273 4258, but definitely older than CM 4254.

274

275 **4.4 Dental and Alveolar Pathology**

276 Discussions of the Cro-Magnon dentoalveolar paleopathology have focused primarily on
277 the possible antemortem loss of teeth by CM 4253 and on the alveolar lesions of that individual.
278 There have been additional comments on dental carious lesions.

279 *4.4.1 Antemortem Tooth Loss*

280 None of the alveolar remains other than CM 4253 indicate possible antemortem tooth loss
281 (AMTL). Their preserved portions either contain teeth or portions of teeth, or they present root
282 sockets with portions of the lamina dura indicating postmortem loss of the teeth. CM 4253,
283 however, retains extensively remodeled alveoli with only portions of a premolar and three molars
284 in situ.

285 Vallois and Billy (1965) stated that an unspecified number of CM 4253's teeth were lost
286 antemortem due to his alveolar lesions, although Broca (1868) and Pruner-Bey (1865-75)
287 concluded that CM 4253 retained all 32 teeth until death. The same conclusion was reached by
288 one of us (Lacy, 2014), although she inferred that some of the teeth may have been lost shortly
289 prior to death. Reassessment of the alveoli (Table S1; SI S1 and S2; see Figs. 1, S1, S3 and S4)
290 agrees with these conclusions. Four of the teeth (the M², P₃, M₁ and M₃ right) are represented by
291 roots in situ and the M² retained a small portion of the crown (Fig. S2). Twenty-five of the empty
292 alveoli retain sufficient portions of their sockets, mostly with intact lamina dura, to indicate
293 postmortem loss of the teeth. The last two teeth, the left M², the right I₂ and the left M₁, are less
294 clear. All three have alterations of their alveoli from granulomata, although each retains some
295 portion of its root socket. Either they were lost shortly prior to death, with little time for alveolar
296 remodeling, or they were still present but reduced in function given tenuous attachments to the
297 alveolar bone. CM 4253 therefore had no AMTL or minor loss close to death.

298 As a result, the Cro-Magnon dentoalveolar remains indicate little or no AMTL, despite
299 pronounced occlusal wear on the teeth of a least CM 4253, 4257 and 4258. In this aspect, they
300 follow the general pattern of E/MUP dentitions. The three other complete E/MUP dental arcades

301 with advanced wear – Caviglione 1, Dolní Věstonice 16 and Sunghir 1 – retained all of their
302 teeth (Hillson, 2006; Trinkaus et al., 2014; Pinilla et al., 2016). Clear evidence of E/MUP AMTL
303 is present on Barma Grande 4, Mladeč 1 and 8, and two isolated mandibles from Isturitz, and
304 Brno 2 and Willendorf 2 may have each lost one tooth antemortem (Lacy, 2014).

305 4.4.2. *Dental Carious Lesion*

306 There is only one apparent lesion on the teeth, a dental carious lesion. It is a small
307 occlusal pit into the dentin slightly to the lingual of the middle of the M₂ of CM 4258 (Figs. 4
308 and S12), as noted by Brennan (1991) and Lacy (2014). Dental carious lesions are relatively
309 uncommon among E/MUP individuals, having been documented on the molars of Abeilles 1898-
310 5-2, Barma Grande 2, Dolní Věstonice 13 and 15, and Pavlov 1, plus three isolated teeth from
311 Les Rois (Lacy, 2014). [Note that Pruner-Bey (1865-75) referred to alveolar osteophytic lesions
312 as “caries”; he did not document dental carious lesions.] There is no evidence of dental enamel
313 hypoplasia, although the extent of occlusal wear may have removed evidence of these
314 developmental lesions.

315 4.4.3 *Periodontal Alterations*

316 In addition, as noted and variously described by Broca (1868), Pruner-Bey (1865-75),
317 Vallois and Billy (1965) and Lacy (2014), the CM 4253 cranium and mandible exhibit a suite of
318 alveolar lesions. There is general periodontal alteration through the alveoli (SI S1 and S2), and it
319 is accompanied by three granulomata. In the maxilla, there is an area of extensive resorption on
320 the lingual sides of the left M¹ and M² alveoli, which manifests itself as a granuloma primarily
321 associated with the M² (Figs. 1 and S1). In the mandible, there is a fenestration below the left I₁
322 and I₂ (Fig. S4). It is the labial opening of a granuloma centered below the I₁/I₂ septum with its
323 largest portion below the I₁. There is new bone in the I₁ socket and rounded trabeculae in the
324 inferior portion of the cavity.

325 The primary alveolar lesion, as previously noted, is below the left P₃ to M₁ (SI S2; Figs.
326 1, S3 to S5). It consists of a large void in the middle and lateral corpus between the inferior
327 alveolar nerve canal and the remaining lingual alveoli for the P₃ to M₁. The bone was resorbed
328 around the roots of the M₁, especially near their apices. The resorbed area continues
329 buccally/laterally, such that the lateral portion of the corpus is absent from the alveolar margin
330 (or where it would have been) inferiorly to the vertical middle of the corpus. The resorptive area
331 rounds onto the lateral corpus below the M₁, and the exposed trabeculae within the exposed area

332 are rounded (see especially Fig. S5C). This area is best interpreted as a large granuloma from the
333 M₁. As noted above, it is unclear whether the M₁ was in situ at death, given the presence of
335 lingual root sockets, albeit with altered and resorbed bone.

336 The void from the left M₁ granuloma continues mesially below the P₄ and P₃, with
337 resorption of the buccal/lateral corpus along their roots. The void rounds onto the lateral corpus
338 by the P₄, slightly superior and distal of the mental foramen, and the bone within the void is
339 rounded and hence resorbed. It is unclear whether the resorptive area for the P₄ is an extension of
340 the M₁ granuloma or an additional one through the P₄. The void around the P₃ is less clear, as the
341 margins of the void consist of both rounded resorptive surfaces, small bony growths, and broken
342 edges. Therefore, the large left lateral mandibular void consists of either a granuloma of the M₁,
343 which spread mesially under the P₄ and P₃, or granulomata from the M₁ and P₄ (plus possibly the
344 P₃) that combined into a single void along the lateral corpus. A number of other E/MUP
345 individuals exhibit granulomata, both with and without extensive occlusal wear (e.g., Barma
346 Grande 4, Brno 2, Dolní Věstonice 16, Isturitz 4, 11 and 111, Mladeč 2 and 5457, Oreille
347 d'Enfer 1, Pataud 1, Pavlov 1, Předmostí 21 and 26, and Sunghir 1 (Teschler-Nicola et al., 2006;
348 Lacy, 2014; Trinkaus et al., 2006, 2014).

349 Cro-Magnon 4253 therefore has extensive periodontal disease, reflected in general
350 alveolar resorption and multiple granulomata. Given the absence of all of the tooth crowns
351 except for a small piece of the right M², it is not possible to determine to what extent the
352 granulomata were secondary to advanced dental wear. The alveoli of the other Cro-Magnon
353 individuals exhibit some resorption of the preserved alveolar crests, as reflected in cervix-to-
354 alveolar crest (CAC) heights, but the advanced wear of especially CM 4257 and 4258 suggests
355 that it may be due more to supraeruption than periodontal inflammation (see Craddock and
356 Youngson, 2004).

357 Cro-Magnon 4254, 4257 and 4258 exhibit only modest amounts of alveolar remodeling
358 from periodontal disease, to the extent that the alveolar bone is preserved. The first has little
359 alteration around the anterior teeth, but there was some resorption around the M¹ (Figs. 2 and
360 S6). A similar situation is present for the CM 4257 maxilla, although the root exposure is
361 primarily from postmortem bone loss (Figs. 4 and S8). The CM 4258 mandible, despite its
362 extensive tooth wear and hence expected supraeruption, has little change in the molar alveolar
margins where preserved around the M₂ and the impacted M₃ (Figs. 4 and S11). On the other

363 hand, the CM 4256 mandible exhibits general resorption and rounding of the alveolar crests (Fig.
364 3 and S7).

365

366 **4.5 Associations by Individual**

367 The cranial remains from Cro-Magnon have traditionally (Broca, 1868; Pruner-Bey
368 1865-75; Vallois and Billy, 1965, Villotte and Balzeau, 2018) been used to indicate the presence
369 of four adult partial skeletons (Cro-Magnon 1 to 4) in the fossil assemblage. Based on cranial
370 morphology, Cro-Magnon 1, 3 and 4 have been considered to be male, whereas Cro-Magnon 2
371 was viewed as female (i.e., Vallois and Billy, 1965). However, a reassessment of the sexes of the
372 Cro-Magnon crania (Guyomarc'h et al., 2017) was unable to confirm these sex determinations
373 for Cro-Magnon 2 and 3. Cro-Magnon 4 has been considered male based only on the moderately
374 large external occipital protuberance of CM 4259 (Vallois and Billy, 1965); similarly large ones
375 are not unusual among recent human females (Walker, 2008), making its sex ambiguous.

376 The recent resorting of the lower limb remains (Thibeault and Villotte, 2018) was only
377 able to identify three pelvically sexed adults (referred to as Alpha (male), Beta (female) and
378 Gamma (male)), although the subsequent reassessment of the upper limb remains (Villotte et al.,
379 2020) was able to identify a fourth large adult (Delta). Their ages-at-death are elderly for Alpha
380 and Beta and modestly younger for Gamma, but it is unknown but probably younger adult for
381 Delta (Thibeault and Villotte, 2018; Villotte et al., 2020). In the appendicular assessments, Alpha
382 has been linked to Cro-Magnon 1 based on sex, advanced age, carbonate coating, and systemic
383 pathological lesions (Gambier et al., 2006; Thibeault and Villotte, 2018), but the connections
384 between Beta to Delta and Cro-Magnon 2 to 4 have been left unresolved.

385 As has been accepted since the Cro-Magnon remains were first recovered, the CM 4253
386 cranium and mandible fit together (as Cro-Magnon 1) and show a similar degree of age-related
387 dental and alveolar alterations. The pathological alterations of the alveoli, however, are merely
388 advanced conditions of normal periodontal resorption combined with several granulomata, the
389 latter most likely related to advanced tooth wear and pulpal exposure (Clarke, 1990; Alt et al.,
390 1998).

391 Similarly, as noted by Pruner-Bey (1865-75), the CM 4257 and 4258 maxilla and
392 mandible make a logical pair in several respects. They exhibit very similar degrees of occlusal
393 and interproximal wear. Each exhibits an impacted M3. They have little evidence of periodontal

394 disease despite their advanced dental wear. And they both have teeth that are among the largest
395 in the E/MUP and in the Late Pleistocene generally.

396 The CM 4254 maxillae and teeth are part of the Cro-Magnon 2 cranium, which lacks a
397 directly associated mandible. The CM 4258 mandible does not fit with CM 4254 given the
398 marked contrasts in molar occlusal wear and dental dimensions. The CM 4256 mandible could
399 be associated with CM 4254; however, the periodontal resorption throughout the CM 4256
400 dental arcade contrast with the minimal alveolar changes of CM 4254, making a pairing of them
401 unlikely. As a result, the dentoalveolar remains from Cro-Magnon indicate four individuals: CM
402 4253 (Cro-Magnon 1), CM 4254 (Cro-Magnon 2), CM 4256, and CM 4257/58.

403 The first two of these dentoalveolar individuals are portions of the Cro-Magnon 1 and 2
404 craniomandibular remains. The other two represent older individuals, based on periodontal
405 alterations and dental wear. Each one could be associated with either Cro-Magnon 3 or 4, both of
406 which have been considered as an older but not aged individual, albeit on the basis of suture
407 closure (e.g., Vallois and Billy, 1965). Contra Broca (1868), Pruner-Bey (1865-75) and Vallois
408 and Billy (1965) (Table 1), it is not possible to resolve which maxilla/mandible belongs with
409 which of these crania.

410 The associations with the appendicular Alpha to Delta individuals include Cro-Magnon 1
411 with Alpha, but the others are less clear. The unsexed CM 4254 cranium (Cro-Magnon 2), as a
412 probable fourth decade adult based on dental wear, cannot be associated with the female Beta
413 given that the latter's age-at-death was ≥ 60 years based on auricular metamorphosis (Gambier et
414 al., 2006). It could be linked to the male Gamma, although it is unlikely given that Gamma's
415 age-at-death was similarly assessed to be >40 years. Assuming that there are four adults
416 represented in the Cro-Magnon sample, CM 4254 was therefore either the same individual as
417 Delta or, unlikely, Gamma. If CM 4254 and Delta were the same individual, then CM 4256 and
418 4257/58 would then be the same individuals as Beta and Gamma. It is nonetheless not possible to
419 assess which of the CM 4256 and 4257/58 dentoalveolar remains would go with Beta versus
420 Gamma.

421 The most likely combinations, therefore (Fig. 6; Table S5), are CM 4253/Cro-Magnon 1
422 with Alpha and CM 4254/Cro-Magnon 2 with Delta. CM 4256 and CM 4257/58 appear equally
423 likely to associate with either Cro-Magnon 3 or 4 and with either Beta or Gamma.

424

425 **5. Discussion and Conclusion**

426 This reassessment of the adult Cro-Magnon dental and alveolar remains provides
427 additional data on their associations by individual, ages-at-death, oral health, and dental
428 dimensions and morphology. In most respects, they fall comfortably within the patterns evident
429 in other Early and Mid Upper Paleolithic remains.

430 These dentoalveolar remains (three mandibles, a maxilla, and two maxillae within crania)
431 indicate the presence of four adults in the sample, in agreement with the cranial and upper limb
432 remains. The CM 4253 (Cro-Magnon 1) maxilla and mandible, given their advanced dental wear
433 and periodontal changes, fit well together and with the older male postcranial remains designated
434 Alpha. The modest degree of dental wear on the CM 4254 (Cro-Magnon 2) maxilla indicates a
435 younger adult, which makes it unlikely to be associated with the older Beta and Gamma
436 postcrania and therefore, by default, associates it with the Delta upper limb remains. The CM
437 4257 maxilla and 4258 mandible go together by several criteria as from an older adult. The CM
438 4256 mandible does not fit with the CM 4254 maxilla given its alveolar alterations and thus
439 remains as a separate adult. It remains unclear which of the other crania (Cro-Magnon 3 and 4)
440 or postcranial sets (Beta and Gamma) go with CM 4257/58 versus with CM 4256.

441 The Cro-Magnon dental and alveolar remains, in combination with the Alpha to Gamma
442 postcrania, therefore indicate three older adults and one younger adult in the sample. In the
443 broader European E/MUP sample of older versus younger adults (approximately <40 and >40
444 years) (Trinkaus, 2011), the addition of these four Cro-Magnon adults provides a sample with
445 32.6% (n = 43) older adults (31.4% (n = 51) if African and Asian E/MUP remains are included).
446 Although this percentage of older adults is higher than the previous value (26.5%), it remains
447 well below the average percentage (65.0%) for six ethnohistorical samples (52.0% – 80.4%),
448 below the average (39.3%) for nine recent archeological samples, and at the bottom of the range
449 for the archeological ones (30.5% – 48.5%) (Trinkaus, 2011); the lowest of these recent human
450 values has been critiqued as providing a demographic, social and subsistence-related challenges
451 to the population in question (Howell, 1982; Paine and Harpending, 1998). The addition of the
452 older age profile for the Cro-Magnon adults therefore shifts the E/MUP age distribution, but the
453 E/MUP sample still exhibits the modest number of older adults present throughout the
454 Pleistocene fossil record (Trinkaus, 2011; Streeter et al., 2001).

455 Although there has been emphasis on the condition of the alveoli of Cro-Magnon 1 since
456 the early discussions of Broca (1868) and Pruner-Bey (1865-75), the indications of oral health
457 among the Cro-Magnon adults are unexceptional for the E/MUP. Granulomata, some associated
458 with advanced dental wear, are relatively common in the E/MUP, and periodontal disease in
459 general was widespread in the Upper Paleolithic (Lacy, 2014). All of the Cro-Magnon adults
460 exhibit dental calculus, as do most Pleistocene human remains. The impacted M3s of CM
461 4257/58 do not appear to have generated any periodontal disease. These remains indicate little or
462 no antemortem tooth loss, a condition evident in many E/MUP specimens. And the small
463 occlusal carious lesion of CM 4258 adds to the modest number of such lesions among E/MUP
464 humans but does not indicate serious dental decay.

465 The only dental features of note are the premolar rotations of CM 4253, 4256 and 4257
466 and the crown dimensions of the CM 4257/58 molars. Premolar rotations are moderately
467 common among E/MUP humans, and Late Pleistocene remains in general. To the extent that
468 they are genetically determined, they provide some unity to the Cro-Magnon sample but do not
469 imply broader relationships among E/MUP humans. The dimensions of the CM 4254 M¹ and M²
470 are average for an Upper Paleolithic human, but those of CM 4257/58 are exceptional. The CM
471 4257/58 P³ is matched by only one E/MUP specimen (Baoussou da Torre 2), its M² is exceeded
472 only by that of Oase 2, and its probable M¹ and M₂ dimensions are beyond even the very large
473 teeth of the Oase 1 and 2. The only Late Pleistocene M¹ and M₂ teeth with larger crowns are
474 earlier Middle Paleolithic archaic human ones from Krapina and northwest African Aterian sites.

475 The dental and alveolar remains from the Abri de Cro-Magnon therefore contribute to the
476 disentangling of this paleontologically and historically important sample, and they provide
477 further evidence on the oral health and dental configurations of Early/Mid Upper Paleolithic
478 Europeans. With the exception of the very large molars of Cro-Magnon 4257/58, these Mid
479 Upper Paleolithic remains enter comfortably into the variation of these earlier Upper Paleolithic
480 humans.

481

482 **Acknowledgments**

483 The authors thank Veronique Laborde, Aurélie Fort (curators at the Musée de l'Homme)
484 and Dominique Grimaud-Hervé (in charge of the collection) for granting access to the Cro-
485 Magnon remains. Funding: This research was supported by ANR Gravett'Os (ANR-15-CE33-

486 0004) and the Leakey Foundation. Neither funding agency had a role in research design or
487 publication.

488

489 **References**

- 490 Alt, K.W., Türp, J.C., Wächter, R., 1998. Periapical lesions—clinical and anthropological
491 aspects. in: Alt, K.W., Rösing F.W., Teschler-Nicola M. (Eds.), *Dental Anthropology*.
492 Springer, Vienna. pp. 247-276. https://doi.org/10.1007/978-3-7091-7496-8_14.
- 493 Bailey, S., 2006. Beyond shovel-shaped incisors: Neandertal dental morphology in a
494 comparative context. *Periodicum Biologorum* 108, 253-267.
- 495 Bräuer, G., 1988. Osteometrie. in: Knussman, R. (Ed.) *Anthropologie I*. Fischer, Stuttgart. pp.
496 160-232.
- 497 Brennan, M.U., 1991. Health and disease in the Middle and Upper Paleolithic of southwestern
498 France: a bioarcheological study. Ph.D. Thesis. New York University.
- 499 Broca, P., 1868. Sur les crânes et ossements des Eyzies. *Bull. Soc. Anthropol. Paris* 3, 350–392.
500 <https://doi.org/10.3406/bmsap.1868.9548>
- 501 Clarke, N.G., 1990. Periodontal defects of pulpal origin: evidence in early man. *Am. J. Phys.*
502 *Anthropol.* 82(3), 371-376.
- 503 Craddock, H.L., Youngson, C.C., 2004. Eruptive tooth movement – the current state of
504 knowledge. *Br. Dent. J.* 197, 385-391. <https://doi:10.1038/sj.bdj.4811712>.
- 505 de Lumley, M.A., 2016. Estimation de l'âge au décès de “La Dame de Cavillon.” in: de Lumley,
506 H. (Ed.), *La Grotte du Cavillon sous la Falaise des Baousse Rouse, Grimaldi, Vintimille,*
507 *Italie III: Étude Anatomique du Squelette de “la Dame du Cavillon.”* CNRS, Paris. pp.
508 939-940.
- 509 Doboş, A., Sofîcaru, A., Trinkaus, E., 2010. The Prehistory and Paleontology of the Peştera
510 Muierii, Romania. *Étud. Rech. Archéol. Univ. Liège* 124, 1-122.
- 511 Gambier, D., Brůžek, J., Schmitt, A., Houët, F., Murail, P. 2006. Révision du sexe et de l'âge au
512 décès des fossiles de Cro-Magnon (Dordogne, France) à partir de l'os coxal. *C. R.*
513 *Palevol* 5, 735-741. <https://doi.10.1016/j.crpv.2005.12.011>.
- 514 Guyomarc'h, P., Samsel, M., Courtaud, P., Mora, P., Dutailly, B., Villotte, S., 2017. New data on
515 the paleobiology of the Gravettian individual L2A from Cussac cave (Dordogne, France)

516 through a virtual approach. *J. Archaeol. Sci. Rep.* 14, 365–373.
517 <https://doi.org/10.1016/j.jasrep.2017.06.005>.

518 Henry-Gambier, D., 2002. Les fossiles de Cro-Magnon (Les Eyzies-de-Tayac, Dordogne) :
519 nouvelles données sur leur position chronologique et leur attribution culturelle. *Bull. Soc.*
520 *Anthropol. Paris n.s.*, 14, 89–112. <http://bmsap.revues.org/459>.

521 Henry-Gambier, D., Nespoulet, R., Chiotti, L., 2013. An Early Gravettian cultural attribution for
522 the human fossils from the Cro-Magnon rock shelter (Les Eyzies-de-Tayac, Dordogne).
523 *Paleo* 24, 121–138.

524 Hillson, S.W., 2006. Dental morphology, proportions and attrition. in: Trinkaus, E., Svoboda,
525 J.A. (Eds.), *Early Modern Human Evolution in Central Europe: The People of Dolní*
526 *Věstonice and Pavlov*. Oxford University Press, New York, pp. 179-223.

527 Hillson, S.W., Franciscus, R.G., Holliday, T.W., Trinkaus, E., 2006. The ages-at-death. in:
528 Trinkaus, E., Svoboda, J.A. (Eds.), *Early Modern Human Evolution in Central Europe:*
529 *The People of Dolní Věstonice and Pavlov*. Oxford University Press, New York, pp. 31-
530 45.

531 Howell, N., 1982. Village composition implied by paleodemographic life table: the Libben site.
532 *Am. J. Phys. Anthropol.* 59, 263-269.

533 Hublin, J.J., Verna, C., Bailey, S., Smith, T., Olejnczak, A., Sbihi-Alaoui, F.Z., Zouak, M.,
534 2012. Dental evidence from the Aterian human populations of Morocco. in: Hublin, J.J.,
535 McPherron, S.P. (Eds.), *Modern Origins: A North African Perspective*, Springer,
536 Dordrecht, pp 189-204. https://doi.10.1007/978-94-007-2929-2_13.

537 Lacy, S.A., 2014. Oral Health and its Implications in Late Pleistocene Western Eurasian
538 Humans. Ph.D.Thesis, Washington University in Saint Louis.

539 Lacy, S.A., (2021). Evidence of dental agenesis in Late Pleistocene *Homo*. *Intl. J. Paleopathol.* in
540 32, 103-110. <https://doi.org/10.1016/j.ijpp.2021.01.001>.

541 Lartet, L., 1868. Une sépulture des troglodytes du Périgord (crânes des Eyzies). *Bull. Soc.*
542 *Anthropol. Paris* 3, 335–349. <https://doi.org/10.3406/bmsap.1868.9547>

543 Martínón-Torres, M., Bermúdez de Castro, J.M., Gómez-Robles, A., Prado-Simón, L., Arsuaga,
544 J.L., 2012. Morphological description and comparison of the dental remains from
545 Atapuerca-Sima de los Huesos site (Spain). *J. Hum. Evol.* 62, 7-58.
546 <https://doi.10.1016/j.jhevol.2011.08.007>.

547 Matiegka J., 1934. Homo předměstensis. Fossilní člověk z Předměstí na Moravě I. Lebky. Česká
548 Akademie Věd a Umění, Prague.

549 McMullan, R.E., Kvam, E., 1990. Investigation of premolar rotation in a group of 15-year-old
550 Norwegian children. Eur. J. Orthodont. 12, 311-315.

551 Paine, R.R., Harpending, H.C., 1998. Effect of sample bias on paleodemographic fertility
552 estimates. Am. J. Phys. Anthropol. 105, 231-240. [https://doi.org/10.1002/\(sici\)1096-](https://doi.org/10.1002/(sici)1096-8644)
553 8644.

554 Partiot, C., Trinkaus, E., Knüsel, C.J., Villotte, S., 2020. The Cro-Magnon babies: Morphology
555 and mortuary implications of the Cro-Magnon immature remains. J. Archaeol. Sci. Rep.
556 30, 102257. <https://doi.org/10.1016/j.jasrep.2020.102257>.

557 Pinilla, B., Pérez-Pérez, A., Puech, B., Puech, P.F., Garrigue, N., 2016. Usure dentaire et mode
558 masticoire de “La Dame du Cavillon.” Variabilité de la nourriture des hommes
559 modernes lors du dernier maximum glaciaire. in: de Lumley, H. (Ed.), La Grotte du
560 Cavillon sous la Falaise des Baousses Rousse, Grimaldi, Vintimille, Italie III: Étude
561 Anatomique du Squelette de “La Dame du Cavillon.” CNRS, Paris, pp. 1213-1234.

562 Pruner-Bey, F., 1865-75. An account of the human bones found in the cave of Cro-Magnon, in
563 Dordogne, in: Lartet, E., Christy, H. (Eds.), Reliquiae Aquitanicae: Being Contributions
564 to Archaeology and Palaeontology of Périgord and the Adjoining Provinces of Southern
565 France. Williams and Norgate, London, pp. 73–92.

566 Rougier, H., Crevecoeur, I., Wolpoff, M.H., 2006. Lower third premolar rotation in the Krapina
567 dental sample. Periodicum Biologorum 108, 269-278.

568 Scott, G.R., Turner, C.G. II, 1997. The Anthropology of Modern Human Teeth. Dental
569 Morphology and its Variation in Recent Human Populations. Cambridge University
570 Press, Cambridge UK.

571 Smith, B.H., 1984. Patterns of molar wear in hunter-gatherers and agriculturalists. Am. J. Phys.
572 Anthropol. 63, 39-56.

573 Stefan, V.H., 2006. Rotation of the maxillary premolars: Evidence in support of premolar
574 morphogenetic field. Dent. Anthropol. 19, 70-73.

575 Streeter, M., Stout, S.D., Trinkaus, E., Stringer, C.B., Roberts, M.B. & Parfitt, S.A., 2001.
576 Histomorphometric age assessment of the Boxgrove 1 tibial diaphysis. J. Hum. Evol. 40,
577 331-338. <https://doi.org/10.1006/jhev.2001.0460>.

578 Teschler-Nicola, M., Czerny, C., Oliva, M., Schamall, D., & Schultz, M., 2006. Pathological
579 alterations and traumas in the human skeletal remains from Mladeč. in: Teschler-Nicola,
580 M. (Ed.), *Early Modern Humans at the Moravian Gate*. Springer, Vienna. pp. 473-489.

581 Thibeault, A., Villotte, S., 2018. Disentangling Cro-Magnon: A multiproxy approach to
582 reassociate lower limb skeletal remains and to determine the biological profiles of the
583 adult individuals. *J. Archaeol. Sci. Rep.* 21, 76-86.
584 <https://doi.org/10.1016/j.jasrep.2018.06.038>.

585 Trinkaus, E. (2011) Late Pleistocene adult mortality patterns and modern human establishment.
586 *Proc. Natl. Acad. Sci USA* 108, 1267-1271. <https://doi.org/10.1073/pnas.1018700108>. Trinkaus,
587 E., 2018. An abundance of developmental anomalies and abnormalities in Pleistocene
588 people. *Proc. Natl. Acad. Sci. USA* 115(47), 11941-11946.
589 <https://doi.org/10.1073/pnas.1814989115>.

590 Trinkaus, E., Hillson, S.W., Franciscus, R.G., Holliday, T.W., 2006. Skeletal and dental
591 paleopathology. in: Trinkaus, E., Svoboda, J.A. (Eds.), *Early Modern Human Evolution*
592 *in Central Europe: The People of Dolní Věstonice and Pavlov*. Oxford University Press,
593 New York, pp. 419-458.

594 Trinkaus, E., Bailey, S.E., Rougier, H., 2013. The dental and alveolar remains of Oase 1 and 2.
595 in: Trinkaus, E., Constantin, S., Zilhão, J. (Eds.), *Life and Death at the Peștera cu Oase.*
596 *A Setting for Modern Human Emergence in Europe*. Oxford University Press, New York,
597 pp. 348-374.

598 Trinkaus, E., Buzhilova, A.P., Mednikova, M.B., Dobrovolskaya, M.V., 2014. *The People of*
599 *Sunghir: Burials, Bodies and Behavior in the Earlier Upper Paleolithic*. Oxford
600 University Press, New York.

601 Turner, C.G II, 1991. Scoring produces for key morphological traits of the permanent dentition:
602 The Arizona State University dental anthropology system. in: Kelley, M.S., Larsen, C.S.
603 (Eds.), *Advances in Dental Anthropology*, Wiley-Liss, New York, pp. 13-31.

604 Vallois, H.V., Billy, G., 1965. Nouvelles recherches sur les hommes fossiles de l'abri de Cro-
605 Magnon. *L'Anthropol.* 69, 47-74.

606 Villotte, S., Balzeau, A., 2018. Que reste-t-il des hommes de Cro-Magnon 150 ans après leur
607 découverte? *Bull. Soc. Anthropol. Paris* 30, 146-152. [https://doi.org/10.3166/bmsap-](https://doi.org/10.3166/bmsap-2018-0026)
608 [2018-0026](https://doi.org/10.3166/bmsap-2018-0026).

609 Villotte, S., Ogden, A.R., Trinkaus, E., 2018. Dental abnormalities and oral pathology of the
610 Pataud 1 Upper Paleolithic human. *Bull. Soc. Anthropol. Paris* 30, 153–161.
611 <https://doi.10.3166/bmsap-2018-0020>.

612 Villotte, S., Samsel, M., Sparacello, V., 2017. The paleobiology of two adult skeletons from
613 Baouso da Torre (Bausu da Ture) (Liguria, Italy): Implications for Gravettian lifestyle.
614 *C. R. Palevol* 16, 462–473. <https://doi.org/10.1016/j.crpv.2016.09.004>.

615 Villotte, S., Thibeault, A., Sparacello, V., Trinkaus, E., 2020. Disentangling Cro-Magnon: The
616 adult upper limb skeleton. *J. Archaeol. Sci. Rep.* 33, 102475.
617 <https://doi.org/10.1016/j.jasrep.2020.102475>.

618 Walker, P.L., 2008. Sexing skulls using discriminant function analysis of visually assessed traits.
619 *Am. J. Phys. Anthropol.* 136,39-50. <https://doi.10.1002/ajpa.20776>.

620 Willman, J.C., Maki, J., Bayle, P., Trinkaus, E., Zilhão, J., 2012. Middle Paleolithic human
621 remains from the Gruta da Oliveira (Torres Nova), Portugal. *Am. J. Phys. Anthropol.*
622 149, 39-51. <https://doi.10.1002/ajpa.22091>.

623 Wolpoff MH. 1979. The Krapina dental remains. *Am. J. Phys. Anthropol.* 50, 67-114.

624 Wood, B., Abbott, S., 1983. Analysis of the dental morphology of Plio-Pleistocene hominids. I.
625 Mandibular molars: crown area measurements and morphological traits. *J. Anat.* 136,
626 197-219.

627

628

629 **Captions to the Figures**

630 Figure 1. Occlusal views of the Cro-Magnon 4253 (Cro-Magnon 1) maxillae (above) and
631 mandible (below). The maxillary alveoli are encrusted with thin carbonate. The mandibular
632 alveoli have sustained some erosion, especially lingually by the molars, and the left buccal
633 alveolus is extensively resorbed from an M₁-centered granuloma. Portions of teeth are present for
634 the right M² and the right P₃ and M₁.

635

636 Figure 2. Occlusal view of the Cro-Magnon 4254 (Cro-Magnon 2) maxillae.

637

638 Figure 3. Occlusal view of the Cro-Magnon 4256 mandibular corpus. Portions of the roots are
639 preserved for the left I₁ and both P₃s.

640

641 Figure 4. The Cro-Magnon 4257 left maxilla in occlusal and buccal views (above) and the Cro-
642 Magnon 4258 right mandible in medial and occlusal views (below). Note that the CM 4257 P³
643 does not fit into the left maxilla, and it probably represents the right P³ of the same individual
644 (see Fig. S8).

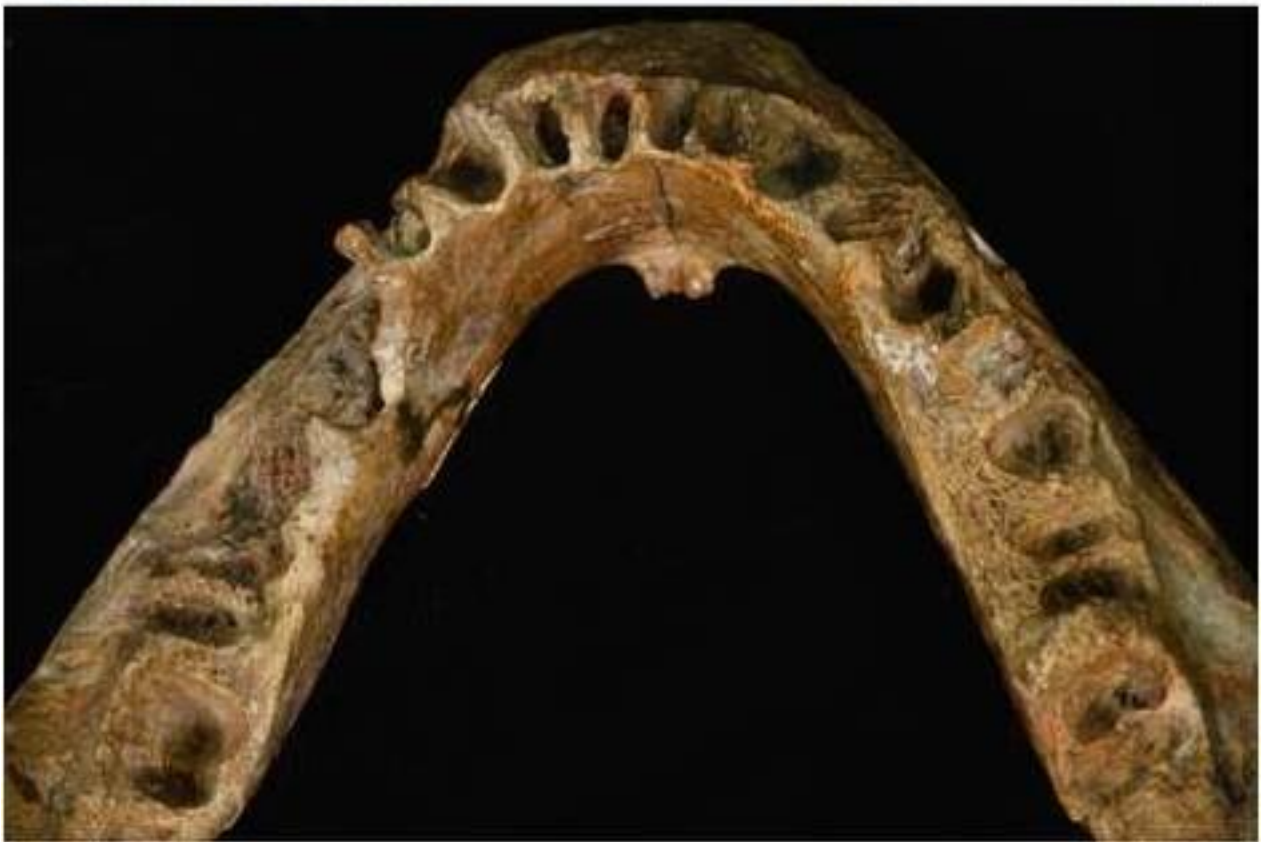645

646 Figure 5. The maxillary P⁴, M¹ and M² and mandibular M₂ crown “areas” (length x breadth) for
647 Cro-Magnon 4254, 4257 and 4258 compared to boxplot distributions of European Upper
648 Paleolithic samples: E/MUP: Early and Mid Upper Paleolithic; LUP: Late Upper Paleolithic.
649 Samples sizes are: E/MUP: 26, 49, 42 and 43; LUP: 5, 13, 11 and 12 for the P⁴, M¹, M² and M₂
650 respectively. The E/MUP high outlier in the M¹ and especially the M² plots is Oase 2 (Trinkaus
651 et al., 2013); the high E/MUP P⁴ value is Baouso da Torre (Bausu da Ture) 2 (Villotte et al.,
652 2017). The two values for CM 4258 M₂ are the minimum “area” (4258a) and the estimated
653 “area” (4258b); the high E/MUP M₂ values are Předmostí 9 and Oase 1 (Matiegka, 1934;
654 Trinkaus et al., 2013).

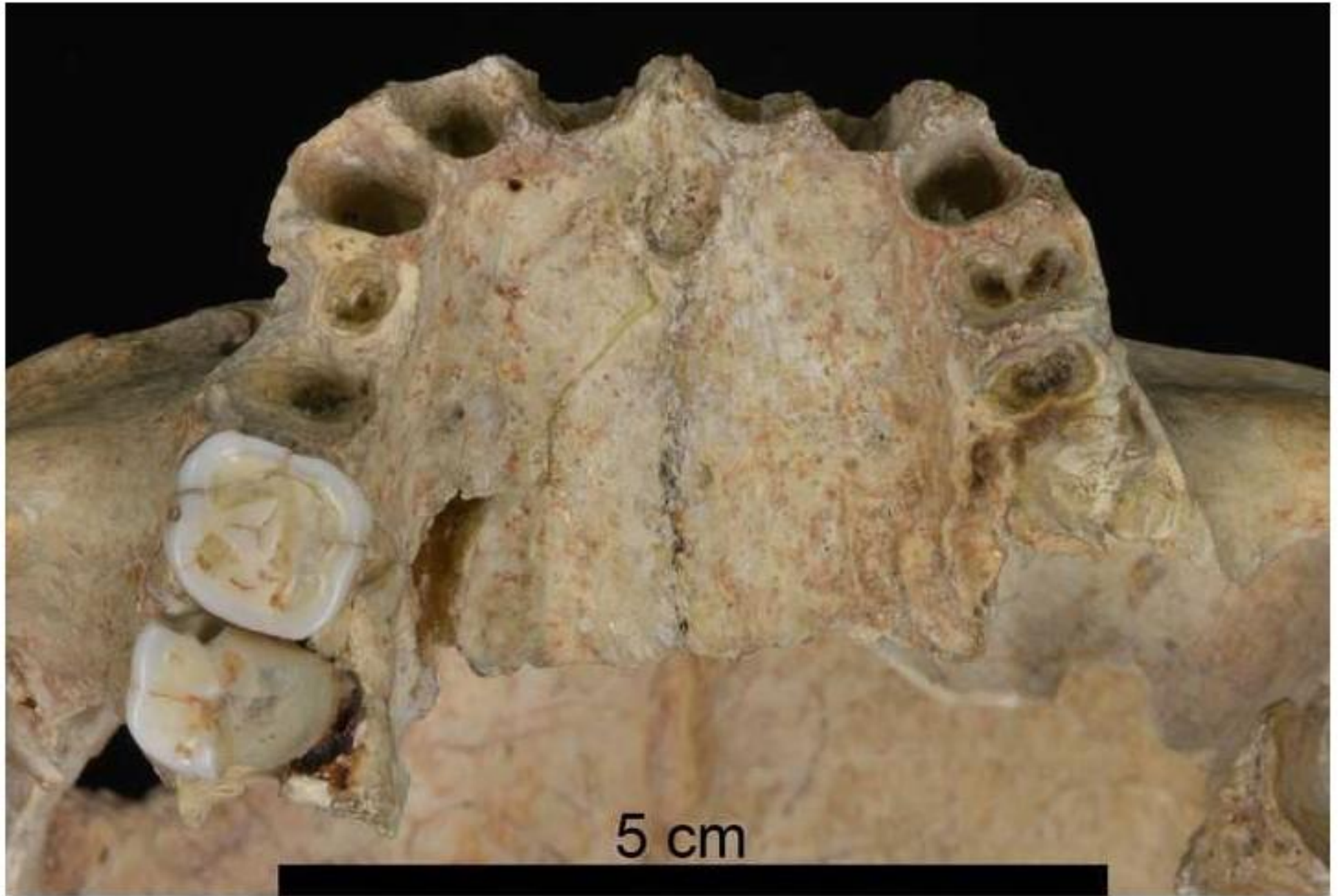
655

656 Figure 6. Probable and possible associations of the Cro-Magnon dentoalveolar remains (middle)
657 with the numbered crania (left) and the appendicular sets (right).

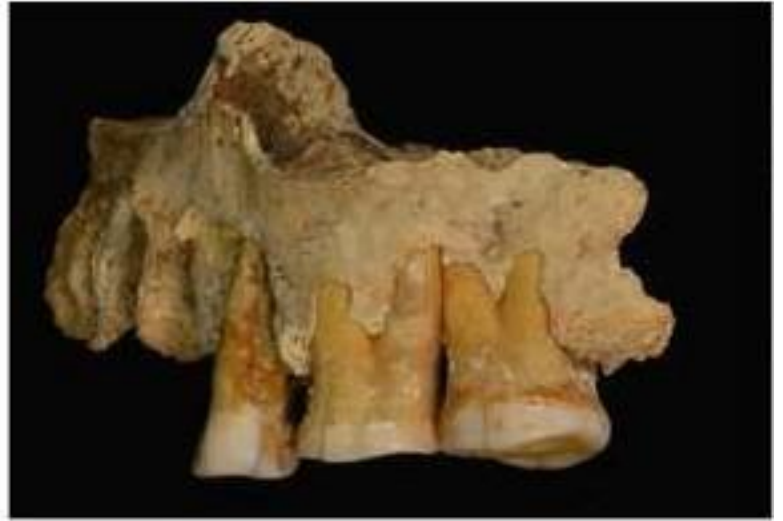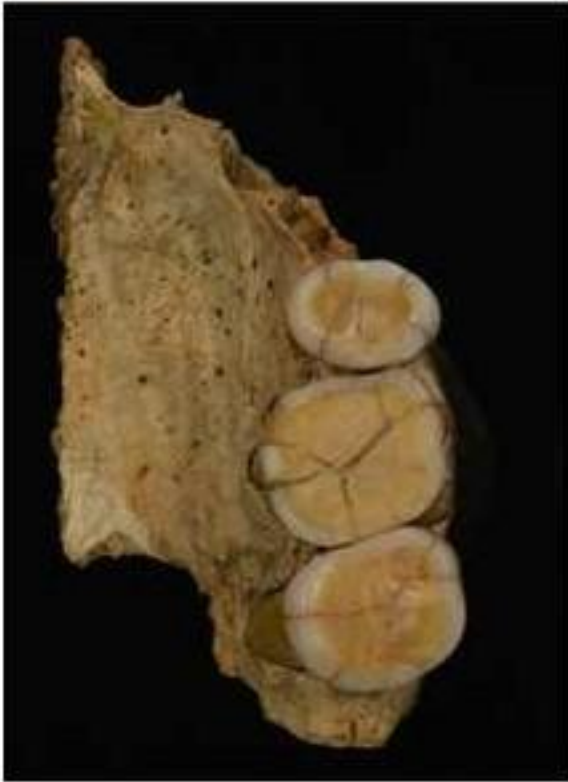658



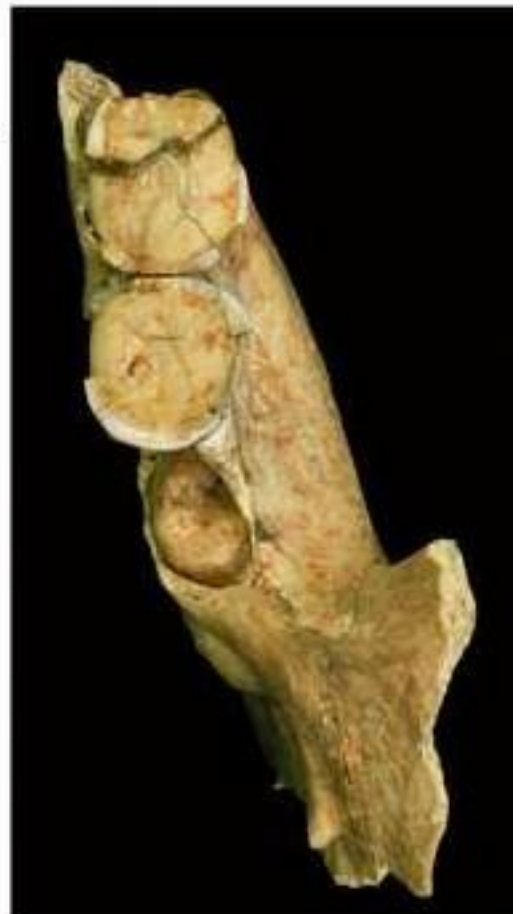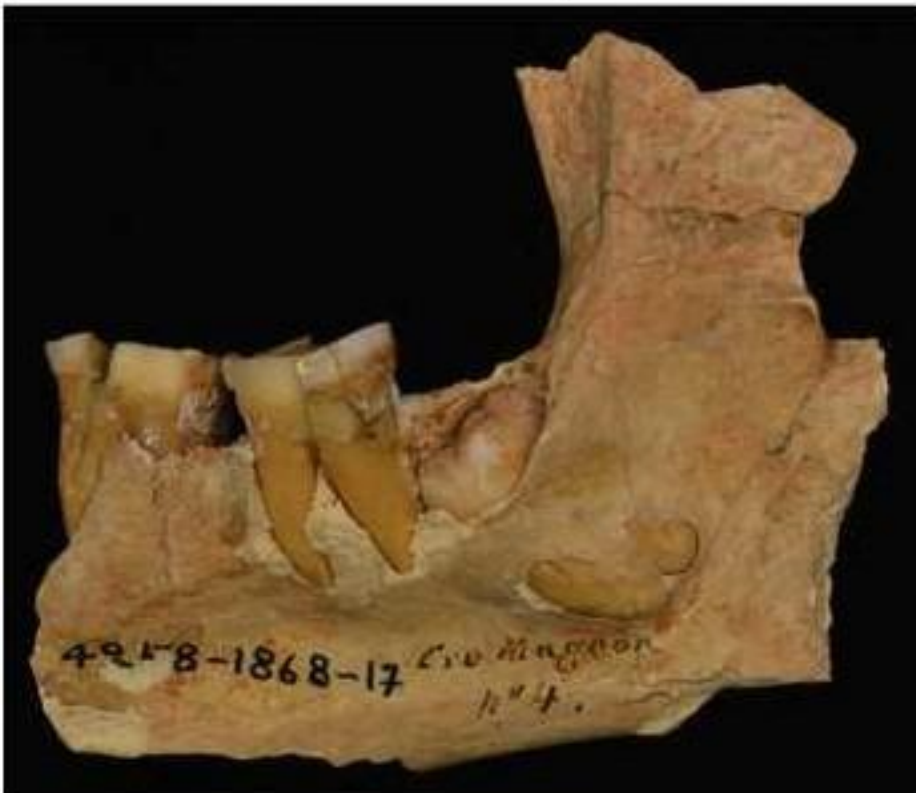5 cm

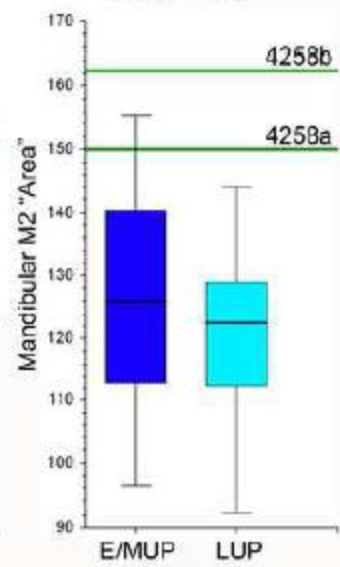
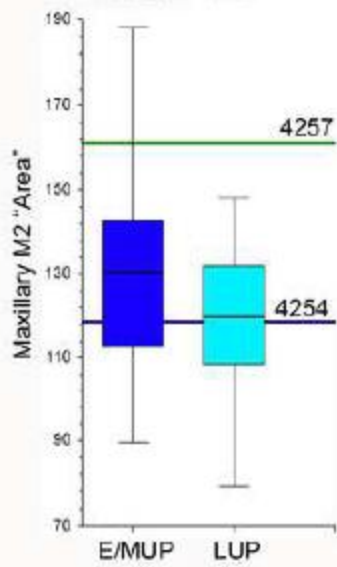
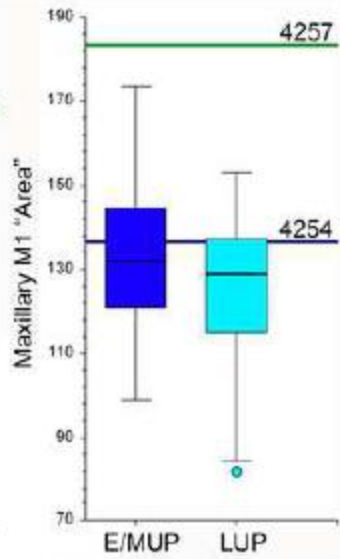
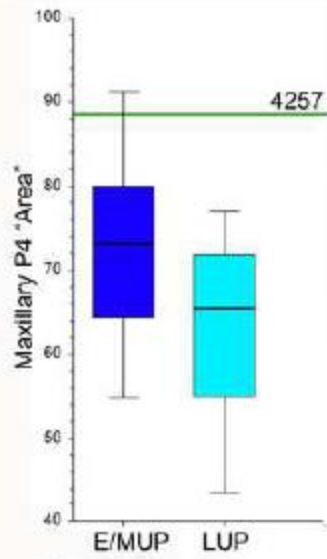






5 cm





0 |

Cro-Magnon 1 CM 4253 Alpha

Cro-Magnon 2 CM 4254

Delta

Cro-Magnon 3

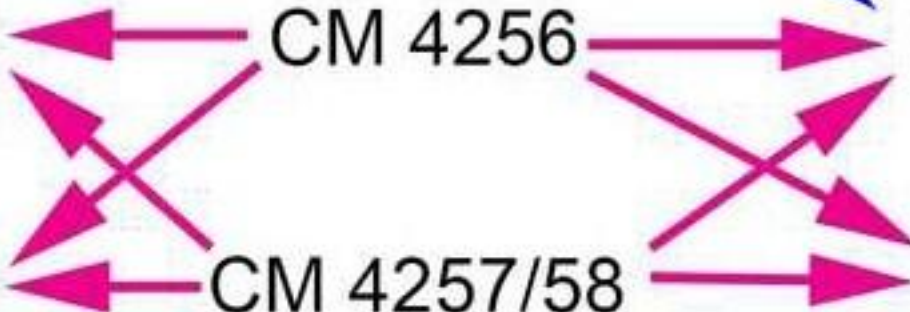
CM 4256

Gamma

Cro-Magnon 4

CM 4257/58

Beta



Author contributions:

Erik Trinkaus: Conceptualization, Data curation, Investigation, Methodology, Visualization, Writing - original draft. **Sarah A. Lacy:** Funding acquisition, Data curation, Investigation, Methodology, Writing-review & editing. **Adrien Thibeault:** Methodology, Visualization, Writing-review & editing. **Sébastien Villotte:** Conceptualization, Funding acquisition, Investigation, Project administration, Resources, Writing-review & editing.


1
2
3 **Disentangling Cro-Magnon: The Dental and Alveolar Remains**
4 **Supporting Information**
5

6 **Erik Trinkaus, Sarah A. Lacy, Adrien Thibeault and Sébastien Villotte**
7
8

9 **S1: Cro-Magnon 4253 (Cro-Magnon 1) Maxillary Dentoalveolar Remains**
10

11 All of the Cro-Magnon 1 maxillary alveoli are encrusted with a thin layer of carbonate,
12 which contains “pearls” of concretions, especially in the postcanine areas. The observations are
13 based on visual assessment of the original specimen combined with a CT slice of the maxilla
14 (Figs. S1 and S3).

15 Except as noted otherwise for molars, all of the sockets appear normal without the
16 resorption associated with antemortem tooth loss, despite damage to the alveolar margins. The
17 incisors, canines and premolars are therefore inferred to have been lost postmortem. Three of the
18 teeth, the left P³ and the right C₁ and P₃, were rotated and/or appear to have been rotated (Table
19 S3).
20



21 **Figure S1.** Occlusal view of the Cro-Magnon 4253 maxillae (left) and horizontal CT slice
22 through the alveoli of the maxillae (right). There are also palatine ridges along the
23 intermaxillary suture, whose developmental basis remains unclear (Léonard et al., 2014)
24
25

26 *I¹ Right*

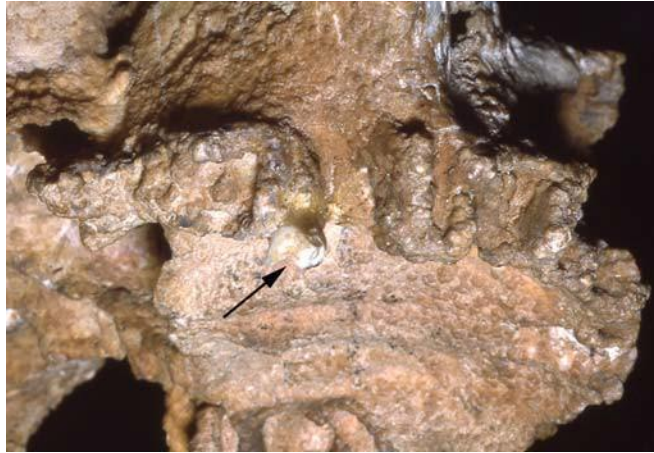
27 There is a largely complete alveolus lacking the labial margin.
28

29 *I¹ Left*

30 The alveolus is essentially complete.

31
32 *I² Right*
33 The lingual half of the alveolus remains with a portion of the mesial side. Carbonate
34 partially filling the mesial side of the socket.
35
36 *I² Left*
37 The lingual and mesial sides of the alveolus are present.
38
39 *C¹ Right*
40 The alveolus is open mesially and labially. The root is tilted such that its apex points
41 distally. based on the lingual side of the socket.
42
43 *C¹ Left*
44 Primarily the lingual side of the tooth socket is preserved. The lingual socket, and hence
45 the root, is angled superior-distally to occlusal-mesially more than the right one.
46
47 *P³ Right*
48 A normal and largely preserved socket is vertically set in maxilla. It appears
49 radiographically to have been single rooted.
50
51 *P³ Left*
52 It appears as a normal, mesiodistally compressed socket, open buccally but intact,
53 especially lingually and distally. The socket slants superior-distally to occlusal-mesially, along
54 with the left C¹. It appears radiographically to have been single rooted. The lingual root is also
55 displaced slightly mesially, suggesting some mesiolingual to distobuccal rotation of the tooth.
56
57 *P⁴ Right*
58 The alveolus is visually obscured, but radiographically the socket appears normal and
59 single rooted.
60
61 *P⁴ Left*
62 The tooth socket is broken open buccally and partially distally. The socket, and hence the
63 root, slants superior-distally to occlusal-mesially, along with the left C¹ and P³.
64
65 *M¹ Right*
66 The alveolus of the right M¹ is damaged lingually and buccally, but it exhibits the apex
67 area and most of the mesial side of the lingual root socket, and an open area for the distobuccal
68 root. The area of the mesiobuccal root is less apparent, but it is likely represented by a buccal
69 depression evident especially radiographically.
70
71 *M¹ Left*
72 There is buccal exposure of both buccal root sockets and lingual exposure of the lingual
73 root socket. All three sockets (hence roots) appear to have been complete, although the distal
74 side of the lingual root socket appears to have been partially resorbed (see M² left). All of the
75 root sockets slant mesially, such that the whole tooth would have been markedly tilted mesially.

76 For the mesiobuccal root, its angle to the approximate alveolar plane is 40°-55°. The condition of
77 the sockets indicates postmortem loss despite the lingual alveolar resorption.
78



79
80 **Figure S2.** The Cro-Magnon 4253 right maxillary alveolus and dentition, with the originally
81 remaining portion of the M² exhibiting crown enamel preservation.
82

83 *M² Right*

84 The right M² was in situ at death. The normal three roots are evident in the radiographic
85 slice, and there is a portion of the mesiolingual cervix exposed currently. However, at least in
86 1985 (when photographed by ET), the mesiolingual corner of the crown extended to the occlusal
87 surface, retaining at least 2 mm of the crown height (Fig. S2). It is therefore inferred that most,
88 if not all of the crown, was present and functioning at the time of death.
89

90 *M² Left*

91 The M² socket is an open, irregularly circular cavity about ≈9 mm in diameter. There is
92 nonetheless a buccal groove for the distobuccal root at its distobuccal corner, but otherwise the
93 void is irregularly smooth or at least without root indications. The lingual side is open,
94 continuing distally the resorption on the lingual side of the M¹ lingual root alveolus. The M²
95 buccal alveolus side retains its bony wall.

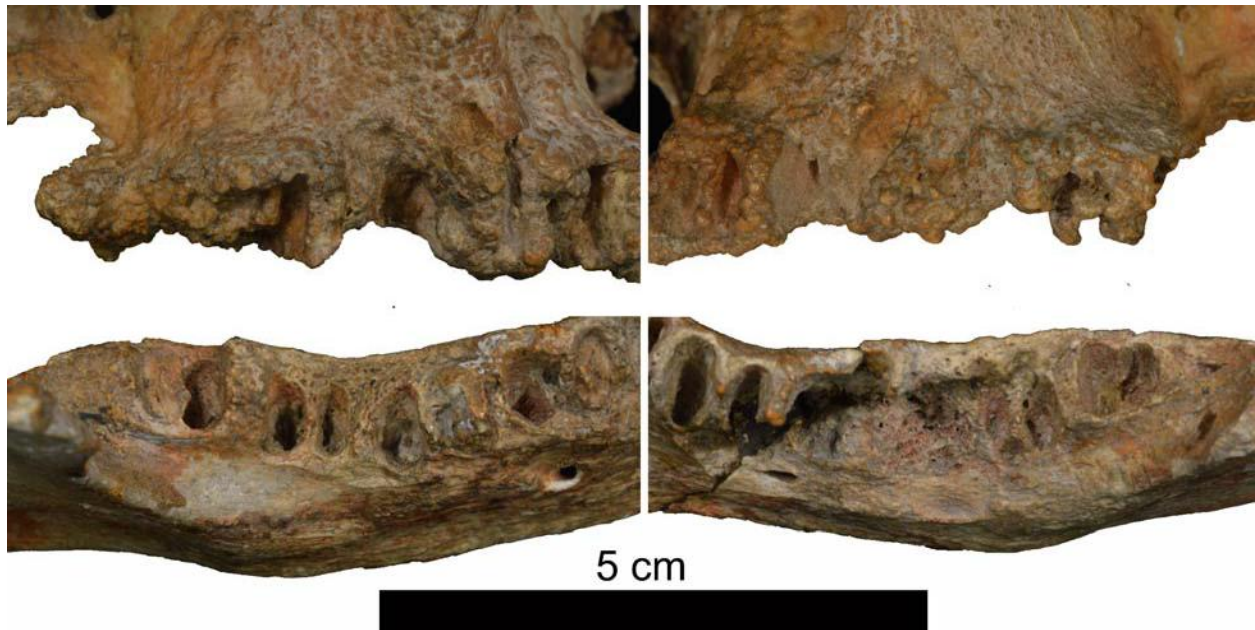96 The tooth therefore appears to have had a large lingual granuloma, especially around the
97 lingual and mesiobuccal roots, The tooth may have been lost antemortem, but if so, shortly prior
98 to death. Alternatively, the tooth was retained by the distobuccal root but reduced in function.
99

100 *M³ Right*

101 The tooth is absent, but in occlusal view the alveolus is evident with the clear apical
102 sockets for the three roots with short septa between the depressions. The M³ was therefore three-
103 rooted and apparently lost postmortem..
104

105 *M³ Left*

106 The area of the left M³ retains (in matrix) buccal bone for its alveolus and what appear to
107 be small sockets for three roots. The two buccal sockets are separate but very close together, and
108 the lingual one is very separate and displaced distally of the distobuccal root. It appears that the
109 tooth was present at death, but that it was altered in position.
110



112

113

114

115

116

117

118

119

120

121

122

123

124

125

126

127

128

129

130

131

132

133

134

135

136

137

138

139

Figure S3. The premolar and molar alveoli of Cro-Magnon 4253 in bucco-occlusal views. The maxillary arcades are above and the right sides are to the left. Note the large resorptive area of the left mandibular M₁ area, and the remains of the right P₃, mesial M₁ and distal M₃ roots.

S2: Cro-Magnon 4253 (Cro-Magnon 1) Mandibular Dentoalveolar Remains

The mandibular alveoli lack the carbonate encrustation of the maxillary alveoli. However, most of them sustained postmortem erosion, especially labially by the anterior teeth and linguallly along the postcanine teeth (Figs. S3 and S4). The preserved dental remains consist of portions of the right P₃ root, the right M₁ mesial root, and the right M₃ distal root.

There was extensive antemortem resorption buccally by the left P₄ and M₁ with possible antemortem tooth loss, and the right I₂ socket apex contains a bony growth suggesting antemortem tooth loss (see below). All of the other alveoli indicate postmortem loss of the teeth.

I₁ Right

The root socket has the lingual and mesial alveolar margins intact. The other alveolar margins are largely eroded.

I₁ Left

The left I₁ preserves a complete socket with eroded alveolar margins. The apex of the socket opens into a granuloma that has its largest portion and opening below the left I₁ (Fig. S4). The anterior/labial opening of the granuloma has been broken superiorly and distally, but the core of the fenestration and its mesial and inferior margins are the original bone. The fenestration is 4.8 mm wide, currently 9.1 mm high, but originally 4.5-5.0 mm high. The interior

140 of the granuloma has new bone laid down up into I₁ left socket, but mostly rounded trabeculae
141 are exposed in lower portion of it.

142
143



144
145 **Figure S4.** The Cro-Magnon 4253 Mandible in occlusal view (left), detail of the anterior alveoli
146 (middle) with the granuloma fenestration below the left incisors, and radiograph of the
147 incisor granuloma (right). Scale for the superior view only.

148

149 *I₂ Right*

150 The socket consists of a lingual margin and the lower portion of the I_{1/2} septum, with loss
151 of the labial and distal margins of the socket. There is an expansion of the apical region of the
152 socket partly filled with matrix distally, but the middle portion has a bony growth within it.
153 Therefore, the tooth was probably lost shortly before death, with only partial remodeling of the
154 socket and a bony growth around the apex of the socket.

155

156 *I₂ Left*

157 The tooth socket is complete with the labial midline and mesial septum lower than the
158 distal I₂ septum. The apex opens in a moderately large granuloma that is below the I_{1/2} septum
159 and enlarged primarily below the I₁ socket (see left I₁).

160

161 *C₁ Right*

162 The lingual socket remains with intact lamina dura. It has lost of all but a small superior
163 the lingual edge of the mesial (I₂/C₁) septum, but most of the lingual margin and two-thirds of
164 the distal septum with lamina dura are preserved. All of the labial socket is gone except for the
165 lower few millimeters to the apex. The labial edge is rounded with tiny knobs of bone, and
166 therefore the labial alveolus was resorbed with the tooth in place. The preserved deeper portion
167 of the tooth socket suggests some mesiolingual to distobuccal rotation of the root, similar to the
168 right P₃, but its extent is unclear given the labial alveolar damage.

169

170 *C₁ Left*

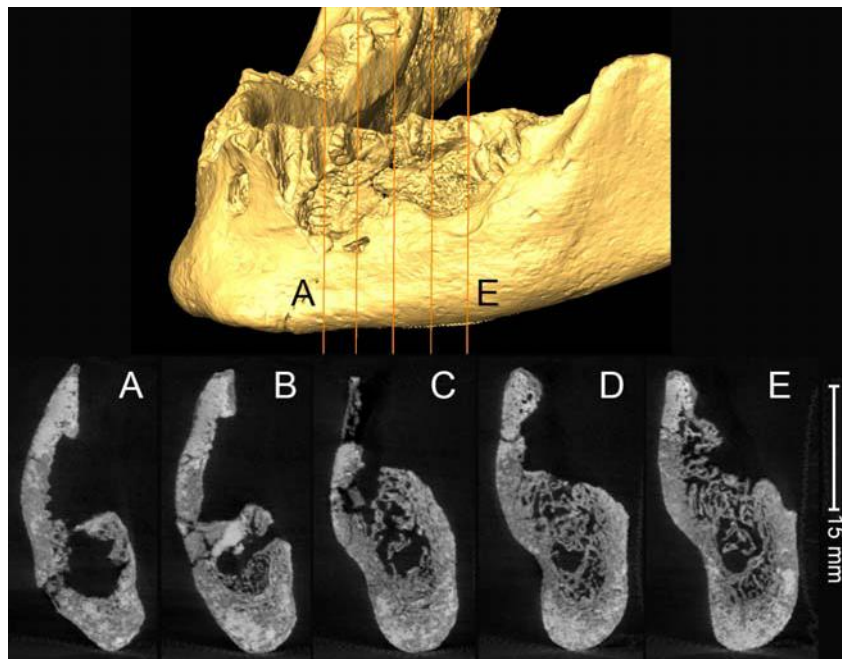
171 The largely complete socket is preserved with the mesial, lingual and distal walls
172 presenting with clean lamina dura. Almost all of the labial wall is absent; the edges appear
173 broken, but they are rounded and there are small growths of bone on them especially around the
174 inferior half of the socket. Therefore, the tooth was in situ, but there was resorption of the labial

175 wall. The maximum height of the socket is 15.3 mm, but only ≈ 1.5 mm remained on the labial
176 side.

177
178 *P₃ – M₁ Left*

179 There is a large void below the left P₃ and P₄, back to the M₁ (Figs. S3 to S5). The bone is
180 clearly resorbed where the M₁ should be, especially at the bottoms of the root sockets and the
181 buccal side, with a rounding out onto the lateral corpus. The buccal/lateral bone is broken below
182 the P₃ and partially broken below the P₄, and it is unclear to what extent the large void below the
183 P₃ and P₄ is resorption versus breakage.

184



185
186
187 **Figure S5.** Above: anterolateral virtual reconstruction of the Cro-Magnon 4253 left mandibular
188 corpus with the positions (A to E) of the CT slices through the P₃ to M₁ resorptive area.
189 Below: the CT slices (lateral to the right) through the damaged and pathologically
190 resorbed area of the mandible.

191
192 *P₃ Right*

193 The socket is present and contains the broken root. The alveolar margin is intact lingually, but it
194 slopes down buccally such that it is ≈ 10 mm lower buccally. The same small
195 buccal growths are present as with the C₁. The root is rotated such that it is oriented mesiolingual
196 to distobuccal.

197
198 *P₃ Left*

199 The superior 10.4 mm of the lamina dura is present mesially and 6.7 mm of it distally
200 with the appropriate septa for the root sides, along with 8.2 mm of the lingual socket with its
201 lamina dura. The adjacent lateral wall is absent, but its lateral edges have rows of small bony
202 growths, and hence there was resorption of the buccal wall antemortem. The remainder of the
203 root socket would have been within the lateral corporeal void, which has broken edges. The P₃

204 therefore sustained buccal socket resorption, possibly extending interiorly to its apex, but the
205 tooth remained in situ.

206

207 *P₄ Right*

208 The single rooted socket is mostly preserved with the buccal margin lower by 7.8 than the
209 lingual one; the adjacent septa slope down from the largely normal lingual alveolar margin.
210 There is the same rounding of the edges as with the P₃. The socket is broken within the mesial
211 side, but the lamina dura appears mostly normal.

212

213 *P₄ Left*

214 The socket and its lamina dura are preserved only on the mesial septum with P₃ and on
215 the mesial half of the lingual side. The distal and buccal sides are absent. There is a large void
216 under the preserved portion. Approximately where the root apex should be ends in irregular
217 rounded bone that rounds out onto the lateral corpus. This portion of the reworked bone is just
218 superior and just distal of the mental foramen. The preservation of mesial and lingual lamina
219 dura suggests that the tooth was at least tenuously in situ at death, even through most of its
220 socket was resorbed.

221

222 *M₁ Right*

223 The lingual alveolar margin is eroded, but the root sockets and the buccal side are intact,
224 with resorption of the buccal alveolus. The mesial root socket retains the broken mesial and
225 lingual portions of the mesial root in place. It is unclear whether the mesial root was merely
226 broken postmortem and eroded (as is most of the mandible), or whether it was worn down to the
227 root, with the consequent separation of the two roots. The distal root socket is empty and had
228 expanded around the superior alveolar margin, with a tiny raised lip of bone buccally. It is
229 unclear whether the distal root was lost antemortem, after separation from the mesial root and
230 resorption around the socket, or if it was lost postmortem.

231

232 *M₁ Left*

233 The only remaining portion of the left M₁ socket is a distolingual and lingual section for
234 the mesial root. For the distolingual corner, there is a small area 5.7 mm obliquely wide and 7.6
235 mm high at the alveolar margin. The lateral margin of it distally is a rounded small bony growth.
236 The small portion of the original lingual alveolar margin is rounded and reduced in height. The
237 margin is 4.6 mm thick, and 5.6 mm high. It lacks the lamina dura and exhibits soft and porous
238 bone.

239 Below these portions of mesial root socket is a void, which ends inferiorly in a large area
240 of irregular, rounded trabecular bone. The fossa is 9.7 mm wide and 10.9 mm mesiodistally, with
241 the lowest point distal. It is not possible to discern root apices within it. The bottom of the area
242 rounds out onto the lateral corpus, with a strip of cortical bone 6 mm wide with a small lip
243 laterally demarcating it.

244 The distal P₄ / mesial M₁ septum is completely absent. The mesial M₂ / distal M₁ septum
245 consists of a small and sharp ridge along the mesial edge of the M₂ mesial root apical socket.
246 These aspects reflect a large granuloma that resulted in the resorption of the mesial, distal and
247 buccal M₁ socket, and then rounding off of the remaining bone. It secondarily involved the P₄
248 and less so the M₂. It remains uncertain whether the small piece of porous bone on the lingual
249 mesial root socket indicates that the tooth was still in situ at death.

250
251
252
253
254
255
256
257
258
259
260
261
262
263
264
265
266
267
268
269
270
271
272
273
274
275
276
277
278
279
280
281

M₂ Right

The alveolus presents complete double root sockets with a normal interradicular septum. The lamina dura is intact. Although slightly broken, the buccal alveolar margin was partially resorbed. The lingual alveolus was broken postmortem. The M₂/M₃ septum is thickened across its width to 4.8 mm.

M₂ Left

The lingual alveolar border was slightly reduced and thickened to 4.2 mm, but the buccal alveolar margin was reduced down to the level of the lateral eminence. The mesial septum is largely absent, reduced to a thin edge that barely projects (see left M₁). The M₂/M₃ septum is thickened, 3.0 mm in its middle, and it is high, probably close to the original alveolar height. The interroot septum is high and 1.4 mm thick, somewhat below the preserved lingual alveolar margin. The lamina dura where present is largely intact, but there is porosity towards the apex and on the lingual side of the distal root socket. The combination of features suggests a tooth tilted modestly towards the absent M₁, in the aftermath of the M₁ loss.

M₃ Right

There is an intact socket with the distal root in place; it was broken off at the lingual alveolar level. There was a clear separation of the two roots, but with a thin interradicular septum. The higher alveolar areas mesial and distal of the socket should both be close to the original “healthy” alveolar level. The lingual and buccal alveoli, however, are resorbed.

M₃ Left

The socket presents intact lamina dura with minimal fine porosity near the apex. There is modest reduction of the lingual alveolus and into the retromolar area. The roots were partially separated near the apex, but mostly there are interradicular septa present along the lingual and buccal margins of the socket.

Table S1. Antemortem versus postmortem loss of the Cro-Magnon 4253 (Cro-Magnon 1) teeth.^{1,2}.

	Maxilla Right	Maxilla Left	Mandible Right	Mandible Left
I1	PM	PM	PM	PM
I2	PM	PM	(AM/PM)	PM
C	PM	PM	PM	PM
P3	PM	PM	Root	PM
P4	PM	PM	PM	(PM)
M1	PM	PM	Partial root	(AM/PM)
M2	Partial tooth	(PM)	PM	PM
M3	PM	PM	Partial root	PM

¹ PM indicates probable antemortem or postmortem tooth loss respectively. AM/PM indicates uncertainty as to whether the tooth was lost antemortem or postmortem.

² Parentheses around “AM” or “PM” indicates uncertainty in the assessment.

282
283
284
285
286

287 **S3: Cro-Magnon 4254 (Cro-Magnon 2) Maxillary Dentoalveolar Remains**

288

289 The Cro-Magnon 4254 maxillary alveoli, part of the Cro-Magnon 2 cranium, are largely
290 preserved from the right mesiolingual M³ socket around anteriorly to the left mesial M² alveolus
291 (Fig. S6). The labial surfaces are absent from the right I¹ to the left I², and there is breakage to
292 the buccal right P³ and P⁴ alveoli. The bone is otherwise well preserved, clean of matrix, and
293 retains most of its alveolar crest. There are two largely complete right molars and a root
294 fragment in situ in the left M¹ alveolus.

295 All of the alveoli either preserve teeth or tooth fragments or are clean and open with
296 normal lamina dura. There is no evidence of antemortem tooth loss. Most of the left M¹
297 alveolus and all of the left M³ alveolus and adjacent maxilla are absent, providing little or no data
298 on those teeth. The only non-dental anomaly is a wide (3.6 mm) diastema between the I¹'s.

299

300 *I¹ Right*

301 The lingual half of the alveolus with the intact lingual alveolar margin is present. There
302 is no resorption or other alterations, except for a slight rounding of alveolar crests. There is a
303 separation of 3.6 mm between the I¹ alveoli and across the intermaxillary suture.

304

305 *I¹ Left*

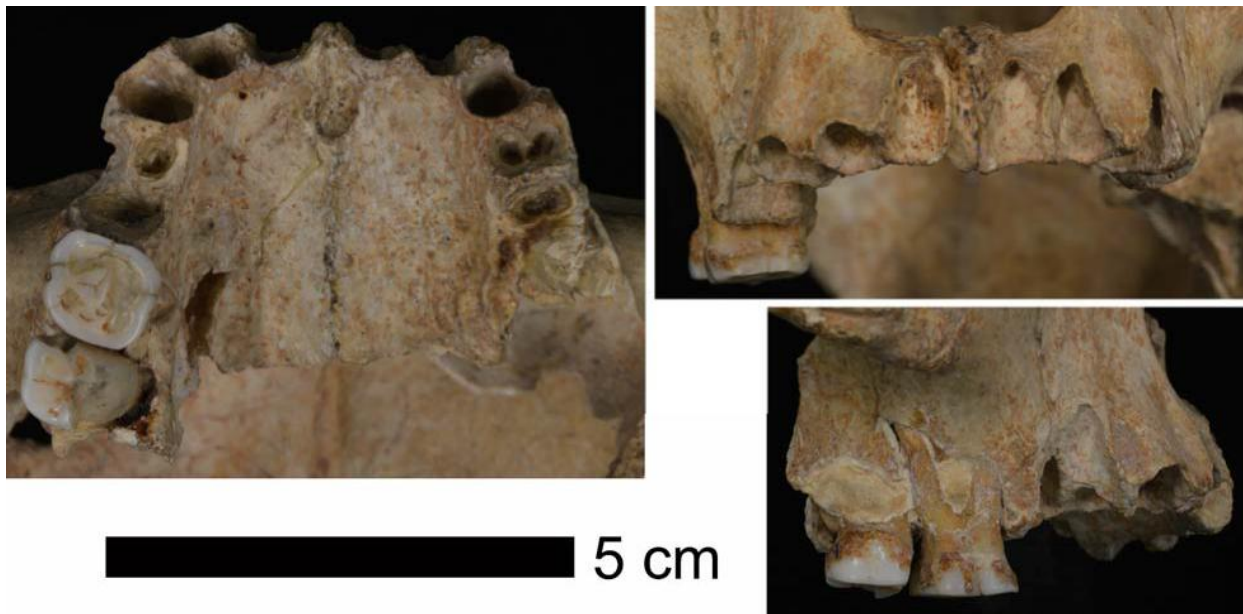
306 The lingual half of the alveolus is present with the intact lingual and mesial alveolar
307 margins. There is no resorption or other alterations, except for a slight rounding of alveolar
308 crests.

309

310 *I² Right*

311 The alveolus is complete except for a slight loss of the thin bone on the labial margin of
312 the socket. There is a slight irregularity of the mesial and distal interdental alveolar crests.

313



314

315 **Figure S6.** The Cro-Magnon 4254 (Cro-Magnon 2) maxillae in occlusal (left), anterior (upper
316 right) and right lateral (lower right) views.

317

318 *P² Left*

319 The lingual and distal sides of the socket are preserved, with breakage to the mesial and
320 labial sides. There is a slight irregularity of the mesial and distal interdental alveolar crests.

321

322 *C¹ Right*

323 The alveolus presents a large ovoid socket, that extends 15-16 mm up into maxilla, with
324 the apex curving distally at the top over the P³ socket (see right P³). The alveolar crest is intact,
325 if slightly rising on the labial side.

326

327 *C¹ Left*

328 The large ovoid socket is similar to the right one, but with the labial side broken. The
329 socket is shorter than the right one (14.4 mm from the C¹/P³ septum); it is straight and conical,
330 with none of the apical distal curving evident on the right.

331

332 *P³ Right*

333 The P³ alveolus is broken away buccally and abraded lingually, but it is otherwise intact.
334 There is a small socket lingually, with its maximum diameter of 5.0 mm oriented obliquely to the
335 tooth row, up against the distolingual C¹ socket. The long axis is mesiolingual to distobuccal.
336 The maximum depth of 5-6 mm may have been constrained by the C¹ root curving above it.

337 The buccal root was longer but thinner, with its socket extending 12.5 mm from the
338 alveolar crest. It is slightly obliquely oriented, more mesial occlusally and more distal above.
339 The buccal side of the buccal alveolus would have protruded buccally relative to the external
340 sides of the C¹ and P⁴ alveoli.

341 The P³ was probably a two rooted tooth (as was the left P³), but with markedly
342 asymmetrical buccal and lingual root, the latter being much smaller in diameter and length than
343 the former.

344

345 *P³ Left*

346 The alveolus exhibits a broad rectangular socket with rounded buccal and lingual
347 margins. The P³ had a clear double root, although the septum is incomplete on the mesial side
348 and largely absent on the distal side until ≈7 mm down from the C¹/P³ septum. There is a little
349 rounding of the alveolar margins, with a slight retraction of the alveolar crest on the lingual side
350 and the buccal margins.

351

352 *P⁴ Right*

353 The alveolus presents a normal P⁴ single rooted socket, tapering to a rounded apex. It
354 was broken buccally and mesiobuccally, but intact lingually and distally.

355

356 *P⁴ Left*

357 There is a normal single rooted P⁴ socket, which is relatively shallow (7.9 mm versus
358 10.5 mm for the right P⁴). There is a small but distinct midline ridge on distal side of the socket,
359 indicating a longitudinal sulcus on the root, but no bifurcation. The distal half of the alveolar
360 crest is a thin and rounded margin.

361

362

363

364 *M¹ Right*

365 The right M¹ presents a complete tooth (despite normal occlusal wear) in situ. The
 366 lingual root is exposed near the cervix due to postmortem bone loss, and the buccal roots are
 367 almost completely exposed buccally due to postmortem surface bone loss. The tooth is
 368 moderately worn (Smith (1984) stage 5a). There are the remains of extensive calculus on the
 369 crown and cervix.

370
 371 *M¹ Left*

372 The preserved alveolus consists primarily of the mesial and lingual margins with small
 373 portions of the adjacent root sockets. The buccal alveolus is broken, and the buccal two-thirds of
 374 the area is plastic filler. The lingual alveolar margin is greatly reduced and descends at the level
 375 of the M¹/M² septum almost to the palate. The edge is rounded and irregular, and has a small
 376 foramen at its mesial (P⁴/M¹) end. Within the area of the socket, along the inside of the raised
 377 lingual edge, there is the ≈4.3 mm long apical end of the lingual root.

378 Therefore, the left M¹ left appears to have experienced serious alveolar resorption,
 379 especially lingually, that began mesially in the mid-P⁴ socket and continued through the M¹ to
 380 reach close to the level of the M¹ lingual root apex and the palate. Hence the left M¹ was in
 381 place at death, but its roots were extensively exposed, especially lingually.

382
 383 **Table S2.** Dental mesiodistal (MD) and buccolingual (BL) crown diameters of the sufficiently
 384 intact Cro-Magnon teeth compared to those of Early/Mid (E/MUP) and Late (LUP)
 385 Upper Paleolithic samples [mean ± standard deviation (N)], in millimeters.
 386

	4254	4257	4258	E/MUP	LUP	p ¹
P ⁴ MD		7.9		7.1 ± 0.5 (21)	6.5 ± 0.7 (10)	0.008*
P ⁴ BL		11.2		9.9 ± 0.6 (31)	9.6 ± 0.6 (16)	0.079
M ¹ MD	(11.0)	(13.0)		10.8 ± 0.7 (46)	10.5 ± 0.9 (17)	0.206
M ¹ BL	12.4	14.1		12.2 ± 0.8 (49)	11.8 ± 1.0 (33)	0.027
M ² MD	(9.5)	(11.6)		10.3 ± 0.9 (39)	10.0 ± 0.8 (14)	0.190
M ² BL	(12.5)	13.9		12.4 ± 0.9 (43)	11.9 ± 1.1 (31)	0.038
M ₂ MD			(13.0) ²	11.4 ± 0.8 (44)	11.0 ± 0.8 (12)	0.166
M ₂ BL			(12.5) ²	11.0 ± 0.7 (51)	10.8 ± 0.7 (36)	0.182
M ₃ MD			(11.9)	11.4 ± 1.0 (20)	10.7 ± 0.7 (11)	0.052

387 ¹ ANOVA p-values across the two comparative samples. *: Only the P⁴ MD diameters are significantly
 388 different at p < 0.05 with a multiple comparison correction.

389 ² The CM 4258 M₂ diameters are the estimated values. The actual values are ≥12.5 and ≥12.0 mm
 390 respectively (see text below).
 391

392 *M² Right*

393 The right M² alveolus retains the complete lingual side, rounding into the M¹/M² septum
 394 mesially and the M²/M³ septum distally. The buccal and distal alveolus is absent and partially
 395 filled with plaster. The tooth is largely in place, but with a 1.8 mm gap with sediment lingually.
 396 The roots and dentin core are largely complete, but the enamel lacks the lingual half and the
 397 mesial margin. The tooth shows little wear (Smith stage 3b). There is half of a small distal
 398 interproximal wear facet preserved.

399 The current gap between lingual alveolus and the M² was filled with wax in the 1970s,
 400 and the wax had been removed by the 1980s, following photos by ET taken in 1978 and 1985. It

401 is therefore likely that the tooth was observed and measured in the 1960s by Vallois and Billy
402 (1965) with the wax in place. The lingual half of the crown enamel was absent at both times,
403 and sediment traces on the exposed dentoenamel surface suggests that the enamel was lost prior
404 to 1868. The M² crown diameters of Vallois and Billy (1965), of 12 and 9 mm, are therefore of
405 the reduced tooth; estimation of the missing enamel provides mesiodistal and buccolingual
406 crown diameters of ≈9.5 and ≈12.5 mm respectively. The tooth also exhibits extensive calculus
407 on the crown.

408
409 *M² Left*

410 The only evidence for the left M² is an edge of its lingual alveolus 7.7 mm long, that
411 continues the resorbed edge of the M¹ alveolus. It is only slightly above the level of the palate
412 and reaches the palatal level distally. There is a hint of the mesial end of its lingual root socket
413 apex.

414
415 *M³ Right*

416 There is a small area of mesiolingual lamina dura, 3.8 mm wide and 7.8 mm high, distal
417 of the M² socket, for the M³. In combination with the distal interproximal facet on the M², it
418 indicates that the M³ was in occlusion normally.

419
420

421 **S4: Cro-Magnon 4256 Mandibular Dentoalveolar Remains**

422
423 The Cro-Magnon 4256 mandibular corpus retains most of the alveoli of all sixteen
424 mandibular teeth, from the distal right M₃ alveolus to the distal portion of the left M₃ alveolus.
425 There is variable fossilization damage/abrasion, especially buccally, but most of the interdental
426 septa are intact. Thirteen of the sockets are empty without resorption indicating postmortem
427 tooth loss. The other three alveoli, those for the left I₁ and both P₃ sockets, hold broken roots in
428 situ. There is also obscuring matrix in the left I₁, I₂ and P₃ sockets.

429 The alveoli, however, present a suite of anomalies of dental orientation. The I₂s are
430 rotated mesiolabially, the P₃s are rotated mesiolingually, the M₂s slope mesially, and the right
431 M₃ exhibits an unusual root pattern (Fig. S7; Table S3).

432
433 *I₁ Right*

434 The alveolus retains a normal mesiodistally narrow socket with loss of the superior half
435 of the labial alveolar bone.

436
437 *I₁ Left*

438 The left I₁ root is still in situ, and it is a very mesiodistally thin normal root. Distal of the
439 root in the socket there is matrix, in some space between the root and the I₁/I₂ septum.

440
441 *I₂ Right*

442 The I₂ socket is normal in form with loss of the superior third of the labial bone. The
443 tooth was set largely parallel to the I₁, albeit with the labial side closer to the I₁. The tooth
444 therefore exhibits mild mesiolabial rotation, also present in the left I₂. As a result, the I₂/C₁
445 septum is triangular, with a broader labial portion, given that the labiolingual axis of the C₁ is
446 perpendicular to the curve of the dental arcade.

447

448 *I₂ Left*

449 Despite matrix and damage to the I₂/C₁ septum, the left I₂ parallels the right one, in
450 anteroposterior orientation and a resultant triangular I₂/C₁ septum that is labially thick. With the
451 I₁s, the two rotated I₂s would have provided a transverse line of labial incisors, but with labial
452 gaps I₂ to C₁.

453

454 *C₁ Right*

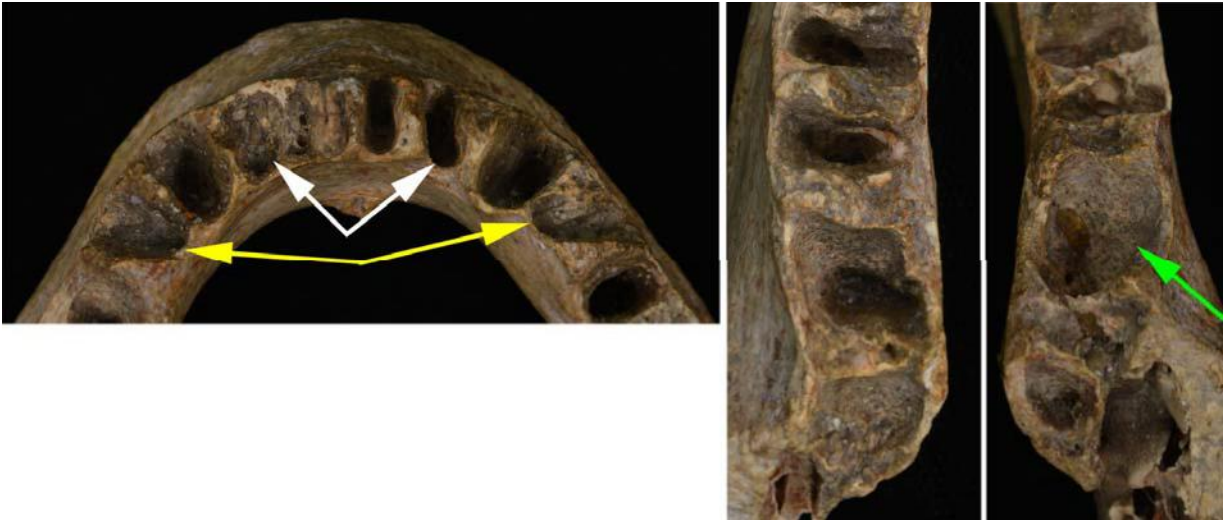
455 It exhibits a broad and straight socket, with labial bone loss on the superior half of the
456 socket, and a small lip of bone along its lingual side.

457

458 *C₁ Left*

459 The left C₁ socket is similar to the right one, although less expanded mesiodistally on its
460 labial side.

461



462

463 **Figure S7.** Details of the Cro-Magnon 4256 alveoli; from left to right: anterior alveoli, right
464 molar alveoli, left molar alveoli. White arrows: rotated I₂s. Yellow arrows: rotated P₃s.
465 Green arrow: mesially sloping M₂.

466

467 *P₃ Right*

468 The P₃ socket retains a mesiodistally thin root. There is some buccal alveolar resorption.
469 The tooth was rotated $\approx 60^\circ$, lingual to mesial/buccal to distal. The rotation produced a very thin
470 lingually but 5.0 mm thick buccally. C₁/P₃ septum. The P₃/P₄ septum is 2.7 mm buccally and 4.5
471 mm thick lingually.

472

473 *P₃ Left*

474 The left P₃ parallels the right one. The socket retains a mesiodistally thin root. There is
475 some buccal alveolar resorption. The tooth was rotated $\approx 70^\circ$ lingual to mesial, resulting in a
476 C₁/P₃ septum which is very thin lingually but 5.5 mm buccally and a P₃/P₄ septum which is 2.9
477 buccally and 4.4 lingually.

478

479

480 *P₄ Right*
 481 The alveolus exhibits a normal thicker root socket, oriented correctly. There is minor
 482 reduction of the P₄/M₁ alveolar crest.

483
 484 *P₄ Left*
 485 The socket is similar the right P₄ one, with the normal lamina dura on the mesial side and
 486 some resorption on the distal side.

487
 488
 489 **Table S3.** The distribution of rotated incisors, canines and premolars in the Cro-Magnon
 490 sample.¹

	I1	I2	C	P3	P4
CM 4253					
Maxilla right	abs	abs	abs	abs	abs
Maxilla left	abs	abs	abs	(pres)	abs
Mandible right	abs	abs	(pres)	pres	abs
Mandible left	abs	abs	abs	abs	abs
CM 4254					
Maxilla right	abs	abs	abs	abs	abs
Maxilla left	abs	abs	abs	abs	abs
CM 4256					
Mandible right	abs	pres	abs	pres	abs
Mandible left	abs	pres	abs	pres	abs
CM 4257					
Maxilla left	abs	abs	abs	pres	abs

491 ¹ (pres) for two of the CM 4253 teeth indicates possible rotation, with uncertainty given resorption and/or
 492 damage to the alveoli.

493
 494 *M₁ Right*
 495 The M₁ alveolus presents two distinctly separated sockets, with damage to the broad
 496 interradicular septum. There is some alveolar resorption along the lingual margin, but it is
 497 broken buccally.

498
 499 *M₁ Left*
 500 The alveolus has normal paired root sockets, well separated by a high (especially
 501 buccally) and thick interradicular septum. There was moderate alveolar resorption lingually, and
 502 damage to the buccal margin of the mesial root.

503
 504 *M₂ Right*
 505 The M₂ socket presents a single “conical” socket for fused roots, with thin and small
 506 crests lingually and buccally for the sulci between the fused roots. However, the hole slopes
 507 mesially, such that the distal lamina dura is vertical to the alveolar plane and the mesial one is at
 508 a distinct angle to the alveolar plane. There is also a pronounced thickness (4.8 mm) of the

509 M₁/M₂ septum. This combination of features suggests that the M₂ was erupted to the occlusal
510 plane, but that its crown was angled up against the M₁. It therefore had the root angled distally,
511 resulting in the thick septum between the M₁ and M₂ roots.

512

513 *M₂ Left*

514 The M₂ socket is partly obscured by thin matrix, but it is similar to the right one; a
515 conical socket for fused roots, a vertical distal septum, an angled mesial septum, and a thickened
516 M₁/M₂ septum. However, the mesial angle is less pronounced, and the thickness of the septum
517 (3.4 mm) is less.

518

519 *M₃ Right*

520 The root socket pattern for the right M₃ is unusual, although the breakage of the
521 distobuccal alveolus makes its full aspect unclear. There is a mesial midline narrow root (6.5
522 mm wide versus 8.4 mm for the M₂ socket) socket which then tapers to a narrowing 5.4 mm
523 from the alveolar plane. To the distal on the lingual side, there is an oval socket 4.5 by 3.5 mm,
524 largely vertically oriented, and ≈4 mm deep. The mesial socket should be for a reduced mesial
525 M₃ root, but it is unclear whether the distolingual socket is for a reduced and rotated distal root.

526

527 *M₃ Left*

528 Only the mesial lamina dura is preserved. It is flat and a normal M₃ mesial root surface,
529 but it slopes slightly mesially, similar to the M₂ mesial root surface.

530

531

532 **S5: Cro-Magnon 4257 Maxillary Dentoalveolar Remains**

533

534 CM 4257 is a complete alveolar and palatal portion of a left maxilla, with the alveoli
535 from the intermaxillary suture mesial of I¹ to the alveolar bone around the missing M³ (Fig. S8).
536 The maxillary portion of the palate is complete, but the labial/buccal portions of the alveoli from
537 I¹ to P⁴ are largely or entirely absent.

538 The maxilla currently retains the M¹, M² and a P⁴. The conditions of the preserved
539 sockets all indicate portmortem loss of the absent teeth.

540 In addition, the largely complete P⁴, which has been in the maxilla since the initial
541 description of Broca (1868), does not belong in the maxilla (see below). It is not clear whether it
542 derives from the same individual but is a right P⁴ or it comes from another individual. Its
543 buccolingual crown diameter is unexceptional relative to those of the M¹ or especially of the M²,
544 and its degree of occlusal wear matches that of the M², both of which should have the same
545 functional occlusal age. It is therefore conservatively considered to be the right P⁴ of Cro-
546 Magnon 4257.

547

548 *I¹ Left*

549 Present is the complete lingual third to half of the socket with the intact lamina dura.
550 There is matrix in its apical portion.

551

552 *I² Left*

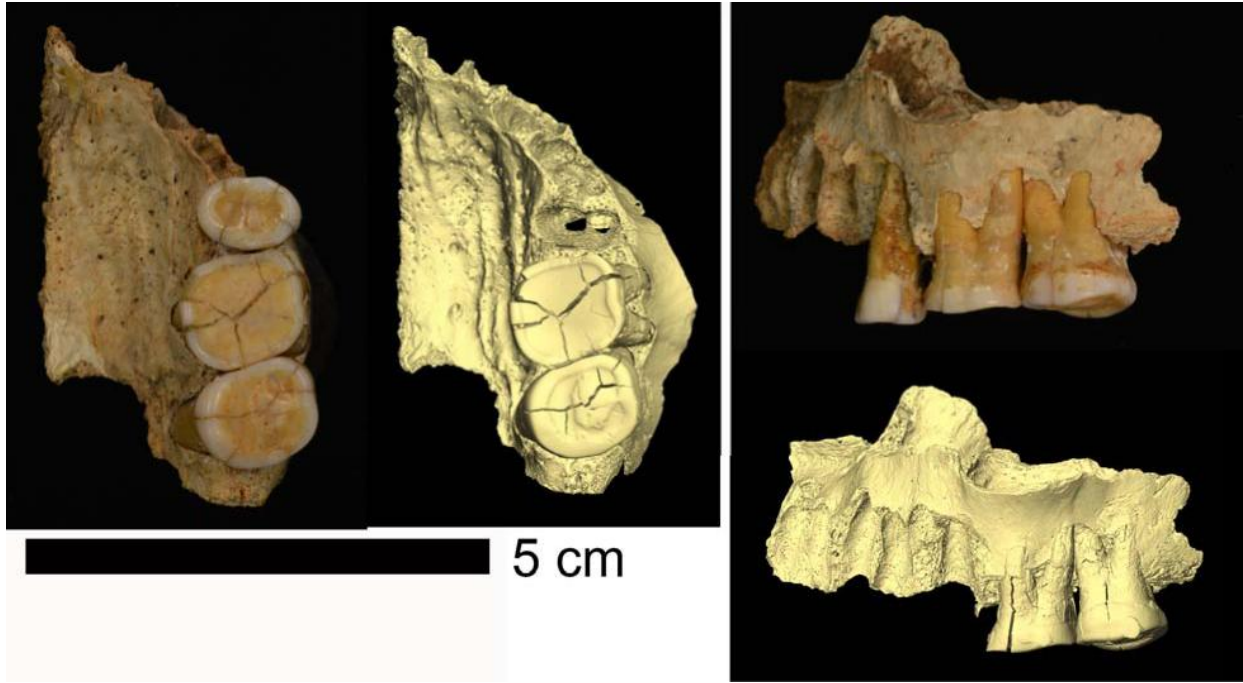
553 Present is the complete lingual third of the socket with the intact lamina dura.

554

555 *C¹ Left*

556 Preserved is the complete lingual half of the socket with the apical portion partly covered
557 labially. There is minor porosity of the lamina dura along the I²/C¹ septum.

558
559



560
561 **Figure S8.** Occlusal (left) and buccal (right) views of the Cro-Magnon 4257 left maxilla. Shown
562 are photographs of the maxilla with the P⁴ in its current position and virtual images of the
563 maxilla with the P⁴ removed. Note the slightly more anterolateral than lateral view of the
564 virtual image.

565
566 *P³ Left*

567 The left P³ alveolus retains its mesial, lingual and distal portions, and presents two
568 sockets with a septum that extends almost to the alveolar margin. As noted by Vallois and Billy
569 (1965), it is best interpreted as a two-rooted P³. It is also rotated almost 90° in the alveolus.

570
571 *P⁴ Right*

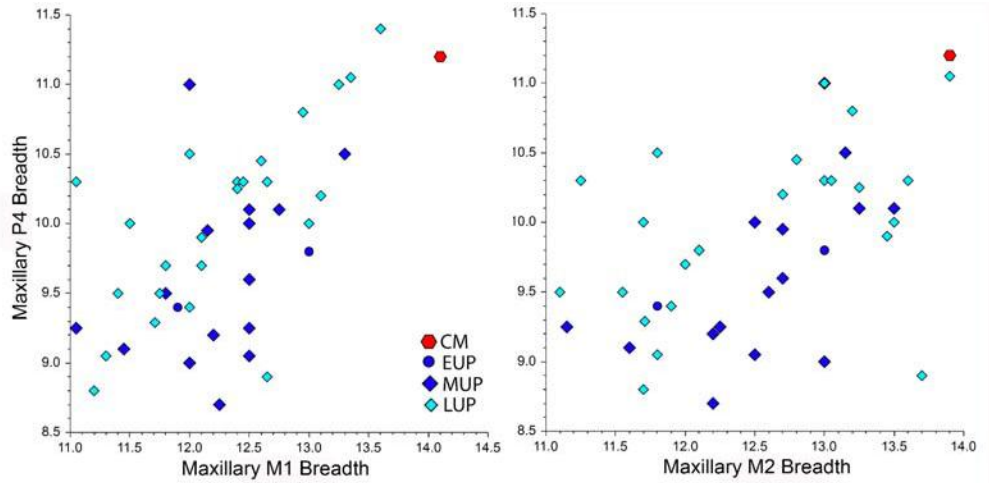
572 As noted above, the complete P⁴ currently in the left P⁴ alveolus was inappropriately
573 placed in that socket, apparently shortly after its discovery. Although the tooth is
574 morphologically a P⁴, with a single root and with buccal and lingual cusps of similar size (the
575 buccal one is slightly larger), it does not fit the CM 4257 left maxilla. Its root is completely
576 pressed into the left P⁴ alveolus, but its occlusal surface projects 2.2 mm above that of the M¹.
577 The very small interproximal facet of the P⁴ does not match the large one on the mesial M¹, and
578 the P⁴ one is above that of M¹. The contour of the distal P⁴ crown does not match that of the M¹,
579 unlike the close fitting of the interproximal facets between the M¹ and the M².

580 Yet, as noted above, the degree of wear of the P⁴ (Smith stage 5b) is similar to that of the
581 M² (Smith stage 5c). Also, comparisons of the P⁴ versus M¹ and M² buccal crown diameters are
582 unexceptional for Late Pleistocene human (Fig. S9). The tooth cannot be easily sided, given the

583 symmetry of the crown and its straight root, but it would make an appropriate right P⁴ of the
584 same individual. It is so considered.

585 The right P⁴ tooth therefore present an ovoid crown with the remains (after wear) of the
586 mesial and distal marginal ridges and an absence of a developmental groove. It has a single
587 straight root.

588
589



590
591 **Figure S9.** The buccolingual diameter of the Cro-Magnon 4257 P⁴ (in mm) compared to the
592 same diameter for its M¹ (left) and M² (right) (Table S2), versus the same comparisons
593 for Early (EUP), Mid (MUP) and Late (LUP) Upper Paleolithic humans.

594

595 *P⁴ Left*

596 The left P⁴ alveolus, with the right one removed virtually (Fig. S8), presents a normal
597 socket for a single rooted premolar, with small ridges (especially mesially) for the sulci running
598 along the root.

599

600 *M¹ Left*

601 The in situ M¹ is a complete tooth and alveolus with the loss of thin alveolar bone on the
602 buccal and lingual sides, exposing much of the roots. The occlusal surface is a dentin basin with
603 a continuous ring of enamel around it (Smith stage 7b); the loss on the mesiolingual corner is
604 postmortem breakage. There are postmortem fissures through the crown, with little of the crown
605 dimensions; any expansion of the mesiodistal diameter (the only one likely to be affected) is
606 more than compensated by the interproximal wear (it measures 12.8 mm, rounded off to ≈13.0
607 mm).

608

609 *M² Left*

610 The M² is a complete tooth in situ with lingual and especially buccal exposures of most
611 of the roots. It has a tight and congruent mesial interproximal flat contact facet with the M¹, but
612 there is no distal interproximal facet. The occlusal surface exhibits a rounded enamel ring, a
613 dentin basin with a center enamel island connected to the enamel ring only on the mid-buccal
614 side (Smith stage 5c). The tip of the mesiolingual root is exposed through breakage alongside of
615 the M³ crypt (see below); although slightly damaged, the apex of the root was fully closed.

616



617
 618 **Figure S10.** The Cro-Magnon 4257 maxilla in superior view. Note the crypt for the impacted
 619 M^3 (red arrow) above the erupted and worn M^2 .
 620

621 *M³ Left*

622 The M^3 is absent and the retromolar bone extends for only 6.9 mm distal of the M^2
 623 cervix. Superior of the retromolar bone is a crypt 12.2 mm mesiodistal and 8.9 mm buccolingual
 624 for the crown of the M^3 (Fig. S10). Because the M^2 and especially the M^1 are heavily worn and
 625 the M^2 roots are closed, this space does not represent a crypt for a developing M^3 . It reflects an
 626 impacted M^3 crown up against the distal M^2 root, as noted by Vallois and Billy (1965).
 627

628
 629 **S6: Cro-Magnon 4258 Mandibular Dentoalveolar Remains**
 630

631 The Cro-Magnon 4258 mandibular piece consists of the alveolar region from the middle
 632 of the M_1 to the ramus (Fig. S11). The alveolar bone is well preserved buccally, especially by
 633 the M_2 and M_3 , but it is partially present by the M_1 and absent from the M_2 and the mesial M_3 .
 634 All three of the teeth, the M_1 to M_3 , are present. However, the M_1 lost most of its mesial and
 635 buccal enamel and the M_2 lost most of its lingual and buccal enamel. The intact M_3 is impacted
 636 with its mesial crown against the distal M_2 root and the distal crown not quite at the alveolar
 637 plane.

638 The mandible is labeled “Cro-Magnon n° 4”, possibly based on Pruner-Bey (1865-75),
 639 but it remains unclear to which of the crania it might have belonged.

640 Vallois and Billy (1965) mentioned four teeth associated with the CM 4258 mandible, P_4
 641 to M_3 . There is no current evidence of a premolar with CM 4258, and Pruner-Bey (1865-75)
 642 mentioned only the three currently present molars. It is not clear to what premolar Vallois and
 643 Billy were referring.
 644

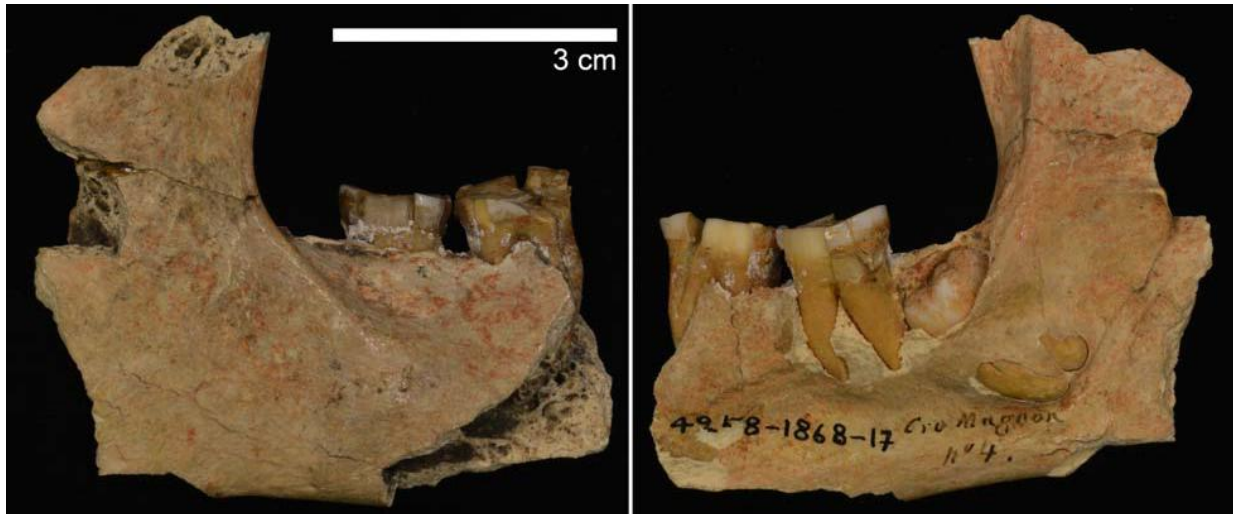645 *M₁ Right*

646 The M_1 is a heavily worn tooth in situ, with a thin enamel around a dentin surface
 647 lingually, distally and on the distal half of the buccal side. The mesial half of the buccal crown
 648 and the buccal side of the mesial crown had the enamel worn away antemortem and the dentin
 649 rounding down below the cervix. As such it exhibits Smith wear stage 7c. Given damage to the
 650 alveolar bone, especially lingually, it is unclear to what extent it may have been resorbed (or the

651 tooth supererupted), but the M₁/M₂ septum appears largely normal and the alveolar-cervix height
652 (≈ 2.5 mm) is unexceptional for the degree of occlusal wear.

653 The mesiodistal diameter of the crown is too damaged and worn to measure. The
654 buccolingual diameter as preserved is 12.5 mm; full crown buccolingual diameter prior to wear
655 should have been ≥ 13 mm.

656
657



658
659 **Figure S11.** Lateral (left) and medial (right) views of the Cro-Magnon 4258 right mandibular
660 corpus and ramus. See also text Fig. 4 and Fig. S12.

661
662

663 *M₂ Right*

664 The M₂ exhibits a dentin occlusal surface with enamel margins preserved mesially and
665 distally; it appears that the enamel ring was complete at death and the missing portions lost
666 subsequently (Smith wear stage 7b). The lingual alveolar bone is absent, but the intact buccal
667 alveolar bone exhibits no resorption. There is a small carious lesion occlusally, slightly lingually
668 of the crown middle, noted by Brennan (1991) and Lacy (2014) (Fig. S12).

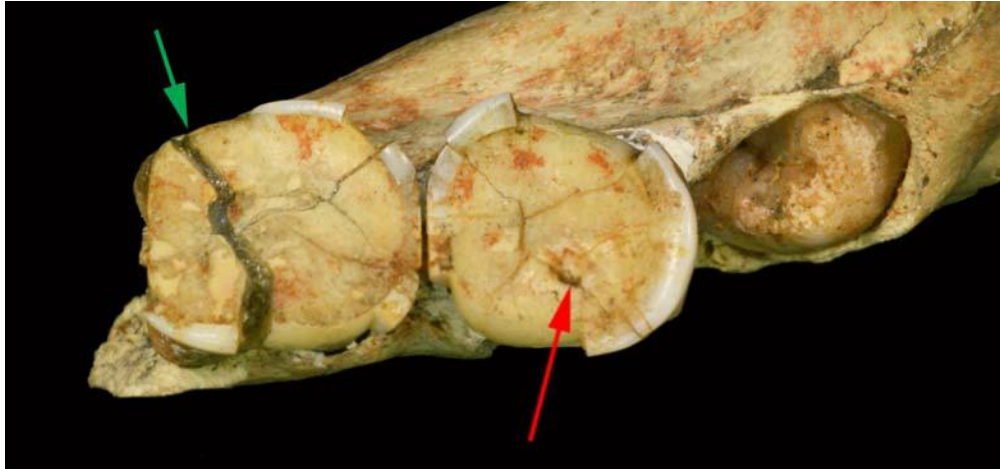
669 The mesiodistal diameter of the crown, as retained with occlusal and interproximal wear,
670 is 12.5 mm. The buccolingual diameter of the crown as worn, estimated continuing the contours
671 of the broken enamel, is ≈ 12.0 mm. Prior to the occlusal and interproximal wear, the two
672 diameters were probably ≈ 13.0 and ≈ 12.5 mm. These values are approximate, but they provide a
673 general assessment of the dimensions of these molar crowns.

674

675 *M₃ Right*

676 As noted above, the completely formed M₃ is fully present and fully impacted in the
677 mandible. The mesial occlusal crown edge is against the M₂ distal root slightly below the middle
678 of the root. The long (vertical) axis of the tooth is $\approx 35^\circ$ from the alveolar plane. The buccal,
679 distal and distolingual margins of the crypt opening through the alveolus are preserved, but little
680 of the calculus on the distal M₂ appears to have penetrated onto the M₃ crown.

681
682



683
684
685
686
687
688
689
690
691
692

Figure S12. Occlusal views of the Cro-Magnon 4258 right mandibular molars, with the impacted M₃ in its crypt. Green arrow: the rounded mesiobuccal edge of the M₁. Red arrow: the small occlusal carious lesion in the M₂.

693 **S7: Micro-CT Resolution Data**

694
695
696
697

Table S4. Resolutions of the microtomodensitometric (μ CT) data for the Cro-Magnon crania and mandibles.

CM 4253 Cranium	Cro-Magnon 1	115.0 μ m
CM 4253 Mandible	Cro-Magnon 1	76.6 μ m
CM 4254 Cranium	Cro-Magnon 2	110.0 μ m
CM 4256 Mandible	--	60.6 μ m
CM 4257 Maxilla	--	30.0 μ m
CM 4258 Mandible	--	38.2 μ m

698
699
700

701 **S8: Proposed Cro-Magnon Associations**

702

703 **Table S5.** Proposed associations of the Cro-Magnon adult remains, based on those proposed for
 704 the lower limbs by Thibeault and Villotte (2018), for the upper limbs by Villotte et al.
 705 (2020), and for the cranial and mandibular remains here. The individuals (Alpha to Delta)
 706 are those based on the appendicular remains, restricting the traditional Cro-Magnon 1 to 4
 707 designations to the crania and the one directly associated mandible.
 708

	Alpha	Beta	Gamma	Delta ²
Neurocranium	4253 (#1)	4255 (#3) or 4259 (#4) ¹		4254 (#2)
Maxilla/Mandible	4253 (#1)	4256 or 4257/4258 ¹		4254 (#2)
Clavicle	4290			
Scapula	4292			
Humerus		4294,4295	4293	
Ulna	4299	4301	4300,4302	4297,4298
Radius	4304	4305	4303	
Hip bone	4314a,4314b	4316a,4317,4316b?	4315,4318	
Sacrum		4314c	4319?	
Femur	4323,4327,4325	4321,4324,4329	4322,4323,4328	
Tibia	4331,4332		4330,4333	
Fibula	4335		4334	
Talus			4337	
Calcaneus			4336	

709

710 ¹ As discussed in the text, the CM 4256 mandible and the CM 4257/4258 maxilla/mandible likely derive
 711 from the Beta and Gamma postcranial pair as well as from the CM 4255 and CM 4259 cranial
 712 pair. It is not currently possible to determine which way these three pairs might be associated.

713 ² As discussed in the text, the association of CM 4254 cranium with Delta is largely based on its unlikely
 714 association with Beta or Gamma, and the assumption of only four adults in the Cro-Magnon
 715 sample.
 716

717

718

719

719 **S9: Supporting Information References**

720

721 Brennan, M.U., 1991. Health and disease in the Middle and Upper Paleolithic of southwestern
 722 France: a bioarcheological study. Ph.D. Thesis. New York University.

723 Broca, P., 1868. Sur les crânes et ossements des Eyzies. Bull. Soc. Anthropol. Paris 3, 350–392.
 724 <https://doi.org/10.3406/bmsap.1868.9548>

725 Lacy, S.A., 2014. Oral Health and its Implications in Late Pleistocene Western Eurasian
 726 Humans. Ph.D.Thesis, Washington University in Saint Louis.

727 Leonard, A., Bayle, P., Murail, P., Brůžek, J., 2014. Oral exostoses: An assessment of two
 728 hundred years of research. Bull. Mém. Soc. Anthropol. Paris 26, 1-22.
 729 [doi.10.1007/s13219-013-0089-3](https://doi.org/10.1007/s13219-013-0089-3).

730 Pruner-Bey, F., 1865-75. An account of the human bones found in the cave of Cro-Magnon, in
 731 Dordogne, in: Lartet, E., Christy, H. (Eds.), Reliquiae Aquitanicae: Being Contributions

- 732 to Archaeology and Palaeontology of Périgord and the Adjoining Provinces of Southern
733 France. Williams and Norgate, London, pp. 73–92.
- 734 Smith, B.H., 1984. Patterns of molar wear in hunter-gatherers and agriculturalists. *Am. J. Phys.*
735 *Anthropol.* 63, 39-56.
- 736 Vallois, H.V., Billy, G., 1965. Nouvelles recherches sur les hommes fossiles de l’abri de Cro-
737 Magnon. *L’Anthropol.* 69, 47–74.