

Cellular therapy treatment of chronic radiation cystitis in rats

IRSN

INSTITUT
DE RADIOPROTECTION
ET DE SÛRETÉ NUCLÉAIRE

Brossard C.¹,

Dos Santos M.², Demarquay C.¹, Buard V.¹, Tarlet G.¹, Squiban C.¹, Linard C.¹, Mathieu N.¹, Granger R.³, Sache A.³, Denais Lalieue D.³, Milliat F.¹, Chapel A.¹

¹Radiobiology of Medical Exposure Laboratory (LRMed), ²Radiobiology of Accidental Exposure Laboratory (LRAcc), ³Support Group for Research and Animal Ethics (GSEA)

MEMBRE DE

ETSON


EUROPEAN
TECHNICAL SAFETY
ORGANISATIONS
NETWORK

08 -10
JUL 2019

Paris, France

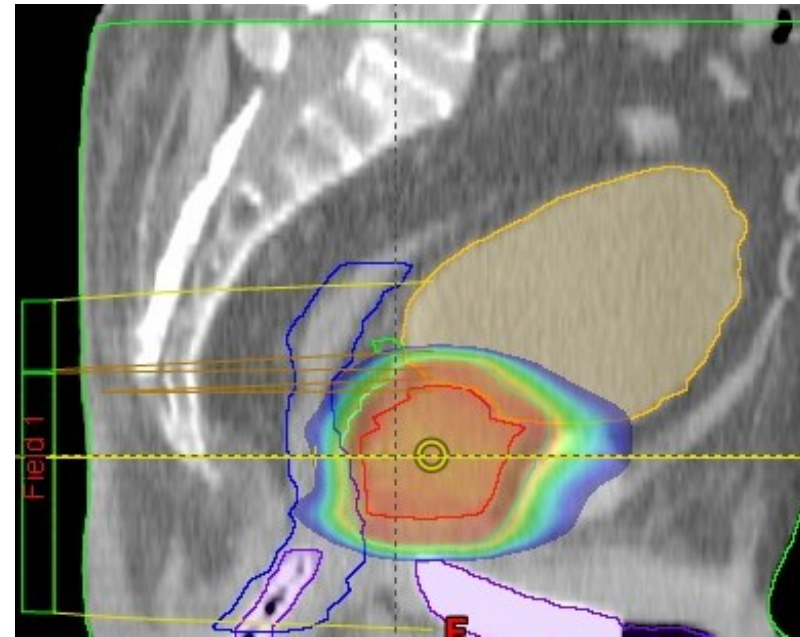
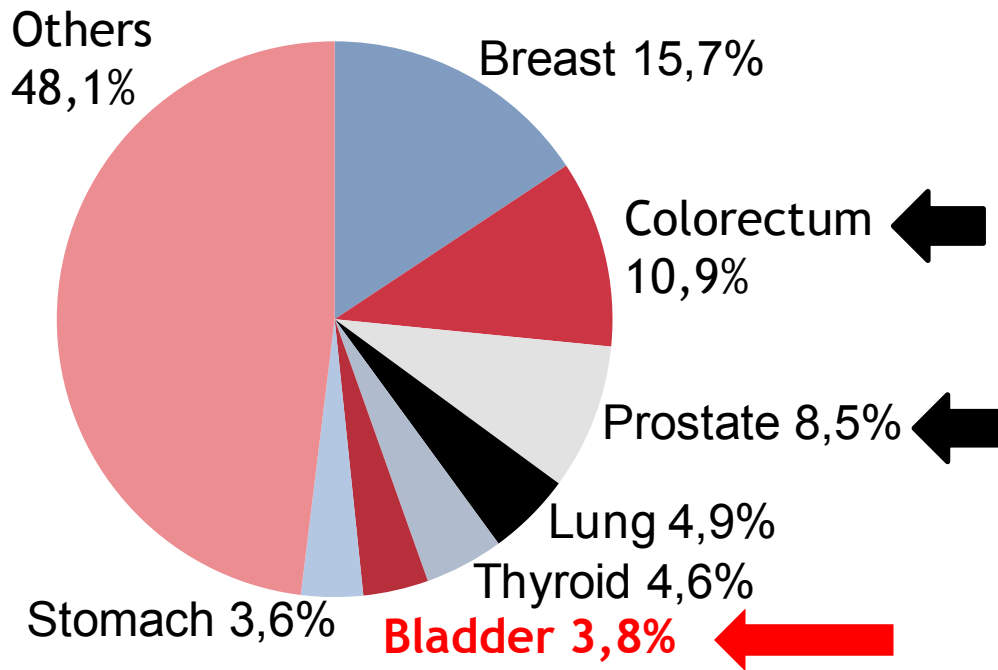
International Conference on
Cell Science & Molecular Biology

Theme: Exploring Last Frontiers in Molecular Biology & Cell Science



Introduction: Pelvic cancers

Global estimation of the number of prevalent cases of cancer, 2018

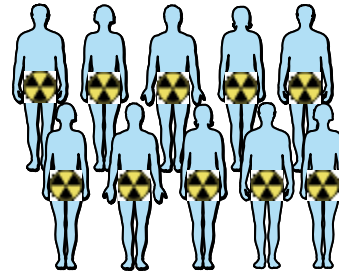
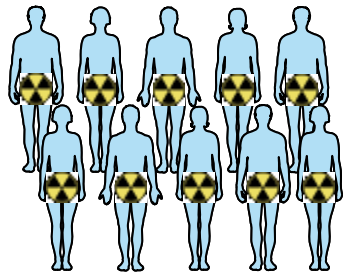


Varian.com

Abdominal-pelvic sphere = 25% of cancers (←)
The bladder is an organ at risk of scratching

Introduction: Complication radiotherapy

Population concerned



Radiotherapy



Days - weeks



Acute effects
40% of
patients

Month - years

Late effects (Chronic Radiation Cystitis or CRC)
5 to 10% of patients (6 month at 20 years)
9000 to 18 000 patients per years in France

Levenback et al., 1994; Manikandan et al., 2006

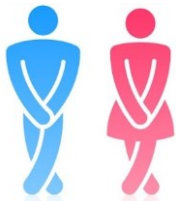Chronic effects :



Pain

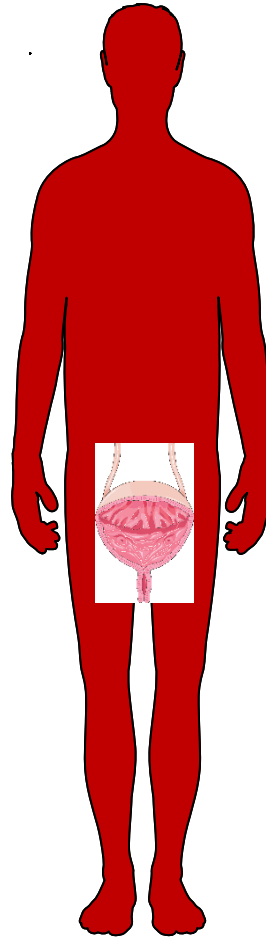


Hematuria

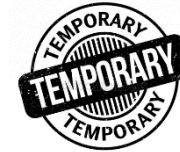

Incontinence

Significant decrease
in quality of life



Treatments :



Palliative
treatments



Intravesical
instillations



Hematuria



Pain



Regeneration



Hyper bar
treatment



Tumorigenicity

Need for a relevant model and curative treatments

Introduction: Bladder structure

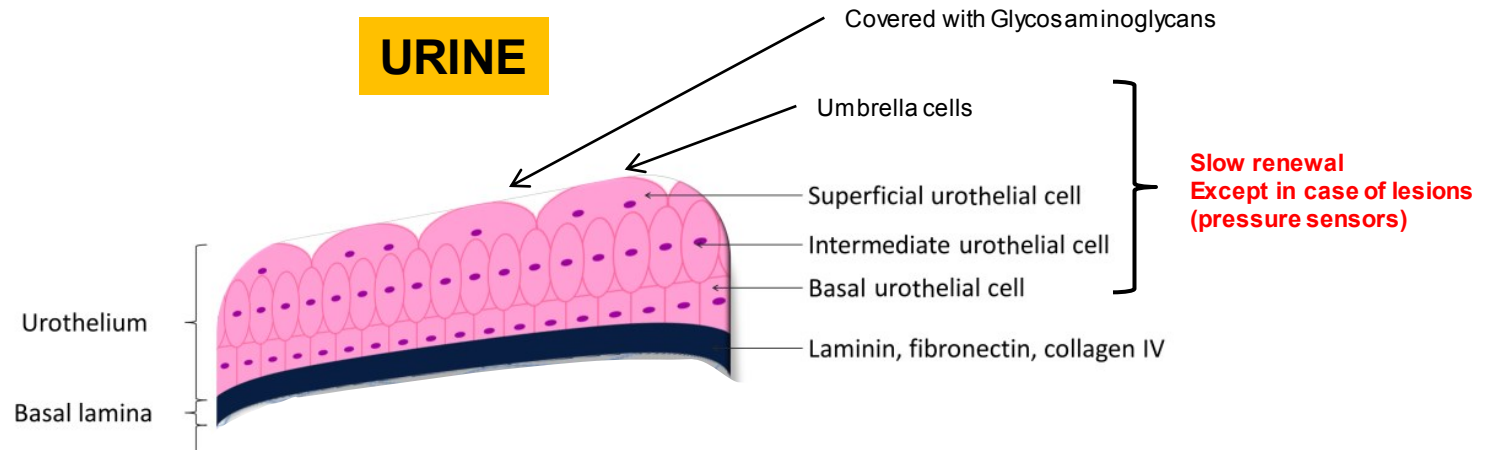
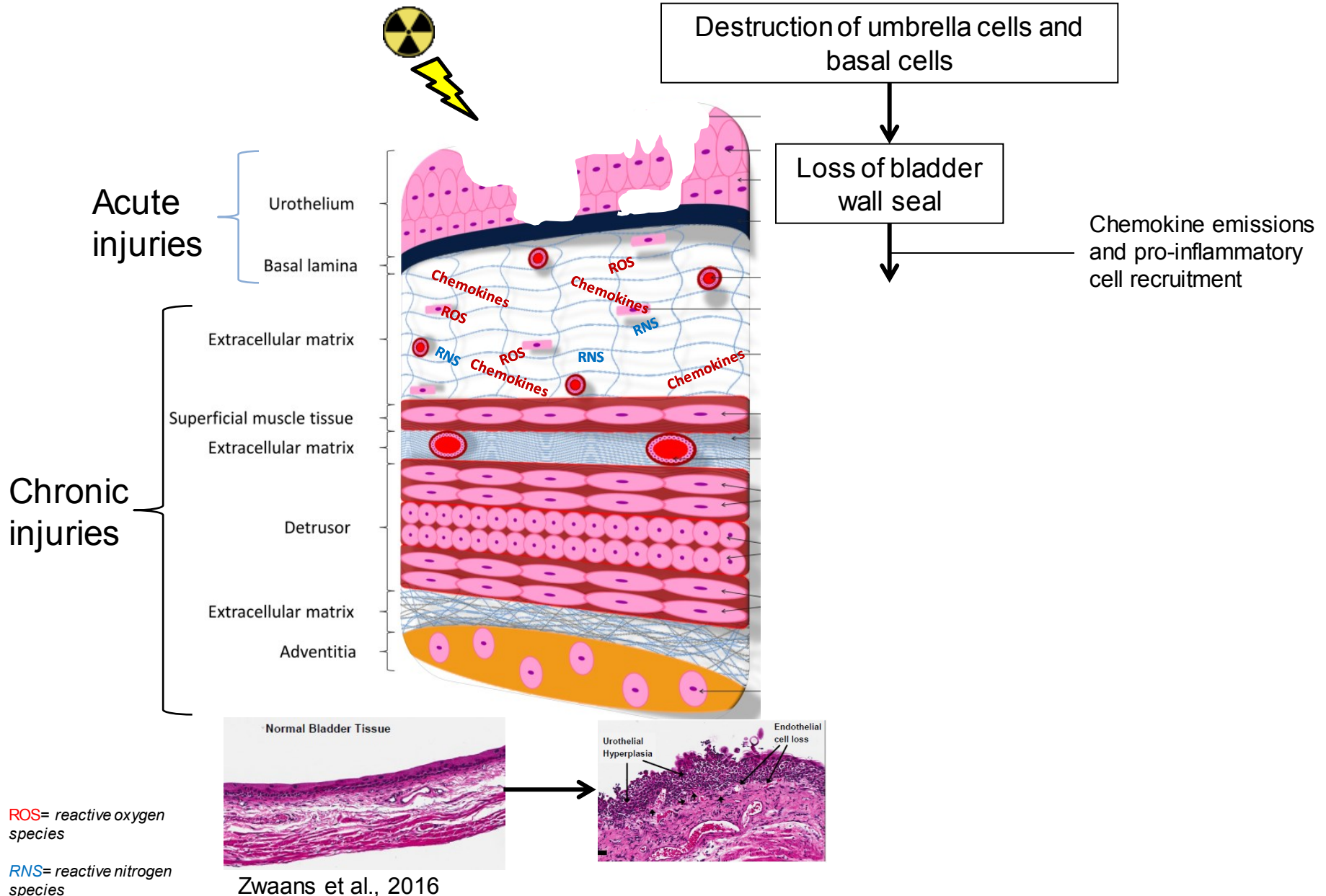
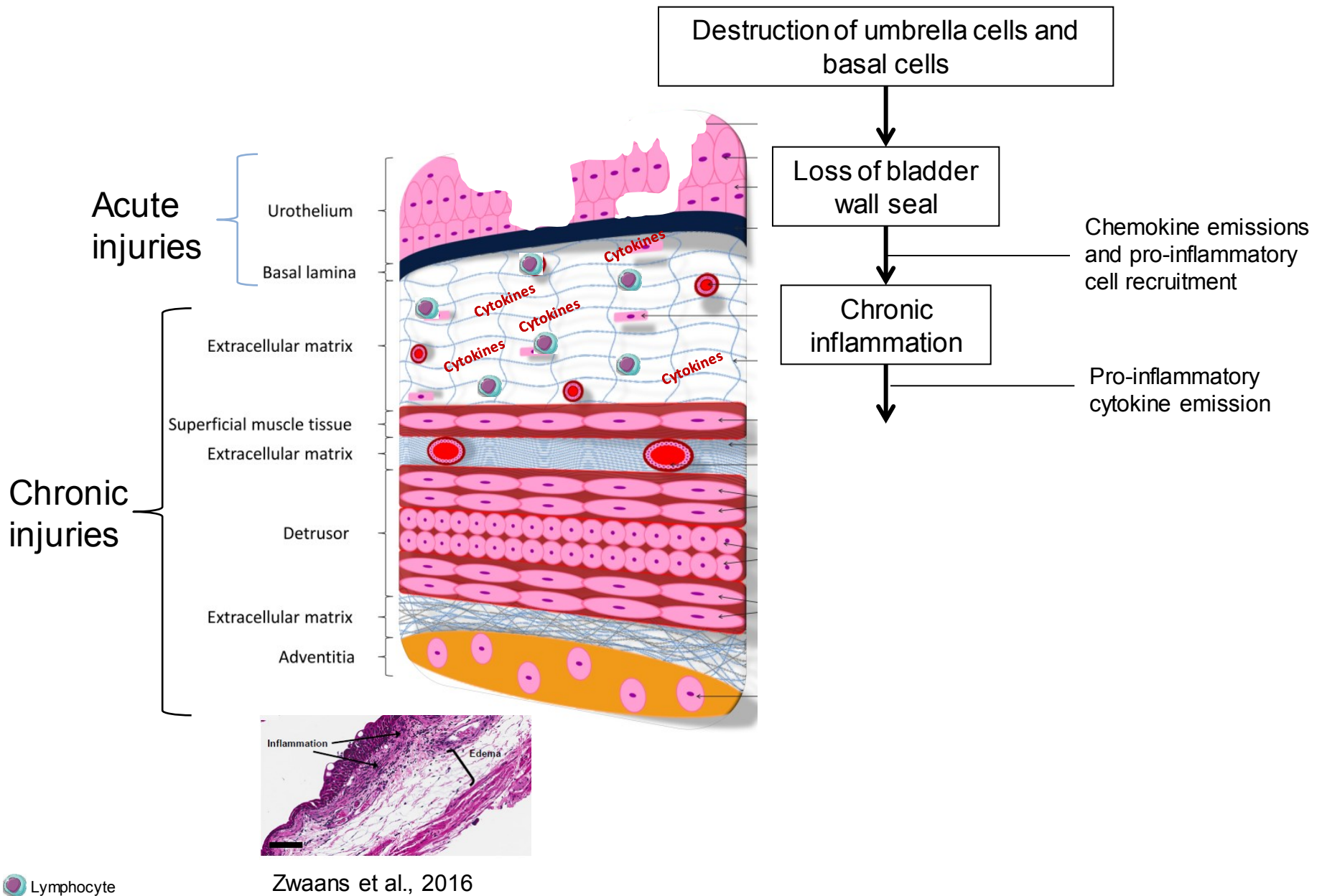


Image from :embryology.med.unsw.edu.au

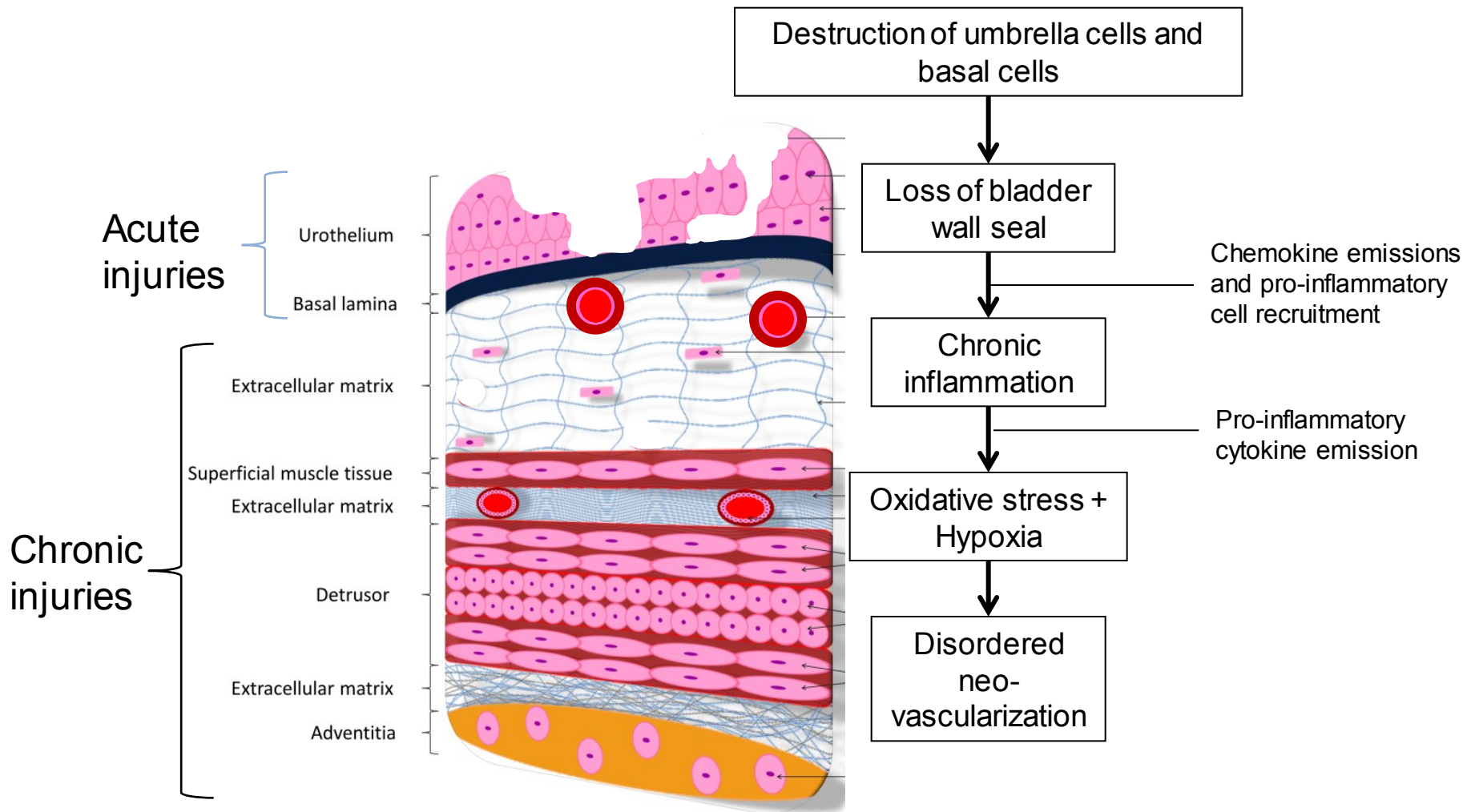
Introduction: Mechanism of CRC



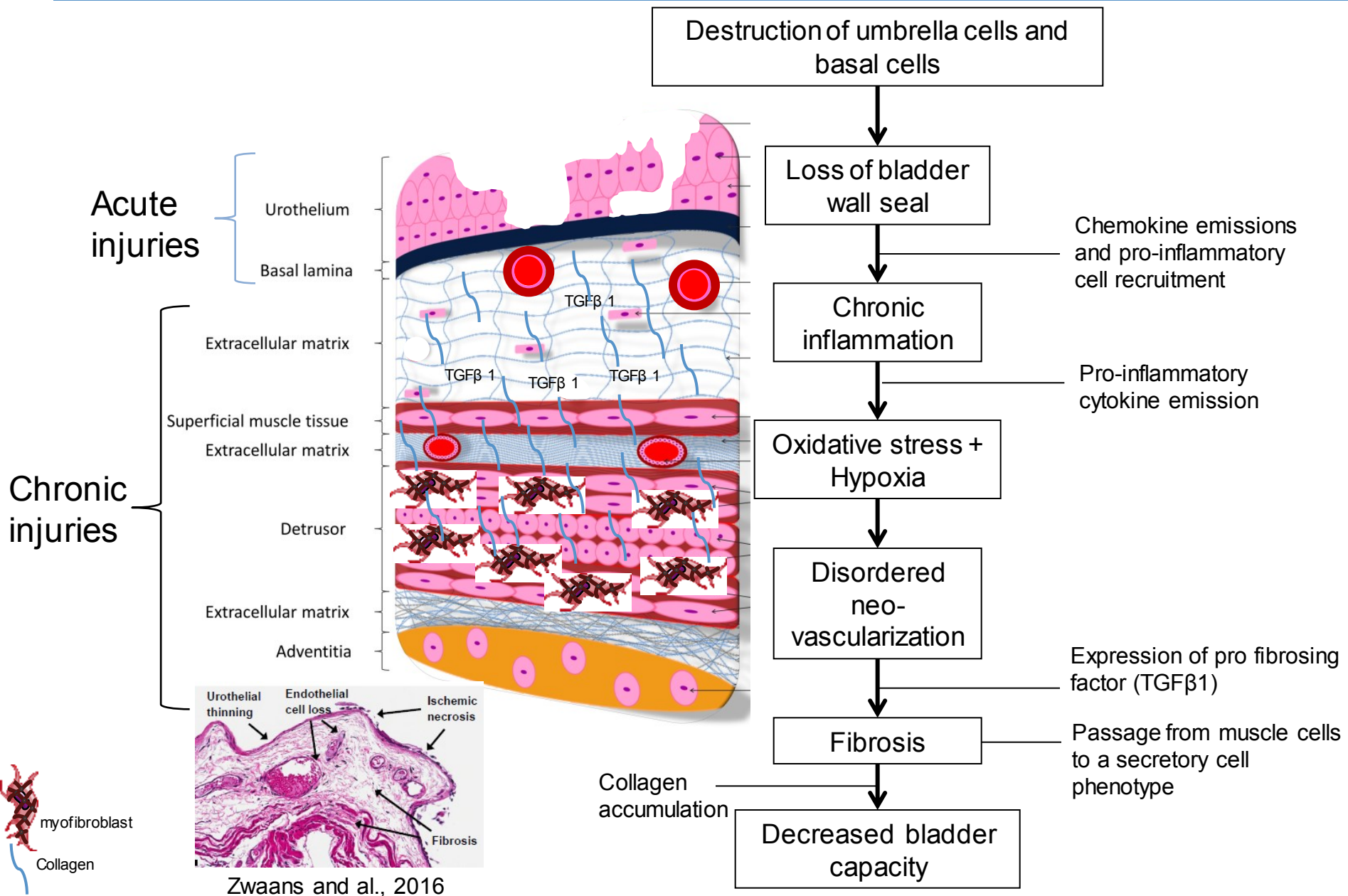
Introduction: Mechanism of CRC



Introduction: Mechanism of CRC



Introduction: Mechanism of CRC



Mesenchymal Stem Cells (MSC) Effects

Other pelvic radio-induced diseases

Usunier et al., 2014
Linard et al., 2013

↓ Inflammation
↓ Fibrosis
↑ Tissue regeneration

Interstitial cystitis

Kim et al., 2016
Song et al., 2015

↓ Inflammation
↓ Fibrosis
↑ Tissue regeneration

Hemorrhagic cystitis

Lee et al., 2003
Song et al., 2015

↑ Tissue regeneration
↓ Hemorrhage

MSCs have a significant effect on diseases similar to CRC. However, this one has not been tested on CRC.

Hypothesis: MSCs can reduce inflammation and fibrosis and increases tissue regeneration in CRC.

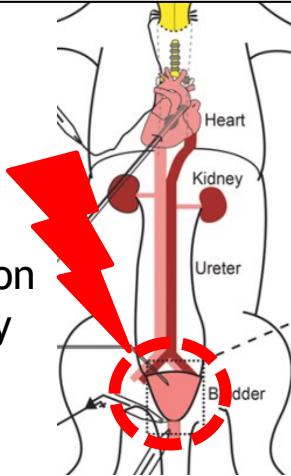
Study design

Local bladder irradiation

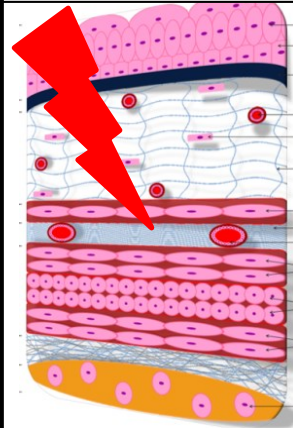


Irradiation
20-40Gy

Bladder



CRC



Urothelium

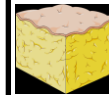
Under
Mucosa

Detrusor


Adventice

1. Inflammation
2. Vascular damage
3. Fibrosis
4. Ulcer

Treatment

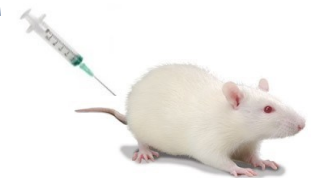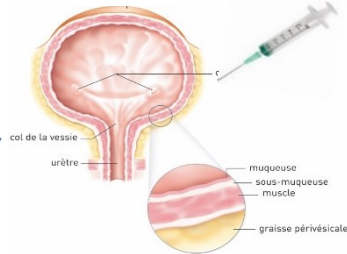


Adipose
tissue

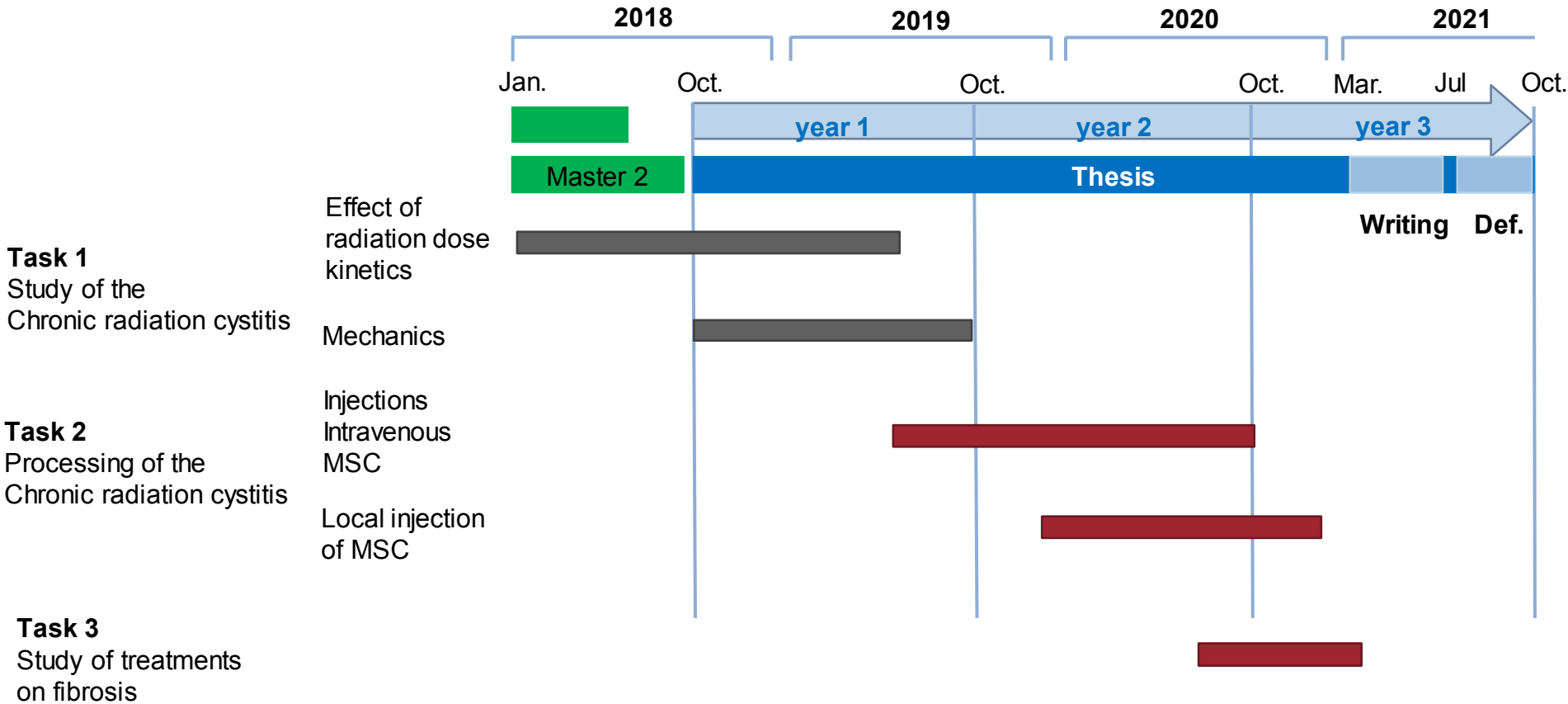


Local
injection

Intravenous
injection



Gantt diagram: Provisional planning of the thesis



Objective:

- Creation of a model of chronic radiation cystitis in rats
 - New method of irradiation using SARRP
- ➔ Irradiator for small animals (similar characteristic to clinical models)

SARRP

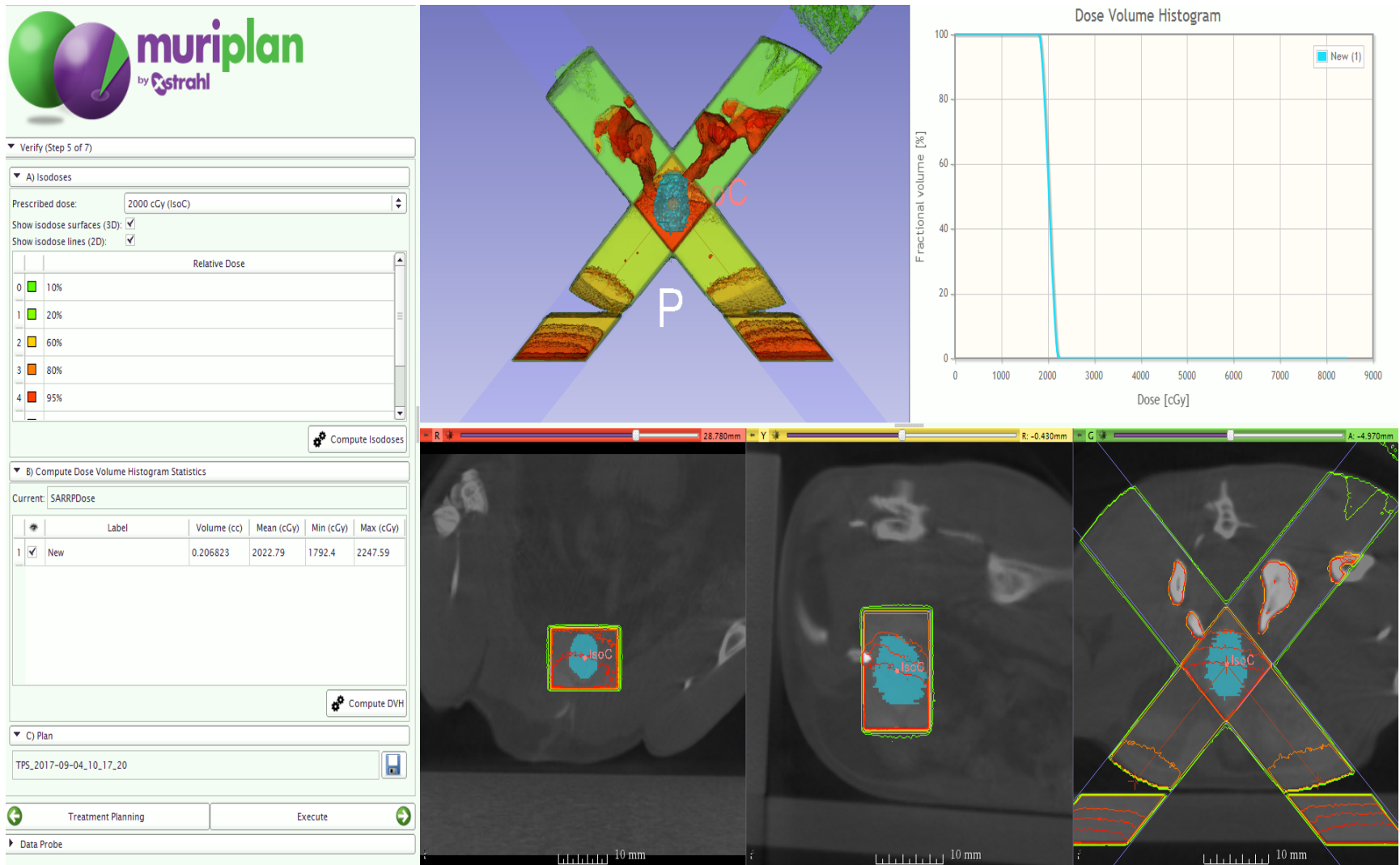
- Small Animal Radiation Research Platform (SARRP, Xstrahl)
- Single or multi beam(s)
- Combined with scanner imaging and treatment plan software (MuriPlan) => stereotaxy
- 4 available field sizes: **10x10 mm²**, 7x7 mm², 3x3 mm² and Ø 1 mm



Picture of SARRP
Dr M. Dos Santos, LRAcc

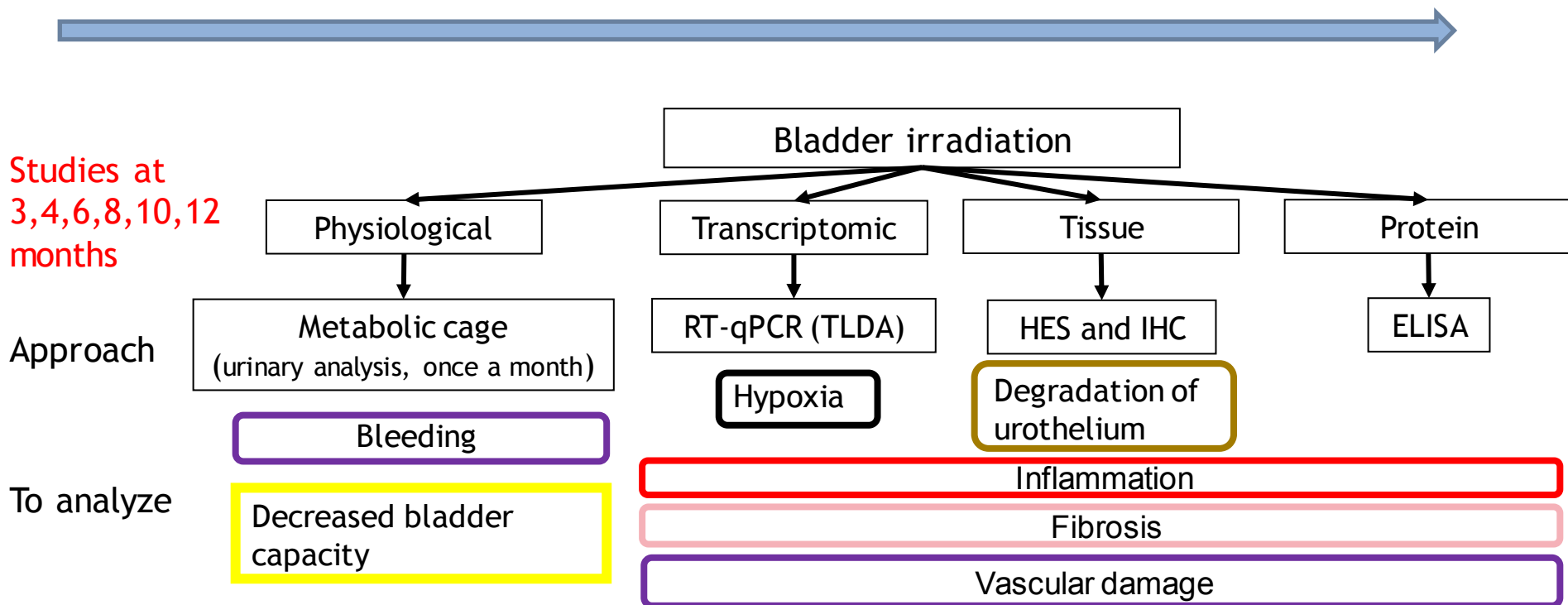
Method of irradiation: Local bladder irradiation

Method of irradiation: Local bladder irradiation



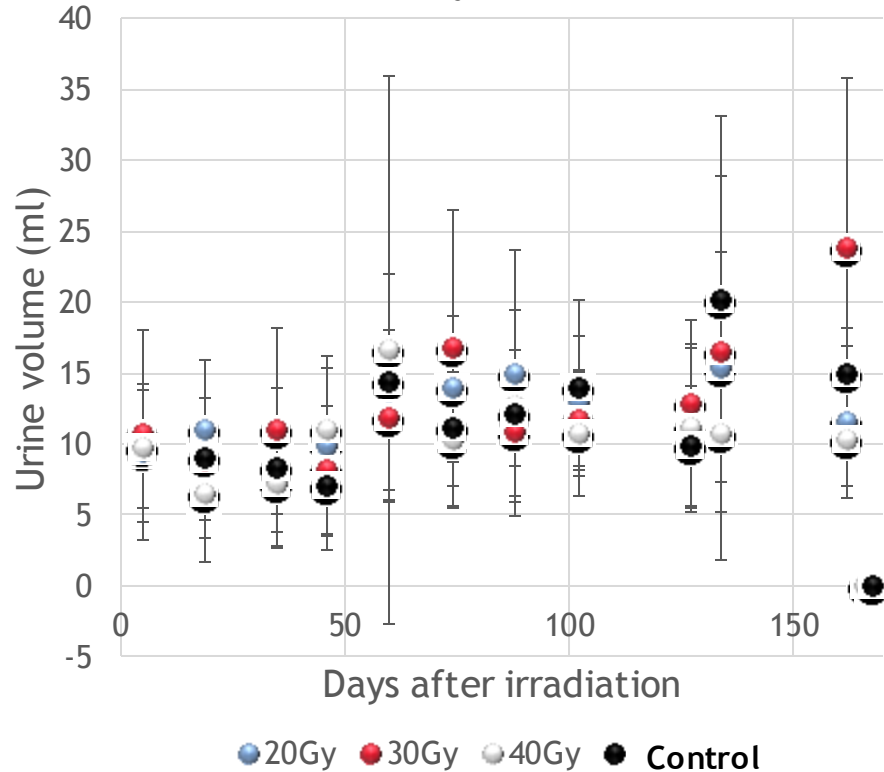
- 2 irradiation beams
- Maximizes the dose on the bladder and minimizes the dose on surrounding tissues

Protocole opératoire physiopathologie

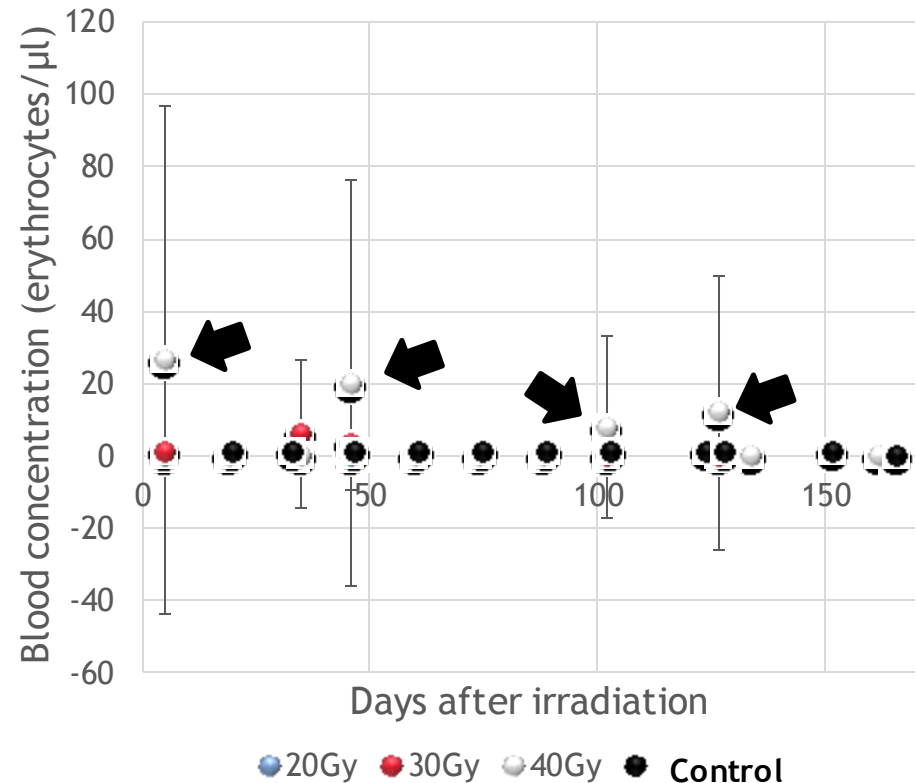


Urinary analysis over time post irradiation

Variation in urinary volume (on 24h)



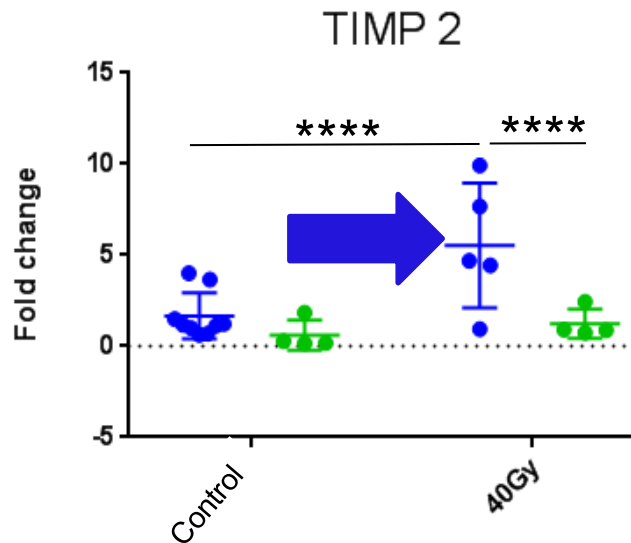
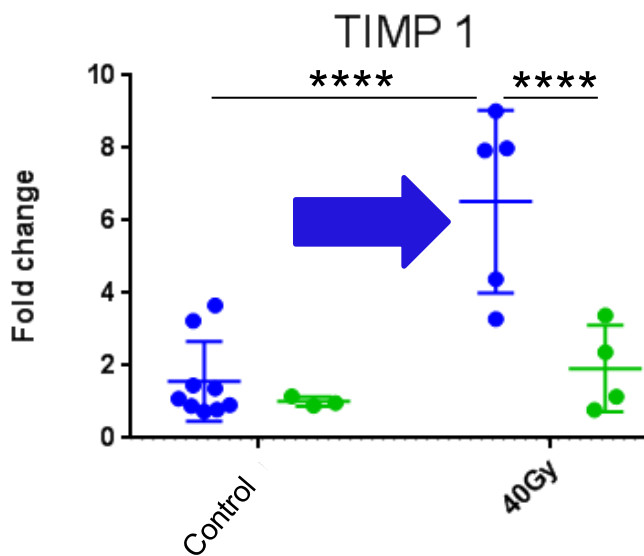
Hematuria (on 24h)



No decrease in urine volume during the six months

Transient hematuria (←) were observed in rats irradiated at 40 Gy

Transcriptomics studies: fibrosis



● 3months

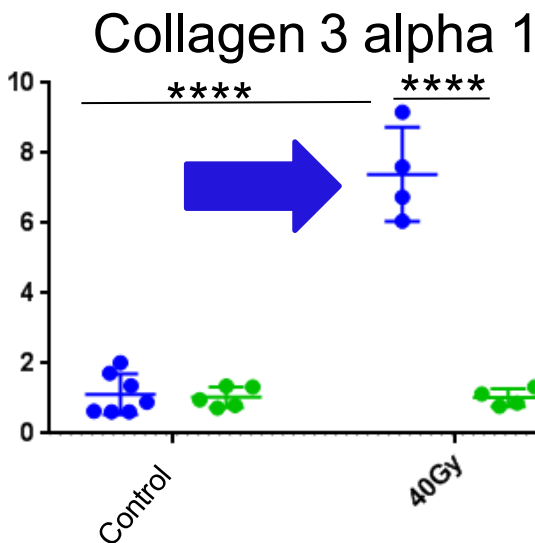
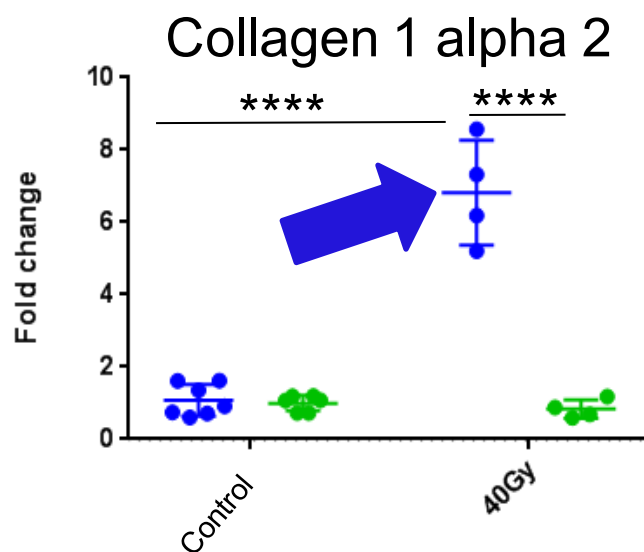
● 6months

*: p-value<0,05

** : p-value<0,01

***: p-value<0,001

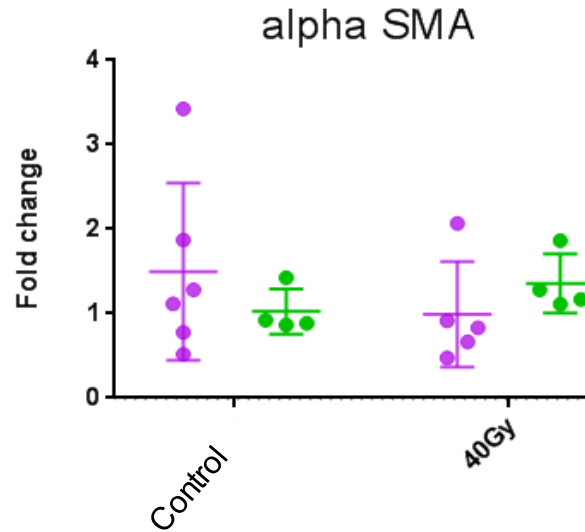
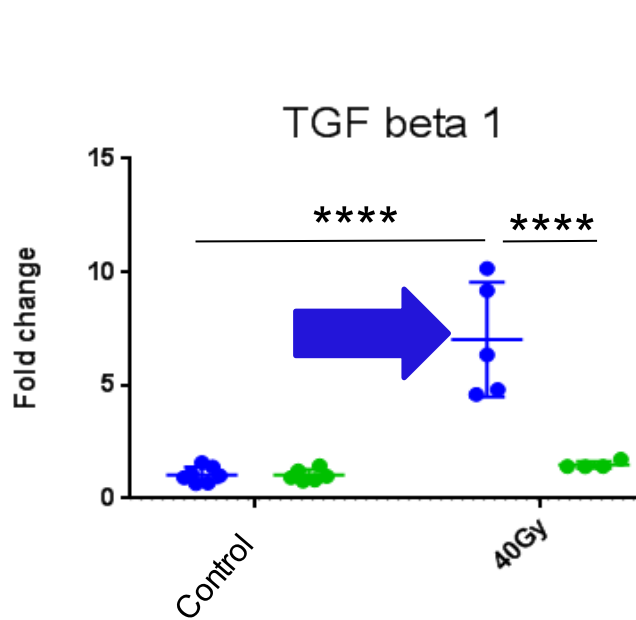
****: p-value<0,0001



TIMP: inhibitors of metalloproteinases

Significant remodelling of the extracellular matrix at 3 months for 40Gy

Transcriptomics studies: fibrosis



- 3 months
- 4 months
- 6 months

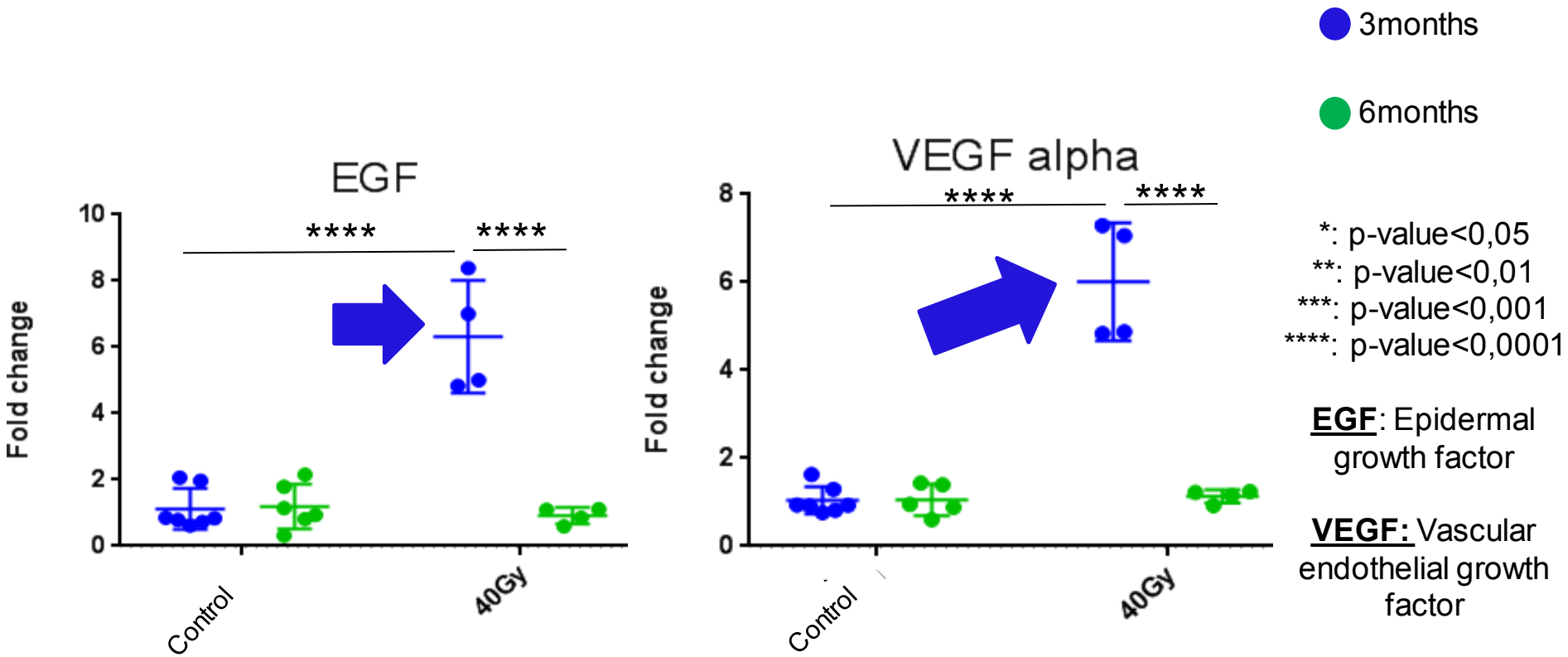
*: p-value<0,05
**: p-value<0,01
***: p-value<0,001
****: p-value<0,0001

TGF: Transforming growth factor

SMA: Smooth Muscle Actin, Alpha

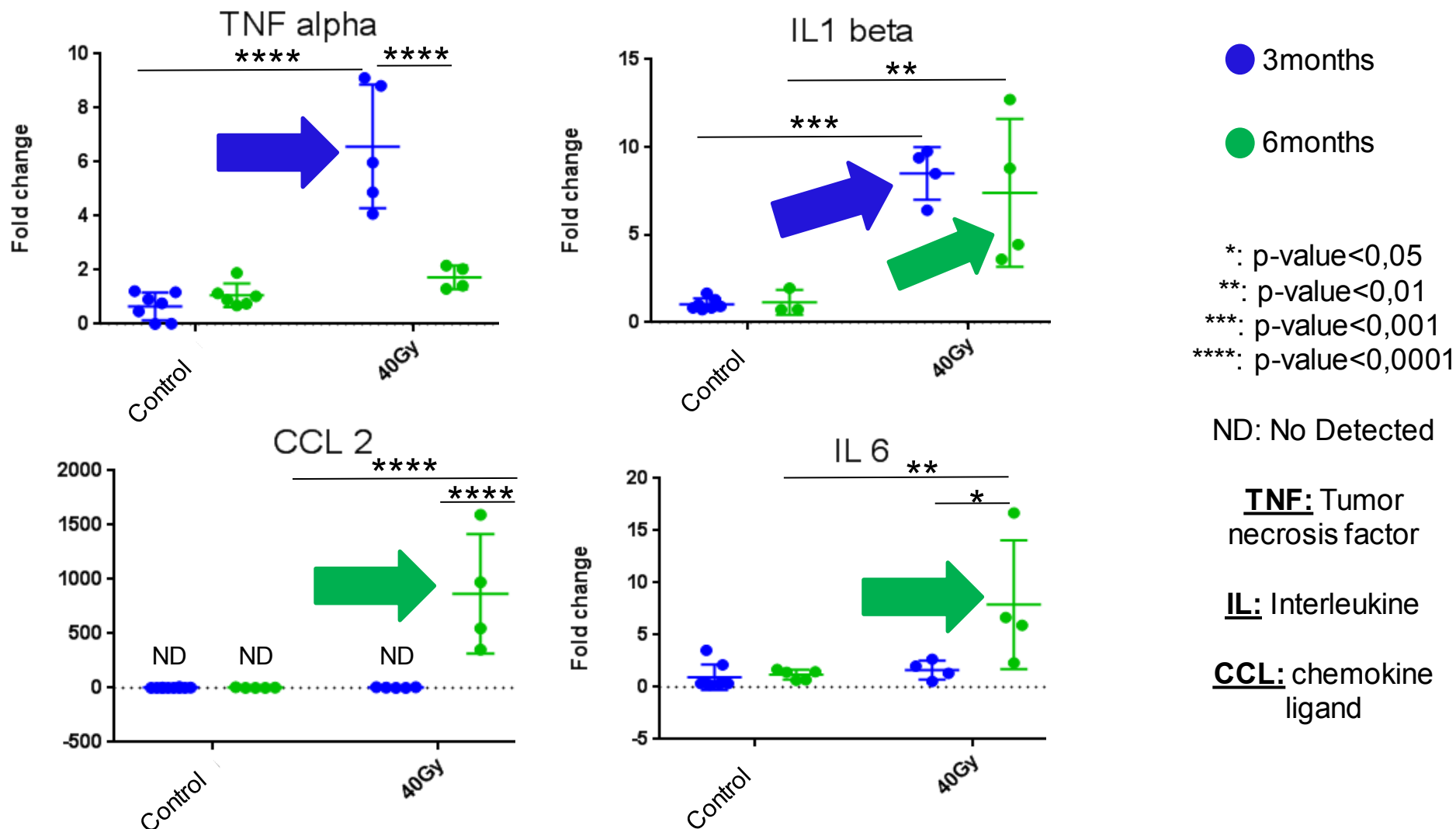
At 6 months no fibrosis

Transcriptomics studies: Tissue regeneration



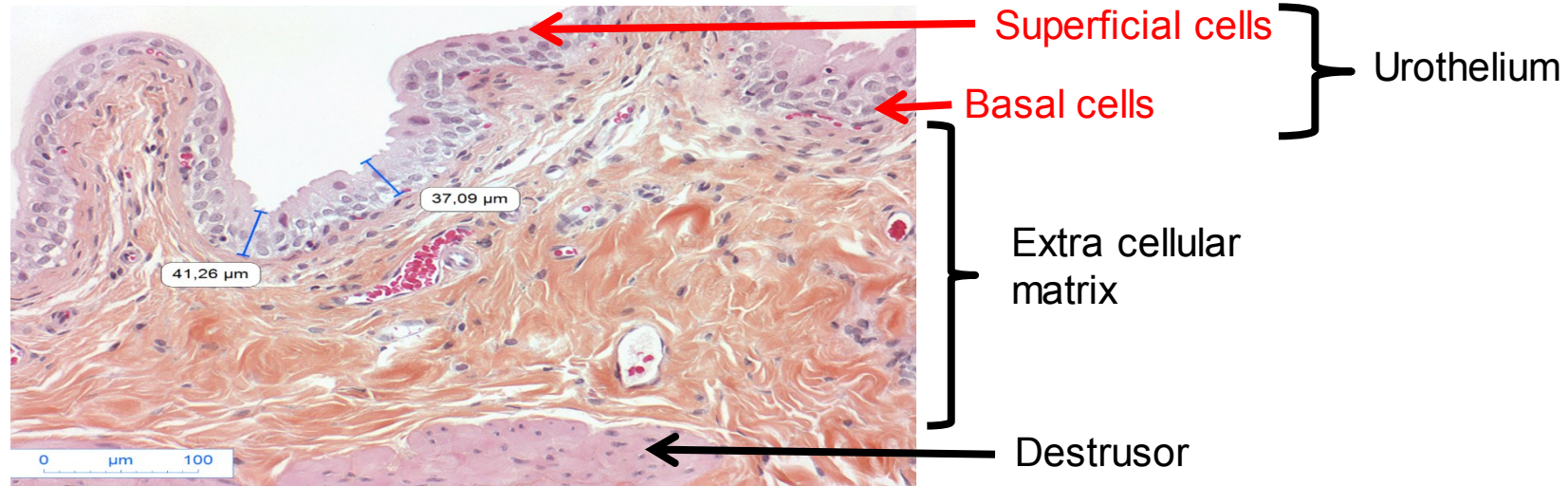
Increased tissue regeneration at 3 months

Transcriptomics studies: inflammation

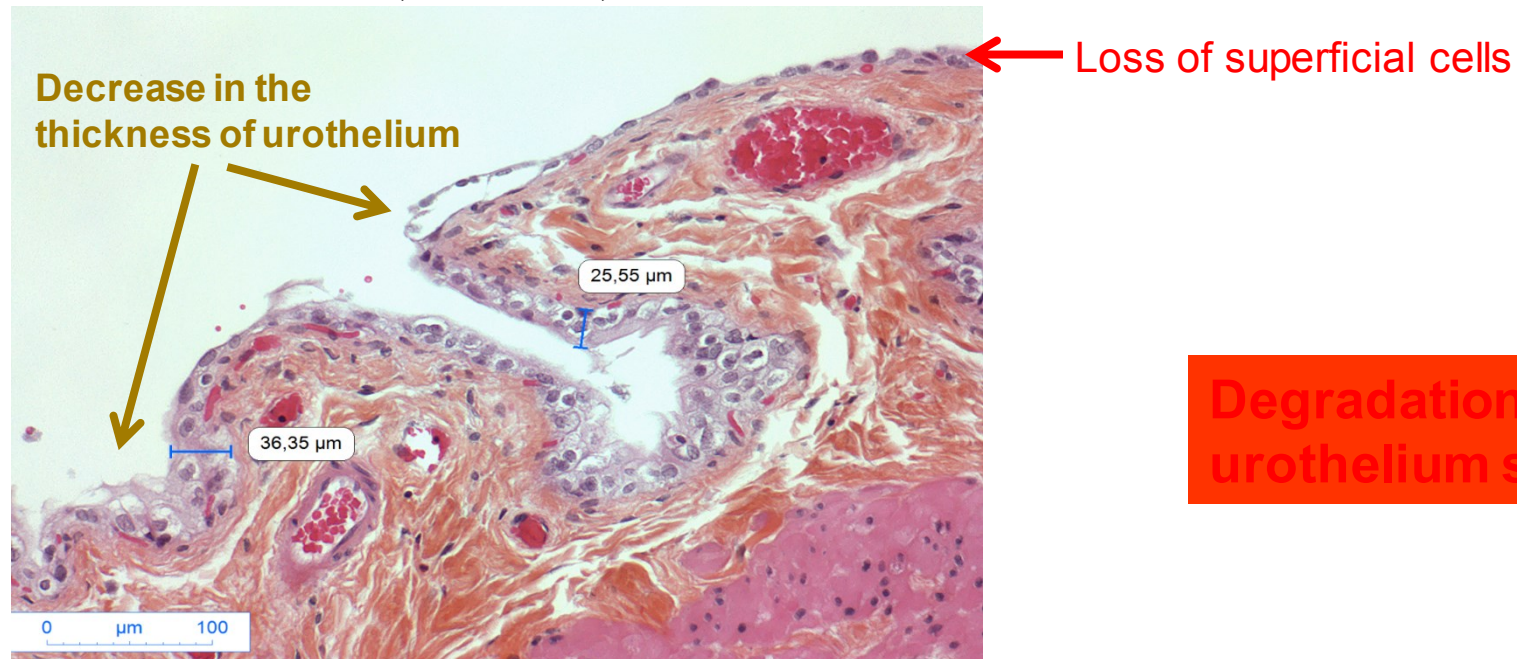


Acute inflammation at 3 months and chronic at 6 months

Tissue study: urothelium damages (HES)



Unirradiated bladder, 6 months, X 200



Degradation of the urothelium structure

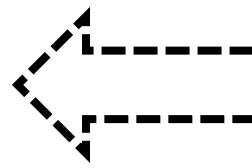
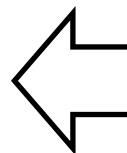
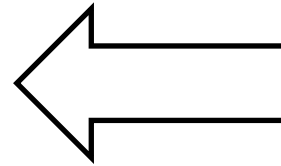
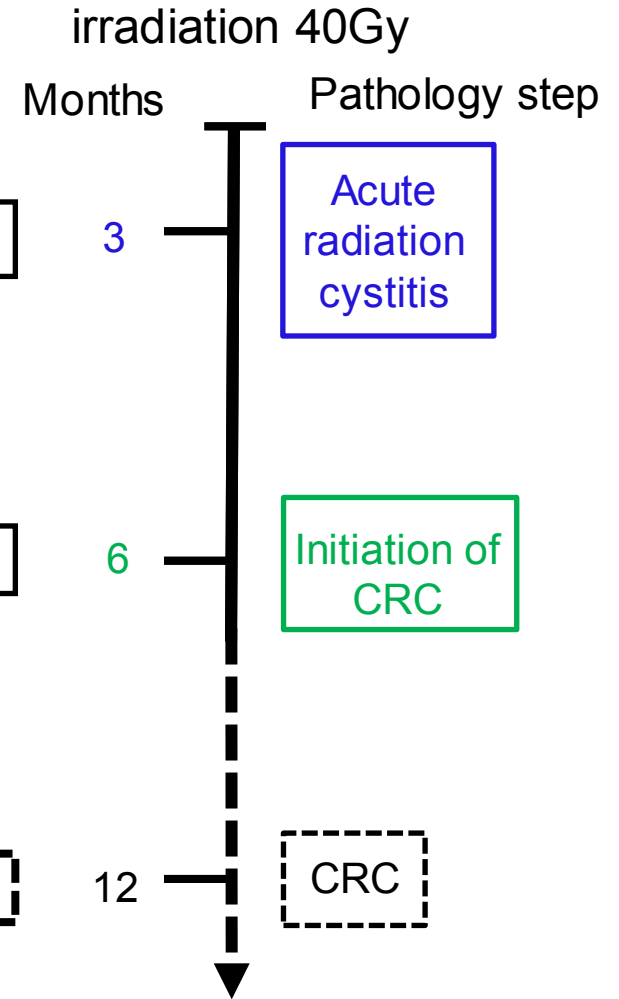

Bladder irradiated at 40 Gy, 6 months, X 200

HES: Hematoxyline, Eosin, Safran

Conclusions: physiopathologie

Early inflammation: ↑ IL1 β , TNF α
Vascular damage: microscopic hematuria
ECM : ↑ TIMP 1 et 2, col1 α 2, col3 α 1, TGF β 1
Tissue regeneration : ↑ EGF, VEGF α

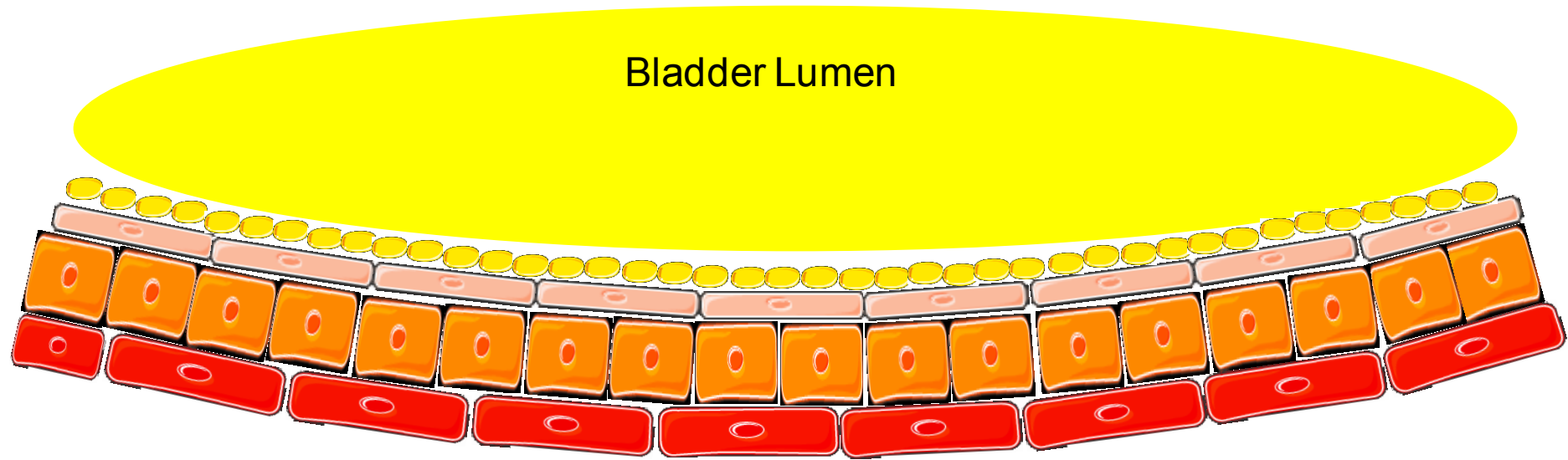
Chronic inflammation: ↑ IL1 β , CCL2, IL6
Degradation of urothelium: structure (HES sections)
Vascular damage: microscopic hematuria



6 months = Initiation of the chronic phase

ECM: extra cellular matrix

Conclusions: Global mechanism



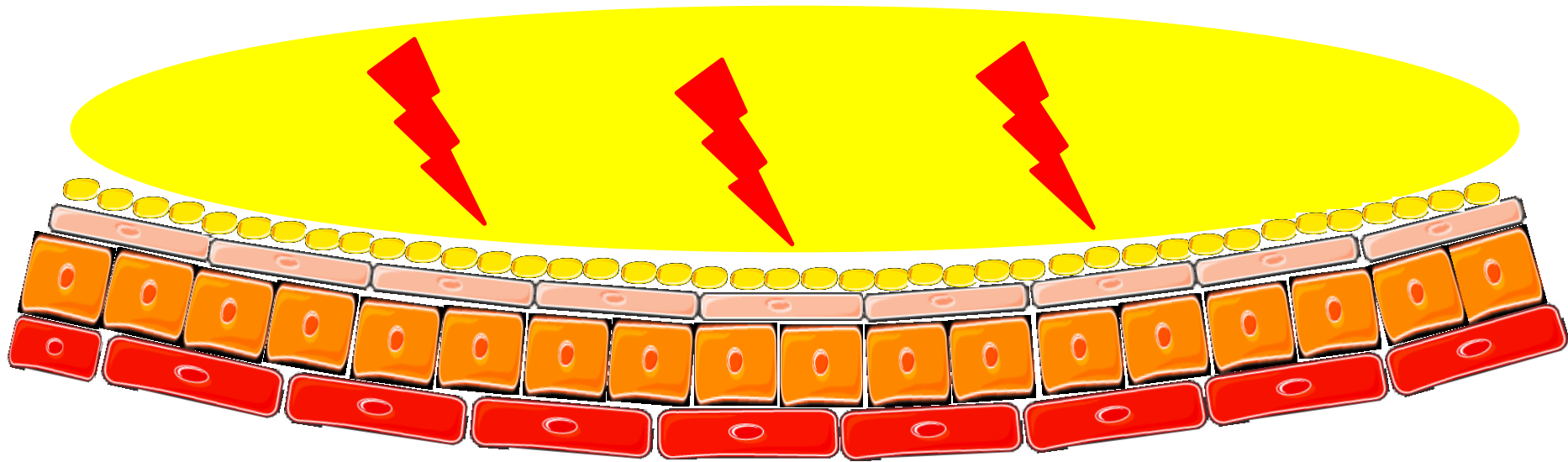
 GAG layer

 Superficials cells

 Intermediates cells


 Basals cells

Conclusions: Global mechanism



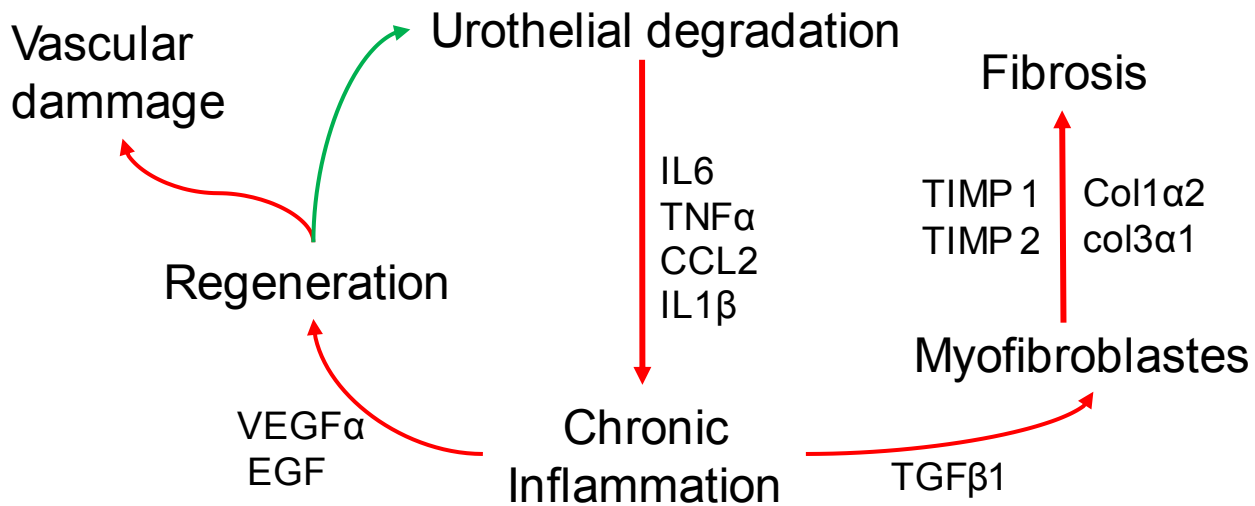

 GAG layer

 Superficials cells

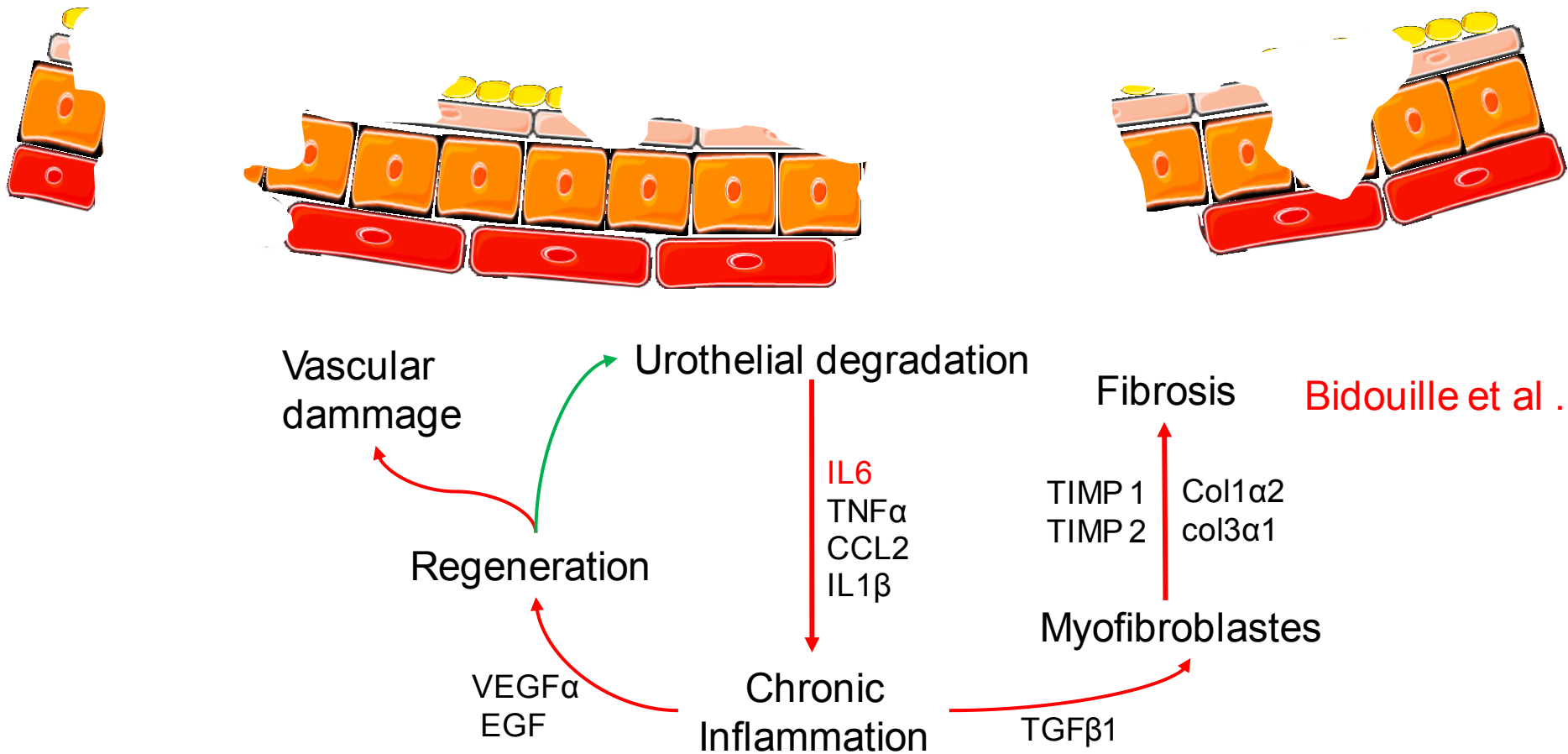
 Intermediates cells

 Basals cells

Conclusions: Global mechanism

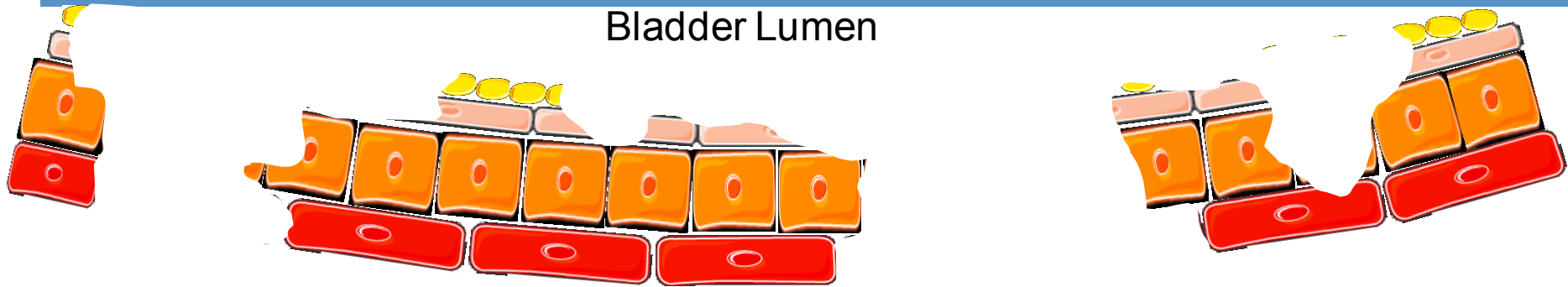


Conclusions: Global mechanism

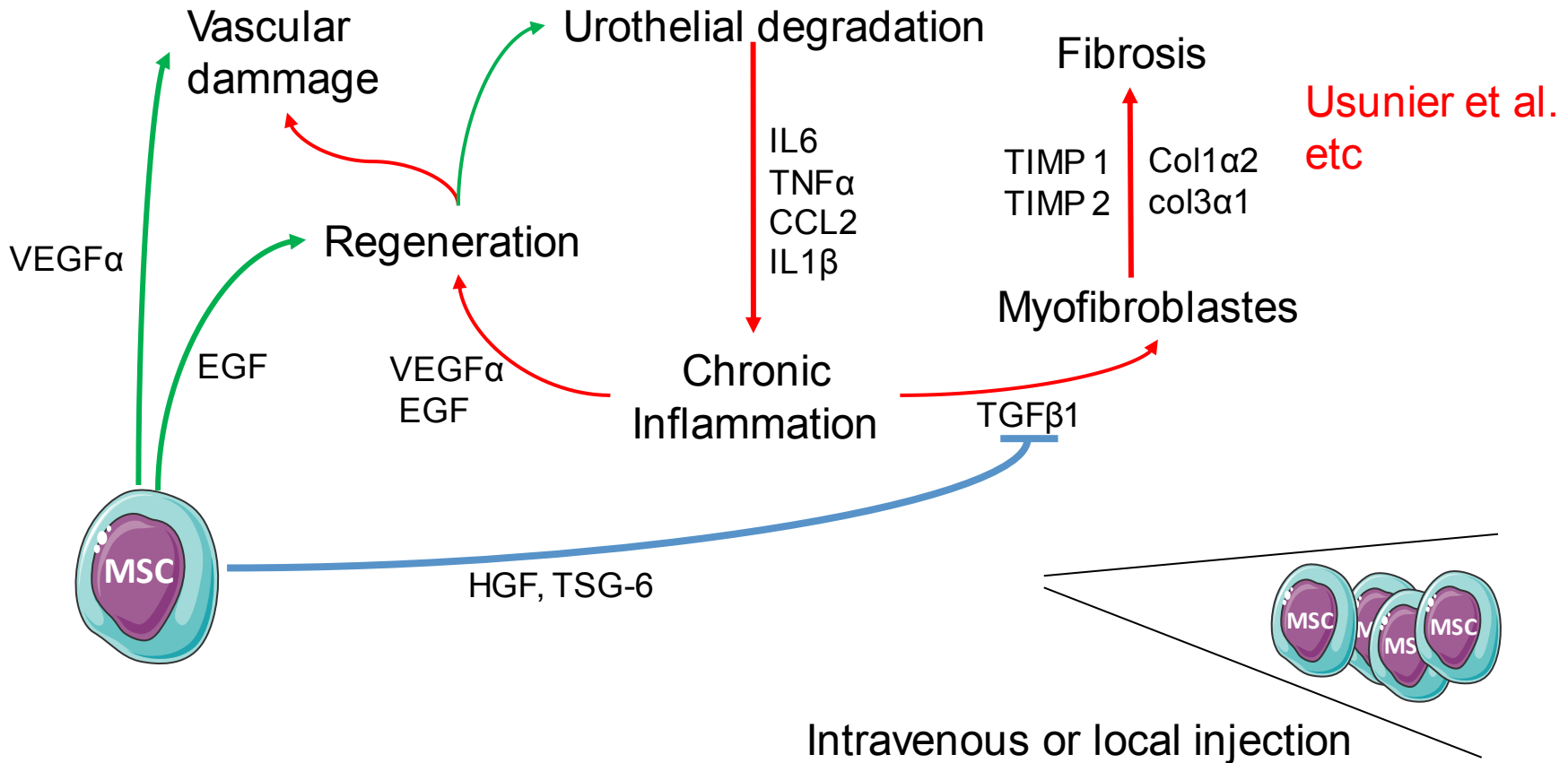


Study of MSC action

Study of MSC action : principal hypothesis



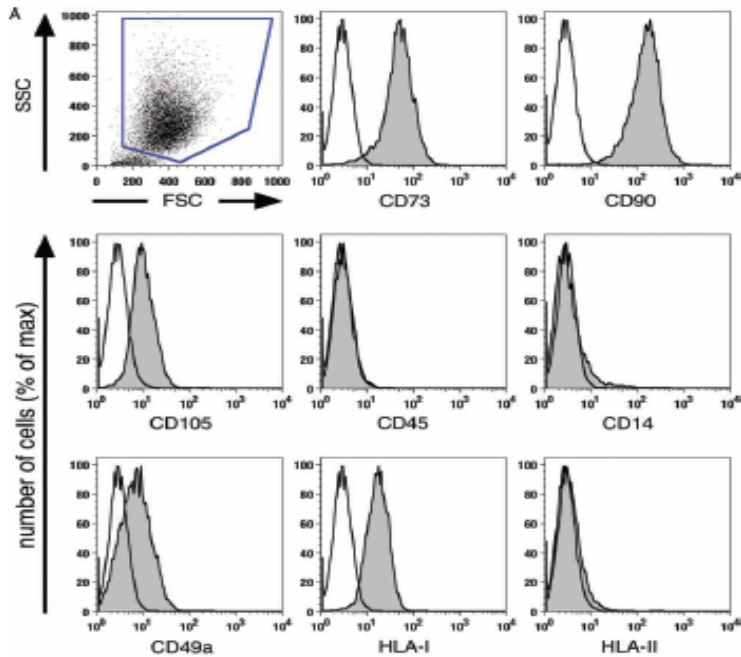
Bladder Lumen



Usunier et al.
etc

Intravenous or local injection

Characteristic of MSC



Torin 2009

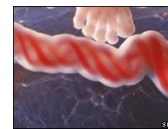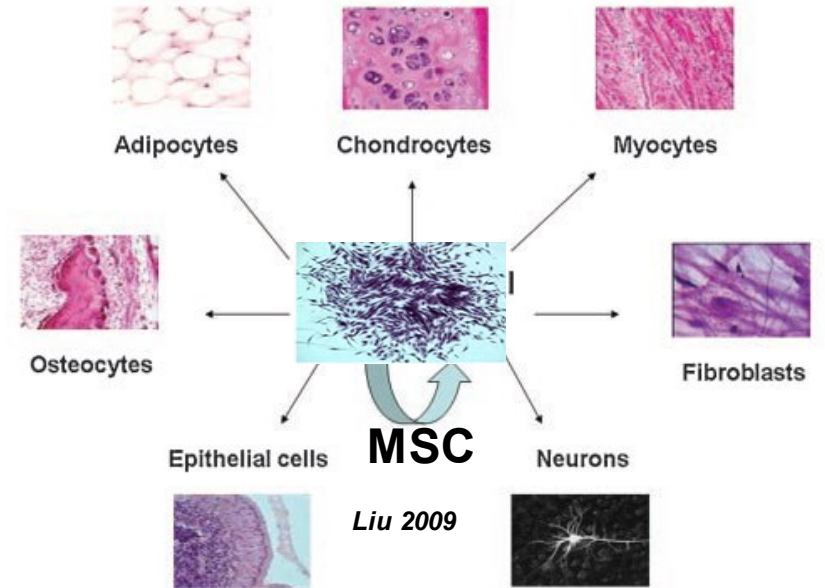
Cytotherapy (2009) Vol. 11, No. 2, 114-128



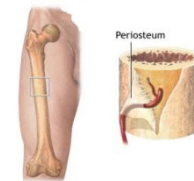
informa healthcare

Characterization of bone marrow-derived mesenchymal stromal cells (MSC) based on gene expression profiling of functionally defined MSC subsets

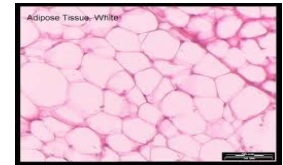
Ariane Torin¹, Jan C. Brune¹, Eleonor Olsson^{1,2}, Jeanette Valcich^{1,2}, Ulf Neuman³, Tor Olofsson⁴, Sten-Eirik Jacobsen^{1,5} and Stefan Scheduling^{1,6}



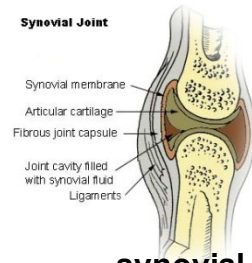
Umbilical cord Wharton's jelly



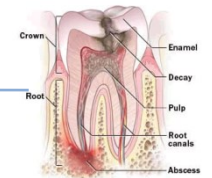
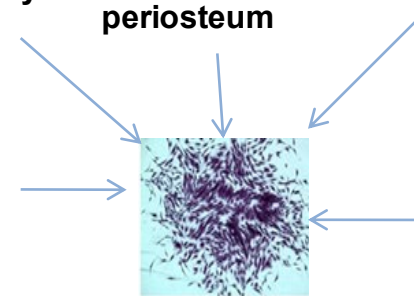
Bone marrow periosteum



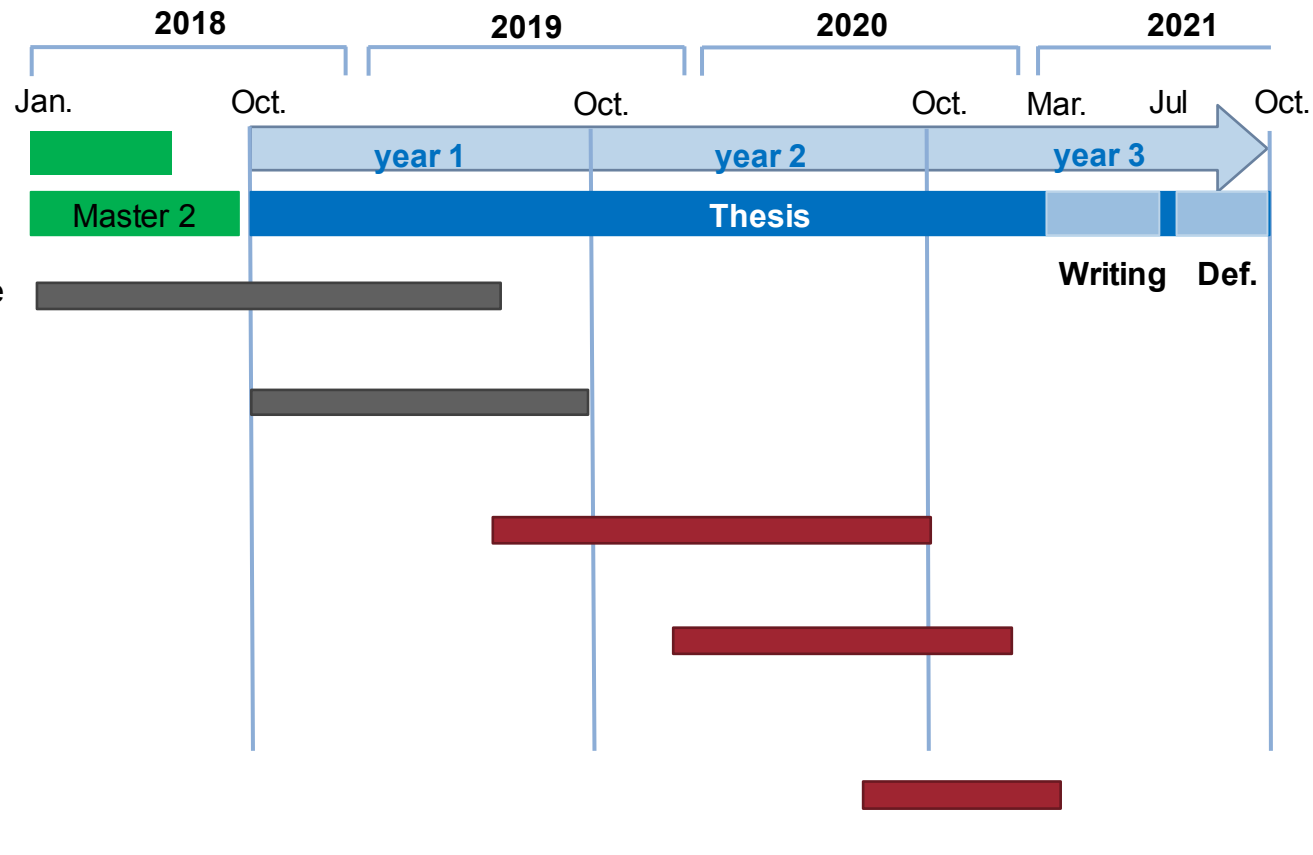
Adipose tissue



synovial membranes



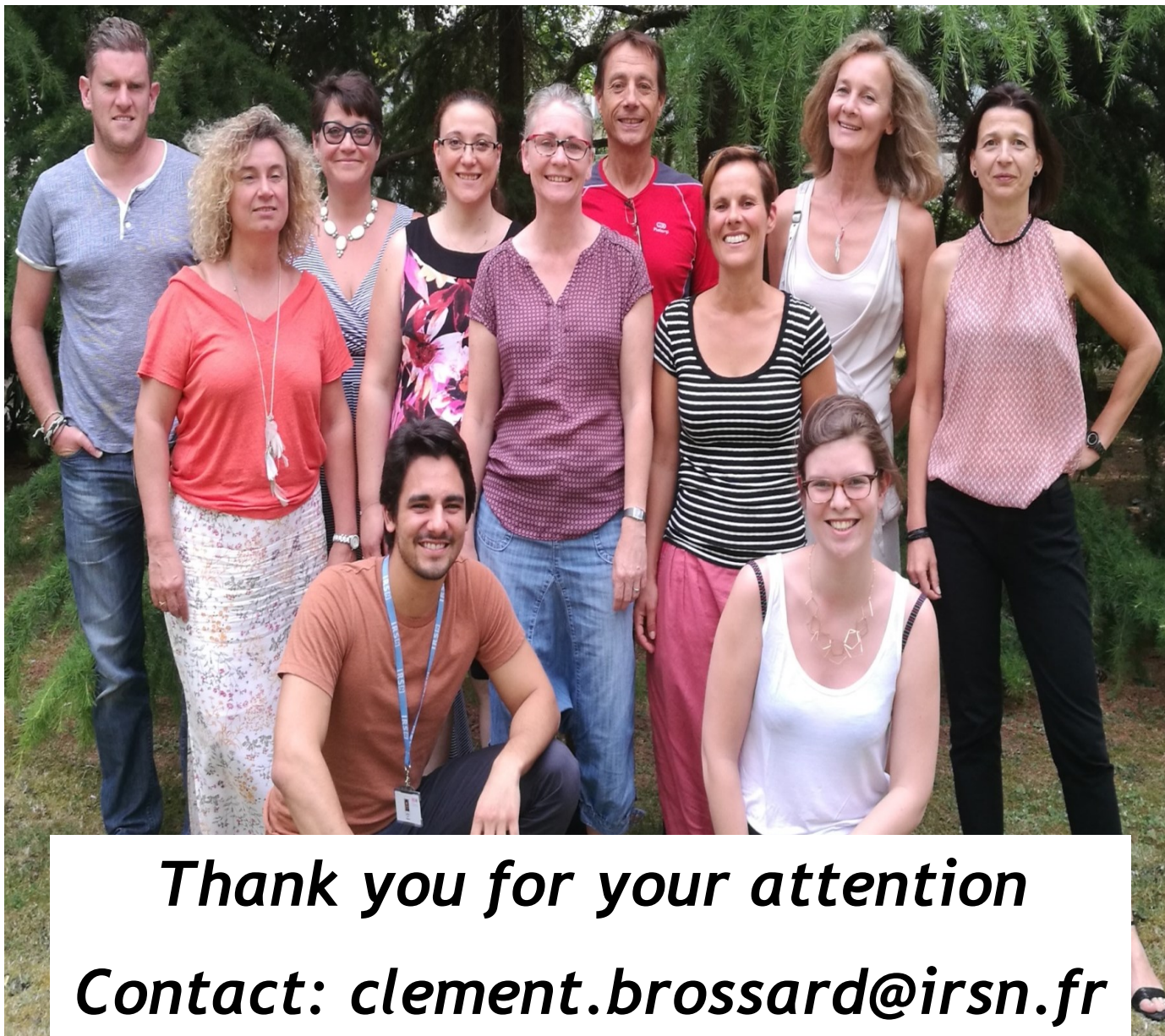Dental pulp



Task 1
Study of the
Chronic radiation cystitis

Task 2
Processing of the
Chronic radiation cystitis

Task 3
Study of treatments
on fibrosis



Thank you for your attention
Contact: clement.brossard@irsn.fr



IRSN



• saint
antoine




SERVICE DE SANTÉ
DES ARMÉES




ÉTABLISSEMENT FRANÇAIS DU SANG

Table 1 | RTOG/EORTC grading of hematuria events

Hematuria morbidity	Grade 1	Grade 2	Grade 3	Grade 4	Grade 5
Acute hemorrhagic radiation cystitis (RTOG scale)	NA	NA	Gross hematuria with or without clot passage	Hematuria requiring transfusion	Death from uncontrolled hematuria
Late hemorrhagic radiation cystitis (RTOG/EORTC scale)	Minor telangiectasia (microscopic hematuria)	Generalized telangiectasia (macroscopic hematuria)	Severe generalized telangiectasia (macroscopic hematuria)	Severe hemorrhagic cystitis	Death from uncontrolled hematuria

Abbreviations: EORTC, European Organisation for Research and Treatment of Cancer; RTOG, Radiation Therapy Oncology Group.

Traitement:

- Intravesical instillation :
- Aluminium
 - Formalin
 - Alun
 - Pentosan polysulfate

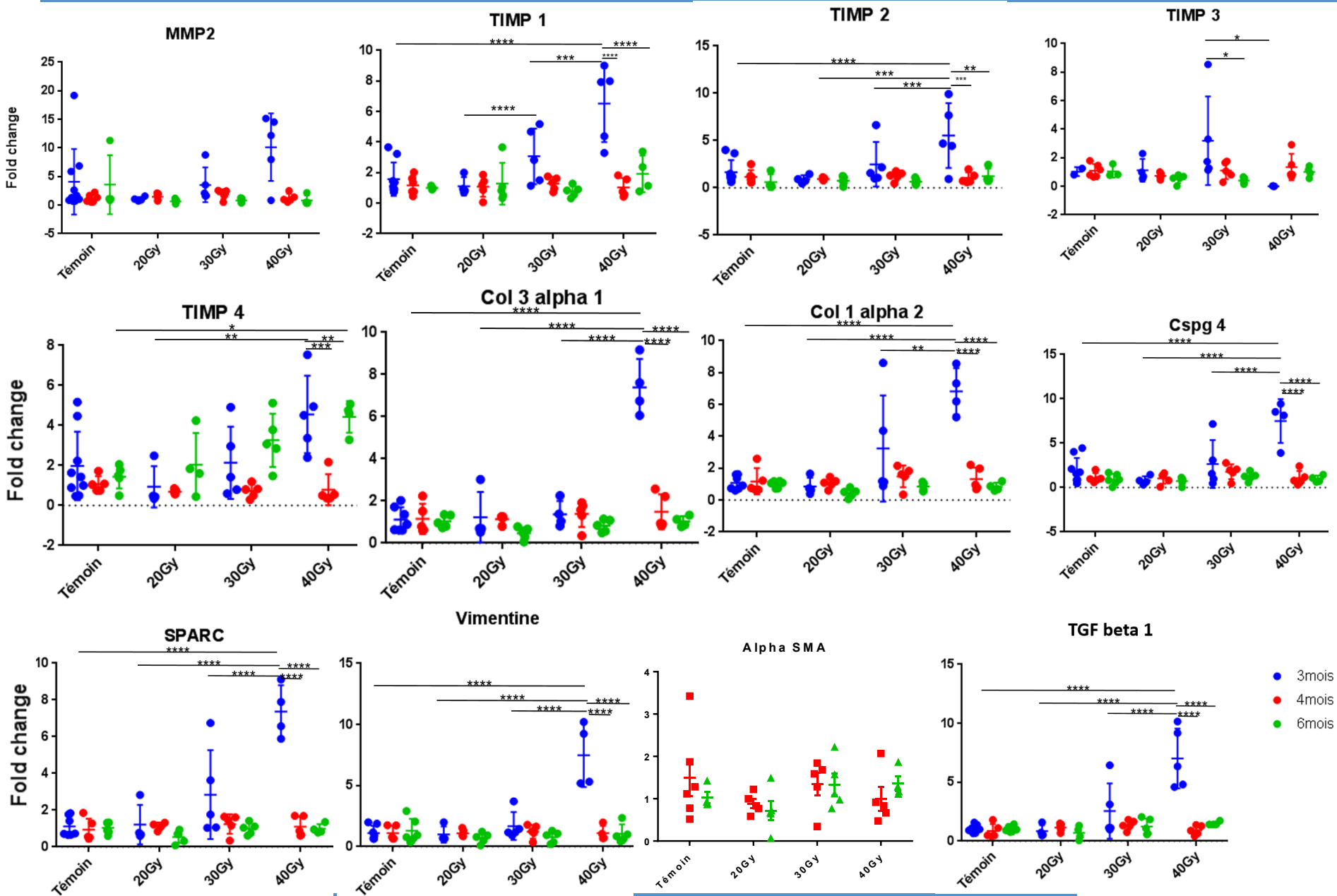
Traitement hyper bar

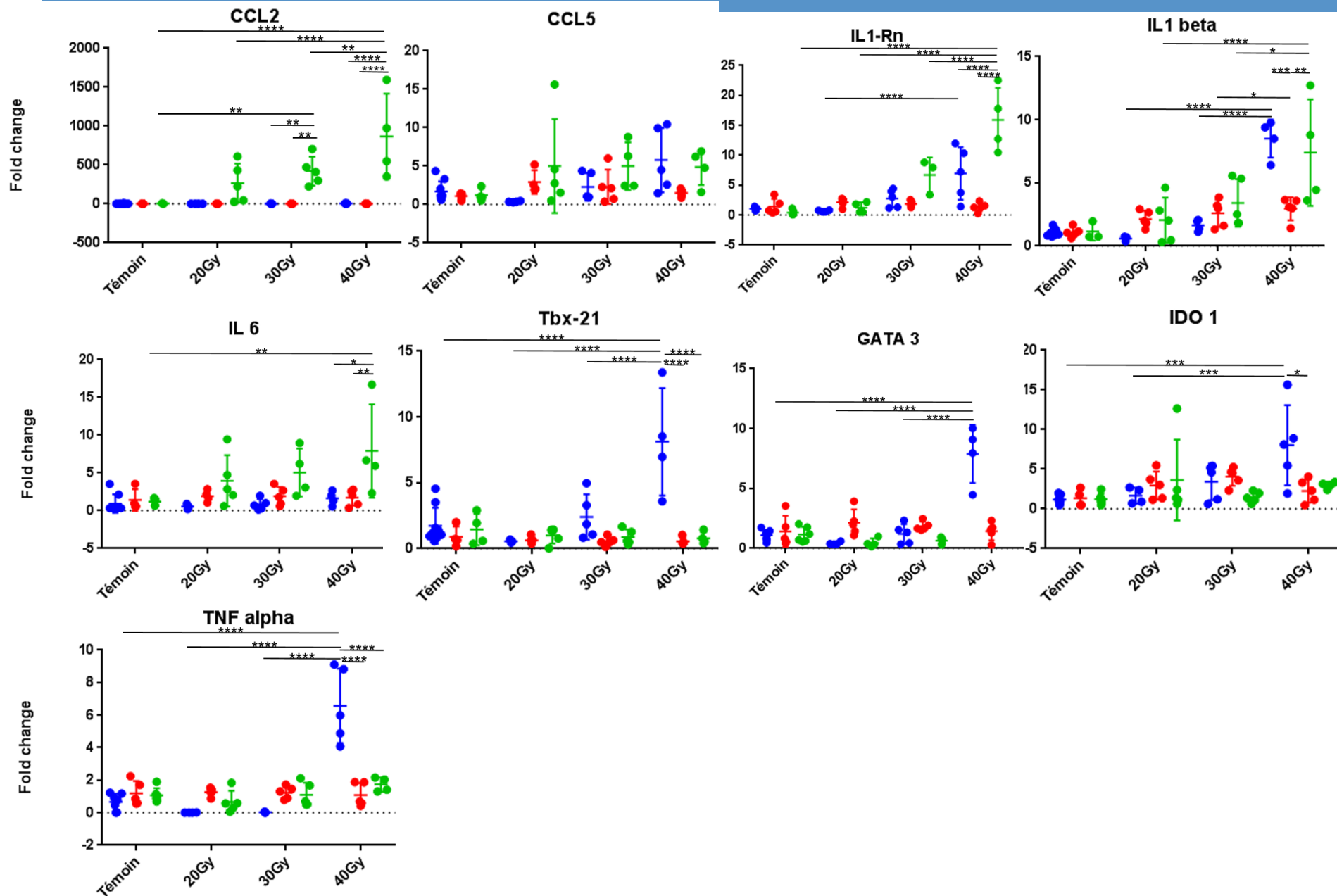
Smit SG, Heyns CF. [Management of radiation cystitis](#). Nat Rev Urol. 2010 Apr;7(4):206-14. doi: 10.1038/nrurol.2010.23. Epub 2010 Mar 9. Review. PubMed PMID: 20212517.

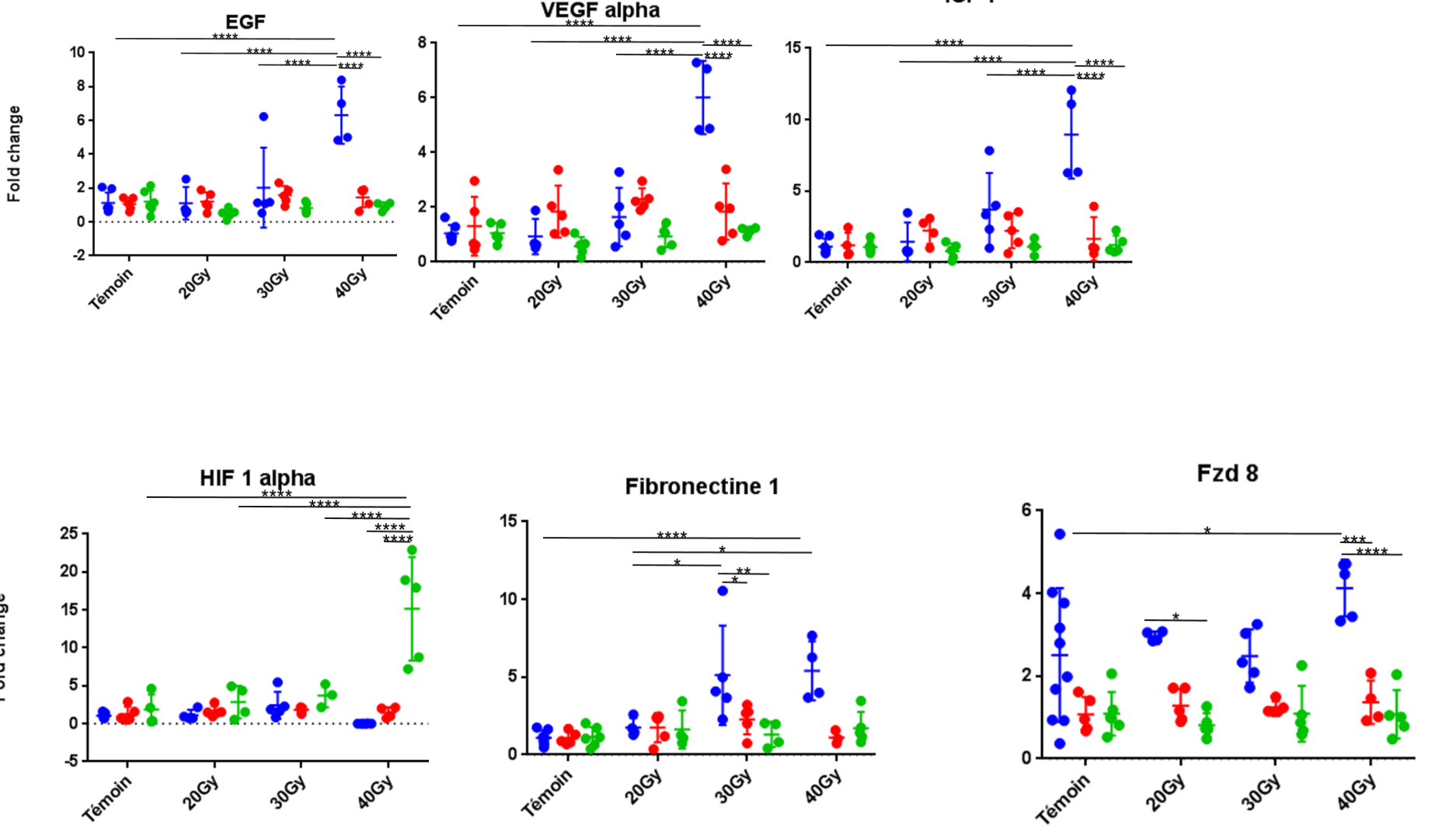
Intestin grêle	Dose maximale de 50 Gy Dose maximale de 40 Gy sur un grand volume
Estomac, duodénum	Dose maximale de 45 Gy Dose maximale de 54 Gy dans un petit volume
Vessie	$V_{60} \leq 50\%$ $V_{70} \leq 25\%$
Cols, têtes fémorales, grand trochanter	$V_{50} \leq 10\%$
Rectum (paroi rectale)	$V_{60} \leq 50\%$ $V_{70} \leq 25\%$ $V_{74} \leq 5\%$


CSM pathways of action on preclinical fibrosis models

Mode of action	Mechanism	References
Immunomodulation	<p>Decrease in inflammatory infiltration</p> <p>Polarity change of macrophages: M1 -> M2</p> <p>Decrease in the expression and secretion of pro-inflammatory cytokines (TNF-α, IL-1, IL-6...)</p> <p>Decrease in apoptosis</p>	<p>Linard et coll., 2013</p> <p>Zhou et coll., 2013</p> <p>Semedo et coll., 2009</p> <p>Horton et coll., 2013</p>
Inhibition of the TGF pathway- β 1	<p>Decreased expression and secretion of TGF-β1</p> <p>Decrease in the activation of the Smad channel</p> <p>Decrease in the number of myofibroblasts</p>	<p>Ueno et coll., 2013</p> <p>Wu et coll., 2014</p> <p>Jang et coll., 2014</p> <p>Li et coll., 2013</p>
Pro-angiogenic/anti-oxidant	<p>Increase in the expression and secretion of antioxidant enzymes (NQO1, HO-1, SOD...)</p> <p>Pro-angiogenic effect: increase in VEGF and FGF-2</p> <p>Augmentation de la prolifération des cellules endothéliales</p>	<p>Chen et coll., 2011</p> <p>Kinnaird et coll., 2004</p> <p>Niu et coll., 2008</p> <p>Kinnaird et coll., 2004</p>
Remodelage matriciel	<p>Decrease in the expression and production of MEC components</p> <p>Rebalancing the MMP/TIMP balance</p>	<p>Moodley et coll., 2009</p> <p>Mias et coll., 2009</p> <p>Ebrahimi et coll., 2013</p>

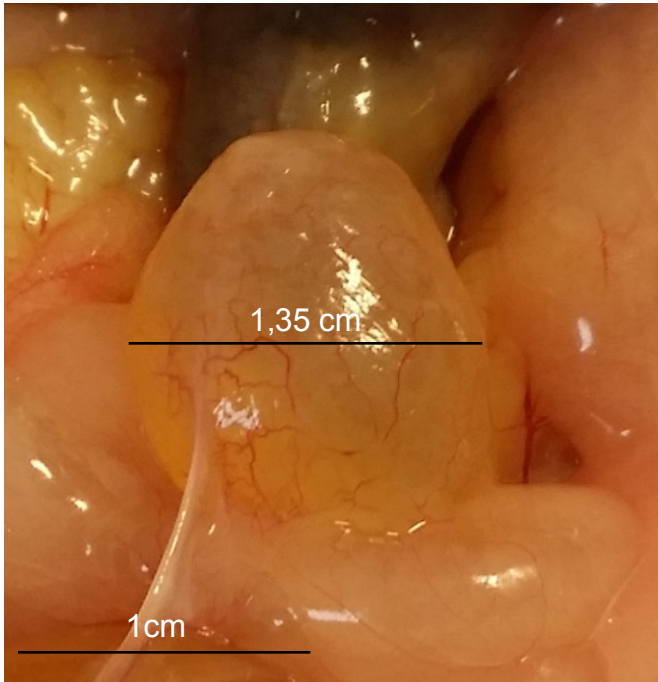






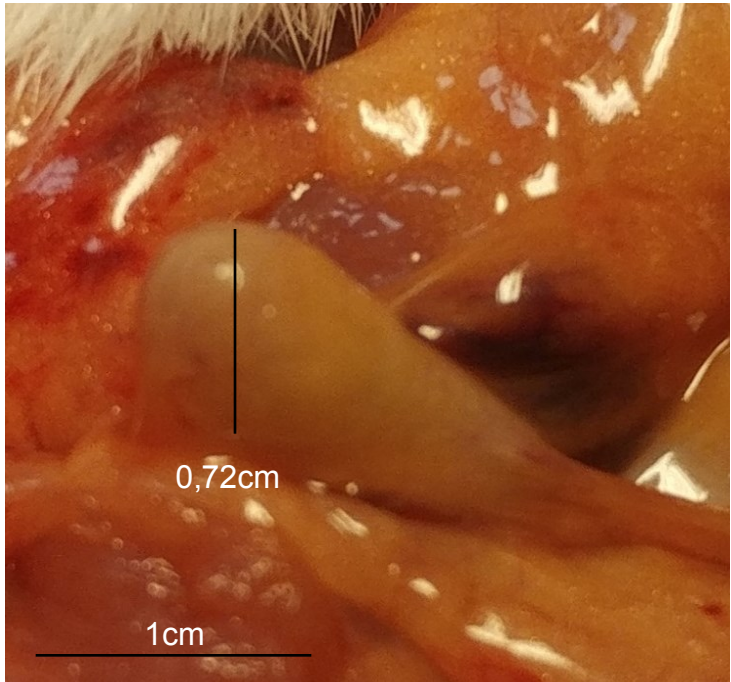


Example of a bladder with chronic radiation cystitis (60 Gy, 4 months)



Normal bladder in rat

- Decrease in volume
- Opacification
- Rigidification



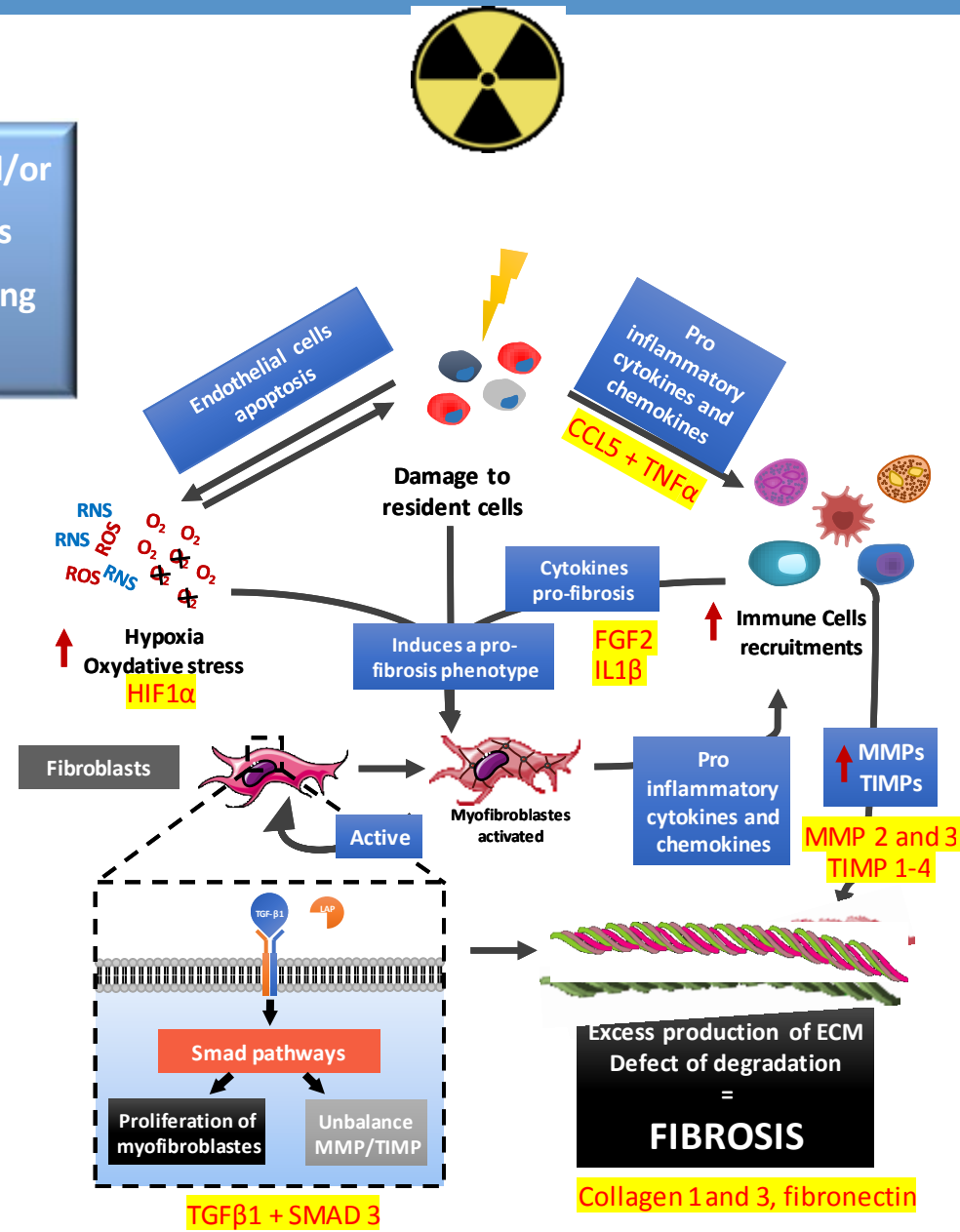
Chronic radiation cystitis in rat

“Fibrosis is defined by the overgrowth, hardening, and/or scarring of various tissues and is attributed to excess deposition of extracellular matrix components including collagen” (Wynn TA, 2008)

Cytokine pro fibrosis secreted following irradiation

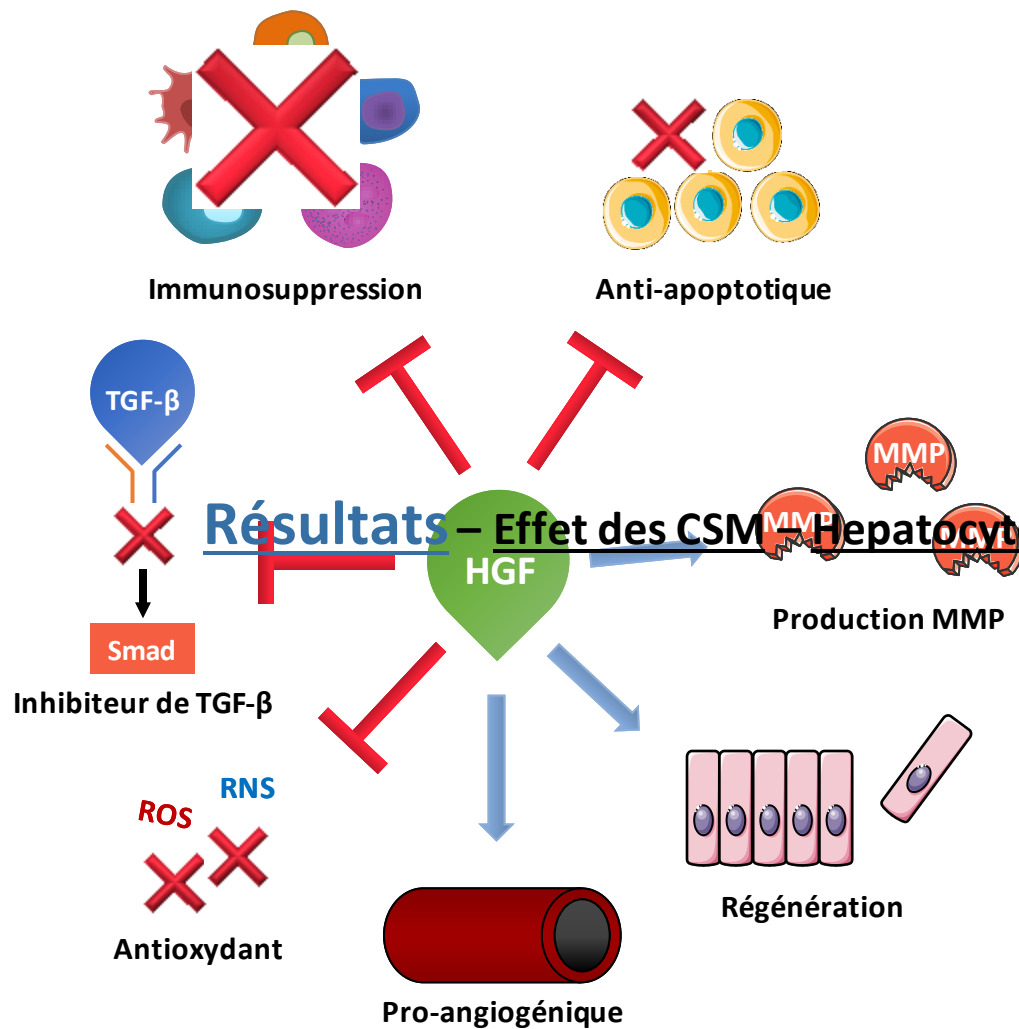
Activation of extracellular matrix secreting cells

Imbalance of the accumulation/degradation of the ECM



HIF1 α = results of M2

ECM: ExtraCellular Matrix



Hepatocyte Growth Factor (HGF)

Facteur de croissance pléiotropique

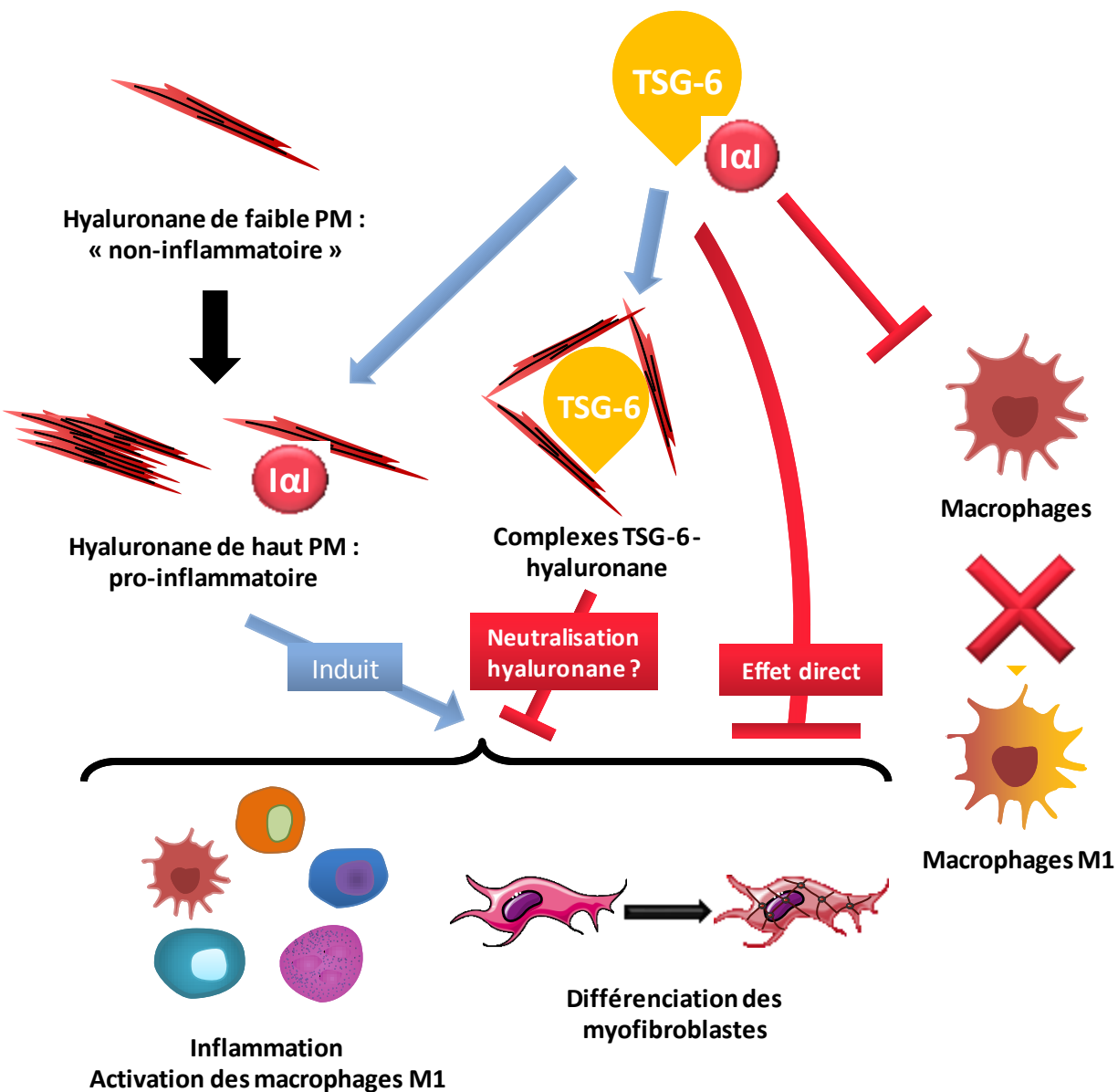
Exprimé dans de nombreux tissus en cas de lésion

Pouvoir anti-fibrosant démontré

Sécrété par les CSM dans plusieurs modèles de fibrose (rein, foie, poumon)

Implication du HGF sécrété par les CSM lors de la fibrose colorectale radio-induite ?

Résultats – Effet des CSM – Hepatocyte Growth Factor – Propriétés démontrées



TNF-stimulated Gene-6 (TSG-6)

Protéine immunomodulatrice

Exprimé lors de l'inflammation (induit par TNF-α)

Stimule/réduit l'inflammation

Sécrété par les CSM dans plusieurs modèles de fibrose (rein, peau) : effet anti-fibrosant

Implication du TSG-6 sécrété par les CSM lors de la fibrose colorectale radio-induite ?

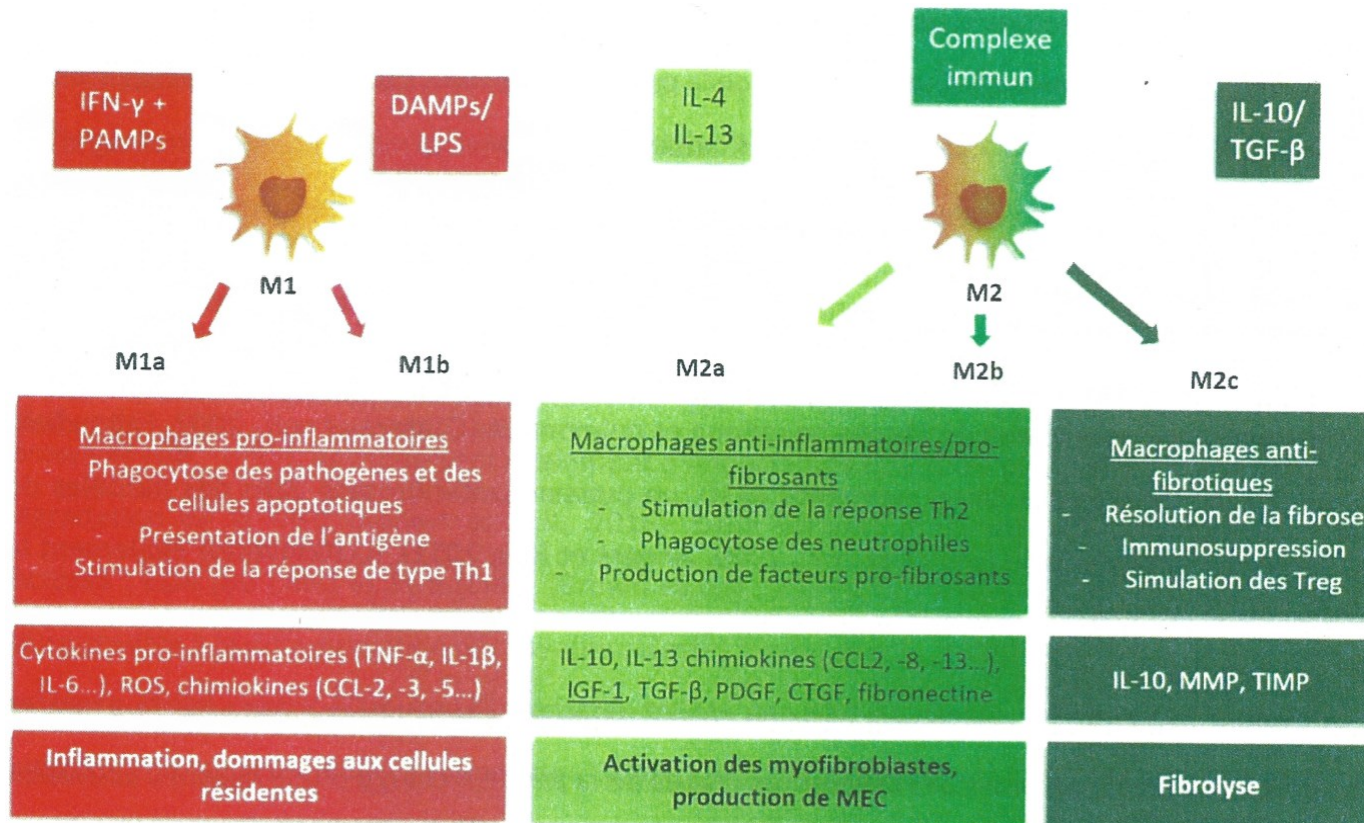


Figure 8 : Caractéristique des différents états de polarisation des macrophages.

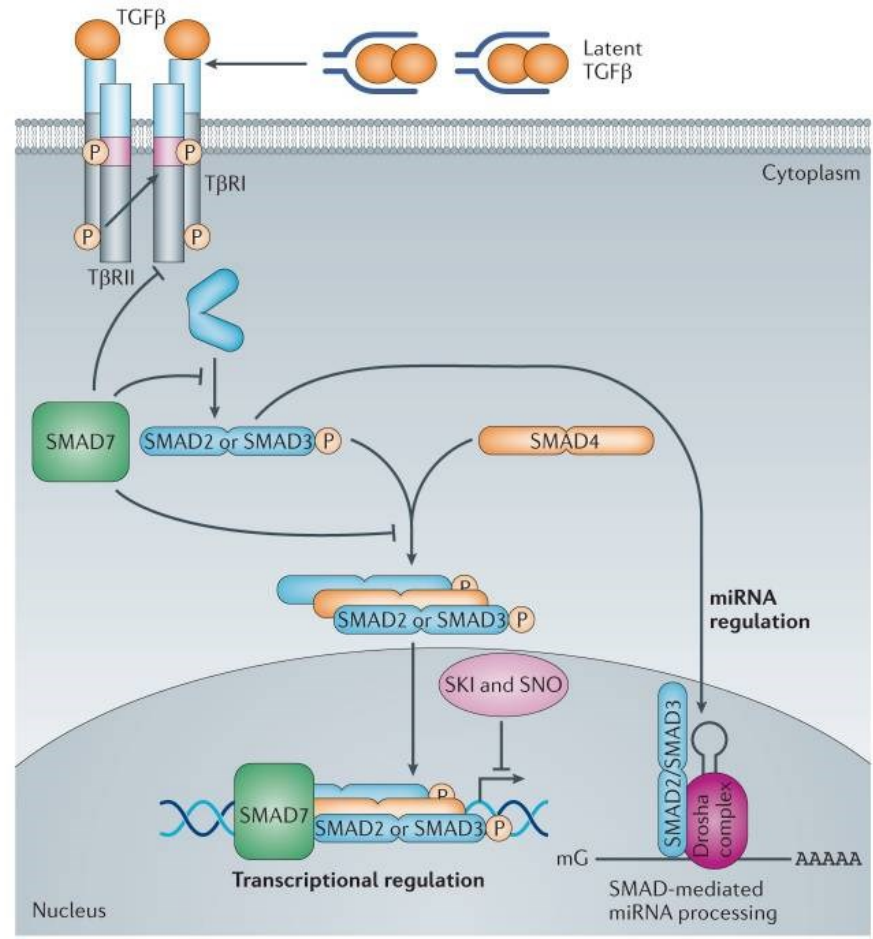
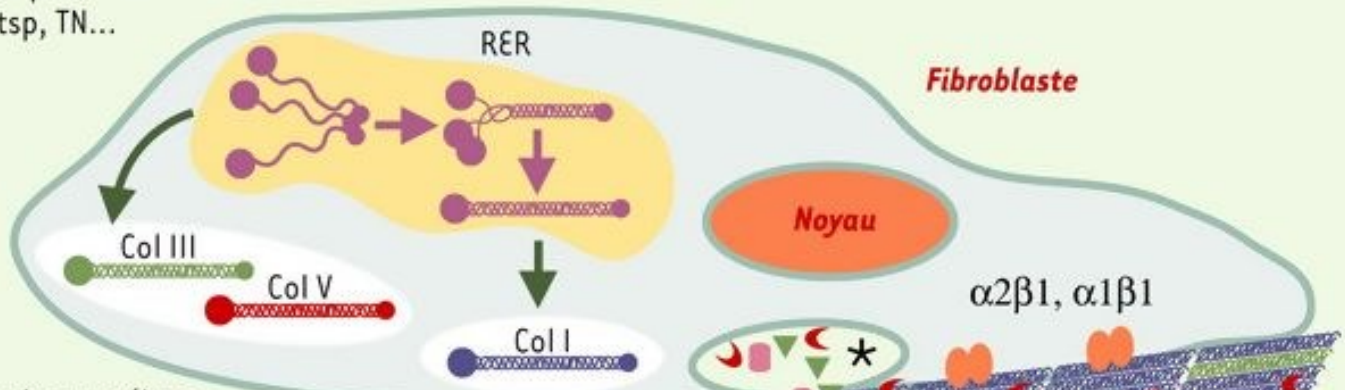
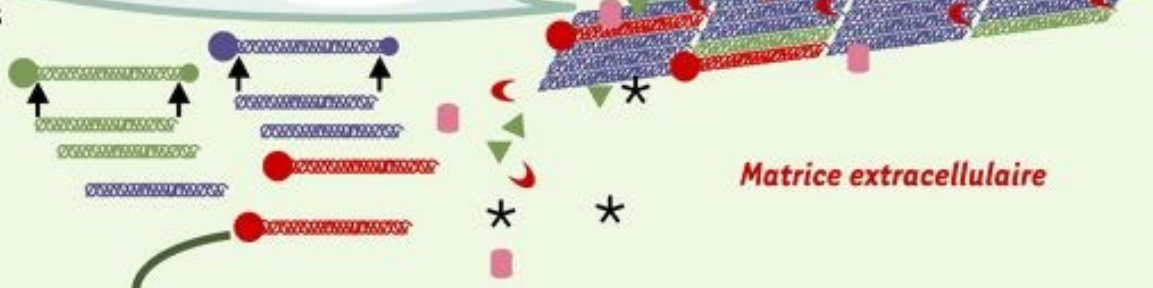


Figure: mécanismes d'activation et d'inhibition de la voie Smad (D'après Akhurst, 2012) (Akhurst and Hata, 2012)

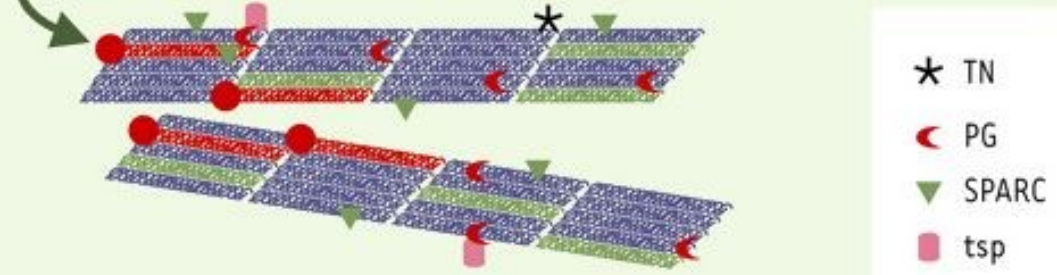
1. Synthèse des collagènes et autres composés matriciels : PG, SPARC, tsp, TN...



2. Sécrétion des protéines matricielles, maturation des collagènes



3. Association en fibres et interaction avec d'autres composants matriciels



- * TN
- ◀ PG
- ▼ SPARC
- tsp