HAL open science

Cardiac stereotactic ablative radiotherapy for refractory ventricular arrhythmias: A radical alternative? A narrative review of rationale and cardiological aspects

Karim Benali, Julien Bellec, Nicolas Jaksic, Pierre Caille, Louis Rigal, Antoine Simon, Vincent Galand, Néfissa Hammache, Antoine da Costa, Renaud de Crevoisier, et al.

To cite this version:

Karim Benali, Julien Bellec, Nicolas Jaksic, Pierre Caille, Louis Rigal, et al.. Cardiac stereotactic ablative radiotherapy for refractory ventricular arrhythmias: A radical alternative? A narrative review of rationale and cardiological aspects. Journal of Medical Imaging and Radiation Sciences, 2021, 52 (4), pp.626-635. 10.1016/j.jmir.2021.09.007 . hal-03414452

HAL Id: hal-03414452

https://hal.science/hal-03414452

Submitted on 29 Nov 2021

HAL is a multi-disciplinary open access archive for the deposit and dissemination of scientific research documents, whether they are published or not. The documents may come from teaching and research institutions in France or abroad, or from public or private research centers.

L'archive ouverte pluridisciplinaire **HAL**, est destinée au dépôt et à la diffusion de documents scientifiques de niveau recherche, publiés ou non, émanant des établissements d'enseignement et de recherche français ou étrangers, des laboratoires publics ou privés.

Distributed under a Creative Commons Attribution - NonCommercial - NoDerivatives 4.0 International License

Cardiac stereotactic ablative radiotherapy for refractory ventricular arrhythmias: A radical alternative? A narrative review of rationale and cardiological aspects.

Type of manuscript: Review article

Authors declare no Conflict of Interests for this article.

Funding source: authors received no specific funding for this work.

Karim Benali[1,2]; Julien Bellec[3]; Nicolas Jaksic[3], MD; Pierre Caille[3]; Louis Rigal[4]; Antoine Simon[4]; Vincent Galand[4,5]; Néfissa Hammache[2,] Antoine Da Costa[1]; Renaud De Crevoisier[3,4]; Raphaël Martins[4,5]

WORKING GROUP ADDRESS:

[1] Saint-Etienne University Hospital, Department of Cardiology, Saint-Priest-En-Jarez, F-42270, France

[2] INSERM-IADI, U947, Vandœuvre lès-Nancy, F-54500, France

[3] Centre Eugène Marquis, Department of Radiation Oncology, Rennes, F-35000, France

[4] INSERM-LTSI, U1099, Rennes, F-35000, France

[5] Rennes University Hospital, Department of Cardiology, Rennes, F-35000, France

Authors declare no Conflict of Interests for this article.

Funding source: authors received no specific funding for this work.

Address for correspondence:

Karim BENALI, MD

From the division of Cardiology, Saint-Etienne University hospital,

Saint-Etienne, F-42270, France

Electronic address: mirakbenali@gmail.com

WORD COUNT: 3418

Accepted manuscript

Abbreviations

ATP: antitachycardia pacing

CT: computed tomography

ICD: implantable cardioverter-defibrillator

MRI: magnetic resonance imaging

PTV: planning target volume

RF: radiofrequency

SABR: stereotactic ablative radiation therapy

SPECT: single photon emission computed tomography

VA: ventricular arrhythmia

VF: ventricular fibrillation

***VT:* ventricular tachycardia**

Accepted manuscript

Introduction

Ventricular tachycardias (VT) are cardiac arrhythmias defined by a rapid and organized rhythm originating from the ventricle(1). These tachycardias can occur on healthy hearts but most often develop on structural heart diseases (2–4). VTs can be well tolerated, or cause hemodynamic instability leading to life-threatening complications. In some cases, they can be responsible of sudden cardiac death(5). Antiarrhythmic drugs represent the reference therapy for VT management but are often incompletely effective and/or responsible of serious adverse effects(6). In order to prevent sudden cardiac death risk, an implantable cardioverter-defibrillator (ICD) is often required (7). Nevertheless, patients' quality of life after ICD implantation can be severely impaired in cases of recurrent VTs. Over the past twenty years, VT catheter ablation has experienced considerable development(8). This technique is demonstrated to be effective and safe for preventing VT and shocks recurrences(9). However, despite many technological improvements, a non-negligible number of patients present refractory VTs, resistant to a catheter ablation procedure, placing these patients in a therapeutic impasse(10,11). A new approach based on a single high dose radiation delivered over a small area of the ventricular myocardium has been developed. Cardiac stereotactic ablative radiation therapy (SABR), also known as cardiac radioablation or cardiac stereotactic body radiation therapy, is an emerging treatment that has the advantage of overcoming some of the limitations of current standard treatments. This application of SABR on cardiac structures has been tested on small series of patients with encouraging results. In this review, we aimed to explain the cardiological background and the reasons for considering this more radical approach as an alternative therapy to treat patients with refractory ventricular arrhythmias (VA).

VT management

VTs and ICD

The term ventricular arrhythmias refers to a wide range of abnormal cardiac rhythms, from single premature ventricular contractions to sustained monomorphic VT, polymorphic VT and ventricular fibrillation (VF). These arrhythmias originate from below the atrioventricular node, whether from ventricular myocytes or from His-Purkinje tissue. Sustained VT and VF are the most common cause of sudden cardiac death(12). ICD implantation is not a curative treatment for VAs. Its role is limited to the prevention of sudden cardiac arrest(13). ICD implantation is recommended either as primary prevention in patients with heart disease presenting a high risk of ventricular arrythmia, or as secondary prevention in patients who have already presented a sustained VA (14–16). The ICD device consists in a generator placed under the skin in the pectoral region, connected to 1 or 2 leads fixed in the right ventricle and atrium (*Figure 1*). The system is able to detect life-threatening arrhythmias (sustained VT and VF) and to terminate them using two types of therapies: 1) by pacing the ventricle faster than the VT in order to interrupt the tachycardia circuit, known as antitachycardia pacing (ATP) or 2) by delivering an electrical shock to break the tachycardia.

Quality of life deterioration

Accepted manuscript

Patients' quality of life after ICD implantation is well known to be highly impaired. Arrhythmic events themselves according to their frequency and hemodynamic repercussion (dizziness, syncope…) have an impact on the daily life(17). In addition, ICD treatments are often the main cause of the quality-of-life deterioration(18,19). Electrical shocks are delivered by the ICD regardless of the patient's state of consciousness, and are therefore often traumatizing for conscious patients with well-tolerated VT (20,21). The incidence of appropriate therapies in patients suffering from refractory VT (such as patients for whom SABR is being considered) can reach considerable proportions, with several therapies delivered per week or even per day (22,23). The fear of ICD shocks often has profound social and psychological impact on these patients, from dramatically reduced activities of daily living to severe anxiety and depressive syndromes (24–27).

VT catheter ablation

Despite having a good effectiveness for VAs termination, ICDs do not have any impact on preventing recurrences, as opposed to VT catheter ablation, which aims to eliminate the arrhythmogenic substrate(28). VTs in structural heart disease are mediated by an underlying myocardial substrate that allows the initiation and maintenance of the arrhythmia. Such tissue with abnormal electrical conduction is a result of the electrophysiological remodelling related to post-myocardial infarction or post-inflammatory scars. VT catheter ablation procedure consists in the introduction into the heart cavities of electrophysiology catheters equipped with electrodes and able to record electrical signals(29). These catheters can record voltage data (electrical signal amplitude) of the myocardium, allowing the electrophysiologist to differentiate areas of healthy tissue from totally electrically silent ones (dense scare), and from low voltages zones corresponding to pathological but viable tissue *(Figure 2, Panel A)*(30,31). These intermediate zones of slow electrical conduction are often the cornerstone substrate for VT re-entry circuit genesis(31–33). During the intervention, it is also possible to trigger VT in order to identify its precise circuit. This technique, called "VT activation mapping", is a reference technique for treating a hemodynamically well tolerated VT (*Figure 2, Panel B*). However, this mapping technique is not feasible when the patient presents nonsustained VTs or VTs with poor haemodynamic tolerance(34).

Causes of catheter ablation failure

Once the tachycardia circuit or substrate is defined, an ablation catheter can be used to deliver radiofrequency (RF) energy to the critical areas of the VT circuit. VT catheter ablation has considerably improved the prognosis of heart disease as well as patients' quality of life, especially those with an ICD. However, the procedure failure rate remains high, about 50% over 12 to 24 months, even in experienced centres(35,36). Main reasons include the existence of multiple VT circuits and/or inaccessible localization of VT critical areas(37,38). In fact, if the target zone is located too deeply inside the myocardial tissue (for example in the inter-ventricular septum), the creation of a transmural lesion can be difficult or even impossible *(Figure 3)*(39,40). Many innovations are underway to optimize ablation technologies such as needle-tip catheters to penetrate more deeply into the myocardium(41), bipolar ablation(42) or arterial alcoholization(43), but their effectiveness are limited. Accordingly, some patients remain in a therapeutic impasse after failure of antiarrhythmic drugs and conventional ablation procedures.

Accepted manuscript

Rationale for cardiac use of stereotactic radiation therapy

Prognosis of patients referred for cardiac SABR

Management of refractory VTs is a major issue for patients implanted with ICD and for whom antiarrhythmic drugs and catheter ablation procedures have failed to treat the myocardial substrate. In radiation oncology, the historical approach consisting in delivering low doses radiation over a large number of sessions has seen the more recent emergence of stereotactic radiosurgery and stereotactic ablative radiotherapy(44,45). Stereotactic radiation is also used in non-malignant pathologies such as treatment of arteriovenous malformation, epilepsy or trigeminal neuralgia(46,47). The main obstacle to the use of radiation therapy especially SABR in non-malignant diseases is the fear of side effects in patients with better long-term prognosis, and for whom benefit/risk ratio of stochastic effects appears unfavourable. On the other side, the prognosis of patients with advanced heart failure and persistent systolic dysfunction is estimated around 50% at 5 years, making heart failure of worse prognosis than many tumour pathologies in current practice(48). In addition, the occurrence of VAs significantly impacts patients' prognosis, with, for example, a 17-time increased risk of death after an electrical storm, often constituting a turning point in the disease(49). Recent meta-analyses have demonstrated that patients with ablation failure and refractory VTs had an extremely poor prognosis with more than 40% of death at 6 months (50). In this context, cardiac SABR has been envisaged as an alternative strategy to eliminate the myocardial substrate at the origin of VAs.

Non-invasive last-line therapy

A major strength of cardiac SABR is the ability to create transmural lesions in any cardiac region, including regions where RF lesions effectiveness is limited. Validating this technique as an alternative to conventional VT catheter-based ablation could constitute a highly promising solution for this subset of patients without any other therapeutic possibilities. Cardiac SABR also has the significant advantage of being a non-invasive approach while VT catheter ablation remains a risky procedure. The acute complication rate of VT catheter ablation is around 12%, notably vascular (false aneurysms ...), cardiac (tamponade ...) and with a significant in-hospital mortality (1.6%)(51). Conversely, cardiac radioablation has the advantage to be painless and do not require sedation, in a category of patients for whom general anaesthesia remains risky(52). In addition to patients with unsuccessful catheter ablation procedures, cardiac SABR also appears to be a promising alternative for elderly patients and/or those in poor general condition for whom a catheter ablation procedure is not suitable or contraindicated.

Cardiac radiation therapy in animal model

Determination of the optimal dose

Numerous pre-clinical studies have attempted to validate SABR for cardiac arrhythmias this last decade. The ability to create an electrical block after irradiating the myocardium was the major issue, significantly differing from a usual oncological approach. All these pre-clinical studies have specified the dose-effect relationship that led to the dose choice of 25 Gy in a single fraction. *Sharma and al*

Accepted manuscript

first described the feasibility of cardiac structure ablation using ionizing radiation(53). In animal models, they demonstrated the possibility of creating an atrio-ventricular electrical block after stereotactic radiation of atrio-ventricular nodes with the CyberKnife robotic radiosurgery system. The dose ranging from 25 to 50 Gy showed that a single fraction of 25 Gy appeared to be the effective dose to have an electrophysiologic effect while minimizing the risk of complications and collateral damages. In pulmonary veins, *Zei and al* also demonstrated that the desired ablation effect was obtained for doses ranging from 25 to 35 Gy(54). Histological analyses of tissues confirmed the creation of transmural necrosis lesions in the majority of cases, without lesions of tissue architecture in surrounding organs (oesophagus, stomach, trachea, lungs...).

Characteristics of radioablation lesions

Contrary to RF lesions, the electrophysiological effect of radioablation lesions was not found to be acute even at high doses. With a radiation dose of 25 Gy, the average time in *Sharma and al.* before obtaining an atrio-ventricular block was 30 to 35 days(53). This delay was equally reproducible in other pre-clinical studies and was dose-dependent: the higher the dose, the shorter the time to ablation effect(54,55). This delay in efficacy is explained by the complex cellular and tissue effect created by a single high dose of radiation(56). Several mechanisms have been evidenced such as significant cytotoxicity on vascular endothelial cells, oxidative cell injuries, myocytes architecture alteration and modulation of the inflammatory response leading to a progressive tissue fibrosis(57,58). These time-delayed effects explain the clinical blanking period (a blind period without counting the arrhythmias recorded by the ICD) of 4 to 6 weeks after treatment used in the clinical studies described below. This delay seems to be the necessary period for appearance of the complete radioablation effect and during which rhythmic events can still occur without prejudging the effectiveness or failure of the treatment(53,56).

Cardiological definition of the target

From electrical information

Target volume definition can be considered as one of the most critical steps in the cardiac SABR process (Figure 4). Cardiologists knows from 12-leads electrocardiogram data and mainly from previously available catheter ablation, the most likely location of the arrhythmogenic substrate(59). When available, activation map data from the VT (Figure 2, Panel B) can be used to accurately localise critical areas involved in the tachycardia circuit. Voltage data are also useful for defining the electrophysiological substrate and identify all pathological areas that are potential sources for future arrhythmias. Figure 4 (Panel A) illustrates a left ventricular voltage map. Areas bordering dense necrosis/fibrosis are important to include in the cardiological target volume to eliminate intermediate zones of slow electrical conduction constituting the cornerstone substrate for VTs re-entry circuit. The elimination of all pathological areas with local abnormal electrical signals (black dots in Figure 4, Panel A) is also an important element to take into account for the definition of the cardiological target. This strategy is associated with improved mid- and long-term arrhythmia-free survival in catheter ablation(60,61).

Accepted manuscript

From imaging information

The extension of myocardial substrate can be determinate using information from cardiac computed tomography (CT), magnetic resonance imaging (MRI) or single photon emission computed tomography (SPECT). Cardiac CT-scan can highlight the arrhythmogenic substrate by enhancing dense scar zones and specifying myocardium thickness(62,63). Cardiac-MRI remains a reference imaging to define myocardial fibrosis, notably to precise its localization within the endocardium or epicardium(64). Late gadolinium enhancement is a validated surrogate marker of dense fibrosis. It can delimitate the heterogeneous tissue inside a scar region, that could support a VT re-entrant circuit (*Figure 5*) (65). SPECT and PET-scanner, by revealing myocardial viability zones, can also be useful to differentiate dense scars from surviving areas of myocardial tissue surrounded by fibrous tissue, representing favourable conditions for the development of VT circuits (66). Currently, there are insufficient data to determine whether one imaging technique is superior to the others in identifying the arrhythmogenic substrate extension. At the moment, a combination of all of these informations appears as the best compromise. The cardiological definition of the target volume can therefore be very different from one case to another, by merging electrical data, imaging data, but also clinical data on a case-by-case basis related to the specificities of each patient.

Stereotactic radiation therapy efficacy

In 2013*, Loo and al* reported the first in-human cardiac stereotactic ablation, in a 71-year-old patient hospitalized for refractory VT and contraindicated for catheter ablation (67). An irradiation of 25 Gy was carried out on the scar region (determined by CT imaging), using a CyberKnife system. A temporary pacing wire was fluoroscopically placed in the right ventricle apex as an imaging fiducial marker that could be dynamically tracked to compensate for respiratory motion. The decrease in rhythmic events was considerable with 562 treated VT during the 2 months before the radiation therapy to 52 VT during 7 months after treatment. In 2017, *Cuculich and al.* presented the first cohort of stereotactic VT radioablation (68). Five patients with ischemic and non-ischemic heart disease were treated using a linear accelerator (Varian TrueBeam). A 25 Gy therapy was delivered in a single fraction, in ablation volumes from 17 to 81 cc. A total of 6577 episodes of VT were recorded in 3 months before treatment for the five patients included, compared to 4 VT episodes over the one-year follow-up after treatment (corresponding to a 99% reduction in events from baseline). *Robinson and al* published in 2019 a prospective phase I/II trial(69). Nineteen patients were included and treated with a linear accelerator (Varian TrueBeam and Varian Edge). The 25 Gy dose was delivered on an average planning target volume (PTV) of 98 cc, (from 60 to 298 cc). During the 6 months before treatment 117 VT episodes were recorded versus 3 episodes after treatment (a 94% events reduction). 1 patient presented a paradoxical increase of VT episodes after radioablation. A significant improvement in quality of life was also found using the SF-36 questionnaire. In 2019, *Lloyd and al* published a series of 10 patients treated with a linear accelerator (70). Patients received a single 25 Gy dose, with PTV ranging from 37 to 238 cc. Among the 8 patients with available ICD data, the total reduction in seconds of detected VT was 69% and the reduction in total ICD shocks after treatment was 68%. In 2019, *Neuwirth et al* published their series with the CyberKnife. 10 patients were treated with a mean PTV of 22.2 cc (71). During a median follow-up of 28 months, VT burden was reduced by 87.5% compared with baseline and three patients suffered non-arrhythmic deaths. After the blanking period, VT recurred in 8 of 10 patients.

Accepted manuscript

The mean time to first ATP and shock were 6.5 and 21 months, respectively. Recently, *Gianni and al* published their series of 5 patients using the Cyberknife system, with a mean PTV of 143 cc (72). Four out of five patients had their VT burden reduced within 6 months after treatment. However, despite the initial reduction observed, the 1-year follow-up reports a recurrence of VAs in all patients, and two patients died of complications associated with their advanced heart failure. Characteristics of the main cohorts of cardiac SABR are described in *table 1*.

Stereotactic radiation therapy safety

Extra-cardiac side effects

Side effects possibly related to the delivery of an unfractionated dose of 25 Gy on cardiac structures remain mostly unknown. Classical non-serious side effects were observed in the case series described above, such as dizziness, nausea, vomiting, hypotension or asthenia. In extra-cardiac structures, several cases of inflammatory reactive pneumopathy have been described(68–70). These lesions of lung parenchyma adjacent to the treated areas seem to correspond to traditional radiotherapy lesions observed during treatment of pulmonary and mediastinal tumours. According to the authors, these clinically asymptomatic pneumonitis disappeared on control CT at one month. During the follow-up of ENCORE-V study, one patient died from a major stroke (68). This patient was described as having a high embolic risk atrial fibrillation with a contraindication to anticoagulants. In light of this outcomes, patients in the following study of the same group, ENCORE-VT trial, received curative anticoagulation for one month after the radiation therapy(69).

Cardiac side effects

Regarding ICD devices, no treatment-related adverse events on the generator or leads were reported. Similarly, no adverse events were reported for coronary arteries. In the different cohorts, patients' follow-up has never shown any significant impact of radioablation on the left ventricular ejection fraction measured by transthoracic echography. *Neuwirth and al.* noted a case of increase in a mitral regurgitation grad possibly related to the treatment (71). Finally, pericardial effusions were one of the most important treatment-related cardiac adverse events. In the ENCORE-VT trial, 6 pericardial effusions were recorded. 4 were classified as non-severe, resolved with medical management (corticotherapy treatment) and 2 were classified as higher grade. However, no pericardial effusion was reported in other case series. As most of these cohorts are recent, caution should be taken about the possibility of additional long-term side effects occurrence. In fact, we have to wait for a longer follow-up to discover potential long-term effects of high radiation dose on structures such as coronary arteries or heart valves.

Discussion

The considerable deterioration in quality of life and the poor short/medium-term prognosis of patients with refractory VTs in therapeutic impasse has led to the use of a more radical ablation therapy than

Accepted manuscript

our existing treatments. From the pioneer works on the subject to the numerous and increasing case series, radiation therapy tends to confirm its effectiveness in the treatment of refractory VTs. Additional multicentre clinical studies will be required to confirm these preliminary results in larger prospective series, and to precise the long-term results. One of the major challenges will be to quantify whether or not the safety of the technique is as high as the clinical benefit expected. In the absence of long-term efficacy data, it is not known whether the electrophysiological effect remain valuable over time. For patients with VAs recurrences after SABR, it will be important to determine whether these recurrences correspond to the initial targeted arrhythmia (unsuccessful treatment) or to others arrhythmia circuits possibly related to the creation of a new substrate by the radioablation or by the heart disease progression. Another obstacle to the safe and consistent use of cardiac SABR appears to be the target definition stage. The current approach is a case-by-case strategy (including electrophysiological data, imaging information, clinical characteristics...) and, in addition to the final uncertainty related to the therapy delivery, there is already an initial uncertainty related to the definition and delineation of the optimal cardiological target.

Future directions

There is still a lot to learn about how to integrate scar and electrical data in a consistent and reproducible way to standardise the cardiac SABR process. On the other hand, data are still insufficient to show the superiority of one radiotherapy device over another in this indication, to highlight irradiation thresholds for surrounding organs and cardiac structures or to determine differences in outcomes according to the type of cardiomyopathy being treated. Likely, these questions will be gradually answered over the time. Meanwhile, new approaches for guiding or delivering the therapy are also being developed, such as MRI-guided cardiac SABR or proton beam therapy (73,74). The use of cardiac SABR to treat arrhythmias originating from the atria is also being studied (75,76). However, in our opinion, although these works are interesting, the current risk-benefit ratio of the technique is unfavourable for treating diseases such as atrial fibrillation where the expected benefit is merely symptomatic.

Conclusion:

Cardiac SABR for refractory VTs appears as an alternative ablation strategy with an acceptable safety profile for a category of patients with poor prognosis and extremely impaired quality of life. Multicentre prospective studies are still needed to validate these preliminary encouraging results. So far, this emerging treatment is still limited to a palliative role, as a last line solution for patients with no other therapeutic alternative. This technique historically brings together two fields of expertise unknown to each other, pointing out the necessity of an optimal partnership between cardiologists and radiation oncologists to successfully carry out the treatment. The understanding of cardiological aspects of the process for radiation oncologists and treatment technical aspects comprehension for cardiologists represent the key element for an optimal application and the development of this promising treatment.

Accepted manuscript

References

1. Khurshid S, Choi SH, Weng L-C, Wang EY, Trinquart L, Benjamin EJ, et al. Frequency of Cardiac Rhythm Abnormalities in a Half Million Adults. Circ Arrhythm Electrophysiol [Internet]. juill 2018 [cité 14 mai 2021];11(7). Disponible sur: https://www.ahajournals.org/doi/10.1161/CIRCEP.118.006273

2. Lo R, Chia KKM, Hsia HH. Ventricular Tachycardia in Ischemic Heart Disease. Card Electrophysiol Clin. mars 2017;9(1):25-46.

3. Alvarez CK, Cronin E, Baker WL, Kluger J. Heart failure as a substrate and trigger for ventricular tachycardia. J Interv Card Electrophysiol. déc 2019;56(3):229-47.

4. Liuba I, Marchlinski FE. The Substrate and Ablation of Ventricular Tachycardia in Patients With Nonischemic Cardiomyopathy. Circ J. 2013;77(8):1957-66.

5. Chugh SS, Reinier K, Teodorescu C, Evanado A, Kehr E, Al Samara M, et al. Epidemiology of Sudden Cardiac Death: Clinical and Research Implications. Prog Cardiovasc Dis. nov 2008;51(3):213-28.

6. Exner DV, Pinski SL, Wyse DG, Renfroe EG, Follmann D, Gold M, et al. Electrical Storm Presages Nonsudden Death: The Antiarrhythmics Versus Implantable Defibrillators (AVID) Trial. Circulation. 24 avr 2001;103(16):2066-71.

7. Roberts-Thomson KC, Lau DH, Sanders P. The diagnosis and management of ventricular arrhythmias. Nat Rev Cardiol. juin 2011;8(6):311-21.

8. Guandalini GS, Liang JJ, Marchlinski FE. Ventricular Tachycardia Ablation. JACC Clin Electrophysiol. déc 2019;5(12):1363-83.

9. Sapp JL, Wells GA, Parkash R, Stevenson WG, Blier L, Sarrazin J-F, et al. Ventricular Tachycardia Ablation versus Escalation of Antiarrhythmic Drugs. N Engl J Med. 14 juill 2016;375(2):111-21.

10. Shirai Y, Liang JJ, Santangeli P, Arkles JS, Schaller RD, Supple GE, et al. Long-term outcome and mode of recurrence following noninducibility during noninvasive programmed stimulation after ventricular tachycardia ablation. Pacing Clin Electrophysiol. mars 2019;42(3):333-40.

11. Vergara P, Tzou WS, Tung R, Brombin C, Nonis A, Vaseghi M, et al. Predictive Score for Identifying Survival and Recurrence Risk Profiles in Patients Undergoing Ventricular Tachycardia Ablation: The I-VT Score. Circ Arrhythm Electrophysiol [Internet]. déc 2018 [cité 14 mai 2021];11(12). Disponible sur: https://www.ahajournals.org/doi/10.1161/CIRCEP.118.006730

12. Tang PT, Shenasa M, Boyle NG. Ventricular Arrhythmias and Sudden Cardiac Death. Card Electrophysiol Clin. déc 2017;9(4):693-708.

13. Priori SG, Blomström-Lundqvist C, Mazzanti A, Blom N, Borggrefe M, Camm J, et al. 2015 ESC Guidelines for the management of patients with ventricular arrhythmias and the prevention of

Accepted manuscript

sudden cardiac death: The Task Force for the Management of Patients with Ventricular Arrhythmias and the Prevention of Sudden Cardiac Death of the European Society of Cardiology (ESC)Endorsed by: Association for European Paediatric and Congenital Cardiology (AEPC). Eur Heart J. 1 nov 2015;36(41):2793-867.

14. Kuck K-H, Cappato R, Siebels J, Rüppel R. Randomized Comparison of Antiarrhythmic Drug Therapy With Implantable Defibrillators in Patients Resuscitated From Cardiac Arrest: The Cardiac Arrest Study Hamburg (CASH). Circulation. 15 août 2000;102(7):748-54.

15. Moss AJ, Zareba W, Hall WJ, Klein H, Wilber DJ, Cannom DS, et al. Prophylactic Implantation of a Defibrillator in Patients with Myocardial Infarction and Reduced Ejection Fraction. N Engl J Med. 21 mars 2002;346(12):877-83.

16. Al-Khatib SM, Stevenson WG, Ackerman MJ, Bryant WJ, Callans DJ, Curtis AB, et al. 2017 AHA/ACC/HRS Guideline for Management of Patients With Ventricular Arrhythmias and the Prevention of Sudden Cardiac Death. J Am Coll Cardiol. oct 2018;72(14):e91-220.

17. Magyar-Russell G, Thombs BD, Cai JX, Baveja T, Kuhl EA, Singh PP, et al. The prevalence of anxiety and depression in adults with implantable cardioverter defibrillators: A systematic review. J Psychosom Res. oct 2011;71(4):223-31.

18. Groeneveld PW, Matta MA, Suh JJ, Heidenreich PA, Shea JA. Costs and Quality-of-Life Effects of Implantable Cardioverter-Defibrillators. Am J Cardiol. nov 2006;98(10):1409-15.

19. Timal RJ, de Gucht V, Rotmans JI, Hensen LCR, Buiten MS, de Bie MK, et al. The impact of transvenous cardioverter-defibrillator implantation on quality of life, depression and optimism in dialysis patients: report on the secondary outcome of QOL in the randomized controlled ICD2 trial. Qual Life Res [Internet]. 19 févr 2021 [cité 14 mai 2021]; Disponible sur: http://link.springer.com/10.1007/s11136-020-02744-7

20. Kou WH. Incidence of Loss of Consciousness during Automatic Implantable Cardioverter-Defibrillator Shocks. Ann Intern Med. 15 déc 1991;115(12):942.

21. Merchant FM, Hoskins MH, Benser ME, Roberts G, Bastek AN, Knezevic A, et al. Time Course of Subsequent Shocks After Initial Implantable Cardioverter-Defibrillator Discharge and Implications for Driving Restrictions. JAMA Cardiol. 1 mai 2016;1(2):181.

22. Borne RT, Varosy PD, Masoudi FA. Implantable Cardioverter-Defibrillator Shocks: Epidemiology, Outcomes, and Therapeutic Approaches. JAMA Intern Med. 27 mai 2013;173(10):859.

23. Sagone A. Electrical Storm: Incidence, Prognosis and Therapy. J Atr Fibrillation. déc 2015;8(4):1150.

24. Herrmann C, Muhen F, Schaumann A, Buss U, Kemper S, Wantzen C, et al. Standardized Assessment of Psychological Well-Being and Quality-of-Life in Patients with Implanted Defibrillators. Pacing Clin Electrophysiol. janv 1997;20(1):95-103.

25. Bostwick JM, Sola CL. An Updated Review of Implantable Cardioverter/Defibrillators, Induced Anxiety, and Quality of Life. Psychiatr Clin North Am. déc 2007;30(4):677-88.

26. Ofman P, Hoffmeister P, Kaloupek DG, Gagnon DR, Peralta A, Djousse L, et al. Posttraumatic stress disorder and mortality in VA patients with implantable cardioverter-defibrillators. Clin Cardiol. mai 2018;41(5):652-9.

Accepted manuscript

27. Cho E-YN, von Känel R, Marten-Mittag B, Ronel J, Kolb C, Baumert J, et al. Determinants and trajectory of phobic anxiety in patients living with an implantable cardioverter defibrillator. Heart. 15 mai 2012;98(10):806-12.

28. AbdelWahab A, Sapp J. Ventricular Tachycardia with ICD Shocks: When to Medicate and When to Ablate. Curr Cardiol Rep. nov 2017;19(11):105.

29. Stevenson WG, Soejima K. Catheter Ablation for Ventricular Tachycardia. Circulation. 29 mai 2007;115(21):2750-60.

30. Tung R. Substrate Mapping in Ventricular Arrhythmias. Card Electrophysiol Clin. déc 2019;11(4):657-63.

31. de Baker JMT, Coronel R, Tasseron S, Wilde AAM, Opthof T, Janse MJ, et al. Ventricular tachyrdia in the infarcted, Langendorff-perfused human heart: Role of the arrangement of surviving cardiac fibers. J Am Coll Cardiol. juin 1990;15(7):1594-607.

32. de Bakker JM, van Capelle FJ, Janse MJ, Wilde AA, Coronel R, Becker AE, et al. Reentry as a cause of ventricular tachycardia in patients with chronic ischemic heart disease: electrophysiologic and anatomic correlation. Circulation. mars 1988;77(3):589-606.

33. Segal OR, Chow AWC, Peters NS, Davies DW. Mechanisms that initiate ventricular tachycardia in the infarcted human heart. Heart Rhythm. janv 2010;7(1):57-64.

34. Pandozi C, Lavalle C, Russo M, Galeazzi M, Ficili S, Malacrida M, et al. Mapping of ventricular tachycardia in patients with ischemic cardiomyopathy: Current approaches and future perspectives. Clin Cardiol. oct 2019;42(10):1041-50.

35. Stevenson WG, Wilber DJ, Natale A, Jackman WM, Marchlinski FE, Talbert T, et al. Irrigated Radiofrequency Catheter Ablation Guided by Electroanatomic Mapping for Recurrent Ventricular Tachycardia After Myocardial Infarction: The Multicenter Thermocool Ventricular Tachycardia Ablation Trial. Circulation. 16 déc 2008;118(25):2773-82.

36. Tanner H, Hindricks G, Volkmer M, Furniss S, Kühlkamp V, Lacroix D, et al. Catheter Ablation of Recurrent Scar-Related Ventricular Tachycardia Using Electroanatomical Mapping and Irrigated Ablation Technology: Results of the Prospective Multicenter Euro-VT-Study. J Cardiovasc Electrophysiol. janv 2010;21(1):47-53.

37. Tokuda M, Kojodjojo P, Tung S, Tedrow UB, Nof E, Inada K, et al. Acute Failure of Catheter Ablation for Ventricular Tachycardia Due to Structural Heart Disease: Causes and Significance. J Am Heart Assoc [Internet]. 20 mai 2013 [cité 14 mai 2021];2(3). Disponible sur: https://www.ahajournals.org/doi/10.1161/JAHA.113.000072

38. Liang JJ, Khurshid S, Schaller RD, Santangeli P, Marchlinski FE, Frankel DS. Safety and Efficacy of Catheter Ablation for Ventricular Tachycardia in Elderly Patients With Structural Heart Disease. JACC Clin Electrophysiol. mars 2015;1(1-2):52-8.

39. Neira V, Santangeli P, Futyma P, Sapp J, Valderrabano M, Garcia F, et al. Ablation strategies for intramural ventricular arrhythmias. Heart Rhythm. juill 2020;17(7):1176-84.

40. Yang J, Liang J, Shirai Y, Muser D, Garcia FC, Callans DJ, et al. Outcomes of simultaneous unipolar radiofrequency catheter ablation for intramural septal ventricular tachycardia in nonischemic cardiomyopathy. Heart Rhythm. juin 2019;16(6):863-70.

Accepted manuscript

41. Sapp JL, Beeckler C, Pike R, Parkash R, Gray CJ, Zeppenfeld K, et al. Initial Human Feasibility of Infusion Needle Catheter Ablation for Refractory Ventricular Tachycardia. Circulation. 19 nov 2013;128(21):2289-95.

42. Nguyen DT, Tzou WS, Brunnquell M, Zipse M, Schuller JL, Zheng L, et al. Clinical and biophysical evaluation of variable bipolar configurations during radiofrequency ablation for treatment of ventricular arrhythmias. Heart Rhythm. nov 2016;13(11):2161-71.

43. Sacher F, Sobieszczyk P, Tedrow U, Eisenhauer AC, Field ME, Selwyn A, et al. Transcoronary ethanol ventricular tachycardia ablation in the modern electrophysiology era. Heart Rhythm. janv 2008;5(1):62-8.

44. Song CW, Lee Y-J, Griffin RJ, Park I, Koonce NA, Hui S, et al. Indirect Tumor Cell Death After High-Dose Hypofractionated Irradiation: Implications for Stereotactic Body Radiation Therapy and Stereotactic Radiation Surgery. Int J Radiat Oncol. sept 2015;93(1):166-72.

45. Connell PP, Hellman S. Advances in Radiotherapy and Implications for the Next Century: A Historical Perspective. Cancer Res. 15 janv 2009;69(2):383-92.

46. Nugent GR, Berry B. Trigeminal neuralgia treated by differential percutaneous radiofrequency coagulation of the Gasserian ganglion. J Neurosurg. avr 1974;40(4):517-23.

47. Oermann EK, Murthy N, Chen V, Baimeedi A, Sasaki-Adams D, McGrail K, et al. A Multicenter Retrospective Study of Frameless Robotic Radiosurgery for Intracranial Arteriovenous Malformation. Front Oncol [Internet]. 4 nov 2014 [cité 10 mai 2021];4. Disponible sur: http://journal.frontiersin.org/article/10.3389/fonc.2014.00298/abstract

48. Stewart S, MacIntyre K, Hole DJ, Capewell S, McMurray JJV. More 'malignant' than cancer? Five-year survival following a first admission for heart failure. Eur J Heart Fail. juin 2001;3(3):315-22.

49. Sesselberg HW, Moss AJ, McNitt S, Zareba W, Daubert JP, Andrews ML, et al. Ventricular arrhythmia storms in postinfarction patients with implantable defibrillators for primary prevention indications: A MADIT-II substudy. Heart Rhythm. nov 2007;4(11):1395-402.

50. Carbucicchio C, Santamaria M, Trevisi N, Maccabelli G, Giraldi F, Fassini G, et al. Catheter ablation for the treatment of electrical storm in patients with implantable cardioverter-defibrillators: short- and long-term outcomes in a prospective single-center study. Circulation. 29 janv 2008;117(4):462-9.

51. Palaniswamy C, Kolte D, Harikrishnan P, Khera S, Aronow WS, Mujib M, et al. Catheter ablation of postinfarction ventricular tachycardia: Ten-year trends in utilization, in-hospital complications, and in-hospital mortality in the United States. Heart Rhythm. nov 2014;11(11):2056-63.

52. Killu AM, Sugrue A, Munger TM, Hodge DO, Mulpuru SK, McLeod CJ, et al. Impact of sedation vs. general anaesthesia on percutaneous epicardial access safety and procedural outcomes. EP Eur. 1 févr 2018;20(2):329-36.

53. Sharma A, Wong D, Weidlich G, Fogarty T, Jack A, Sumanaweera T, et al. Noninvasive stereotactic radiosurgery (CyberHeart) for creation of ablation lesions in the atrium. Heart Rhythm. juin 2010;7(6):802-10.

Accepted manuscript

54. Zei PC, Soltys S. Ablative Radiotherapy as a Noninvasive Alternative to Catheter Ablation for Cardiac Arrhythmias. Curr Cardiol Rep. sept 2017;19(9):79.

55. Lehmann HI, Graeff C, Simoniello P, Constantinescu A, Takami M, Lugenbiel P, et al. Feasibility Study on Cardiac Arrhythmia Ablation Using High-Energy Heavy Ion Beams. Sci Rep. déc 2016;6(1):38895.

56. Song CW, Glatstein E, Marks LB, Emami B, Grimm J, Sperduto PW, et al. Biological Principles of Stereotactic Body Radiation Therapy (SBRT) and Stereotactic Radiation Surgery (SRS): Indirect Cell Death. Int J Radiat Oncol. mai 2021;110(1):21-34.

57. Park HJ, Griffin RJ, Hui S, Levitt SH, Song CW. Radiation-Induced Vascular Damage in Tumors: Implications of Vascular Damage in Ablative Hypofractionated Radiotherapy (SBRT and SRS). Radiat Res. mars 2012;177(3):311-27.

58. Song CW, Lee Y-J, Griffin RJ, Park I, Koonce NA, Hui S, et al. Indirect Tumor Cell Death After High-Dose Hypofractionated Irradiation: Implications for Stereotactic Body Radiation Therapy and Stereotactic Radiation Surgery. Int J Radiat Oncol. sept 2015;93(1):166-72.

59. Kuo L, Liang JJ, Nazarian S, Marchlinski FE. Multimodality Imaging to Guide Ventricular Tachycardia Ablation in Patients with Non-ischaemic Cardiomyopathy. Arrhythmia Electrophysiol Rev. 11 févr 2020;8(4):255-64.

60. Jaïs P, Maury P, Khairy P, Sacher F, Nault I, Komatsu Y, et al. Elimination of Local Abnormal Ventricular Activities: A New End Point for Substrate Modification in Patients With Scar-Related Ventricular Tachycardia. Circulation. 8 mai 2012;125(18):2184-96.

61. Sacher F, Lim HS, Derval N, Denis A, Berte B, Yamashita S, et al. Substrate Mapping and Ablation for Ventricular Tachycardia: The LAVA Approach: Substrate Mapping and Ablation. J Cardiovasc Electrophysiol. avr 2015;26(4):464-71.

62. Esposito A, Palmisano A, Antunes S, Maccabelli G, Colantoni C, Rancoita PMV, et al. Cardiac CT With Delayed Enhancement in the Characterization of Ventricular Tachycardia Structural Substrate. JACC Cardiovasc Imaging. juill 2016;9(7):822-32.

63. Piers SRD, van Huls van Taxis CFB, Tao Q, van der Geest RJ, Askar SF, Siebelink H-MJ, et al. Epicardial substrate mapping for ventricular tachycardia ablation in patients with non-ischaemic cardiomyopathy: a new algorithm to differentiate between scar and viable myocardium developed by simultaneous integration of computed tomography and contrast-enhanced magnetic resonance imaging. Eur Heart J. 21 févr 2013;34(8):586-96.

64. Cochet H, Komatsu Y, Sacher F, Jadidi AS, Scherr D, Riffaud M, et al. Integration of Merged Delayed-Enhanced Magnetic Resonance Imaging and Multidetector Computed Tomography for the Guidance of Ventricular Tachycardia Ablation: A Pilot Study. J Cardiovasc Electrophysiol. avr 2013;24(4):419-26.

65. Perez-David E, Arenal Á, Rubio-Guivernau JL, del Castillo R, Atea L, Arbelo E, et al. Noninvasive Identification of Ventricular Tachycardia-Related Conducting Channels Using Contrast-Enhanced Magnetic Resonance Imaging in Patients With Chronic Myocardial Infarction. J Am Coll Cardiol. janv 2011;57(2):184-94.

66. Fahmy TS, Wazni OM, Jaber WA, Walimbe V, Di Biase L, Elayi CS, et al. Integration of positron emission tomography/computed tomography with electroanatomical mapping: A novel

Accepted manuscript

approach for ablation of scar-related ventricular tachycardia. Heart Rhythm. nov 2008;5(11):1538-45.

67. Loo BW, Soltys SG, Wang L, Lo A, Fahimian BP, Iagaru A, et al. Stereotactic ablative radiotherapy for the treatment of refractory cardiac ventricular arrhythmia. Circ Arrhythm Electrophysiol. juin 2015;8(3):748-50.

68. Cuculich PS, Schill MR, Kashani R, Mutic S, Lang A, Cooper D, et al. Noninvasive Cardiac Radiation for Ablation of Ventricular Tachycardia. N Engl J Med. 14 déc 2017;377(24):2325-36.

69. Robinson CG, Samson PP, Moore KMS, Hugo GD, Knutson N, Mutic S, et al. Phase I/II Trial of Electrophysiology-Guided Noninvasive Cardiac Radioablation for Ventricular Tachycardia. Circulation. 15 janv 2019;139(3):313-21.

70. Lloyd MS, Wight J, Schneider F, Hoskins M, Attia T, Escott C, et al. Clinical experience of stereotactic body radiation for refractory ventricular tachycardia in advanced heart failure patients. Heart Rhythm. mars 2020;17(3):415-22.

71. Neuwirth R, Cvek J, Knybel L, Jiravsky O, Molenda L, Kodaj M, et al. Stereotactic radiosurgery for ablation of ventricular tachycardia. EP Eur. 1 juill 2019;21(7):1088-95.

72. Gianni C, Rivera D, Burkhardt JD, Pollard B, Gardner E, Maguire P, et al. Stereotactic arrhythmia radioablation for refractory scar-related ventricular tachycardia. Heart Rhythm. août 2020;17(8):1241-8.

73. Kovacs B, Mayinger M, Tanadini-Lang S, Ehrbar S, Wilke L, Chamberlain M, et al. First two MRI guided stereotactic body radiation therapy of recurrent sustained ventricular tachycardia. Eur Heart J. 1 nov 2020;41(Supplement_2):ehaa946.0758.

74. Hohmann S, Deisher AJ, Konishi H, Rettmann ME, Suzuki A, Merrell KW, et al. Catheter-free ablation of infarct scar through proton beam therapy: Tissue effects in a porcine model. Heart Rhythm. déc 2020;17(12):2190-9.

75. Lydiard S, Caillet V, Ipsen S, O'Brien R, Blanck O, Poulsen PR, et al. Investigating multi-leaf collimator tracking in stereotactic arrhythmic radioablation (STAR) treatments for atrial fibrillation. Phys Med Biol. 28 sept 2018;63(19):195008.

76. Qian PC, Azpiri JR, Assad J, Gonzales Aceves EN, Cardona Ibarra CE, Pena C, et al. Noninvasive stereotactic radioablation for the treatment of atrial fibrillation: First-in-man experience. J Arrhythmia. févr 2020;36(1):67-74.

Accepted manuscript

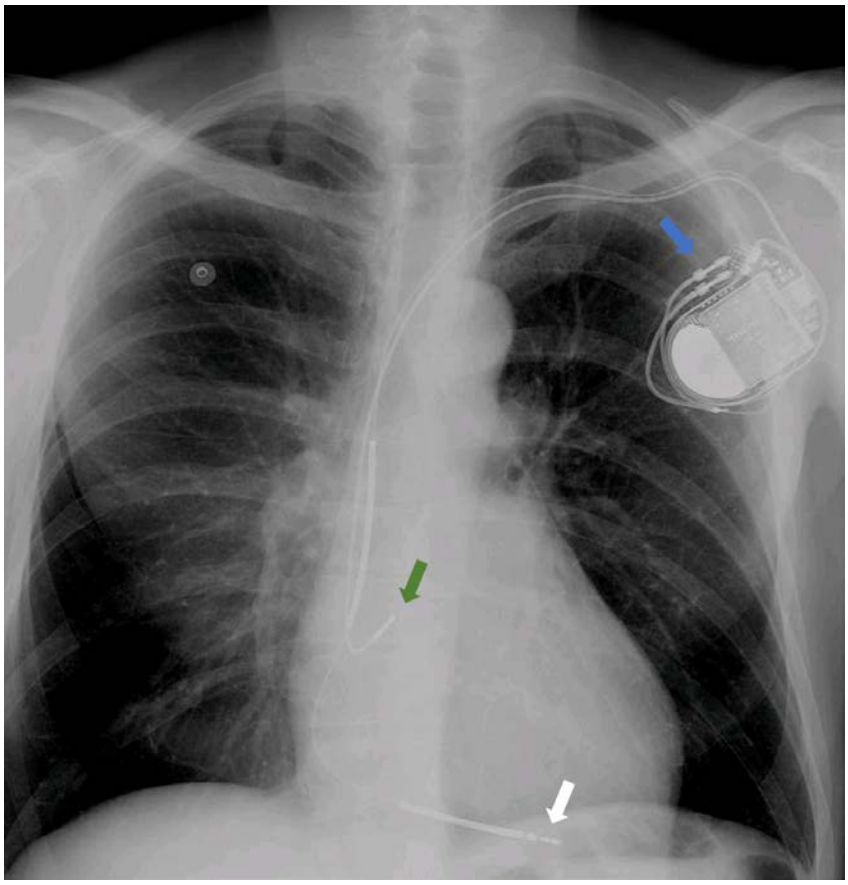

Figure 1: Frontal chest X-ray in a patient implanted with an ICD for primary prevention. *An atrial lead is implanted in the right appendage (green arrow), and a ventricular lead at the apex of the right ventricle (white arrow). The ICD generator is located in the pectoral region (blue arrow).*

Accepted manuscript

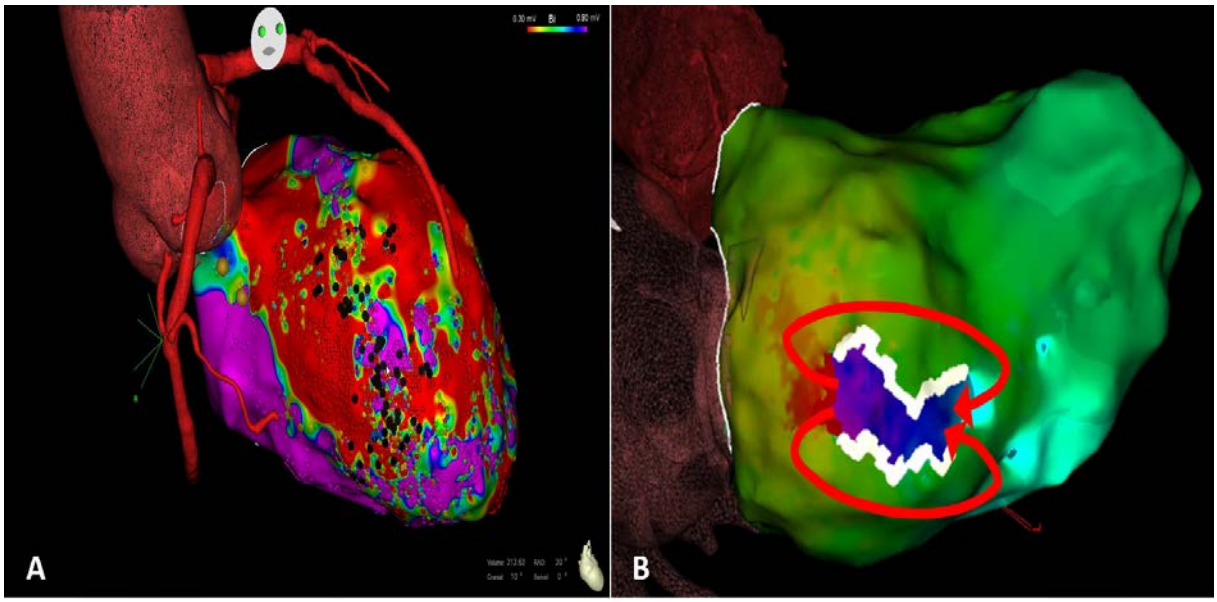

Figure 2. Catheter ablation procedure. *Panel A: Anatomical reconstruction of the left ventricle and voltage indications. In red are the low voltage areas corresponding to dead scar tissue and in purple the normal voltage areas corresponding to healthy tissue. A colour gradation between red and purple indicates the more or less healthy character of myocardium. The black dots indicate local abnormal electrical signals representing a substrate for potential sustained VAs / Panel B:* VT activation mapping. The VT circuit is colour coded, showing a re-entrant circuit (red arrows) supported by a critical area also known as the "VT isthmus" (purple area localised between the two white lines).

Accepted manuscript



Figure 3. Cross-section of a heart in a patient treated by catheter ablation for a VT originating from the interventricular septum. *(RV :right ventricle, LV :left ventricle) The red arrow illustrates the thickness of the interventricular septum. The blue arrows show the myocardial lesions created by the radiofrequency catheter. The radiofrequency lesions are not transmural and do not appear to reach the centre of the septum.*

Accepted manuscript

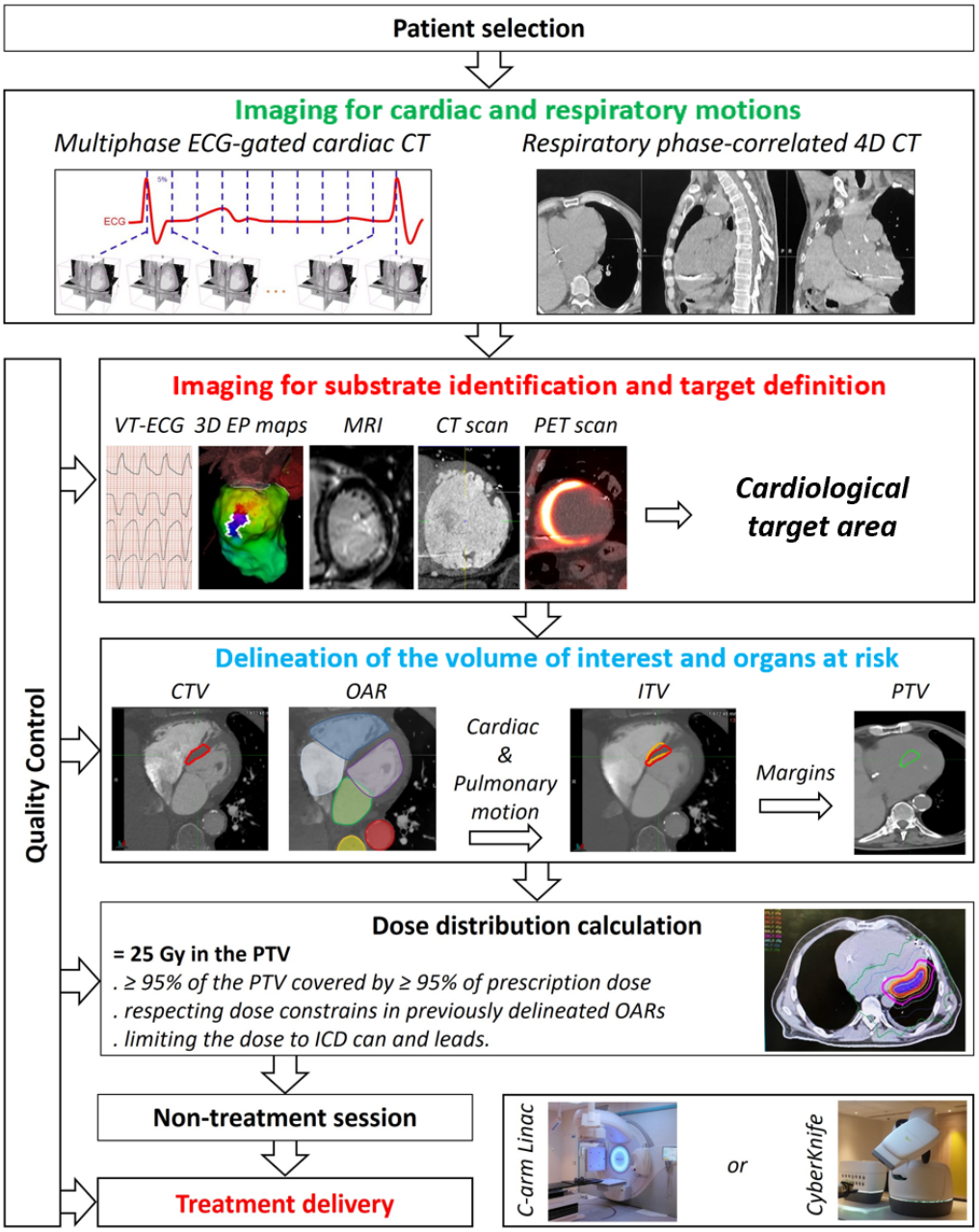

Figure 4. Schematic processing steps of cardiac SABR for refractory VTs.

Accepted manuscript

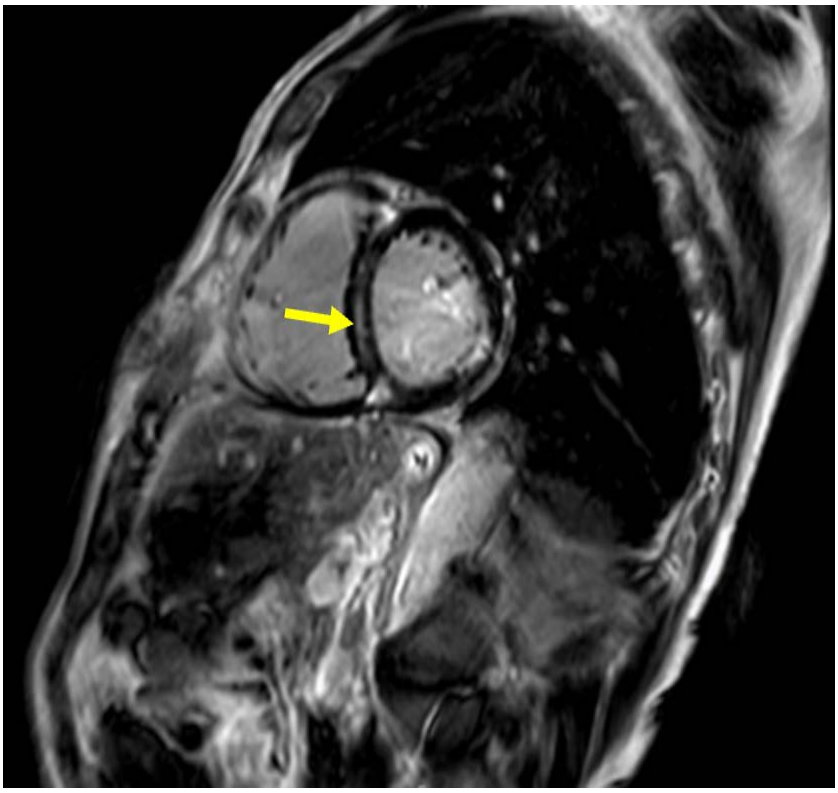

Figure 5. Cardiac MRI in a patient hospitalized for electrical storm*. The yellow arrow indicates a scar/fibrosis area revealed by late gadolinium enhancement. This substrate is located inside the interventricular septum, an an area difficult to reach with radiofrequency lesions.*

Accepted manuscript

Cohort/Study	*Cuculich et al. 2017*	*Robinson et al. 2019*	*Neuwirth et al. 2019*	*Lloyd et al. 2019*	*Gianni et al. 2020*
Patients (Sex) **Mean Age, (Mini, Maxi)**	5 (4M, 1F) 66 yo (60 to 83)	19 (17M,2F) 66 yo (49 to 81)	10 (9M,1F) 66 yo (61 to 78)	10 (7M, 3F) 61 yo (50 to 78)	5 (5M,0F) 63 yo (45 to 76)
Cardiopathy	3 Non-ischemic 2 Ischemic	8 Non-ischemic 11 Ischemic	2 Non-ischemic 8 Ischemic	6 Non-ischemic 4 Ischemic	1 Non-ischemic 4 Ischemic
Mean LVEF (%)	23% (15 to 37)	25% (15 to 58)	26,5% (25 to 35)	Non available	34% (20 to 55)
Treatment unit	Varian TrueBeam	Varian TrueBeam and Varian Edge	CyberKnife	Varian TruBeam	CyberKnife
Electrophysiologic data	Non-invasive mapping(ECG-Vest) / Prior CA if available	Non-invasive mapping (ECG-Vest) / Prior CA if available	Prior CA if available	Prior CA if available	Prior CA if available
Other Imaging modalities	SPECT, Cardiac MRI, 4D-CT	SPECT, Cardiac MRI, 4D-CT	4D and ECG-Gated CT	4D-CT	Cardiac CT, end expiration chest-CT
Dose delivery	25 Gy in a single session	25 Gy in a single session	25 Gy in a single session	25 Gy in a single session	20 to 25 Gy in a single session
Immobilization	Custom immobilization device	Immobilization with abdominal compression and body mold	Non available	Rigid immobilization	Non available
Cardio-respiratory motion management	4D-CT to assess cardiac and respiratory motions	4D-CT to assess cardiac and respiratory motions	ECG-gated CT for cardiac motion + ICD lead tracking for respiratory motions	4D-CT to assess cardiac and respiratory motions ampltiude	3mm margin to CTV for cardiac motion + Temporary pacing lead tracking for respiratory motions
PTV margin	5 mm	5mm	No additional margin for PTV	1 to 5 mm	Non available

Accepted manuscript

Mean PTV (Maxi, Mini)	49 cc (17.3 to 81)	98.9 cc (60.9 to 298,8)	22.2 cc (14.2 to 29.6)	81,4 cc (29 to 238)	143 cc (80 to 184)
Treatment mean time	14 minutes	15,3 minutes	68 minutes	<30 minutes	82 minutes
Median Follow-up	12 months	13 months	28 months	176 days	12 months

Table 1. Characteristics of main cardiac SABR cohorts for refractory VT. *CA=Catheter ablation, SPECT=single-photon emission computed tomography*

Accepted manuscript