



**HAL**  
open science

## **Sacroiliac joint in sarcoidosis on computed tomography: a monocentric retrospective study (SISTER)**

Simon Cadiou, Guillaume Coiffier, Stéphane Jouneau, Patrick Jego, Aleth Perdriger, Nicolas Belhomme, Raphaël Guillin, Pascal Guggenbuhl

### ► To cite this version:

Simon Cadiou, Guillaume Coiffier, Stéphane Jouneau, Patrick Jego, Aleth Perdriger, et al.. Sacroiliac joint in sarcoidosis on computed tomography: a monocentric retrospective study (SISTER). *Rheumatology International*, 2022, 42 (3), pp.431-440. 10.1007/s00296-021-05021-z . hal-03414250

**HAL Id: hal-03414250**

**<https://hal.science/hal-03414250v1>**

Submitted on 29 Nov 2021

**HAL** is a multi-disciplinary open access archive for the deposit and dissemination of scientific research documents, whether they are published or not. The documents may come from teaching and research institutions in France or abroad, or from public or private research centers.

L'archive ouverte pluridisciplinaire **HAL**, est destinée au dépôt et à la diffusion de documents scientifiques de niveau recherche, publiés ou non, émanant des établissements d'enseignement et de recherche français ou étrangers, des laboratoires publics ou privés.

**Title:** Sacroiliac joint in sarcoidosis on computed tomography: a monocentric retrospective study (SISTER)

**Authors:** Simon Cadiou<sup>1</sup>, Guillaume Coiffier<sup>2</sup>, Stéphane Jouneau<sup>3</sup>, Patrick Jego<sup>4</sup>, Aleth Perdriger<sup>1</sup>, Nicolas Belhomme<sup>5</sup>, Raphaël Guillin<sup>6</sup>, and Pascal Guggenbuhl<sup>1,7</sup>

<sup>1</sup> Department of Rheumatology, Rennes University Hospital, University of Rennes 1, 35000, Rennes, France

<sup>2</sup> Department of Rheumatology, Dinan Hospital, 22000 Dinan, France

<sup>3</sup> Department of Respiratory Medicine, Rennes University Hospital, Rennes, France; University of Rennes 1, Rennes, France. INSERM-IRSET UMR1085, Rennes, France

<sup>4</sup> Internal Medicine Department, Rennes University Hospital, University of Rennes 1, 35000, Rennes, France

<sup>5</sup> Internal Medicine Department, Rennes University Hospital, 35000, Rennes, France

<sup>6</sup> Department of Medical Imaging, Rennes University Hospital, 35000, Rennes, France

<sup>7</sup> Univ Rennes, INSERM, CHU Rennes, Institut NUMECAN (Nutrition Metabolisms and Cancer), UMR 1241, F-35000 Rennes, France

**Keywords:** sarcoidosis, sacroiliitis, sacroiliac joint, spondyloarthritis, computed tomography, osteoarthritis

**Highlights:**

Sacroiliitis by computed tomography is rare relative to the higher proportion of sacroiliitis found by x-ray and MRI reported in the literature.

In patients with sarcoidosis, sacroiliitis is generally associated with concomitant spondyloarthritis rather than being true sarcoidotic sacroiliitis.

Osteoarthritis of the sacroiliac-joints is more frequent with age and pregnancy and is associated with a rural lifestyle.

Osteoarthritis of the sacroiliac joints may explain overestimation of sacroiliitis in previous publications by MRI and x-ray imaging.

**Corresponding author:** Cadiou Simon, 16 Boulevard de Bulgarie 35000 Rennes, Hôpital Sud, Service de Rhumatologie. Email : [simon.cadiou@chu-rennes.fr](mailto:simon.cadiou@chu-rennes.fr); [sicadiou@gmail.com](mailto:sicadiou@gmail.com)

Phone number: (+33)02.99.26.71.40. Fax number: (+33)02.99.26.71.90

## **Abstract**

**Objectives:** Sacroiliitis and spondyloarthritis (SpA) have been associated to sarcoidosis. Sarcoidosis bone involvement of the sacral or iliac bones has been reported to mimic SpA. We aimed to evaluate the prevalence of structural sacroiliitis and structural changes of the sacroiliac joints (SIJ) in patients with sarcoidosis by abdominal-pelvic computed tomography (AP-CT).

**Methods:** In this monocentric retrospective study, three blinded readers evaluated AP-CT that had already been performed on patients with sarcoidosis and classified them as normal, degenerative, or inflammatory. A consensus was reached for the divergent cases. Erosion, ankylosis, and sclerosis, classically associated with sacroiliitis, were noted. SpA was defined according to the ASAS 2009 classification criteria.

**Results:** We identified 217 patients with proven sarcoidosis who underwent AP-CT. Only three patients had sacroiliitis by CT and four had SpA, representing 1.38% and 1.85% of the patients, respectively. Degenerative SIJs represented 28.1% of patients and were significantly associated with age, at least one pregnancy, rural lifestyle, ankylosis, diffuse idiopathic skeletal hyperostosis, sclerosis, and the presence of osteophytes. Four patients had axial bone sarcoidosis.

**Conclusion:** sacroiliitis, SpA, and degenerative changes of the SIJ have been highlighted by AP-CT in patients with sarcoidosis. Osteoarthritis of the SIJ in sarcoidosis was associated with age, pregnancy, and rural lifestyle. Further studies are needed to assess the link between SpA and sarcoidosis.

Accepted manuscript

**Title:** Sacroiliac joint in sarcoidosis on computed tomography: a monocentric retrospective study (SISTER)

**Keywords:** sarcoidosis, sacroiliitis, sacroiliac joint, spondyloarthritis, computed tomography, osteoarthritis

**Highlights:**

Sacroiliitis by computed tomography is rare relative to the higher proportion of sacroiliitis found by x-ray and MRI reported in the literature.

In patients with sarcoidosis, sacroiliitis is generally associated with concomitant spondyloarthritis rather than being true sarcoidotic sacroiliitis.

Osteoarthritis of the sacroiliac-joints is more frequent with age and pregnancy and is associated with a rural lifestyle.

Osteoarthritis of the sacroiliac joints may explain overestimation of sacroiliitis in previous publications by MRI and x-ray imaging.

## **Abstract**

**Objectives:** Sacroiliitis and spondyloarthritis (SpA) have been associated to sarcoidosis. Sarcoidosis bone involvement of the sacral or iliac bones has been reported to mimic SpA. We aimed to evaluate the prevalence of structural sacroiliitis and structural changes of the sacroiliac joints (SIJ) in patients with sarcoidosis by abdominal-pelvic computed tomography (AP-CT).

**Methods:** In this monocentric retrospective study, three blinded readers evaluated AP-CT that had already been performed on patients with sarcoidosis and classified them as normal, degenerative, or inflammatory. A consensus was reached for the divergent cases. Erosion, ankylosis, and sclerosis, classically associated with sacroiliitis, were noted. SpA was defined according to the ASAS 2009 classification criteria.

**Results:** We identified 217 patients with proven sarcoidosis who underwent AP-CT. Only three patients had sacroiliitis by CT and four had SpA, representing 1.38% and 1.85% of the patients, respectively. Degenerative SIJs represented 28.1% of patients and were significantly associated with age, at least one pregnancy, rural lifestyle, ankylosis, diffuse idiopathic skeletal hyperostosis, sclerosis, and the presence of osteophytes. Four patients had axial bone sarcoidosis.

**Conclusion:** sacroiliitis, SpA, and degenerative changes of the SIJ have been highlighted by AP-CT in patients with sarcoidosis. Osteoarthritis of the SIJ in sarcoidosis was associated with age, pregnancy, and rural lifestyle. Further studies are needed to assess the link between SpA and sarcoidosis.

## **1. Introduction**

Sarcoidosis is a granulomatous disease of unknown origin [1]. The most common localization is the lungs, but granulomas can affect all organs, including the skin, lymphoid system, eyes, and liver [1]. Musculoskeletal involvement is found in 4 to 38% of patients [2], consisting of either an acute form, such as Löfgren's syndrome, or chronic arthropathy, with a synovial granuloma. Bones are involved in 3 to 5% of cases [3].

Sacroiliac joint (SIJ) involvement is classic in sarcoidosis and is reported in most textbooks [4]. Despite such occurrence, only very few studies have truly described it or its incidence. By definition, sacroiliitis is characterized by inflammation of the sacroiliac joint (SIJ), and generally causes inflammatory low back and buttocks pain. The main cause of sacroiliitis is spondyloarthritis (SpA). Another important cause is septic arthritis of the sacroiliac joint [5], in this case, usually one-sided. Prevalence of sacroiliac osteoarthritis has been long underestimated even though it appears now to be the most frequent imaging lesion of these joints [6]. An incorrect diagnosis of sacroiliitis has been made in numerous cases, especially with magnetic resonance imaging (MRI) [6, 7]. CT is more accurate for the diagnosis of sacroiliitis when structural lesions are present [8].

Since the first case of ankylosing spondylitis (AS) associated with sarcoidosis described in 1951 by Verstraeten et al. [9], 39 case reports have been published but only three series have evaluated the prevalence of sacroiliitis in sarcoidosis in different back-pain populations [10, 11] by X-ray or MRI. In this study, we aimed to evaluate the prevalence of sacroiliitis and specify the type of SIJ involvement in sarcoidosis through available abdominopelvic computed tomography (AP-CT) already performed on patients with proven sarcoidosis.

## **2. Methods**

### **2.1 Study sample**

Patient identification was performed anonymously using eHOP software [12], which allowed anonymous and blind consultation of the medical records of Rennes University Hospital. All patients of the hospital with the word "sarcoidosis" in their medical files between January 1, 2011 and December 31, 2017 were screened. Patients with a diagnosis of sarcoidosis according to the ATS/ERG/WASOG criteria [13] and histological confirmation of granuloma (except for Löfgren's syndrome) were eligible. An AP-CT or CT of positron emission tomography (PET) had to be available in the Picture Archiving and Communication System (PACS). Patient

identification was also performed using a register from the pneumology department, a national competence centre for pulmonary sarcoidosis and interstitial lung diseases. An information letter was sent to all participants. The Ethics Committee of Rennes University Hospital approved the study (number 19.19 on February 10, 2019).

## **2.2 Computed tomography and reading of the images**

CT scans were carried out during routine care at Rennes University Hospital and four other imaging centres, then sent to the PACS. The most commonly used matrix was a 512 x 512 resolution and a soft tissue filter with a bone window setting was used for reading. However, the X-ray energy delivered, slice thickness, and interval between slices varied. Nevertheless, AP-CT with slice thicknesses of 1.25 mm showed good diagnostic relevance (Sensitivity (Se) of 71.4% and Specificity (Sp) of 100%) relative to a specific SIJ CT scan for the analysis of SIJs in a previous study [14]. In another study, AP-CT with a slice thickness of 5 mm was shown to be a promising screening tool for sacroiliitis [15].

Three readers independently evaluated the CT scans. Patients were diagnosed with inflammatory, degenerative, normal, or unknown/doubtful SIJs on semi-coronal and semi-axial reconstructions. The primary outcome was a diagnosis of inflammation of the SIJ by CT according to the three readers. They collected data on changes associated with sacroiliitis in the cartilaginous compartment in the semi-coronal view, as suggested by Chan and Melchior [14–16], in iliac and sacral bones on the right and left sides as follows:

- Erosions, defined as a clear outbreak of  $\geq 2$  mm in the SIJ.
- Sclerosis, measured in millimetres in the semi-coronal view.
- Ankylosis, partial or complete, defined as contiguous bone marrow between the iliac and sacral bones.

The secondary outcome was other changes of the SIJ, such as degenerative changes. Joint space narrowing defined by a focal narrow of the SIJ of asymmetrical joint width was noticed, as well as osteophytes defined by a bone proliferation next to SIJ. SIJs were classified as degenerative according to the reader's opinion in case of SIJ narrowing, osteophytes, sclerosis or non-inflammatory ankylosis. Discrepant cases were classified with consensus in case of disagreement or unknown/doubtful diagnosis. Intra-reader reproducibility was tested by having the three readers twice evaluate 15 CT scans excluded from the cohort study after at least two months between the two reading sessions.



## 2.3 Data collection

The demographic data collected were: age, ethnicity, gender, with the number of pregnancies for women, body mass index (BMI) at diagnosis, rural or urban lifestyle (a rural lifestyle was designated for patients outside of urbanized areas with a population of < 2,500 people [17]), smoking, and alcohol abuse. The clinical data collected for sarcoidosis were histological proof or Löfgren's syndrome and the organs involved. Other inflammatory and auto-immune diseases were noted, with a special focus on SpA. Clinical, imaging data and HLA B27 status of axial or peripheral SpA were also retrieved.

Available biological data were also gathered: serum calcium concentration (2.26 - 2.62 mmol/l), lymphocyte count (1.0 - 4.0 G/L), angiotensin converting enzyme concentration (ACE, 20 - 70 U/l), C reactive protein concentration (CRP, < 5 mg/l), and immunoglobulin level (8.0 – 13.5 g/l) [18]. At baseline, chest X-rays with pulmonary staging from 0 (normal) to 4 (fibrosis) were collected, as well as pulmonary function test (forced expiratory volume in on second-VEF1, total lung capacity-TLC, and diffusing capacity of the lung for carbon monoxide-DLCO) and broncho-alveolar lavage (BAL) (hyperlymphocytosis and CD4/CD8 ratio) data. We also collected treatment data on the duration of glucocorticoid therapy (in months), estimated cumulative doses in prednisone equivalent grams, and other immunosuppressive therapy, as well as data on the duration of follow-up (in months), relapses, and deaths (related to sarcoidosis or not).

## 2.4 Statistical analysis

Quantitative variables are presented as mean  $\pm$  SD and comparisons analysed using Mann-Whitney Wilcoxon tests or Student t-tests when appropriate. Qualitative variables were analysed using Fisher's exact test or chi-square tests. A  $p$  value < 0.05 was considered to be statistically significant. Agreement between readers was calculated using the kappa test.

# 3. Results

## 3.1 Characteristics of the study population

In total, 314 patients were selected from a pre-existing register of sarcoidosis from the Pneumology Department. Using eHOP software [12], 2,991 additional anonymized patients from the entire hospital were pre-selected. The flow chart is presented in **Figure 1**. Characteristics of the 217 patients (434 SIJ analysed) finally included in this study are summarized in **Table 1**.

Histological evidence of granuloma was obtained for 91.2% of the cases (see **Supplementary Data S1** for more details). Phenotypes of the 217 sarcoidosis patients are summarized in **Table 2**. During the mean follow-up of 5.5 years ( $\pm 5.1$ ), 51/217 (23.5%) patients did not require treatment, except for occasional non-steroidal anti-inflammatory drugs (NSAIDs) use for joint pain.

### 3.2 Sacroiliac joints on computed tomography

According to our structural definition, bilateral sacroiliitis on CT was found in three patients (1.38%) after agreement between the three readers. In addition, four patients had SpA according to their medical records (1.84%), among whom two had sacroiliitis and three, HLA B27 antigen. Due to the small number of patients with sacroiliitis or SpA, no statistical analysis between the sacroiliitis and non-sacroiliitis groups nor SpA and non-SpA groups was done. Sixty-one (28.1%) patients had degenerative SIJs and they were normal for 153 (70.5%). The clinical characteristics of the inflammatory, normal, and degenerative subgroups are summarized in **Table 3**. The frequency of osteoarthritis of the SIJ was higher in older patients and in women who had had at least one pregnancy. The age-stratified frequency of degenerative SIJs is shown in **Figure 2**. Intriguingly, patients with degenerative SIJs lived significantly more often in rural areas. There was no association between degenerative changes and sarcoidosis phenotypes, biology, or treatment.

Among the 217 patients, four had a medical history of SpA before sarcoidosis, including two with sacroiliitis on CT scans (see **Supplementary Data Table 1**). The two others had degenerative SIJ according to our evaluation. One patient with sacroiliitis on CT had no medical history of SpA. She suffered from chronic truncated sciatica with “mixed” chronic low back pain, had Crohn’s disease, and had a familial history of SpA. Her HLA B27 status was unknown (see **Supplementary Data Figure 1**). The five cases with sacroiliitis and/or SpA are summarized in **Table 4**. Five patients had a diagnosis of bone granulomatous disease in their chart, four with axial involvement of the iliac or sacral bones. However, specific images were not available.

The mean age at the time of CT assessment was  $49.7 \pm 15.7$  years. The duration of sarcoidosis at the time of the AP-CT was  $5.3 \pm 7.4$  years; 79.3% of patients had active disease at the time of the CT. The optimal slice thickness to study SIJ based on the literature is between 1.25 and 5.0 mm [14, 15]. In this study, the mean slice thickness ( $\pm$  SD) was  $1.85 \pm 0.83$  mm:  $\leq 1.25$  mm in 35.9% and  $> 5$  mm in 0.9% of the AP-CT scans. Inter-reader agreement for the diagnosis

of sacroiliitis was moderate, with  $k = 0.49$  (0.21; 0.78). The reliability of the sacroiliitis diagnosis appeared to be weaker than that for non-inflammatory SIJ. The kappa for inter-reader reproducibility for ankylosis, erosions, and sclerosis was 0.81 (0.65-0.97), 0.11 (-0.01-0.24), and 0.28 (0.18-0.38), respectively. Inter-reader reproducibility for the diagnosis of normal and degenerative SIJ was low, with a kappa of 0.38 (0.28; 0.47) and 0.31 (0.21; 0.41), respectively. The kappa for intra-reader reproducibility of the SIJ diagnosis was 0.35 (-0.07;0.78), 0.57 (0.24; 0.90), and 0.46 (0.03; 0.90) for each reader, respectively.

## 4. Discussion

Sarcoidosis and SpA have been found to be associated in previous case reports and classically in textbooks but, in reality, only three studies have truly investigated this link [19–21]. In our study, the prevalence of sacroiliitis in non-selected sarcoidosis was 1.38%, 1.84% for SpA, 28.1% for degenerative SIJ, and 70.5% for normal SIJ. This is the first study to evaluate the prevalence of sacroiliitis and SpA in sarcoidosis using AP-CT.

SIJ abnormalities and sarcoidosis can be associated in several ways [10]. First, it can occur as an inflammatory manifestation with an association between SpA and sarcoidosis. A nationwide study in Taiwan showed that patients with sarcoidosis developed SpA more easily than the general population (Odds Ratio: 3.80 [2.42-5.97]) [22]. The positivity of HLA B27 in sarcoidosis is 0% and 25% in patients with sacroiliitis for Kobak et al. [20] and Erb et al. [19], respectively, 7.1% in patient with sarcoidosis and chronic back pain for Sigaux et al [21]. However, the imaging modality used for the diagnosis of sacroiliitis in most of the studies was X-ray [10, 19, 20], which is difficult to read and can lead to potential misdiagnoses. For example, degenerative changes in the antero-inferior ligamentous compartment of the SIJ can be classified as bilateral grade 2 sacroiliitis [23] according to the modified New York (mNY) criteria [24]. Sigaux et al. [21] recently reported that sacroiliitis and SpA are associated with sarcoidosis in cases of inflammatory back pain. The SpA diagnosis was established according to ASAS 2009 classification criteria for sacroiliitis [25]) mainly with bone marrow oedema (BMO) found by MRI, which is now known to overestimate sacroiliitis [26].

Using MRI, Sigaux et al. [21] found a higher prevalence of sacroiliitis and SpA than we did, 3.9% and 4.5%, respectively, in a wider sample of 334 patients with sarcoidosis. MRI of SIJ was performed only in patients with inflammatory back pain and therefore no direct comparison can be made with pain-free patients or those with mechanical back pain. In their study, only five patients had concomitant radiographic sacroiliitis among those with sacroiliitis by MRI

(38.5%). Radiographic sacroiliitis in the study of Sigaux et al. therefore represented 1.49% of the patients with sarcoidosis, which is close to our estimation by CT. With X-ray, Erb et al. [19] estimated the prevalence of sacroiliitis in sarcoidosis to be 6.6%, 8.2% in a “back-pain” subgroup and 12.9% in an IBP subgroup. Kobak et al. [20] found a higher prevalence of sacroiliitis, 14.3% in sarcoidosis and 43% in an IBP subgroup. For these two latter studies, there was a selection bias, because only patients with back pain (and sarcoidosis) were referred to the rheumatology department.

These differences may also be explained by differences between the studied populations. Our study showed a higher rate of extra-thoracic sites of the disease than that of Sigaux et al. [21]; there were also more men and more patients of Caucasian origin. The geographical origin was not the same for the three studies, which were conducted in France [21], Turkey [20], and in the United Kingdom [19]. This may have influenced the genetic background such as HLA B27 antigen or HLA DRB1\*03 which is, when absent, associated with a chronic course of sarcoidosis after Löfgren’s syndrome [27]. The mean duration of sarcoidosis was shorter in our study (5.8 years) than in those of Sigaux et al. [21] and Erb et al. [19] (12.2 and 9.1 years, respectively), which may have resulted in a smaller number of lesions. The mean age at the time of the MRI [21] or X-ray [19, 20] was similar. The duration of back pain was only mentioned in the study of Sigaux et al. and was, on average,  $3.6 \pm 5.6$  years in the inflammatory back pain group. It would have been informative to know the average duration of low back pain in the other studies. Indeed, the onset of symptoms classically occurs approximately nine years before radiographic lesions of sacroiliitis become apparent [28]. Overall, the characteristics of our non-selected sarcoidosis population appear to be very similar to those of the populations of patient with sarcoidosis [29], except for male predominance and a low prevalence of Löfgren’s syndrome.

The prevalence of sacroiliitis in sarcoidosis we found is comparable to that found on CT scans in the general asymptomatic population, which was 1.14% in a recent study published by Slobodin et al. [30]. The lower sensitivity of AP-CT relative to specific SIJ-CT may have led us to slightly underestimate the prevalence of sacroiliitis. In a recent meta-analysis, the worldwide prevalence of SpA was estimated to be from 0.20 to 1.61% [31], which is lower than the 1.84% in our study.

Imaging is the cornerstone for the diagnosis of sacroiliitis and is an important component in the diagnosis of SpA. The scoring system of New York criteria [24] from grade 0 (normal SIJ) to grade 4 (complete ankylosis) has been widely used since 1973. However, inter-reader reproducibility of pelvic X-rays for the diagnosis of sacroiliitis is low to moderate, with kappa ranging from 0.39 to 0.45 [14, 23]. This could partially explain the higher prevalence of sacroiliitis in previous studies using X-rays. Yazici et al. [32] found that the higher the proportion of AS is in a population, the better is the reproducibility of X-rays. In our study, the kappa value of inter-reader reproducibility for the diagnosis of sacroiliitis on CT scans was 0.49 in a population with a low prevalence of SpA, which may have decreased the reproducibility. The two-dimensional view of X-ray images can lead to the misdiagnosis of degenerative changes in the antero-inferior ligamentous compartment of the SIJ as sacroiliitis, and may explain the overestimation of sacroiliitis in sarcoidosis in previous publications [19, 20]. Although, pelvic X-rays is still an important component of the current ASAS 2009 classification criteria.

CT scans were used for SIJ assessment in our study. CT in SpA was surprisingly left out of the ASAS 2009 and EULAR 2015 recommendations [25, 33]. It is only recommended in suspected nr-SpA if MRI is not available. CT is less costly and more accessible than MRI, but it is an irradiating imaging modality. However, AP-CT may have already been performed on patients for another reason, becoming an interesting tool for screening sacroiliitis. For example, SIJ on CT scans have been well studied in inflammatory bowel diseases, and revealed 67% underdiagnosed sacroiliitis [34]. CT is more sensitive than X-ray and detected sacroiliitis in 10/14 patients with SpA who had had back-pain for two years, whereas X-ray detected it in only 2/14 [35]. Three variables on CT scans are classically associated with sacroiliitis: (1) ankylosis, which is very specific but usually present late in the course of the disease and can sometimes be present without inflammation [15, 36], as observed for seven patients in our study; (2) erosions, defined as a clear outbreak in the SIJ, with a high specificity for sacroiliitis when  $\geq 3$  erosions are present [15]; and (3) sclerosis, which is less specific, with low inter-reader reproducibility [15]. Joint-space width alone is not of high relevance: joint space decreases with age, gender, pregnancies, and BMI [37] and suffers from very low inter-reader reproducibility [15]. In an early publication, Melchior et al. [16] also demonstrated that CT is superior to X-ray for the diagnosis of sacroiliitis. For patients with suspected SpA, the mean time interval between normal SIJ and the onset of sacroiliitis on CT scans is 5.5 years [38], which is shorter than the mean time of 9 years with X-ray [28].

In a study on SIJ [14], Melchior et al. used SIJ-CT as a reference for 58 patients with SpA and found a sensitivity of 85.7% and a specificity of 82.6% for SIJ-MRI, whereas they were 71.4% and 100%, respectively, for AP-CT, the method we used here. Several studies showed equal efficacy of MRI and CT for detecting sclerosis and erosion, but others suggested that CT may even be better [39]. Nonetheless, only MRI can visualize the inflammatory changes in the SIJ before other changes become visible by CT. Moreover, Geijer et al. [40] showed that CT scans of patients aged under 30 years provided better inter-reader reproducibility than those of patients over 50. This was probably due to the higher proportion of osteoarthritis of the SIJ with increasing age [41], which could also be a limitation in the use of CT for screening for sacroiliitis.

Nowadays, MRI is considered to be the gold standard for SIJ imaging and offers an alternative modality for the diagnosis of SpA. BMO is one of the main features of SIJ-MRI for the early diagnosis of sacroiliitis and is often the only lesion found. Baraliakos et al. [26] recently found that 17.2% of healthy subjects with BMO fulfilled the ASAS criteria. BMO can also be present in early and late post-partum and occupational activities that involve mechanical stress on SIJ, such as those practiced by athletes or military recruits. This leads to reconsideration of the border between inflammatory and degenerative changes of the SIJ detected by MRI. Thus, as stated in previous publications, “not everything that glitters is gold (standard)” [7].

We found significantly more rural patients in the degenerative SIJ group than normal SIJ group. Lack of data concerning occupational behaviour and daily life activities makes it difficult to interpret this difference. Osteoarthritis of the SIJ is nevertheless an important cause of SIJ symptoms and damage on imaging, as shown in 4.3% of patients with SIJ-MRI assessed for sacroiliitis [6].

SIJ involvement in sarcoidosis can also be due to iliac or sacral bone localisation of the disease [10]. Axial or SIJ involvement is probably underestimated because of asymptomatic cases of bone disease (50%) [42]. The one-sided presentation in most cases should otherwise result in an investigation of sepsis [5]. True granulomatous synovial involvement of the SIJ independently of SpA may also theoretically occur, similarly to chronic peripheral musculoskeletal involvement [43]. No case with histological evidence has yet been described.

In our study, sacroiliitis and SpA in patients with sarcoidosis cannot be compared to the prevalence of general population in absence of control group. Moreover, the retrospective design using imaging to detect sacroiliitis and SpA without clinical features, such as chronic low back pain, is one of the main limitations of this study. Another is recruiting patients by AP-CT which consist in a selection bias.

Although so-called “typical” findings of sacroiliitis can be found by MRI, there is an increasing awareness of potential pitfalls and inflammatory changes that are not related to sacroiliitis such as age, gender and pregnancy, daily activities and occupational behaviour, being overweight, and various anatomical variations. CT may help to describe osteoarthritis of the SIJ, thus avoiding misclassifying patients as having SpA. Although CT is not currently recommended for the diagnosis of SpA for detecting sacroiliitis, increasing evidence suggests its usefulness to assess true structural changes. However, standardized reading recommendations for the diagnosis of sacroiliitis are needed. Such questions concerning the limits of sacroiliac imaging in sacroiliitis also move clinical features back to the centre of SpA diagnosis. A multimodal approach for the SIJ may be the key to providing a reliable diagnosis of sacroiliitis, with CT coupled to MRI in difficult cases.

Finally, the prevalence of sacroiliitis found in sarcoidosis is of 1.38% on AP-CT. Heterogeneity of prevalence estimates in the literature depends on the imaging modality (i.e. X-ray, MRI, or CT) and clinical condition (or patient’s selection), such as low back pain. Thus, association of sarcoidosis with sacroiliac disease or SpA should be reconsidered. SIJ pain or damage in sarcoidosis viewed by imaging may be linked to the disease itself (bone or joint location), spondyloarthritis, or related to degenerative changes of SIJ. We describe the prevalence of SIJ degeneration in sarcoidosis for the first time. It appears to be higher with age, pregnancies, and for patients living in rural areas. Further studies are needed to confirm and explain this last finding.

#### **Declarations of interest**

The authors have no conflict of interest to declare for this work. This research did not receive any specific grant from funding agencies in the public, commercial, or not-for-profit sectors.

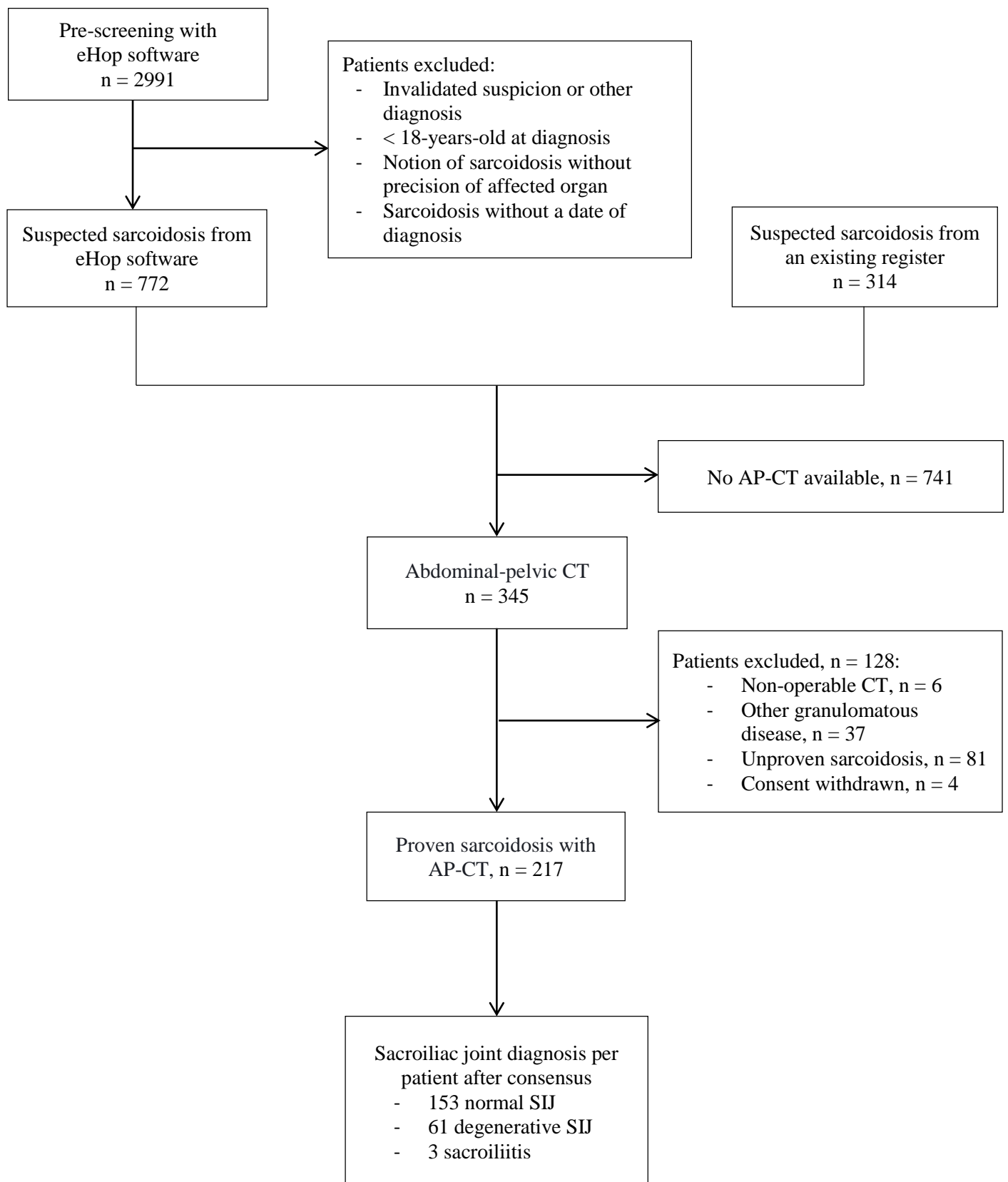
1. Valeyre D, Prasse A, Nunes H, et al (2014) Sarcoidosis. *Lancet* 383:1155–1167. [https://doi.org/10.1016/S0140-6736\(13\)60680-7](https://doi.org/10.1016/S0140-6736(13)60680-7)
2. Goussault C, Albert J-D, Coiffier G, et al (2018) Ultrasound characterization of ankle involvement in Löfgren syndrome. *Joint Bone Spine* 85:65–69. <https://doi.org/10.1016/j.jbspin.2017.03.004>
3. Zhou Y, Lower EE, Li H, et al (2017) Clinical characteristics of patients with bone sarcoidosis. *Semin Arthritis Rheum* 47:143–148. <https://doi.org/10.1016/j.semarthrit.2017.02.004>
4. Bechman K, Galloway, James, Pouchot, Jacques (2019) Miscellaneous inflammatory arthritides: Adult Still's disease, Sarcoidosis, Palindromic rheumatism, Paraneoplastic arthritis, Hypertrophic osteoarthropathy. In: *EULAR on-line course on Rheumatic Diseases*. p 36
5. Sondag M, Gete K, Verhoeven F, et al (2019) Analysis of the early signs of septic sacroiliitis on computed tomography. *Eur J Rheumatol* 6:122–125. <https://doi.org/10.5152/eurjrheum.2019.18209>
6. Eshed I, Lidar M (2017) MRI Findings of the Sacroiliac Joints in Patients with Low Back Pain: Alternative Diagnosis to Inflammatory Sacroiliitis. *Isr Med Assoc J* 19:666–669
7. Lukas C, Cyteval C, Dougados M, Weber U (2018) MRI for diagnosis of axial spondyloarthritis: major advance with critical limitations “Not everything that glisters is gold (standard).” *RMD Open* 4:e000586. <https://doi.org/10.1136/rmdopen-2017-000586>
8. Tsoi C, Griffith JF, Lee RKL, et al (2019) Imaging of sacroiliitis: Current status, limitations and pitfalls. *Quant Imaging Med Surg* 9:318–335. <https://doi.org/10.21037/qims.2018.11.10>
9. Verstraeten, J.M., Bekaert, J. (1951) Association de spondylite ankylosante et de sarcoidose. *Acta Tuberc Belg* 42:149–151
10. Cadiou S, Robin F, Guillin R, et al (2020) Spondyloarthritis and sarcoidosis: related or fake friends? A systematic literature review. *Joint Bone Spine* 87:579–587. <https://doi.org/10.1016/j.jbspin.2020.06.011>
11. Uslu S (2020) Sacroiliitis in sarcoidosis mimicking ankylosing spondylitis. *Rheumatology (Oxford)*. <https://doi.org/10.1093/rheumatology/keaa445>
12. Bouzillé G, Sylvestre E, Campillo-Gimenez B, et al (2015) An Integrated Workflow For Secondary Use of Patient Data for Clinical Research. *Stud Health Technol Inform* 216:913
13. Costabel U, Hunninghake GW (1999) ATS/ERS/WASOG statement on sarcoidosis. Sarcoidosis Statement Committee. American Thoracic Society. European Respiratory Society. World Association for Sarcoidosis and Other Granulomatous Disorders. *Eur Respir J* 14:735–737. <https://doi.org/10.1034/j.1399-3003.1999.14d02.x>
14. Melchior J, Azraq Y, Chary-Valckenaere I, et al (2017) Radiography, abdominal CT and MRI compared with sacroiliac joint CT in diagnosis of structural sacroiliitis. *Eur J Radiol* 95:169–176. <https://doi.org/10.1016/j.ejrad.2017.08.004>

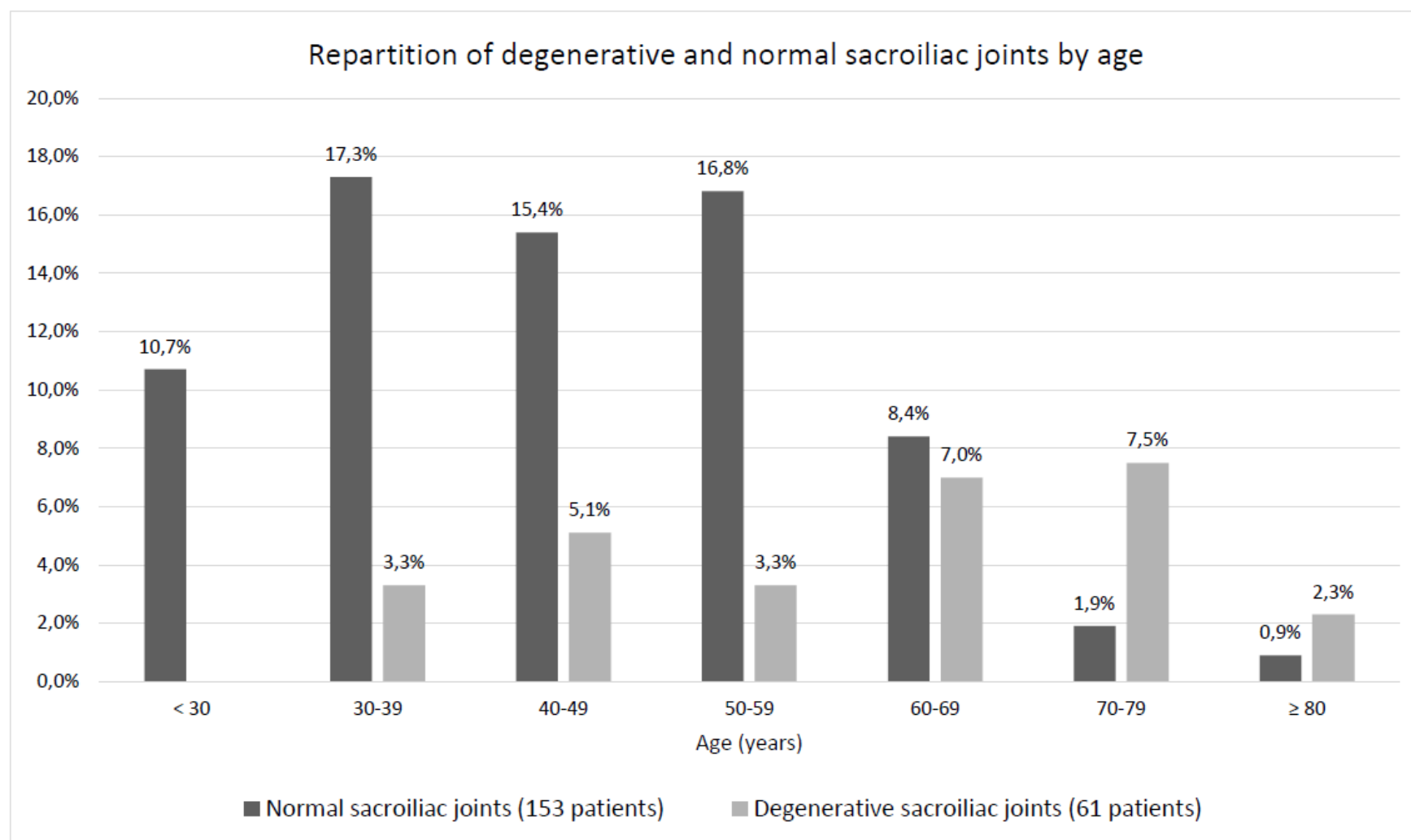


15. Chan J, Sari I, Salonen D, et al (2016) Development of a Screening Tool for the Identification of Sacroiliitis in Computed Tomography Scans of the Abdomen. *J Rheumatol* 43:1687–1694. <https://doi.org/10.3899/jrheum.150939>
16. Melchior J, Azraq Y, Chary-Valckenaere I, et al (2017) Radiography and abdominal CT compared with sacroiliac joint CT in the diagnosis of sacroiliitis. *Acta Radiol* 58:1252–1259. <https://doi.org/10.1177/0284185116688377>
17. Hart LG, Larson EH, Lishner DM (2005) Rural Definitions for Health Policy and Research. *Am J Public Health* 95:1149–1155. <https://doi.org/10.2105/AJPH.2004.042432>
18. Belhomme N, Jouneau S, Bouzillé G, et al (2018) Role of serum immunoglobulins for predicting sarcoidosis outcome: A cohort study. *PLoS One* 13:. <https://doi.org/10.1371/journal.pone.0193122>
19. Erb N, Cushley MJ, Kassimos DG, et al (2005) An assessment of back pain and the prevalence of sacroiliitis in sarcoidosis. *Chest* 127:192–196. <https://doi.org/10.1378/chest.127.1.192>
20. Kobak S, Sever F, Ince O, Orman M (2014) The prevalence of sacroiliitis and spondyloarthritis in patients with sarcoidosis. *Int J Rheumatol* 2014:289454. <https://doi.org/10.1155/2014/289454>
21. Sigaux J, Semerano L, Nasrallah T, et al (2019) High prevalence of spondyloarthritis in sarcoidosis patients with chronic back pain. *Semin Arthritis Rheum* 49:246–250. <https://doi.org/10.1016/j.semarthrit.2019.03.006>
22. Wu C-H, Chung P-I, Wu C-Y, et al (2017) Comorbid autoimmune diseases in patients with sarcoidosis: A nationwide case-control study in Taiwan. *J Dermatol* 44:423–430. <https://doi.org/10.1111/1346-8138.13654>
23. Christiansen AA, Hendricks O, Kuettel D, et al (2017) Limited Reliability of Radiographic Assessment of Sacroiliac Joints in Patients with Suspected Early Spondyloarthritis. *J Rheumatol* 44:70–77. <https://doi.org/10.3899/jrheum.160079>
24. van der Linden S, Valkenburg HA, Cats A (1984) Evaluation of diagnostic criteria for ankylosing spondylitis. A proposal for modification of the New York criteria. *Arthritis Rheum* 27:361–368
25. Rudwaleit M, van der Heijde D, Landewé R, et al (2009) The development of Assessment of SpondyloArthritis international Society classification criteria for axial spondyloarthritis (part II): validation and final selection. *Ann Rheum Dis* 68:777–783. <https://doi.org/10.1136/ard.2009.108233>
26. Baraliakos X, Richter A, Feldmann D, et al (2020) Frequency of MRI changes suggestive of axial spondyloarthritis in the axial skeleton in a large population-based cohort of individuals aged <45 years. *Ann Rheum Dis* 79:186–192. <https://doi.org/10.1136/annrheumdis-2019-215553>
27. Grunewald J, Eklund A (2009) Löfgren’s syndrome: human leukocyte antigen strongly influences the disease course. *Am J Respir Crit Care Med* 179:307–312. <https://doi.org/10.1164/rccm.200807-1082OC>

28. Mau W, Zeidler H, Mau R, et al (1988) Clinical features and prognosis of patients with possible ankylosing spondylitis. Results of a 10-year followup. *J Rheumatol* 15:1109–1114
29. Ungprasert P, Carmona EM, Utz JP, et al (2016) Epidemiology of Sarcoidosis 1946-2013: A Population-Based Study. *Mayo Clin Proc* 91:183–188.  
<https://doi.org/10.1016/j.mayocp.2015.10.024>
30. Slobodin G, Croitoru S, Starikov N, et al (2012) Incidental computed tomography sacroiliitis: clinical significance and inappropriateness of the New York radiological grading criteria for the diagnosis. *Clin Rheumatol* 31:425–428. <https://doi.org/10.1007/s10067-011-1871-6>
31. Stolwijk C, van Onna M, Boonen A, van Tubergen A (2016) Global Prevalence of Spondyloarthritis: A Systematic Review and Meta-Regression Analysis. *Arthritis Care Res (Hoboken)* 68:1320–1331. <https://doi.org/10.1002/acr.22831>
32. Yazici H, Turunç M, Ozdoğan H, et al (1987) Observer variation in grading sacroiliac radiographs might be a cause of “sacroiliitis” reported in certain disease states. *Ann Rheum Dis* 46:139–145
33. Mandl P, Navarro-Compán V, Terslev L, et al (2015) EULAR recommendations for the use of imaging in the diagnosis and management of spondyloarthritis in clinical practice. *Ann Rheum Dis* 74:1327–1339. <https://doi.org/10.1136/annrheumdis-2014-206971>
34. Kelly OB, Li N, Smith M, et al (2018) The Prevalence and Clinical Associations of Subclinical Sacroiliitis in Inflammatory Bowel Disease. *Inflamm Bowel Dis*.  
<https://doi.org/10.1093/ibd/izy339>
35. Geijer M, Sihlbom H, Göthlin JH, Nordborg E (1998) The role of CT in the diagnosis of sacroiliitis. *Acta Radiol* 39:265–268
36. El Rafei M, Badr S, Lefebvre G, et al (2018) Sacroiliac joints: anatomical variations on MR images. *Eur Radiol* 28:5328–5337. <https://doi.org/10.1007/s00330-018-5540-x>
37. Demir M, Mavi A, Gümüşburun E, et al (2007) Anatomical variations with joint space measurements on CT. *Kobe J Med Sci* 53:209–217
38. Geijer M, Gadeholt G, Göthlin JH (2013) Diagnosis and progression of sacroiliitis in repeated sacroiliac joint computed tomography. *Arthritis* 2013:659487.  
<https://doi.org/10.1155/2013/659487>
39. Zhang P, Yu KH, Guo RM, et al (2016) Comparing the diagnostic utility of sacroiliac spectral CT and MRI in axial spondyloarthritis. *Br J Radiol* 89:20150196.  
<https://doi.org/10.1259/bjr.20150196>
40. Geijer M, Göthlin GG, Göthlin JH (2007) Observer variation in computed tomography of the sacroiliac joints: a retrospective analysis of 1383 cases. *Acta Radiol* 48:665–671.  
<https://doi.org/10.1080/02841850701342146>
41. Eno J-JT, Boone CR, Bellino MJ, Bishop JA (2015) The prevalence of sacroiliac joint degeneration in asymptomatic adults. *J Bone Joint Surg Am* 97:932–936.  
<https://doi.org/10.2106/JBJS.N.01101>

42. Sparks JA, McSparron JI, Shah N, et al (2014) Osseous sarcoidosis: clinical characteristics, treatment, and outcomes--experience from a large, academic hospital. *Semin Arthritis Rheum* 44:371–379. <https://doi.org/10.1016/j.semarthrit.2014.07.003>
43. Kollert F, Hadiprasetya ML, Probst C, et al (2012) Clinical images: Multilocular tenosynovitis as a manifestation of sarcoidosis. *Arthritis Rheum* 64:326. <https://doi.org/10.1002/art.33387>

**Figure 1.** Flow-chart of the SISTER study

**Figure 2.** Repartition of degenerative and normal sacroiliac joints by age

Accepted manuscript

**Table 1.** Characteristics of the 217 patients with sarcoidosis.

<b>General characteristics</b>	
Female, n (%)	100 (46.1%)
• Nulliparous (%)	9.5%
• Mean number of pregnancies, n ( $\pm$ SD)	2.4 ( $\pm$ 1.6)
Mean age at diagnosis in years ( $\pm$ SD)	44.4 ( $\pm$ 15.1)
Smoking, n (%)	95/202 (47%)
• Active / Stopped at diagnosis	50 (55.6%) / 40 (44.4%)
Body Mass Index at diagnosis, kg/m <sup>2</sup> ( $\pm$ SD)	26.7 ( $\pm$ 5.5)
• Overweight, 25 to 30 kg/m <sup>2</sup> , n (%)	62/178 (34.8%)
• Obesity, > 30 kg/m <sup>2</sup> (%)	40/178 (22.5%)
Rural lifestyle (%)	74/217 (34.1%)
Geographical origin, n (%)	
• European	184 (84.8%)
• Afro-Caribbean	20 (9.2%)
• North-African	3 (1.4%)
• Asian	10 (4.6%)
Autoimmune and chronic inflammatory diseases (%)	37/217 (17.1%)
<b>Sarcoidosis phenotypes</b>	
Clinical features	
• Limited to the thorax / extra-thoracic, n (%)	56 (25.8%) / 161 (74.2%)
• Multi-visceral sarcoidosis ( $\geq$ 3 organs), n (%)	96/217 (44.2%)
Biological features at diagnosis*	
• C reactive protein, mg/l ( $\pm$ SD)	22.2 ( $\pm$ 38.2)
• ACE, IU/L ( $\pm$ SD)	40 ( $\pm$ 46)
• Blood calcium, mmol/l ( $\pm$ SD)	2.42 ( $\pm$ 0.27)
• Lymphocytes, G/l ( $\pm$ SD)	1.24 ( $\pm$ 0.60)
• Immunoglobulin level, g/l ( $\pm$ SD)	12.67 ( $\pm$ 4.26)
Pulmonary Function Tests (% Pred)	
• TLC (on 151 patients, $\pm$ SD)	95.6 % ( $\pm$ 17.3)
• FEV1 (on 159 patients, $\pm$ SD)	94.1 % ( $\pm$ 19.3)
• DLCO (on 156 patients, $\pm$ SD)	69.7 % ( $\pm$ 16.7)
Bronchoalveolar lavage	
• Hyperlymphocytosis, n (%)	49/71 (69.0%)
• CD4/CD8 ratio (on 49 patients, $\pm$ SD)	6.28 ( $\pm$ 5.74)
<b>Treatments and evolution</b>	
Glucocorticoids, n (%)	155/217 (71.4%)
• Mean duration in years (on 153 patients, $\pm$ SD)	45 ( $\pm$ 51)
• Mean cumulative dose ( $\pm$ SD)**	14.78 ( $\pm$ 11.17)
Other immunosuppressive treatments, n (%)	
• Methotrexate	45 (20.7%)
• Hydroxychloroquine	24 (11.1%)
• Anti TNF $\alpha$	8 (3.7 %)
• Others	26 (12.0%)
Death during follow-up, n (%)	11 (5.1%)

ACE = Angiotensin Converting Enzyme; DLCO = Diffusion Capacity of Lungs for Carbon Monoxide; FEV1 = Forced Expired Volume in one second; TLC = Total Lung Capacity. \* incomplete data \*\* in prednisone-equivalent grams for 88 patients.

**Table 2.** Sarcoidosis phenotypes of the 217 patients.

<b>Thoracic involvement, n (%)</b>	197 (90.8%)
Mediastinal lymph nodes	186/213 (87.6%)
Lungs	141/211 (66.8%)
X-ray stage of 206 patients	
• 0	26 (12.6%)
• 1	80 (38.8%)
• 2	85 (41.3%)
• 3	9 (4.4%)
• 4	6 (2.9%)
<b>Extra-thoracic involvement, n (%)</b>	
Extra-thoracic lymph nodes	72 (33.2%)
Skin	68 (31.3%)
• Erythema nodosa	29/207 (14.0%)
• Skin sarcoids	24/207 (11.6%)
• Lupus pernio	12/207 (5.8%)
Joint	66 (30.4%)
• Inflammatory arthralgias	54 (24.9%)
• Löfgren's syndromes	26 (12.0%)
Eye	33 (15.2%)
Liver	31 (14.3%)
Ears-Nose-Throat	29 (13.4%)
• Salivary gland hypertrophy	17 (7.9%)
• Positive minor salivary gland	32/81 (39.5%)
Spleen	24 (11.1%)
Nervous system	22 (10.1%)
• Peripheral / Central	12 (5.5 %) / 11 (5.1%)
Hypercalcemia	17 (7.8%)
Kidney	15 (6.9%)
Heart	12 (5.5%)
Gastro-intestinal	7 (3.2%)
Muscles	7 (3.2%)
Bone	5 (2.3%)
• Peripheral / Axial	3 (1.4%) / 4 (1.9%)
Gynecological	2 (0.9%)

**Table 3.** Main characteristics of the three groups of patients.

	<b>Sacroiliitis, (n = 3)</b>	<b>Patients with degenerative sacroiliac joints, (n = 61)</b>	<b>Patients with normal sacroiliac joints, (n = 153)</b>	<b>p value *</b>
<b>Clinical data</b>				
Age at time of CT, years ( $\pm$ SD)	33.00 $\pm$ 5.57	61.03 $\pm$ 14.02	45.49 $\pm$ 13.57	< 0.0001
Female, n (%)	1 (33%)	31 (50.8%)	68 (44.4%)	0.40
Mean number of pregnancies, n ( $\pm$ SD)	1	2.8 $\pm$ 1.3	2.3 $\pm$ 1.6	0.098
Nulliparous, n (%)	1	0	8 (13.6%)	< 0.0001
BMI, kg/m <sup>2</sup> ( $\pm$ SD)	28.44 $\pm$ 6.35	27.75 $\pm$ 6.29	26.29 $\pm$ 5.15	0.23
Rural lifestyle, n (%)	1 (33%)	28 (45.9%)	45 (29.4%)	0.022
<b>Imaging data</b>				
Ankylosis, n (%)	1 (33%)	7 (11.5%)	1 (0.7%)	0.0007
Sclerosis, n (%)	2 (66%)	26 (42.6%)	8 (5.2%)	< 0.0001
Erosions, n (%)	2 (66%)	1 (1.6%)	0	-
Joint-space narrowing, n (%)	1 (33%)	4 (6.6%)	1 (0.7%)	0.02
Osteophytes, n (%)	0	21 (34.4%)	0 (0.0%)	< 0.0001

\*univariate analysis between degenerative and normal subgroups.




**Table 4.** Characteristics of sarcoidosis in five patients with sacroiliitis and/or SpA

Patient	Age at diagnosis / Sex	Evidence for sarcoidosis diagnosis	Sarcoidosis phenotypes	Treatments	Age at CT	Final diagnosis of SIJ on CT	Known SpA	Clinical features of SpA	SpA according to ASAS criteria	HLA B27	Imaging used for sacroiliitis diagnosis
n°1	33 / M	Extrathoracic lymph nodes	Lungs, thoracic and extrathoracic lymph nodes, submandibular salivary gland	Adalimumab *	34	Bilateral sacroiliitis	+	IBP, acute anterior uveitis	Axial	+	X-ray and MRI
n°2	27 / F	Löfgren's syndrome	Löfgren's syndrome	CTC	27	Bilateral sacroiliitis	-	Crohn's disease, chronic back pain	-	NR	CT
n°3	35 / M	Endobronchial biopsy	Lungs	CTC, MTX	38	Bilateral sacroiliitis	+	IBP, arthritis, psoriasis	Axial and peripheral	+	CT
n°4	37 / M	Mediastinal lymph nodes	Lungs, thoracic lymph nodes, and joints	None	48	Degenerative	+	Chronic polyarthralgia, calcaneal enthesitis, uveitis	Axial	-	X-ray (normal MRI)
n°5	39 / M	Mediastinal lymph nodes	Lungs and thoracic lymph nodes	CTC	39	Degenerative	+	IBP, familial history of SpA	Axial	+	X-ray

CTC: glucocorticoids, F: female; IBP: inflammatory back pain, M: male, MTX: methotrexate, MRI: magnetic resonance imaging, NR: not reported, SpA: spondyloarthritis. \*adalimumab was started to treat SpA in the first instance.



Accepted manuscript



[Click here to access/download](#)

**Electronic Supplementary Material**

Supp data CLRH.docx





Click here to access/download  
**Conflict Of Interest Form**  
AAuthorship disc form.pdf

